6th Edition

Bedside Clinics in Medicine

Part I

Long Short Spot Cases

Arup Kumar Kundu



Academic Publishers

Other Books by the Same Author

Bedside Clinics in Medicine, Part II

Fifth Edition

Highly practical and informative handbook with a comprehensive approach in questions and answers for MBBS students with oral and practical orientation, which deals with : Procedures and instruments, X-ray, ECG, emergency medicine, drugs, pathological specimens and data analysis (chart)

Published by :

KSP Udyog, 64 College Street, Kolkata-700 073, India
e-mail : kshovanp@yahoo.eom

MCQs in Internal Medicine

Third Edition

An indispensable revision tool for mastery in medicine with almost 2200 systematically arranged questions with single-choice answer covering major aspects of internal medicine, specially for UG students. It forms the foundation for success in different PG entrance examinations

Published by :

Paras Medical Publisher, Hyderabad-500 095, India
e-mail : parasmedpub@hotmail.com

Pearls in Medicine for Students

First Edition

A treasure island in medicine for medical students, which consists of short description of facts frequently encountered at the bedside. A quick-reference ready-reckoner handbook to increase the core knowledge during early years of medical training

Published by :

Jaypee Brothers Medical Publishers, New Delhi-110 002. India
e-mail : jaypee@jaypeebrothers.com

Author : Fellow/Member of

- Indian College of Physicians (Ind)
- New York Academy of Sciences (USA)
- International Advisory Panel of "Kumar & Clark's" Textbook, 'Clinical Medicine', 7th Edition (Edinburgh)
- Association of Physicians of India (API)
- Indian Rheumatology Association (IRA)
- Indian Medical Association (IMA)

"Medicine is to be learned only by experience; it is not an inheritance; it cannot be revealed. Learn to see, learn to hear, learn to feel, learn to smell, and know that by practice alone can vou become expert. Medicine is learned by the bedside and not in the classroom. See, and then reason and compare and control. But see first."

— Sir William Osier (1849-1919)
Professor of Medicine, Oxford, UK

BEDSIDE CLINICS IN MEDICINE

PART I

SIXTH EDITION

Long Short & Spot Cases in Medicine
(Includes 37 Tables & 193 Coloured Photographs)

Arup Kumar Kundu md ficp mnas
Professor, Department of Medicine
KPC Medical College, Kolkata, India
Formerly Professor of Medicine & In-charge, Division of Rheumatology
R. G. Kar Medical College, Kolkata, India
Formerly Assoc. Prof. of Medicine & In-charge, Division of Rheumatology
N. R. S Medical College, Kolkata, India

Author of:
Bedside Clinics in Medicine, Part II
MCQs in Internal Medicine
Pearls in Medicine for Students
Chapter in API Textbook of Medicine, 8th Edition
Chapter in Postgraduate Medicine, 2009
Chapters in 'Rheumatology : Principles and Practice', 2010
Chapters in Medicine Update : 2010 & 2011
&
Section on Online Appendix of "Kumar & Clark's"
Textbook, 'Clinical Medicine', 6th & 7th Edition

ACADEMIC PUBLISHERS
5A, Bhawani Dutta Lane
Kolkata 700 073, India
e-mail : info@acabooks.net
website : www.acabooks.net

Published by :

Kaustuv Paul
For KSP Udyog
64 College Street, Kolkata-700 073
Regd. Office : Flat No. S2W4, Bidhan Nibas
4 Bidhan Sishu Sarani, Kolkata-700 054, India
e-mail : kshovanp@yahoo.com

Distributed by :

Academic Publishers
5A, Bhawani Dutta Lane, Kolkata-700 073, India

BEDSIDE CLINICS IN MEDICINE, PART I

Copyright © 2010, Dr. Arup Kumar Kundu

First Edition : October 1996
Second Edition : June 1997
Third Edition : January 1999
Fourth Edition : August 2002
Fifth Edition : April 2006
Sixth Edition : April 2010
Reprint : July 2010, January 2011, April 2011
Reprint : January 2012

ISBN : 978-93-80599-12-0

All rights reserved. This book is protected by Copyright Act. No part of this publication in general may be reproduced or transmitted, in any form or by any means, electronic, mechanical, photocopying, recording or any information storage and retrieval system, without the prior written permission of the author and the publisher. Breach of this condition is liable for legal action. In case of any dispute, all legal matters are to be settled under Kolkata Jurisdiction only

Printed by :

Graphic Offset Press (P) Ltd.
179A/1C, Manicktala Main Road, Kolkata-700 054, India

Cover design and colour processing done by :

Cosmos Graphics, 71/1A Patuatola Lane, Kolkata-700 009, India

Price : Rs. 460.00

Dedicated to my father

Professor (Dr.) AMIYA KUMAR KUNDU, MD (Cal)

a great clinician

Who inspired me to learn clinical medicine

A few personal communications with Giants of Medicine

(i)

From : (Regarding an error in renal clearance test)
Dr. *John Macleod*
13 Merchlston Avenue
Edinburgh, Scotland, EH 10 4PJ

13/7/83

Dear Dr. Kundu,

It was good of you to take the trouble to write to me about the 13th edition of Davidson.

Thank you for your kind comments.

You are of course, correct about the typographical error on page 428. It should have been C = U x V / P; the printer omitted the division sign. This is now being adjusted.

Again many thanks for writing.

With best wishes.

Yours sincerely

Sd/ **John Macleod**

(**2**)

From : (Regarding errors in serum-ascites albumin gradient)
Kurt J. Isselbacher, M.D.
Director, Massachusets General Hospital Cancer Center, Boston
Mallinckrodt Professor oj Medicine, Harvard Medical School
Editior : Harrison's Principles of Internal Medicine. 13th Edition

February 23, 1998

Dear Dr. Kundu,

I must commend you for your astute and thorough reading of the Harrison's textbook and in addition, thank you for pointing out two obvious typographical errors. In fact, this was already done in the second printing of the 14th edition.....

Again, many thanks for your thoughtfulness in bringing these two typographical errors to our attention.

Sincerely,

Sd/ **Kurt J. Isselbacher**

(3)

From : (Regarding erythema nodosum, & pulmonary stenosis)
Keith A A Fox
Duke of Edinburgh, Professor of Cardiology and Head of Department
Cardiovascular Research Unit. The University of Edinburgh
Hugh Robson Building. George Square, Edinburgh EH8 9XF

5th December 1995

Dear Dr. Kundu,

Re : Davidson's Principles and Practice of Medicine : 1 7th Edition 1995

On behalf of Editors of this textbook I have been asked to respond to you in view of the fact that this chapter was written by Dr. Boon and myself.

In response to your first question we have obtained source material which indicates erythema nodosum is a manifestation of acute rheumatic fever.

In conjunction with pulmonary stenosis, the only reason why the thrill may be best palpated in expiration is because of the fact that the heart moves closer to the anterior chest wall. We entirely agree that the velocity of blood flow across the pulmonary valve is increased in inspiration and this is demonstrated using echo Doppler techniques. However, for the reasons mentioned above palpation of thrill may be more obvious in held expiration when the heart and vessels are closer to the chest wall. I hope that these comments help to clarify the situation.

Yours sincerely

Sd/ **Keith A A Fox**
Professor of Cardiology

(4)

From: (Regarding contribution in "Kumar & Clark's" textbook on Medicine)
Ellen Green
Senior Commissioning Editor
Elsevier. 1 -3 Baxter's Place
Leith Walk. Edinburgh EH1 3AF

23/6/2005

Dear Dr. Kundu

Firstly, **on behalf of Kumar & Clark,** I would like to thank you for your contributions to the Online Appendix for **Clinical Medicine 6e** ..... I hope you are pleased with the book ..... Kind regards.

Sd/ **Ellen Green**

(5)

From: (Regarding some clinical methods & apex beat localisation)

Dr. J G Douglas
Chest Clinic, Clinic C
Aberdeen Royal Infirmary. Foresterhill
Aberdeen AB25 2ZN

2nd November 2005

Dear Dr. Kundu

Ref: MacLeod's Clinical Examination. 11th Edition

Thank you very much tor your recent e-mail ..... I am an editor of this edition..... I am responsible for writing much of the Respiratory Chapter and was most interested in your comments. In response:

Examining for Tracheal Shift..... Clearly this technique could also be performed with the patient standing or sitting.

Technique of Percussion - I entirely agree with your comment that to obtain the loudest percussion note ideally the other fingers, apart from the middle finger, should not touch the skin surface. Figure 4.19 is ambiguous and I will make a note of this for the next (12th) edition.

... Vocal Resonance..... However I agree that as written in the first paragraph of page 143 there is some confusion..... Again I will make a note to clarify this for the next (12th) edition.

Aegophony (page 144) ..... However **I** agree that it's position is a little confusing and again **1** will make a note of this when redrafting the next (12th) edition.

Examination Sequence (page 97 ..... palpation of apex beat) - I entirely agree with you that the second half of the statement under the 3rd arrow: "If you cannot feel it, ask the patient to roll on to their left side" is incorrect and references the wrong figure! I will make sure this is removed at the next reprint.

We are enormously grateful to you for your attention to detail in pointing out these points.

With best wishes. Yours sincerely,

Sd/ **J G Douglas**

(6)

From : (A compliment from Chief Editor of Harrison's book)

Dennis L. Kasper. M.D.
William Ellery Channing Professor of Medicine and
Professor of microbiology and Molecular genetics
Harvard Medical School
Director. Channing Laboratory
Brigham and Women's Hospital. Boton. MA 02115
Editor : Harrison's Principles of Internal Medicine. 16th edition.

7/10/2006

Dear Dr. Kundu,

.....I very much appreciate your interest in contributing to Harrison's. I have looked up your publications on PubMed, and I can see that you are active and productive in your field..... . and I wish you all the best in your ongoing studies and clinical practice.

Best regards,

Sd/ Dennis Kasper

(7)

From : (Regarding some queries on clinical medicine)

Laurence Hunter.
Senior Commissioning Editor. Elsevier

11/9/2008

Dear Dr. Kundu,

ReJ: Hutchison's Clinical Methods. 22 Ed

Once again I am most grateful to you for taking the trouble to contact us with queries about the content of this textbook. I shall pass on to the Editors the comments and ask them to take full account of these in the revision of the book.

Thank you once again for your interest in our publishing programme.

With all good wishes.

Sd/ Laurence Hunter

Foreword

It is a pleasant task for me to introduce Dr. Arup Kumar Kundu, MD (Cal) who is known to me as a brilliant student since his undergraduate days.

He had his postgraduation under my direct supervision and I found him extremely hardworking and very sincere. His clinical acumen was superb. Dr. Kundu was one of my best students I had in my teaching career. I had every reason to believe that Dr. Kundu would be a veiy good teacher in Clinical Medicine in future. Today my expectation has come true.

With the advent of newer and more sophisticated investigative procedures, importance of Clinical Medicine seems to be on the wane at present. But in our country, costly investigations are out of reach to most of the patients. Naturally, Clinical Medicine as basic diagnostic procedure will continue to be important in our country for a long time.

While conducting Oral & Practical part of MBBS examination, Dr. Kundu has attained sufficient knowledge about its protocol. With the help of this knowledge he has written the book—"Bedside Clinics in Medicine' to guide students. He has made a comprehensive list of patients that are given as 'cases' in the examination and has discussed meticulously the different questions a student might encounter with their satisfactory answers.

I am sure, this book will be of great help to both undergraduate and postgraduate students. I wish him all success.

Date : 12.10.96
Kolkata

DR. SUBRATA SEN
MBBS (Cal), FICA (USA), FRCP (Edin),
Ex-Professor Director, Department of Medicine,
Institute of Postgraduate Medical Education
and Research (SSKM Hospital, Calcutta)

Preface to the First Edition

This is not a text book of medicine. This book is based on bedside clinics on hundred 'model cases' oriented to **oral and practical examinations** with special stress on clinical methods. 1 hope this book will be very much helpful to students of clinical medicine both undergraduate and postgraduate.

First, I wish to express my deep sense of gratitude to my parents and family members, whose constant encouragement has enabled me to complete this book.

Next, I take the opportunity to extend my heartfelt reverence and fathomless gratitude to all my respected teachers. I feel, I should make a special mention of the names of Prof. P. Sen, MD (Cal), FRCP (Edin), FICA (USA), Prof. S. Sen, FRCP (Edin), FlCA (USA), Prof. P. C. Das, MD (Cal), FICA (USA), FCCP (USA), and Prof. A. K. Kundu, MD (Cal).

This book would never have been completed without the help of my wife Mrs. Bijoya Kundu. I am greatly indebted to her.

I owe deep sense of gratitude to Prof. S. K. Paul, MO (Cal) without whose constant encouragement, active guidance and blessings, this book would never have seen the light of the day.

I am very much grateful to Mr. Bimal Dhur of Academic Publishers, whose advice has been of great help to me.

I am thankful to Mr. Robin Chatterjee and Ms. Lopamudra Paul for meticulously typing out the manuscript. I also heartily acknowledge Mr. Kaustuv Paul of Crest Publishers who has taken immense pain in publishing this book.

I also express my thanks to all the staff of 'Abhinaba Mudrani' who have helped me in every step to complete the book.

In conclusion, I would like to admit that only few names appear in this acknowledgement, many too much unsung, have significantly contributed to and enhanced the quality of this book. To all, I am deeply obligated.

Date : 12th October, 1996

Arup Kumar Kundu

"Trimurti"
BG-87, Sector-II, Salt Lake City,
Kolkata-700 091, India.

Preface to the Sixth Edition

It gives me immense pleasure to present the sixth edition of the book in a new get-up. The overwhelming success of the previous editions has encouraged me to bring out the present thoroughly revised new edition. Most of the chapters have been rewritten and signifantly revised maintaining the style and old tradition intact. The book reviews a wide range of common clinical cases with discussion on core topics. Many new photographs have enriched the 'colour atlas' section while replacing majority of older ones. I expect that the 'clinical methods atlas' section will prove to be immensely helpful for aspiring students.

I do believe, bedside medicine still holds strong in the era of high-tech medicine and this is why I have attempted to write this book dealing with common clinical problems as well as some fundamental information which the students are expected to know at the end of their clinical training. Even with the availability of modern gadgets to have advanced and accurate investigations, clinical examination is very important in reaching a logical diagnosis. I have retained the original objectives of the book — totally clinically oriented, concise but comprehensive, and as far as practical with a lucid language. The new edition deals with different must-know areas in clinical medicine in a student-friendly way keeping the methodical and logical approach unaltered. The problem-solving attitude will help the students in their oral and practical, as well as theoretical examination, and also in their professional life in future. I think that this monograph is a quick-reference ready-reckoner handbook and a learning-revision tool to increase the core knowledge.

Other than the new look and new photographs, the new edition also includes two very basic chapters on 'cyanotic congenital heart diseases' and 'polyarthritis'. The book remains an invaluable resource for undergraduates, house officers preparing for MD/DNB/MRCP, and the postgraduates, and I hope that the junior teachers will also be benefited by reaching a high level of clinical competence if they go through it. As clinical methods are scattered throughout the book, the students are advised to follow the 'index' for easy reading. I feel happy and jubilant as this book was nicely reviewed by renowned indexed journals, leading physicians, students and many academicians from different corners of the country. However, healthy suggestions and constructive criticisms through e-mail (arup kundu@hotmail.com) will always be appreciated by the author.

I would like to record my appreciation for Mr. Kaustuv Paul of KSP Udyog for publishing, Mr. Bimal Dhur and Dipankar Dhur of Academic Publishers for distributing, and Mr. Amar Nandy for printing the book with great care. I am grateful to all my patients whose photographs have been printed in this book and to the MSVP, R. G. Kar Medical College & Hospital, Kolkata for permitting me to take the photographs. This work would not have been possible without the constant support and encouragement from my family members, specially to speak of my wife Bijoya Kundu, my daughter Ushasi and my son Abhishek, which ultimately made this edition a reality.

Date : 15th April, 2010

Arup Kumar Kundu
"Trimurti"
BG-87. Sector-II, Salt Lake City,
Kolkata-700 091, India.
e-mail : arup kundu@hotmail.com

In their esteemed opinion about the book

- "Your book is an excellent replicative educational medium for exam-going students. Congratulations .....
- ".....I am proud of you as you are a THINKER. May your tribe increase. Many students make you their role model. God will bless you always....." —Prof. B. M. Hegde, Ex-Professor & Dean of Medicine, Kasturba Medical College, Mangalore (Ex-Vice-Chancellor, MAHE University, Manipal).

"... Dr. Kundu has brought out a book based on bedside clinics on 26 model long cases and 74 short and spot cases oriented to clinical and oral examinations with special stress on clinical methods.....He discusses the history, diagnosis, signs, differential diagnosis and management in the form of questions and answers. The answers are given in detail. .....There is an exhaustive coverage of the subject and Dr. Kundu has to be congratulated for bringing out such a wealth of knowledge. This is not a text book but it contains a lot of information which the students are expected to know at the end of the clinical training..... The book is very helpful to the students of clinical medicine while revising the subject before examination. Dr. Kundu has discussed the various questions which student may encounter during the examination and he has done it admirably". —Book review in Journal of the Association of Physicians of India (JAPI) by Dr. P. S. Shankar, Dean, K. J. Somiya Medical College, Mumbai.

".....Examinees who wish to anticipate routine questions and to avoid long embarrassing silences would do well to read these pages..... important points have received appropriate emphasis..... The text is closely written and the amount of information provided is truely gross. Every line and word has to be remembered....." —Book review (Part I) in Journal of the Indian Medical Association (JIMA).

"The monograph on Bedside Clinics in Medicine is very well written, studded with your long experience as clinical teacher. Such monograph was a long felt need. You have really done an excellent job. The monograph will be very well received not only by undergraduate and postgraduate students but by clinical teachers as well." —Dr. A. P. Jain, Professor & Head, Department of Medicine, M. G. Institute of Medical Sciences, Sevagram, Maharashtra.

"I highly appreciate the efforts, hard work and sincerity in bringing up this publication in a beautifully designed manner with rich clinical material inside". —Dr. S. B. Agarwal, Professor & Head, Department of Medicine, B. J. Medical College and Civil Hospital, Ahmedabad, Gujarat.

".....It is a poetry on Clinical Medicine." —Final year MBBS student, N.R.S. Medical College, Kolkata.

".....I congratulate you for bringing out this book....." —Dr. P. K. Rathor, P. G. trainee, M. K. C. G. Medical College, Berhampur, Orissa.

".....The book is good and very useful to undergraduates & postgraduates in Medicine ..... I shall continue to recommend your book.....congratulation to the author for his concentrated effort." — Prof. (Capt.) G. Nagaiah, Professor & Head, Department of Medicine, Thanjavur Medical College & Hospitals, Tamilnadu.

".....I have gone through this book and found it most suitable for the students. I will definitely recommend this book to the students....." — Prof. (Dr.) D.K. Hazra, Director, Professor & Head, Department of Medicine, S.N. Medical College, Agra, Uttar Pradesh.

".....Bedside Clinics in Medicine by Dr. Arup Kumar Kundu is a good book for undergraduate medical students. It is helpful for preparing for final MBBS Examination. Students can guess as what type of questions may be asked in the practicals....." — Dr. B.T. Tukol, Professor of Medicine, K.M.C, Hubli, Karnataka.

" ..... is an excellent book for junior students in Medicine. This book, very simply written in a concised and rational manner will greatly help the undergraduate students to establish the foundation of Clinical Medicine with ease and confidence." **—Dr. P. C. Bhattacharyya, Ex-Professor of Medicine, Gauhati Medical College, Assam.**

" ..... it is just excellent. It is an ideal companion for both undergraduates and post-graduates during exam time....." **—Dr. Neelakantan V. and Dr. N. Parvathi Sulochana, Sundarapuram, Coimbatore, Tamilnadu.**

"The second revised edition of Bedside Clinics in Medicine contains information at one place which postgraduates in Medicine aspire to assimilate in order to learn art and science of Medicine. Really an excellent job by Dr. Arup Kundu". **—Dr. A. P. Jain, Professor** & **Head, Department of Medicine, M. G. Institute of Medical Sciences, Sevagram, Maharashtra.**

"..... It is so nice that all clinical problems are completed in so small a volume..... ". **—Dr. K. Gandhi, Assistant Professor of Medicine, Thanjavur Medical College, Tamilnadu.**

"..... This is not a book but something more than that. This is self-explanative and could be one of the best books in the field of Clinical Medicine required for our students. The book is indispensable for not only undergraduates and postgraduate students but also for teachers and practitioners in Medicine as well. This book is a living Clinical Tutor". **—Dr. Kiranmoy Mitra, Ex-Assoc. Professor & Head, Department of Medicine, Burdwan Medical College and Hospital, West Bengal.**

"Your fascinating presentation of long cases and short cases in Medicine has attended our presence towards your book....." **—R. Ravishankar and S. Gupta, Final year MBBS students, Thanjavur Medical College, Tamilnadu.**

"In keeping with the expanding horizon of medical sciences and the gallant gallops of a plethora of newly emerging methodologies, Dr. Arup. K. Kundu has very meticulously and ingenuously architectured his master creation Bedside Clinics in Medicine, Parts I and II. A purist pedagogue, a massive mentor, and an exemplary exponent engrossed with an expansive professional expertise and competency, he has probed deeply into several cases along with history, diagnosis and management invariably in an easy-to-understand question-answer form. This lucidity, sometimes in a literary, and mostly in a highly scientific manners, has made this work an invaluable medical contribution-cum-anthology for undergraduate and postgraduate students. Moreover a beginner may find it a crutch to have a naive rendezvous into this area of medicine. The diagnostic procedures and methodologies are nicely delineated. This book will be a constant concise companion for all, students and teachers alike, in different Indian Universities and Medical Colleges as this treasure will elicit the clinical spirit of approach from a modest conventional way to highly sophisticated method." **—Prof. (Dr.) C. R. Maity, Ex-Dean, Faculty of Medicine, Burdwan University; Principal, Burdwan Medical College, Burdwan, West Bengal (Ex-Director of Medical Education, WBMES, Government of West Bengal).**

"I happened to go through your book Bedside Clinics in Medicine ..... It was nice and quite interesting..... I can recommend the book to my students as a ready reckoner....." **—Dr. V. Venugopal, Professor of Medicine, Perundurai Medical College, Tamilnadu.**

"The book Bedside Clinics in Medicine, Part I and II is comprehensive with wide coverage of all systems and attractively produced..... it is informative and beneficial not only to the UGs/PGs, but also to the physicians.'' **—Col. A. S. Kasthuri, Professor and Head, Department of Medicine, AFMC, Pune, Maharashtra.**

"..... I found that there is a wealth of information in the book which is difficult to get from other books.....you must have gone through several journals and the whole of encyclopedia of medicine..... Congratulations." **—Dr. K. Ramachandran, Visiting Professor of Radiology; MG University School of Medicine, Gandhi Nagar, Kottayam, Kerala.**

"..... I have been an ardent reader of both of your textbooks on clinical medicine, since the first day of my ward duty. To be very honest I have learnt more from your books than from....." —Dr. Saif Omar, Internee, Katihar Medical College, Katihar, Bihar.

"..... many congratulations for writing an ultimate manuscript in medicine....." —Dr. Kamaalchand M, P.G. trainee in Pediatrics, JNMC, Aligarh Muslim University, Aligarh, Uttar Pradesh.

"..... Bedside Clinics in Medicine, Part 1 & Part II is a Treasure Island" for students of Medicine both undergraduates & postgraduates.....The book has in fact satisfied the need of a long awaited reference book for examinee being complete by itself in all respects.....recommend this book strongly for students of medicine....." —Prof. (Dr.) P. R. Nath Barbhuiya (Retd.), Professor & Head, Department of Medicine, Silchar Medical College & Hospital, Assam.

"..... Bedside Clinics in Medicine, Part I, which is highly informative, well-written with latest additions ....." —Dr. **N.** S. Neki, Associate Professor of Medicine, Government Medical College, Amritsar, Punjab.

"..... the joy of reading the book is so overwhelming that, by far, medicine has never seemed so pleasurable. It definitely provides so much of knowledge and information, that everytime I close the book after reading it, I do so with an extreme sense of happiness and confidence of knowing so much..... It is unequivocal opinion that the book is outstanding and entirety removes the need to study multiple books in clinical medicine..... For my final year exams..... the questions that were asked during discussion were entirely based upon the facts given in your book. I just had to quote them to be appreciated by the examiners. I wish to explain my gratitude as a student of medicine for your valuable contribution which is unfathomable ....." —Dr. Keerthana Karumbaiah K, Internee, Bangalore Medical College, Bangalore, Karnataka.

"..... this *made easy', if assimilated properly by the students, will help to learn many aspects of medicine.....The chapters on radiological diagnosis and ECG interpretations will certainly help all concerned. Emergency tackling of different cases also, will help the young professionals.....The book is likely to be well accepted and the second edition of the book supports that expectation."—Book review (Part II) in Journal of the Indian Medical Association (JIMA).

"..... its really the eighth wonder in the world. Looking back, recollecting my MD days, I repeat my words.....I owe you my MD."—Dr. Pradeep Kumar Shenoy C, Ex-clinical fellow and registrar, Department of Rheumatology, Manipal Hospital, Bangalore.

".....I am very happy to inform you that I have got selected for MD..... I owe my success to your book, and your in time valuable suggestion and advice. You have been my behind the scene teacher and educator and inspiration.....Dr. Bhushan Madke, student of Indira Gandhi Govt. Medical College, Nagpur, Maharashtra.

".....You have donated breath to me....." ■—Jagroop Singh, student of Guru Gobind Singh Medical College, Faridkot, Punjab.

".....I feel it is a very good book and very informative....."—Dr. George K. Chako (MD, PhD), PDH Hospital Group, Mumbai, Maharashtra.

"I am a final year medical student. I read your book on bedside clinical examination..... The book is really wonderful. Hats of sir....."■—J. Mahammad Sadiq, Government Medical College, Salem, Tamilnadu.

".....I am highly impressed with clarity and concept of your book. The book is not only helpful for clinical exams but also for theory. The book is really a wonderful book....."— Ramchandra Chaudhary, student of S.R.T.R Medical College, Ambajogai, Maharashtra.

"Sir, its really great whatever you write, I have read your book in final year to clear exam, that helped very much to pass final prof..... ”—Dr. Amit Sharma, (DM cardiology student), and passed MD (medicine) from KGMC, Lucknow, Uttar Pradesh.

"Bedside Clinics in Medicine by Dr. Arup Kundu is really nice to crash all the viva Q-A in your clinical viva.....also it helps to clear basics.....It teaches you how to think medicine” —in http: / /medcosmosbaroda.blogspot.com/2008 09 01_archive.html

A website in Vietnam, recommended this book as only clinical medicine book from Asia— www. ykhoavn. net/modules. php?name=Forums&file=viewtopic&p=7035-43k

Website in China (Weifang Medical University, Shandong, China) recommends this book for their students— www.xmail.net/wfmustudents/medicalbooks.htm

www.rxpgonline.com

- "Medicine viva—by kundu; this comes in 2 volumes and is a must read stuff....”
- “Kundu is great for symptomatology and specific exam cases.....”
- “.....go through a good clinical exam/cases book like Hutchinson and Kundu...."
- "Some important things you should know before entering clinics is given in Mcleods, Kundu clinical medicine. I think you can get these books and start off....”
- “.....It is wonderful for all category of students whether average or brilliant one. It teaches you the basic medicine..... ”

mciforchina. blogspot.com / 2008/08/m-c-i-screening-t es t-books-syllabus. html-85k—recommended Bedside Clinics in Medicine, Part I & II for MCI screening test books for students passed MBBS from aborad.

www.medicalgeek.com (which book for clinical medicine?)

- “.....Arup Kumar Kundu—notes on all major, minor cases for exam....”
- "For clinical exam I read everything from Kundu part 1 and 2....never touched..... even Dr. Arup Kumar Kundu was our external examiner..... ”
- "I would go for Kundu”
- ".....for cases, Indian book—By Dr. Kundu..... ”
- “.....you must buy Kundu.....”

“.....I m using Kundu.....all case wise clinical study is very fine..... I really like it...." in www.cafemedico.com

".....also Arup Kundu if you want to dash answers in ward round cases. I would recommend Kundu as a must buy over and above one basic book like Hunter.....” — www.aippg.net

“..... Favorite Medical Books: Guyton’s Physiology & Kundu’s Medicine_____ ” in www.doctorshangout.ning.com/profile/DrMansi

"....Favorite medical books: Harrison’s principle’s of internal medicine, Kundu, de Gruchy, John Patten...." in www.doctorshangout.com/profile/PEUISHSUGATHAN

“I would like to meet: Harrison, Hutchison, Davidson, Kundu....” in www.doctorshangout.com/ profile / RAJESHARAHANT.

”1 am a 4th year student at IMTU Dar Es Salaam Tanzania. I have seen one of book titled Bedside clinics in medicine. How can I get my copies..... "—hance Mdunye, IMTU, Dar Es Salaam, Tanzania.

".....It is a well known fact among medical professionals, that your book on bedside medicine has proved to be a holy gift to the generations of medical students in this part of the world—”—Apildev Neupane, final year medical student at Institute of Medicine, Kathmandu, Nepal.

..... and many others from every nook and corner of the country.

CONTENTS

PERSPECTIVES.....1

CHAPTER I : LONG CASES 3-252

CASE-TAKING.....3

CARDIOVASCULAR SYSTEM 6-54

SCHEME OF EXAMINATION.....6
Mitral stenosis.....8
Mitral incompetence.....19
Aortic stenosis.....27
Aortic incompetence.....39
Mitral stenosis and mitral incompetence.....44
Aortic stenosis and aortic incompetence.....47
Infective endocarditis.....51

RESPIRATORY SYSTEM 54-106

SCHEME OF EXAMINATION.....54
Pleural effusion.....56
Pneumothorax.....68
Hydropneumothorax.....80
Consolidation of the lung.....87
Bronchial asthma.....95

GASTROINTESTINAL SYSTEM 106-134

SCHEME OF EXAMINATION.....107
Pyloric stenosis.....109
Acute viral hepatitis.....112
Cirrhosis of liver.....119

NERVOUS SYSTEM 134-187

SCHEME OF EXAMINATION.....136
Hemiplegia.....138
Paraplegia.....155
Peripheral neuropathy.....173
Parkinsonism.....-.....181

GENITOURINARY SYSTEM 187-200

SCHEME OF EXAMINATION.....188
Acute glomerulonephritis.....189
Nephrotic syndrome.....195

LOCOMOTOR SYSTEM 201 - 207

SCHEME OF EXAMINATION..... 201
Polyarthritis.....202

LYMPHORETICULAR SYSTEM 208-234

SCHEME OF EXAMINATION.....208
Thalassaemia..... 208
Chronic myeloid leukaemia.....217
Lymphoma.....222

MISCELLANEOUS 234-252

Chronic kala-azar.....234
Diabetes mellitus.....239

CHAPTER II : SHORT CASES 253-299

Cyanotic congenital heart disease.....253
Fibrosis or collapse of the lung..... 258
Superior mediastinal syndrome.....261
Ascites.....265
Abdominal lump.....275
Hepatosplenomegaly..... 280
Cerebellar disorder.....293
Bulbar palsy..... 297

CHAPTER III : SPOT CASES 300-489

Anaemia..... 300
Cyanosis..... 305
Jaundice..... 308
Pulse.....313
Water-hammer pulse.....319
Abnormal temperature.....322
Oedema.....328
Clubbing.....332
Moon face.....335
Dwarf ism (cretinism)..... 337
Tall stature.....339
Emaciation.....341
Examination of neck veins.....345
Spider naevi.....349
Palmar erythema.....350
Examination of the hands.....351
Wasting of the small muscles of hands..... 355
Claw hand.....357
Gynaecomastia.....358
Hypo- or hyperpigmentation.....360
Scabies..... 362

Psoriasis.....365
Pityriasis versicolor.....367
Haemorrhagic spots.....368
Leprosy.....372
Neurofibromatosis.....376
Scleroderma.....378
Systemic lupus erythematosus (SLE).....382
Erythema nodosum.....386
Subcutaneous nodules.....387
Down's syndrome (mongolism).....389
Hydrocephalus.....390
Rickets.....392
Myxoedema.....396
Hyperthyroidism.....400
Exophthalmos.....406
Cushing's syndrome.....409
Acromegaly.....413
Palpation of base of the heart.....416
Percussion of the sternum or base of the heart.....416
Auscultation of different areas of heart.....418
Pericardial rub.....419
Shape of the chest.....422
Auscultation of the chest.....425
Pleural rub.....428
Examination of the tongue.....431
Visible peristalsis.....433
Prominent veins with venous hum.....434
Kayser-Fleischer (K-F) ring.....437
Pes cavus.....440
Tests of memory.....441
Speech disorders.....443
Tremor.....445
Ptosis.....447
Squint.....452
Nystagmus.....457
Bell's palsy.....459
Chorea.....464
Fasciculation.....466
Myotonia.....470
Myopathy.....472
Jerks and clonus.....476
Plantar response (reflex).....480
Trophic changes.....483
Charcot joint.....484
Abnormal gait.....487

APPENDIX 490-503

YOUR EXAMINATION HALL AND PATH OF SUCCESS.....490
INSTRUMENTS TO CARRY IN THE EXAMINATION HALL.....490
THE HISTORY SHEET AND DISTRIBUTION OF MARKS.....491
INDEX.....492

(Perspectives

In 1816, Rene Theophile Hyaeinthe Laennec invented the stethoscope — the single instrument that came to symbolize the bedside physician and the weapon used by the clinicians for almost last two centuries.

The term patient is derived from the Latin word 'patiens', or 'to suffer'. A 'patient' is one who feels sick physically or mentally and consults doctor for relief of his ailments. In clinical medicine, patients hold the key position. Naturally, it is the task of the physician that he should do the needful for the recovery of the patient.

To relieve the sufferings of the patients, a doctor should ascertain at first, the nature of illness from which the patient is suffering from. In other words, the doctor has to diagnose the existing disease. Physical diagnosis makes the bridge between the study of disease and the management of illness. Clinical diagnosis is an artistic science, based on three kinds of medical informations :

(I) Communication with the patient (i.e., the history taking),

(II) Physical examination, and

(III) Investigations.

Clinical medicine deals with the first two parts of diagnosis i.e., 'clinical examination' of a patient consists of history taking as well as physical examination. These are the most important parts and it starts as soon as the patient comes to the doctor. At no point can **history taking** (medical events that have already taken place) be considered as 'wastage' of time; in most cases, the diagnosis can be made with history alone. History taking is an art, which a doctor should learn over years by repeated practice. Regarding history taking, it is my advice to the students of clinical medicine that they should try to disprove Ben Berston's comment, who told 'A funny thing happens to medical students on their way to becoming physicians; they forget how to hold a conversation'. While examining the patient, an experienced doctor not only 'sees' but also 'uses all of his senses' and gradually develops the keen 'power of observation' which is known as 'clinical eye' or 'clinical acumen'. These can not be acquired in a short-cut way and there is no rule of thumb in it. To learn this, one has to go to the bedside of the patients for years together, to make keen observations, to examine them thoroughly and sympathetically, and to try to 'associate' different observations and findings. Gradually the person develops the inherent 'knowledge of correlation' with the help of clinical eye. This is why, Hippocrates commented, 'A great part, I believe, of the art of medicine is the ability to observe. Leave nothing, combine contradictory observations and allow yourself enough time'. ***An experienced clinician not only hears but listens, not only sees but observes, and not only touches but feels.*** One, who has sharp clinical eye, becomes successful in life in the long run.

Traditionally, the process of **physical examination** (clinical state at that given time) is divided into four parts like looking (inspection), feeling (palpation), tapping (percussion), and listening (auscultation). From our student days we have learned to determine 'where is the lesion' as well as 'what is the lesion' derived by physical examination to arrive at a definitive diagnosis; this is also true to the students of this generation too. It should be realized that inspection / palpation / percussion / and specially auscultation are skills acquired over years of training. We know that our professional progenitors relied more on ***power*** of smelling (sweetish musty odour of hepatic coma) and tasting as well (the sweetness of urine in diabetes mellitus), but these facts have lost their importance in today's modern medicine. A sincere and meticulous physical examination combined with in-depth as well as sound knowledge of internal medicine would help the physician to determine the most probable cause / causes of the patient's present ailments. It is wise to consider the patients as living pages of books, and instead of examining from 'head to feet', I should rather advise students to examine patients from 'head to toes'.

Another important part of clinical medicine is doctor-patient relationship. It has got immense value in ultimate recovery of the patient. By the way of'conversation' and physical examination, one sympathetic doctor gains confidence and wins trust of the patient. This should never be neglected. Whenever the

confidence of the patient is achieved, it becomes easier for the doctor to get his cooperation to examine the painful areas or even the diseased private parts of the body. In a non-cooperative patient, diagnosis may be much more difficult and delayed.

Investigations help the doctor to confirm the diagnosis made by clinical examination. Of course, clinical diagnosis by physical examination has limitations. No doubt, in many cases one has to take the help of newer and sophisticated investigations to arrive at a definitive diagnosis. Recently there is a boom in investigational facilities like polymerase chain reaction, ELISA test, ultrasound, CT scan, NMR scan, PET scan, SPECT scan where the patient is being fragmented into systems, organs, tissues, cells or even the smallest DNA, and very often these facilities erode the confidence of the clinicians concerned. Now-a-days, a large section of doctors feel that clinical examination is not at all essential and diagnosis can be made easily with the help of sophisticated investigations only. But this is not at all true. The laboratory should be used as an aid for confirmation of diagnosis and the final approach should be to 'treat the patient', not the laboratory reports. One confident doctor should never disregard his own clinical findings; moreover, newer investigations are often very costly and out of reach of most of the patients of a developing country like India. A long time back, Alvan R. Feinstein remarked, 'Clinical judgement depends not on knowledge of causes, mechanisms or names of disease but on a knowledge of patients. The background of clinical judgement is clinical experience; the things that clinicians have learned at the bedside is the care of sick people'.

In spite of these facts we can not ignore the importance of 'chemical' diagnosis and contribution of physics in medicine e.g., the discovery of X-ray by Wilhelm Roentgen or ECG by Willem Einthoven. So question arises, will this computer and sophisticated newer technology replace the physician's task of performing physical examination? The answer is simply 'no'. The computer necessarily deals in the cold literal aspects of words, whereas the doctors are trained to search for hidden meanings. To the question, 'is your pain continuing at the present moment'? The mechanical computer only records 'yes' even when the patient shows agony while responding. The doctor reads far more to the patient's response to 'yes'. Moreover, detailed questioning and physical examination frequently build the first emotional contact between the doctor and the patient. Can a computer be sympathetic to the patient regarding his illness? Or can a fascinating electronic gadget replace the excellence of Giant Clinicians like Batista Morgani, Leopold Auenbrugger, Rudolf Virchow, RTH Laennec, Sir William Osier, Adolph Kussmaul and Josef Francois Felix Babinski? A human brain created the computer, and thus a slave can neither demonstrate physical signs of the disease in a patient nor can interpret the complexities encountered to have a definitive diagnosis. So there is reason to believe that clinical medicine will ever persist as a basic diagnostic method and investigations will remain as 'complementary' to the clinician.

Unlike physics or chemistry, medicine is not a pure science. Half of what is true today will be proven to be incorrect in the next five years, and unfortunately we don't know which half that is going to be. The question arises whether medicine is a science, or an art, or an art based on science? The scientists say that medicine is sometimes considered a science, and sometimes an art, and the object of medical science is to study disease. I think medicine is an art based on science; medicine is supposed to be a scientific study whether its practice is an art, and does not consist of compounding pills and plasters only. Today, every senior doctor is shouting in every corner of this globe that the art of clinical medicine is dying in the present teaching set up with high-tech gadgets. I also think that they are mostly true; today, doctors are more powerful but more deaf. Medical students are advised to revive the dying art of medicine and to be good artists with sufficient scientific knowledge.

In the beginning of their clinical training, the students should also remember these golden words: **'there is no substitute for watchful eyes, alert ears, and tactful fingers in a logical mind'.**

CHAPTER I : LONG CASES

SCHEME OF CASE-TAKING

(A) Particulars (biodata) of the patient : **Bed No.----------**

1. Name
2. Age
3. Sex
4. Religion
5. Occupation
6. Address
7. Date of admission
8. Date of examination

(B) The history or history proper :

1. Chief or presenting complaints
2. History of (H/O) present illness
3. Past history
4. Personal history
5. Family history
6. Treatment history
7. Psychological history
8. Menstrual and obstetric history in females

(C) Physical examination :

I. GENERAL SURVEY —

1. Level of consciousness; whether alert, oriented and co-operative
2. Apparent age (corroborative or not)—Down's syndrome, thalassaemia and a pituitary dwarf look younger; and in progeria or precocious puberty, the patient looks older than his/her chronological age
3. Decubitus (position of the patient in bed)
4. Build or built (skeletal framework)—Average/dwarf/tall stature
5. Nutrition (nourishment of the body)—Average/undemutrition/obese. Try to determine body mass index (BMI)
6. Fades (facial appearance)
7. Anaemia (mild, moderate, severe)—Probably 'pallor' is a better terminology
8. Cyanosis (central or peripheral type)
9. Jaundice (mild, moderate, severe)
10. Neck vein (jugular venous engorgement, pressure and pulsation)
11. Neck artery (carotid arteries)
12. Lymph nodes (all over the body)
13. Thyroid gland
14. Clubbing
15. Koilonychia
16. Pulse (with all the points)
17. Respiration (rate, rhythm, type, depth and breathing pattern)
18. Temperature (record oral tempeature)
19. Blood pressure — Preferably both in supine (compulsory) and standing position. Measurements both in right and left arm are sometimes necessary
20. Oedema
21. Skin, hairs (including head to see alopecia) and nails
22. Height and weight, arm span, upper segment-lower segment ratio (anthropometry)
23. Any obvious deformity (of skull, spine, limbs, or swelling of abdomen)

24. General : any acute distress present or not
25. Handedness (right or left) with level of intelligence (average, low, high)

II. SYSTEMIC EXAMINATION —
1. Cardiovascular system (CVS)
2. Respiratory system
3. Gastrointestinal system (G.I. system) or alimentary system
4. Nervous system
5. Genitourinary system
6. Lymphoreticular system
7. Locomotor system (optional)

(D) Summary of the case (construct two paragraphs. First paragraph : short history in two or three sentences, and second paragraph : examination findings in brief with major abnormalities constructed in two or three sentences)

(E) Provisional diagnosis

(F) Differential diagnosis

(G) Relevant investigations (optional)

* In the history sheet, one may add 'points in favour of diagnosis' after the provisional diognosis.

** In the systemic examination, one must write 'all' the systems, e.g., in a patient with mitral stenosis —first the CVS is dealt with in details and then the other systems are considered in brief.

*** Stand on the right side of the patient during examination.

THE HISTORY

1. *CHIEF COMPLAINTS :*

Major complaints with the duration should be written in the patient's own language in chronological order of their appearance.

2. *H/O PRESENT ILLNESS :*

a) Expansion of the chief complaints in relation to their mode of onset (acute/subacute/insidious), progress (progressive/static/with exacerbations and remissions) and duration. Progress during stay in the hospital should be enquired into.

b) Positive, plus **important negative points** (e.g., paralysis in neurological disorder or breathlessness in cardiovascular diseases).

c) Use patient s own words and avoid scientific or medical terms as far as possible (joint pain is preferable term than arthritis).

d) Do not put leading questions (i.e., questions suggesting their own answers) but many a time direct relevant question makes an essential component of sensitive history-taking.

e) Record relevant associated symptoms.

D Generalities — Appetite, loss of weight, fatigue, sleep, bladder and bowel.

* Bladder and bowel habit may be included in personal history instead.

3. *PAST HISTORY :*

History of relevant past illness like,

a) Rheumatic fever.
b) Tuberculosis.
c) Malaria.
d) Kala-azar.
e) Jaundice.
f) STD (sexually transmitted diseases like gonorrhoea, syphilis, AIDS etc.).
g) Systemic hypertension.
h) Diabetes mellitus.
i) Trauma or injury.
j) **'H/O contact'** with persons suffering from tuberculosis or any contagious disease.
k) **'H/O exposure'** (sexual) to STD.
1) Any illness which demanded 'blood transfusion' (e.g., accidents or any operation).
m Childhood illness (e.g., eruptive fevers).
n) Past hospital admissions.
o) Any other major medical or psychiatric illness in the past.
P) H/O travel (abroad or disease-prone areas).

In pediatrics age group take the birth history (asphyxiated or not), H/O immunisation, past H/O any injury, umbilical sepsis or meningitis from the parents.

Few clinicians prefer to mention hypertension and diabetes mellitus within personal history.

*** Never comment, 'past history nothing significant', rather say 'the patient had no history suggestive of tuberculosis, jaundice..... and rheumatic fever'.

4. PERSONAL HISTORY :

, This includes H/O the patient, spouse and children only. Following points (e.g., personal details and lifestyle) should be noted carefully :

a) Marital status with number of children.
b) Occupation (nature and environment of job) and education; unemployment.
c) Income (asked indirectly) and social (socio-economic) status.
d) Addiction (tea. coffee, smoking, alcoholism, or substance abuse e.g., chewing tobacco, cannabis, heroin; try to estimate the amount of consumption of tobacco or alcohol).
e) Dietary habit (for diagnosis of avitaminosis, malnutrition, obesity),
fj History of contraception.
g) Whether performing exercise regularly or not?
h) High risk behaviour (e.g., IV drug abuse, multiple unprotected sexual exposure, homosexuality etc)—important in hepatitis B or C infection, AIDS and SBE.
i) Domestic and marital relationship; hobbies and pets.

* Tobacco abuse : form (cigarette/biri), quantity and duration of exposure

5. FAMILY HISTORY :

This includes the parents, brothers, sisters, uncles (maternal or paternal), nephew etc. H/O tuberculosis (affected by contact), diabetes mellitus, systemic hypertension, ischaemic heart disease (IHD), bronchial asthma, eczema, haemophilia, thalassaemia, schizophrenia within the family should be enquired into. H/O similar type of illness (as the patient is suffering from) in the family should be asked for. Cause of death of the near relatives (parents) should be mentioned. H/O consanguineous marriage within the family should be recorded (autosomal recessive disorders e.g., homocystinuria may result from consanguineous matings). Family history is important in hereditary and communicable diseases (e.g., mumps, measles, chickenpox). Environmental factors should always be taken into account e.g., effects of passive smoking in a woman who is having a heavy-smoker husband. Lastly, the 'pedigree chart' (symbols used in construction of a family) may be drawn.

6. TREATMENT HISTORY :

a) Treatment received so far, for the present illness.
b) Any H/O drug allergy or reactions.
c) Any surgical intervention or H/O accidents in significant past.
d) Prolonged use of oral contraceptives (may precipitate CVA), penicillamine (used in Wilson's disease; may develop nephrotic syndrome) or vitamin C (may produce oxalate stone) etc.
e) Blood transfusion—frequency, amount, type (e.g., whole blood, packed cell).
fj Intake of NSAID (may produce acute gastric erosion, NSAID-induced asthma etc.).
g) Regular user of oral contraceptives, vitamins, laxatives, sedatives or herbal remedies.
h) Immunisation.
i) Self-medication.

7. *PSYCHOLOGICAL HISTORY :*

Observe the 'mood' of the patient, i.e., whether anxiety, depression, irritability, euphoria, obsession, neurosis, depersonalisation are present or not. Peptic ulcer, bronchial asthma, irritable bowel syndrome are examples of psychosomatic disorder.

8. MENSTRUAL AND OBSTETRIC HISTORY :

■ These include the following :

a) Menarche.
b) Duration of the period.
c) Quantity of blood loss (usually assessed by number of pads consumed or passage of clots).
d) Dysmenorrhoea, amenorrhoea or other menstrual irregularities.
e) Date of last menstrual period. ,
fj Menopause, post-menopausal bleeding.
g) Obstetric history—
  (i) No of pregnancies
  (ii) Outcome of pregnancies; H/O abortions, or carried to term; live birth (male/female)
  (iii) Complications during pregnancy (e.g.. hypertension, gestational diabetes mellitus)
  (iv) Mode of delivery (vaginal, forceps. Caesarean)
  (v) Last child birth

* Occupational history (exposure to dust/chemicals, working in a high altitude, coalmines and other business affairs) may be taken into account.

N.B.: While history-taking, full concentration is paid to the patient and the barriers of communications (foreign visitors, difficulty in hearing/vision, dysphasic/aphasic patient, emotionally disordered i.e., angry or abusive patient) may be overcome by informations obtained from a relative. Catch the non-verbal clues (e.g., catch in breath, flushing, restlessness or changing eye contacts are signs of 'stress') in the patient. One must be very careful on highly sensitive topics in history-taking e.g., drug addiction, eating disorder, marital disharmony, sexual abuse or offending behaviour. Remember, in case of females, there might be some triggering influence of menstruation on migraine or pregnancy on heart failure.

During history-taking be sympathetic and show patience, and always try to be on the patient's level in all respect. The skills of history taking can be obtained and maintained satisfactorily only by practice.

ESSESI

CARDIOVASCULAR SYSTEM

The symptoms of CVS are mentioned below :

1. Breathlessness (dyspnoea, orthopnoea, paroxysmal nocturnal dyspnoea)
2. Chest pain (angina pectoris, acute myocardial infarction or AMI, pericardial pain, aortic dissection)
3. Palpitation
4. Cough and expectoration
5. Haemoptysis (expectoration of blood, or bloody sputum; seen in mitral stenosis)
6. Dizziness and syncope; black-out
7. Convulsions or past H/O neurodeficit
8. Tiredness or fatigue (aortic stenosis, [5-blocker therapy)
9. Swelling of feet (peripheral oedema) or facial puffiness
10. Intermittent claudication or limb pain
11. Squatting or cyanotic spells (cyanotic congenital heart diseases)
12. Visual disturbance (retinal haemorrhage or embolism)
13. G. I. symptoms like anorexia, nausea, vomiting (digitalis toxicity or protracted congestive cardiac failur [CCFD, pain abdomen (mesenteric embolism, tender hepatomegaly in CCF, inferior wall AMI)
14. Renal symptoms like oliguria, nocturia (in CCF)
15. Hoarseness of voice or dysphagia (left atrial enlargement due to mitral valve disease, or aortic aneurysm)
16. Fever (SBE, tuberculous pericarditis, rheumatic activity, deep vein thrombosis, Dressler's syndrome)
17. Fleeting joint pain, sore throat, subcutaneous nodules for rheumatic heart diseases
18. General symptoms — Appetite, loss of weight (cardiac cachexia) or gain in weight (due to edema), fatigue, sleep, bladder and bowel

* No. 1, 2, 3, 6 and 9 are cardinal symptoms in cardiology

Scheme of Examination

(A) Pulse :

1. Rate
2. Rhythm
3. Volume
4. Condition of the arterial wall
5. Comparison between two radial pulses
6. Radio-femoral delay
7. Any special character
8. Other peripheral pulses

* May add **blood pressure** here

(B) Examination of neck veins :

1. Engorged or not
2. If engorged,
   - (i) Pressure
   - (ii) Pulsation — Present or not
   - (iii) Hepato-jugular reflux — Present or not

(C) Examination of the heart :

I. INSPECTION :

a) Inside the precordium —

(i) Shape — Presence of any deformity or bulging.

(ii) Pulsation — Apical impulse; diffuse pulsation over precordium (see page 42).

(iii) Engorged superficial veins — Present or not (see page 436).

(iv) Polythelia (accessory nipple) — Often indicates underlying congenital heart disease, cardiomyopathy etc.

(v) Any scar mark (specially for previous cardiac operation), sinuses.

b) Outside the precordium — Any pulsation present in.

(i) Aortic area.

(ii) Pulmonary area.

(iii) Parasternal areas (right and left).

(iv) Epigastrium.

(v) Suprasternal area.

(vi) Carotid pulsation.

(vii) Locomotor brachialis.

(viii) Back — Specially at the inferior angle of scapula in coarctation of aorta (Suzman's sign).

c) Inspection of the BACK for scoliosis, kyphosis, gibbus, drooping of the shoulder, winging of the scapula; examine the skin for any sinus, ulcer, venous or arterial prominence, scar mark etc.

* Look for midline sternotomy scar for coronary artery by-pass surgery, left submammary scar for mitral valvotomy and infraclavicular scar for implantation of pacemaker.

II. PALPATION :

a) Mitral area —

1. Apex beat - (i) Site, and
(ii) Character

2. Palpable heart sound (M^

3. Thrill

b) Pulmonary area —

1. Pulsation

2. Palpable heart sound (P_2)

3. Thrill

c) Aortic area —

1. Pulsation

2. Palpable heart sound (A_2)

3. Thrill

d) Tricuspid area —

1. Left parasternal heave

2. Palpable heart sound (T,)

3. Thrill

e) Direction of venous blood flow (in engorged superficial veins).

f) Thrill in carotid arteries (carotid shudder).

g) Epigastric or suprasternal pulsation, or any pulsation over the back.

h) Palpable pericardial rub.

i) Tracheal tug.

* See page 418 for different areas of heart, pages 30 and 42 for thrill, page 416 for palpation of heart sounds and parasternal heave.

III. PERCUSSION : Not done

IV. AUSCULTATION :

a) Cardiac rate

b) Rhythm

c) Mitral area —

1. Heart sounds

2. Murmur (in detail)

3. Adventitious sounds — Opening snap, ejection click, splitting of heart sound, S_3 or S_4

d) Pulmonary area — As in mitral area

e) Aortic area — As in mitral area

f) Tricuspid area — As in mitral area
g) Auscultation over neoaortic area
h) Auscultation over carotid arteries for bruit (after holding the breath)
i) Venous hum at root of neck (e.g., severe anaemia)
j) Pericardial rub

* It is better to write 'audible' in case of heart sounds which are not produced in that area. Thus, in pulmonary hypertension S_2 (P_2) is loud but Sj is audible in pulmonary area.

** Always examine female patients in the presence of a female attendant.

*** Before doing any clinical procedure or manoeuvre (e.g., palpation of apex beat) always take permission of the patient and explain briefly what you are going to do.

**** Always think of some common disease by the 'law of probability'; if you give the provisional diagnosis of a rare disease, you are rarely correct. Remember the dictum : Uncommon presentations of common diseases are more common than common presentations of uncommon diseases.

Case 1

MITRAL STENOSIS

What is your diagnosis ?

Give the provisional diagnosis (P/D).

It is a case of mitral stenosis (MS) of rheumatic origin without any evidence of congestive cardiac failure (CCF) and the patient is in sinus rhythm at present.

What is your case ?

One should describe the summary of the case without mentioning the P/D directly, e.g.,

Sunita Devi, 26 years female patient presented with gradually increasing breathlessness for last 10 months, and cough with haemoptysis for last 1 month. The breathlessness was gradually progressive, exertional, non-seasonal and NYHA (New York Heart Association) grade II in severity. Cough was not associated with rise of temperature. She had no H/O palpitation, chest pain, swelling of legs, syncope, squatting (to exclude cyanotic congenital heart diseases), pain in legs during walking or any neurodeficit. Two weeks back, she experienced acute respiratory distress at middle of night due to paroxysmal nocturnal dyspnoea (PND). She was neither hypertensive nor diabetic; there was no H/O contact with tuberculosis and no H/O exposure. She had an uneventful H/O child birth, 4 years back. She had definite H/O rheumatic fever in her childhood which affected mainly the big joints like knee, ankle and elbow following an attack of sore throat. The arthritis was fleeting in nature and not associated with any skin lesion or chorea.

On examination, there is no anaemia; pulse is 78/minute, low volume, regular with all the peripheral pulses palpable equally; BP is 100/70 mm of Hg. in supine position and the neck veins are neither engorged nor pulsatile. There is no deformity of precordium (precordial bulging indicates early onset and longer duration cardiac diseases). On palpation, the apex beat is present in left 5th intercostal space (ICS) 1/2" inside the left midclavicular line (MCL) and is tapping in character (i.e., Sj is palpable). A diastolic thrill is palpable in the mitral area which is best felt in left lateral position and in full expiration, and there is absence of left parasternal heave. On auscultation of the mitral area the 1st heart sound (S^ is short, sharp, accentuated, and the 2nd heart sound (S_2) is audible. Opening snap (OS) is heard just after S_2. There is a low-pitched mid-diastolic rumbling murmur with presystolic accentuation of grade IV intensity in the mitral area without any radiation (use the term 'radiation' or direction of selective propagation' but it is better to avoid the term conduction of murmur). The murmur is best audible at cardiac apex with the bell of stethoscope (placed lightly), in left lateral position, at the height of expiration and after doing mild exercise. There is absence of split, click, rub or murmur over the other areas. Examination of the respiratory system revealed no abnormality (no adventitious sound, no hydrothorax etc.) and there is absence of hepatosplenomegaly or ascites.

* Features of right ventricular hypertrophy (RVH) and pulmonary hypertension are absent in this patient.

** Past H/O rheumatic fever, hypertension, diabetes mellitus, tuberculosis (and syphilis) are important in all CVS cases.

*** A big summary is elaborated here for the sake of better understanding of the case history of MS.

Give the summary of the case :

Give the short case history from the question discussed above.

Provisional diagnosis in valvular heart diseases :

1. Anatomical — Mitral, tricuspid, aortic, pulmonary.

2. Structural abnormality—Stenosis, regurgitation.
3. Aetiologieal — Rheumatic, congenital.
4. Complications — Pulmonaiy hypertension, CCF, subacute bacterial endocarditis (SBE) etc.
5. Rhythm — Sinus rhythm or dysrrhythmia (e.g., irregularly irregular rhythm due to atrial fibrillation).

   Some clinicians prefer to add NYHA classification in the provisional diagnosis (see page 24).

Why it is a case of mitral stenosis ?

It is a case of mitral stenosis because of the following :

(A) Symptoms (from the history) :

a) Breathlessness or effort intolerance for last 10 months.
b) Cough with haemoptysis from time to time for 1 month.
c) Attacks of paroxysmal nocturnal dyspnoea since last 2 weeks.
d) Past H/O rheumatic fever (tell about the symptoms).

(B) Signs :

a) Pulse - 78/minute, LOW VOLUME, REGULAR, no radio-radial or radio-femoral delay, all the peripheral pulses are palpable, no abnormality in the arterial wall or no special character.
b) BP - Low (or normal).
c) Apex beat - Normal in position and tapping in character. There is presence of diastolic thrill, best palpable in left lateral position and at the height of expiration. S, is palpable.
d) Auscultation (of the mitral area) :

   S, - Short, sharp and accentuated (loud and snapping Sj — a very important clinical clue).
   S_2 - Normal.
   Opening snap — Audible, just after S_2.
   Murmur - Describe the classical murmur (as described in summary).
   Other areas - No murmur.

* ADD FEATURES OF PULMONARY HYPERTENSION. IF PRESENT.

** Auscultatory cadence of murmur and heart sounds of MS are as follows: ***ffout*** (presystolic murmur ending in loud Sj) — ***ta*** (S_2) — ***ta*** (opening snap) — ***rrrou*** (mid-diastolic murmur).

*** 'Usually' the apical impulse in an established MS is diffuse and formed by right ventricle. There is a diastolic thrill at apex, best palpable at left lateral position. There is sustained left parasternal heave as a result of RVH from pulmonary hypertension.

If no ***past H/O rheumatic fever present :***

Rheumatic fever is the commonest aetiology of MS and it is true in other valvular heart diseases. 60% of the MS patients do not give definite H/O rheumatic fever, still one should consider rheumatic fever as the probable aetiology. In that case it is better to say in P/D as 'a case of MS probably of rheumatic origin'.

Importance of past and family history in CVS :

	Past history		**Family history**
1.	Rheumatic fever	1.	Hypertension
2.	Cyanotic spells with H/O squatting	2.	Congenital heart disease
3.	Recurrent respiratory tract infection	3.	Rheumatic heart disease
4.	Any murmur or cardiac lesion detected at school	4.	Ischaemic heart disease (IHD)
5.	Hypertension, diabetes mellitus, IHD	5.	Obesity, diabetes, dyslipidaemia
6.	Thyrotoxicosis	6.	Sudden (cardiac) death

How to diagnose congenital / early onset cardiac disease ?

1. History with ailments since birth/childhood with special reference to squatting.
2. Bulged precordium.
3. Clubbing with cyanosis plus polycythemia.
4. May be associated with dwarfism.

What is 'precordium' ?

It is the anterior chest wall which overlies the heart. In health, it is slightly convex and associated with a smooth contour. The different deformities are :

a) Bulging - Early onset and longer duration cardiac diseases (e.g., VSD, rheumatic heart diseases), pericardial effusion, scoliosis, mediastinal tumours, left-sided pleural effusion.

b) Flattening - Fibrosis of the lung, congenital deformity of chest, adherent pericarditis.

What is mitral fades ?

It is the pinkish purple patches on cheeks. As low cardiac output in MS produces vasoconstriction, peripheral cyanosis is often seen in lips, tip of the nose and cheeks. Occasionally along with these, malar flush is seen due to vasodilatation (vascular stasis) in malar area. All these features constitute 'mitral facies' and is rarely seen in India.

Causes of malar flush :

1. High altitude.
2. Myxoedema.
3. Mitral stenosis.
4. Cushing's syndrome.
5. Thyrotoxicosis.
6. Chronic alcoholism.
7. Polycythemia.
8. Carcinoid syndrome.
9. Menopausal syndrome
10. Pheochromocytoma.

How loud Sj ***in MS can be explained*** ?

Due to persistent diastolic gradient across the mitral valve, the valve cusps remain wide open throughout the diastole and as soon as the ventricular systole starts, the widely opened mitral valve cusps close rapidly, giving rise to loud Sj (think of the sound produced when a door is closed from a short distance or from widely opened position, and it is obvious that closing the door from a long distance will produce more sound).

Factors influencing the intensity of S_l :

1. Position of valve cusps (mitral or tricuspid) at the onset of ventricular systole :
   a) Wide open valve cusps — MS or TS, hyperdynamic circulatory states (produce loud Sj).
   b) Valve cusps remaining close to each other or can not close completely (e.g., MI or TI) —The S! becomes muffled e.g., in myocarditis, myocardial infarction, heart failure, MI or TI.
2. PR interval (in ECG) — S, is loud if PR interval is short, and S, becomes muffled if PR interval is prolonged.
3. Pliability of the valve cusps e.g., calcification results in loss of pliability, and the heart sound becomes muffled or faint.
4. Ventricular muscle mass (booming Sj is heard in patients with systemic hypertension leading to LVH).
5. Heart rate — In tachycardia, Sj tends to be loud as a result of short PR interval.
6. Intervening media between heart (valve cusps) and the stethoscope e.g., emphysema, pericardial effusion or obesity diminishes the intensity of S_r

* Normally the S, is dull and prolonged (lubb in 'lubb-dup'), and best audible at the apex. S_1 indicates the beginning of ventricular systole and is produced due to closure of atrioventricular valves. It has two components : mitral (Mj) and tricuspid (TJ.

* Sj coincides with carotid pulsation while S_2 comes after the pulsation. During auscultation of heart sounds in different areas, always palpate right carotid artery with the left thumb.

Table 1 : Variations in intensity of S_1

Loud Sj	**Soft or muffled S_t**
1. Mitral stenosis, tricuspid stenosis 2. Sinus tachycardia due to any cause 3. Hyperkinetic circulation e.g., severe anaemia, pyrexia, exercise, pregnancy, thyrotoxicosis, Paget's disease, beriberi 4. Short PR interval, e.g., tachycardia, nodal rhythm 5. Normally in children	1. Mitral incompetence, tricuspid imcompetence 2. Prolonged PR interval (e.g., 1° heart block), bradycardias 3. Right or left ventricular dysfunction 4. Calcified mitral/tricuspid valve 5. Obesity, emphysema, thick chest wall, pericardial effusion
Varying intensity of S_t	**Splitting of Sj**
1. Atrial fibrillation 2. Ventricular tachycardia 3. Complete heart block (cannon sound) 4. Multiple extrasystoles	1. Wide splitting : complete RBBB, left ventricular pacing, Ebstein's anomaly 2. Reversed splitting : complete LBBB, right ventricular pacing, severe MS, left atrial myxoma

Muffled S_2 ***in MS :***

When MS is associated with :

1. Mitral incompetence (MI) or severe aortic incompetence (AI).
2. Mitral valve calcification.
3. Active rheumatic carditis (due to prolonged PR interval).
4. Digitalis overdose (due to prolonged PR interval).
5. Acute myocardial infarction.
6. Left atrial failure (LAF).
7. Atrial fibrillation (produces varying intensity of S_1).
8. Rotation of heart due to gross right ventricular hypertrophy (RVH) and consequently right ventricle is forming the apex.
9. Emphysema, obesity, thick chest wall (transmission of S, is hampered).

Comment on apex beat in MS :

Usually the apex is in normal position. If the apex goes outward, think of RVH (from pulmonary hypertension) and if it is downward plus outward, think of LVH (i.e., search for associated MI, AI, AS. systemic hypertension). Normally, the apex is tapping (palpable SJ in character and may be diffuse (due to RVH). LVH is not a feature of isolated MS.

How do you clinically assess the 'severity' of MS ?

Features of severe MS are :

1. Narrow S_2-OS gap (the smaller the gap, the more severe is the MS), and
2. Longer duration of mid-diastolic murmur.

N.B. : Remember, it is the duration and not the intensity, which assesses the severity of MS. Other signs of severity are : symptomatic patient, low volume pulse, RVH and pulmonary hypertension in ECG, and cardiomegaly in chest X-ray.

Recognition of pliable mitral valve cusps :

1. Short, sharp, accentuated Sj, and
2. Presence of opening snap.

* If the valve cusps are non-pliable (i.e., in mitral valve calcification), S, will be muffled and the opening snap will not be heard.

Absent presystolic accentuation in MS :

1. Artrial fibrillation,
2. Left atrial failure,
3. Big left atrial thrombus.

Why the murmur is mid-diastolic in MS ?

The interval between closing of the aortic valve (S_2) and opening of the mitral valve is known as 'isovolumetric relaxation' period. Diastolic murmur of MS is heard as soon as the blood flows from the left atrium to left ventricle after opening of the mitral valve (i.e., in the mid-diastole). There is no blood flow in the isovolumetric relaxation period and this is why the murmur of MS is mid-diastolic, not early diastolic.

The last part of ventricular diastole (last rapid filling phase) actually coincides with atrial systole. Atrial systole increases the blood flow across the stenotic valve and thus, there is accentuation of the diastolic murmur (presystolic accentuation).

What is an opening snap (mitral) ?

(A) Opening snap is produced due to bellowing down of the closed mitral valve cusps at the onset of ventricular diastole (i.e., mitral valve will open just now but has not opened yet). It is :

a) Sharp and high-pitched.
b) Best heard with the diaphragm of stethoscope.
c) Best heard after expiration with the patient in standing position.
d) Loudest in between the apex beat and the left sternal border.
e) Present in early diastole (at the end of isovolumetric relaxation period).
f) It may be the loudest sound in the cardiac cycle.

(B) It indicates :

a) MS is organic.

b) Valve cusps are pliable.
c) Significant MS.
d) High left atrioventricular pressure gradient.
e) Severe AI, gross MI. gross pulmonary hypertension, atrial fibrillation, left atrial failure or SBE (subacute bacterial endocarditis) is absent.
f) Diminishing S_2-OS gap indicates increasing tightening of stenosis (severe MS).
g) MS is readily amenable to surgery.

* Opening snap is also audible in tricuspid stenosis, ASD, VSD, PDA, posterior cuspal type of MI.

** To differentiate OS from splitting of S_2, ask the patient to stand. As standing reduces the venous return, the S_2-OS gap increases and A_2-P_2 gap of S_2 decreases on assuming standing position (dynamic auscultation).

Aetiology of MS :

MS is 'almost always' or invariably of **rheumatic** in origin. Rarely the congenital form ('parachute' mitral valve—all chordae inserted into a single left ventricular papillary muscle) may produce MS, or very rarely it may arise from severe mitral annular calcification, carcinoid syndrome, collagen vascular disease (SLE), endomyocardial fibrosis or mucopolysaccharidosis. MS results from shortening of chordae tendineae and fusion of commissures.

* IN CLINICAL PRACTICE IT IS SAID THAT THE COMMONEST AETIOLOGY OF MS IS RHEUMATIC, THE SECOND IS RHEUMATIC AND THE THIRD IS ALSO RHEUMATIC.

** Rheumatic MS is much more common in females.

Pathological types of MS :

1. Button hole, 2. Fish mouth, and 3. Funnel type.

* Mitral valve apparatus in composed of 1. valve leaflets, 2. valve annulus, 3. chordae tendineae 4. papillary muscles, and 5. myocardium (the papillary muscles are attached here).

Common symptoms of MS :

Dyspnoea, orthopnoea, paroxysmal nocturnal dyspnoea (PND), palpitation, fatiguability, haemoptysis, recurrent bronchitis, cough, chest pain, right hypochondrial pain (tender hepatomegaly), and symptoms related to complications.

* 1. Symptoms due to low cardiac output—fatiguability,

2. Symptoms due to left atrial failure (i.e., pulmonary congestion)—dyspnoea, orthopnoea, PND, cough, haemoptysis, recurent bronchitis.

3. Symptoms due to RVF—swelling of legs (oedema), pain in right hypochondrium.

4. Symptoms due to arrhythmia—palpitation.

** Chest pain in MS is due to 1) RVH, 2) coincidental coronary atherosclerosis, or 3) coronary embolism.

Lutembacher's syndrome :

Atrial septal defect (ASD) plus MS (of rheumatic origin).

Changes noticeable when atrial fibrillation develops in MS :

1. Ventricular rate (heart rate) is about 100-150/minute.
2. **Irregularly irregular pulse with varying volume, and a pulse deficit > 10.**
3. Varying intensity of S, (classical loudness of Sj is lost); opening snap is not heard.
4. Absent a-wave in the neck veins or JVP.
5. **Presystolic accentuation of the diastolic murmur disappears;** only mid diastolic rumble persists.
6. Congestive cardiac failure may precipitate and embolic manifestations may appear (CVA, intermittent claudication, pain abdomen etc).

* *Aetiology of atrial fibrillation* are rheumatic (commonly MS), ischaemic, hypertensive, thyrotoxicosis, cardiomyopathy, myocarditis, pericarditis, idiopathic or 'lone' atrial fibrillation (in elderly persons without any demonstrable heart disease), congenital (especially ASD) and sinoatrial disease.

** In atrial fibrillation, the atria usually fire impulses at a rate of 350-600/minute.

Changes occuring after left atrial failure in MS producing pulmonary oedema :

1. S, becomes muffled,
2. Opening snap is not heard.

3. Presystolic component of the murmur disappears, and
4. Presence of bilateral basal crepitations (fine).

Which chamber of heart fails first in MS ?

The left atrium. Chamber involvement in MS : LA -> RV -> RA.

Which ventricle fails first in MS ?

The right ventricle **(left ventricle does not fail in MS as mitral valve lies proximal to it)**

* In the presence of left ventricular hypertrophy or failure in MS, think of associated valvular diseases like MI, AI, AS, or systemic hypertension, ischaemic heart disease, cardiomyopathy.

What is tight or severe MS ?

Normal cross-sectional area of mitral valve orifice is 4-6 cm^2 (average 5 cm^2). Classification in relation to dimension of mitral valve orifice is : Minimal — >2.5 cm^2, mild—1.6 to 2.5 cm^2, moderate — 1 to 1.5 cm^2, and severe (tight/critical) — <1 cm^2.

What is juvenile mitral stenosis :

This type of MS is usually found in India. In India, MS develops earlv in contrast to the west where the patient experience disability in the 4th decade. The criteria for diagnosis are :

1. Occurs below 18 years of age.
2. Pin-point mitral valve.
3. Atrial fibrillation is rare.
4. Valve calcification is uncommon.
5. Needs immediate operation.
6. Common in South-East Asia.

Haemoptysis in MS : explanation :

The possible mechanisms are —

1. Pulmonary apoplexy — Due to rupture of thin-walled, dilated bronchial veins or pulmonary veins (frank haemoptysis) resulting from sudden rise in LA pressure.
2. Winter bronchitis (chronic bronchitis) — Blood-streaked mucoid sputum.
3. Acute pulmonary oedema — Profuse, pinkish, frothy sputum is produced due to rupture of capillaries into the alveoli.
4. Pulmonary infarction — Frank haemoptysis.
5. Overdose of anticoagulant therapy (rare) — Often required for embolic manifestation.
6. Pulmonary haemosiderosis — Rare.

Most significant finding in your case :

The mid-diastolic rumbling murmur.

What is damped MS ?

Development of pulmonary hypertension diminishes the cardiac output (throttle effect) and results in temporary symptom-free period (period of illusion). Often the mid-diastolic murmur is not audible and thus known as silent MS.

What is intermittent claudication ?

This is a cramp-like pain, tightness and numbness (due to ischaemia) felt commonly in calves, thighs or buttocks on walking a certain distance, and characteristically relieved by taking rest. The •claudication' (Latin meaning 'to limp') suggests peripheral vascular disease and the most important risk factor is smoking. The common causes are,

1. Buerger's disease (thromboangiitis obliterans; young heavy-smoker males).
2. Atheroma or severe atherosclerosis of lower limb arteries; Leriche's syndrome (embolism at branching of common iliac artery i.e., claudication of thigh + impotence).
3. Coarctation of aorta.
4. Arteritis.
5. Lumbar canal stenosis (patient often stoops forward during walking to reduce symptoms. If he continues to walk, paraesthesia in feet and even foot drop may develop).
6. Venous claudication (bursting pain on walking, previous H/O DVT), and
7. Over-exertion.

Palpation of peripheral pulses in legs, i.e., arteria dorsalis pedis shows diminution in the volume of pulse in 1, 2, 3 and 4. In 5. 6 and 7, peripheral pulses remain normal but in 5, ankle jerk may be diminished or absent.

- Vascular claudication (No. 1. 2, 3, 4) : Cold legs, pallor, feeble pulse are common. Common risk factors are diabetes, smoking, hypertension and hypercholesterolaemia.

- Neurogenic claudication (No. 5 or cauda equina compression) : Paraesthesia, limb weakness, diminished ankle jerk with normal pulse.

Differential diagnosis (D/D) of mitral diastolic murmur :

1. Carey-Coombs murmur — Soft mid-diastolic murmur of active rheumatic valvulitis, localised to the apex. The murmur varies in intensity from day to day and usually disappears after the acute attack. There is absence of loud S,, opening snap and diastolic thrill. Oedema of the matral valve cusps produce obstruction and gives rise to diastolic murmur.
2. Austin Flint murmur — It is a functional low-pitched, mid-diastolic rumbling murmur produced in a patient with severe AI. When the aortic regurgitant jet of blood impinges on the anterior mitral leaflet (thereby stenosing the mitral orifice relatively), a murmur (actually the murmur is due to both antegrade now of blood from left atrium and regurgitant jet from AI) is audible with the following features :
   a) Mid-diastolic murmur with absence of presystolic component; heard in the mitral area.
   b) No thrill.
   c) S, is not loud.
   d) Absense of opening snap.
   e) Commonly found in syphilitic AI.
   f) Isometric hand-grip increases the murmur.
   g) Presence of AI murmur in the aortic area with features of LVH, plus
   h) Peripheral signs of AI (read the section on 'Aortic incompetence').
3. Functional mid-diastolic murmur — Found in increased left-to-right shunt in ventricular septal defect (VSD), atrial septal defect (ASD), or patent ductus arteriosus (PDA). Increased flow through the normal mitral valve also occurs in severe MI. There is absence of diastolic thrill, opening snap and presystolic accentuation but S_3 may be present.
4. Left atrial myxoma—
   a) Alteration of physical signs (murmur) with change of posture; H/O postural syncope.
   b) Tumour 'plop'—a sound heard as the pedunculated tumour comes to a halt.
   c) Constitutional symptoms like fever, weight loss, anaemia, arthralgia, rash; high ESR.
   d) Embolic episodes.
   e) 2-D echocardiography is diagnostic.
5. Tricuspid stenosis — Mid-diastolic murmur with presystolic accentuation which is loudest at lower left sternal edge. Murmur increases at the height of inspiration. Features of RVH are never present.
6. Ball valve thrombus — The thrombus usually floats in the left atrium and obstructs the mitral orifice in diastole. Echocardiography is essential for final diagnosis.
7. Conducted murmur of AI — Early diastolic, soft blowing; no thrill, no opening snap. Peripheral signs of AI are present.
8. Cor triatriatum — A correctable malformation of heart where an abnormal fibromuscular diaphragm separates the left atrium into two chambers. Echocardiography and cardiac catheterisation are diagnostic.

* Closest D/D of MS are left atrial myxoma and ball valve thrombus in the left atrium.

Describe the classical attack of paroxysmal nocturnal dyspnoea (PND) :

It is the sudden and dramatic development of acute dyspnoea occuring in the early hours of night, i.e., nearly 30 minutes to 2 hours after retiring to bed. The patient is awakened from sleep with a feeling of apprehension, intense suffocation and choking sensation. He sits upright gasping in the bed with the legs hanging by the side of the bed (to reduce left atrial pressure by gravitational pooling) or rushes to an open window in the hope that cool fresh air will relieve him. Dyspnoea progresses with profuse^sweating. These are accompanied by a dry, repetitive cough which is due to **'acute interstitial oedema** resulting from pulmonary venous hypertension, when there is no collection of fluid within the alveoli. The attack may subside spontaneously within 30 minutes but often progresses to **'acute pulmonary oedema'** which may end fatally. The cough becomes productive with profuse, watery, pinkish and frothy sputum due to acute pulmonary oedema (collection of fluid within the alveoli).

PND signifies the earliest symptom of acute left-sided heart failure (due to LAF or LVF). Acute dyspnoea with wheeze and repetitive productive cough are features of **'cardiac asthma'.** Actually 'cardiac asthma' is closely related to PND and is characterised by wheezing due to bronchospasm which is most prominent at night. Acute pulmonary oedema is the severe form of cardiac asthma due to marked increase in pulmonary capillary pressure leading to alveolar oedema.

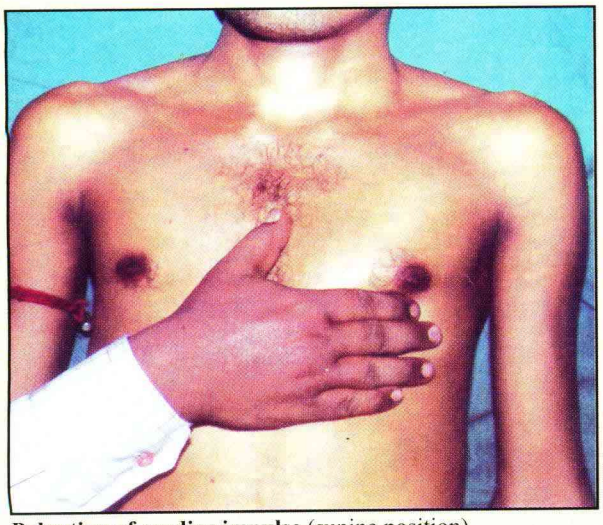

Palpation of cardiac impulse (supine position)

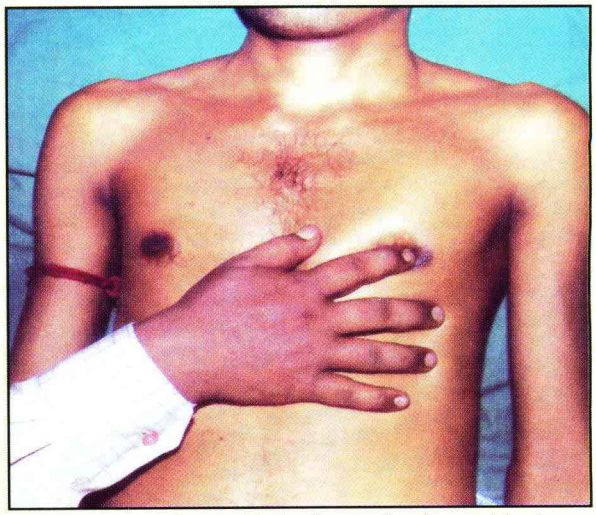

Localizing apex beat with the fingers (supine position)

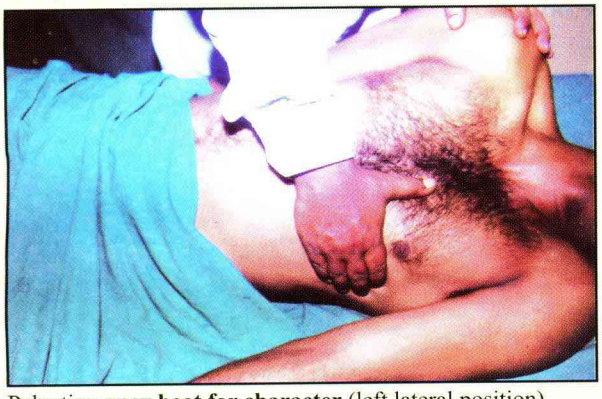

Palpating **apex beat for character** (left lateral position)

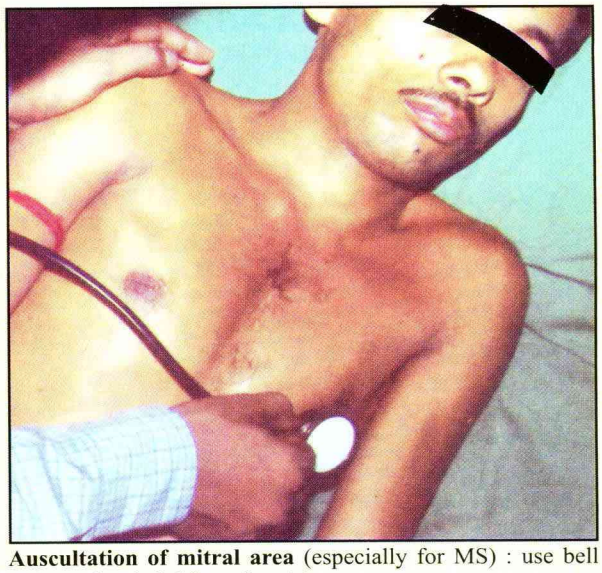

Auscultation of mitral area (especially for MS) : use bell while patient in left lateral position

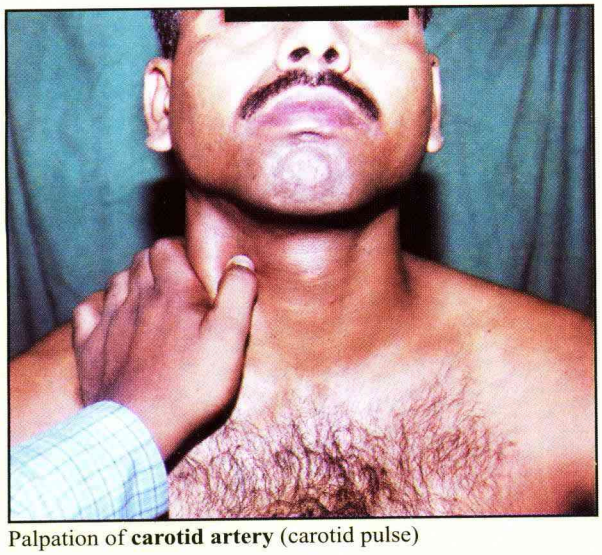

Palpation of **carotid artery** (carotid pulse)

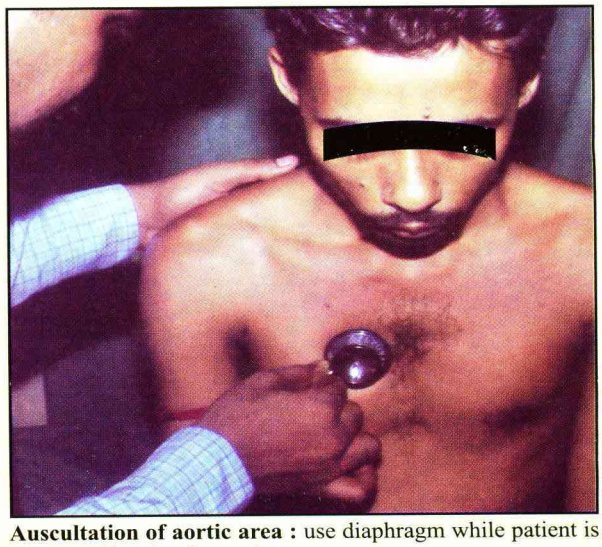

Auscultation of aortic area : use diaphragm while patient is sitting and leaning forward

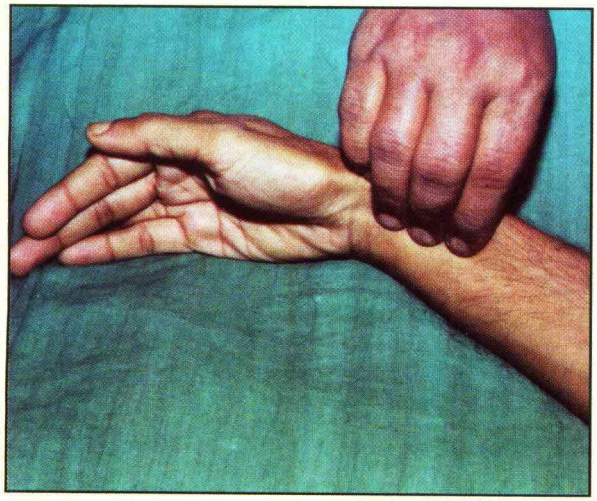

Palpation of **radial artery** ('the pulse')

Palpation of **arteria dorsalis pedis** (pedal pulse)

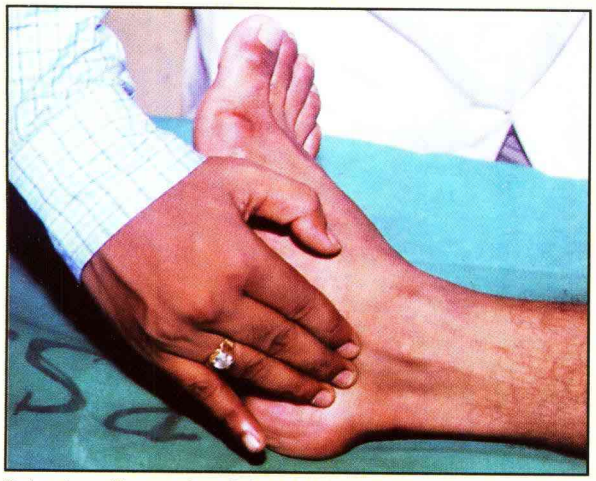

Palpation of **posterior tibial artery**

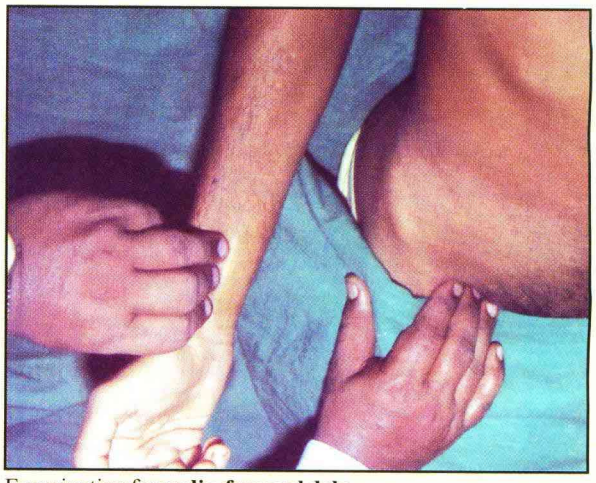

Examination for **radio-femoral delay**

Examination of **popliteal artery**

Elicitation of **water-hammer pulse** (collapsing radial pulse)

Clinical examination at the time of an attack of PND reveals :

a) Severe dyspnoea and orthopnoea; tachypnoea associated with air hunger and recruitment of accessory muscles.
b) Anxious and pale (ashen-grey pallor) patient with profuse sweating; cold extremities.
c) Central cyanosis.
d) Pulse — Tachycardia; feeble pulse.
e) BP — May be high (as hypertension is the commonest cause of PND).
f) JVP — Raised.
g) Heart — S_3 gallop rhythm; signs of underlying heart disease.
h) Lungs — Vesicular breath sound with prolonged expiration; bubbling crepitations +++ (predominantly basal), and scattered rhonchi + present.

* Acute pulmonary oedema is the phenomenon of "cough, cough, cough — spit, spit, spit".

**** So, causes of LAF and LVF are the basic causes for paroxysmal nocturnal dyspnoea or acute pulmonary oedema.** PND is a symptom of decompensation of the left heart.

*** 'Left side' of the heart encompasses the functional unit of left atrium, left ventricle, mitral valve and aortic valve; and the 'right side' of the heart is used for the term encompassing right atrium, right ventricle, tricuspid valve and pulmonary valve.

****In recumbency, the rapid increase in venous return leads to pulmonary congestion and the left-sided chambers can not cope up with this increased inflow in MS. Breathlessness in PND is due to inappropriate awareness of respiratory tract and firing of 'J' receptors in lung.

Why dyspnoea occurs in MS ?

It is known that abnormally elevated LA-LV pressure gradient is the haemodynamic hallmark of MS. The events in MS go like this : TLA pressure ->Tpulmonary venous pressure ->Tpulmonary capillary wedge pressure -> icompliance of lung -> dyspnoea (exertional).

Protective mechanisms to prevent pulmonary oedema in MS :

As the disease progresses to chronic mitral stenosis, there is development of :

1. High pulmonary vascular resistance (pulmonary hypertension),
2. Capillary-alveolar-interstitial barrier, and
3. Broncho-pulmonary venous shunts.

Thus, it is clear that a recent onset MS patient may die of LAF (acute pulmonary oedema) and an old or chronic patient dies of RVF (from pulmonary hypertension). An old case of MS usually does not suffer from PND because of the development of protective mechanisms mentioned above.

Causes of 'non-cardiogenic' pulmonary oedema (loosely termed as 'ARDS') :

Pulmonary oedema is of two types ; cardiogenic and non-cardiogenic. The causes of non-cardiogenic type are—

1. Diffuse pulmonary infections (viral, bacterial, fungal, pneumocystis jiroveci).
2. Inhalation of toxins and irritants (phosgene, chlorine, high concentration of 0_2).
3. Aspiration of vomitus, water (near drowning), acid/alkali poisoning, kerosine poisoning.
4. Narcotic (heroin, morphine, methadone, dextropropoxyphene) and non-narcotic (nitrofuran-toin) overdose/effects.
5. Severe sepsis, gram negative septicaemia, shock, major trauma, uraemia.
6. Acute haemorrhagic pancreatitis, amniotic fluid/fat/air embolism, fulminant hepatic failure, insecticide poisoning, snake bite, high altitude, eclampsia.
7. Miscellaneous — Cardio-pulmonary bypass, major blood transfusion reaction, anaphylaxis (bee, wasp, snake venom, crab), major burns, head injury, SLE, DIC, lymphangitis carcinomatosa.

* In severe cases, pink and frothy sputum comes out through the nose. **Remember, pneumonia (exudate) is not pulmonary oedema (transudate).**

** 'Cardiogenic' pulmonary oedema — results from left-sided heart failure (LAF/LVF), acute myocar-dial infarction, cardiac dysrrhythmias, acute pulmonary thromboembolism.

*** Right heart cethterisation by Swan-Ganz catheter allows differentiation of two types. **Cardiogenic**—engorged neck veins, TCVP (central venous pressure) and tPCWP (pulmonary capillary wedge pressure); **non-cardiogenic**—normal left-sided atiral or ventricular pressure, neck viens are not engorged, and with normal CVP and PCWP.

Why the dyspnoea is usually nocturnal in MS ?

Probable theories are :

1. Venous return increases in recumbency.
2. Mobilisation of oedema fluid from extravascular to intravascular compartment on lying.
3. Adrenergic drive is reduced during sleep.
4. Heart rate increases during rapid eye movement (REM) sleep.
5. Reduction of vital capacity in supine position.
6. Elevation of left atrial pressure and fall in $Pa0_2$ during sleep.

Complications of MS :

1. Acute left atrial failure and acute pulmonary oedema.
2. Pulmonary hypertension.
3. Right ventricular failure (RVF/CCF).
4. Atrial fibrillation (AF), atrial flutter, ventricular or atrial premature beats.
5. Embolic manifestations (20%) due to AF (from dislodged clots formed in the LA),
   a) Cerebral - 60% (cerebral infarction leading to hemiplegia)
   b) Peripheral arteries - 30% (aorta—Leriche's syndrome)
   c) Visceral - 10%
6. Haemoptysis.
7. Infective endocarditis — Very rare (more common in milder form of MS than in severe form); endocarditis is common in 'regurgitation' than in 'stenosis'.
8. Recurrent broncho-pulmonary infections.
9. Complications due to giant left atrium (LA)—
   a) Hoarseness of voice — Due to compression of left recurrent laryngeal nerve by enlarged LA (Ortner's syndrome); very rare.
   b) Dysphagia — Due to oesophageal compression.
   c) Clot present in a giant LA may give rise to embolic manifestations even in sinus rhythm.
10. Jaundice, cardiac cirrhosis.
11. Sudden death may be caused by ball valve thrombus where the LA outlet is blocked by large pedunculated thrombus.

* Complications not related to severity of MS are atrial fibrillation, embolic manifestations and SBE.

How do you like to investigate a case of MS ?

(A) Chest X-ray (PA view) —

a) Slight increase in transverse diameter of heart (due to RVH).

b) 'MITRALISATION' of heart means straightening of the left border of heart and is due to (from above downwards) :
   1) Aortic knuckle — Small (due to low cardiac output).
   2) Convexity due to dilated pulmonary artery (due to pulmonary hypertension).
   3) Left atrial appendage — becomes prominent and produces a convexity.
   4) Left border of left ventricle — NO CHANGE.

c) Double contour of the right border of heart (shadow within shadow) — The outer and upper border is due to LA, and the inner and lower border is due to RA enlargement.

d) Evidence of 'pulmonary hypertension' — Dilated pulmonary arteries at hilum with peripheral pruning (i.e., peripherally pulmonary arteries taper sharply).

e) Dilatation of upper lobe pulmonary veins (earliest X-ray feature of pulmonary venous hypertension).

f) Fan-shaped opacity ("bats'-wing" appearance from parahilar region to periphery indicates pulmonary oedema.

g) Kerley's B lines — Fine, dense horizontal lines at the base of the lung due to distension of interlobular septa and lymphatics, with oedema.

h) Mitral valve calcification — Best seen in fluoroscopy.

i) Elevation of left upper lobe bronchus which becomes horizontal (due to LA enlargement).

j) Multiple small opacities from pulmonary haemosiderosis (subjects who had multiple haemoptysis may show haemosiderin deposits in the lungs) and parenchymal ossification—rare.

(B) Chest X-ray (RAO view) — Right anterior oblique (RAO) view with barium-filled oesophagus is done. Oesophagus is pushed or curved backward (sickling of oesophagus) by the enlarged LA.

(C) Chest X-ray (lateral view)—Obliteration of retrosternal space in left lateral view with slight increase in transverse diameter of heart (PA view) indicates RVH. -Upturned' apex (in PA view) may result in boot-shaped configuration due to RVH.

(D) Electrocardiography (ECG) — In early stages, the ECG may be normal.

a) LA enlargement — Wide and notched P-wave (P-mitrale)

b) RVH

c) 'f-waves replacing P-waves, if atrial fibrillation develops

(E) Blood examination (for active rheumatic carditis) —

a) Total and differential count (TC and DC) b) ESR c) ASO titre

* All are raised in the presence of active carditis.

(F) Echocardiography (M-Mode and 2-D) to see chamber enlargement, valve pathology, valve movement, mitral orifice etc (in MS there are thickened immobile cusps, reduced valve area, LA enlargement and reduced rate of diastolic filling of LV).

(G) Cardiac catheterisation — To determine the haemodynamic status of the patient (pressure measurement, oxygen saturation in blood samples)—pressure gradient between LA and LV is determined.

(H) Doppler study — To know the functional status, speed and direction of blood flow in the heart chambers; to record pressure gradient across mitral valve.

**** Echocardiography confirms the diagnosis of valvular heart disease.**

Rationality of nervous system examination in MS i.e., in CVS ***cases :***

1. Hemiplegia or monoplegia may occur in a patient with MS (commonly with atrial fibrillation).
2. Sydenham's chorea.
3. Fundoscopy — Roth spot, hypertensive retinopathy.

Rationality of respiratory system examination in MS i.e., in CVS cases :

1. Respiration (tachypnoea, orthopnoea).
2. Hydrothorax (from CCF).
3. Crepitations at lung bases (due to left-sided heart failure).

Rationality of G. I. system examination in MS i.e., in CVS cases :

1. Liver — Soft and tender liver with mild enlargement due to CCF.
2. Spleen — In the presence of SBE, spleen may be palpable.
3. Ascites may develop from CCF.
4. Mesenteric embolism.

Rationality of skeletal system examination in cardiac disorders :

1. Build—
   a) Tall — Marfan's syndrome (MI or AI).
   b) Stunted growth — Turner's syndrome (coarctation of aorta).
2. Kyphoscoliosis (shifting of apex beat, deformity of precordium).
3. Polydactyly or syndactyly (congenital heart disease).
4. Cubitus valgus (Turner's syndrome may be associated with coarctation of aorta).
5. Fingerisation of thumb with upper limb dysplasia (Holt-Oram syndrome with ASD).
6. Rheumatoid arthritis or ankylosing spondylitis (MI or AI); rhumatic arthritis (carditis).

* Heart diseases may be congenital or acquired. The external features for *congenital heart diseases* are : cyanosis, clubbing, polycythemia, webbing of neck, hypertelorism, syndactyly, low set ears, cryptorchidism etc. In *acquired heart diseases,* search for stigmata of rheumatic fever (arthritis, subcutaneous nodules etc.), infective endocarditis (anaemia, clubbing, splenomegaly, Osier's node etc.) and coronary heart diseases (xanthelasma, arcus senilis, obesity, nicotine staining, ear lobe creases etc.).

Important points in general survey in CVS :

1. ***Decubitus*** - May be propped-up; orthopnoea.
2. Build - Dwarfism in cyanotic congenital heart diseases; tall in Marfan's syndrome.
3. Nutrition - Cardiac cachexia in severe chronic heart failure.

4. ***Anaemia*** - Present in SBE (remember, anaemia can aggravate all heart diseases).
5. ***Cyanosis*** - Cyanotic congenital heart diseases, acute pulmonary oedema.
6. ***Clubbing*** - Cyanotic congenital heart disease, SBE, Eisenmenger's syndrome.
7. ***Pulse*** - Very important clue to diagnosis in different cardiovascular disorders.
8. ***BP*** - Must be seen in all patients: of immense value in diagnosis.
9. Respiration - Tachypnoea, hyperventilation.
10. Temperature - Elevated in SBE, tuberculous pericarditis.
11. ***Oedema*** - CCF, constrictive pericarditis, pericardial effusion, tricuspid value disease.
12. ***Neck vein*** - Reflects central venous pressure; found in RVF.
13. Thyroid - One should search for thyrotoxic features in all CVS disorders.
14. Jaundice - Rare; due to congestive hepatomegaly from CCF, or cardiac cirrhosis.
15. Skin - Osier's node, patechial haemorrhages, rheumatic subcutaneous nodules.
16. Skeletal - Kyphoscoliosis, cubitus valgus, polydactyly.

Treatment of MS :

Mild MS may need no treatment. The different modalities of treatment are :

a) Drugs (medical treatment).
b) Percutaneous mitral balloon valvuloplasty (treatment of choice).
c) Valvotomy or commissurotomy — Closed and open (closed type is preferred). Open valvotomy needs open heart surgery with cardio-pulmonary by-pass.
d) Mitral valve reconstruction including annuloplasty.
e) Valve replacement or prosthesis (Starr-Edwards ball valve or Bjork-Shiley disc valve).

Indications of valvotomy :

1. Progressive symptomatic deterioration inspite of medical treatment.
2. MS with complications (as mentioned earlier) e.g., haemoptysis.
3. Asymptomatic patients with a single attack of thromboembolic manifestation.
4. MS with pregnancy where previous pregnancy was symptomatic.
5. Mitral valve orifice <1 cm^2.

Contraindications of closed valvotomy :

1. **MS** with significant MI.
2. MS with left atrial thrombus.
3. Valvular calcification.
4. Presence of active rheumatic carditis.
5. Extremely tight stenosis.
6. Mitral valve distorted by previous operation (i.e., restenosis cases).

Actually, these are indications for open valvotomy.

N.B. : Approximately 85% patients develop restenosis at 10 years after mitral valvotomy. Loud S, and OS persist after mitral valve prosthesis.

Criteria for mitral valvuloplasty :

1. Significant symptomatic MS.
2. Pure MS (may have trivial MI).
3. Left atrium is free of clots.
4. Valve and sub-valvular apparatus are free of calcification.

Treatment done in MS with MI:

Mitral valve replacement (prosthesis). Mechanical prosthesis like Starr-Edwards valve or Bjork-Shiley valve, or porcine bioprosthesis may be used. Prosthesis is done in grossly damaged valve and sub-valvular structures, and in presence of MI. Artificial valves may work for more than 20 years.

Medical treatment in MS :

1. Treatment of CCF by restriction of physical activity, salt-restricted diet, diuretics and digoxin (available as 0.25 mg tablet).
2. Antibiotic prophylaxis against infective endocarditis is advised though it is uncommon in pure MS (see the section on 'Aortic stenosis'). Secondary prevention of acute rheumatic fever is done.
3. Anticoagulation in the presence of atrial fibrillation or big left atrial clot to reduce the risk of systemic embolism.

4. Treatment of atrial fibrillation with digoxin, (3-blockers or rate-limiting calcium channel blockers (singly or in combination).
5. Management of complications like haemoptysis, acute pulmonary oedema are done accordingly.

MS with pregnancy : outline of management :

Rheumatic heart disease accounts for 90% of all cardiac diseases in pregnancy. Of these, MS is the commonest lesion. The principles of management are,

1. Schedule treatment of MS. Note : functional degradation (e.g., patient deteriorates from grade I to grade II NYHA classification) occurs in pregnancy due to increase in cardiac output.
2. Increased bed rest.
3. Adequate nutrition and correction of anaemia.
4. Therapeutic abortion—in selected cases e.g., with H/O repeated heart failure before conception, controlled heart failure in 1st trimester.
5. Mitral valvotomy—in symptomatic tight MS, in midtrimester.
6. Ideally all other cases should go Into labour with scrupulous monitoring and not allowing the patient to strain in 2nd stage of labour.
7. Caesarean section may be performed where indicated.
8. Patients are advised to restrict the number of children to one or two.

Metallic mitral valve prosthesis in MS—auscultatory findings :

1. A metallic sound is audible in mitral area which coincides with S .
2. Normal S_2.
3. A metallic opening snap.

Prosthetic valves are of two types :

- Metallic valve—Starr-Edwards, Bjork-Shiley, St. Judes valve
- Tissue valve (human—homograft; porcine or bovine—xenograft)—Carpentier-Edwards, Ionescu-Shiley. Hancock porcine valve.

Complications of prosthetic valve :

Thromboembolism (needs anticoagulation), infective endocarditis, valve failure/leaking/obstruction by thrombosis or calcification/perforation/rupture, microangiopathic haemolytic anaemia etc.

N.B. : One should not use abbreviations like MS, MI, PH, BP etc; use the full term e.g., mitral stenosis, mitral incompetence, pulmonary hypertension, blood pressure respectively. In this book, abbreviations are used just to avoid repetition of long words. One should search for signs of active rheumatic carditis in all valvular heart diseases. Before stating the P/D as MS, one must be sure that there are no other valvular lesion like AI. MI or AS. If MS is associated with pulmonary hypertension, some changes develop in the palpatory and auscultatory findings — carefully search for them: often they are missed (read the section on 'Mitral incompetence' for the features of pulmonary hypertension).

Case 2

MITRAL INCOMPETENCE

What is your diagnosis ?

This is a case of organic mitral incompetence (regurgitation) of rheumatic origin with features of congestive cardiac failure and pulmonary hypertension, and the patient is in sinus rhythm at present.

What is your case ?

Build up the summary. The symptoms are almost similar to that of MS. Symptomatology consists of exertional dyspnoea, orthopnoea, PND, fatigue, recurrent respiratory tract infections, palpitation, oedema feet due to CCF or features of SBE (fever, embolic episodes etc.).

Palpitation is due to.

1. LVH, and / or
2. Atrial fibrillation (palpitation in MS is due to RVH or atrial fibrillation).

Why ***it is a case of mitral incompetence (MI)*** ?

It is a case of MI because of the presence of :

(A) Symptoms (from the history) :

a) Exertional dyspnoea, and

b) Palpitation for last 6 months.

(plus past H/O rheumatic fever).

(B) Signs :

a) Decubitus - Propped-up.

b) Pulse - Rate is 110/minute; otherwise normal arterial pulse (rarely the pulse is jerky or of good volume); describe all the points.

c) JVP - Engorged and pulsatile (CCF).

d) Oedema - Bipedal and pitting in nature (CCF).

e) Precordium - Bulged.

f) Epigastric pulsation - Present (RVH).

g) Apex - Present in left 7th ICS, 1/2" outside the left MCL (LVH); hyperdynamic in character; systolic thrill is present in apical area which is best palpable in left lateral position and at the height of expiration.

h) Left parasternal heave - Present (RVH).

i) Palpation of pulmonary area - Diastolic shock (palpable P_2) present,

j) Auscultation—

(i) Mitral area -

S_1 — Soft

5_2 — Audible

5_3 or S_4—Not audible at present

There is a high-pitched, soft blowing pansystolic murmur of Grade IV intensity which is best heard with the diaphragm of stethoscope, in left lateral position of the patient and at the height of expiration. The murmur is radiated towards the left axilla and inferior angle of left scapula **(hallmark of diagnosis)**

(ii) Pulmonary area - Ejection systolic murmur (different from pansystolic murmur at apex) with loud P_2.

(iii) Other areas - Within normal limit, i.e., S, and S_2 are audible, and there is no murmur, split, click or rub.

[k) G. I. tract —

(i) Liver—Mild (enlargement), soft and tender hepatomegaly (CCF).

(ii) Spleen—Not palpable.

(iii) Ascites—Absent.

1) Respiratory system —

(i) Breath sound - Vesicular, rhonchi—occasionally present, crepitations - nil.

(ii) Hydrothorax—Not present.

m) Nervous system—Within normal limits.]

* Actually, these are features of MI with pulmonary hypertension and CCF.

** 'Rocking motion over the precordium' in each cardiac cycle in MI may be due to retraction of the left ventricle as well as expansion of the left atrium during systole.

Features of LVH :

Apex goes down and outwards.

Features of RVH :

1. Apex goes outwards.
2. Left parasternal heave.
3. Epigastric pulsation.

* Cardiac apex remains down and outwards in combined LVH + RVH.

Cardinal signs of LVF (left heart failure / left-sided failure) :

Three cardinal signs are—

1. Gallop rhythm (addition of S_3 or S_4, along with S, and S_2 produces **'triple rhythm'.** Triple rhythm with sinus tachycardia is known as **gallop rhythm** — so called because of its resemblance with the cadence produced by galloping of horses). So, *presence of gallop rhythm indicates heart failure.*
2. Fine crepitations at lung bases (i.e., basal crepitations).
3. Pulsus altemans.

* Sometimes, there are associated Cheyne-Stokes breathing, tachypnoea, central cyanosis, LVH and signs of underlying disease. The patient usually c/o breathlessness (including orthopnoea and PND), fatigue and mental confusion. Remember, pulmonary oedema is a feature of left-sided heart failure.

** **Gallop** is of two types :

1. Quadruple gallop — Four distinct heart sounds due to audibility of S_3 and S_4 separately, and
2. Summation gallop — The extra sound is produced as a result of superimposition of S_3 on S_4 (i.e., three audible sounds in one cardiac cycle).

*** Ventricular gallop S,, S_2, S.(; atrial gallop S_p S_2, S_4

Cardinal signs of RVF (right heart failure / right-sided failure / CCF) :

Three cardinal signs are —

1. Engorged and pulsatile neck veins.
2. Mildly enlarged, soft, tender liver.
3. Dependent bipedal oedema (pitting).

* Sometimes there are associated cardiomegaly, peripheral cyanosis, pulsatile liver (rare), pansystolic murmur of TI and right ventricular gallop rhythm. The patient c/o breathlessness, cough, oedema, oliguria, G. I. tract disturbances (e.g., anorexia, nausea, vomiting, right hypochondriac pain due to stretching of hepatic capsule) and swelling of abdomen (ascites). Cardiac cachexia (due to T tumour necrosis factor, T basal metabolic rate, anorexia, nausea, vomiting) is not uncommon.

Precipitating causes of cardiac failure in a patient of valvular heart disease :

- Severe anaemia, pregnancy, respiratory tract infections.
- Tachyarrhythmias, infective endocarditis, pulmonary thromboembolism, thyrotoxicosis.
- Ongoing rheumatic activity.

What is apex beat ?

It is the lowermost and outermost part of the precordium where a DEFINITE (most important, and not necessarily the maximum) thrust can be felt.

When the same cardiac pulsation is seen, it is called **apical impulse.** 'Cardiac impulse' is a better terminology than apical impulse because any pulsation 'seen' over the precordium may not correspond with the apex beat detected by palpation. If the apical impulse is not visible in supine position of the patient (best visible from the right side of the patient by a tangential view), the patient is turned to left lateral position when the apical impulse may be visible somewhere near the left anterior axillary line. Causes of non-visibility of apical impulse are same as causes of non-palpable apex (see below).

What is the significance of apex beat ?

It is an important parameter by which one can assess the enlargement of heart (in the absence of push-pull effect of lung) and the activity of myocardium.

How to localise the apex ?

1. The patient should lie flat or supine. Place your whole flat of right palm over the precordium (always stand on the right side of the patient). Try to localise the definite thrust (not necessarily the maximum) with outstretched fingers. If a definite thrust is palpable, confirm it by pulp of index or middle finger, and locate it by counting the ribs; look, how far it is from the left midclavicular line (inside or outside).
2. If the apex beat is not palpable in dorsal decubitus position, ask the patient to sit and lean forward. Again try to locate it.
3. If the apex is not palpable even in sitting position, place your right palm over the right side of the chest (to detect the presence of dextrocardia or dextroversion).
4. If still not palpable — Say that 'the apex could not be localised properly'.

* Remember, the heart has some mobility within the chest and thus never turn the patient to left lateral position for localisation of the apex beat (in left lateral position, apex shifts about 1-2 cm towards the left). **Normal position of the apex beat is in the left 5th ICS, 1/2" inside the left MCL (adult).**

In palpating apex, why the finger is lifted in systole when the ventricle is contracting ?

This is due to the complex rotatory movement of the heart in systole (vortex like movement), one manifestation of which is the forward movement of apex (the rotatory movement is due to the complex spiral arrangement of ventricular muscles).

ises of non-palpable apex ?

1. Apex lying behind a rib.
2. Obesity or thick chest wall.
3. Pendular breast in elderly female.
4. Emphysema (COPD).
5. Pleural effusion (left).
6. Pneumothorax (left)
7. Constrictive pericarditis.
8. Pericardial effusion.
9. Acute myocardial infarction.
10. Deformity of the chest (gross kyphoscoliosis)
11. Thickened pleura (left).
12. Heart failure.
13. Heart may be somewhere else (dextrocardia).

Describe different characters of the apex beat :

The normal apex beat is early systolic outward thrust located at a point not more than 2-3 cm in diameter. The different types are :

1. **HYPERDYNAMIC** (volume overload apex) —It means 'forceful and ill sustained' impulse found in conditions with diastolic overload of the left ventricle like MI, AI, VSD, PDA etc. As there is no obstruction to the blood pumped from the left ventricle, the apex remains ill sustained.
2. **HEAVING** (pressure overload apex) — It is a 'forceful and well sustained' impulse found in conditions with systolic overload of the left ventricle like AS, systemic hypertension, coarctation of aorta, obstructive cardiomyopathy etc. As there is some obstruction in left ventricular outflow tract, the apex becomes well sustained.
3. **TAPPING** (small area) or **SLAPPING** (diffuse)— When the accentuated first heart sound is palpable in MS or tachycardia due to any cause, it is known as tapping apex beat (remember, heart sounds are not palpable in health). The palpating finger is not lifted and the S_1 is felt as distinct palpable shock.
4. **HYPOKINETIC** — The thrust felt by the hand is minimal. It is found in acute myocardial infarction, pericardial effusion, constrictive pericarditis, myxoedema, peripheral circulatory failure.
5. **NORMAL** — Situated in the left 5th ICS, 1 /2" inside the left MCL which is a brief gentle tap not exceeding a 25-paisa coin size, not much forceful but usually palpable with certainty. In children, the apex beat is located in the left 4th ICS and in lean-tall persons, it is usually present in the left 6th ICS.

* There may be double kicking apex beat in IHSS (idiopathic hypertrophic subaortic stenosis or hypertrophic cardiomyopathy) and ventricular aneurysm.

** Regarding the **character of the apex beat,** some clinicians prefer the terms 'right ventricular (RV)' or 'left ventricular (LV)' type. In **LV type** the apex goes downwards and outwards as well as there is a larger impulse (usually more than a 25-paisa coin), and the impulse is maximal at the apex; if there is a left parasternal impulse, it is asynchronous with the apex beat. Whereas in **RV type,** the apex goes outwards as well as there is production of left parasternal heave, and both are synchronous; in RV type, the cardiac impulse is maximal over the lower left sternal border.

*** *While palpating for pulsations, e.g., apex beat — use the pulp of the fingers; for thrills—use the base of the fingers; and for parasternal heaves—use the base of the hand (i.e., thenar and hypothenar eminences).*

Different positions of heart :

- Levocardia — Cardiac apex on left side of chest (situs solitus).
- Dextrocardia — Cardiac apex on right side of chest.
- Mesocardia — Cardiac apex over the centre of chest.
- Dextrocardia with situs inversus (heart per se does not show any abnormality).
- Isolated dextrocardia — Dextrocardia without situs inversus; almost always have cardiac malformations.
- Isolated levocardia — Cardiac apex on left side with viscera rotated (partial or totally) to opposite side.
- Dextroversion — Always acquired; cardiac apex is on right side due to extracardiac causes like left-sided pleural effusion/pneumothorax, or right-sided fibrosis/collapse of lung (i.e., push-pull effects). Remember, trachea is moved to the right side too.

* 'Situs inversus' is the rotation of abdominal /thoracic organs to opposite site, either totally (totalis) or partially (partialis).

Clinical features of pulmonary hypertension :

Normal pulmonary artery pressure is 25 / 10 mm of Hg. Pulmonary hypertension is said to be present when mean pulmonary artery pressure is > 25 mm of Hg at rest or > 30 mm of Hg during exercise.

(A) Symptoms—

1. Breathlessness (often severe; exertional).
2. Easy fatiguability.
3. Dizziness.
4. Syncope (due to low fixed stroke volume).
5. Chest pain (angina pectoris).
6. Cough; haemoptysis.

(B) Signs—

1. Pulse — Low volume.
2. Neck veins — a-wave is prominent.
3. Central cyanosis—in right-to-left shunt, lung diseases (COPD, interstitial lung disease).
4. a) **Inspection**—
   (i) Visible pulmonary artery pulsation in left 2nd ICS.
   (ii) Epigastric pulsation.

   b) **Palpation**—
   (i) Apex goes outwards.
   (ii) P_2 — Diastolic shock, i.e., P_2 is palpable.
   (iii) Left parasternal heave.
   (iv) Pulsation of pulmonary artery may be felt in upper left parasternal area.

   c) **Purcussion**—Left 2nd ICS may be dull on percussion.

   d) **Auscultation (pulmonary area)** — The **classical sequence of events** are,
   (i) S, — Audible.
   (ii) Pulmonary ejection click.
   (iii) Ejection systolic murmur (due to relative obstruction at pulmonary orifice).
   (iv) Close splitting of S_2 with loud P_2.
   (v) Graham Steell murmur — A high-pitched early diastolic decrescendo murmur due to functional pulmonary incompetence (pulmonary valve ring dilatation).
   (vi) Right-sided S_3 (right ventricular gallop) — Heard at the lower left sternal border.

Among these features, the ejection systolic murmur with palpable as well as audible loud P_2 are commonly found. Remember, (i) Epigastric pulsation, (ii) Left parasternal heave, and (iii) Outward apex are features of RVH. RVH is usually present in a case of pulmonary hypertension of some duration.

(• Chest X-ray- Bulging right and left pulmonary arteries at hilum, peripheral pruning of large pulmonary arteries, enlargement of RV and RA of heart.
- ECG - RV strain or hypertrophy, and RA enlargement.
- Echocardiography - RV enlargement with paradoxical motion of interventricular septum.
- Pulmonary function test, lung scan and pulmonary angiorgraphy in appropriate cases].

* For demonstration of 'Signs' anywhere in clinical medicine, always start from general survey.

** Unless otherwise mentioned, pulmonary hyertension means pulmonary arterial hypertension. As soon as pulmonary hypertension develops from valvular heart disease, it protects the patient from pulmonary oedema.

Causes of pulmonary hypertension :

Pulmonary hypertension is basically of two types : Primary pulmonary hypertension (No. 6 below) and secondary pulmonary hypertension (No. 1 to 7, except No. 6)

1. Passive — From left-sided heart diseases like MS, MI, AI, AS.
2. Hyperkinetic (left-to-right shunt) — ASD, VSD, PDA.
3. Vasoconstrictive (hypoxic) — Chronic cor pulmonale.
4. Obstructive — Pulmonary thromboembolism (acute cor pulmonale).
5. Obliterative — SLE, systemic sclerosis, polyarteritis nodosa.
6. Neurohumoral or idiopathic — Primary pulmonary hypertension (common in females in 3rd and 4th decades).
7. Miscellaneous — Sleep apnoea, Pickwickian syndrome, drugs like aminorex fumarate.

Gradation of dyspnoea :

Functional gradation of heart disease by New York Heart Association— **'NYHA classification':**

Grade I : No limitation of activities with ordinary physical work (activity), i.e., asymptomatic though the patient is suffering from organic heart disease (there is no grade 0).

Grade II : No limitation under resting condition but symptoms appear on ordinary activity.

Grade III : Limitation of activities on mild exertion or less than ordinary physical activity.

Grade IV : Limitation of activities at rest, restricting the person to bed or chair.

* Remember, this functional classification refers not only to dyspnoea but to symptoms like fatigue, palpitation, angina pectoris etc. This is actually a *classification of cardiac disability.* Dyspnoea due to cardiovascular diseases should always be quantified by this classification.

Aetiology of MI:

1. **Rheumatic** (commonest).
2. Functional Associated with LVH (due to dilatation of mitral ring) as found in systemic hypertension, aortic valvular diseases (AS, AI). IHD, myocarditis, cardiomyopathy or acute rheumatic carditis.
3. Mitral valve prolapse syndrome (MVPS).
4. Dysfunction of papillary muscle or chordae tendineae (due to IHD i.e., ischaemic heart disease).
5. Acute myocardial infarction (due to rupture of papillary muscle).
6. Traumatic — During mitral valvotomy.
7. Infective endocarditis.
8. Collagen vascular diseases Marfan's syndrome, SLE (Libman-Sacks endocarditis), rheumatoid arthritis, ankylosing spondylitis etc.
9. Dilated cardiomyopathy.
10. Congenital.

* Three most common causes of MI according to order of frequency are rheumatic. MVPS and IHD.

Causes of acute MI:

1. Acute myocardial infarction (papillary muscle dysfunction/or rupture of chordae tendineae).
2. Infective endocarditis (rupture of valve cusps or chordae tendineae).
3. Trauma in the chest.
4. Acute rheumatic fever.
5. Cardiac surgery.

What is mitral valve prolapse syndrome (MVPS) ?

The other names of this disease are systolic click-murmur syndrome, Barlow's syndrome, floppy-valve syndrome. There is excessive mitral leaflet tissue which is commonly involved with myxomatous degeneration. MVPS is frequently associated with Marfan's syndrome, Ehlers-Danlos syndrome and osteogenesis imperfecta. It is common in young females. The patient is usually asymptomatic or may present with palpitation or chest pain. A mid- or late systolic click with high-pitched late systolic murmur best heard at the apex is the classical auscultatory finding. Treatment is done by propranolol for chest pain and arrhythmia, antibiotic prophylaxis for SBE, antiplatelets (e.g., aspirin) for prevention of transient ischaemic attacks (TLA), and valve replacement by prosthesis for permanent remedy.

What is seagull murmur ?

If a patient develops SBE over MI, the character of MI murmur changes with a musical quality called seagull murmur. Here the ruptured chordae tendineae acts as the string of the musical instrument. Seagull murmur is also known as 'cooing dove murmur'. This type of musical murmur is also found in acute myocardial infarction, syphilitic AI and rarely in acute rheumatic fever.

Can MI produce apical mid diastolic murmur ?

Yes. The increased flow through the valve in diastole may produce a low-pitched mid-diastolic rumbling murmur (functional MS), often with a S_r

Radiation of murmur if posterior mitral leaflet is affected :

In *posterior mitral leajlet* affection, pansystolic murmur of MI radiates to the anterior precordium and upto the pulmonary area. In a classical case of MI with radiation of murmur towards the left axilla and inferior angle of left scapula, the pathology remains in the *anterior mitral leajlet.* Rheumatic MI predominantly affects anterior mitral leaflet.

What is 'bruit'?

When the murmurs occur at the site of arterial stenosis, they are traditionally called bruits, e.g., renal artery bruit in renal artery stenosis. A short systolic bruit is produced in 50% or less obstruction, continuous bruit in 75% or more obstruction, and there is no bruit in 100% obstruction.

Differential diagnosis (D/D) of your case :

1. Functional murmur - Usually soft, not pansystolic, do not radiate to the axilla and without any thrill. No alteration with change of posture and respiration.
2. VSD - History starts from early childhood. Rough, pansystolic murmur, best audible over the lower left parasternal area; radiation to right chest. Very often associated with systolic thrill.
3. Conducted murmur of aortic stenosis - Harsh, mid-systolic murmur.
4. Tricuspid incompetence (TI) - Murmur best audible over the tricuspid area with positive Carvallo's sign (increase in intensity of murmur with inspiration), not conducted to the axilla, and may be associated with features of CCF (in functional TI, search for pulsatile liver and engorged-pulsatile neck vein).

Definition of pansystolic or holosystolic murmur :

They start immediately with the S and continue through to the S_2 (pansystolic). They always have a uniform intensity and thus known as holosystolic.

Why the murmur of MI is pansystolic ?

As soon as the LV pressure exceeds LA pressure, i.e., JUST AFTER THE Sj, the regurgitant jet of blood goes from LV to LA and CONTINUES TO AND THROUGH THE S_2 until the LA pressure exceeds LV pressure. This is why the murmur of MI is pansystolic in nature.

How to describe the 'intensity' or 'grading' of a murmur ?

The intensity of murmurs are divided into SIX GRADES (Levine's grading system). Grade I is a very faint murmur heard on careful auscultation, and grade VI murmur may be heard without a stethoscope and with the head just away from the chest (loudest).

If the murmur is associated with thrill, the grading is IV or IV+ (i.e., it may be grade IV, V or VI). Thrill is absent in grade I, II, and III. Diastolic murmurs are only graded upto IV.

Grade I — Very faint or soft (can be heard only with special effort)

Grade II — Soft

Grade III — Moderate

Grade IV — Loud with presence of thrill

Grade V — Very loud with associated thrill

Grade VI — Extremely loud and may be heard without a stethoscope; with associated thrill.

How to assess the 'severity' of MI clinically ?

Severe MI is assessed at the bedside by :

1. Presence of apical mid-diastolic flow murmur,
2. Left ventricular (apical) S_3,
3. Degree of LVH, and
4. Presence of systolic thrill with a loud murmur over the apical area.

Surface marking of mitral valve :

It is obliquely placed behind the left 4th costal cartilage and the adjacent part of the sternum.

What is mitral area ?

It corresponds with the apex of the heart. Normally in an adult, the apex is situated in the left 5th ICS, 1/2" inside the left MCL. Suppose, in a patient the apex beat is palpable in the left 6th ICS, 1/2" outside the MCL (in LVH) - this (apical) area will be the mitral area of the patient. So mitral area is a mobile area according to the position of the apex or apical area, i.e., it is not a fixed area. Tricuspid, aortic and pulmonary areas are always fixed in their location. See page 418 for other details.

When the patient is turned to left side while examining the CVS ?

1. To note the 'character' of apex beat,

2. For better palpation of the diastolic thrill (MS), and
3. For better auscultation of the diastolic murmur (MS).

* It is also said that in a case of MI. palpation of the systolic thrill and auscultation of the systolic murmur are better perceived in left lateral position. Never turn the patient to the left to localise the site of apex beat.

Palpate the mitral area :

Following four points are to be noted :

a) Site of apex beat.
b) Character of apex beat.
c) Palpable heart sound (M,).
d) Any thrill.

Steps :

1. First locate the apex by proper clinical method described in page 21.
2. Then note the character of the apex beat — Turn the patient to left lateral position.
3. Next, one should confirm whether any palpable heart sound is present or not.
4. Lastly, feel for any thrill (one should put his left thumb over the right carotid) - if there is any difficulty, turn the patient to left lateral position and try to palpate the thrill in a better way at the height of expiration.

Complications of MI:

1. Acute LVF.
2. Infective endocarditis (more common than MS).
3. CCF.
4. Arrhythmias :
   (i) Ventricular ectopics.
   (ii) Atrial fibrillation (with embolic manifestations).
5. Giant left atrium may produce :
   (i) Pressure symptoms — dysphagia, hoarseness of voice.
   (ii) Atrial fibrillation.
6. Recurrent respiratory tract infections.

How do you like to investigate a case of MI ?

(A) Chest X-ray (PA view) :
   1. LVH.
   2. LAH (giant left atrium).
   3. Signs of pulmonary venous hypertension (in acute MI).
   4. RVH.

(B) ECG : The ECG may be normal in early stages. Following abnormalities may be seen :
   1. LAH (approximately in all chronic cases).
   2. LVH (50% cases).
   3. Biventricular hypertrophy (25% cases).
   4. Atrial fibrillation.

(C) Curved barium-filled oesophagus pushed by enlarged LA in RAO view of chest X-ray.

(D) Blood for (to detect active rheumatic carditis) :
   1. TC and DC 2. ESR 3. ASO titre

(E) Echocardiography (giant or aneurysmal left atrium may be seen).

(F) Doppler study (it quantifies the regurgitation).

(G) Cardiac catheterisation with left ventriculography.

Treatment of MI:

1. Medical treatment — As in MS. MI of moderate severity can be managed medically. For the case described at the outset, digitalis and diuretic should be given to treat CCF; penicillin prophylaxis against SBE is a must. Digitalis and anticoagulants are aded if AF is present. Vasodilators (nitrates, ACE-inhibitors) can reduce the regurgitant flow and may be helpful in severe cases.

2. Surgical treatment — Implantation of prosthesis (mitral valve replacement) is done under open heart surgery; sometimes, repair by mitral annuloplasty or valvuloplasty is done.

Features of digitalis toxicity :

1. Non-cardiac - Anorexia, nausea, vomiting (due to direct stimulation of CTZ at medulla), and diarrhoea; these are the earliest signs of toxicity.
2. Cardiac -
   - (i) Premature ventricular beats (bigeminy and multiform).
   - (ii) Varying degree of AV block (bradycardia).
   - (iii) Paroxysmal atrial tachycardia with block.
   - (iv) Ventricular tachycardia.
   - (v) Bidirectional tachycardia.
   - (vi) Sinus arrest.
   - (vii) Ventricular fibrillation.
3. Chronic toxicity -
   - (i) Weight loss.
   - (ii) Cachexia.
   - (iii) Gynaecomastia.
   - (iv) Xanthopsia (yellow vision).
   - (v) Agitation, psychosis, delirium

* Digitalis toxicity is managed by withholding digoxin. withdrawal of diuretic (hypokalaemia increases digitalis toxicity), giving potassium, administration of lignocaine or phenytoin to combat ventricular arrhythmias, and repeated application of digoxin antibody (Fab fragments).

What is cadiac output, cardiac index and ejection fraction ?

(A) CARDIAC OUTPUT = Stroke volume (output per ventricle per beat) X heart rate.

Normal - . 5 - 6 litre/minute

(B) CARDIAC INDEX = Cardiac output / minute / square meter of body surface

Normal : 3.3 litre / minute / m^2

(C) EJECTION FRACTION = $\frac{\text{End-diastolic volume - End-systolic volume}}{\text{End-diastolic volu}^{\wedge}}$

Normal : 55-80%
Mild left ventricular dysfunction : 40-50%
Moderate left ventricular dysfunction : 30-40%
Severe left ventricular dysfunction : < 30%

Why history of drug intake is important in cardiology ?

1. Drugs can aggravate a disease ([3-blockers in heart block, thyroxine in angina, amlodipine in oedema, salbutamol in palpitation, a-blockers in postural hyotension, steroids in systemic hypertension).
2. Drugs can mask a disease (antihypertensives in systemic hypertension, diuretics in MS).
3. Drugs can modify a disease (oral contraceptive pills in systemic hypertension).
4. Drugs can cure a disease or alter physical sign (diuretics abolish the gallop rhythm in heart failure).
5. Drugs can induce a disease ((3-blockers in hyperlipidaemia, alcohol in cardiomyopathy).

N.B. : Diastolic murmur in MS is very frequent clinical sign, but systolic murmur in MS is rather common.

Case 3

AORTIC STENOSIS

What is your diagnosis ?

This is a case of valvular aortic stenosis (AS) of rheumatic origin with congestive cardiac failure and the patient is in sinus rhythm at present.

What is your case ?

Build up the summary. The chief presenting symptoms in AS are exertional dyspnoea, angina pain, syncope and features related to LVF. All the symptoms are usually 'exertional'.

a) Dyspnoea is primarily due to elevation of the pulmonary capillary pressure, pulmonary oedema; later on PND may occur. Severe AS may exist for many years without producing any clinical disability.

b) Anginal pain is due to low aortic blood pressure and low cardiac output. Increased 0_2 demand due to increased muscle mass (LVH) is also important. Thus, coronary blood flow cannot be maintained while on exertion.

c) Syncope or black-out may be due to low and fixed cardiac output, LVF, low BP or transient atrioventricular block (all causing cerebral hypoperfusion). Sometimes, the patient complains of light-headedness, faintness or giddiness.

* *Dyspnoea, angina pectoris and syncope are three cardinal symptoms of AS;* sometimes, a patient may be brought in the hospital emergency with 'sudden cardiac death'.

Why do you say aortic stenosis ?

Because there is presence of :

(A) Symptoms (from the history) -

a) Pain chest for 1 year.

b) Exertional dyspnoea for 9 months.

c) Occasional black-out for last 2 months.

(plus past H/O rheumatic fever).

(B) Signs -

a) Pulse - 72 / min, low volume, regular, no radio-radial and radio-femoral delay, arterial wall is not thickened, all the peripheral pulses are palpable and of 'anacrotic' in type (also called pulsus parvus et tardus). *'Carotid shudder'*, i.e., a systolic thrill in the carotid artery is felt.

b) BP - Low (say, 90/65 mm of Hg.) with low pulse pressure (in supine position).

c) Apex beat - In normal position (i.e., left 5th ICS, 1/2" inside the left MCL) and heaving in character (though there is LVH, apex is usually not shifted because AS causes concentric hypertrophy). There is no palpable heart sound, no thrill in the apical area.

d) Palpation of the aortic area - Systolic thrill felt. Best felt in full expiration with the patient sitting and leaning forward. The thrill is radiated to the carotid artery.

e) Auscultation of the aortic area —

S, - Audible

S_2 (A_2) - Muffled

Ejection click — Present

A harsh midsystolic ejection murmur of grade V with direction of selective propagation towards the carotids is heard. The murmur is best audible in full expiration with the patient sitting and leaning forward, and with the diaphragm of stethoscope (occasionally the murmur of AS is transmitted to the mitral area and is known as *Gallavardin's phenomenon).*

0 Auscultation of other areas of heart and lung—Within normal limit. No adventitious sound heard.

(g) Examination of respiratory system, G. I. tract and nervous system revealed no abnormality).

* The murmur of AS is known as saw-like murmur or crescendo-decrescendo murmur (never say diamond shaped' murmur as this is the phonocardiographic pattern of AS murmur).

** Add features of pulmonary hypertension, if present.

*** The normal aortic valve area is 2.5-3.5 cm^2. If it is < 1 cm^2 or having a gradient > 50 mm of Hg (normally, no gradient), the stenosis is critical.

****The pulse is not only small in volume but is slow in rising to a peak (plateau pulse).

Why the murmur of AS is midsystolic ?

The pressure gradient between the left ventricle and aorta is greatest in the middle of systole, and this is why the murmur of AS is midsystolic.

Significance of ejection click :

Ejection click is a sharp and high-pitched clicking sound heard immediately after the first heart sound due to sudden opening of the aortic or pulmonary valve (semilunar valves), and are best audible in aortic (in aortic stenosis) and pulmonary area (in pulmonary stenosis) respectively. **Its presence indicates that the stenosis is at the 'valvular' level and the stenosis (aortic stenosis or pulmonary stenosis) is of milder degree.** Pulmonary ejection click in pulmonary stenosis becomes less audible (soft) in inspiration, in contrast to all other right-sided events.

Example of 'non-ejection click' is mitral valve prolapse syndrome (MVPS).

Aetiology of AS :

1. **Rheumatic** (it should be remembered that isolated rheumatic AS is rare: usually it is associated with MS, AI or MI — So, try to find them out. Aortic valve is the second most frequently affected valve in rheumatic fever after mitral valve).
2. Congenital (commonly bicuspid aortic valve) - Young adult patients.
3. Calcific degeneration of the aortic valve (old age).
4. Associated with familial hypercholesterolaemia, mucopolysaccharidosis.
5. Functional — In severe AI, thyrotoxicosis, severe anaemia etc.

* Calcific valvular disease is the commonest cause of AS.

Types of aortic stenosis :

(A) Valvular — Examples are described above in 'Aetiology of AS'.

(B) Supravalvular — May be associated with Elfin facies, mental retardation, hypercalcaemia.

(C) Subvalvular (special variety is IHSS) — Idiopathic hypertrophic subaortic stenosis.

* Elfin facies — Broad forehead, pointed chin, cupid's bow-like upper lip, upturned nose, hypertelorism and low set ears (seen in supravalvular AS and when associated with mental retardation and hypercalcaemia, it is known as William's syndrome).

Causes ***of RVH :***

1. Pulmonary hypertension (specially MS and other left-sided valvular diseases, COPD).
2. Pulmonary stenosis.
3. Cardiomyopathy.
4. ASD, VSD.
5. Fallot's tetralogy.
6. Hyperdynamic circulation.

What are the types of LVH ?

(A) **CONCENTRIC** (muscle mass increases at the cost of left ventricular cavity i.e., left ventricle is more hypertrophied than dilated - so the apex is not shifted much). The examples are basically left ventricular outflow tract obstruction, and are :

1. AS.
2. IHSS.
3. Coarctation of aorta.
4. Systemic hypertension.

(B) **ECCENTRIC** (left ventricular dilatation as well as increase in its muscle mass - so the apex goes down and outwards). The examples are :

1. Systemic hypertension.
2. MI or AI.
3. Ischaemic heart disease (IHD).
4. Severe anaemia (hyperdynamic circulation).
5. Thyrotoxicosis.
6. Cardiomyopathy (dilated).
7. VSD, PDA.

* **Combined A + B are the causes of LVH.**

** Hypertrophy of ventricle is due to pressure overload (e.g., systemic hypertension) and dilatation is the result of volume overload (e.g., AI, MI).

Causes of right atrial hypertrophy :

1. Tricuspid stenosis.
2. Tricuspid incompetence.
3. RVH of some duration.

Causes of left atrial hypertrophy :

1. MS.
2. MI (giant left atrium may be seen).
3. LVH of some duration.

Causes of ***biventricular hypertrophy (LVH + RVH) :***

1. Cardiomyopathy (dilated).
2. Ventricular septal defect.

3. Myocarditis.
4. Ishaemic heart disease.
5. Systemic as well as pulmonary hypertension.
6. Hyperkinetic circulation (e.g., in severe anaemia).

Commonest cause of displaced apex :

Deformity of thoracic cage, usually scoliosis. So, never forget to inspect the back in any CVS case.

Thrill in different areas of the heart :

(A) MITRAL AREA :

a) Systolic -
   1. MI (commonest).
   2. VSD.
   3. ASD (ostium primum type).

b) Diastolic -
   1. MS (commonest).
   2. Left atrial myxoma (very rare).

(B) AORTIC AREA :

Congenital or acquired AS (thrill in aortic area is almost exclusively systolic). Rarely, there is diastolic thrill of AI.

(C) PULMONARY AREA : Usualy it is systolic thrill—

1. Pulmonary stenosis.
2. ASD.
3. High VSD.
4. Fallot's tetralogy.
5. PDA (sometimes, continuous thrill).

* Graham Steell murmur is usually not associated with diastolic thrill.

(D) TRICUSPID AREA : Usually it is systolic thrill—

1. VSD.
2. Tricuspid incompetence.
3. ASD (ostium primum).
4. Pulmonary stenosis (infundibular type).

Causes of systolic murmur in base of the heart :

(A) AORTIC AREA :

1. Aortic stenosis (AS).
2. Coarctation of aorta.
3. Systemic hypertension.
4. Functional (from AI).
5. Aneurysm of aorta.
6. Aortic sclerosis (old age).

(B) PULMONARY AREA :

1. Pulmonary stenosis (PS).
2. Pulmonary hypertension.
3. Hyperkinetic circulatory states
4. ASD.
5. Fallot's tetralogy.
6. Innocent murmur.

Classify 'organic' murmurs :

(A) SYSTOLIC :

1. Ejection systolic — Starts after the S, and ends before the S_2. Examples are AS, PS and ASD.
2. Pansystolic — Starts immediately with the Sj and continues through to the S_2, and typically they are of uniform intensity (holosystolic), e.g.. MI, TI and VSD.
3. Late systolic, e.g., MVPS, IHSS, papillary muscle dysfunction.

(B) DIASTOLIC :

1. Early diastolic — AI, and PI (Graham Steell murmur).
2. Mid-diastolic — MS, TS, Austin Flint murmur, Carey-Coombs murmur, and flow murmur in ASD or VSD.
3. Presystolic or late diastolic — MS, atrial myxoma.

Palpation of base of the heart (in sitting position)

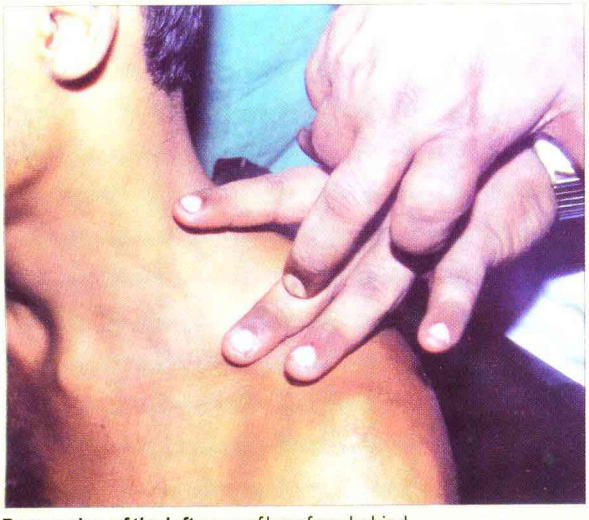

Percussion of the left apex of lung from behind

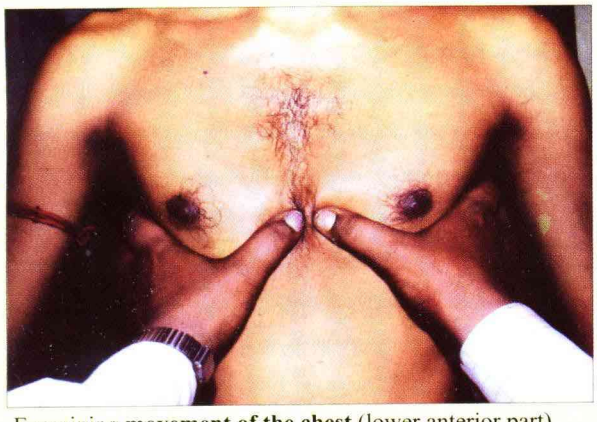

Examining **movement of the chest** (lower anterior part)

Palpation of trachea

Examining **movement of the chest** from back (apical area)

Examining **movement of the chest** (upper anterior part)

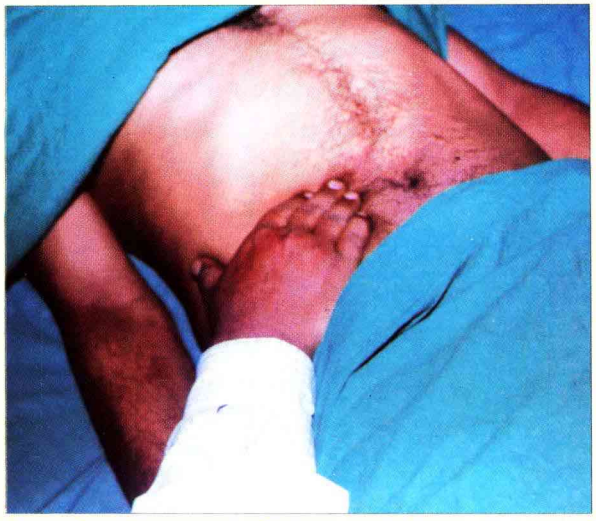

Palpation of liver (conventional method)

Palpation of liver (preferred method)

Palpation of liver (alternative method)

Palpation of spleen

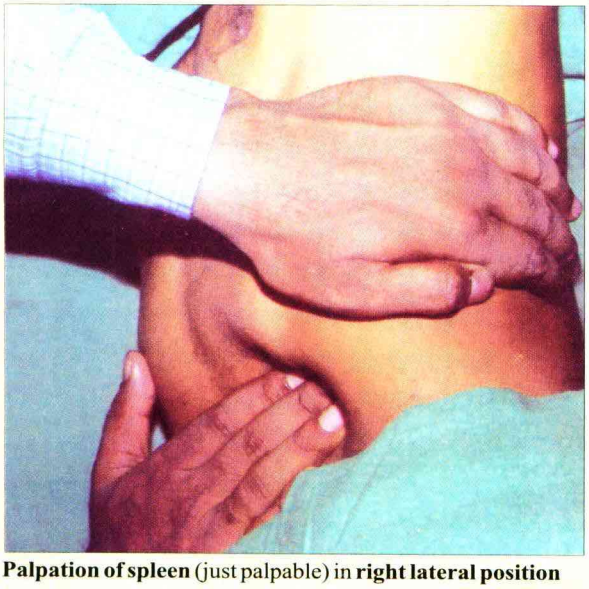

Palpation of spleen (just palpable) in **right lateral position**

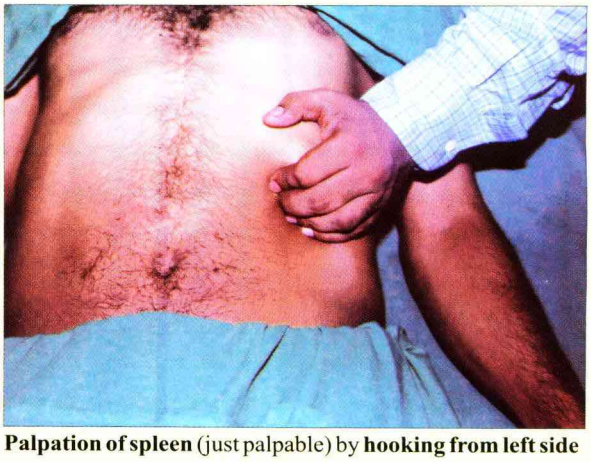

Palpation of spleen (just palpable) by **hooking from left side**

(C) CONTINUOUS :

1. PDA.
2. Rupture of sinus of Valsalva.
3. Pulmonary arteriovenous fistula.
4. Aortopulmonary window.
5. Coronary arteriovenous fistula.

Innocent murmur :

These are commonly found in **children** (Still's murmur) and usually disappear as the child grows older. Here, the heart with its valves are absolutely normal. Possible mechanisms are :

a) Hyperkinetic circulatory states in children due to increased heart rate, and

b) Increased resistance of the pulmonary vascular bed in children.

The characteristics are :

1. Usually systolic; soft (upto grade II); localised.
2. No thrill.
3. Best heard over the pulmonary area (mainly along upper left sternal border).
4. Heard best in supine position and may disappear in upright position; often the murmur is heard after exercise, crying or fever.
5. Associated with normal heart sounds, chest X-ray and ECG.

Haemic murmur :

Sometimes, an ejection systolic murmur is heard in pulmonary area when the person suffers from severe anaemia (so called haemic). The possible mechanisms are :

a) Increased flow of blood through the pulmonary artery, and

b) Dilatation of the pulmonary artery.

These mechanisms also play their part in other hyperkinetic circulatory states like pregnancy, thyrotoxicosis, high fever etc. Often severe anaemia produces mitral systolic murmur due to ring (mitral) dilatation. This type of murmur disappears after correction of the primary disease. They are never associated with abnormality in ECG. Sometimes, a systolic thrill is associated with haemic murmur.

Functional* murmur *:

In functional murmur, there is no organic heart disease present at the site of production of murmur and is produced only due to increased flow of blood. Many clinicians know these murmurs as 'flow murmurs'.

The common examples are :

1. Systolic murmur in the pulmonary area in a case of ASD.
2. Early diastolic Graham Steell murmur of pulmonary hypertension (functional pulmonary incompetence).
3. Functional systolic murmur in aortic area (functional AS) in a case of severe AI.
4. Apical mid-diastolic murmur in a case of severe AI (Austin Flint murmur).

Characteristics :

1. Usually systolic, may be diastolic.
2. Intensity of murmur — Not very loud.
3. Commonly without a thrill (remember, presence of thrill does not exclude functional murmur).
4. Not distributed to a wide area (more or less localised).
5. Does not change much with change of posture.
6. Does not produce cardiomegaly (haemodynamically insignificant).
7. Murmur disappears after correction of the increased flow.

Changing murmur :

These are the murmurs which change their character or intensity from time to time, e.g.,

1. Infective endocarditis,
2. Atrial myxomas, and
3. Atrial thrombus.

***How to assess the 'severity' of* AS *clinically* ?**

Severe AS is assessed at the bedside by the presence of :

1. H/O effort dyspnoea, effort syncope, effort angina.
2. Low volume pulse with a slowly rising plateau (e.g., delayed carotid upstroke).
3. Systolic decapitation of BP (low systolic pressure due to low and fixed cardiac output; in a patient with isolated AS, systolic BP never goes above 150 mm of Hg.).
4. Paradoxical splitting of S_2 — the splitting happens to occur only during expiration.
5. Presence of S_4.
6. Absence of systolic thrill often tells against a severe stenosis.
7. Harsh, loud and long murmur with late systolic peaking.

***Splitting of S_2* ?**

It is of three types —

1. Physiological—When the splitting is present only during inspiration, it is physiological splitting. . Here A_2 occurs earlier than P_2.
2. Reversed (paradoxical)—Splitting occurs only during expiration.
3. Pathological—Splitting of S_2 is audible both in inspiration and expiration.

Causes of wide and fixed (no change with respiration) splitting of S_2 :

1. Atrial septal defect (hallmark of ASD),
2. CCF (severe right heart failure),
3. Massive pulmonary thromboembolism,
4. Total anomalous pulmonary venous connection (TAPVC),
5. Right ventricular pacing.

Causes of wide but variable splitting of S_2 :

1. RBBB (right bundle branch block).
2. Pulmonary stenosis.
3. Left ventricular pacing.
4. Ventricular septal defect (VSD).

Reversed (paradoxical) splitting of S_2 :

1. Severe AS.
2. LBBB (left bundle branch block).
3. Systemic hypertension.
4. Severe left ventricular dysfunction.

Single S_2 :

1. Severe AS (with absent A_2), aortic atresia (absence of aortic valve).
2. Severe PS (with absent P_2), pulmonary atresia (absence of pulmonary valve).
3. Fallot's tetralogy.

Causes of loud S_2 :

(A) Loud P_2 — Pulmonary hypertension, pulmonary artery dilatation.

(B) Loud — Systemic hypertension, dilated aorta, aneurysm of aorta, hyperkinetic circulatory states.

t Palpable S_2 (either P_2 or A_2) is known as **diastolic shock** or **diastolic knock.**

** Soft P_2, and A_2 occur respectively due to PS, and AS.

*** Loud (both) P_2 and A_2 may be found in patient with thin chest wall, and combined pulmonary hypertension plus systemic hypertension.

**** N_{orma}uy the S_2 is short and high-pitched (dup in 'lubb-dup'), and is best audible in the pulmonary (P_2) and aortic area (A_2). S_2 indicates the beginning of ventricular diastole and is produced due to closure of aortic (A_2) and pulmonary (P_2) valves. In health, there is a gap of 0.03 second between A_2 and P_2. Normal physiological splitting of S_2 is audible in children and young adults in inspiration.

Murmur of bicuspid aortic valve :

Usually the AS-murmur is heard but sometimes, Al-murmur Is also present. The Al-murmur is haemodynamieally insignificant and in bicuspid aortic valve, features of AS is always greater than AI.

Who invented the stethoscope ?

The French physician R.T.H. Laennec (1816).

Bedside diagnosis of 'acute rheumatic carditis' :

This is a **'PANCARDITIS'** involving endocardium, myocardium and pericardium to varying degree. The features are :

(A) Pericarditis :

1. Pericardial rub.
2. Pericardial effusion (rare and always mild).

(B) Myocarditis :

1. Relative tachycardia (pulse rate rises by more than 10/minute with per degree (°F) rise of temperature).
2. Tic-tac' quality of heart sounds (due to tachycardia and mimic foetal heart sounds).
3. S, — Muffled or soft (reflected as prolonged PR interval in ECG).
4. S_3 gallop rhythm due to heart failure.
5. Congestive heart failure.
6. Heart size — Enlarged (apex goes down and outwards due to cardiac dilatation). It is a very important clinical sign.
7. Conduction defects — Dropped beat in pulse due to heart block.
8. Arrhythmia — May occur.

(C) Endocarditis :

1. The appearance of —
   a) Soft systolic murmur due to mitral incompetence.
   b) Soft early diastolic murmur in the aortic area due to acute involvement of the aortic valve (murmur of AI).
   c) Carey-Coombs murmur — Due to mitral valvulitis (temporarily producing MS as a result of oedema of the mitral valve cusps),

or, 2. Change in the character of existing organic heart murmurs.

* Rheumatic subcutaneous nodules are almost always associated with active carditis.

** An accelerated heart beat during rest or sleep make the clinician suspicious of carditis.

Appearance of murmur in rheumatic valvulitis (carditis) from acute rheumatic fever :

In order of sequence :

1. MI murmur.
2. AI murmur.
3. Carey-Coombs murmur.

Diagnosis of acute rheumatic fever :

It is done by revised **JONES CRITERIA,** updated in 1992 (after Dr. T. Duckett Jones) —

(A) MAJOR MANIFESTATIONS :

1. Carditis
2. Polyarthritis
3. Chorea
4. Erythema marginatum
5. Subcutaneous nodules

(B) MINOR MANIFESTATIONS :

1. Fever
2. Arthralgia
3. Previous rheumatic fever
4. High ESR or positive C-reactive protein (CRP)
5. Leucocytosis
6. Increased PR interval on ECG

The presence of,

a) Two or more major, or

b) One major + 2 or more minor criteria strongly suggest rheumatic fever

WITH

One supporting evidence of preceding streptococcal infection such as :

a) H/O recent scarlet fever,

b) Positive throat culture for group A streptococcus,

c) Increased ASO (antistreptolysin O) titre or titre of other streptococcal antibodies.

* Do not forget to take the H/O sore throat, 2-4 weeks prior to the onset of acute rheumatic fever. Evidence of recent streptococcal infection is particularly valuable if only one major manifestation is present.

** Acute rheumatic fever develops as a delayed sequel to pharyngeal infection caused by group A beta-haemolytic streptococci (type 5 most commonly causes rheumatic fever; other rheumatogenic serotypes are 1, 3, 6, 14, 18, 19 and 24). Streptococcal skin infection never produces rheumatic fever.

*** The WHO (2002-2003) criteria for the diagnosis of rheumatic fever is a minor variation of Jones criteria (1992).

Investigations done in acute rheumatic fever :

(A) Blood ;

1. Anaemia, polymorphonuclear leucocytosis, raised ESR.
2. Raised ASO titre (> 200 units in adult and > 300 units in children).
3. Raised C-reactive protein and other acute phase reactants (e.g., serum complements).
4. Other streptococcal antibodies — Antihyaluronidase (AH), anti-streptokinase (ASK), anti-streptozyme (ASTZ), and anti-DNase B (antideoxyribonucleotidase B). Now-a-days, anti-DNase B and ASO titre are preferred for diagnosis.
5. Positive throat swabs culture for Group A streptococci in 25-40% cases.

(B) ECG (evidence of carditis) :

1. Sinus tachycardia.
2. Prolonged PR interval.
3. Features of pericarditis.
4. T wave inversion.
5. Reduction in QRS voltage.

(C) Chest X-ray :
Cardiomegaly, pulmonary congestion or evidences of heart failure.

(D) Echocardiography : Cardiac dilatation with valve abnormalities (in case of carditis).

Latent period from rheumatic fever to organic valvular heart disease :

In temperate climates, this gap is usually 15 years. In India, organic disease (mainly MS) develops much earlier (latent period may be as short as 1-2 years), and frequently causes serious symptoms before the age of 20 years. This happens to be due to repeated attacks of severe carditis in India.

***Characteristics of rheumatic arthritis* :**

1. Most common in children (5 to 15 years); commonest 'major' manifestation (75%).
2. Big joints are involved (knee, most commonly); but no joint is immune to the inflammatory process. Small joints of hand and feet may be affected as seen in rheumatoid arthritis. Joint involvement is often symmetrical. Involved joints are swollen, painful and tender.
3. Typically it is fleeting or migratory in nature (as the inflammation of one joint is subsided, others tend to become affected); the affection of joints in rheumatoid arthritis is 'additive in nature.
4. Spine, sternoclavicular and temporo-mandibular joints are rarely affected (affected more in rheumatoid arthritis).
5. Recovery is complete.
6. Usually there is no residual deformity (rarely, recurrent attacks of arthritis may lead to minor deformities of the hand at MCP joints — Jaccoud's arthritis). Deformity is very common in rheumatoid arthritis.
7. Muscle spasm and muscular wasting are not common (common in rheumatoid arthritis).
8. No radiological abnormality (rheumatoid arthritis have characteristic X-ray features).

* **Arthritis** means inflammation of the joint, i.e., pain plus swelling of the joint. **Arthralgia** means subjective presence of pain only (no inflammation, no swelling). *Acute rheumatic fever bites the heart and licks the joint in children, whereas it bites the joints and licks the heart in adults.*

Possible causes of fleeting or migratory arthritis :

1. Rheumatic arthritis (commonest).
2. SLE.
3. Drug reaction/serum sickness.
4. Arthritis following gonococcal or meningococcal bacteraemia.
5. Viral arthritis (Lyme arthritis, Chikungunya).
6. Arthritis associated with inflammatory bowel disease or Whipple's disease.
7. 'Seroconversion' phase in AIDS.
8. Septicaemia.
9. Following intestinal by-pass surgery.
10. Sarcoidosis.

Active rheumatic carditis with low ESR—reason behind :

The patient is in heart failure.

Causes of very low ESR :

1. Polycythemia (COPD, Fallot's tetralogy).
2. Congestive cardiac failure.
3. Congenital fibrinogen deficiency.
4. Sickle cell anaemia.

Causes of high ESR :

1. All acute infections (e.g., tuberculosis).
2. Severe anaemia.
3. Pregnancy.
4. Old age.
5. Collagen vascular diseases (SLE).
6. Malignancy.
7. Multiple myeloma (stormy ESR).
8. Vasculitis.
9. Acute rheumatic carditis.
10. Temporal arteritis.

* Very high ESR is seen in multiple myeloma, temporal arteritis and advanced tuberculosis.

** Normal ESR in men is 0-15 mm/hr and in women it is 0-20 mm/hr. ESR reflects changes in plasma proteins. Some clinicians use ESR as 'sickness index.'

What are acute phase reactors ?

These are a class of liver-produced proteins, which rise in response to cytokines synthesized in tissue injury e.g., in inflammation. Phase reactors are fibrinogen, haptoglobulin, ferritin, a,-antitrypsin, serum amyloid-A, mannose-binding protein, C_3 complement, ceruloplasmin, C-reactive protein and orosomucoid. In clinical practice, estimation of C-reactive protein is commonly done. They are responsible for rise in the ESR. Phase reactors serve as markers for 'disease activity'.

Differential diagnosis (D/D) of your case :

It is a patient of valvular AS (due to the presence of ejection click and soft A_2). The D/D are :

1. Subvalvular aortic stenosis—Characterised by,
   a) Early diastolic murmur of AI (common),
   b) No ejection click,
   c) In IHSS variety - double kicking apex beat and pulsus bisferiens may be present,
   d) The murmur does not radiate to carotids,
   e) No post stenotic dilatation,
   f) Heart size tends to be larger.
2. Supravalvular aortic stenosis—Characterised by,
   a) Systolic BP, of right arm > left arm,
   b) No ejection click,
   c) Thrill transmitted to carotids (thrill is more conspicuous than other types),
   d) May be associated with mental retardation, Elfin facies, squint, infantile hypercalcaemia,
   e) A_2 - Normal / accentuated,
   f) No post stenotic dilatation.

* Also consider *other causes of systolic murmur* in the aortic area (page 30 and 31).

Complications *of* AS :

1. Acute LVF.
2. Right-sided heart failure (CCF).

3. Infective endocarditis.
4. Tachy-and bradyarrhythmias.
5. Precipitation of angina pectoris or syncope.
6. Sudden death due to complete heart block or ventricular fibrillation.

* Bleeding per rectum resulting from angiodysplasia of colon may be associated with AS.

How do you like to investigate a case of AS ?

1. X-ray chest (PA view) :
   a) Normal sized heart due to concentric hypertrophy of left ventricle or LVH.
   b) Post stenotic dilatation of ascending aorta.
   c) Calcification of aortic valve (in left anterior oblique view or on fluoroscopy).
2. Fluoroscopy : Aortic valve calcification is seen.
3. ECG :
   a) LVH.
   b) LAH.
   c) First degree heart block.
   d) LBBB, complete heart block (when calcification extends into conducting system).
4. Blood for (to detect active rheumatic carditis) :
   a) TC and DC b) ESR c) ASO titre
5. Echocardiography shows calcified aortic valve, LVH; doppler estimate of gradient etc.
6. Cardiac catheterisation : to identify associated coronary artery disease.
7. Coronary angiogram : To rule out IHD in patients of AS with angina pectoris.

How will you like to treat this case ?

By, 1. Medical management — as in MS. Treatment of angina, atrial fibrillation and LVH should be done carefully. |3-blockers should preferably be avoided.

2. Asymptomatic AS — Review regularly for development of angina, syncope or heart failure.
3. In childhood or adolescence — valvotomy; adults and elderly—valvuloplasty.
4. For calcific AS — Aortic valve replacement (prosthesis).

Describe the classical pain of angina pectoris :

Characteristics :

1. Commonly retrosternal; sometimes, felt in left side of the midline.
2. Constricting, pressing or squeezing in nature; along with a sense of chocking. Often described as 'like a band around the chest'.
3. Radiation — Both upper extremities (left > right), shoulders, lower jaw, neck, back, rarely to the upper abdomen. Radiation to the ulnar aspect of the left arm is characteristic.
4. Exertional commonly. Often increases with emotion, exposure to cold or walking uphill after a heavy meal.
5. Duration is usullally 2-5 minutes; seldom lasts more than 20 minutes.
6. Relieved by rest, or after taking sublingual nitrates or nitroglycerin.
7. Usually associated with palpitation and diaphoresis.

N.B. ; A chest pain present in the left inframammary region is usally not due to IHD. The pain of myocardial infarction is more severe, lasts longer, persists at rest, and very often associated with nausea, vomiting, diaphoresis and pallor. If the anginal pain occurs at rest ('rest pain') think of acute myocardial infarction, unstable angina, vasospastic angina (Prinzmetal's angina) and emotion-induced angina.

The diagnosis of ischaemic chest pain depends on history and different investigations (ECG, stress testing, thallium stress test, Holter monitoring, echocardiography and Doppler study, and the most specific coronary angiography).

Syncope, fainting or black-out — definition and aetiology :

Definition - Syncope is sudden and transient loss of consciousness with inability to stand upright as a result of impairment of cerebral blood flow (i.e., postural collapse).

Aetiology -

1. Simple syncope, i.e., due to vasovagal phenomenon (in an unpleasant sight, micturition syncope, cough syncope, carotid sinus syncope or acute severe pain due to any cause).
2. Cardiovascular (complete heart block, AS, IHSS, sick sinus syndrome, hypersensitive carotid sinus syncope, prolonged QT syndromes, acute pulmonary thromboembolism, Eisenmenger's syndrome, other brady- or tachyarrhythmias, left atrial ball valve thrombus or myxoma).
3. Metabolic or drug-induced (hypoglycaemia, hypocalcaemia, alcohol intoxication; methyl dopa, prazocin, vasodilators or diuretics-induced postural hypotension).
4. Postural hypotension (in patients receiving antihypertensives and vasodilator drugs).
5. Nervous system disorders (vertebro-basilar insufficiency, diabetic neuropathy, G.B.syndrome, familial dysautonomia, glossopharyngeal neuralgia).
6. Hyperventilation and hysterical fainting, breath-holding (children), unknown causes.

* Exertional syncope is classically seen in aortic stenosis.

D/D of syncope with episodic weakness/fainting :

Hyperventilation syndrome, hypoglycaemia, acute blood loss (hypovolaemia), vertigo, transient ischaemic attack, severe anaemia etc.

Describe the 'black-out' in this patient :

1. Present for last 2 months,
2. Persists for few seconds,
3. Almost always exertional,
4. No H/O trauma.

***How to take the H/O dyspnoea in a patient* ?**

Following points should be noted carefully :

1. Paroxysmal or exertional ? How much exertion is needed?
2. Any H/O PND ? or orthopnoea?
3. Seasonal variation present or not?
4. Associated with wheeze or not?
5. Grading of dyspnoea (NYHA classification).
6. Whether associated with cough or pain chest (pneumothorax) or shock (myocardial infarction), fever (consolidation), angina (AMI).
7. Time of appearance : early night (cardiac asthma), early morning (bronchial asthma).
8. Progressive or not?
9. How releived? by drugs/rest/change of smoky environment/squatting / change of posture or by expectoration of tenacious sputum.

Enumerate the different* causes *of dyspnoea :

The major causes of dyspnoea are due to cardio-respiratory abnormalities ;

1. Respiratory : Bronchial asthma, COPD, airways obstruction, lobar and bronchopneumonia, spontaneous pneumothorax, pleural effusion, pulmonary thromboembolism, pulmonary oedema, bronchogenic carcinoma, fibrosing alveolitis, pulmonary infections (pneumonias).
2. Cardiovascular : Acute left ventricular failure (e.g., AMI, valvular heart disease), SVC syndrome, cyanotic congenital heart diseases, pericardial effusion and cardiac tamponade, constrictive pericarditis, rapid cardiac arrhythmias, IHD, cardiomyopathy.
3. Metabolic : Diabetic ketoacidosis, uraemia, high fever.
4. Neurological ; Depression of respiratory centre from motor neurone disease, GB syndrome, bulbar poliomyelitis, syringobulbia; raised intracranial tension; diaphragmatic or respiratory muscle paralysis, myasthenia gravis.
5. Mechanical : Huge ascites.

6. Psychogenic : Hysterical hyperventilation, anxiety neurosis.
7. Physiological : High altitude, exercise, severe anaemia.

Differentiation between dyspnoea of pulmonary and cardiac origin :

Dyspnoea due to pulmonary aetiology :	**Dyspnoea due to cardiac aetiology :**
1 Cough with expectoration precedes dyspnoea	1. PND and orthopnoea
2. Wheeze or stridor	2. Dyspnoea precedes cough with expectoration
3. Pleuritic chest pain	3. Associated angina, syncope, palpitation; hypertension
4. Pyrexia	4. Rapid progression of symptoms
5. Seasonal variation	5. Little or no cyanosis (+)
6. Cyanosis (++ or +++)	6. Erect posture or squatting may relieve
7. Progression over many years	7. Oedema is an important sign
8. Response to oxygen, bronchodilators	8. Response to diuretics and digoxin
9. Absence of obvious cardiac disease	' 9. Physical signs of cardiac disease

Management of acute rheumatic fever in a nutshell :

1. Bed rest - specially for fever, arthritis, arthralgia, carditis and heart failure.
2. High calorie, salt restricted diet.
3. Chorea - reassurance, sedatives like clonazepam or chlorpromazine, and in severe cases halo-peridol, sodium valproate or carbamazepine is used.
4. Symptomatic treatment :
   a) Arthritis, arthralgia, fever—aspirin in a dose of 80-100 mg/kg/day in children and 4-8 g/day in adults in 4-6 devided doses is started, and continued for 2 weeks. If symptoms subside, a lower dose of 60-70 mg/kg/day (in children) is continued for a further 2-4 weeks.
   b) Patient without carditis — aspirin is preferred.
   c) Patient with carditis but without heart failure — aspirin ± glucocorticoid (role of corticosteroids are doubtful in carditis but majority of cardiologists believe that they help in rapid resolution of heart failure). Prednisolone 1-2 mg/kg/day (maximum of 80 mg) is given orally for a period of 2 weeks and then tapered off over next 2 weeks.
   d) patient with carditis and heart failure—majority opine that corticosteroid is mandatory over and above aspirin.
   e) Antibiotics — single injection of 1.2 million units of benzathine penicillin, I.M is given to eradicate group A streptococcal infection, if present. Oral penicillin (penicillin V) 500 mg twice daily, orally for 10 days or erythromycin 40 mg/kg/day, orally may be used for 10 days (in patient allergic to penicillin).
5. Secondary prevention of acute rheumatic fever :

   The mainstay of controlling rheumatic heart disease is secondary prevention. The dose of inj. benzathine penicillin is 1.2 million units, I.M given at 4 weekly interval (in endemic areas and high-risk cases, the interval is 2-3 weekly); dose of penicillin in children is 0.6 million units. Instead oral penicillin V may be used 250 mg twice daily or oral erythromycin 250 mg twice daily (in penicillin allergy). Controversies exist regarding duration of therapy and the guideline is—

   a) Rheumatic fever without proven carditis - 5 years after the last attack or until the age of 18 years, whichever is longer.
   b) Rheumatic fever with carditis but having minimal residual valve damage—10 years after the last attack or 25 years of age, whichever is longer.
   c) Rheumatic fever with carditis along with residual heart disease—10 years after the last episode or until the age of 40, whichever is longer. Few clinicians prefer to give penicillin life long in this situation.
   d) If valvular surgery is done—Penicillin prophylaxis is continued life long.

* Prophylaxis against infective endocarditis is also needed in valve damage.

Case 4

AORTIC INCOMPETENCE

What is your diagnosis ?

This is a case of valvular aortic incompetence (regurgitation) of rheumatic origin without congestive cardiac failure and the patient is in sinus rhythm at present.

What is your case ?

Try to build up the summary. Aortic incompetence (AI) remains asymptomatic for years or decades. Main symptms of aortic incompetence are,

1. Palpitation,
2. Awareness of the heart beat, specially on lying; pulsatile or throbbing sensation.
3. Chest pain (angina pectoris, or due to pounding of heart against chest wall),
4. Dyspnoea (exertional),
5. Features of LVF or CCF (orthopnoea, PND, oedema etc).

Peripheral signs of AI (chronic) :

Start from hands and go to the neck, head and then downwards to the legs systematically in search of peripheral signs. **Peripheral signs are produced as a result of 'wide pulse pressure'.** They are :

1. Visible capillary pulsation (Quincke's sign) at nail-beds or lip i.e., blanching and quick refill—
   a) When light pressure is applied to the tip of fingers or nails, there is alternate flushing and pallor of the nail-bed, or
   b) When a glass slide is pressed on the everted lower lip, it produces alternate redness and blanching.
2. Prominent digital artery pulsation — Hold the flexed fingers of the patient with your fingers in flexed position to feel the pulsation.
3. High volume collapsing pulse or Corrigan's pulse (water-hammer pulse).
4. Locomotor brachialis — Look at the medial side of lower arm (with semiflexed elbow) for 'tortuous and highly pulsatile' brachial artery. Tortuosity is the most important component of locomotor brachialis and thus, it is commonly found in atherosclerosis (old age).
5. Blood pressure — Wide pulse pressure with low diastolic pressure (even Korotkoff sounds may continue upto 0 mm of Hg.). Pulse pressure is usually > 60 mm of Hg.
6. Corrigan's sign — Dancing carotids in neck.
7. de Musset's sign (named after a French poet) — To and fro head-nodding synchronous with carotid pulsation (systolic extension of neck).
8. Visible pulsation in the suprasternal (jugular) notch.
9. 'Pistol shot' sound or Traube's sign—Booming sound produced after pressing the stethoscope over femoral artery.
10. Systolic murmur on compression of the femoral artery proximally.
11. Duroziez's murmur — Diastolic murmur on compression of the femoral artery distally.
12. Hill's sign — Increase in the femoral artery systolic BP > 20 mm of Hg above the brachial artery systolic BP. In health, the systolic difference between two extremities remains within 20 mm of Hg. In severe AI, the increase is > 60 mm of Hg. It is very important and specific sign of AI.

* Pulsations in uvula, liver and enlarged spleen are respectively known as Muller's sign, Rosenbach's sign and Gerhardt's sign. Changes in pupil size with each cardiac systole is known as Landolfi's sign. Alternate flushing and blanching of forehead is known as Lighthouse sign, and pulsation of retinal artery is Becker's sign. Duroziez' sign is the combination of No. 10) and 11).

Why do you say aortic incompetence ?

Because there is presence of :

(A) **Symptoms (from the history)** — Palpitation, throbbing sensation all over the body, chest pain, dyspnoea for last 2 years. Past H/O reheumatic fever is also present.

(B) Signs —

a) Pulse — 80 / min, regular, high volume, neither there is any inequality nor any delay, arterial wall is not thickened, all the peripheral pulses are 'nicely' palpable and it is water-hammer in type.

b) BP — Say, 145/40 mm of Hg. (in supine position), i.e., high systolic and low diastolic BP. So, there is wide pulse pressure.

c) **All the peripheral signs are present** (described above).

d) Apex — Diffuse, goes down and outwards (LVH) with hyperdynamic character.

e) Palpation of the aortic area — No thrill, no palpable heart sound, no pulsation [though very rare, one may get a diastolic thrill (5%) in aortic area or in lower left sternal border].

f) Ausculation of the aortic area—

S! — Audible

S_2 (A,) — Muffled

Murmur— High-pitched, soft blowing, early diastolic decrescendo murmur of grade III which is best audible in sitting and leaning forward position, in full expiration and with the diaphragm of stethoscope. The murmur is radiated towards the apex and is best heard at neoaortic area (left 3rd ICS).

* Occasionally, the murmur may radiate upto apex and left axilla, and is known as ***Cole-Cecil murmur.*** Sometimes, S_3 may be heard.

g) Other areas of heart and lungs— Within normal limit.

* Add features of pulmonary hypertension, if present. Always examine the neck for thyroid enlargement in a patient with wide pulse pressure.

[h) Examination of respiratory system, G. I. tract and nervous system revealed no abnormality],

* Patients of AI remains asymptomatic for years after years, but once decompensated, they start deteriorating rapidly.

Different types of murmur found in AI:

1. Classical early diastolic, soft blowing, high-pitched murmur in the aortic or neoaortic area.
2. Ejection systolic murmur of functional AS in the aortic or neoaortic area.
3. Austin Flint murmur — Mid-diastolic rumbling murmur (flow murmur) in the mitral area.

How to assess the 'severity' of AI ?

Bedside assessment of severe AI is done by,

1. Presence of marked peripheral signs.
2. Hill's sign of more than 60 mm of Hg (difference in systolic BP between lower and upper extremity 20-40 mm of Hg—mild AI, 40-60 mm of Hg—moderate AI, and > 60 mm of Hg— severe AI). Hill's sign is due to the phenomenon of recruitment of impulses.
3. Long duration of early diastolic murmur.
4. Presence of Austin Flint murmur.
5. Pulsus bisferiens (read the section on 'Water-hammer pulse').

Aetiology of AI:

1. **Rheumatic** (80%).
2. Traumatic.
3. Infective endocarditis.
4. Bicuspid aortic valve.
5. Atherosclerotic.
6. Dissection of aorta.
7. Syphilitic (H/O exposure should be taken).
8. Marfan's syndrome (look for tall stature).
9. Ankylosing spondylitis.
10. Rheumatoid arthritis.
11. Reiter's syndrome.
12. Dissecting aneurysm of aorta.

* First 4 causes are due to 'valve involvement' and the others produce AI by 'ring dilatation' due to aortic root disease.

Causes of 'acute AI' :

Peripheral signs are absent in acutely developing AI. They develop from :

1. SBE.
2. Trauma to the chest.
3. Dissection of aorta.
4. Acute rheumatic fever.
5. Prosthetic valve dysfunction.

AI with normal or low pulse pressure :

1. Acutely developing AI (see above).

2. Associated with AS or tight MS.
3. AI with CCF.
4. AI associated with systemic hypertension.

Is there any systolic murmur present in the aortic area ?

No; occasionally a harsh systolic murmur of 'functional' AS of grade II to V may be heard in the aortic area. This murmur may be transmitted towards carotids. This is caused by increased flow across the aortic valve and does not necessarily indicate an organic AS (for the difference between organic and functional AS, read the section on Aortic stenosis and aortic incompetence').

Clinical features of 'acute AI' :

1. Acutely ill and symptomatic (breathlessness, chest pain) patient.
2. 100% patients have acute left heart failure.
3. Peripheral signs are absent (normal or low pulse pressure).
4. No cardiomegaly.
5. Diastolic thrill is present in majority of patients.
6. Sj — Soft to absent.
7. Short, soft, early diastolic murmur.

Features of rheumatic AI:

1. Age — Young age group.
2. H/O rheumatic fever present in majority of patients.
3. Involvement of other valves—May be present.
4. Diastolic thrill—Usually absent.
5. A_2 — May be diminished (soft) or absent.
6. Murmur—Best audible in left 3rd ICS (neoaortic area), blowing in character.
7. Peripheral signs — Present.

Features of syphilitic AI:

1. Age — Older age group (> 40 years).
2. H/O exposure to syphilis—Present.
3. Usually isolated lesion. Anginal pain is more common.
4. Diastolic thrill—May be present (commoner than rheumatic).
5. Right parasternal heave—Very often present.
6. A, — usually loud (tambour quality).
7. Murmur — Best audible along right sternal border (right 3rd ICS); ringing, cooing or musical in nature.
8. Peripheral signs—More marked than rheumatic AI.
9. Austin Flint murmur — May be present.

* If the early diastolic murmur of AI is best audible along right sternal border, it suggest syphilis, Marfan's syndrome or ankylosing spondylitis, and is due to dilatation of ascending aorta.

** In atherosclerotic AI, the A_2 is ringing in quality.

Causes of pulsation at different areas :

(A) CAROTID PULSATION :

1. Exertion, emotion and excitement,
2. Aortic incompetence (Corrigan's sign),
3. Hyperkinetic circulatory states like severe anaemia, thyrotoxicosis, pyrexia, pregnancy etc,
4. Atherosclerosis,
5. Aortic aneurysm,
6. Kinked carotid artery (right > left).

(B) SUPRASTERNAL (JUGULAR) NOTCH PULSATION :

1. Hyperkinetic circulatory states like severe anaemia, thyrotoxicosis, pyrexia, pregnancy etc,
2. Aortic incompetence,
3. Coarctation of aorta,
4. Unfolding of the arch of aorta (old age; commonly in patient with systemic hypertension),

5. Aneurysm of the arch of aorta,
6. High arch of aorta (congenital).

(C) PULSATION OVER THE PULMONARY AREA :

1. Children (physiological),
2. Pulmonary hypertension (severe),
3. ASD
4. PDA.
5. VSD,
6. Idiopathic dilatation of pulmonary artery.

(D) LEFT PARASTERNAL PULSATION :

1. RVH,
2. LAH (rare).
3. ASD (left parasternal lift).

(E) RIGHT PARASTERNAL PULSATION :

1. Dextrocardia,
2. Dextroversion (due to extracardiac cause, i.e., cause in lung, pleura, thoracic cage),
3. Aneurysm of the ascending aorta,
4. Right atrial hypertrophy due to any cause.

* *(F) EPIGASTRIC PULSATION :*

1. Excitement specially in a thin person (physiological),
2. Right ventricular hypertrophy (RVH),
3. Transmission of aortic pulsation by any growth like gastric carcinoma (pulsation disappears after adopting knee-elbow position)—i.e., transmitted pulsation,
4. Aneurysm of the abdominal aorta (expansile pulsation),
5. Transmitted hepatic pulsation in tricuspid incompetence.

(G) PULSATION AT THE BACK :

1. Coarctation of aorta (Suzman's sign),
2. Pulmonary arteriovenous fistula.

(H) *JUXTA-APICAL* **:** Ventricular aneurysm.

(I) *APICAL* **:** nomally in health. LVH or RVH.

* The epigastric pulsation is felt with the tip of the index finger inserted upwards and obliquely under the xiphoid process, or it is often better seen after tangential application of light.

Meaning of a 'thrill' :

This is palpable low-frequency vibrations with the sensation like 'purring of a cat', and is always associated with heart murmur. It is synonymous with palpable murmur. A thrill is always described by its site and timing.

How to determine the timing of a thrill ?

Palpate the thrill with the whole flat of the right palm (mainly by the base of the fingers.) While palpating for a thrill, always put your left thumb over the right carotid artery at the level of the upper border of thyroid cartilage to confirm the timing. If the thrill is synchronous with carotid pulsation, it is systolic in timing and if it appears before carotid pulsation, it is diastolic thrill. Many clinicians adjust the timing of a thrill with the apex beat instead of carotid pulsation.

Always remember :

a) In mitral or apical area — Diastolic thrill is very common.
b) In all other areas (base of the heart and tricuspid area) — Systolic thrill is more common.
c) In pulmonary area — Thrill may be continuous or systolo-diastolic, e.g., PDA.

N.B. : It is seen that thrill is usually present in stenotic lesions and generally absent in regurgitant lesions of the heart. The presence of a thrill, most of the time, indicate that the murmur is organic.

* Sudden appearance of thrill usually indicates SBE or failure of prosthetic valve.

** Austin Flint and Carey-Coombs murmur do not have thrills.

Importance of joint involvement in CVS :

1. Acute rheumatic arthritis.
2. Rheumatoid arthritis. SLE, ankylosing spondylitis may be associated with AI or MI.
3. Arthralgia may be seen in valvular heart diseases complicated by SBE.

Why the murmur of AI is early diastolic ?

The leaking back of blood from the aorta to the left ventricle is greatest in early part of diastole for obvious reason (as pressure in the aorta is more than that of the left ventricle in early diastole). In the mid-diastole, no leak is possible as the pressure in the aorta and the left ventricle becomes equal.

Differential diagnosis (D/D) of your case ?

1. PDA, coronary arteriovenous fistula, ruptured sinus of Valsalva Considered for wide pulse pressure; they produce continuous murmur.
2. Graham Steell murmur (rare) — Considered for diastolic murmur; features of pulmonary hypertension are present without any peripheral sign of AI.

Complications of AI:

1. Acute LVF.
2. Infective endocarditis.
3. Congestive cardiac failure.
4- Arrhythmias.
5. Heart block.
6. Angina pectoris (specially nocturnal).

How do you like to investigate a case of AI ?

1. X-ray chest (PA view) :
   a) Cardiomegaly (LVH)—also known as Cor Bovinum.
   b) Aortic root dilatation (prominent aortic knuckle).
   c) Aortic valve calcification (raises the possibility of concomitant AS).
2. ECG :
   a) LVH.
   b) Conduction defects.
3. Blood for (to detect active rheumatic carditis) :
   a) TC and DC b) ESR c) ASO titre, and
   d) VDRL and Kahn test (for syphilis); ANF, rheumatoid factor, CRP to exclude connective tissue diseases.
4. Echocardiography (M-mode and 2-D)—to diagnose, assess severity and possible cause of lesion.
5. Cardiac catheterisation.
6. Doppler study—most sensitive for detecting mild AI.

How will you treat this case ?

1. Medical management - as in MS; underlying cause, e.g., infective endocarditis or syphilitic aortitis needs to be treated. Chronic AI with significant volume overload needs vasodilator therapy with hydralazine, nifedipine or ACE-inhibitors.
2. Surgical — aortic valve replacement (prosthesis); ideal time of operation is selected after haemodynamic or echocardiographic evidence of left ventricular dysfunction but before the development of significant symptoms.

N.B. : Diastolic thrill in the aortic area is rare in AI. If really a diastolic thrill is present, it is better to think of leutic orgin or ruptured sinus of Valsalva or AI developed from dissecting aneurysm.

Common causes of palpitation :

Palpitation means 'abnormal unpleasant awareness of the heart beat.

(A) Cardiac —

1 AI, MI, TI, MS.
2 ASD VSD, PDA.
3. Paroxysmal atrial tachycardia.
4- Atrial fibrillation.
5. Ventricular ectopics.
6. Brady arrhythmias.

(B) Non-cardiac —

1. Hyperkinetic circulatory states like severe anaemia, thyrotoxicosis, arteriovenous shunt, anxiety, pyrexia.
2. Drug-induced, e.g., sympathomimetics (e.g., salbutamol), vasodilators (e.g., nifedipine), atropine.
3. Non-organic diseases, e.g., excessive smoking, anxiety states, cardiac neurosis, hysteria.
4. Miscellaneous—Hypoglycaemia, pheochromocytoma, menopause.

Case 5

MITRAL STENOSIS AND MITRAL INCOMPETENCE

What is your diagnosis ?

This is a case of organic mitral incompetence and mitral stenosis of rheumatic origin with pulmonary hypertension but without any evidence of congestive cardiac failure or arrhythmia at present (start with the dominant lesion).

N.B. . Never use the term double mitral lesion or MS with MI (abbreviations) in the examination. A combined lesion is difficult to be diagnosed correctly by an undergraduate student. But if one is meticulous and to the point in the clinical examination, it is not very difficult to diagnose the lesion. In a patient with MS and MI, both may be organic or the MS may be functional, if present with gross MI. When both are organic lesions, it is the duty of a student to determine the predominant (haemodynamicallv significant) one.

Palpatory findings in the apical area in this patient :

1. Site of the apex beat is in left 6th ICS, 1/2" outside the left MCL (LVH due to MI).
2. Character—Hyperdynamic (due to MI).
3. Palpable S_t—Absent.
4. Thrill Systolic thrill, best felt in left lateral position with full expiration.
   Here, all the features point towards predominant MI.

   N.B. : Remember, diastolic thrill in MS is more common than systolic thrill in MI (in the mitral area).

If MS is the predominant lesion, the findings in the apical area would be :

1. Site—Left 5th ICS, 1/2" outside the left MCL (RVH).
2. Character—Tapping.
3. Palpable S_t—Present.
4. Thrill Diastolic thrill, best felt in left lateral position with full expiration.

Is pulmonary hypertension present here ?

Yes. In a combined lesion of MS and MI, pulmonary hypertension is usually present though it depends mainly on the duration of the disease.

How to determine the dominant lesion ?

FEATURES	MS>MI	MI>MS
(A) Symptoms :		
Haemoptysis, H/O PND, systemic embolisation, symptoms of CCF, pulmonary congestion, chest pain	+++	+
(B) Signs :		
1. Pulse–	Low volume, features of atrial fibrillation are more common	Within normal limit (not low volume); may be 'collapsing'
2. BP—	Low systolic BP	Within normal limit
3. Apex—	Already described	Already described
4. Left parasternal heave—	+++	+
5. S_1 —	Short, sharp and accentuated (snapping)	Soft or muffled
6. Opening snap—	**Usual and the lesion is organic**	OS is absent in a dominant MI
7. S_3 —	Absent	**+; Presence of S_3 signifies dominant and gross MI**

FEATURES	MS>MI	MI>MS
8. Diastolic murmur—	Classical murmur of MS	Short mid-diastolic flow murmur without presystolic accentuation (due to functional MS)
9. Systolic murmur—	Pansystolic blowing murmur of MI without radiation	Classical pansystolic murmur of MI with radiation
(C) Investigations :		
1. Chest X-ray (PA view)—	LAH + RVH	LVH + LAH
2. ECG—	See the section on 'MS' (LVH is not present)	See the section on 'MI' (LVH is usually present)
3. Echocardiography—	Final diagnosis with certainty (thick, immobile cusps with diminished rate of diastolic filling)	Final diagnosis with certainty (LA enlargement with hyperdynamic LV)

* MS>MI → commonly dyspnoea on exertion →orthopnoea →PND →haemoptysis; palpitation in the presence of AF.

** MI>MS →commonly palpitation →dyspnoea →orthopnoea →PND.

What are the evidences of MI present here ?

Read the differentiation carefully and give your answer accordingly.

Why this is MI murmur, not TI ?

Describe the classical MI murmur. It is best heard over the mitral area with typical radiation, and increases with expiration. The TI murmur is best heard in lower left parasternal area, localised and increases with inspiration ***(Carvallo's sign).***

Conditions associated with S_3 :

S., signifies diastolic overload of the ventricles. It occurs during the first rapid filling phase of cardiac cycle (in ventricular diastole). It is a ventricular distension sound and the clinical associations are :

1. Healthy young adults (< 40 years) and children, pregnancy, athletes.
2. Heart failure (LVF or RVF).
3. Chronic MI, TI, AI.
4. Hyperkinetic circulation like severe anaemia, thyrotoxicosis.
5. ASD. VSD or PDA; dilated cardiomyopathy.

Conditions associated with S_4 :

It signifies systolic overload of the ventricles. It occurs during the last rapid filling phase of cardiac cycle (in ventricular diastole) which also coincides with the atrial systole. Presence of S_4 is always abnormal. It is an atrial contraction sound and the clinical associations are :

1. Ischaemic heart disease, specially acute myocardial infarction.
2. Aortic stenosis.
3. Systemic hypertension.
4. Rarely, in normal individuals (above 60 years).
5. Hypertrophic cardiomyopathy.

How to auscultate for S_3 or S_4 ?

S_3 or S_4 is best heard at the ***apex*** with the ***bell*** of stethoscope placed lightly. Sometimes, they are best heard with the patient turned to ***left lateral*** position; often they are better felt than heard. They are low-pitched sounds.

Left-sided S_3 (LVF) is best audible at the apex during expiration while the right-sided S_3 (RVF) is best heard at the lower left sternal border during inspiration.

Can ***you accentuate gallop sounds*** ?

Elevate both lower limbs at 60° -> maintain the position for 30 seconds -> cardiac output T ->

accentuation of gallop sounds. In this way a latent S_3 can be made audible. Isometric handgrip also accentuate gallop.

What is dynamic auscultation ?

Circulatory dynamics can be altered by application of certain body manoeuvres (respiration, isometric handgrip, Valsalva manoeuvre, leg raising) and administering certain vasoactive substances (amyl nitrite, phenylephrine), and auscultation of these events in the CVS is known as dynamic auscultation.

Table 2 : Dynamic manoeuvres in differentiation of murmurs

Manoeuvres	Increased	Decreased
1. Isometric handgrip (T afterload)	AI, MI	HOCM, MVPS
2. Valsalva monoevure (i venous return)	HOCM, MVPS	All organic murmurs except HOCM and MVPS
3. Squatting (T venous return and Tperipheral resistance)	AS, AI, MI	HOCM, MVPS
4. Standing (1 venous return)	HOCM, MVPS	AS, MI
5. Both leg raising (T venous return)	All right-sided murmur	HOCM, MVPS
6. Inspiration (T venous return)	All right-sided murmur	Pulmonary ejection click
7. Expiration (T cardiac output of left heart)	All left-sided murmur	—
8. Amyl nitrite (J. arterial pressure and T cardiac output)	HOCM, AS, MS	AI, MI

HOCM (hypertrophic obstructive cardiomyopathy), MVPS (mitral valve prolapse syndrome)

How and where the 'bell' is used ?

During the use of the bell, it should be placed very lightly over the skin. More pressure will tighten the skin and smother the low-frequency sounds. It is made for listening low-pitched sounds like,

1. Murmur of MS and TS.
2. S_3 or S_4.
3. Foetal heart sounds.
4. Venous hum.

Cardinal points to diagnose dominant lesion (MS + MI) :

1. History.
2. Pulse.
3. Apex (LVH or RVH, hyperdynamic or tapping).
4. S, (loud or muffled).
5. S_3 (S_3 signifies significant MI).
6. Opening snap (always signifies dominant MS).
7. Mid-diastolic rumbling murmur with presystolic accentuation signifies predominant MS; only mid-diastolic murmur points towards a dominant MI.

Mitral diastolic murmur—organic or functional ?

Functional MS (from gross MI) will have the following features :

1. Pulse—Normal volume.
2. Diastolic thrill in mitral area—Absent; rather a systolic thrill may be present.
3. S_t—Not very loud.
4. Presystolic accentuation (of the murmur) is absent.
5. Opening snap—Absent; rather S_3 is heard due to significant MI.
6. Features of LVH.

D/D of opening snap :

1. Splitting of S_2, 2) S_3, and 3) Pericardial knock.

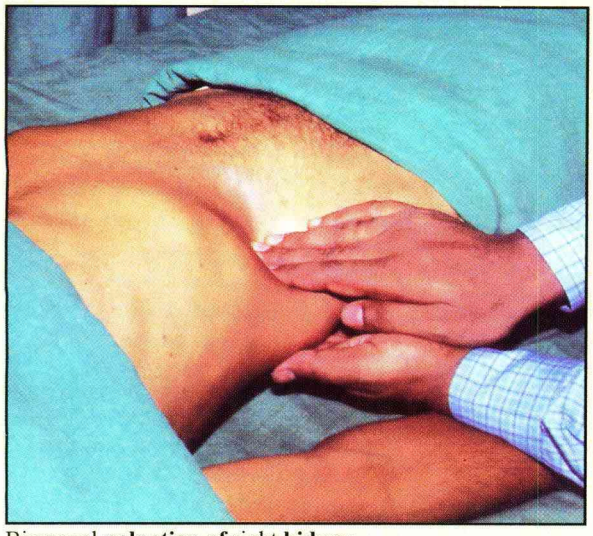

Bimanual **palpation of** right **kidney**

Elicitation of **fluid thrill**

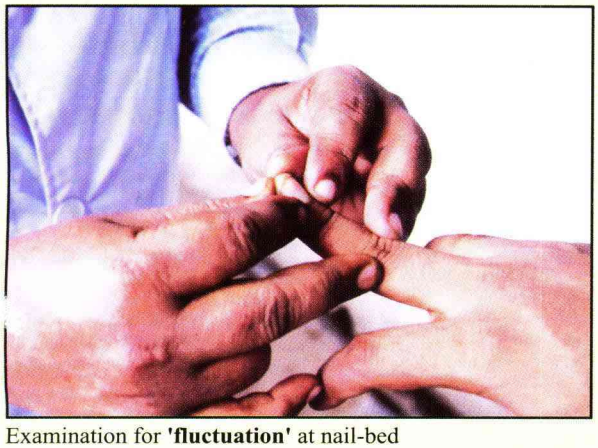

Examination for **'fluctuation'** at nail-bed

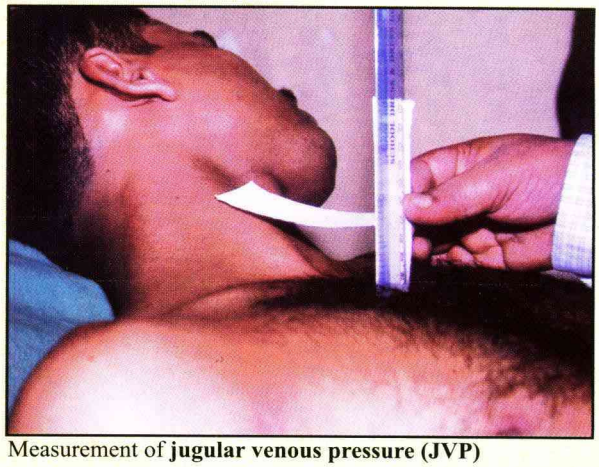

Measurement of **jugular venous pressure (JVP)**

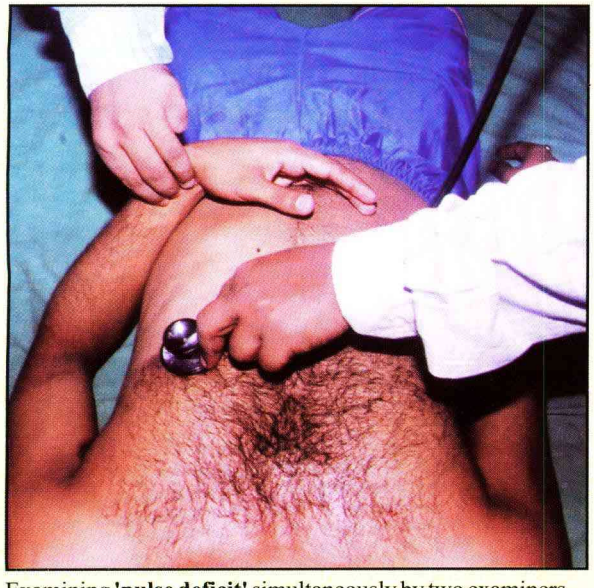

Examining **'pulse deficit'** simultaneously by two examiners

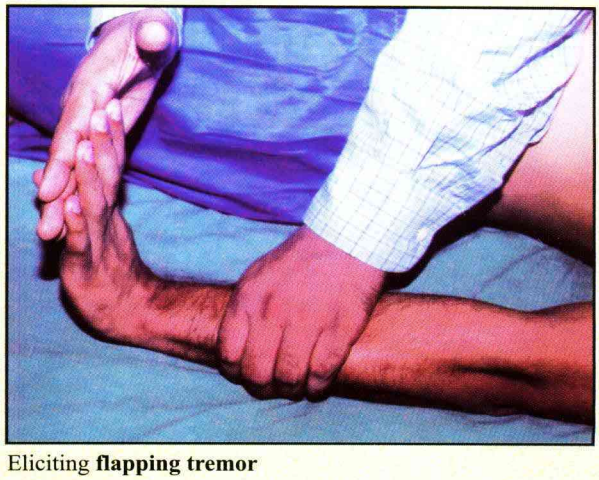

Eliciting **flapping tremor**

Testing for **neck rigidity**

Eliciting **Kernig's sign**

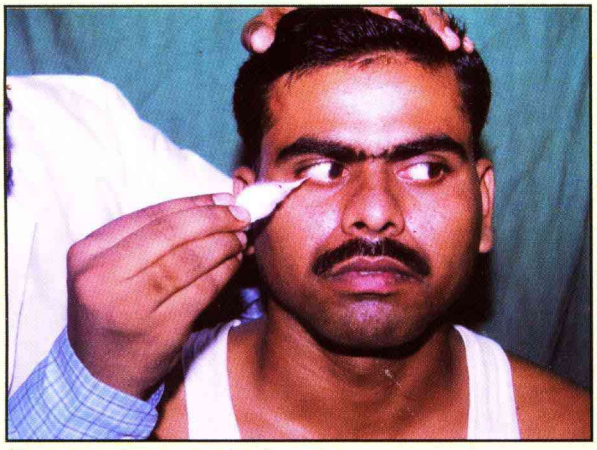

Demonstrating **corneal reflex**

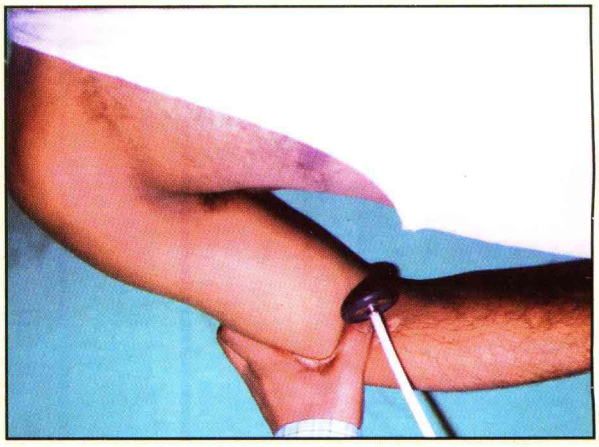

Testing **biceps jerk**

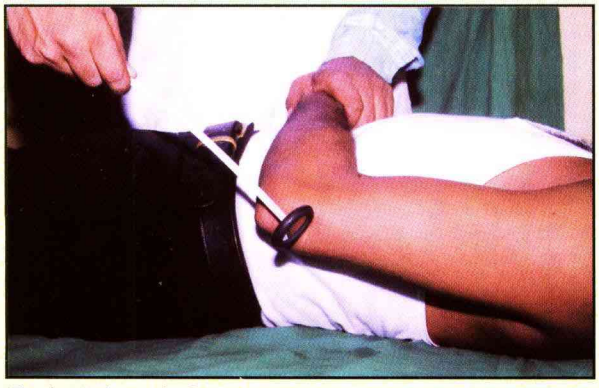

Testing **triceps jerk**

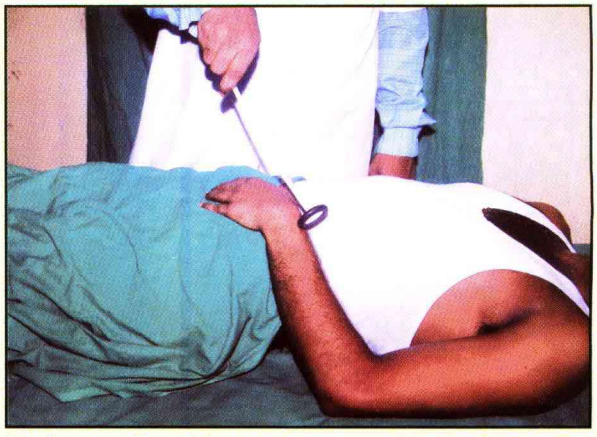

Testing **supinator jerk**

Table 3 : Differentiation between opening snap and S_3

	Features	Opening snap	S_3(LV)
1.	Where found —	MS	Heart failure or chronic MI
2.	Best audible—	At lower left parasternal region; with the diaphragm of stethoscope in standing position	At apex; with the bell of stethoscope in left lateral position
3.	Pitch—	High-pitched	Low-pitched
4.	Palpability—	Not palpable	May be palpable
5.	Timing—	0.04 to 0.12 seconds after A_2 (early part of diastole)	0.14 to 0.16 seconds after A_y (mid-.diastole)
6.	After treating heart failure—	OS becomes louder	S_3 vanishes

What is the aetiology of your case ?

Rheumatic; an organic MS with MI is virtually always of RHEUMATIC in origin.

How will you manage this case ?

1. Prophylaxis against rheumatic recurrence.
2. Mitral valve replacement (prosthesis).
3. Treatment of complications :
   a) Heart failure, b) SBE, c) Atrial fibrillation, d) Embolic manifestations.

Case 6

AORTIC STENOSIS AND AORTIC INCOMPETENCE

What is your diagnosis ?

This is a case of organic aortic incompetence and aortic stenosis of rheumatic origin without any evidence of congestive cardiac failure and the patient is in sinus rhythm at present (start with the dominant lesion).

N.B. : Do not use the term 'double aortic' lesion or AS with AI (abbreviations) in the examination. Often a functional systolic murmur is heard in a patient with severe AI. Thus, one has to determine whether the AS is organic or functional. Lastly, in a combined AS with AI, dominant lesion (haemodynamically significant) should be diagnosed. It is worthwhile to remember that combined AS with AI is usually of rheumatic in origin.

How to determine the dominant Isetion ?

	FEATURES	AS>AI	AI>AS
(A)	**Symptoms :**		
	1. Effort angina, dysponea on effort, effort syncope, black-out etc	+++	+ (chest pain, dyspnoea may occur)
	2. Palpitation, throbbing	+ (palpitation)	+++
(B)	**Signs :**		
	1. Pulse—	Low volume; pulsus bisferiens (tidal>percussion wave)	High volume collapsing pulse; pulsus bisferiens (percussion> tidal wave)
	2. BP—	Low systolic BP; pulse pressure is low	Wide pulse pressure due to high systolic and low diastolic BP

	FEATURES	AS>AI	AI>AS
3.	Peripheral signs of AI—	±	+++
4.	Apex—	Heaving, apex may be in normal position	Hyperdynamic, down and outwards (LVH)
5.	Thrill—	Always systolic; palpated on aortic area and on carotids	a) Rarely present; systolic thrill due to functional AS b) Very rarely diastolic thrill may be palpable along the left sternal border
6.	S_3-	Absent	May be present
7.	S-	May be present	Absent
8.	Ejection click—	Present in mild to moderate AS	Rare; sometimes present in severe AI
9.	Diastolic murmur—	Very short duration AI murmur	Classical mumur of AI
10.	Systolic murmur—	Classical murmur of AS	Functional midsystolic ejection murmur may be audible

(C) Investigations :

1.	Chest X-ray (PA view)—	Read the section on AS'	Read the section on AI'
2.	ECG—	Read the section on AS'	Read the section on AI'
3.	Echocardiography—	Final diagnosis with certainty	Final diagnosis with certainty

Cardinal points to diagnose dominant lesion (AS + AI) :

1. History — angina and syncope are seen more in AS. Palpitation and dyspnoea are common in AI.
2. Pulse.
3. BP.
4. Apex.
5. $S_{3,4}$ or S,.
6. Ejection click.
7. Peripheral signs of AI (best indicator of severity of AI lesion).

Aortic stenosis murmur—organic or Junctional ?

1. History—Patients with organic AS will give H/O angina and/or syncope.
2. Pulse— Low volume, often anacrotic in nature (in organic AS).
3. BP—Systolic decapitation of BP in organic lesion.
4. Apex—Heaving in organic lesion.
5. Systolic thrill in aortic area—Present in organic lesion (rarely, functional AS may give rise to systolic thrill).
6. Ejection click—Always in favour of valvular (organic) AS.

* In a functional AS, peripheral signs of AI will be very prominent like presence of water-hammer pulse, dancing carotids etc. Thus in a functional AS, pulse is of high volume.

Possible BP in patients where AS>AI and AI>AS :

If AS>AI — the approximate BP will be 90/60 mm of Hg and if AI>AS — the approximate BP will be 130/20 mm of Hg. So, measurement of BP should be done carefully in all CVS patients.

What is aortic sclerosis murmur ?

In aged persons suffering from atherosclerosis with or without hypertension, there is fibrosis, thickening and calcification of bases of the aortic valve cusps. These may give rise to harsh, ejection systolic murmur upto grade IV in some cases. Differentiate aortic sclerosis from aortic stenosis by,

a) Normal pulse volume,
b) Absence of thrill.
c) Normal A_2, and
d) Often by the features of atherosclerosis like thick peripheral arteries, kinked carotids, locomotor brachialis, suprasternal pulsation, xanthelasma (deposition of lipids) around the eyes. Occasionally, the calcification becomes excessive and thus, produces severe aortic valve obstruction. This is known as 'calcific aortic stenosis' (see aetiology of AS).

What is the possible aetiology of your case?

Rheumatic.

Sometimes, the bicuspid aortic valve (congenital) produces features of combined AS and AI though the AI lesion is insignificant (always AS>AI). Bicuspid aortic valve is the most common congenital malformation of the heart though it may go undetected in early life.

Signs of aortic arch aneurysm :

1. Swelling in the chest wall.
2. Pulsation in the upper part of anterior chest wall.
3. Suprasternal pulsation.
4. Difference between right and left radial pulses (radio-radial delay).
5. Left 2nd ICS is dull on percussion.
6. Ejection click.
7. Systolic murmur in the aortic area.
8. 'Tracheal tug'— It is the downward pull of trachea synchronous with each cardiac cycle. Stand in front of the erect (upright) patient. Raise the chin and apply upward pressure on the trachea with two fingers placed on the lower border of cricoid cartilage. A downward traction is felt on the trachea. This sign is also seen in COPD patients when the downward tracheal pull is felt on each inspiration. The other name of this manoeuvre is ***Olliver's sign.***

Differential diagnosis (D/D) of your case :

Actually, a patient with AS and AI having systolic and diastolic murmur in aortic area mimic a 'continuous murmur'. The common causes of **continuous murmur** (begins in systole and extends through second heart sound into part or whole of diastole) are :

1. Patent ductus arteriosus (PDA, Train in tunnel' murmur, machinery murmur, Gibson's murmur)—Commonly found in female patients with water-hammer pulse and continuous murmur with late systolic accentuation, best audible in left infraclavicular area and left 2nd ICS. Thrill may be systolic or systolo-diastolic.
2. Rupture of sinus of Valsalva—Dramatic onset of chest pain with continuous murmur along the left sternal border.
3. Coronary arteriovenous fistula—Along left sternal edge, superficial, harsh.
4. Pulmonary arteriovenous fistula— Along left 2nd ICS.
5. Aortopulmonary window— Along left 3rd ICS.
6. Rarely, in coarctation of aorta (better auscultated at the back).
7. Mammary souffle (in pregnancy) —Best heard over the mammary area, and 2nd to 4th ICS.
8. Venous hum at root of neck (Devil's murmur) — Actually it is a D/D of continuous murmur.
9. VSD with AI, AS with AI, and MS with MI mimic continuous murmur.
10. After Blalock-Taussig operation done in Fallot's tetralogy— In upper sternal area.

Continuous murmur with high pulse pressure :

1. PDA, 2. Rupture of sinus of Valsalva, and 3. Aortopulmonary window.

Clues to diagnose multivalvular lesions :

1. Mild or moderate AI is frequently missed. Carefully listen to the aortic and then the neoaortic area (Erb's point) in sitting posture of the patient, in full expiration and with the diaphragm of stethoscope, in the search of an early diastolic murmur. For confirmation, measure the BP (in all cases) to record the pulse pressure.
2. Short mid-diastolic murmur of MS is often missed. Thus, it is a dictum to listen the mitral area with the bell of stethoscope, in left lateral position and with full expiration. For corroboration, carefully auscultate for loudness of S .
3. Murmur of insignificant MS may be pronounced after little exercise, if the condition of the patient permits (e.g., in the absence of heart failure).
4. Carefully palpate the brachial and carotid arteries. Actually, the commonest cause of pulsus bisferiens is combined lesion of AS and AI. If you get pulsus bisferiens in your patient, you are sure about the presence of two valvular diseases (rarely, it is seen in isolated AI).

Causes of LVF :

1. Systemic hypertension.
2. IHD, i.e., acute myocardial infarction.
3. AI.
4. AS.
5. MI.
6. Cardiomyopathy.
7. Coarctation of aorta.
8. Myocarditis.
9. Severe anaemia.
10. VSD, PDA.

Causes of RVF (CCF) :

1. Secondary to left-sided heart failure (LVF/LAF).
2. COPD.
3. Pulmonary stenosis.
4. ASD, VSD or PDA.
5. Pulmonary hypertension due to any cause.
6. Pulmonary thromboembolism.
7. Cardiomyopathy.
8. Myocarditis.
9. Right ventricular infarction.

Causes of LAF :

1. Mitral stenosis.
2. Left atrial myxoma.
3. Ball valve thrombus in the left atrium.
4. Mitral atresia (rare).

Causes or RAF:

1. Tricuspid stenosis.
2. Secondary to RVF.
3. Right atrial myxoma (very rare).

*** Bernheim effect** (it is the RV pressure change resulting from LVH without developing pulmonary hypertension. Actually, interventricular septum hypertrophies from LVH and produces obstruction to right ventricular outflow and thus, manifests as prominent a-wave in the neck vein without developing RVH or RVF). Lungs are clear on auscultation.

** Commonest cause of RVF is LVF.

Causes of biventricular failure :

1. Hyperkinetic circulation, e.g., severe anaemia, thyrotoxicosis, arteriovenous shunts.
2. Myocarditis—Viral, rheumatic, diphtheritic etc.
3. Ischaemic heart disease.
4. Dilated cardiomyopathy.
5. Patients with systemic hypertension and pulmonary hypertension (commonly from COPD).
6. RVF following chronic left-sided heart failure.

Causes of sudden cardiac failure :

1. Acute myocardial infarction.
2. Malignant or accelerated hypertension.
3. Dissection of aorta.
4. Massive pulmonary thromboembolism.
5. Arrhythmias.
6. Circulatory overload (fluid infusion or blood transfusion, severe anaemia).
7. Myocarditis.
8. Subacute bacterial endocarditis.

Causes of high output failure :

1. Hyperthyroidism.
2. Severe anaemia.
3. Arteriovenous fistula.
4. Paget's disease.
5. Pregnancy
6. Chronic cor pulmonale.
7. Beriberi.

* In high output failure, cardiac output is usually higher than normal.

Accelerated and malignant hypertension :

(A) Accelerated hypertension—Significant recent increase in BP level associated with evidence of vascular damage on fundoscopic examination but **without papilloedema.**

(B) Malignant hypertension—Severe accelerated hypertension with diastolic BP > 130 mm of Hg. with haemorrhage, exudate and **papilloedema** found on fundoscopic examination, and often associated with one or more of the following :

a) Rapidly deteriorating renal function (oliguria).
b) Cardiac decompensation (acute LVF).
c) Central nervous system manifestations, e.g., hypertensive encephalopathy (severe headache, vomiting, convulsions, coma).

It is papilloedema, not the diastolic BP—which is important here.

Management of multivalvular heart diseases :

1. AS with AI is managed by aortic valve replacement (prothesis).
2. MS with AI—First the AI is dealt with and next the MS. If MS is operated before AI, there will be left ventricular overload (blood coming from LA and aorta both) and ultimately LVF occurs. Actually, both the operations are done simultaneously.
3. MS with AS — MS protects the heart from failure. First deal with AS and then MS.

Case 7

INFECTIVE ENDOCARDITIS

What is your diagnosis ?

This is a patient of rheumatic mitral incompetence complicated by subacute bacterial endocarditis (SBE) and without any heart failure or dysrrhythmia at present.

Reasons behind your diagnosis :

(A) Symptoms (from the history) —

Fever with chills present persistently with diaphoresis, arthralgia, lassitude, anorexia, pain in the loin etc; over and above dyspnoea, fatigue, chest discomfort and palpitation due to MI.

(B) Signs —

1. Anaemia — Severe with a peculiar pallor (cafe-au-lait pallor).
2. Temperature (oral) — Elevated (101°F); toxic look.
3. Clubbing — Present (may be painful).
4. Pulse — Tachycardia, regular in rhythm (describe all points).
5. Petechiae, Osier's node and splinter haemorrhage — Present.
6. Pansystolic murmur (due to pre-existent MI) with a musical quality — 'Seagull murmur'. There may be change in the pre-existent murmur or appearance of a new diastolic murmur.
7. Mild, tender splenomegaly (30-40%) with splenic rub.
8. Renal angle is tender.
9. Arthralgia or arthritis.

[10. Ophthalmoscopy — Roth spots in <5% cases (see page 53)].

Hands in SBE :

1. Clubbing (10%).
2. Pallor (due to anaemia).
3. Osier's node (5%)—Painful and tender papule about the size of pinhead to pea, and is seen in the *pulp offingers,* toes and palms (due to septic embolism or arteritis). The nodes usually last for 1-5 days.
4. Splinter haemorrhage (10%; also known as Horder's line)—Linear longitudinal haemorrhage under the nail (other causes of splinter haemorrhage are trauma, trichinosis, leukaemia, scurvy, psoriasis, rheumatoid arthritis, systemic vasculitis).
5. Janeway's spot — Large, non-tender maculopapular lesion *in palms* (and soles).
6. Temperature — Elevated.
7. Petechiae (40-50%) may be found in dorsum of hands.
8. Gangrene of the fingers due to embolism rarely.
9. Nail-fold thrombi (due to embolisation).
10. Painful finger tips; loss of pulses (embolic manifestation).

* 3, 4, 5, 7, Roth spots, nephritis and positive rheumatoid factor are immunological phenomenon.

** Features of septic embolisation : 3, 4, 5, 7-10, painful splenomegaly, CNS and renal manifestations.

*** Though initially thought of an exclusive manifestation of SBE, Roth spots are also non-specific sign in blood dyscrasias (e.g., acute leukaemias) and anaemia (e.g., aplastic anaemia).

D/D you like to consider in your patient:

The features like fever, cardiac murmur and embolic phenomenon may be present in,

1. Acute rheumatic fever,
2. Atrial myxoma (left),
3. Marantic endocarditis,
4. Systemic lupus erythematosus.

The clinical findings in different systems in SBE :

1. General—Pyrexia, malaise, anorexia, diaphoresis, weight loss.
2. CVS—Breathlessness, pain chest, palpitations, tachycardia, changing of pre-existent murmur or appearance of new murmur, CCF and conduction defects.
3. Kidneys—Haematuria, glomerulonephritis, loin pain due to embolic renal infarction, tender renal angle.
4. Lungs—Haemoptysis, chest pain, pleural rub (embolic infarction of lung).

5. Nervous system—Headache, meningitis, embolic stroke, convulsions, intracranial haemorrhage due to ruptured mycotic aneurysm, encephalopathy.
6. Blood vessels—Cold periphery due to loss of pulses as a result of embolisation.
7. Skin and mucous membrane—Petechiae, purpura, subungual haemorrhage.
8. Hands—Described above.
9. Eyes—Red eyes, sudden blindness, subconjunctival haemorrhage, Roth spots.
10. Haematopoietic—Fatiguability, anaemia, leucocytosis, thrombocytopenia, T ESR and T CRP.
11. Spleen—Splenomegaly, pain in left hypochondrium, splenic rub (due to splenic infarction).
11. Bowel—Pain abdomen, mesenteric artery embolism, bowel infarction.

* Read modified Duke criteria for the clinical diagnosis of infective endocarditis from any standard text book.

How to establish the diagnosis of SBE ?

1. Blood—
   a) Anaemia (normocytic-normochromic).
   b) Leucocytosis (neutrophilia).
   c) Thrombocytopenia.
   d) Raised ESR and high C-reactive protein.
   e) Blood biochemistry—urea, creatinine, bilirubin and alkaline phosphatase levels may be elevated.
   f) Immunoglobulins and complements—tserum immunoglobulins, Tcirculating immune complexes and ^-complement levels are characteristic.
   g) Repeated blood culture (typical organism for infective endocarditis are diagnosed from two seperate blood cultures drawn 12 hours apart which detect bacteraemia in 90% culture-positive cases; or detected from all of 3, or majority of 4 or more seperate blood cultures done, with the first and last blood cultures obtained at least 1 hour apart. Blood is drawn under aseptic technique from different venepuncture sites; both aerobic and anaerobic, and rarely fungal cultures are done). At least10-20 ml blood is taken at a time which is not related to height of temperature. An indwelling I.V line should not be used for collection of blood. *Streptococcus viridans is the commonest pathogen in SBE. Positive blood culture gives the definite diagnosis of SBE.* Presumptive antibiotic therapy should be started immediately after obtaining the blood culture samples.
2. Urine—
   a) Microscopic haematuria (frank haematuria is rare).
   b) Slight proteinuria.
3. Chest X-ray—cardiac failure, cardiomegaly.
4. Electrocardiography (ECG) —
   Sinus tachycardia, prolonged PR interval, AV block (if septum is involved).
5. Echocardiography (2-D) — to assess valve damage, identification of vegetations (small/sessile/polypoidal), progress of vegetations, and abscess detection :
   a) Demonstration of parent disease (e.g.. MI here) with chamber dilatation.
   b) Vegetations (> 2 mm by transthoracic echo and < 2 mm by transoesophageal echo) are detected.
6. Bone marrow culture and serological study for Candida, Histoplasma and Brucella may be helpful in culture-negative cases.

* Positive past H/O recent dental extraction, genitourinary instrumentation or IV drug abuse is important in diagnosis of SBE.

Haematuria in SBE :

1. Autoimmune nephritis, and/or
2. Infarction of the kidney.

Features in the nervous system (in SBE) :

They are due to embolism or mycotic aneurysm. The features are,

1. Toxic psychosis, meningitis, metastatic brain abscess.
2. Convulsions, hemiplegia, intracranial haemorrhage due to haemorrhagic infarcts, subarachnoid haemorrhage (mycotic aneurysm), coma.

3. Roth spots—Yellowish, elliptical, *flame-shaped, haemorrhage with a pale centre* present in the retina and is found in ophthalmoscopy. This is due to deposition of circulating immune complex (other causes of Roth spots are aplastic anaemia, leukaemia, scurvy, dysproteinaemia and HIV retinopathy).

Right-sided endocarditis :

1. *Commonest organism is Staphylococcus aureus.*
2. Affects mainly the tricuspid valve and rarely the pulmonary valve.
3. Common in drug addicts or patients receiving central venous catheters.
4. Prognosis is relatively better.
5. Systemic embolisation is rare though pulmonary infection and infraction are not uncommon.

Clinical spectrum of infective endocarditis :

It is of two types :

1. Acute bacterial endocarditis—see below.
2. Subacute bacterial endocarditis (SBE)—caused by less virulent organisms with an indolent course. Cardiac damage occurs slowly and rarely metastasize unless complicated by a major embolic event. Organisms are Streptococcus viridans (commonest), staphylococci, HACEK organisms (Haemophilus, Actinobacillus, Cardiobacterium, Eikenella and Kingella), fungi (Candida) or rickettsia. SBE affects a patient who is suffering from either rheumatic heart disease or congenital heart disease or has undergone some sort of cardiac surgery (e.g., valvotomy, prosthesis).

Acute bacterial endocarditis :

1. Often involves the normal heart with a rapidly progressive course (SBE invariably involves damaged heart), and is caused by highly virulent and invasive organisms.
2. Right-sided involvement (tricuspid valve) is common; pneumonia may be present.
3. Clubbing is not a feature.
4. Common in I.V drug abusers.
5. Source of CVS involvement is often evident i.e., there may be preceding staphylococcal abscess or pneumococcal meningitis. *Staphylococcus aureus is the commonest pathogen.*
6. Cardiac and renal failure develop rapidly.

   Rapid onset and fulminant course; damages cardiac structures very rapidly and haematogenously metastasize in extracardiac sites.

Causes of culture-negative SBE :

This accounts for 5-10% of cases.

1. Partially treated patients.
2. Fungal, yeast infection or Q fever.
3. Intermittent bacteraemia.
4. L-form (cell-wall deficient form) of organism or fastidious organism (e.g., H. parainfluenzae).
5. Marantic endocarditis (non-bacterial thrombotic endocarditis, usually in elderly dying patients with advanced carcinomatosis).
6. Libman-Sacks endocarditis (non-bacterial verrucous endocarditis in SLE).
7. Right-sided endocarditis.

* 5 and 6 are examples of non-infective endocarditis.

Poor prognosis *in SBE :*

1. Prosthetic valve, fungal or gram-negative endocarditis.
2. Culture-negative endocarditis.
3. Presence of congestive cardiac failure,
4. Involvement of multiple valves.
5. Polymicrobial bacteraemia.

Cardinal features of SBE for 'bedside' diagnosis :

1. Fever (persistent or swinging), toxic look
2. Pallor,
3. Clubbing,
4. Mild splenomegaly,
5. Microscopic haematuria, and
6. Embolic manifestations.

* As soon as SBE is diagnosed, it should be managed very promptly. The life of the patient is in danger if there is delay in the diagnosis and initiation of treatment. **So, it is a rule to examine all CVS patients for anaemia, pyrexia, clubbing and splenomegaly.**

SBE with absence of fever :

1. CCF.
2. Uraemia.
3. Fungal endocarditis.
4. Severe sepsis.
5. Prior antibiotic therapy.
6. Elderly patients.

Cardiac diseases predisposing SBE :

1. Mitral and aortic valve diseases (mainly regurgitant diseases as regurgitant jet damages the endocardium and predisposes a bed for seeding of the microorganism) i.e., MI, mitral valve prolapse, AI commonly; MS, AS rarely.
2. VSD, PDA, bicuspid aortic valve, Fallot's tetralogy, rarely ASD.
3. Prosthetic heart valves, indwelling catheters.
4. Prior cardiac surgery (valvotomy, valve replacement).

N.B. : Read the management of CCF, LVF, atrial fibrillation, rheumatic fever and SBE in details from standard text books.

O

Section 2

RESPIRATORY SYSTEM

The cardinal symptoms of respiratory system are :

1. Cough
2. Expectoration
3. Haemoptysis (expectoration of blood or bloody sputum)
4. Chest pain (pleural pain or pain of tracheitis)
5. Breathlessness
6. Wheeze or stridor

Other symptoms are,

7. Hoarseness of voice
8. Heaviness in the chest
9. Fever
10. Swelling of feet (in chronic cor pulmonale).
11. Epistaxis (nosebleeds), symptoms related to ear/nose/throat (e.g., sinusitis, rhinitis, running nose, sneezing)
12. Syncope (e.g., cough syncope), bone pain (hypertrophic osteoarthropathy or rib pain in bronchogenic carcinoma), altered mentation (respiratory failure)
13. General symptoms — Appetite, loss of weight (pulmonary tuberculosis or bronchogenic carcinoma), fatigue, sleep, bladder and bowel

* ***Upper resperatory tract*** extends from external nares to the junction of largnx with trachea (i.e., upto lower border of cricoid cartilage), and includes nasal cavity, nasopharynx, sinuses, oropharynx and larynx. ***Lower respiratory tract*** includes trachea, lobar bronchus, segmental bronchi, generations of tracheobronchial tree and alveolar air sacs.

Scheme of Examination

(A) Upper respiratory tract (URT) :

1. Nose (congestion, discharge, hypertrophied turbinate, bleeding spots and polyp) and nasal septum (deviation); alae nasi (nasal flare).
2. Mouth breathing (e.g., adenoids) or purse-lip respiration (e.g., COPD).

3. Air sinuses (examine for tenderness over maxilla; ask the patient to sit and lean forward whether any heaviness on forehead is complained or not).
4. Pharynx (throat, gum, teeth, palate, posterior pharyngeal wall, post-nasal drip), nasopharynx, tonsils with oral hygiene; halitosis present or not
5. Larynx—Could not be examined (examined by direct and indirect laryngoscopy).

* The motto of examination of URT is to determine whether it is healthy/unhealthy, or favouring aspiration or not.

(B) Examination of the chest (lower respiratory tract) :

I. INSPECTION :

1. Shape of the chest.
2. Movement of the chest.
3. Apical impulse (stand on the right side of the patient and look tangentially over precordium).
4. Respiration — Rate, rhythm, type, depth and breathing pattern.
5. Venous prominence.
6. Fullness or depression —
   (i) Unilateral or bilateral.
   (ii) Localised or generalised.
7. Supraclavicular and infraclavicular fossae.
8. Whether both the nipples are at the same level or not.
9. Whether accessory muscles of respiration are working or not.
10. Wheeze or stridor.
11. Intercostal suction.
12. Skin (front and back) —
    Gynaecomastia (from bronchogenic carcinoma), pigmentation, sinus (e.g., from empyema, cold abscess or systemic fungal infection), ulcer, herpes zoster, puncture mark, any swelling (e.g., cold abscess or metastatic nodule), parietal oedema (e.g., amoebic liver abscess, empyema thoracis), shiny skin over empyema thoracis, blue markings for radiotherapy over sternum etc.
13. BACK —
    Scoliosis, kyphosis, drooping of the shoulder, winging of the scapula, gibbus, position of inferior angle of both scapula, symmetry of interscapular areas (spino-scapular distance), ankylosing spondylitis and venous prominence. Also observe the skin condition (e.g., sinus) over back.

* Any deformity after thoracic operation e.g., thoracoplasty, should be carefully looked for.

II. PALPATION :

1. Surface temperature.
2. Tenderness (rib tenderness in trauma, fracture or secondary metastasis; intercostal tenderness or punch tenderness in liver abscess or empyema thoracis).
3. Corroboration of the findings of inspection—Examine the spinal deformity, direction of venous flow, details of any swelling present, parietal oedema etc.
4. Position of the trachea and the apex beat (i.e, position of the mediastinum).
5. Movement of the chest (always measure the expansion of the chest by a tape in full inspiration and in full expiration).
6. Vocal fremitus.
7. Any other palpatory findings i.e., 'palpable accompaniments' like friction fremitus, rhonchial fremitus, palpable coarse crepitations, subcutaneous emphysema, palpable pericardial rub.

III. PERCUSSION ;

		Right	Left
a)	Conventional percussion		
b)	Shifting dullness	—	
c)	Coin percussion		

d) Hepatic and cardiac dullness — Lost or not (both are lost in emphysema); delineate the upper border of hepatic dullness along the right MCL.

IV. AUSCULTATION :

		Right	Left
a)	Breath sounds	—	—
b)	Vocal resonance	—	—
	(diminished or increased; whispering pectoriloquy, aegophony)		
c)	Adventitious sounds	—	—
	(rhonchi, crepitations and pleural rub)		
d)	Miscellaneous	—	—
	(succussion splash, post-tussive suction etc.)		

* It is better to auscultate all over the chest without leaving any space unexamined.

** Never forget to examine the upper respiratory tract and the back in respiratory system.

***** No examination of the lungs, however carefully performed, should be considered entirely satisfactory or final, if made in the recumbent position.**

Case 8

PLEURAL EFFUSION

What is your diagnosis ?

This is a case of left-sided massive pleural effusion, probably of tuberculous in origin.

Why do you say so ?

This is a case of pleural effusion (fluid collected within pleural cavity) because there are presence of:

(A) SYMPTOMS (from the history) :

a) Evening rise of temperature for 1 month.

b) Dry cough with left-sided chest pain for 20 days.

c) Heaviness on left side of chest for last 15 days.

d) Respiratory distress for last 3 days.

(B) SIGNS :

1. General survey :

a) Decubitus—Prefers to lie on left lateral decubitus.

b) Respitration—26/min, abdomino-thoracic in type and the rhythm is regular. There is less movement on left side of chest.

c) Lymph nodes—Not palpable (rarely, few matted non-tender or slightly tender cervical lymph nodes may be palpable in tuberculosis).

d) Pulse—90/min, regular; mention other points.

e) Temperature—100.8°F (oral) at present.

f) Emaciation.

g) Nicotine staining of the fingers (e.g., pleural effusion developing from bronchogenic carcinoma)—absent.

2. Inspection :

a) Upper respiratoy tract is within normal limit.

b) Increased respiratory rate of 26/min.

c) Fullness of intercostal spaces on left side of chest.

d) Diminished movement of chest on left side.

e) Apical impulse could not be visualised.

f) Absence of intercostal suction.

3. Palpation :

a) Diminshed movement on left side of chest and the expansion is only $1^1/_2$" as measured by the tape.

b) Trachea is shifted to the right side and apex beat could not be localised (i.e., impalpable) (if apex beat can be localised in a left-sided pleural effusion, it will be situated somewhere near the sternum, i.e., towards the right side],

c) Vocal fremitus is diminished on left side.

d) Absence of tenderness.

e) Friction fremitus—absent.
f) Normal palpatory findings on right chest.

4. Percussion :

Stony dullness on the whole of left side of chest which does not alter with change of posture, i.e., shifting dullness is absent. Traube's space is dull on percussion. Tenderness is absent while percussing the chest. Normal resonant note on right side of chest.

5. Auscultation :

a) Diminshed vesicular breath sound on left side (or absent breath sound). Normal vesicular breath sound on right side.
b) Vocal resonance—Diminished on left side; normal vocal resonance on right side.
c) Adventitious sounds —Crepitations, rhonchi or pleural rub is absent both in left and right side of chest.

* Sometimes, there is tubular breath sound, bronchophony and whispering pectoriloquy (with increased vocal fremitus), and aegophony present at the upper border of pleural effusion.

* * Vocal fremitus, percussion and auscultation are carried out in the following way :

1. Anterior chest—Along MCL (supraclavicular [apex], infraclavicular, mammary and inframammary area).
2. Lateral chest—Along MAL (axillary and infra-axillary area).
3. Back —
   (i) Upper part—Suprascapular area,
   (ii) Middle part—Interscapular area,
   (iii) Lower part—Infrascapular area (along scapular line)

*** According to few clinicians, 'slow' shifting dullness may be present in pleural effusion though it is difficult to demonstrate (not accepted by all).

**** The stony dullness of 'right'-sided pleural effusion is continuous with liver dullness while in 'left'-sided pleural effusion, the dullness is continuous with cardiac dullness with loss of Traube's space tympanicity.

What is your case ?

Build up the summary from the symptoms and signs, and try to say systematically as described above.

Why it is not a case of pneumothorax ?

Presence of stony dullness on percussion rules out pneumothorax (pneumothorax is tympanitic on percussion) and establishes the diagnosis of pleural effusion.

Why it is not a case of hydropneumothorax ?

As there is absence of :

1. Shifting dullness,
2. Succussion splash, and
3. Classical horizontal fluid level.

Important points in general survey in respiratory system :

1. ***Decubitus***—May be propped-up; orthopnoea.
2. Nutrition—Emaciation in tuberculosis, bronchogenic carcinoma, diabetes mellitus and AIDS (DM and AIDS are often associated with pulmonary tuberculosis).
3. Fades — Moon face due to SVC syndrome, sarcoidosis (lupus pernio).
4. Anaemia—Tuberculosis, bronchogenic carcinoma, massive haemoptysis.
5. Jaundice—Bronchogenic carcinoma metastasizing in liver, antituberculosis drug-induced hepatitis, disseminated tuberculosis, pulmonary thromboembolism.
6. ***Cyanosis***—Acute severe asthma, tension pneumothorax, lobar pneumonia etc.
7. ***Clubbing***— Bronchogenic carcinoma, bronchiectasis, lung abscess, empyema thoracis etc.
8. Pulse—Pulsus paradoxus in acute severe asthma.
9. ***Lymph* nodes**—Specially the supraclavicular glands, scalene nodes, Virchow's gland and glands in the posterior triangle of neck.
10. ***Respiration***—Tachypnoea, orthopnoea, hyperpnoea etc.
11. Temperature—For any infective aetiology like tuberculosis, lung abscess, pneumonia etc.
12. Any obvious deformity —Gibbus (due to caries spine), kyphoscoliosis, different chest deformities.
13. Oedema—From chronic cor pulmonale.

14. Eye—Horner's syndrome (bronchogenic carcinoma), subconjunctival haemorrhage (chronic cough, SVC syndrome), chemosis of conjunctiva (SVC syndrome), polycythemia (COPD), phlyctenular keratoconjunctivitis (primary tuberculosis), choroid tubercle in retina (miliary tuberculosis), colour blindness (ethambutol toxicity), papilloedema (COPD and SVC syndrome).
15. Hands—Nicotine staining, clubbing, cyanosis, wasting of small muscles of one hand (thoracic inlet syndrome), warm and moist hand (type II respiratory failure) and flapping tremor.
16. Skin—Erythema nodosum, scars and sinuses in neck, scrofuloderma.

What is pleural effusion ?

Collection of serous fluid within the pleural cavity (in between visceral and parietal layers of pleura) is *pleural effusion.* Only when the character of the fluid is transudate, it is known as *hydrothorax.*

Actually, the collection of fluid (resulting from increased hydrostatic pressure or decreased plasma oncotic pressure) occuring with a 'normal pleura' is ultrafiltration of plasma (transudate) in **hydrothorax;** it is usually bilateral. The effusion due to 'pleural diseases' more nearly resemble plasma (exudate) which results from increased capillary permeability; **pleural effusion** is commonly unilateral but may be bilateral.

Causes of pleural effusion :

(A) Exudative (pleural effusion) :

a) Pneumonia (bacterial and viral)—possibly the commonest cause worldwide.
b) Tuberculosis (possibly the commonest cause in India).
c) Bronchogenic carcinoma.
d) Pulmonary infarction (may be transudative in character).
e) Collagen vascular diseases like SLE, rheumatoid arthritis.
f) Pleural mesothelioma.
g) Lymphoma and leukaemias.
h) Meig's syndrome (many authorities believe it to be transudative in nature).
i) Pancreatitis, subphrenic abscess, liver abscess, oesophageal perforation, drug-induced,
j) Asbestosis-associated pleural effusion (benign).
k) Yellow nail syndrome (rare; due to lymphoedema).
1) Post-myocardial infarction syndrome (rare).

(B) Transudative (hydrothorax) :

a) Congestive cardiac failure (CCF).
b) Nephrotic syndrome.
c) Cirrhosis of liver.
d) Hypoproteinaemia with severe anaemia.
e) Constrictive pericarditis, pericardial effusion.
f) Myxoedema.
g) SVC syndrome.
h) Peritoneal dialysis.

a) b) c) and d) under (A) are most common causes of pleural effusion.

How to diagnose hydrothorax ?

1. Affection is usually bilateral.
2. Presence of anasarca.
3. Evidence of CCF, cirrhosis of liver, nephrotic syndrome or severe anaemia with malnutrition.
4. Absence of signs of inflammation (i.e., no H/O fever, local tenderness etc).
5. Transudative nature of pleural fluid on aspiration.

In patients with hydrothorax, always look for collection of fluid in other serous sacs. So, one should be careful in detecting oedema, pericardial effusion, ascites, hydrocele etc.

Haemorrhagic pleural effusion (haemothorax) :

1. Neoplasm—primary or secondary, pleural mesothelioma.
2. Chest trauma (during paracentesis or placement of central line).
3. Tuberculous effusion.
4. Bleeding diathesis.
5. Lymphoma and leukaemias.
6. Anticoagulant therapy.

7. Pulmonary infarction.
8. Acute haemorrhagic pancreatitis.

* Pleural effusion resulting from mesothelioma usually does not shift the mediastinum as mesothelioma encases the lung on the affected side and is commonly related to asbestos exposure.

Chylous (milky) pleural effusion :

It results from leakage of chyle into the pleural space and is due to,

1. Tuberculosis.
2. Malignancy.
3. Lymphoma.
4. Filariasis.
5. Myxoedema (gold paint effusion).
6. Trauma to the chest wall.
7. Congenital absence of thoracic duct.
8. Yellow nail syndrome.

Bilateral pleural effusion :

1. Rheumatoid arthritis.
2. SLE.
3. Lymphoma and leukaemias.
4. Bilateral tuberculous effusion (rare).
5. Pulmonary infarction.
6. Pleural metastases.

* Remember, hydrothorax is usually bilateral.

Predominant right-sided pleural collection :

1. Rupture of amoebic liver abscess into pleural cavity.
2. Cirrhosis of liver.
3. Congestive cardiac failure.
4. Meig's syndrome (fibroma of the ovary with ascites and pleural effusion).
5. Right-sided subphrenic abscess.

Predominant left-sided pleural collection :

1. Acute pancreatitis.
2. Oesophageal rupture.
3. Dressler's syndrome (post-myocardial infarction syndrome).
4. Left-sided subphrenic abscess.
5. Aortic dissection.

Recurrent pleural effusion (reappearance after thoracentesis) :

1. Bronchogenic carcinoma.
2. Pulmonary tuberculosis.
3. Congestive cardiac failure.
4. Collagen vascular diseases.
5. Pleural mesothelioma.
6. Lymphoma.

Drug-induced pleural disease and/or pleural effusion :

1. Nitrofurantoin.
2. Methysergide.
3. Amiodarone.
4. Dantrolene sodium.
5. Bromocriptine.
6. Procarbazine.

* The pleural fluid is eosinophilic in drug-induced plural effusion.

Bedside diagnosis of malignant pleural effusion :

Elderly patient with H/O smoking, nicotine stain in hand, emaciation, clubbing, palpable scalene nodes and may be with radiation mark over anterior chest. There is rapid and repeated collection of pleural fluid after thoracentesis, and the fluid may be haemorrhagic.

Causes ***of empyema thoracis (purulent effusion) :***

Collection of pus within the pleural cavity is known as empyema thoracis. The causes are,

1. Rupture of tuberculous cavity or post-pneumonic.
2. Secondary infection of haemothorax.
3. Rupture of subphrenic abscess; perforation of oesophagus.
4. Rupture of lung abscess (mostly staphylococcal—thin walled and multiple).
5. Septicaemia or pyaemia.
6. Traumatic (penetrating wounds of chest, after chest aspiration or liver biopsy).

Bedside diagnosis ***of empyema thoracis (purulent effusion) :***

1. Patient looks toxic and prostrated; loss of weight.
2. Hectic rise of temperature with rigors and sweating.

3. Tachycardia as well as tachypnoea.
4. Development of clubbing.
5. Intercostal tenderness (patient winces with pain) as well as fullness.
6. Skin is red, oedematous and glossy overlying empyema.
7. Signs of pleural effusion.
8. Rarely, a swelling in the chest wall is seen which gives impulse on coughing—'empyema necessitatis' (i.e., pus collected under the skin of the chest wall due to rupture of purulent material from the pleural cavity, which communicates with the empyema thoracis).

What is meant by 'stony dullness' on percussion ?

1. Dull note elicited by percussion, PLUS
2. Feeling of increased resistance by the percussing finger.

Bronchial breath sound above the fluid level in pleural effusion—mechanism behind :

It is said that air conducted through the relaxed or collapsed lung (compression collapse) produces tubular breath sound (so, there is bronchophony and whispering perctoriloquy). Conductivity of the sound through collapsed (airless) lung is increased if the bronchus remains patent.

Classical findings at the upper border of moderate pleural effusion :

1. Actually there is horizontal upper border of fluid level. Ellis's S-shaped curve (i.e., highest level of dullness is in axilla in comparison to anterior and posterior wall, and thus assuming the shape of the letter 'S') is not demonstrated clinically. It is said that the upper border of fluid level sweeps towards the axilla due to capillary action, and the highest point of fluid in axilla is just a radiological observation.
2. Skodaic resonance (after Josef Skoda) on percussion —It is observed just above the upper border of moderate effusion and the note (hyperresonant) mimics the percussion over an empty wooden box (boxy note). It is due to compensatory emphysema.
3. Bronchial breath sound (tubular)—May be audible.
4. Pleural rub, rarely.
5. Aegophony.

Who keeps the trachea in the midline ?

The equally negative intrapleural pressure on both sides.

Is it possible to have trachea shifted towards the side of pleural effusion ?

It is possible in a case of pleural effusion (malignant) developing from ipsilateral bronchogenic carcinoma. If we go through the basic physiology, it is very easy to understand.

(A) In absorption collapse (due to endobronchial growth, i.e., bronchogenic carcinoma or foreign body impaction) :

1. Bronchus—Not patent (obstructed),
2. Intrapleural pressure—Remains negative, and
3. Trachea—Shifted to the same side. It is the more negative intrapleural pressure which draws the trachea to same side.

(B) In compression collapse (due to pleural effusion, pneumothorax or hydropneumothorax) :

1. Bronchus—Patent,
2. Intrapleural pressure—Positive, and
3. Trachea—Pushed to the opposite side due to positive intrapleural pressure.

Now, if we deal with a case of bronchogenic carcinoma with malignant pleural effusion, the tussle between (A) and (B) will determine the position of trachea. If (B) plays more, trachea will go to the opposite side and if (A) plays more, **trachea will be shifted towards the same side.** If (A) and (B) play equally, trachea will remain in the midline.

So, if the pulling effect on trachea by absorption collapse (i.e., bronchogenic carcinoma) overcomes the pushing effect on trachea by compression collapse (i.e., pleural effusion), trachea remains on the same side of effusion.

Red flag signs in pleural effusion :

1. Trachea shifted to the side of effusion.
2. Developing into empyema thoracis.

Pleural effusion present but trachea remains in the midline :

The possibilities are :

1. Mild pleural effusion (only the apical impulse is shifted to opposite side).
2. Malignant pleural effusion secondary to bronchogenic carcinoma (as described above).
3. Loculated or encysted pleural effusion (both the apical impulse and trachea may not shift).
4. Bilateral pleural effusion (if the amount of collection is more or less equal).
5. Pleural effusion associated with mesothelioma of pleura.
6. Coincidental association of pleural effusion with ipsilateral apical fibrosis.

Observation on inspection of 'back' in respiratory system :

Inspection of back (in respiratoty system or CVS) **is always done in standing position** (if the condition of the patient permits) to avoid undue obliquity. Go to the back of the patient and look for :

1. Kyphosis (look from sides in profile).
2. Scoliosis (may be responsible for mediastinal shifting)
3. Drooping of the shoulder (signifies apical fibrosis or collapse, or tapezius paralysis).
4. Winging of the scapula (long thoracic nerve palsy or spinal deformity—Prominent medial border of scapula).
5. Whether the inferior angle of scapula on both sides are at the same level or not.
6. Interscapular area (spino-scapular distance)—Comparison between two sides of chest.
7. Intercostal suction.
8. Gibbus (acute angulation in the spine due to collapsed vertebra which is commonly developing from caries spine, and sometimes as a result of metastasis, or trauma).
9. Ankylosing spondylitis (stiff and immobile spine)—May produce restrictive lung disease.
10. Crowding of ribs (both in the front as well as the back).
11. Skin condition—Scar, sinus, herpes zoster, local oedema, venous prominence, arterial pulsation (Suzman's sign), pigmentation, deformity after thoracic operation, e.g., thoracoplasty etc.
12. Movement—Whether both the sides are moving simultaneously and symmetrically, or not.

Importance of past history in pleural effusion :

Any H/O :

1. Trauma.
2. Tuberculosis.
3. Asbestosis (mining, textile workers,, pipe fitters)—So, occupational history is important.
4. Diabetes mellitus.
5. Smoking (for malignant pleural effusion).
6. Skin rash, joint pain, neck swelling (lymphadenopathy)—For collagen vascular diseases, lymphoma etc.
7. Swelling all over the body (anasarca with hydrothorax).
8. Haemoptysis (tuberculosis, bronchogenic carcinoma etc).
9. Same type of illness in significant past (recurrence) or in the family (e.g., tuberculosis).

Differential diagnosis (D/D) of your case :

(A) Pneumonic consolidation—

1. Acute onset with high fever, rusty sputum and chest pain.
2. Pulse : respiration = 2 : 1 or 3 : 1 (normal ratio is 4 : 1).
3. Trachea and apex beat—**Normal** in position (i.e., no shifting).
4. Percussion—**'Woody dullness'.**
5. Auscultation—Tubular breath sound, bronchophony, whispering pectoriloquy, aegophony, crepitations and pleural rub may be present.

(B) Thickened pleura* —

1. Long history.
2. Crowding of ribs with drooping of the shoulder. Depression of intercostal spaces with reduced movement on the affected side.
3. Trachea and apex beat may be shifted towards the diseased side (in fibrothorax).
4. Dull note on percusion but **never stony dull.**

5. Diminished vesicular breath sound with diminished vocal resonance. Bronchial breath sound is never heard. Pleural rub may or may not be present.
6. Commonly an end result of tuberculosis, asbestosis or haemothorax.

* Often known as '***fibrothorax***' (diffuse pleural thickening when entire lung is surrounded by fibrotic pleura) and the clinical findings depend on degree of pleural thickening. There is blunting of costophrenic angle with tenting of diaphragm in chest X-ray.

(C) Fibrosis or collapse (absorption) of the lung—

1. Crowding or ribs, drooping of the shoulder and retraction of intercostal spaces: flat chest.
2. **Apex beat and trachea are shifted towards the affected side.**
3. Impaired resonance on percussion; never stony dull.
4. Diminished vesicular breath sound with occasional crepitations.

(D) Empyema thoracis— Already described.

(E) Bronchogenic carcinoma—

1. H/O cough, haemoptysis, chest pain and emaciation in an aged patient; smoker.
2. Superior mediastinal syndrome.
3. Cervical adenopathy (scalene group specially); clubbing.
4. **Usually no shifting of mediastinum** unless complicated by pleural effusion.
5. Localised rhonchi or crepitations.

(F) Pericardial effusion— Considered only in left-sided pleural effusion.

1. Trachea is in normal position (i.e., no mediastinal shift).
2. Tympanicity on Traube's space percussion—retained (lost in left-sided pleural effusion).
3. JVP—Engorged and may be pulsatile. Kussmaul's sign may be present.
4. Pulsus paradoxus.
5. Apex beat (if possible to localise) is medial to outer border of cardiac dullness.
6. Muffled heart sounds.

(G) Subphrenic abscess—

1. H/O recent abdominal operation or appendicitis etc.
2. Fever (hectic) with chill and rigor; pain in upper abdomen.
3. Rigidity in upper abdomen.
4. Absence of stony dullness in chest (on percussion).

[(H) Liver abscess— Considered only in right-sided pleural effusion.

1. H/O intestinal amoebiasis may or may not be present.
2. Patient looks toxic; fever with chill; shiny skin over the right lower chest.
3. Severe upper abdominal pain with right-sided intercostal tenderness present.
4. Upper border of liver dullness goes upwards.)

Confirmation of your diagnosis :

1. Chest X-ray — PA and lateral view, PLUS
2. Aspiration of pleural fluid (absolute proof).

Other findings on percussion in pleural effusion :

1. Area of dullness (triangular) on percussion against the vertebral column at the base of opposite lung (Grocco's triangle)—as a result of fluid forming a mediastinal bulge.
2. Loss of tympanicity of Traube's space (in left-sided pleural effusion).

Why there is dyspnoea in pleural effusion ?

Dyspnoea occurs if there is,

1. Massive collection and / or
2. Rapid collection.

Pleural effusion produces (compression) collapse of the lung with shifting of the mediastinum to opposite side which leads to reduction in the vital capacity.

Examination of CVS in respiratory diseases :

Search for ditated superficial veins over chest wall as well as engorged, non-pulsatile neck vein (SVC syndrome), pericardial effusion (as a complication of anasarca), and signs of RVH and RVF (chronic cor pulmonale).

Eliciting **ankle jerk**

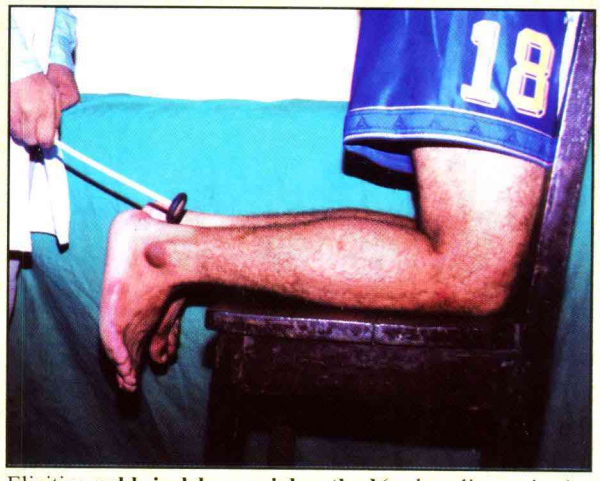

Eliciting **ankle jerk by special method** (on kneeling patient)

Eliciting **ankle clonus**

Eliciting **knee jerk**

Eliciting **knee jerk by special method** with **'reinforcement'**

Eliciting **patellar clonus**

Testing **jaw jerk**

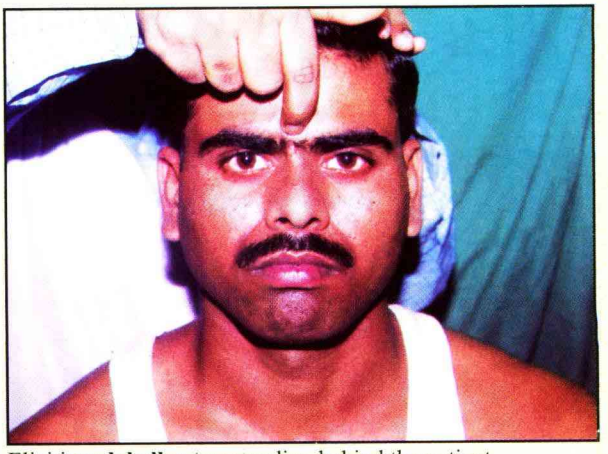

Eliciting **glabellar tap** standing behind the patient

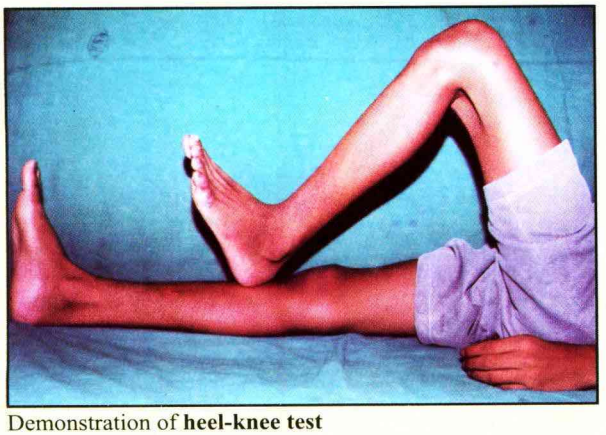

Demonstration of **heel-knee test**

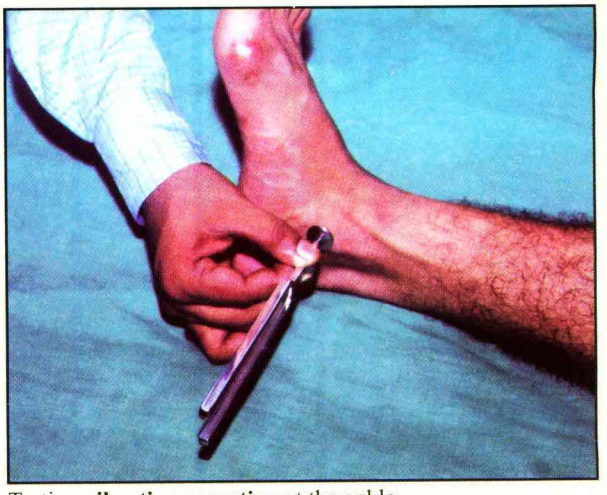

Testing **vibration sensation** at the ankle

Testing **joint-position sense**

Elicitation of **plantar response**

Examination of G. I system in respiratory diseases :

1. Halitosis (e.g., lung abscess).
2. Hepatosplenomegaly— Liver or spleen may be palpable due to the push effect of massive pleural effusion commonly rather than the cause of pleural effusion. Liver may be soft and tender in chronic cor pulmonale (liver of CCF). Splenomegaly is present in lymphoma, miliary tuberculosis, SLE and amyloidosis.
3. Ascites— In patients with hydrothorax (e.g., CCF), or disseminated tuberculosis.
4. Hydrocele or scrotal oedema— In patients with hydrothorax.
5. Abdominal lump— Pre- and paraaortic lymph nodes are palpable in lymphoma (may produce pleural effusion or SVC syndrome).
6. Hernial sites—Should be examined as protracted cough is common in COPD.

Examination of nervous system in respiratory diseases :

1. Neck rigidity / stiffness— If present, goes in favour of tuberculous meningitis or meningism due to pneumonia.
2. Higher function may be altered in SVC syndrome or respiratory failure.

* Horner's syndrome (bronchogenic carcinoma), myasthenic syndrome (Eaton-Lambert syndrome) and peripheral neuropathy may develop; the last two are non-metastatic complications of bronchogenic carcinoma.

Lymphadenopathy in a case of pleural effusion :

Think of :

1. Tuberculosis (specially in the posterior triangle of neck, supraclavicular fossa, axilla).
2. Lymphoma (generalised lymphadenopathy).
3. Bronchogenic carcinoma (scalene node, Virchow's gland).
4. Acute leukaemias (cervical, axillary).
5. SLE (generalised lymphadenopathy).

* Splenomegaly with pleural effusion is common in lymphoma, miliary tuberculosis, acute leukaemias, collagen vascular diseases (e.g., SLE) and cirrhosis of liver (hydrothorax).

What is 'phantom tumour' ?

Occasionally, effusion (transudate) forms between the lobes of lung (interlobar effusion) and produces a rounded opacity in chest X-ray, which mimics a solitary pulmonary nodule or mass lesion (sharply marginated with bi convex appearance). The mass usually disappears with the resolution of effusion and this is why they are known as phantom tumour. Phantom tumour may be seen in congestive cardiac failure, and 'vanishes' after diuretic therapy.

Sub-pulmonic effusion and its diagnosis :

Here the effusion collects underneath the lung and the chest X-ray (PA view) gives an impression of elevated hemidiaphragm. To confirm the diagnosis, a chest X-ray in 'LATERAL DECUBITUS' position (affected side down) is taken which shows the pleural fluid layering out along the lateral chest wall.

Clinically, the left-sided sub-pulmonic effusion is diagnosed by loss of Traube's space tympanicity and the right-sided effusion is suspected in abnormal tidal percussion on right side.

How massive pleural effusion is diagnosed clinically ?

In massive pleural effusion, the dullness (on percussion) extends upto the 2nd ICS or above. Radiologically, it produces dense opacification of hemithorax with mediastinal shift. Usually it is designated as mild (< 500 ml), moderate (500-1500 ml) and massive (>1500 ml) according to the collected amount of fluid. Massive effusion commonly results from malignancy, CCF, tuberculosis, cirrhosis of liver and trauma.

Points in favour of tuberculous aetiology in your patient :

It is possibly the commonest cause of pleural effusion in India. The points in favour are :

1. H/O evening rise of temperature and cough for approximately 1 month.
2. Presence of anorexia, night sweats, malaise and loss of weight for last 2 months.
3. H/O contact.
4. Emaciation.

* Tuberculous effusion Is thought to be due primarily to a hypersensitivity reaction to tuberculous protein. Other hypersensitivity reactions of tuberculosis are erythema nodosum and phlyctenular keratoconjunctivitis.

Complications of pleural effusion :

1. Thickened pleura.
2. Empyema thoracis.
3. Collapse (compression) of the lung followed by fibrosis later on.
4. Spread of infection (tuberculosis) to pericardium or peritoneum.
5. Cardio-respiratory embarrassment as a result of massive pleural effusion.
6. Acute pulmonary oedema (rare)— As a complication of rapid pleural aspiration.
7. Hydropneumothorax— May develop after pleural aspiration.

How do you like to investigate a case of pleural effusion ?

1. Blood—TC, DC. ESR, sugar (PP), serum amylase, any abnormal cell (high ESR and mild lymphocytosis goes in favour of tuberculous aetiology).
2. Chest X-ray (PA view) —
   a) Triangular homogeneous opacity with a curved upper border which is concave medially and upwards, and extends upto axilla.
   b) Obliteration of costophrenic angle (earliest site of fluid collection).
   c) Massive effusion produces unilateral homogeneous opacity.
   d) Displacement of mediastinum to the opposite side.
   e) LATERAL VIEW is done to differentiate it from lobar consolidation.

* Encysted pleural effusion may not obliterate the costophrenic angle.

** A lateral decubitus film may be taken in a suspected patient of sub-pulmonic effusion.

*** Repeatation of chest X-ray should be done in all cases after therapeutic paracentesis thoracis.

3. Aspiration of pleural fluid—
   For diagnostic purpose, at least 50 ml fluid should be aspirated. It helps by,
   a) Confirmation of diagnosis of pleural effusion.
   b) Examination of the nature of fluid—Transudate or exudate [physical character (clear in hydrothorax, red in haemorrhagic effusion, milky white in chylous and purulent in empyema thoracis), biochemical (TLDH in exudate,tadenosine deaminase activity in tuberculosis), and cytological (RBC, WBC, malignant cells) examination].
   c) Smear examination—
   Gram's stain, Ziehl-Neelsen stain, Leishman's stain for microfilaria or special stains for detection of malignant cells.
   d) Culture of the aspirated fluid (bacteriological including culture of M. tuberculosis in Lowenstein-Jensen media). Recently introduced culture technique (Bactec system) gives result within 7 days in favour of tuberculous effusion.
   A chest X-ray should be repeated after aspiration of pleural fluid to see the pulmonary parenchyma, specially in a suspected case of bronchogenic carcinoma. Sometimes, ultrasonography (USG) is done to differentiate an encysted pleural effusion from pleural tumour, and to localise effusion before aspiration or pleural biopsy.
   e) Special tests—Pleural fluid adenosine deaminase activity (Tin tubercubsis), and PCR study (polymerase chain reaction to detect organisms including tubercle bacilli).
4. Sputum examination— It is done for 3 consecutive days.
   a) For demonstration of AFB (surest test for tuberculosis) — Rarely positive.
   b) To diagnose the aetiology of pneumonia (if effusion develops from pneumonia).
   c) For malignant cells.
5. Mantoux test (not much informative)—
   a) Positive in cases of tuberculosis.
   b) May be negative in lymphoma.
6. Fine needle aspiration cytology (FNAC) or excision biopsy of lymph nodes (axillary, cervical or scalene node) —• May give a clue to the aetiology.
7. Imaging—Ultrasonography, CT scan or MRI scan detects fluid as small as 50 ml, and may be done if facilities are available.
8. Pleural biopsy (by Abram's, Cope's or trucut needle) — Specially in malignancy or tuberculosis.

9. Serological tests like rheumatoid factor, antinuclear factors, complement level etc.
10. Bronchoscopy and biopsy (in a suspected case of bronchogenic carcinoma).
11. Thoracoscopy and biopsy (pleura is inspected after inducing an artificial pneumothorax).

Minimal collection of pleural fluid for clinical detection :

At least 500 ml of fluid is necessary for clinical detection (minimally 300 ml fluid is required for radiological detection).

Possible causes of malignant pleural effusion :

1. Bronchogenic carcinoma (commonest).
2. Metastatic carcinoma (often from breast or thyroid).
3. Pleural mesothelioma.
4. Lymphoma.
5. Acute leukaemias.

* These are the causes of rapid and repeated accumulation of pleural fluid.

Indications of paracentesis thoracis (thoracentesis) :

1. Diagnostic - For physical character, biochemical, cytological and bacteriological study of pleural fluid to come to a definite diagnosis. At least, 50 ml fluid should be aspirated.
2. Therapeutic - If there is,
   (i) Respiratory distress,
   (ii) Massive collection,
   (iii) Rapid collection of fluid, and
   (iv) Suspected secondary infection of effusion.

Fluid should be aspirated slowly and as much as possible until it is harmful for the patient. Few clinicians advocate not to aspirate more than 1 litre of pleural fluid on the first occasion because of the risk of developing acute pulmonary oedema. The area of maximum dullness on percussion (usually in the mid-axillary line) should be the appropriate site for aspiration of fluid.

Complications of pleural aspiration or pleural tapping (thoracentesis) :

It is always done under strict aseptic condition with slow withdrawal of fluid. The complications are,

1. Pleural shock.
2. Empyema thoracis.
3. Hydropneumothorax.
4. Acute pulmonary oedema (non-cardiogenic; unilateral) - If fluid is removed very quickly.
5. Air embolism.
6. Cardio-respiratory embarrassment with circulatory collapse.
7. Subcutaneous emphysema.

Special characteristics of tuberculous effusion :

1. Possibly the commonest cause of plueral effusion in India and is usually associated with primary tuberculosis.
2. Straw-coloured or amber-coloured; EXUDATE in character (see below).
3. > 50% lymphocytes with paucity of eosinophils.
4. Cobweb coagulum formed in pleural fluid.
5. p^H is towards the acidic side.
6. Adenosine deaminase activity (ADA) in the fluid is elevated (>40 IU/L).
7. Others : elevated level of interferon-gamma (IFN-y> 140 pg/ml), presence of mycobacterial DNA (detected by PCR).
8. Paucity of AFB in pleural fluid. Yield :
   a) Pleural fluid—AFB is found in 6-8% cases.
   b) Ultracentrifused fluid—AFB is detected in 25-30% cases.
   c) Pleural biopsy—AFB is detected in 80% cases.
9. Pleural fluid culture for M. tuberculosis is 45% sensitive.

* 'Quantiferon-TB Gold test' is a test which detects latent as well as active tuberculous disease. The test measures a component of cell-mediated immune reactivity to M. tuberculosis and is based on quantification of IFN-y released from sensitized lymphocytes. The test requires a blood sample and the result is available within 24 hours. It is not affected by prior BCG vaccination.

Table 4 : Differentiation between transudate and exudate

Tests	Transudate	Exudate
(A) Routine :		
1. Apearance	Clear or light yellow. No froth on shaking	Straw-coloured, cloudy, purulent, milky, haemorrhagic. Froth formation on shaking
2. Protein	< 3.0g / 100ml	> 3.0g / 100 ml
3. LDH	Low (< 200 IU/L)	High (> 200 IU/L)
4. Pleural fluid LDH	< 2/3rd of normal upper limit of serum LDH	> 2/3rd of normal upper limit of serum LDH
5. Pleural fluid LDH/ serum LDH ratio	< 0.6	> 0.6
6. Plueral fluid protein / serum protein ratio	< 0.5	> 0.5
(B) Cytology :		
7. RBC	< 10000/mm^3	> 100000/mm^3
8. WBC	< 1000/mm^3	> 1000 mm^3 (> 50% lymphocytes in tuberculosis and neoplasm; >50% polymorphs in acute infections
9. Mesothelial or malignant cells	Not found	May be seen in neoplasm
(C) Special :		
10. p^H	> 7.3	< 7.3
11. Specific gravity	< 1016	> 1016
12. Glucose	Same as blood concentration	Low in infections and neoplasm (very low in rheumatoid arthritis)
13. Amylase	—	High in pancreatitis, oesophageal rupture and neoplasm
14. Microbiology	Negative	Positive

* No. 4, 5 and 6 are known as *Light's criteria* in pleural effusion.

** Some clinicians opine that SFAG [serum-fluid albumin gradient (i.e., serum albumin minus fluid albumin')] value may determine the nature of the fluid, i.e., SFAG > 1.1 is transudate, while <1.1 is exudate. The same calculation may be done by 'serum protein' minus 'fluid protein and if >3.1, it is tranudate and if <3.1, it is exudative in nature.

How to assess the movement of the chest ?

One has to assess whether both sides of the chest are moving simultaneously and symmetrically, or not. This is conventionally done at 3 places :

(A) FRONT-

Place both palms laterally on the lower rib cage in such a way that the thumbs touch each other in the middle anteriorly with a fold of skin in between the thumbs. Place the palms on the chest wall at the end of expiration. Now note the separation of thumbs and feel over the palms with inspiration. Usually this is done *at the level just below the nipples ('lower anterior chest).*

Normal expansion of the chest in an adult is at least 5 cm (5—8 cm normally), and expansion of 2 cm or less is abnormal. In severe emphysema and ankylosing spondylitis, it is found to be **1** cm or less.

N.B. : According to many clinicians, the respiratory movement of the *'upper' anterior chest* is determined by placing both palms side by side with thumbs touching the midline (terminal part of fingers will fall over clavicles). Now, note the elevation or lifting of palms, and not the speration of thumbs to assess the movement of the 'upper' anterior chest.

(B) BACK -

a) Place the palms vertically side by side in the interscapular region. Note the elevation or lifting of palms with inspiration.

b) At the infrascapular region—Same manoeuvre, as done in the 'lower' anterior part of the chest. Note the separation of thumbs with inspiration.

(C) APEX-

Patient will sit, and standing behind the patient place two palms on the shoulder (over the clavicle) in such a way that thumbs touch each other in the nape of the neck at the level of the vertebra prominence. Note the elevation or lifting of palms with inspiration (not the separation of the thumbs). The movement of the apex may be examined from the front in a patient who is unable to sit (patient will lie down and palms will be placed over the clavicles from the front).

After the clinical assessment of movement of the chest, always measure the expansion (in the lower part of anterior chest wall and infrascapular region of back) with a measuring tape. Take the measurement both in inspiration and expiration.

* The side with diminished expansion is likely to be the pathological side.

** Upper and middle lobe expansion Is best assessed from the front while lower lobe expansion is measured from the back.

Restriction of chest movement :

(A) Unilateral :

1. Pleurisy.
2. Chest trauma*.
3. Pleural effusion.
4. Pneumothorax.
5. Hydropneumothorax.
6. Collapse of the lung.
7. Fibrosis of the lung.
8. Thickened pleura.
9. Consolidation of the lung.
10. Empyema thoracis.

(B) Bilateral :

1. Emphysema.
2. Diffuse interstitial fibrosis.
3. Hydrothorax (bilateral).
4. Ankylosing spondylitis.
5. Sometimes in bronchial asthma.
6. Weak inspiratory muscles, e.g.. myasthenia gravis, respiratory paralysis (e.g., G.B. syndrome).
7. Any extensive bilateral disease.
8. Obesity.

* Due to severe chest pain, fractured ribs, flail segment following trauma or previous thoracoplasty.

What do you mean by 'expansion' of the chest ?

Expansion and movement of the chest are not Interchangeable terms e.g., in emphysema, chest may move but there is little expansion. 'Expansion' is the difference between inspiration and expiration, and is commonly measured by a tape.

Why there is aegophony above the level of effusion ?

It is due to interceptions of the relaxed lung as well as the fluid level, with the low-pitched component of the sound.

Why the upper margin goes towards axilla in chest X-ray ?

This Is a radiological illusion. A horizontal section of hemithorax at the level of the upper margin of fluid shows that there is same amount of fluid present anteriorly, posteriorly and laterally. But it is a fact that X-ray beam traverse more fluid laterally than they do centrally because of the peculiar shape of hemithorax. So we see the curved upper margin going towards axilla in X-ray picture.

Some clinicians opine that it is due to capillary suction between two pleural layers, which draws the fluid up.

How will you manage a case of pleural effusion ?

1. Rest in bed with good nutritious diet.
2. NSAID - To relieve chest pain.
3. Aspiration of pleural fluid if the patient suffers from respiratory distress or if there is rapid collection.
4. Chest physiotherapy should be encouraged to help in the expansion of lower chest.
5. According to aetiology :
   a) Tuberculous -
      (i) Antituberculosis chemotherapy.
      (ii) Sometimes, corticosteroid is added to prevent adhesion (20-40 mg daily for 6-12 weeks with gradual tapering).
   b) Malignancy-
      (i) Repeated aspiration of pleural fluid.

(ii) Pleurodesis (obliteration of the pleural space by adhesion) is done by tetracycline, bleomycin, mustine hydrochloride, talcom powder, Corynebacterium parvum etc. Alternatively, thoracotomy with pleurectomy or pleural abrasion may be tried.

(iii) Treatment of bronchogenic carcinoma or lymphoma is done accordingly,

c) Hydrothorax- Treatment of CCF or cirrhosis of liver is done accordingly.

CONCLUSION :

1. Always look for puncture mark, benzene stain or cotton seal in the lower chest (indication of pleural aspiration).
2. Shifting of mediastinum to the opposite side, stony dullness on percussion, and diminished (or absent) vesicular breath sound and vocal resonance on the affected side are **cardinal points for diagnosis.**
3. Examine for shifting dullness in the chest to exclude hydropneumothorax in all cases of pleural effusion.
4. Never forget to write measurement of the chest in two phases, i.e., both in full inspiration and in full expiration.
5. Always examine the upper respiratory tract (nose, nasal septum, air sinuses, pharynx) at the beginning of clinical examination of respiratory system,
6. **Do not forget to examine the breast, testes and spine in a patient of pleural effusion.**

Case 9

PNEUMOTHORAX

What is your diagnosis ?

It is a case of right-sided spontaneous pneumothorax of closed type, probably of tuberculous aetiology.

Why do you say so ?

It is a case of pneumothorax (air collected within pleural cavity) because there are presence of :

(A) SYMPTOMS (from the history)—

a) Respiratory distress for 3 days,

b) Pain in the right chest for 3 days, and

c) Rise of temperature for 2 months.

* *Breathlessness and pain chest started suddenly.*

(B) SIGNS—

1. General survey :

a) Decubitus—Propped-up position at present. The patient prefers to lie on right lateral decubitus and becomes breathless on left lateral decubitus.

b) Respiration—30/min, abdomino-thoracic in type and regular in rhythm. There is less movement on right side of chest.

c) Lymph nodes—Not palpable.

d) Cyanosis—Absent at present.

e) Pulse—84/minute and regular; mention other points.

f) Temperature—100°F (oral) at present.

2. Inspection :

a) Upper respiratory tract is within normal limit.

b) Increased respiratory rate of 30/min.

c) Intercostal spaces are full on right side.

d) No intercostal suction; accessory muscles of respiration are not working at present.

e) Diminished movement on right side of chest.

f) Apical impulse is seen on left side of chest, below the left nipple and placed more outward than normal.

3. Palpation :

a) Diminished movement on right chest. Expansion of chest is $1\frac{1}{2}$" as measured by the tape.

b) Trachea is shifted towards left side. Apex beat is palpable at left 5th ICS, **1'/$_2$**" outside the left MCL.

c) Vocal fremitus is diminished (or absent) on right chest. Normal vocal fremitus on left side.

d) Absence of local tenderness all over in the chest.

Percussion :

a) Tympanitic note on all over the right chest.

b) Obliteration (reduction) of liver dullness, and the upper border of dullness is present on right 7th ICS in the MCL.

c) Shifting dullness—Absent.

d) Normal resonant note on percussion over left side of the chest.

Auscultation :

a) Breath sound is diminished vesicular (or absent) on right chest.

b) Vocal resonance is diminished (or absent) on right chest.

c) Abventitious sounds — Neither rhonchi nor crepitations are heard. Pleural rub is absent.

d) Coin sound — Present on right chest.

Auscultatory findings on the left side of chest are normal.

* Pyrexia may be absent in pneumothorax; *chest pain and dyspnoea are two chief complaints.*

** *The chest in pneumothorax is known as 'tympanicity with silence'* (i.e., tympanitic note on percussion with diminished or absent breath sound).

*** A small pneumothorax may be asymptomatic without any abnormal physical signs in chest.

What is your case ?

Build up the summary from the symptoms and signs mentioned above.

Describe the dyspnoea (H/O present illness) in your patient :

The dyspnoea is due to collapse (compression) of the lung. It is,

1. Acute (sudden) in onset which compelled the patient to attend hospital immediately.
2. Sense of something being torn inside the chest, at the beginning of symptoms.
3. Not associated with wheeze (may be associated with wheeze in a COPD patient).
4. Dyspnoea at rest.
5. Not relieved by drugs, rest, squatting etc; minimally releived by adopting sitting posture or by right lateral decubitus position.
6. Associated with chest pain.
7. Non-progressive.
8. No H/O PND.
9. Not associated with 'shock and collapse' at the onset.
10. Cough aggravated the breathlessness.

* For gradation of 'respiratory' dyspnoea, see page 96.

Describe the chest pain (H/O present illness) in your patient :

1. It is sharp, and stabbing or tearing in nature; acute in onset and excruciating.
2. Present on the right side of the chest.
3. Increases by coughing, laughing, sneezing, jolting and inspiration.
4. Associated with dry cough.
5. The patient is forced to take shallow breathing and suppression of coughing.
6. Not relieved by any drug or by any other measure; forced the patient to attend hospital.
7. Without any radiation.
8. In all respect, it is a pleuritic pain.

Importance of past history in pneumothorax :

History of ;

1. Respiratory distress (COPD may be an aetiology of pneumothorax).
2. Tuberculosis.
3. Haemoptysis.
4. Trauma.

5. Prolonged recumbency with calf pain (indicates pulmonary thromboembolism—as D/D of dyspnoea of sudden onset).
6. Similar episode (recurrent pneumothorax) in the past.
7. Chest pain (IHD) — Indicates acute myocardial infarction (D/D of dyspnoea and pain chest).
8. Systemic hypertension (LVF may be a D/D of acute onset dyspnoea).

Other possible auscultatory findings in pneumothorax :

1. Amphoric breath sound may be heard on the affected side (open type).
2. Pneumothorax click—Sharp clicking sound synchronous with the heart beat may be heard in left sided 'shallow' or small pneumothorax.
3. Hamman's sign (in case of pneumomediastinum)— Read the section on 'Pericardial rub'.

How to examine for subcutaneous emphysema ?

It is the presence of air in the subcutaneous soft tissue and is also known as *'surgical emphysema'* (older term). When one gives light pressure after placing the fingers fanwise on the affected area, a peculiar spongy or crackling sensation (crepitus) is obtained. If a stethoscope is placed and pressed there, crepitations-like sound is heard. It may extend from face to the foot resulting in diffuse swelling of the part. The clinical associations are :

1. **Pneumothorax** (after intercostal tube drainage) or severe bronchial asthma (air may track into mediastinum resulting in mediastinal emphysema).
2. Rib fracture which penetrates the lung i.e., injury to the chest wall.
3. Fracture of paranasal air sinus.
4. Rupture of the oesophagus.
5. Laryngeal perforation (accidental).
6. Gas gangrene.

* Always search for subcutaneous emphysema in a case of pneumothorax having tube drainage.

Types of pneumothorax :

1. ARTIFICIAL - Artificially done to control tuberculosis by inducing collapse of the lung (not used now-a-days) or to differentiate radiologically among the lesion in pleura, lung and chest wall (diagnostic purpose).
2. TRAUMATIC - Chest trauma (stab injury), thoracic surgery, after pleural or lung biopsy, CVP recording through subclavian vein, fractured ribs, pericardiocentesis, bronchoscopy.
3. SPONTANEOUS -
   a) Closed [mild (<20% of radiographic volume in chest X-ray), moderate (20-50%) and large (>50%) variety [- Usually develops due to rupture of emphysematous bulla or from rupture of subpleural tuberculous focus. The communication between pleura and lung closes by fibrin clot as well as collapse of the lung, and usually does not reopen. Dyspnoea is not very severe and infection of pleural space does not occur. There is presence of mediastinal shift.
   b) Open - There is development of free communication between pleural space and bronchus ***(bronchopleural fistula).*** Air goes in and out of the pleural space with inspiration and expiration respectively. Expansion of collapsed lung is hampered and infection of the pleural space is a common complication (pyopneumothorax). Open type usually originates from the tuberculous cavity, lung abscess or apical subpleural bleb. Amphoric breath sound may be auscultated. The patient is dyspnoeic and there is presence of mediastinal shift. Penetrating wound of the chest also produces open type of pneumothorax.
   c) Tension (valvular) - The pleuro-pulmonary communication acts as a check-valve which allows air to enter into the pleural cavity during inspiration, coughing, sneezing and straining but prevents escape of air during expiration. Very large amount of air may be trapped within the pleural cavity in this way. Dyspnoea is very severe, and mediastinal shift is obvious and progressive (thus, there is shock and collapse). Central cyanosis is present. **It is a medical emergency** and the patient should be tackled immediately.

* Clinical classification of pneurmothorax : closed type, open type and tension type.

Pneumothorax in relation to atmospheric pressure :

1. Closed type—Intrapleural pressure < Atmospheric pressure.
2. Open type—Intrapleural pressure = Atmospheric pressure.
3. Valvular type—Intrapleural pressure > Several times of atmospheric pressure.

What is normal intrapleural pressure ?

Normal Intrapleural pressure is -2.5 to -6 mm of Hg. It is the negative intrapleural pressure, i.e., -2.5 mm of Hg. (subatmospheric) which keeps the lungs in apposition with the chest wall (at the end of expiration). At the height of inspiration, it becomes more negative, i.e., -6 mm of Hg.

Recent classification of spontaneous pneumothorax :

Spontaneous pneumothorax is one where air develops within the pleural space without antecedent trauma to the thorax. It is basically of two types :

(A) **'Primary'** spontaneous pneumothorax :
- a) Without underlying lung disease.
- b) Usually due to rupture of apical subpleural blebs of 1-2 cm in diameter,
- c) In tall, thin individuals between 20-40 years of age, and
- d) Usually in smokers.

(B) **'Secondary'** spontaneous pneumothorax :
- a) With underlying lung disease (different aetiology are mentioned below),
- b) Usually from COPD,
- c) Most common in older persons, and
- d) More dangerous than primary variety because of underlying lung disease.

Aetiology of pneumothorax :

1. Rupture of an apical subpleural bleb or bulla (usually in young patients).
2. Rupture of a subpleural tuberculous focus or tuberculous cavity.
3. Rupture of the pulmonary end of pleuro-pulmonary adhesion.
4. Rupture of subpleural emphysematous bullae (usually in elderly).
5. Staphylococcal lung abscess.
6. Penetrating or non-penetrating trauma to the chest.
7. Bronchogenic carcinoma.
8. Pulmonary infarction.
9. Rupture of 'Honeycomb lung' (bronchiectasis, scleroderma, histiocytosis X disease, tuberous sclerosis etc).
10. Bronchial asthma.
11. Whooping cough.
12. Cystic fibrosis.
13. Rupture of oesophageal carcinoma.
14. Rupture of a tension cyst in lung.
15. Artificial pneumothorax.
16. Catamenial pneumothorax—rare disorder in women over 25-30 years, occuring within 48 hours of onset of menstruation; probably due to pleural endometriosis; recurrent and usually right-sided, treated by OC pills to suppress ovulation, or danazole, surgical explorations and pleurodesis.
17. Caisson's disease.
18. ARDS.

* 1, 2, 3 and 4 are principle causes of pneumothorax. Aetiology No. 1 is usually congenital and probably the commonest cause worldwide.

Causes of recurrent (more than twice) spontaneous pneumothorax :

1. Patients with emphysematous bulla or apical subpleural bleb.
2. Cystic fibrosis.
3. Rupture of bronchogenic carcinoma or oesophageal carcinoma.
4. Patient with lung cysts.
5. Catamenial pneumothorax.
6. Honeycomb lung.
7. AIDS.
8. Ehlers-Danlos syndrome, Marfan's syndrome.

Causes of bronchopleural fistula :

1. Tuberculous cavity.
2. Lung abscess.
3. Necrotising pneumonia.
4. Following lung resection.
5. Chest trauma.
6. Barotrauma.
7. Empyema thoracis.

* Bronchopleural fistula is often used synonymously with open pneumothorax.

Percussion note over normal lung :

Lung is resonant on percussion while abdomen is tympanitic. When the air in a cavity of sufficient size is set into vibration, the character of the sound becomes tympanitic, e.g., in the case of percussion over stomach. On the other side, the lung alveoli are small pockets of air seperated by numerous septa which dampen down the sound from tympanitic to resonant note.

Differentiation between different characters of percussion note :

It is described below from higher to lower note of resonance :

(A) Resonant note :

1. Tympanitic (abdomen, pneumothorax) of the lung).
2. Hyperresonant (emphysema)
3. Resonant (normal lung)
4. Impaired resonance (thickened pleura)

(13) Dull note :

5. Woody dullness (consolidation
6. Stony dullness (pleural effusion)

Tympanitic note on percussion :

1. Pneumothorax.
2. Superficial, big, empty cavity.
3. Over a large emphysematous bulla.
4. Subpleural lung cyst.
5. Sliding hiatal hernia (left side only).
6. Over Traube's space.

* Remember, tympanitic note is elicited on percussion over any hollow viscus.

Hyperresonant note on percussion :

1. Emphysema.
2. Occasionally over lung cyst.

Impaired note (slightly diminished normal resonance) on percussion :

1. Thickened pleura.
2. Fibrosis of the lung.
3. Collapse of the lung.
4. Over pulmonary neoplasm.
5. Early pleural effusion.
6. Consolidation of the lung.

Dull note on percussion :

1. Consolidation **(woody dullness).**
2. Pleural effusion, empyema thoracis and over 'hydro' part of hydropneumothorax **(stony dullness).**

Causes of acute chest pain :

1. Ischaemic heart disease (IHD), i.e., angina pectoris or acute myocardial infarction.
2. Acute dry pleurisy due to any cause (e.g., tuberculosis, pneumonia).
3. Spontaneous pneumothorax.
4. Diffuse oesophageal spasm (may be food-related), gastro-oesophageal reflux disease.
5. Acute pulmonary thromboembolism.
6. Musculoskeletal pain : rib fracture (trauma, cough), secondary deposits in rib (malignancy, multiple myeloma), costochondritis (Tietze's syndrome), abscess or furuncle on the chest wall, myositis, fibrositis, intercostal myalgia (Bornholm disease — intercostal muscle involvement by Coxsackie B virus infection), thrombophlebitis of anterior thoracic vein (Mondor's disease), arthritis of shoulder joint or spine, intercostal neuralgias.
7. Acute dry pericarditis.
8. Acute tracheobronchitis, mediastinitis.
9. Aortic stenosis, hypertrophic cardiomyopathy.
10. Dissecting aneurysm.
11. Herpes zoster on the chest wall.

12. Anxiety states/psychogenic (cardiac neurosis).
13. ***Abdominal disorders*** e.g., hiatal hernia, acute cholecystitis, acute pancreatitis, perforated peptic ulcer, ruptured amoebic liver abscess, splenie flexure syndrome.

* Local tenderness is found in 6 and 11; 2 and 7 may produce tenderness.

Enumerate the causes of 'retrosternal' chest pain :

1. Ischaemic heart disease.
2. Oesophagitis or diffuse oesophageal spasm.
3. Acute dry percarditis.
4. Acute mediastinitis.
5. Diaphragmatic hernia.
6. Mediastinal tumour or mediastinal emphysema
7. Aneurysm of the aorta.
8. Dissecting aneurysm.
9. Tracheitis.
10. Psychogenic.

* Causes of chest pain remain within :

a) Retrosternal (central), b) Pleural (non-central; causes of pleurisy), and c) Musculoskeletal pain (non-central).

** ***'Precordial catch'***—Sudden, momentary stabbing pain at cardiac apex experienced by normal subjects; physiological and does not indicate organic heart disease.

*** Sharp stabbing left 'submammary pain' associated with anxiety is known as cardiac neurosis or Da Costa's syndrome.

Dyspnoea of acute or sudden onset :

1. Cardiac asthma (cardiogenic pulmonary oedema).
2. Acute severe asthma (status asthmaticus).
3. Acute exacerbation of chronic obstructive pulmonary disease (COPD), or acute viral/bacterial bronchitis.
4. Acute laryngeal obstruction (child—foreign body, diphtheria, oedema of glottis; adult — foreign body like dentures, loose teeth, tetany, oedema of glottis etc.).
5. Spontaneous pneumothorax (tension type).
6. Anaphylaxis (oedema of glottis).
7. Acute pulmonary thromboembolism.
8. Rapidly accumulating massive pleural effusion.
9. Diabetic ketoacidosis.
10. Lobar pneumonia.
11. Cardiac tamponade.
12. ARDS.

13 Hysterical hyperventilation (dyspnoea is more at rest than on exertion).

* 1, 2, 4, 5, 6 and 7 are very important causes. Acute obstruction of upper airway with food is known as 'cafe coronary'.

**** Classification of dyspnoea according to time course of onset :**

a) In seconds—4, 5, 6 and 7
b) In hours—1, 2, 9, 10, 11 and 13
c) In days—3, 8 and 12
d) In weeks to months—Severe anaemia, pleural effusion, COPD, weakness of respiratory muscles e.g., myasthenia gravis.

Aetiology of chest pain with dyspnoea :

1. Spontaneous pneumothorax.
2. Acute myocardial infarction.
3. Trauma to the chest wall.
4. Acute pulmonary thromboembolism.
5. Dissection of aorta.
6. Acute dry pleurisy (specially from consolidation).
7. Psychogenic.

* Usually (No. 5) from Marfan's syndrome, hypertension, coarctaion of aorta and pregnancy.

Aetiology of chest pain with circulatory collapse or syncope :

1. Acute myocardial infarction.
2. Tension pneumothorax.
3. Acute pulmonary thromboembolism.
4. Dissection of aorta.
5. Cardiac tamponade.
6. Acute pancreatitis.
7. Upper gastro-intestinal bleeding.

Different types of fremitus over chest :

Fremitus is synonymous with 'palpable vibrations'. The different types are :

1. Vocal fremitus.
2. Rhonchial fremitus (palpable rhonchi; rhonchi are better felt than crepitations).
3. Friction fremitus (palpable pleural rub).
4. Tactile fremitus :
   a) Palpable coarse crepitations,
   b) Palpable subcutaneous emphysema,
   c) Palpable pericardial rub.

* Except the vocal fremitus, others are sometimes called as **'palpable accompaniments'.**

** **Vocal fremitus** is the palpation of laryngeal vibrations on the chest wall when the patient speaks some words repeatedly in a constant tone and voice (e.g., 'one, one' or 'ninety-nine, ninety-nine'). Place the palm of the hand (thenar and hypothenar eminences) or the ulnar border of right hand over the intercostal spaces on the chest, comparing the corresponding areas on both sides. Always use the same hand for examining both the sides (use right hand). Avoid the area of cardiac dullness on left side and place the hand a bit laterally. Start from above downwards in the front, sides and back of the chest. For changes (diminished or increased) in vocal fremitus, see page 92 as causes for changes in vocal fremitus are exactly the same as that of vocal resonance.

How cough is analysed at the bedside ?

1. Duration (days/months/years); acute < 3 weeks, chronic > 3 weeks.
2. Variability (daytime/noctumal/morning).
3. Precipitating factors (dust/fumes/pollen/cold air; lying down-^ gastro-oesophageal reflux disease or CCF).
4. Sputum analysis (see below).
5. Types (dry/wet/bovine->see below).
6. Haemoptysis — present or not.
7. Associated symptoms (post-nasal drip, gastro-oesophageal reflux disease or occult asthma —> these are common causes of long-standing, undiagnosed cough); wheeze? seasonal?
8. Chest pain (pleuritis) or breathlessness (COPD) — present or not.
9. H/O drug intake—ACE-inhibitor, p-blocker.

Types of cough :

1. Dry (non-productive) — Acute dry pleurisy, acute tracheobronchitis, interstitial lung disease.
2. Wet (productive) — Bronchiectasis, lung abscess, resolution stage of lobar pneumonia.
3. Hacking (pharyngeal cough) — Heavy smokers.
4. Whooping — Found in whooping cough. There is rapid succession of dry coughs which gather speed gradually and end in a deep inspiration during which the characteristic 'whoop' (noise) is heard.
5. Brassy (with a metallic sound) — In carcinoma of larynx.
6. Bovine (laryngeal cough) — In recurrent layngeal nerve palsy, which is commonly due to bronchogenic carcinoma (the explosive nature of cough is lost).
7. Spluttering cough In tracheo-oesophageal fistula (cough during swallowing).
8. Barking Harsh and loud cough; found in epiglottitis and hysteria.
9. Nocturnal — Chronic bronchitis, LVF, tropical eosinophilia, post-nasal drip, aspiration.
10. 'Croupy' cough — Laryngitis, specially in children.
11. Foetid cough In bronchiectasis and lung abscess, there is foul smelling expectoration.
12. Recurrent cough since childhood Cystic fibrosis, childhood asthma, congenital heart disease, cystic disease of lung, hypogammaglobulinaemia.
13. Cough with postural variation (postural cough)—Bronchiectasis, lung abscess, gastro-oesophageal reflux disease (GERD), bronchopleural fistula.

Profuse purulent sputum :

1. Bronchiectasis.
2. Lung abscess.
3. Sometimes, chronic bronchitis.
4. Empyema throacis ruptured into bronchus.
5. Tuberculous cavity.
6. Cystic fibrosis, resolving pneumonia.

* 1, 2 and 4 are causes of **profuse and offensive** sputum. Infection with anaerobic organisms and necrotising pneumonia also produce offensive sputum.

** **Profuse sputum** means approximately a teacupful (> 100 ml) of sputum production per day.

How sputum (expectoration or 'phlegm') is analysed clinically ?

1. Amount (profuse or not).
2. Character (serous, mucoid, purulent, mucopurulent).
3. Colour (yellow, green, black, rusty, pinkish or anchovy-sauce like).
4. Odour or taste (offensive or not).
5. Mixed with blood (haemoptysis) or not.
6. Sputum production influenced by change of posture (bronchiectasis, lung abscess) or not.

How to palpate the trachea ?

Normal position of trachea in a healthy person is **central** or slight deviation to the right side.

Steps :

1. Trachea should be palpated in standing (most preferable) or sitting position with arms placed symmetrically on two sides and chin held in the midline. **Trachea should not be examined in lying down position** unless the patient is very ill.
2. One may fix the head of the patient with his left hand. Standing in front of the patient (patient looking directly forward), place the right index finger on the cricoid cartilage (trachea starts from lower border of cricoid) and slide it down over the tracheal rings upto the suprasternal notch.
3. Now slide the index finger in the angle between the sternomastoid muscle and trachea on both sides (never poke the finger, otherwise the patient may start coughing). **The angle is narrowed and feels more resistant on palpation with deviation of trachea to that side.**

* It is better to have the patient's and examiner's head at the same level by proper adjustment (while sitting). Always exclude goitre (by inspection only) before palpating the trachea.

Shifting of trachea and apex beat :

(A) To same side (pull effect) :

1. Fibrosis of the lung.
2. Collapse of the lung (absorption collapse).
3. Grossly thickened pleura.
4. Pneumonectony.

B) To opposite side (push effect) :

1. Pleural effusion.
2. Pneumothorax.
3. Hydropneumothorax.
4. Empyema thoracis.
5. Pyopneumothorax.
6. Haemothorax, haemopneumothorax.

Tracheal shifting is absent in consolidation, emphysema. bronchial asthma, interstitial lung disease, bronchitis, bronchiectasis and lung abscess.

** **'Mediastinal shifting'** means shifting of trachea (superior mediastinum) PLUS shifting of apex beat (inferior mediastinum). Trachea is commonly shifted in diseases of the upper part of chest (like shifting of trachea to same side in apical fibrosis or collapse) and predominantly apex beat is shifted in involvement of the lower part of chest (like shifting of the apex beat to opposite side in mild to moderate pleural effusion though a massive pleural effusion shifts the trachea too).

*** Remember, mediastinum may be shifted in ***scoliosis.***

summarise, **causes of displacement of apex beat** are LVH, RVH, mediastinal shift (pleuro-pulmonary diseases), thoracic deformity (e.g., scoliosis) and dextrocardia.

How to differentiate dextrocardia from dextroversion ?

In dextrocardia (congenital), heart is present in right hemithorax with apex pointing to the right while trachea remains central in position. In dextroversion due to extracardiac causes (e.g., left-sided pleural effusion or pneumothorax, or right-sided fibrosis or collapse of the lung), both trachea and apex beat will be shifted to the right.

To ***differentiate dextrocardia from dextroversion, always palpate the trachea.***

What is sternomastoid sign ?

It is the undue prominence of lower part of sternomastoid muscle due to deviation of trachea to that side. This is also known as **Trail's sign.**

Shifting of trachea without any lung pathology :

1. Severe scoliosis.
2. Enlarged lymph nodes on one side of neck.
3. Huge enlargement of one lobe of thyroid gland.

4. Aneurysm of the arch of aorta.
5. Any superior mediastinal growth.

Elicitation of 'coin sound' :

It is classically found in pneumothorax (and rarely, in the 'pneumo' part of hydropneumothorax). Coin sound is mostly found in a **tense pneumothorax** (elicited by coin percussion) and also known as bell sound, bell tympany, bruit-de-airain or 'distal anvil sound'. The clinical examination goes like this :

1. The observer sands at the back. A metallic coin (one rupee coin preferably) is placed over the upper part of front of the affected chest and is percussed with a similar type of coin when the observer listens at the back (just diametrically opposite to the point of percussion) with the diaphragm of stethoscope. A high-pitched tympanitic bell-like metallic sound (ringing sound) is heard in a patient with tense pneumothorax. It is necessary to compare the sound with the healthy side (which produces a dull thud as the normal lung does not transmit the ringing metallic sound distinctly). The patient helps here by fixing one coin in the anterior chest wall with his left hand and also by beating it with another coin with his right hand.

Or,

2. An alternative method : the patient fixes the diaphragm of observer's stethoscope over the anterior chest wall (observer stands at the back of the patient and throws the stethoscope over the patient's shoulder) while the observer himself puts a coin in the back and strikes it with the second coin. In these methods, one coin is acting as pleximeter finger while the other is serving the purpose of percussing finger.

D/D you will consider in this case :

(A) Causes of unilateral tympanitic or hyperresonant note with diminished breath sound :

1. Large emphysematous bulla—Symptoms of chronic bronchitis may be present.
2. Lung cyst May be difficult to distinguish from pneumothorax (in contrast to pneumothorax, there is no mediastinal shifting and absence of collapsed lung at hilum in lung cyst).
3. Superficial, big, empty cavity (connected with a patent bronchus)—
   a) Cavernous breath sound,
   b) Post-tussive suction,
   c) Post-tussive crepitations,
   d) Cracked-pot sound on percussion.

[4. Sliding hiatal hernia May have chest pain, dysphagia, heart burn, respiratory distress due to nocturnal regurgitation. The whole chest is not tympanitic. Breath sound is not totally absent in **the left side of chest.]**

(B) Causes of chest pain with dyspnoea :

1. Acute myocardial infarction Occurs in middle aged or aged persons, retrosternal chest pain with radiation to left hand, drenching sweat and shock. Breathlessness with signs of heart failure may be found.
2. Acute pulmonary thromboembolism—Sudden onset of pain chest with dyspnoea, haemoptysis and circulatory collpase are present. Tachycardia, low BP, elevated JVP, right ventricular gallop rhythm, loud P_2 are not uncommon. Normal resonant note on percussion over the chest with paucityj>f signs on auscultation. H/O prolonged recumbency or signs of thrombophlebitis may
3. Trauma to the chest—H/O trauma, 'point of tenderness' may be detected. Normal resonant note on percussion. Typical findings of pneumothorax are lacking.
4. Acute dry pleurisy—Dyspnoea is not so common but chest pain is present. Pleural rub is audible and no sign of pneumothorax can be detected.
5. Dissection of aorta—Abrupt onset of tearing retrosternal chest pain and dyspnoea (mimicking acute myocardial infarction) with pain referred to the back. There is discrepancy between carotid pulses, difference of BP in two arms, arrhythmia, shock and features of acutely developing aortic incompetence. No sign of pneumothorax is present. The patient is commonly hypertensive or having Marfan's syndrome or in the third trimester of pregnancy.
6. Massive collapse of the lung—H/O aspiration of foreign body may be present. Mediastinal shifting is towards the side of collapse. Impaired resonance note is revealed on percussion. Breath sound is diminished vesicular or absent.

Complications of pneumothorax :

1. Hydropneumothorax.
2. Pyopneumothorax.
3. Empyema thoracis.
4. Haemopneumothorax.
5. Thickened pleura.
6. Circularoty collapse; acute respiratory failure.
7. Atelectasis of lung.
8. Surgical emphysema and pneumomediastinum.

How do you like to investigate this case ?

1. Chest X-ray (PA view)—Done in **erect posture.** Sometimes, the X-ray is taken **after full expiration,** specially in a small pneumothorax. The radiological features are :
   a) Increased radiolucency on right side of the chest with absence of bronchovascular markings in that area.
   b) Collapsed right lung is seen as a homogeneous opacity with sharp outline (present paracardiac or paravertebrally).
   c) Shifting of mediastinum towards the left side.
   d) The left lung is showing mottled opacity in the apical area (signs of pulmonary tuberculosis) — May be normal.
   e) Costophrenic angles are clear.

* Remember, in large lung cyst or large bulla (mimics pneumothorax in chest X-ray) there is no mediastinal shifting.

2. Blood—TC, DC, ESR (increased lymphocytes with high ESR point towards tuberculosis).
3. Mantoux test—Positive in tuberculous aetiology.
4. Sputum for detection of AFB is done for consecutive 3 days along with culture for M. tuberculosis.
5. Lung function tests—FEV^, FVC, PEFR etc. (to detect underlying emphysema, COPD etc).

Management of pneumothorax :

(A) Small pneumothorax (less symptoms)—The air gets absorbed spontaneously within few days and no treatment is required. The patients with underlying lung disease (COPD) can not tolerate even a small pneumothorax and in that case air must be removed. Small pneumothorax needs close observation with serial radiographic monitoring.

(B) Large pneumothorax or tension pneumothorax—0_2 inhalation and propped-up position. A self-retaining catheter is inserted into the pleural cavity (in sitting position) in ***the 2nd ICS along the MCL (preferable),*** or in the 4th or 5th ICS behind the anterior axillary fold (more comfortable for the patient and cosmetic for a female patient though not used routinely). The tube is now connected to a water-seal drainage system. If no bubbling is seen for 24 hours, or the patient is relieved of dyspnoea, or the chest X-ray shows complete re-expansion of lung, the tube is removed. The whole process takes approximately 3-4 days.

(C) Recurrent spontaneous pneumothorax—Chemical pleurodesis is done by intrapleural instillation of kaolin, talcom powder, minocycline, 50% glucose solution, iodised oil etc. Alternatively, parietal pleurectomy or pleural abrasion may be tried.

(D) Antituberculosis chemotherapy, whenever indicated. Sometimes, antibiotics are used to prevent secondary infection; antibiotics are always used in open type.

(E) SurgeFy—
   a) Thoracoscopy and cauterisation of the breach in the pleura, or excision of the bulla.
   b) Pleurectomy (in recurrent type when pleurodesis fails).
   c) Decortication and closure of bronchopleural fistula, lobectomy or thoracoplasty.

* Surgery is usually required for open type (cauterization, or open thoracotomy and direct closure of fistula).

** The rate of reabsorption of air is about 1.25% of the total radiographic volume per day and thus, a 50% pneumothorax (occupying 50% of hemithorax) will take 40 days to resolve totally.

Immediate management of tension pneumothorax :

(A) 0_2 inhalalation and propped-up position.

(B) Do not wait for the chest X-ray, and immediately insert a wide-bore needle (16 G) into the pleural space through the 2nd ICS at MCL (in sitting position). If large amount of gas escapes from the needle, the diagnosis is confirmed and the patient gets relieved. The needle should be left in place until an intercostal tube drainage with water-seal drainage system can be arranged at the earliest opportunity. If the tension penumothorax is dealt in this way, circulatory collapse (cardio-respiratory embarrassment) can be prevented.

(C) Treatment of shock and circulatory collapse, if present (tension pneumothorax^ mediastinal shift plus severe hypoxaemia-> diminished venous return-* inadequate cardiac output).

Water-seal drainage : whether working properly or not ?

The tube coming out from the pleural cavity should be placed under water. Exit-tube (for air) will always remain above the water level in the bottle. Look for bubbling of air in the water. The whole channel is patent and working if :

1. During each expiration or coughing, more bubbling occurs, and
2. During inspiration, water column ascends within the tube, which remains under water.

* The bottle should be kept below the level of thorax. If the water-seal drainage is required to continue for more than a week, the tube should be removed (always remove after clamping it) and a new tube is attached (the then may change the site of insertion in the chest).

Reasons behind failure of the lung to re-expand in due time :

1. The lung is trapped, or
2. A major bronchus is obstructed, or
3. Presence of bronchopleural fistula, or
4. Water-seal drainage is not working properly.

Will ***you advise any respiratory exercise*** ?

Yes. The patient is advised to inflate incentive spirometer, air pillows, balloons or football bladder, which will help in expansion of the collapsed lung. Before discharge from hospital, the patient is advised not to smoke, and must stop to fly or.dive for 3 months.

Basic treatment strategy in pneumothorax :

1. Closed type—Observation, water-seal drainage if necessary.
2. Open type—Water-seal drainage system; treat hydropneumothorax or pyopneumothorax. Consult thoracic surgeon. Treat with proper antibiotic.
3. Tension type—Always tackle this medical emergency by water-seal drainage system.

N.B. : PLUS, Antituberculosis chemotherpy, if indicated.

Pneumothorax is seen in X-ray plate : will you treat ?

If the patient suffers from :

1. Dyspnoea, and/or
2. Cyanosis, and/or
3. Gross mediastinal shifting, and/or
4. Pneumothorax occupying > 50% of hemithorax, and/or
5. With underlying lung disease (e.g., COPD), and/or
6. Circulatory collapse

—Immediate treatment by intercostal tube drainage with underwater seal is necessary.

Describe the antituberculosis treatment :

It is the standard practice for patients with pulmonary and lymph node disease ;

(A) Short course chemotherapy **for 9 months** with three drugs regimen :

1. Rifampicin- 450 mg/day, if < 50 kg and aged; 600 mg/day, If > 50 kg.
2. INH (isoniazid)- 300 mg/day.
3. Ethambutol- 25 mg/kg/day.
   or Pyrazlnamide- 20-35 mg/kg/day (maximum 2.5 g).
   or Inj. streptomycin (I.M) - 1 g/day, if > 45 kg ; and 0.75 g/day, if < 45 kg.

'Initial phase' for 2 months with 1+2+3, and 'Continuation phase' for 7 months with 1+2.

(B) Short course chemotherapy **for 6 months** with four drugs regimen :

1. Rifampicin- 450 mg/day, If < 50 kg and aged; 600 mg/day, if > 50 kg.
2. INH (isoniazid)- 300 mg/day.
3. Ethambutol- 25 mg/kg/day.
4. Pyrazinamide- 20-35 mg/kg/day (maximum 2.5 g).

'Initial phase' for 2 months with 1 + 2 + 3 + 4, and 'Continuation phase' for 4 months with 1+2.

N.B.: If ethambutol has to be continued after 2 months for any reason (like rifampicin toxicity etc), the dose will be 15 mg/kg/day. Bone tuberculosis should be treated for 9 months while tuberculous meningitis should receive treatment for 1 year. All the drugs should be taken In empty stomach and In single dally dose. Pyridoxlne 10 mg/day may be added to prevent peripheral neuropathy induced by INH.

Corticosteroids in tuberculosis :

As steroids reduce inflammation and limit tissue damage, steroids are now recommended in patients with tuberculous affection of the following though opinion differs from clinician to clinician—

1. Pleural effusion.
2. Pericardial disease.

Nephrotic syndrome. Note the puffy and rounded face. Left eye is virtually closed by periorbital oedema due to posture-dependent nature of oedema

Scarring alopecia following bacterial folliculitis (inflammatory)

Chemotherapy-induced **non-scarring alopecia**

Hirsutism following prolonged corticosteroid therapy in bronchial asthma

Madarosis – loss of lateral third of eyebrows in myxoedema

Detection of clubbing by bringing patient's fingers at eye level and looking tangentially

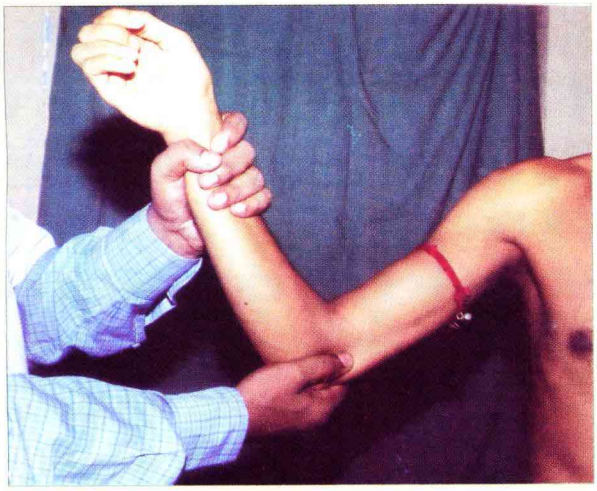

1 ›lpation of **epitrochlear lymph nodes** of right side

Detection of **direction of venous blood flow** – a sitting patient with legs hanging from bed and by selecting a tributory-free vein while the patient is performing Valsalva manoeuvre to make the veins more prominent

Palpation of **cervical glands** from behind using both hands

Palpation of **axillary lymph nodes** of left side

Detection of **sternal tenderness** – pressing the upper part of body of sternum with ball of the right thumb

3. Meningeal disease or CNS tuberculosis.
4. Endobronchial disease (specially in children).
5. Extensive pulmonary disease.
6. Genitourinary tuberculosis.
7. Ophthalmic disease.
8. Hypersensitivity antituberculosis drug reactions.
9. Laryngeal or adrenal tuberculosis.
10. Phlyctenular keratoconjunctivitis.

Steroids should always be given under cover of antituberculosis chemotherapy.

Common side-effects of antituberculosis drugs :

Rifampicin—Nausea, vomiting, red-orange urine, flu syndrome, hepatitis, vasculitis, thrombocytopenia.

INH Peripheral neuropathy, hepatitis, lack of mental concentration, psychosis, convulsions.

Ethambutol—Optic neuritis, arthralgia, hypersensitivity (rare).

Pyrazinamide—Hepatitis, anorexia, nausea, vomiting, gout, fever, rash.

Streptomycin—Giddiness, loss of renal function, deafness.

PAS—Nausea, vomiting, goitre, blood dyscrasia, hypothyroid, hepatic damage.

Thiacetazone—Exfoliative dermatitis, gastro-intestinal reactions, hepatitis.

Cycloserine—Depression, psychosis, headache, somnolence, convulsions.

Ethionamide or prothionamide—Nausea, jaundice, neuropathy, metallic taste in mouth.

Kanamycin, capreomycin, viomycin—Giddiness, loss of renal function, deafness.

* **First five drugs are 'first line drugs' and others are 'second line drugs'. First four drugs are first line essential drugs while streptomycin, rifabutin and rifapentine are first line supplemental drugs.**

** Other drugs are—Rifabutin, rifapentine, quinolones (ciproflxoacin, sparfloxacin), macrolides (clarithromycin, azithromycin), amikacin, phenazines (clofazimine), linezolid, co-amoxyclav, different immunomodulators (cytokine immunotherapy).

What is DOTS ?

Directly Observed Treatment Short course (DOTS) chemotherapy is the backbone of revised National Tuberculosis Control Programme (RNTCP) in India. It is the administration of potent antituberculosis regimens to a patient having tuberculosis, in an intermittent manner, under direct supervision. As poor adherence to therapy is responsible for prolonged illness, relapse and resistance, supervised therapy 2-3 times per week definitely improves compliance. For DOTS, the patients are divided into 3 categories (I, II and III). Read DOTS in details from any standard text book.

Prognosis of pneumothorax :

It depends on :

1. Type of pneumothorax (closed, open or tension).
2. Amount of air present (indicates mediastinal shifting).
3. Underlying disease (emphysema, COPD).

* *It* ***is important to remember that a large pneumothorax in a young individual may be less dangerous than a small pneumothorax in an aged patient with COPD.***

Conclusion :

1. Always look for puncture mark, benzene stain or cotton seal in the upper chest (anteriorly or axilla). If a tube or catheter is seen with water-seal drainage system, the diagnosis of pneumothorax is obvious (sometimes, a hydropneumothorax may be present with water-seal drainage).
2. Diminished or absent breath sound with tympanitic note on percussion on the affected side are **cardinal points for diagnosis** (there is loss of liver dullness in right-sided pneumothorax and loss of cardiac dullness in left-sided pneumothorax).
3. Search for shifting dullness in the chest to exclude hydropneumothorax in all cases of pneumothorax.
4. Remember, breath sound may be absent in both pneumothorax and pleural effusion, and in that case percussion note is the only guide (pneumothorax—tympanitic, pleural effusion—stony dullness) for diagnosis. Never forget that bronchial breath sound may be audible at the upper border of moderate pleural effusion as well as in case of open pneumothorax (bronchopleural fistula).

Case 10

HYDROPNEUMOTHORAX

What is your diagnosis ?

This is a patient of right-sided hydropneumothorax, probably of tuberculous in origin.

* Hydropneumothorax is collection of both fluid (lower part) and air (upper part) in the pleura) cavity.

What are the cardinal features of hydropneumothorax ?

The hallmark of diagnosis in hydropneumothorax are 3 'S' :

1. Shifting dullness,
2. Succussion splash, and
3. Straight (horizontal) fluid level (upper limit of dullness is horizontal).

Is there any other feature present ?

1. In a sitting patient, the percussion note over air-containing upper part is tympanitic, and fluid-containing lower part is stony dull.
2. Tinkling sounds or metallic crepitations (specially after coughing) heard by stethoscope in upper chest, and
3. Positive coin sound in upper chest (rare).

Why do you say hydropneumothorax ?

One of the common aetiology of hydropneumothorax in our day to day practice is secondary infection of an open type of pneumothorax, or sympathetic collection of fluid in closed or tension pneumothorax. Thus, the patient will have symptoms like,

a) Dyspnoea.
b) Pain chest.
c) Splashing sound during jolting.
d) Cough
e) Heaviness in the chest.
f) Pyrexia.

The physical signs in hydropneumothorax are more or less similar to pneumothorax. While eliciting the signs mentioned above, one should be careful about (to differentiate from pleural effusion),

(A) During percussion -

(i) There is horizontal fluid level (so called Ellis's S-shaped curve in pleural effusion, if any), and
(iii) Shifting dullness (absent in pleural effusion).

(B) During auscultation, one should search for **-**

(i) Amphoric breath sound (bronchial breathing)—as bronchopleural fistula is a common cause of hydropneumothorax (pleural effusion rarely may have bronchial breath sound),
(ii) Succussion splash (absent in pleural effusion),
(iii) Tinkling sounds (absent in pleural effusion), and
(iv) Positive coin sound in upper chest (absent in pleural effusion).

So, describe the symptomatology and signs with special reference to above points to prove the rationality of your diagnosis.

Aetiology of hydropneumothorax :

1. Rupture of a subpleural tuberculous focus or cavity (commonest cause).
2. Rupture of subpleural lung abscess (staphylococcal).
3. Chest injury (penetrating).
4. Acute pulmonary infarction.
5. Following cardiac surgery.
6. During aspiration of fluid in pleural effusion (iatrogenic).
7. Secondary infection of pneumothorax, specially after water-seal drainge.

* Actually No. 2 produces pyopneumothorax (pus and air), and No. 3 haemopneumothorax (blood and air).

How shifting dullness is elicited ?

Due to the presence of free fluid and air within the pleural cavity, dullness (fluid) shifts from one place to other with the change of posture of the patient (similar mechanism as ascites).

Clinical method :

1. In **sitting position** of the patient, percussion is done in the conventional method in anterior chest wall along the MCL. In hydropneumothorax, the lower part of the affected chest will be stony dull and the upper part tympanitic.
2. Now the percussion is done In **lying down position** when the fluid gravitates in the dependent part and the air comes in front. Percussion along the MCL in anterior chest wall in lying down position will elicit tympanitic resonance all over the anterior chest. So, the lower part of anterior chest which was dull on percussion in sitting position becomes tympanitic in lying down position, i.e.. dullness shifts.
3. The same manoeuvre can be done in the back (always after doing the percussion in sitting position) when the patient lies in prone position.

* Alternative method—Few clinicians follow this manoeuvre. First, percussion of the back in sitting position of the patient is done and the patient is then instructed to bend forward in the same sitting position. Percussing again in the back will reveal change of fluid level (which goes up) in forward bending position of the patient.

Demonstrate succussion splash (Hippocratic succussion) :

By the method of percussion, the upper border of dullness is detected in the lateral chest wall along the MAL, in sitting position of the patient. Now the diaphragm of stethoscope is placed on the air-fluid level and the patient is shaken from side to side vigorously. A splashing sound (like splashing sound of intact coconut) is audible with every jerk. Sometimes, the sound can be heard without the help of stethoscope (unaided ear, i.e., ear placed over the chest wall and the patient is shaken from side to side). The stethoscope may also be placed in the anterior or posterior chest wall at the air-fluid level to demonstrate succussion splash. Succussion splash in the chest is always pathological and is found in :

1. Hydropneumothorax or pyopneumothorax.
2. Herniation of stomach in the thorax.
3. Rarely, over a large cavity in the lung partially filled with exudate.

How to elicit the horizontal fluid level ?

This is classically found in hydropneumothorax. In sitting position of the patient, percussion is done from above downwards in the front (along MCL), lateral chest wall (along MAL) and back (along scapular line) in the conventional method. During percussion from above downwards, a point of dullness is reached in the front, lateral chest wall and back where markings are given by the skin pencil. These three points are joined transversely and a horizontal line is drawn encircling the affected chest wall. This is the upper horizontal border of fluid level.

N.B. : Ellis's S-shaped curve in pleural effusion does not exist today. Actually, it is a radiological observation (highest level of fluid in axilla). Previously the lesson was that the highest level of dullness (elicited by percussion) is present in axilla (so called Ellis's S-shaped curve) though it is not true. The upper limit of fluid in pleural effusion is horizontal like hydropneumothorax but it is not easily demonstrable.

In hydropneumothorax, the difference in the note of percussion (from above downwards, it is tympanitic to stony dullness) is very distinct and clear cut in comparison to pleural effusion (from above downwards, it is resonant note to stony dullness). So the term 'horizontal fluid level' is classically used in hydropneumothorax.

From which ICS, the axilla starts ?

The 4th intercostal space (ICS).

Surface marking of 'root or hilum of the lung' :

It is the space in between the spine and vertebral border of scapula opposite to T_4, T_5 and T_6 vertebrae on both sides. In health, bronchovesicular breath sound is audible here.

Purpose of percussion in clinical practice :

It is done to note the resonance or dullness of an organ, and also to know the :

1. Content (state of underlying tissue i.e., whether solid organ, fluid or gas is present),
2. Contour (topographical percussion), and
3. Depth (usually by percussion, we get an idea upto a depth of 2 inches).

* Percussion indirectly diagnoses tenderness (e.g., empyema thoracis, liver abscess).

** A lesion of < 2 cm diameter does not produce change in the percussion note.

Purpose of percussion over chest :

1. Conventional or general percussion,
2. Liver or cardiac dullness,
3. Coin percussion,
4. Shifting dullness,
5. Tidal percussion, and
6. Traube's space percussion.

Three cardinal rules of percussion :

1. Percuss from resonant to dull area, or more resonant to less resonant area.
2. Pleximeter finger should be placed parallel to the border of the organ to be percussed and the line of percussion should be perpendicular to that arbitrary border.
3. Heavy percussion for deeply placed viscera (e.g., upper border of liver) and light percussion for superficial viscera (e.g., lower border of liver).

* The art of respiratory medicine remains in performing 'percussion'. The method of percussion was first described by Leopold Auenbrugger (1722-1809) when he was a medical student.

How far you can go during conventional percussion in the chest ?

In the MCL, MAL and scapular line, the lower border of lung extends upto 6th rib, 8th rib and 10th rib respectively. The lower limit of pleura is present two-spaces downwards than the lung, i.e., at 8th rib, 10th rib and 12th rib respectively. These are true in a patient with quiet respiration.

So, conventionally one should percuss :

1. Along MCL - upto 7th ICS (the space just above the lower limit of pleura).
2. Along MAL - upto 8th ICS (upper border of spleen lies at 9th rib).
3. Along scapular line - upto 11th ICS (the space just above the lower limit of pleura).

Basic principles for conventional percussion over the chest :

1. The dorsal aspect of middle phalanx of the middle finger of left hand (the PLEXIMETER FINGER) is kept tightly over the chest wall (i.e., over intercostal spaces), and is struck suddenly with the tip of the middle finger of right hand (the PERCUSSING or PLEXOR FINGER) perpendicularly (with 'hammer effect')—mediate percussion. The entire movement is delivered from the wrist joint, and not from the elbow. Strike once or twice on the pleximeter finger (avoid repeated heavy striking). The other fingers of the left hand should not touch the chest wall.
2. Ask the patient to sit. Direct percussion is done over bones and indirect percussion for other areas. First percuss the clavicle (direct percussion) and then the anterior chest wall along MCL. The first palpable interspace in anterior chest wall is 2nd ICS. *Keep the hands by the side in resting position while percussing the anterior chest wall along MCL. During percussion of axilla along MAL, patient's hands are kept over his head. While percussing the back, cross the patient's hands over the knees or shoulders* (this position wide aparts the scapulae), and percuss in a bat's-wing or fish-bone pattern. Lastly, *percuss the apex of the lung from the back of the patient keeping the patient's hands by the side* (read Kronig's isthmus from page 84).
3. Always percuss from above downwards and compare the note on the identical site on the opposite side of chest. All the areas should preferably be percussed in sitting position of the patient.

* While percussing the left side of anterior chest wall, always follow the left MCL (do not deviate laterally, because the most outer border of cardiac dullness lies 1/2 inch inside the left MCL). One may start percussion from apparently healthy side, or the right side of the chest (if it is not possible to detect the diseased side from history). Use light percussion for anterior chest and heavy percussion for posterior chest. Never percuss over ribs.

Format of percussion over the chest :

(A) Anterior chest wall :

1. Over the clavicle (direct percussion)
2. Infraclavicular area (clavicle to 3rd rib)
3. Mammary area (3rd to 6th rib)
4. Inframammary area (6th rib to 7th ICS).

Both the sides of the chest should be percussed with special reference to—

Right side

1. Conventional percussion
2. Shifting dullness
3. Liver dullness
4. Coin percussion
5. -

Left side

1. Conventional percussion
2. Shifting dullness
3. Cardiac dullness
4. Coin percussion
5. Traube's space percussion

(B) Lateral chest wall (right and left side)
  1. Axillary area (4th ICS to 6th rib)
  2. Infra-axillary area (6th rib to 8th ICS or lower costal margin)

(C) Posterior chest wall (right and left side) :
  1. Suprascapular (above the upper border of scapula)
  2. Interscapular (between the medial border of scapula and spine->T_2 to T_7 vertebrae->in a ■fish-bone pattern' percussion)
  3. Infrascapular (below the inferior angle of scapula->T_7 to T_n vertebrae).

(D) Apical (or supraclavicular area) : always done from the back (read "Kronig's isthmus")—right and left side.

How to count the ribs and ICS in clinical practice ?

First place the right index finger in the suprasternal notch and then go downwards till the **sternal angle** (angle of Louis) is felt as a transverse bony ridge (junction of the body of the sternum and manubrium sterni). If the finger is moved sideways, it will touch the 2nd ribs. Now count the ribs with ICS from above downwards.

Posteriorly, the ribs and ICS are counted from below upwards (difficulty faced in a muscular body or in an obese patient). If the arms rest by the side of the body, the inferior angle of scapula lies at the level of T_y vertebra (or the 7th rib) — this may be of some help in counting ribs or ICS in the back.

* **Angle of Louis** or sternal angle (i.e., the level of 2nd costal cartilage) corresponds with the disc space between T_4 and T_s vertebrae posteriorly, and anteriorly it is the landmark for tracheal bifurcation.

Traube's semilunar space and its importance :

This is a triangular space or semilunar topographic area in the left lower chest anteriorly which is bounded by,

Laterally - Left midaxillary line

Above - Left dome of diaphragm and left lung i.e., the 6th rib.

Below - Left lower costal margin.

Detection : The triangle is percussed during normal breathing across one or more level from its medial to lateral margin, i.e., from xiphistemum to left midaxillary line across 6th and 7th intercostal space (Barkun's method).

Importance : Normally the space is tympanitic on percussion as **it contains the fundus of the stomach.** The tympanicity of Traube's space (after Ludwig Traube) is lost in :

a) Carcinoma involving the fundus of the stomach or full stomach.
b) Left-sided pleural effusion.
c) Enlarged left lobe of liver.
d) Massively enlarged spleen or ruptured spleen.
e) Situs inversus totalis (Traube's space is present on the right side).
f) Achalasia cardia (often the fundal gas is absent).

* Traube's space is shifted upwards in fibrosis or collapse of the left lower lobe of lung and left-sided diaphragmatic palsy.

** Traube's space tympanicity is retained in pericardial effusion.

Shifting of upper border of liver dullness :

To delineate the upper border of liver dullness, percuss the anterior chest wall along right MCL from above downwards. Normally the **upper border of liver dullness is present in right 5th ICS at MCL.**

(A) Lowered or obliterated :
  1. Emphysema.
  2. Pneumothorax (right-sided).
  3. Perforation of abdominal hollow viscus e.g., perforation of peptic ulcer.
  4. Chilaiditi's syndrome (interposition of colon between liver and diaphragm—an anatomical variation).
  5. Cirrhosis of liver (liver becomes small).
  6. Visceroptosis of liver.

(B) Elevated :

1. Amoebic or pyogenic liver abscess.
2. Subdiaphragmatic abscess (right).
3. Diaphragmatic palsy (right).
4. Pleural effusion (right).
5. Basal pneumonia (right).
6. Increased intraabdominal tension due to ascites or pregnancy.

* The upper border of liver dullness is present in right 7th and 9th ICS when percussed along midaxillary and scapular line respectively.

Where do you beat in clavicular percussion ?

It is a **direct percussion** (clavicle acts as pleximeter finger) done by right middle finger,

(i) Over the most prominent part of clavicle, or

(ii) Over the medial 1/3 rd of the clavicle, just lateral to its expanded medial end.

During percussion, stretch the overlying skin downwards with the left thumb so that the percussing finger does not slip over the clavicle. It is a light percussion. Few clinicians advise to place pleximeter finger over clavicle to reduce pain while percussing.

What is tidal percussion ?

While percussing during delineating the lower border of lung, there is difference in resonance by one space in full inspiration. It happens to be due to the downward movement of diaphragm. Today, this method has little practical value and is only of historical interest.

Method :

The patient will sit with hands crossed over the knees or shoulders. First **percuss the lower** back along the scapular line at the end of forced expiration and then percuss the same place at the height of full inspiration. Note the increase in resonance by one space after full inspiration.

Clinical importance :

1. Paradoxical resonance i.e., there is dull note on inspiration and resonant note on expiration due to paradoxical movement of diaphragm in diaphragmatic palsy.
2. Dullness which does not change on inspiration or expiration indicates basal pneumonia, basal pleurisy or subdiaphragmatic abscess.

What is Kronig's isthmus ?

It is a small area (a band of resonance of 5-6 cm width, connecting the lung resonance on the anterior and posterior chest on each side) in the apex of the lung (supraclavicular area) which is bounded,

Medially—By neck muscles, and laterally—By the ipsilateral shoulder joint.

Anteriorly—By the clavicle, and posteriorly—By the trapezius muscle.

Kronig's isthmus is elicited by percussion over the apex of the lung (percussion done from the back of the patient), where the note is normally resonant. The area becomes dull on percussion in the presence of apical tuberculosis, Pancoast's tumour or apical pneumonia. *The pleximeter finger should be placed over the supraclavicular fossa, across the anterior border of trapezius, perpendicular to the clavicle.*

What is percussion myokymia ?

In some chronic wasting diseases e.g., pulmonary tuberculosis, if a light tap is applied over the chest (on the sternum or near the sternum), it may produce transient twitching of pectoral muscles as a result of undue irritability. This phenomenon is also known as 'myotatic irritability'.

Diagnosis of diaphragmatic palsy :

Unilateral paralysis is more common than bilateral paralysis. Unilateral paralysis commonly results from tumour (bronchogenic carcinoma), birth injury, surgery or trauma to the mediastinum. Bilateral paralysis may occur due to,

a) High cervical cord injury.

b) Motor neurone disease.

c) Poliomyelitis.

d) Demyelinating disease.
e) Polyneuropathies (e.g., G.B. syndrome).
f) Bilateral involvement by mediastinal lesions.

Diaphragmatic palsy is diagnosed by :

1. Dyspnoea in supine posture.
2. Abdominal movement is less in comparison to thoracic movement.
3. As a whole the respiratory excursions in chest are diminished.
4. Tachypnoea may be present with intercostal suction.
5. **Paradoxical respiration** — Depression of abdomen with inspiration, and elevation with expiration. It is best observed in unilateral palsy and is known as 'see-saw movement' of abdomen.
6. Tidal percussion (see above).
7. Counting sign — Patient can not count aloud upto 10 in one breath (sometimes, it is seen that COPD patients can not count upto 20 in one breath; often it is observed that patient of myasthenia gravis starts counting normally but the voice becomes unintelligible after crossing 10).
8. Litten's sign — Absence of indrawing of subcostal margin during inspiration.
9. Elevated hemidiaphragm in chest X-ray which is confirmed by fluoroscopy.
10. **Sniff test** (diagnostic on fluoroscopy) — When the patient is asked to sniff, there is upward motion of the affected hemidiaphragm (the unaffected diaphragm descends). Sniff test can also be confirmed by USG.

* Patient with diaphragmatic palsy will have difficulty in sniffing—a rough test for integrity of diaphragm. Bilateral diaphragmatic palsy is a cause of sleep apnoea. Treatment is done by diaphragmatic pacing or nighttime assisted ventilation.

Put your hand over lower lobe of left lung :

Place your hand in the lower part of back of the chest on left side. Actually when seen **from behind,** mainly the lower lobes are seen while a small area near the apex is occupied by the upper lobes. When seen **from front,** the upper and middle lobes on the right, and the upper lobe on the left side occupy the most. When seen **from sides** (axillary region), parts of all the lobes are accessible.

Absent shifting dullness in hydropneumothorax : is it possible ?

Shifting dullness is absent in loculated or encysted variety of hydropneumothorax. A case with small air and large fluid, or large air and small fluid may not have shifting dullness.

Diagnosis of pyopneumothorax developed from hydropneumothorax :

1. Patient will be toxic and prostrated; loss of weight.
2. Hectic rise of temperature with rigors and sweating.
3. Tachycardia as well as tachypnoea.
4. Intercostal tenderness and tenderness on percussion (patient winces with pain).
5. Skin is red, oedematous and glossy over lower part of affected chest.
6. Development of clubbing, plus
7. Signs of hydropneumothorax.

D/D you will consider in your case :

1. Pyopneumothorax.
2. Pleural effusion.
3. Herniation of stomach in the thorax.
4. A large lung abscess partially filled with exudate.

Clinical differentiation between pleural effusion and hydropneumothorax :

Theoretically there may be many differences but basic bedside dissimilarities are :

Pletiral effusion :

1. Percussion note above the fluid level—Skodaic resonance.
2. Shifting dullness—Absent.
3. Coin sound in upper chest—Absent.

4. Succussion splash—Absent.
5. Classical horizontal fluid level—Present but difficult to demonstrate.
6. Breath sound and vocal resonance—Commonly diminished vesicular breath sound with diminshed vocal resonance is audible though bronchial (tubular) breath sound, bronchophony and whispering pictoriloquy may be heard at the upper border of moderate effusion.

Hydropneumo thorax :

1. Percussion note above the fluid level—Tympanitic.
2. Shifting dullness—Present.
3. Coin sound in upper chest—May be present.
4. Succussion splash—Present.
5. Horizontal fluid level on percussion—Easily demonstrated.
6. Diminished vesicular breath sound with diminished vocal resonance at the upper border of fluid level. There may be bronchial (amphoric) breath sound in bronchopleural fistula.

How do you like to investigate this case ?

The investigations will be done in the line of both pleural effusion and pneumothorax already described but the X-ray features will be different in hydropneumothorax.

Chest X-ray (PA view) in **erect posture** shows :

1. Horizontal fluid level on right chest.
2. Increased radiolucency above the horizontal level which is lacking in lung markings Cpneumo' component) and a homogeneous opacity below the horizontal level ('hydro' component).
3. Shifting of trachea and cardiac shadow towards the left side.
4. The left lung shows wooly opacities in apex (i.e., apical tuberculosis).

   It is worthwhile to remember that in erect posture, the fluid remains below and the air above. The collapsed lung is usually hidden within the fluid and is not visible in X-ray (rarely, collapsed lung is visible paravertebrally).

Blood (R/E). sputum examination and Mantoux test are done routinely.

How will you manage a patient of hydropneumothorax ?

1. Intercostal tube drainage through water-seal drainage system is applied as done in pneumothorax. The catheter is introduced in the ***dependent part*** in such a way that fluid can come out through the tube (special tube with multiple perforations like 'Romodrain') and the air is absorbed or expelled in due course of time.
2. Antituberculosis chemotherapy,
3. Proper antibiotics (in case of pyopneumothorax).
4. Surgery in resistant cases with pyo- or haemopneumothorax.

Management of empyema thoracis :

Diagnosis of empyema is made by clinical features, radiology (similar to pleural effusion) and aspiration of pus by a wide-bore needle through an intercostal space over the area of maximum dullness. Then bacteriological examination of pus is done accordingly.

(A) Treatment of non-tuberculous empyema :

a) Acute —
   (i) Intercostal tube drainage through water-seal drainage system.
   (ii) Proper antibiotic after sensitivity test (arbitrary use may produce resistance).
   (iii) If pus is very thick, rib resection and clearing of empyema cavity is done; a wide bore tube helps in prolonged drainage.

b) Chronic — it is the domain of thoracic surgeon.
   (i) Resection of empyema sac in toto (if the underlying lung is healthy).
   (ii) Thoracotomy and decortication of pleura (in patients with thickened pleura). Decortication means stripping of the whole of the thickened visceral pleura.

(B) Treatment of tuberculous empyema :

a) Antituberculosis chemotherapy.
b) Repeated drainage of pus through a wide-bore needle or tube-drainage.
c) Rarely, surgery is necessary.

Case 11

CONSOLIDATION OF THE LUNG

What is your diagnosis ?

This is a case of consolidation of the lower lobe of left lung.

Why do you say so ?

This patient is suffering from consolidation because there is presence of :

(A) SYMPTOMS (from the history) —

a) High fever with chill and rigor, malaise and headache for 5 days.
b) Pain on the left side of chest, and dyspnoea for 3 days.
c) Harassing dry cough for 2 days.

(B) SIGNS —

1. General survey :

a) Patient looks toxic and ill, but conscious and co-operative at present.
b) Decubitus — Propped-up at 45°.
c) Cyanosis—Absent at present.
d) Respiration—42/min, regular and predominantly abdomino-thoracic in type.
e) Pulse — 86/min, regular (describe other points in pulse).
f) Pulse : Respiration—2 : 1
g) Herpes labialis—Present on left side.
h) Temperature (oral)—100°F at present.
i) Neck stiffness—Absent (to diagnose meningism).

2. Inspection :

a) Upper respiratory tract reveals no abnormality.
b) Absence of intercostal suction but accessory muscles of respiration are working.
c) Absence of fullness or flattening of chest wall anywhere.
d) Apical impulse—Seen below the left nipple, approximately 3" lateral to midline.
e) Diminished movement on left side of chest, mainly the lower part of back and lateral aspect of chest.

3. Palpation :

a) Restricted movement on left side of chest.
b) TRACHEA AND APEX BEAT ARE NORMAL IN POSITION (I.E., NO MEDIASTINAL DISPLACEMENT).
c) Vocal fremitus—Increased on left side (lower part of lateral aspect and back mainly).
d) Friction fremitus—Present in lower part of back, on the left chest.

4. Percussion :

Woody dullness on left side of chest (lower part), mainly at the back and lateral aspect. The outline of woody dullness is irregular and limited.

5. Auscultation :

All the positive findings are present mainly on the left base (left infrascapular region).

a) Tubular breath sound (high-pitched bronchial).
b) Increased vocal resonance—Bronchophony and whispering pectoriloquy.
c) Aegophony.
d) Pleural rub
e) Absence of rhonchi and crepitations (as lung is solidified and liquefaction has not started yet).

* The right lung seems to be normal clinically. Characteristic rusty sputum may not be found.

** The surface marking of the dullness in consolidation and collapse follows the distribution of affected lobe which is not seen in pleural effusion.

*** The involvement of lung in acute bronchopneumonia is usually patchy, bilateral and more widespread in lower lobes.

**** 'Consolidation' i.e., pneumonia is exudative solidification of lung parenchyma (alveoli).

Why do you say consolidation of the lower lobe ?

The signs are predominantly present in the back and at basal region.

Pathological 'stages of pneumonia' with auscultatory findings :

(A) Stage of hyperaemia or congestion : Diminished vesicular breath sound with fine crepitations (indux crepitations) — 24-48 hours.

(B) Stage of 'Red Hepatisation' (2-4 days) : \

(C) Stage of Grey Hepatisation (4-8 days) : J TT .. ,. , „ , , f Classical features of consolidation described above

(D) Stage of resolution : Breath sound is vesicular or rarely bronchovesicular in type. Coarse crepitations are heard (redux crepitations) —2-3 weeks.

* Respiratory symptoms and signs in consolidation are often absent in elderly, alcoholic, immunocompromised or neutropenic patients.

Classification of pneumonia :

Pneumonia (synonym : pneumonitis) is defined as acute inflammation of the lung parenchyma.

(A) Main classification : *

1. 'Primary' pneumonia (Streptococcus pneumoniae [most common], Staphylococcus aureus, Haemophilus influenzae, Klebsiella pneumoniae etc.)—Usually community-acquired (in normal healthy Individuals).
2. 'Secondary' pneumonia (occurs when the host is weakened) —
   - (i) Acute bronchopneumonia, acute lobular or hypostatic pneumonia.
   - (ii) Benign aspiration pneumonia.
   - (iii) Suppurative or necrotislng pneumonia (lung abscess)—Commonly by Staphylococcus aureus and Klebsiella pneumoniae.
   - (iv) Hospital-acquired pneumonia (nosocomial).
   - (v) In immunocompromised host (Pneumocystis jiroveci infection in AIDS).

* Lung abscess may be a part of 'primary' pneumonia.

(B) Empiricist's classification (most commonly used) :

1. Community-acquired pneumonia (Streptococcus pneumoniae, Haemophilus influenzae).
2. Hospital-acquired pneumonia (nosocomial)—Mainly by aerobic gram-ve bacilli, anaerobes.
3. Pneumonia in immunocompromised host—Pseudomonas aeruginosa, Pneumocystis jiroveci.

(C) Anatomical classification :

1. Lobar.
2. Lobular (bronchopneumonia, if bilateral).
3. Segmental (benign aspiration pneumonia).

(D) Aetiological classification :

1. Infective—Bacterial, viral, rickettsial, yeast and fungi, protozoa (Pneumocystis jiroveci).
2. Chemical agents—Irritant gases, aspiration of vomitus, kerosine oil etc. (kerosine oil produces 'lipoid pneumonia').
3. Physical agents—Irradiation.
4) Hypersensitivity reaction—SLE, Stevens-Johnson syndrome, Loeffler's syndrome.

(E) Radiological classification :

1. Alveolar or air space pneumonia (pneumococcal mainly)— air bronchogram in chest X-ray.
2. Bronchopneumonia (Haemophilus influenzae etc.)— atelectasis is seen in chest X-ray.
3. Interstitial (virus, mycoplasma etc.)—Reticular or reticulonodular pattern in chest X-ray.

(F) Behaviorist's classification : 1. Easy, and 2. Difficult : non-resolving.

* Now-a-days, ventilator-associated pneumonia (VAP) with MDR and non-MDR pathogens pose problem in treatment (MDR = multiple drug resistance).

Characteristics of viral pneumonia :

1 Constitutional symptoms like anorexia, headache, myalgia, malaise are predominant (commonly due to influenza, parainfluenza and respiratory syncytial virus). Fever and toxaemia usually precede respiratory symptoms.
2. Cough may be absent initially and sputum is mucoid in nature.
3. Haemoptysis, pleuritic chest pain and pleural effusion are rare.
4. **Spleen may be palpable** in the first week; tachypnoea may be absent.
5. **Paucity** of **physical signs** in chest but may develop later and seldom gross.
6. WBC count is usually normal.

7. X-ray—Usually do not correspond to lobes or segments, which is typical of consolidation. Reticular or reticulonodular patterns may be seen.
8. Failure of rapid resolution or response with antibiotics.

Absence of physical signs of consolidation in lobar pneumonia : is it possible ?

Yes. The possibilities are :

1. Deep seated consolidation.
2. Associated pleural effusion or empyema thoracis.
3. When the bronchus is not patent (exudate fills the bronchus along with the alveoli) — As seen in 'massive pneumonia' caused by Klebsiella pneumoniae (Friedlander's pneumonia).

* Sometimes in hypostatic pneumonia, the classical signs of consolidation are lacking.

What is massive consolidation ?

It is the consolidation involving more than one lobe.

Appearance of physical signs of consolidation :

Usually appear within 2 days.

Usually disappear within 2 weeks.

Appearance of radiological signs of consolidation :

Opacity in X-ray appears within 12-18 hours of the onset of illness.

Radiological opacity usually disappears within 4 weeks.

How to suspect development of effusion with pneumonia ?

Development of effusion with pneumonia is known as 'synpneumonic' pleural effusion. When the effusion appears after resolution of pneumonia, it is called 'postpneumonic' pleural effusion. Together, they are known as 'parapneumonic effusion'. These terms are going to be obsolete now-a-days.

Persistence of fever, stony dullness on percussion and shifting of mediastinum make the clinician suspicious about the development of pleural effusion. Radiology (obliteration of costophrenic angle in chest X-ray) further supports the diagnosis.

Causes of 'delayed resolution' of pneumonia : ■

Delayed resolution means when the physical signs persist for > 2 weeks and the radiological features persist for > 4 weeks after proper antimicrobial treatment. The possibilities are :

1. Inappropriate chemotherapy like incomplete treatment, suboptimal dose, wrong choice of antibiotics, drug resistance, irregular intake of drugs.
2. Complicated by pleural effusion, suppurative pneumonia or empyema thoracis.
3. Decreased host resistance like diabetes mellitus, chronic alcoholism, agranulocytosis, lymphoma, leukaemia, multiple myeloma, corticosteroid therapy, hypogammaglobulinaemia, AIDS etc; elderly and debilitated patient.
4. Tuberculous pneumonia (needs specific antituberculosis chemotherapy).
5. Partial obstruction of bronchus by a foreign body like dentures in the elderly or ***bronchogenic carcinoma*** (common in clinical practice).
6. Fungal or atypical pneumonia.
7. Pneumonia resulting from connective tissue diseases, pulmonary infarction etc.
8. Recurrent aspiration in achalasia cardia.

* Common causes of 'non-resolution' of pneumonia are inappropriate chemotherapy, bronchogenic carcinoma, diabetes mellitus or pneumonia caused by virulent organism (e.g., staphylococcal pneumonia).

Possible causes of recurrent pneumonia :

Chronic bronchitis, SLE, multiple myeloma, diabetes, AIDS, recurrent aspiration in achalasia cardia or pharyngeal pouch or scleroderma, bronchiectasis, bronchogenic carcinoma, cystic fibrosis, sequestration of the lung or foreign body aspiration.

Is it possible to have shifting of trachea to the same side in pneumonia ?

In pneumonia, trachea remains in the midline. Rarely, there may be same-sided shifting of trachea in massive pneumonia producing 'collapse consolidation" (may be from bronchogenic carcinoma).

Predisposing factors to pneumonia :

1. Cigarette smoking (strongest independent risk factor).

2. Upper respiratory tract viral infection, followed by streptococcus pneumoniae infection.
3. Excess of alcohol.
4. Immunosuppression.
5. I.V drug abusers.
6. Bronchial obstruction (malignancy), bronchiectasis.
7. Old age.

When will you advise hospitalisation in a patient of pneumonia ?

Hospitalisation is advised in :

1. Elderly patients (over 60 years of age) and with,
2. Severe dyspnoea with hypoxia (tachypnoea with respiratory rate > 30/min).
3. Central cyanosis.
4. Fall of diastolic BP (< 60 mm of Hg.).
5. Empyema, meningism, meningitis.
6. Altered mental status, delirium.
7. Shock.
8. Underlying serious cardio-pulmonary diseases, diabetes mellitus, uraemia.
9. Hypoxia ($Pa0_2$ < 60 mm of Hg), leucopenia (< 4000/mm^3) or leucocytosis (> 20000/mm^3 e.g., in empyema), high blood urea or culture +ve pneumonia.

* The patient is reffered to ITU (Intensive Therapeutic Unit) in No. 6, 7, 8, 9 and severe acidosis.

What are the accessory muscles of respiration ?

Normal muscles of respiration are intercostals (external and internal) and diaphragm. Accessory muscles are not required for respiration in health; they are required to assist breathing in respiratory embarrassment, and may therefore be active and prominent. They are :

1. Alae nasi (nasal flare).
2. Sternomastoid.
3. Scalenii.
4. Latissimus dorsi.
5. Trapezius.
6. Pectoralis major.
7. Serratus anterior.
8. Abdominal muscles.

Common causes of 'intercostal suction' :

Normally intercostal spaces expands and draw-out in inspiration. It is the drawing-in of the inter-costal spaces with inspiration and is commonly seen in,

1. Foreign body within larynx or trachea.
2. Diphtheria.
3. Oedema of the glottis (in anaphylaxis).
4. COPD.
5. Bronchiolitis (in infants and children).
6. Bilateral diaphragmatic palsy.

* Produced as a result of positive atmospheric pressure pressing the lower intercostal spaces in the face of negative intrathoracic pressure due to failure of air entry in respiratory tract.

What are the D/D you will consider in your case ?

(A) Pleural effusion ;
- a) Gradual onset.
- b) Dry cough may be present; patient does not look toxic.
- c) **Mediastinal shifting to opposite side, stony dullness on percussion.**
- d) Diminished vesicular breath sound or absent breath sound with diminished or absent vocal resonance. Usually there is no added sound.

(B) Collapse of the lung :
- a) Cause is detected from the history e.g., aspiration, trauma, post-operative events etc.
- b) Patient does not look toxic.
- c) **Mediastinal shift is towards the affected side** with flattening of chest wall and aggregation of ribs.
- d) Impaired resonance on percussion.

(C) Bronchogenic carcinoma :
- a) Age is higher; male, smoker commonly.
- b) Clubbing.
- c) Cervical lymphadenopathy.
- d) Emaciation.
- e) **Usually no shifting of mediastinum unless complicated by pleural effusion.**
- f) Localised crepitations over the mass.

(D) Pulmonary tuberculosis :
- a) Gradual onset of weight loss, anorexia, evening rise of temperature, night sweats.
- b) Physical signs are mainly present in apical region, if there are any.
- c) Absence of high rise of temperature or rigor.
- d) Classical signs of consolidation are absent.

(E) Pulmonary infarction (thromboembolism) :
- a) Sudden onset of chest pain with dyspnoea.
- b) Pyrexia is usually less.
- c) There may be evidence of thrombophlebitis in legs.
- d) Cough is not troublesome.
- e) Patient is not toxic.
- f) Heamoptysis is much more common.

Causes of haemoptysis :

(A) Pulmonary :
1. Bronchitis (acute and chronic).
2. Plumonary tuberculosis.
3. Bronchiectasis.
4. Lung abscess.
5. Bronchogenic carcinoma.
6. Pneumonia.
7. Pulmonary thromboembolism.
8. Lupus pneumonitis (i.e., from SLE)
9. Foreign body in bronchus or lung.

(B) Cardiovascular :
10. Mitral stenosis.
11. Acute left ventricular failure.
12. Primary pulmonary hypertension.
13. Eisenmenger's syndrome.

(C) Coagulation disorder :
14. Haemorrhagic diathesis (leukaemia, haemophilia).
15. Anticoagulant therapy.

(D) Miscellaneous :
16. Vasculitis (Wegener's granulomatosis).
17. Arteriovenous malformation.
18. Trauma.
19. Aspergilloma ('fungus ball').
20. Goodpasture's syndrome.
21. After bronchoscopy/lung biopsy.
22. Systemic hypertension.
23. Pulmonary haemosiderosis.
24. Hydatid disease of lung.
25. Idiopathic.

* No 1, 2, 3, 5, 6, 10 are common causes of heamoptysis. Worldwide, chronic bronchitis is possibly the commonest cause of haemoptysis. Recurrent haemoptysis is commonly due to chronic bronchitis, bronchiectasis, bronchogenic carcinoma and pulmonary thromboembolism. Sources other than lower respiratory tract like nasopharyngeal bleeding or laryngeal carcinoma may be a cause of haemoplysis.

What is massive haemoptysis ?

Variably defined as coughing out of blood of > 100-600 ml/24 hours is 'massive' one and potentially lethal due to combined effect of blood loss as well as asphyxia.

Table 5 : Bedside differentiation between haemoptysis and haematemesis

	Features	Haemoptysis	Haematemesis
1.	Definition	Coughing out of blood	Vomiting out of blood
2.	Symptoms	Symptoms of pulmonary and CVS diseases	Symptoms of upper G.I. tract diseases
3.	Content and colour	Blood is mixed with sputum; bright red in colour and 'frothy' from admixture of air	Blood is mixed with food particles, may be coffee-ground in colour
4.	Premonitory Symptoms	Premonitory symptoms like cough, salty sensation or tickling sensation in throat	Nausea, vomiting, retching, fainting, abdominal discomfort, perspiration
5.	Melaena	Melaena does not occur (very rarely may occur, if blood is ingested)	Usually followed by melaena on the next day
6.	Amount	Relatively less; shock is rare	Huge in amount; patient may be in impending shock
7.	Reaction	Alkaline (blue litmus remains unchanged)	Acidic (blue litmus turns red)

Special signs in a 'cavity' within the lung :

Pulmonary cavity is an area of liquefaction necrosis within the lung (may remain empty or filled with secretion) and is usually communicating with a patent bronchus.

1. Post-tussive crepitations (crepitations evoked by coughing).
2. Post-tussive suction (high-pitched sucking sound audible during the phases of long inspiration following a bout of cough)—Hallmark sign of a thin-walled superficial, compressible cavity connected with the patent bronchus.
3. Cracked-pot sound by percussion over (a tympanitic note) empty communicating cavity (mimics the sound produced by percussion over a cracked pot).

Findings over a superficial, big, empty cavity connected with a patent bronchus :

1. Slight reduction in chest movement on affected side.
2. Absence of mediastinal displacement.
3. Increased vocal fremitus.
4. Percussion—Hyperresonant or tympanitic note when filled with air (empty); impaired note when filled with exudate.
5. Cavernous breath sound (low-pitched bronchial) with bronchophony and whispering pectoriloquy.
6. Coarse crepitations (specially when filled with exudate); may be post-tussive.

* Physical signs are absent in deep-seated cavity.

Common causes of pulmonary cavity :

1. Pulmonary tuberculosis (commonest), anaerobic infection in lung (lung abscess).
2. Lung abscess.
3. Necrotic degeneration of bronchogenic carcinoma (i.e., cavitating lung cancer).
4. Bronchiectasis.
5. Pseudocavity in large emphysematous bulla or lung cyst.
6. Wegener's granulomatosis, rheumatoid arthritis, pulmonary infarction, fungal cavity.

Vocal resonance (voice sounds) and its classification :

(A) DEFINITION:

This is the auscultation of laryngeal vibrations transmitted to the chest wall and nothing but the auscultatory homologue of vocal fremitus.

(B) METHOD OF ELICITATION :

1. The patient will repeat 'one, one' or 'ninety-nine, ninety-nine'.
2. The patient will speak in a constant tone and voice (the depth and intensity of voice remaining the same); the voice should be clear.
3. Both sides of the chest are auscultated area by area, **comparing with the corresponding site on the other side.** Auscultation starts from above downwards in the front, sides and back of the chest.
4. It is better to start from the apparently healthy side. Do not auscultate over clavicle, sternum and scapula.

(C) Classification :

I) Quantitative change —

1. Diminished — Pleural effusion, pneumothorax, hydropneumothorax, thickened pleura, fibrosis of the lung, collapse with obstructed bronchus, emphysema etc.
2. Increased —

(1) **Bronchophony** — Seems to appear from the ***earpiece of stethoscope.***

(ii) **Whispering pectoriloquy** —

a) Patient whispers.

b) Increased sound is heard clearly or distinctly, i.e., syllable by syllable (pectoriloquy).

c) It seems to be spoken right into the ***auscultator's ear.***

Bronchophony and whispering pectoriloquy are classically heard over consolidation. It is

also heard in collapse with patent bronchus, over a superficial empty cavity, sometimes above the level of pleural effusion, and in an open pneumothorax.

II) Qualitative change —

Aegophony — This is a qualitative change in vocal resonance with nasal intonation mimicking the bleating of a goat. It is classically found over consolidation and sometimes, above the level of pleural effusion. Though the speech remains intelligible, the removal of low-pitched elements of the sound explains the nasal bleating quality of aegophony (i.e., there is selective transmission of high-pitched components of the sound).

* The mechanism of production of quantitative increase in vocal resonance and that of bronchial breath sound is same, and naturally both are present in a single patient.

What is normal vocal resonance :

1. The sound seems to be produced at the ***chest piece of stethoscope,***
2. Heard as indistinct rumble, and
3. Individual syllables are indistinguishable.

Complications of pneumonia :

(A) Pulmonary :

1. Delayed resolution.
2. Lung abscess or cavitation.
3. Pleural effusion.
4. Empyema thoracis.
5. Pyopneumothorax.
6. Pneumatocele.*
7. Fibrosis of the lung, rarely.
8. Respiratory failure.

(B) Neurological :

1. Mental confusion.
2. Meningism.
3. Meningitis.
4. Cerebral abscess.

(C) CVS :

1. Myocarditis.
2. Endocarditis.
3. Pericarditis.
4. Peripheral circulatory failure.

(D) G. I. tract : Meteorism (distended tense abdomen), hepatitis.

(E) Musculo-skeletal : Septic arthritis.

(F) Septicaemia, herpes labialis, thrombophlebitis, uraemia, ARDS, multi-organ failure.

* Multiple thin-walled cystlike lesions in staphylococcal pneumonia.

What is atypical pneumonia ?

There is a group of pneumonia which do not behave like lobar pneumococcal pneumonia (typical pneumonia) and do not respond to penicillin. This type of 'atypical' pneumonia is not severe and is caused by Chlamydia psittaci (psittacosis), Coxiella burnetii (Q fever), Legionella pneumophila and Mycoplasma pneumoniae. Predominent features are diy cough, constitutional sympfoms, abnormality in chest X-ray inspite of lack of physical signs in chest.

How will you investigate pneumonia ?

1. Blood examination — TC, DC and ESR. TC shows polymorphonuclear leucocytosis. Persistence of leucocytosis signifies lung abscess or empyema formation, and absence of leucocytosis carries a bad prognosis (atypical pneumonia). Toxic granulation within the neutrophils may be present in bacterial pneumonia. ESR tends to be high. Blood culture may be helpful.
2. Sputum examination :
   (i) For identification of organism, and
   (ii) Detection of sensitivity to antibiotics.

   — Always an attempt should be made to establish a microbiological diagnosis, if possible. Administration of nebulised hypertonic saline often helps in expectoration. Many a time false positive results come out (non-pathogenic organism from oropharynx). In our country, sputum should always be examined for identification of AFB. So, smear examination of sputum by both Gram and Ziehl-Neelsen stains, and culture and sensitivity test of sputum should be done.

3. X-ray chest (PA and lateral view)—This is helpful for confirmation of diagnosis. Homogeneous opacity is seen involving segments, part of a lobe or lobes of lung. Rarely, reticular patterns may be seen (viral, Mycoplasma pneumoniae). Pleural effusion or empyema may be present. Follow-up X-ray after 7-10 days is important to assess the response to therapy and for diagnosis of development of any complication.

   Sites of lung involvement in pneumonia are as follows—Right lung is involved more because of its continuity with the trachea; apical area is affected more in tuberculosis or Klebsiella pneumoniae infection; basal segments of lower lobes in sitting-up position, and posterior segment of upper lobe and superior segment of lower lobe are mostly affected in a recumbent patient.
4. Blood culture—Sometimes this is done in severe pneumonia, specially when the sputum examination is negative. PCR tests are available for a number of pathogens.
5. Serological tests—For the diagnosis of Mycoplasma pneumoniae, Coxiella burnetii, Legionella pneumophila or viral infections; a four-fold rise in antibody titre repeated after 10 days suggests a recent infection. Pneumococcal antigen can be detected in pneumococcal pneumonia.
6. Nose and throat swabs—May be cultured for viruses or examined under electron miscroscope.
7. Pleural fluid—If there is formation of parapneumonic effusion, the fluid may be aspirated for microbiological examination.
8. Pulmonary function test (PFT) and arterial blood gas analysis (ABG)—Usually hypoxia with hypocarbia is seen (type I respiratory failure). It is done in the management of seriously ill patients in anticipation of assisted ventilation.
9. CT scan of thorax, if an obstructing tumour in suspected.
10. Bronchoalveolar lavage (BAL) or transtracheal aspiration.
11. Bronchoscopy—May be done whenever there is evidence of an obstructing tumour or foreign body.
12. Lung biopsy—Rarely needed. Sometimes, open lung biopsy is done in patients who are immunocompromised, e.g., Pneumocystis jiroveci infection in AIDS.

Line of management of pneumonia :

1. General—Rest in bed, good nutritious diet (high calorie with plenty of fluids).
2. Specific—Antibiotics; usually given after sputum examination. If sputum is unobtainable or unhelpful, start with erythromycin 500 mg QDS, orally. In hospital-acquired pneumonia and pneumonia in immunocompromised host, a third-generation cephalosporin should be started.
3. Symptomatic (hospitalisation, wherever indicated)—
   a) 0_2 inhalation in high concentration for cyanosis.
   b) Cough suppression by methadone, pholcodine etc. in harassing non-productive cough; otherwise, expectoration should be encouraged.
   c) Hydrocortisone for peripheral circulatory failure.
   d) I.V fluid infusion for dehydration.
   e) Warmth, counterirritants and analgesics (e.g., paracetamol) for pleural pain.
   f) Inj. diazepam (use cautiously) for delirium.
   g) Assisted ventilation in respiratory failure.
   h) Postural drainage and chest physiotherapy in cases of suppurative pneumonia.

Conclusion :

Mediastinum (trachea and apex beat) is not shifted in consolidation. Fever (may have chill and rigor), cough (initially dry and painful, later on productive), haemoptysis (rusty sputum or frank haemoptysis), gross anorexia, headache and bodyache, pleuritic chest pain, tachypnoea with herpes labialis are common mode of presentations.

The **hallmarks of diagnosis** are :

1. Absence of mediastinal shifting.
2. (Woody) dullness on percussion on the affected side.
3. Tubular breath sound, bronchophony and whispering pectoriloquy with aegophony on the affected side.

Clinical Atlas

Thalassaemia with frontal bossing, depressed bridge of the nose, malar prominence and mild icterus

cretinism showing dwarfism, depressed bridge of the nose, broad flat nose with big nostrils, scanty hairs in scalp, thick lips with a dull, idiotic and expressionless face

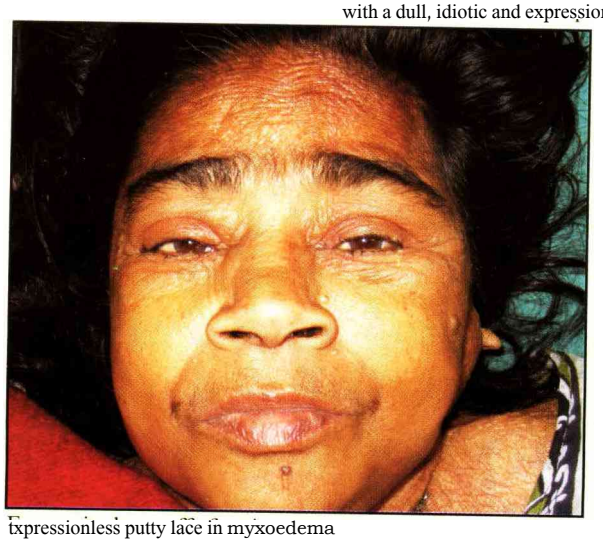

Expressionless putty face in myxoedema

Acromegaly characterized by prognathism, enlargement of face and 'spade-shaped' hands

Thyrotoxicosis with exophthalmos and staring look

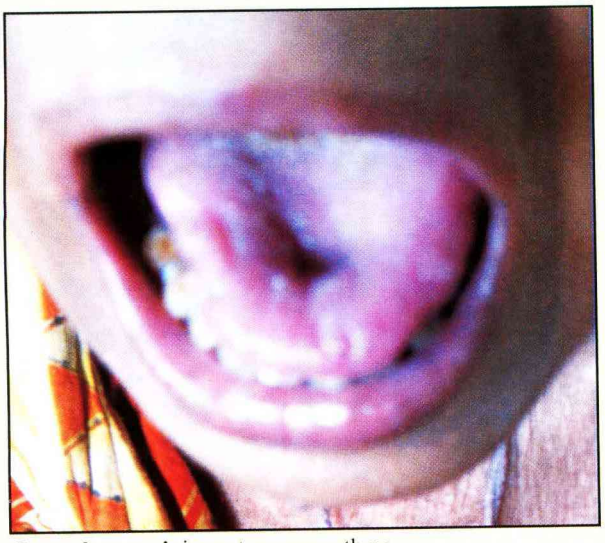

Central cyanosis in acute severe asthma

Suffused bulbar conjunctiva and increased redness of lower palpebral conjunctiva in **polycythema** from cyanotic congenital heart disease

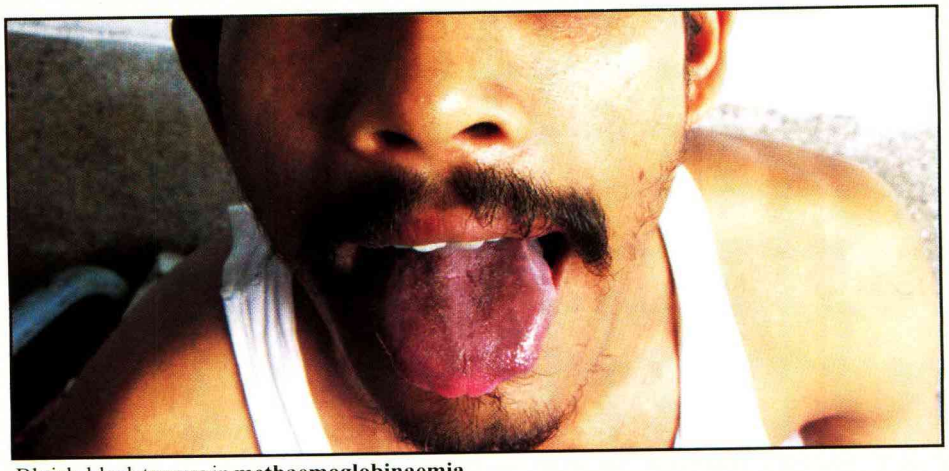

Bluish-black tongue in **methaemoglobinaemia**

Gum hypertrophy in acute myeloid leukaemia

Angioneurotic oedema of face with swollen lips

Case 12

BRONCHIAL ASTHMA

What is your diagnosis ?

It is a case of bronchial asthma with recent acute paroxysmal attack.

Why do you say so ?

This patient is suffering from bronchial asthma because of the presence of :

(A) SYMPTOMS (from the history)—

1. Respiratory distress for 2 years with acute exacerbation for last 3 days.
2. Cough with mucoid expectoration for last 2 years.

[H/O present illness—describe dyspnoea, fever, cough, chest pain, H/O oedema, seasonal variation etc, if any. Past history—chronic exposure to dust and smokes. H/O repeated cough and cold in the childhood. Recurrent attacks of rhinorrhoea and angioneurotic oedema present.

Personal history—smoker (12 cigerettes/day for 14 years) and bus driver by profession.

Family history—maternal uncles suffer from same type of respiratory distress.]

* Family history regarding bronchial asthma, hay fever and eczema are important in respiratory system. Occupational history e.g., exposure to coal mines, asbestos, silica dust, or H/O exposure to cotton dust, pollen, perthenium, feather, or pets (i.e., pigeon, parrot) should always be taken into account. Drugs like fi-blockers or aspirin can induce bronchoconstriction. For bronchiectasis, ask for H/O measles, influenza or whooping cough in childhood.

(B) SIGNS—

1. General survey :

a) Decubitus—Propped-up at 45°.
b) Cyanosis—Absent at present.
c) Neck veins—Within normal limit (neither engorged nor pulsatile).
d) Polycythemia—Absent (present in patients with COPD).
e) Respiration—30/min. regular and without purse-lip respiration.
f) Temperature—101° F (oral) at present.
g) Pulse—90/min, regular, without any special character (describe all other points).

2. Inspection :

a) Accessory muscles of respiration are working.
b) Wheeze—Present.
c) Upper respiratory tract—Hypertrophied inferior turbinate; no nasal polyp seen.
d) Indrawing of suprasternal and supraclavicular fossae without any intercostal suction at present.
e) Shape of the chest—Normal.
f) Respiration— 30/min. regular in rhythm and predominantly thoraco-abdominal in type.
g) Tracheal tug—Absent.

* Severe bronchial asthma persisting from childhood may have 'pigeon chest'.

3. Palpation :

a) Apex beat—Can not be localised properly (due to overinflation of lung).
b) TRACHEA—In the midline (central).
c) Movement—Both the sides are moving simultaneously and symmetrically, and the expansion is 2" (measured by the tape).
d) Vocal fremitus—Symmetrically reduced all over the chest (bilaterally and uniformly).
e) Rhonchial fremitus—Present.

4. Percussion :

a) Resonant note all over the chest (bilaterally and uniformly).
b) Liver dullness—Present at right 5th ICS at right MCL.

5. Auscultation :

a) Vesicular breath sound with prolonged expiration present all over the chest.
b) Vocal resonance—Diminished uniformly all over the chest.
c) Adventitious sounds—
(i) Sibilant (high-pitched), polyphonic expiratory and inspiratory rhonchi all over the chest.
(ii) Coarse crepitations at the bases.
(iii) Absence of pleural rub.

Describe the 'breathlessness' in your patient :

]. Acute respiratory distress for last 3 days though he is suffering from mild to moderate respiratory distress from time to time for last 2 years.
2. This attack is paroxysmal, and probably precipitated by respiratory tract infection.
3. Exertional at present.
4. H/O seasonal variations (increased in winters).
5. Associated with wheeze.
6. Associated with cough and there is production of mucoid expectoration.
7. No H/O pain chest.
8. No H/O PND.
9. The disease was stationary for last 2 years (non-progressive).
10. It used to relieve by inhaled drugs and taking rest.

Gradation of respiratory dyspnoea :

The Medical Research Council Classification (dyspnoea scale) is as follows :

Grade I : Dyspnoea on strenous exertion.

Grade II : Dyspnoea on hurrying on a level ground or walking up a small hill.

Grade III : Dyspnoea is of such a degree that the person has to stop after a mile or walk slower than most people on level ground.

Grade IV : Dyspnoea appears after walking about 100 yards.

Grade V : Dyspnoea even on undressing or at rest.

* Actually, try to assess the severity by asking to what extent the lifestyle is affected.

What do you mean by wheeze and stridor ?

(A) Wheeze :

1. High-pitched musical sound heard from a distance (specially heard by bed-partner at night).
2. *Better heard in expiratory phase.*
3. Indicates small airways obstruction.
4. Usually associated with rhonchi in the chest.

Clinical associations :

a) Bronchial asthma.
b) Chronic bronchitis.
c) Tropical eosinophilia.
d) Cardiac asthma.
e) Carcinoid syndrome.
f) Endobronchial disease (neoplasm).
g) GERD with aspiration.

* Bronchial asthma is associated with reversible wheeze whereas COPD with irreversible one.

(B) Stridor :

1. Low-pitched crowing or croaking sound (loud) heard from a distance.
2. *Better heard in inspiratory phase.*
3. Indicates larger airways obstruction like larynx, trachea and major bronchus.
4. Very common in children.
5. *Laryngeal stridor is a medical emergency* and urgent respiratory support may be required.

Clinical associations :

a) Foreign body inhalation in larynx or trachea.
b) Laryngeal oedema (angio-oedema).
c) Diphtheria, whooping cough.
d) Vocal cord palsy due to *recurrent laryngeal nerve paralysis* (other features of recurrent laryngeal nerve paralysis are bovine cough and hoarseness of voice).
e) Croup (acute laryngotracheobronchitisj.
fj Acute epiglottitis.
g) Paratracheal and subcarinal lymph nodes pressing over main bronchi (e.g., from bronchogenic carcinoma).
h) Laryngysmus stridulus in tetany.
i) Rapidly progressive laryngomalacia. papilloma of larynx.

Classify respiratory disorders :

(A) Obstructive ventilatory defect : Bronchial asthma, COPD, bronchiectasis, cystic fibrosis; FEV_t is grossly 1, VC 1 or normal, and FEV_t / VC 4-

(B) Restrictive ventilatory defect: Pleural diseases, interstitial lung disease, alveolar diseases, neuromuscular disorders (myasthenia gravis, G. B. syndrome), thoracic cage abnormalities (severe kyphoscoliosis, ankylosing spondylitis, obesity); FEV, is slightly i, VC ***i*** and FEV,/VC normal or T

What is' bronchial asthma' ?

It is a chronic inflammatory disorder of the airways where the tracheobronchial tree shows increased responsiveness to multiplicity of intrinsic and extrinsic stimuli, producing reversible airflow obstruction (due to muscle spasm, mucosal oedema and viscid secretion), and is characterised by paroxysm of dyspnoea, cough, tightness of chest and wheeze. Bronchial asthma is of two types :

1. Episodic asthma—Early onset, extrinisic or atopic, and
2. Persistent or chronic form—Late onset, intrinsic or non-atopic types.

What is' acute severe asthma' ?

This condition was previously known as **'status asthmaticus'.** It is a severe airway obstruction where paroxysm of acute asthmatic attacks occur without any remission in between and is not controlled by conventional bronchodilators. Remission is usually attained by the use of corticosteroid and sometimes, by respiratory assistance. This is a life-threatening attack of bronchial asthma and should be treated urgently. The clinical features are :

1. Severe dyspnoea (orthopnoea) with wheeze, tachypnoea, restlessness.
2. Active accessory muscles of respiration.
3. Unproductive cough in the presence of profuse bronchial secretions.
4. Profuse sweating.
5. Central cyanosis.
6. Tachycardia.
7. Pulsus paradoxus.
8. Diminished breath sound with minimal or absence of high-pitched polyphonic rhonchi_____ 'SILENT CHEST' (airflow may be insufficient to produce rhonchi).
9. PEFR (peak expiratory flow rate) is < 50% of predicted or patient's best.

How to assess the severity of bronchial asthma at the bedside ?

Clinical parameters of life-threatening asthma are :

1. Exhaustion and unable to speak in one breath; inability to lie supine.
2. Confusion and diminished level of consciousness.
3. Pluse rate > 120/min.
4. Pulsus paradoxus.
5. Central cyanosis.
6. Silent chest (ominous sign).
7. Hypotension.
8. Coma.
9. Unrecordable PEFR.
10. Arterial blood gas (ABG) analysis—
    - Normal or high $PaC0_2$ > 5-6 KPa (37.5 to 45 mm to Hg).
    - Severe hypoxaemia, pO_a < 8 KPa (60 mm of Hg).
    - Low p^H < 7.2 or high H^+concentration.

* It is said that tachypnoea and apparent distress may be misleading. In life threatening asthma, there may be bradycardia and arrhythmia.

What is chronic obstructive pulmonary disease (COPD) ?

It is a condition where there is chronic obstruction to airflow (major site being the small airways) due to chronic bronchitis, emphysema, and chronic bronchiolitis (small airway disease). The airflow limitation is progressive and not fully reversible. Often it is known as chronic obstructive lung disease (COLD) or chronic obstructive airway disease (COAD). The nearest D/D is chronic severe bronchial asthma.

What are the alterations in breathing ?

1. DYSPNOEA—Abnormally uncomfortable subjective awareness of breathing. Dyspnoea is a subjective symptom and related to undue consciousness for the respiratory effort ('dys' means 'difficult, painful', and 'pnoia' means 'breathing').
2. ORTHOPNOEA—Dyspnoea in recumbent (lying down) position and is of such a degree as to make the patient sit upright for relief. The patient may sleep in a chair or uses some extra pillows at night (often quantified by number of pillows e.g., 'two-pillow orthopnoea'). There is

less efficient lung movement in lying down position, and sitting gives relief to the patient by helping in descent of liver with free diaphragmatic movement as well as diminishing the venous return in a failing heart.

3. Trepopnoea—Dyspnoea only in left or right lateral decubitus position, most often in patients with heart disease.
4. TACHYPNOEA or polypnoea—Increased rate of respiration e.g., > 20/min is tachypnoea (normal respiratory rate in an adult is 14-18 breaths/min). Very high respiratory rate is observed in lobar pneumonia. Many a time, it is the only clue to shortness of breath or presence of respiratory disease.
5. HYPERVENTILATION—Increased depth of respiration (ventilation in excess of metabolic needs).
6. HYPERPNOEA—Increase in rate and depth of respiration (increased ventilation due to increased metabolic needs).
7. Platypnoea or orthodeoxia—Dyspnoea only on assuming upright position, i.e., just opposite to orthopnoea. Though rare, it happens to be due to some cardiac diseases (e.g., left atrial myxoma or left atrial ball valve thrombus), massive pulmonary thromboembolism, pulmonary arterio-venous fistula, hepato-pulmonary syndrome or in selective paralysis of intercostal muscles.
8. Bradypnoea—Abnormaly low respiratory rate (e.g., < 10/min), commonly due to opium or morphine poisoning, increased intracranial tension, myxoedema coma, carbon dioxide narcosis, hypothermia or respiratory centre abnormality.
9. Sighing respiration—It is functional in nature, and occurs mostly in young females and children. Here, deep inspiration is followed by deep expiration with a pause in between the two. It is found in the presence of relatives or parents, and never occurs during sleep or when the patient is unmindful; if associated with 'hyperventilation syndrome , the patient may complain of giddiness, black-out, tingling of extremities, circumoral numbness, palpitation, chest wall tightness with local tenderness elicited all over the chest. Restlessness, anxiety and panic attacks are common. Features of tetany (e.g., carpopedal spasm) may be manifested in some cases. Tachypnoea and occasionally tachycardia may be present. This type of hyperventilation returns to normal during sleep, and often associated with underlying anxiety or depression.
10. Cheyne-Stokes respiration—This is a form of periodic respiration where periods of apnoea (cessation of breathing for 10 seconds or more) rhythmically alternate with periods of hyperpnoea, each phase lasting for about 30 seconds, and the whole cycle is usually completed in less than 2 minutes. The rate and depth of respiration increase to a maximum (hyperpnoea), and then decrease when breathing virtually ceases (apnoea). The hypercapnoea (as a result of apnoea) stimulates brainstem centres resulting in hyperventilation drive, which washes out $C0_2$ resulting in depression of respiratory centre leading to apnoea. It is commonly seen in,
    a) Healthy infants, adults during deep sleep, in high altitude (physiological).
    b) Severe cardiac failure (acute LVF).
    c) Uraemia.
    d) Narcotic poisoning (opium, barbiturates).
    e) Increased intracranial tension.
    f) Severe cardio-respiratory embarrassment.
11. Kussmaul's breathing—Vide infra.
12. Stertorous breathing—Breathing with rattling noise in throat (i.e., fall-back of tongue, pharyngeal secretions), often seen in deep coma or in dying patients, is known as stertorous breathing.
13. Cogwheel breathing—An interrupted type of breathing pattern, seen particularly in nervous/anxious/weeping individuals.
14. Gasping respiration—Dying patients often take few deep, irregular inspirations mimicking a 'fish out of water', is known as 'gasping' respiration. It is the terminal respiratory pattern of lower brainstem damage.

Common causes of orthopnoea, tachypnoea, hyperpnoea and hyperventilation :

(A) Orthopnoea :

1. CCF.
2. LVF.
3. Bronchial asthma.
4. COPD.
5. Massive pleural effusion.
6. Pericardial effusion (cardiac tamponade).
7. Huge ascites.
8. Bilateral diaphragmatic palsy.

(B)Tachypnoea :

1. Nervousness, exertion, anxiety.
2. Fever.
3. Acute lobar pneumonia.
4. LVF.
5. COPD (hypoxia).
6. Shock, ARDS.
7. Acidosis.
8. Hysteria.

(C) Hyperpnoea :

1. Severe exertion e.g., 100 or 200 meter race.
2. Metabolic acidosis (Kussmaul's breathing).
3. Hysteria.

(D) Hyperventilation :

1. Hysteria.
2. Pain anywhere in the body, fever, anoxia
3. Anxiety neurosis.
4. Salicylate overdose.
5. Metabolic acidosis.

What is Kussmaul's breathing (air hunger) ?

Deep sighing, rapid breathing at a regular rate and with a hissing sound (i.e. there is hyperpnoea with increased rate and depth of respiration) is known as Kussmaul's breathing. It Is commonly seen in metabolic acidosis and is also known as 'acidotic breathing'. The causes are :

1. Diabetic ketoacidosis.
2. Uraemia.
3. Cerebral tumour.
4. Sometimes in hepatic coma.

Features of upper airway obstruction (e.g., laryngeal oedema) :

1. Restlessness with hyperactive accessory muscles of respiration.
2. Dyspnoea and even orthopnoea.
3. Cough (croupy cough in diphtheria).
4. Stridor,
5. Central cyanosis.
6. Intercostal suction.

Bedside diagnosis of ad.vanced airflow obstruction (COPD or bronchial asthma) :

1. Dyspnoea and even orthopnoea (sometimes with purse-lip breathing).
2. Hyperactive accessory muscles of respiration.
3. Reduction in the length of trachea palpable above the suprasternal notch.
4. Tracheal tug (tracheal descent during inspiration; if the ericosternal distance is reduced to less than 3 fingerbreaths, it indicates hyperinflation of the lungs).
5. Inspiratory excavation of the suprasternal and supraclavicular fossae.
6. Expiratory filling of neck veins.
7. Central cyanosis.
8. Intercostal suction.
9. Relative increase in antero-posterior diameter of the chest.
10. Wheeze.

* Characteristic 'tripod' position (patient sits with knee bending and flexed head placed in between knees) and Hoover's sign (paradoxical inward movement of rib cage with each inspiration) may be seen in adanced disease.

How to assess 'respiratory depression' (e.g., opium poisoning) at the bedside ?

1. Features of hypoxia (vide page 104).
2. Presence of central cyanosis.
3. Shallow respiration (expansion of the chest will be less).
4. Decreased respiratory rate (bradypnoea).
5. Diminished air entry in lungs (diagnosed by auscultation).

* ***Hypoventilation*** is regular, rhythmic and shallow breathing (may be due to brainstem defects, alveolar disorder, chest wall defects or massive obesity).

Breath sound over compensatory emphysema :

Usually it is harsh vesicular. Compensatory emphysema is usually unilateral.

Bedside diagnosis of emphysema :

1. Barrel-shaped chest.
2. Purse-lip respiration.
3. Non-localisation of the apex beat.
4. Diminished chest expansion.
5. Diminished vocal fremitus.
6. Hyperresonant note on percussion bilaterally.
7. Loss of both liver and cardiac dullness.
8. Breath sound will be diminished vesicular with prolonged expiration.
9. Diminished vocal resonance.
10. Usually rhonchi and crepitations are absent. Sometimes, there is wheezy rhonchi.

11. Heart sounds — Distant (muffled).
12. Liver and spleen may be palpable due to descent of diaphragm.

* Added to these 12 points, there are features of'advanced airflow obstruction' (question above).

** ***Emphysema*** is the permanent overinflation of air spaces in lung distal to terminal bronchiole as well as destruction of alveolar septae. Emphysema is of four types : centriacinar, paracinar, paraseptal, and scar or irregular.

Classification of crepitations :

Crepitations are discontinuous (< 20 millisecond in duration) bubbling or crackling (wet) sound produced by the passage of air through exudate-filled bronchi, bronchioles, alveoli, big cavity, or due to sudden snapping open of the relatively stiff alveoli at inspiration.

(A) Fine crepitations (end-inspiratory) — Soft, high-pitched and <10 millisecond in duration, and is produced due to presence of exudate in the alveoli.

1. LVF (at lung bases).
2. Fibrosis of the lung.
3. Indux crepitations of pneumonia (i.e., early stage of consolidation).
4. Fibrosing alveolitis (velcro crepitations) - See below for its mechanism of production.

* Velcro crepitations — sound resembles as if two strips of adhered velcro tapes are being seperated.

(B) Coarse crepitations (biphasic)—Louder, low-pitched and **<** 20 millisecond in duration, and is produced due to presence of exudate in the bronchi, bronchioles, alveoli or big cavities.

1. Acute bronchopneumonia.
2. Bronchiectasis.
3. Lung abscess or pulmonary cavity.
4. Redux crepitations of pneumonia (i.e., resolution stage of consolidation).
5. Cystic diseases of lung.
6. Pulmonary oedema (often called 'death rattle' when occurs as a terminal event).

Recent classification of crepitations :

The new terminology for crepitations is 'crackles'. Now-a-days crepitations are described by the undermentioned **two points** :

1. To note their timing in relation to respiratory cycle, and
2. Whether they are affected by coughing or not. Crepitations heard in fibrosing alveolitis are due to sudden snapping open of the relatively stiff alveoli at the end of inspiration, and are uninfluenced by coughing. Crepitations in the presence of secretions is confirmed by the observation that they either disappear temporarily or reduce in number after coughing.

* Crepitations of LVF are often silenced by bending forward.

Types of crepitations in relation to phases of respiration :

(A) Inspiratory—

1. Early—Chronic bronchitis.
2. Mid—Pulmonary oedema.
3. Late—Fibrosing alveolitis, pulmonary oedema, lung abscess, cavity within the lung..

(B) Expiratory—

Severe airway obstruction e.g., bronchial asthma.

* Bronchiectasis gives rise to biphasic i.e., both inspiratory and expiratory crepitations.

What is post-tussive crepitations ?

These are the crepitations heard after coughing and are often diagnostic of superficial tuberculous cavity.

How do we classify rhonchi ?

Rhonchi are continuous (> 80 millisecond in duration), uninterrupted musical (dry) sound produced in the narrowed bronchi or bronchioles as a result of muscle spasm, collection of viscid secretion, mucosal oedema or narrowing by an endobronchial growth.

(A) Old classification :

1. High-pitched rhonchi which are produced in smaller bronchi or bronchioles, and of squeaky quality is known as 'SIBILANT' rhonchi (end-inspiratory or early-expiratory)—Found in bronchial asthma.
2. Low-pitched rhonchi which are produced in larger bronchi, and of snoring quality is known as 'SONOROUS' rhonchi (biphasic)—Found in endobronchial growth affecting a large bronchus.

(B) Recent classification :

1. **Monophonic rhonchi** - May be inspiratory or expiratory or both, and may change in intensity with change of posture. It is produced due to narrowing of a single bronchus by tumour or foreign body (i.e., localised obstruction), which produces a single musical note.
2. **Polyphonic rhonchi** - Particularly heard in expiration and are characteristically found in diffuse airflow obstruction e.g., bronchial asthma or chronic bronchitis. They denote dynamic compression of bronchi. This is the most common type of rhonchi where the musical sound (rhonchi) contains several notes of different pitch, and results from oscillation of many large bronchi at a time.

* Few clinicians now prefer to call rhonchi as 'wheeze'.

Common causes ***of rhonchi :***

1. Bronchial asthma, COPD.
2. Wheezy bronchitis.
3. Cardiac asthma (LVF).
4. Tropical pulmonary eosinophilia.
5. Laryngeal oedema, foreign body or tumour obstructing bronchus (fixed monophonic).

What is chronic cor pulmonale ?

It is a condition where there is right ventricular hypertrophy with or without failure resulting from diseases affecting the structure (i.e.. lung parenchyma and vasculature) and / or function of the lung. This is also known as 'pulmonary heart disease' or heart disease secondary to disease of the lung.

(A) Disorders of lung parenchyma :

COPD (commonest cause), bronchial asthma, pneumoconiosis, fibrosing alveolitis, scleroderma etc.

(B) Diseases of pulmonary vessels :

Primary pulmonary hypertension, recurrent pulmonary thromboembolism, polyarteritis nodosa etc.

(C) Disorders affecting movements of thoracic cage (i.e., affecting the function of lung) : severe kyphoscoliosis, ankylosing spondylitis, neuromuscular disorder like poliomyelitis, thoracoplasty, Pickwickian syndrome (hypoventilation with extreme obesity) etc.

What is acute cor pulmonale ?

It is synonymous with acute pulmonary thromboembolism where **right ventricle dilates with or without failure.** As a result, acute pulmonary hypertension develops from massive pulmonary throm boembolism.

Features of chronic cor pulmonale :

(A) Symptoms : Cough, expectoration, breathlessness (may not be relieved by sitting up), atypical chest pain, weakness, pedal swelling, excessive day time somnolence.

(B) General survey :

1. Orthopnoea or a stooping forward position in bed: tachypnoea; purse-lip respiration.
2. Central cyanosis.
3. Pulse - Tachycardia, may be water-hammer in character; regular (mention all other points).
4. Face - Dusky and plethoric (due to polycythemia).
5. Hands - Warm and blue; may have flapping tremor.
6. Neck veins - Engorged and pulsatile (RVF).
7. Oedema - Bipedal pitting oedema (RVF).
8. Engorged veins may be seen in the forehead.
9. Nicotine staining of the finger (as commonly a smoker).

(C) Inspection :

1. Hyperactive accessory muscles of respiration with intercostal suction.
2. Barrel-shaped chest with features of emphysema.
3. Epigastric pulsation (RVH).

(D) Palpation :

1. Tracheal tug may be evident.
2. Apical impulse may not be localised due to emphysema (outward apex—RVH).
3. Palpable P_2 (diastolic shock).
4. Left parasternal heave (RVH).
5. Liver—Enlarged, soft and tender (RVF).

(E) Percussion :

Hyperresonant note all over the chest with loss of hepatic and cardiac dullness.

(F) Auscultation:

1. Diminished vesicular breath sound with prolonged expiration.
2. Occasional rhonchi with or without coarse crepitations.
3. Vocal resonance—Diminished all over the chest uniformly.
4. Loud P_2.
5. Right ventricular gallop (RVF) may be audible.
6. Pansystolic murmur of TI is audible in high pulmonary artery pressure.

Actually, we get a mixture of signs of emphysema PLUS signs of pulmonary hypertension. Emphysema overshadows all the inspectory and palpatory signs in the chest, and we have to depend on **epigastric pulsation (RVH), engorged and pulsatile neck vein (RVF), and loud P_2 (due to pulmonary hypertension)** to diagnose a case of chronic cor pulmonale.

Why a COPD patient purses the lips ?

Pursing of lips during expiration helps the patient to maintain high intrabronchial pressure (i.e., to keep high end-expiratory pressure) above that within the surrounding alveoli (alveoli are overinflated or air-trapped in COPD) and thus prevents the collapse of bronchial walls by overinflated alveoli.

Who is a 'blue bloater' ?

In patients with 'predominant chronic bronchitis', there is severe hypoxia with hypercapnia, pulmonary hypertension and RVF from the very early stage though the ventilatory capacity is well preserved. They suffer from cyanosis (blue), oedema (bloated) and thus known as blue bloaters. Cough with sputum production is the main feature while dyspnoea is less common.

Who is a 'pink puffer' ?

In patients with 'predominant emphysema', there is gross impairment of ventilatory capacity and they usually suffer from severe disabling exertional dyspnoea. They are not cyanosed (so, pink) because the arterial 0_2 is sufficient to saturate haemoglobin and try to blow off the excess $C0_2$ (puffer). They maintain a near-normal $Pa0_2$ and $PaC0_2$. The patient is usually lean and thin.

Complications of COPD :

1. Recurrent pulmonary infections (very common).
2. Chronic cor pulmonale.
3. Spontaneous pneumothorax (due to rupture of emphysematous bulla).
4. Right ventricular failure (often a part and parcel of chronic cor pulmonale).
5. Type II respiratory failure.

What are the D/D you will entertain in your case ?

1. Chronic bronchitis —
   a) Chronic cough with expectoration on most days for at least 3 consecutive months in a year, for more than 2 successive years.
   b) Family history is absent.
   c) Often a smoker.
   d) Symptom-free childhood.
   e) Episodes of frequent respiratory tract infection.
   fl Copious mucoid sputum.
   g) Wheeze and rhonchi+.

* Chronic bronchitis is associated with chronic cough with expectoration (phlegm). A patient of ***chronic bronchitis with acute exacerbation*** presents with pyrexia, and persistent or recurrent mucopurulent sputum production.

2. Tropical eosinophilia—
   a) Nocturnal cough; breathlessness in a young patient.
   b) H/O urticaria, worm infestation.
   c) Absolute eosinophil count > 3000/mm^3.
   d) High level of filarial antibody.
   e) Miliary mottlings in the chest X-ray.
3. Allergic aspergillosis—
   a) Episodic cough, wheeze and dyspnoea.
   b) Migratory densities in chest X-ray.
   c) Sputum contains Aspergillus fumigatus.
   d) High eosinophil count in blood.
4. Cardiac asthma—Described in the section on 'Mitral stenosis'.

5. Acute bronchopneumonia—
   a) No family history.
   b) Extremes of ages.
   c) Patient will be toxic.
   d) Fever; bilateral patchy involvement affecting mainly the lower lobes.
   e) Recently developing dyspnoea.

* D/D of'acute severe asthma' in clinical practice are acute LVE, acute exacerbation of COPD, ARDS and tension pneumothorax.

** Recurrent bronchospasm is classically seen in bronchial asthma, recurrent pulmonary thromboembolism, tropical eosinophila, carcinoid syndrome (tumour), acute exacerbation of chronic bronchitis/ emphysema, and cardiac asthma (acute LVF).

Table 6 : Bedside differentiation between bronchial and cardiac asthma

	Features	**Bronchial asthma**	**Cardiac asthma**
1.	Past history-	Allergy and atopy; past H/O similar attacks	No H/O allergy: there may be few similar attacks in the past
2.	Family history—	Often positive	Negative
3.	Onset—	Late night or early morning	Early hours of night or midnight
4.	Age—	Any age; usually young	Usually older age group
5.	Clinical features-		
		a) Scanty, mucoid and tenacious expectoration	a) Profuse, pinkish and frothy expectoration
		b) Wheeze + + +	b) Wheeze +
		c) Cyanosis + +	c) Cyanosis +
		d) Pulsus paradoxus	d) Pulsus alternans
		e) BP—Usually normal	e) BP—May be hypertensive*
		f) Apex beat—Normal character	f) Apex beat—Heaving or tapping
		g) There may be obliteration of liver and cardiac dullness	g) Cardiac dullness may be increased due to LVH
		h) RVH—May be present	h) LVH—may be present
		1) Heart sounds are muffled	1) Gallop rhythm present
		j) Rhonchi + + +, crepitations +	j) Rhonchi +, crepitations + + +
		k) May have 'silent chest'	k) Breath sound is not altered

* As hypertension is the commonest cause of cardiac asthma.

Complications of bronchial asthma :

1. Acute severe asthma.
2. Recurrent bronchitis and pneumonia (from infections).
3. Atelectasis (collapse) of lung or bronchiectasis (from mucous plugs).
4. Emphysema.
5. Pneumothorax (spontaneous).
6. ***Complications of cough*** like chest and abdominal wall soreness, exhaustion, severe vomiting, rib fracture (specially in elderly with osteoporosis or multiple myeloma), cough syncope, spontaneous pneumothorax, subconjunctival haemorrhage, frenal ulcer, urinary incontinence; prolapse of rectum, hernia or uterus.
7. Chronic cor pulmonale and respiratory failure (in late stage).

What is respiratory failure ?

It is a condition which is characterised by abnormality in blood gases ($Pa0_2$ < 60 mm of Hg and / or PaCO > 50 mm of Hg). The normal arterial blood gases are no longer maintained and the lung function is inadequate for the metabolic needs of the individual. It is of two types :

1 Type I — Low $Pa0_2$ with normal or low $PaCO_z$; also known as hypoxaemic respiratory failure. It is found in ; pulmonary oedema (acute LVF), pneumonia, ARDS (acute lung injury), bronchial asthma, fibrosing alveolitis, pulmonary thromboembolism, pneumothorax, hysterical hyperventilation.

2. Type II — High $PaC0_2$ with low $Pa0_2$; also known as hypercarbic failure or 'ventilatory failure'. It is found in : chronic bronchitis, emphysema, acute severe asthma, gross kyphoscoliosis, ankylosing spondylitis, trauma, neuromuscular disorders like myasthenia gravis, polyneuritis, poliomyelitis; depression of respiratory centre by narcotics or anaesthetics; end-stage of type I failure.

* **Commonest cause of respiratory failure is chronic bronchitis.**

Table 7 : ***Features of respiratory failure at the bedside***

Features due to hypoxia :	**Features due to hypercapnoea :**
1. Restlessness, tachypnoea	1. Headache (bifrontal or occipital)
2. Impaired judgement	2. Reduced psychomotor activity
3. Mental confusion	3. Drowsiness, confusion or even coma
4. Depression of consciousness level	4. Flapping tremor (asterixis)
5. Central cyanosis	5. Water-hammer pulse and capillary pulsation
6. Tachycardia; systemic hypotension	6. Flushed and warm extremities (e.g., hands)
7. Cardiac arrhythmias	7. High blood pressure
8. Damage to organs like liver and kidney	8. Muscle twitching (fasciculations)
9. Convulsions	9. Papilloedema
10. Coma	10. Chemosis of the conjunctiva

Hypoxic features are more prominent in Type I failure. It was previously known as 'alcoholic type' as the patient becomes restless. Severe hypoxia may lead to bradycardia and systemic hypertension.

Features of hypercapnoea are more pronounced in Type II failure. It was previously known as 'anaesthetic type' as the patient becomes drowsy. Majority of hypercapnoic features are due to cerebral and peripheral vasodilatation. This spectrum is also known as hypercapnoic encephalopathy or carbon dioxide narcosis.

* Features of **hypocapnoea** are : hyperventilation, dizziness, circumoral paraesthesia.

Bedside assessment of pulmonary function :

1. Tachypnoea.
2. Central cyanosis.
3. Rising pulse rate.
4. Inability to speak.
5. Progressive exhaustion.
6. Altered sensorium.
7. Profuse sweating.
8. Pulsus paradoxus.
9. Asynchronous respiration (i.e respiratory muscle fatigue).
10. Silent chest.

If these features are present, immediately check the arterial blood gas and start mechanical ventilation accordingly.

What is ARDS ?

ARDS is a non-specific reaction of the lungs to a wide variety of insults, and by far the commonest one is sepsis. Previously called Adult Respiratory Distress Syndrome (ARDS) is now-a-days known as Acute Respiratory Distress Syndrome or ***'acute lung injury'.*** This is a severe form of type I respiratory failure caused by non-cardiogenic pulmonary oedema, or it is an acute hypoxaemic respiratory failure following a systemic or pulmonary insult without having any evidence of cardiac failure. Acute lung injury is a less severe disorder which can evolve into ARDS at any point of time. It is a serious disorder which is characterised by damage of alveolar as well as pulmonary capillary endothelium, where the alveoli become flooded with oedema fluid. The salient features are tachypnoea followed by dyspnoea, central cyanosis and crepitations throughout both lung fields; chest X-ray reveals diffuse, bilateral, interstitial and alveolar infiltrates ('fluffy' shadow). ARDS is also characterized by normal pulmonary capillary wedge pressure (<18 mm of Hg) and a $Pa0_2/F_I0_2$ (inspiratory 0_2 fraction) ratio < 200 mm of Hg. Read the causes of non-cardiogenic pulmonary oedema from the section on 'Mitral stenosis'.

How do you like to investigate bronchial asthma ?

1. Peripheral blood film — May show eosinophilia. Polymorphonuclear leucocytosis occurs in the presence of respiratory tract infection.
2. Sputum examination - Reveals,
   a) Eosinophils,
   b) Charcot—Leyden crystals (rhomboid crystals derived from eosinophils),
   c) Laennec's pearls,
   d) Curschmann's spiral (mucus casts of small airways),

e) Dettrich's plugs, and
f) Bronchial casts.

3. Chest X-ray - May be normal or show overinflation of lungs (due to emphysema). Rarely, there may be segmental or lobar collapse due to obstruction of bronchus by tenacious mucus. ***In worsening dyspnoea, always rule out the presence of pneumothorax.*** HRCT scan of thorax may be helpful to exclude other diseases.
4. Arterial blood gas analysis - In between the paroxysms, there is low $Pa0_2$ with normal or low $PaC0_2$. But in acute severe asthma, there is low $Pa0_2$ with high $PaC0_2$.
5. Lung function tests -
   a) FEV,.
   b) FEV, / FVC.
   c) PEFR.

   The effects are seen before and after application of bronchodilator drugs. These values are low in bronchial asthma. There is marked diurnal variation in PEFR (no diurnal variation in chronic bronchitis or emphysema) and the value is lowest in the morning (early morning dipping).
6. Skin hypersensitivity tests - Done by 'prick method'. It may identify the allergen in an atopic individual (wheal and flare reaction after intradermal injection of common allergens).
7. Serum IgE — Elevated serum IgE level supports atopy.

What will be the outline of management of bronchial asthma ?

1. Rest in bed in propped-up position with moist 0_2 inhalation at the rate of 4-6 litre / minute.
2. Salbutamol or terbutaline—I.M or I.V route in a dose of 250-500 |_ig, or inj. aminophylline with a loading dose of 5.0 mg/kg of body weight by slow I.V infusion over 20 minutes and maintenance dose of 0.5 mg/kg/hour, given as a continuous IV infusion (in acute case). Tablet salbutamol (2 mg), terbutaline (2.5 mg) or theophylline (100 mg) may be given three times daily in between the attacks. Long-acting (i_2-stimulants like salmeterol or formeterol are now used routinely as inhaler or spacer.
3. Corticosteroid—Hydrocortisone hemisuccinate 200 mg I.V may be given in acute severe asthma as a loading dose, followed several hours later by an infusion regulated to deliver 3 mg/kg every 6 hours. Now-a-days corticosteroid (as inhaler) is also used in between the attacks.
4. Sodium chromoglycate inhalation 20 mg, four times daily in between the attacks; recently nedocromil sodium is used as 4 mg, 2-4 times daily.
5. Ipratropium bromide (anticholinergic) inhalation, or tablet ketotifen (antihistaminic) 1 mg twice daily may be given in between the attacks.
6. Leucotriene antagonist, montelukast (10 mg, orally, once daily) or zafirlukast (20 mg, orally, BD) may be used to provide control of mild to moderate persistent asthma.
7. Sedatives, tranquillisers or narcotics should preferably be avoided.
8. Treatment of pulmonary infection with proper antibiotics. Expectorants or mucolytics (bromhexine, acetyl-cysteine) may be used.
9. Desensitisation or immunotherapy by repeated subcutaneous injections of gradually increasing dose of extracts of allergen/allergens may be tried (doubtful value).
10. Recent development—Omalizumab (recombinant humanized monoclonal antibody which modulates IgE-associated inflammation) or etanercept (anti-TNF therapy) may be tried in corticosteroid-resistant severe asthma.

* Acute severe asthma needs special management. Read the step-up and step-down drug treatment of bronchial asthma from any standard text book.

Side effects of pure (100%) oxygen therapy :

1. Cough and bronchial irritation as it is both irritant and toxic; drying of secretions.
2. Carbon dioxide narcosis occurs when high 0_2 concentration is given to patients with respiratory failure who thrives on 'hypoxic drive', e.g., in chronic bronchitis'.
3. Retrolental fibroplasia (blindness) and bronchopulmonary dysplasia—in premature infants.
4. Pulmonary oedema and ARDS.
5. Consolidation of the lung.
6. Absorption collapse (in low ventilation/perfusion zones).
7. Respiratory depression.

* Newborn and infants are more susceptible to effects of pure 0_2 than older children and adults.

Conclusion :

The **hallmark of diagnosis** of bronchial asthma is sibilant, polyphonic rhonchi (mainly expiratory) present all over the chest.

------ O------

Section 3

GASTROINTESTINAL SYSTEM

The cardinal symptoms of G.I. system are enlisted below :

1. Anorexia (loss of appetite), dyspepsia, indigestion
2. Dysphagia, odynophagia (painful swallowing); toothache, bleeding gum, dentures
3. Nausea, vomiting, retching, eructation, hiccough (singultus)
4. Heartburn (pyrosis i.e., a hot, burning retrosternal discomfort), water brash (salivary hypersecretion) and regurgitation (effortless appearance of gastric contents in mouth)
5. Jaundice, yellow urine, pruritus
6. Pain abdomen (including biliary colic)
7. Haematemesis
8. Melaena
9. Haematochezia
10. Bleeding per rectum
11. Alteration in bowel habit
12. Diarrhoea or constipation, mucus in stool, worms in stool.
13. Swelling in the abdomen, distension of the abdomen or mass in the abdomen.
14. Wind or flatulence (belching or flatus)
15. Loss of weight
16. Pedal oedema
17. Oliguria (e.g., hepato-renal syndrome from cirrhosis of liver)
18. Neuropsychiatric manifestations (inversion of sleep rhythm, drowsiness from hepatic pre-coma)
19. Fever (intestinal tuberculosis, lymphoma, spontaneous bacterial peritonitis)
20. General symptoms—fatigue, bladder symptoms etc.

* ***Dyspepsia*** is the summation of a variety of G.I. symptoms e.g., anorexia, early satiety plus flatulance.

** Difficulty in defecation with straining (dyschezia), and feeling of incomplete evacuation with a constant desire for defecation (tenesmus) fall within 'alteration in bowel habit'. Rule out malignancy of bowel in recent alteration in bowel habit.

*** Don't forget to take the H/O hernia or haemorrhoids. Other minor symptoms are halitosis, dry mouth, ulcers in mouth (e.g., aphthous ulcer) or pain in the oral cavity.

****Too much flatus production is commonly due to aerophagia (air ingestion), malabsorption or lactase deficiency.

***** Terminology associated with alimentary system :

- Appetite—pleasurable desire to eat
- Hunger—unpleasant sensation produced as a result of empty stomach as well as peristaltic contraction
- Satiety—a sensation of satisfaction after taking food
- Sitophobia—fear of eating (e.g., in oropharyngeal dysphagia, pulmonary aspiration of food occurs during swallowing)
- Phagophobia—fear of swallowing (e.g., in rabies, tatanus and hysteria)
- Globus pharyngeous—sensation of something lodged in the throat or lump in the throat
- Nausea—feeling or desire to vomit
- Retching—laboured and rhythmic contraction of respiratory and abdominal muscles preceding vomiting
- Heartburn (pyrosis)—burning sensation or a sensation of warmth located substemally
- Dysgeusia—altered taste sensation

Scheme of Examination

(A) UPPER G.I. TRACT :

1. Lips.
2. Teeth.
3. Gum.
4. Cheek (buccal mucosa).
5. Tongue.
6. Fauces and tonsils.
7. Palate.
8. Breath (halitosis or foul
9. Oropharynx.

* A torch, a tongue depressor and a pair of gloves are necessary for examination of oral cavity. It is not possible to examine the oesophagus at the bedside; ask the patient for dysphagia, odynophagia, heart burn, or give the patient a glass of water or biscuits, and ask him to swallow. Oesophageal disorder is analysed by barium swallow, upper G.I endoscopy, and motility study by manometry and isotope Tc" taken with solid or liquid food.

(B) EXAMINATION OF THE ABDOMEN :

I. INSPECTION :

1. Shape of the abdomen.
2. Flanks - Full or not (presence of free fluid within the peritoneal cavity i.e., ascites makes the flanks 'full').
3. Venous prominence (examine in sitting or standing position with asking the patient to cough).
4. Umbilicus -
   (i) Position of the umbilicus and the slit :
      a) Whether inverted or everted.
      b) Whether situated midway between xiphisternum and symphysis pubis, or not.
      c) Whether the slit is circular, transverse or vertical.
   (ii) Venous prominence around the umbilicus (caput medusae from portal hypertension).
   (iii) Hernia (umbilical).
   (iv) Granuloma, adenoma (raspberry tumour), endometriosis (looks raw and red).
   (v) Nodules around the umbilicus (e.g., metastatic nodule from intra-abdominal malignancy).
   (vi) Bluish discolouration around the umbilicus (Cullen's sign from haemoperitoneum) or Grey Turner's sign (discolouration of skin in the abdominal flanks due to haemoperitoneum).
   (vii) Omphalolith (inspissated desquamated epithelium with other debris)—specially in elderly.
   (viii) Sinus (malignant or tuberculous peritonitis, Crohn's disease, patent urachus).
5. Condition of the skin — Ulcer, striae, pigmentation, scar and puncture mark, sinus, keloid.
6. Any localised swelling.
7. Movement of the abdomen —
   (i) Respiratory movement.
   (ii) Pulsation.
   (iii) Peristalsis.
8. Hernial sites like —
   (i) Inguinal,
   (ii) Femoral,
   (iii) Umbilical,
   (iv) Epigastric, or
   (v) Incisional hernia.
9. Hair (secondary sexual hair—Loss of pubic hair, virilism etc).

* During inspection of the abdomen, extend the legs of the patient.

** Ask the patient to stand and note the presence of impulse on coughing on the hernial swellings.

*** For observation of respiratory movements, pulsation and peristalsis—squat down by the side of the bed to have a tangential inspection.

**** Finally, inspect the posterior abdominal wall (back), groins, penis and scrotum.

II. PALPATION :

a) Superficial —

1. Surface temperature.
2. Tenderness or hyperaesthesia.
3. Parietal oedema.
4. Consistency or feel (normal elastic feel, or muscle guard or rigidity).
5. Localised lump.
6. Divarication of recti (if any) by rising test.
7. Direction of blood flow in prominent veins.
8. Pulsation (transmitted or expansile).
9. Fluid thrill with girth of the abdomen at the level of the umbilicus.

* Measure the girth of the abdomen at the level of umbilicus with the help of a tape.

** Divarication of recti—two rectus abdominis muscles are widely seperated.

b) Deep —

1. Liver (in details).
2. Spleen (in details).
3. Gall bladder.
4. Kidneys (in details).
5. Colon.
6. Palpation of the testes - It is a must.
7. Any other lump in the abdomen.
8. Deep tender spots - McBurney's point, gall bladder point, epigastric point, renal angle etc.
9. Rebound tenderness.
10. Examination of hernia and external genitalia (for examination of hernia, ask the patient to stand and cough with turning the head to other side). Palpate both groins.
11. The aorta, paraaortic glands and common femoral vessels.
12. Urinary bladder.

* ***Rebound tenderness***—First give firm pressure over the abdomen, and then 'suddenly' take off the hands. The patient complains of severe pain in the abodmen if the sign is positive. This is positive in peritonitis (basically inflammation of perietal peritoneum) from any cause, including acute appendicitis.

** For deep palpation, conventionally palpate with the dominant hand. In any obese, muscular or poorly relaxed patient, the left hand is placed over the right hand to exert more pressure during palpation. Dipping method is adopted in the presence of ascites. The ***abdominal aorta is*** palpated by placing both hands vertically with extended fingers (eight fingers of both hands except thumbs), which are held side by side, and the palpation is carried a little above and to the left of umbilicus.

*** Groin should be carefully examined for inguinal lymph nodes, hernia and femoral pulsation.

**** $E_nq_Ui_{re}$ about pain in the abdomen and it is preferable to examine that part at the last.

III. PERCUSSION :

1. General note of the abdomen (tympanitic note in health is clicited by 'light' percussion).
2. Upper border of liver (and splenic) dullness.
3. Band of colonic resonance over a kidney lump.
4. Shifting dullness.
5. Urinary bladder - Full or empty.

IV. AUSCULTATION :

1. Peristalsis.
2. Hepatic / splenic rub.
3. Venous hum.
4. Bruit (e.g., hepatic bruit, renal artery bruit).
5. Ausculto-percussion and succussion splash (in pyloric stenosis).

(C) PER RECTAL EXAMINATION (optional) :

* Abdominal examination is never completed without examining external genitalia and performing rectal examination. Per rectal examination is important in females to note fullness of pouch of Douglas by ovarian cyst, fluid collection or malignant deposits. Per vaginal examination is often helpful to diagnose the nature of an abdominal mass.

Case 13

PYLORIC STENOSIS

What is your diagnosis ?

This is a patient of pyloric stenosis possibly developed from chronic duodenal ulcer.

Reasons behind your diagnosis :

This is a case of pyloric stenosis because :

1. The patient is giving a long history of duodenal ulcer. Previously the pain was present in epigastrium, appeared in empty stomach (or there was H/O hunger pain) with history of heartburn, water brash, nocturnal pain and pointing sign. The pain was relieved by taking food or antacid.
2. Distension of the upper part of abdomen with foul smelling gaseous eructation and belching.
3. Nausea as well as projectile vomiting is present which contains food taken by the patient 1-2 days back and is copious in amount, and the smell of the vomitus is very offensive. Vomiting greatly relieves the patient. Vomiting is often self-induced.
4. The typical character of epigastric pain (of chronic duodenal ulcer) is now changed and instead a sense of epigastric fullness or discomfort is present. The periodicity of pain is lost. The pain has lost its relationship with food in the last few months.
5. Rapid loss of weight and increasing constipation.
6. Features of tetany is present (alkalosis caused by vomiting) - Say, if present; signs of dehydration are present.
7. **A diffuse swelling** is present in the upper abdomen.
8. **Visible peristalsis** from left to right hypochondrium is seen (see the section on 'Visible peristalsis').
9. **Succussion splash** is heard (splashing sound heard on shaking the patient's abdomen).
10. **Ausculto-percussion** over the abdomen reveals gastric distension.

* A lump in the upper abdomen may be felt in case of carcinoma of the pylorus presenting as gastric outlet obstruction.

What is your case ?

Build up the summary from the history and physical findings.

Aetiology of 'gastric outlet obstruction' :

1. Chronic duodenal ulcer.
2. Carcinoma of the stomach (antrum).
3. Oedema of the pylorus.
4. Adult hypertrophic pyloric stenosis.
5. Congenital hypertrophic pyloric stenosis (in infants).
6. Hypertrophic gastritis, rarely.
7. Gastroparesis (e.g., from diabetes mellitus)
8. Bezoars (trichobezoars or phytobezoars).
9. Gastric lymphoma.

* Chronic duodenal ulcer -> duodenal cicatrisation -» fibrotic stricutre -> pyloric stenosis.

Common differential diagnosis you will consider in your case :

1. Carcinoma of the antrum :
   a) Age will be higher.
   b) History is short.
   c) Classical presentation of gastric carcinoma (vide infra).
   d) Rarely, epigastric pain relieves with food.
2. Adult hypertrophic pyloric stenosis :
   a) No past H/O peptic ulcer disease.
   b) Other features are like classical pyloric stenosis.
3. Intestinal obstruction :
   a) Peristalsis will be periumbilical.
   b) Abdomen will be tympanitic.
   c) Obstipation (absolute constipation, i.e., no passage of faeces and flatus).
   d) Bowel sounds gradually diminish.
4. Primary carcinoma of liver (predominantly involving the left lobe) :
   a) History is short.

b) Jaundice (rare).
c) Vomitus is not offensive.
d) Neither peristalsis seen nor any succussion splash heard.
e) Hard, tender, nodular liver; emaciation.

Common physical signs in gastric carcinoma :

1. Tender mass in the epigastrium (hard lump).
2. ***Anaemia.***
3. ***Asthenia*** (cachexia).
4. Jaundice (due to hepatic metastasis).
5. Liver - Enlarged, tender, hard with nodular surface and sharp margin; hepatic rub may be present due to metastasis.
6. Palpable Virchow's gland (palpable hard and fixed lymph nodes in between two heads of left stemomastoid muscle - ***Troisier's sign).***
7. Metastatic nodules around the umbilicus (Sister Marie Joseph's nodule).*
8. Ascites (due to malignant peritonitis).
9. Visible gastric peristalsis.
10. Succussion splash (due to gastric outlet obstruction).
11. Krukenberg's tumour (due to metastasis in the ovary) - Detected by P/V examination.
12. Blumer's shelf (shelf-like mass in the prerectal pouch) - Detected by P/R examination.
13. Rarely, there may be dermatological features like acanthosis nigricans, dermatomyositis, migratory thrombophlebitis (Trousseau's sign) etc.

N.B. : Examination of neck glands, jaundice, anaemia, ascites are important in a patient suffering from gastric outlet obstruction. ***Anorexia*** is a very important symptom. The tympanicity of Traube's space percussion is often lost.

* The Sister was nursing superintendant of St. Mary's Hospital, Rochester. USA.

How to elicit succussion splash (Hippocratic succussion} ?

This is the characteristic splashing sound heard in pyloric obstruction when gastric contents are retained for more than 4 hours in the stomach. The sign is elicited by shaking the patient from side to side and simultaneously listening the splashing sound by placing the diaphragm of stethoscope over the distended area in the epigastruim.

The splash is often realised by palpation (by placing hands over epigastrium) and heard without the help of stethoscope. This splashing sound may be normally present after taking a large amount of water.

How to elicit ausculto-percussion ?

This method helps to ***delineate the enlarged stomach*** in cases of pyloric stenosis and sometimes in acute dilatation of the stomach. Put the diaphragm of stethoscope over the epigastrium and scratch the upper part of the abdomen by finger or a pen/ pencil in a centrifugal fashion downwards and sideways. Note the sudden change in character of the sound and mark individual points with a skin pencil. The pencil marks are joined to get the outline of distended stomach which generally crosses the umblicus in a patient with pyloric stenosis. This method is called 'ausculto-scratching'. In the classical method of ausculto-percussion, a doctor percusses the stomach centrifugally (in the direction away from the stethoscope) while the other doctor listens the sudden changes in character of the sound.

Medical causes of peptic ulcer :

1. Cirrhosis of liver.
2. COPD.
3. Hyperparathyroidism.
4. Polycythemia vera.
5. Cushing's syndrome.
6. Chronic renal failure.
7. Systemic mastocytosis.
8. NSAID or corticosteroid therapy.

How will you confirm your diagnosis in a case of gastric outlet obstruction ?

1. Typical history with physical findings.
2. Analysis of gastric contents (fractional test meal) —
   a) Volume of gastric aspiration will be > 200 ml after overnight fasting.
   b) The colour of the juice is coffee-ground (in gastric carcinoma).
   c) Bile is absent in all the samples.
   d) Aspirate is offensive and contains food residue (classical pyloric stenosis).
   e) Pentagastrin-fast achlorhydria virtually diagnoses gastric malignancy.

3. Barium meal X-ray of stomach and duodenum -
   a) Grossly dilated stomach with excessive fasting contents.
   b) Lesion at or near the pylorus.
   c) **Failure of the stomach to evacuate the meal even after 6 hours (characteristic).**
4. Upper G. I. endoscopy - Diagnostic and a standard practice now.
   a) Can identify the obstruction and its degree.
   b) Old food material may be seen.
   c) May identify carcinoma in the antrum (biopsy may be taken).
5. FNAC (fine needle aspiration cytology) or excision biopsy of a palpable cervical lymph node (may diagnose carcinoma of stomach causing gastric outlet obstruction).
6. Liver biopsy may be done (to diagnose metastasis from gastric carcinoma).
7. Blood biochemistry - Persistent vomiting may give rise to hypokalaemia, hypochloraemia and alkalosis. Hyponatraemia and high blood urea level may be present.

* Coffee-ground colour vomitus (gastric carcinoma) is due to coversion of haemoglobin to acid haematin by gastric acid.

How are you going to manage your case of pyloric stenosis ?

1. Repeated stomach wash or gastric decompression is done (at 2-4 hourly interval for 3-4 days) to remove all food debris.
2. Correction of dehydration, dyselectrolytaemia and metabolic alkalosis are done by :
   a) 5% dextrose and normal saline.
   b) Injection potassium chloride 80-100 mmol / day.
3. Proton pump inhibitors may reduce pyloric oedema or heal ulcer.
4. Gradually the patient is put on oral diet. At first liquid, then semisolid diet is started.
5. Elective surgery—Surgery is required in majority of patients in the long run. Vagotomy with gastrojejunostomy, or subtotal gastrectomy is done according to the choice of the surgeon. Balloon dilatation of the obstructed outlet may be done by upper G.I. endoscopy.

Late complications after gastric surgery :

1. Recurrent ulceration.
2. Afferent loop syndrome.
3. Dumping syndrome—Early and late.
4. Bile reflux gastropathy.
5. Postvagotomy diarrhoea.
6. Osteomalacia and osteoporosis.
7. Haematological complications—Iron deficiency anaemia, megaloblastic anaemia
8. Maldigestion and malabsorption.
9. Small stomach syndrome.
10. Adenocarcinoma of gastric stump.

Describe the normal peristaltic sound :

'Bowel sounds' are produced by the movement of faeces, fluid and flatus within the bowel lumen as a result of peristalsis. Place the stethoscope on one side of the abdominal wall and keep it there minimally for one minute until the bowel sounds are heard. Usually the stethoscope is placed just to the right of the umbilicus. Stethoscope should not be shifted from site to site. Normal bowel sounds are intermittent (at 5 or 10-second's interval) low-or medium-pitched gurgles mixed with occasional high-pitched tinkle.

In mechanical intestinal obstruction—Frequent loud low-pitched gurgles (borborygmi) are heard, often interspersed with high-pitched tinkles occuring in a rhythmic pattern with peristalsis. As a whole, the peristaltic sounds are ***exaggerated.***

In paralytic ileus and peritonitis—Abdomen is ***silent.***

N.B. : Bowel sounds are also exaggerated in malabsorption and severe G.I. bleeding.

* While dealing with a patient related to gastrointestinal system, one should be careful in examining :

1. Anaemia.
2. Jaundice.
3. Neck glands (Virchow's gland specially).
4. Oedema (nutritional, malabsorption).
5. Ascites (cirrhosis, peritonitis).
6. Hernial sites.
7. Testes.
8. Spine (referred pain from caries spine).
9. Rectum (per rectal examination), and
10. Auscultation of peristaltic sounds.

Case 14

ACUTE VIRAL HEPATITIS

What is your diagnosis?

This is a case of acute viral hepatitis probably due to type B virus infection, the patient is in the icteric stage and without any sign of hepato-cellular failure at present.

What is the reason behind your diagnosis?

This is a case of acute viral hepatitis because :

The patient suffered from high fever with mild chill and rigor, aches and pain all over the body 8 days back, and these ailments persisted for next 5 days. Initially, it was associated with profound anorexia, nausea and vomiting. At the onset, he also had urticarial rashes and arthralgia. The colour of the urine was yellow from the very beginning, and the patient complained of yellowish discolouration of eyes for last 5 days. The patient is having slightly pale stool from day before yesterday. He also complained of dull-aching, non-colicky, non-radiating pain in the right hypochondrium. Neither he is suffering from generalised pruritus nor any bleeding diathesis at present. There is no past H/O dental extractions, tattooing, acupuncture, blood taken (by unsterile syringe) for any investigational purpose within last 6 months or 'high risk behaviour' (all predispose to type B infection), jaundice, biliary colic, drug intake (like OC pills, rifampicin, INH), amoebic dysentery or alcohol intake. There was H/O receiving blood transfusion 3 months back when he suffered from a serious street accident. No family member or persons in his locality is suffering from similar type of illness (vide Type A infection). Thus, the disease started acutely and is progressing gradually. For the last 8 days of illness, he is feeling extremely weak.

On examination, there is presence of moderate degree of jaundice; liver is enlarged 4 cm below the right costal margin at right MCL, soft, tender with rounded and regular margin; it has a smooth surface and there is absence of pulsation, rub or bruit. Spleen is just palpable, soft and non-tender. The gall bladder is not palpable and there is discomfort on percussion over the right lower chest. There is neither any free fluid in the abdomen nor any sign of hepato-cellular failure present. CVS, nervous system and respiratory systems are essentially within normal limit.

* Splenomegaly and cervical adenopathy are present in 10-20% cases.

Give the summary of the case :

Described above.

'Extrahepatic associations' of type B infection :

1. Serum sickness-like' syndrome manifested by arthralgia or arthritis, fever, urticarial rash (present in this patient), angio-oedema and rarely haematuria or proteinuria.
2. Polyarteritis nodosa (systemic necrotising vasculitis).
3. Acute glomerulonephritis.
4. Polymyalgia rheumatica.
5. Essential mixed cryoglobulinaemia (arthritis with cutaneous vasculitis; commoner in hepatitis C).
6. Guillain-Barre syndrome.
7. Myocarditis.

* Porphyria cutanea tarda, essential mixed cryoglobulinaemia, lichen planus and sicca syndrome are clinical associations with hepatitis C.

Chief complaints of your patient :

1. Anorexia, nausea and vomiting for last 8 days.
2. Yellowish discolouration of urine for last 7 days.
3. Yellowish discolouration of eyes for last 5 days.
4. Fever for 5 days (initial 5 days of illness).
5. Pain in the right upper abdomen for last 3 days.

Common symptoms of acute viral hepatitis :

1. Anorexia, nausea and vomiting.
2. Arthralgia, myalgia and headache.
3. Pharyngitis, cough and coryza.
4. Fatigue and malaise.

5. Dark urine.
6. Clay-coloured stool (due to canalicular obstruction caused by swelling of hepatocytes).

Probable causes ***of marked anorexia :***

1. Acute viral hepatitis.
2. Tuberculosis.
3. Malignancies, specially carcinoma of the stomach (TNF-a is an anorectic substance).
4. Chronic diseases like cirrhosis of liver, chronic renal failure, CCF.
5. Drugs e.g., chloroquine, quinine, digitalis, metronidazole, erythromycin.
6. Psychogenic—depression, emotional upset, anorexia nervosa.
7. Chronic smoking, chronic alcoholism.

Agents responsible for acute viral hepatitis :

1. Hepatitis A, B, C, D and E.
2. Yellow fever virus.
3. Epstein-Barr virus.
4. Cytomegalovirus.
5. Herpes simplex virus.
6. Coxsackie B virus.

* Other infective causes of acute hepatitis are : non-viral—leptospira (Weil's syndrome), toxoplasma and coxiella; post-viral—Reye's syndrome in children (aspirin-induced).

Features of different types of viral hepatitis (A to E) :

Type A :

1. Transmission—Faecal-oral route commonly (percutaneous and sexual route—uncommon).
2. Age—Children and young adults.
3. Seasonal influence—In winter and rainy seasons.
4. Incubation period—15 days to 45 days (mean 30 days).
5. Severity—Generally mild.
6. Chronicity—Never occurs.
7. Prognosis—Excellent.
8. Carrier state—Never occurs.
9. Australia antigen (HB_sAg)—Negative.
10. Peak ALT—800 to 1000 IU/L.

Type B :

1. Transmission—Usually parenteral (also sexually transmitted).
2. Age—Any age group may be affected (young adults, babies, toddlers).
3. Seasonal influence—Occurs round the year.
4. Incubation period—30 days to 180 days (mean 60-90 days).
5. Severity—Occasionally severe.
6. Chronicity—Occurs in 1-10% (90% of neonates).
7. Prognosis—Not bad but worse with increasing age.
8. Carrier state—Occurs (1-30%).
9. Australia antigen—Positive.
10. Peak ALT—1000 to 1500 IU/L.

* Humans are the only source of infection. HB_sAb is protective.

Type C :

1. Transmission—Parenteral (sexual transmission uncommon).
2. Age—Any age may be affected (common in adults).
3. Seasonal influence—Occurs round the year.
4. Incubation period—15 days to 160 days (mean 50 days).
5. Severity—Moderate.
6. Chronicity—Commonly occurs (85%).
7. Prognosis—Not good, not bad (moderate).
8. Carrier state—Exists (0.5-1%).
9. Australia antigen—Negative.
10. Peak ALT—300 to 800 IU/L.

* Accounts for more than 90% of post-transfusion hepatitis. Anti-HCV is not protective.

Type D (Delta virus) :

1. Transmission—Commonly parenteral (also sexually transmitted).
2. Age—Any age (as type B virus).
3. Seasonal influence—Occurs round the year (as type B virus).
4. Incubation period—30 days to 180 days (mean 60-90 days).
5. Severity—Occasionally severe.
6. Chronicity—Commonly occurs.
7. Prognosis—Good in acute variety, poor in chronic variety.
8. Carrier state—Variable (10-20% in pregnant women).
9. Australia antigent—Positive (as there is 'coinfection' with or 'superinfection' on type B).
10. Peak ALT—1000 to 1500 IU/L.

* Delta virus requires hepatitis B virus for replication i.e., it has no independent existence.

Type E :

1. Transmission—Only by faecal-oral route.
2. Age—Young adults.
3. Seasonal influence—Commonly after monsoon and flood but sporadic, isolated cases occur.
4. Incubation period—15 days to 60 days (mean 40 days).
5. Severity—Usually mild.
6. Chronicity—None.
7. Prognosis—Good (mortality is very high in women in the last trimester of pregnancy).
8. Carrier state—Does not exist.
9. Australia antigen—Negative.
10. Peak ALT—800 to 1000 IU/L.

* Faecal-oral route—Type A and E; Parenteral route—Type B, C, D.
Chronicity—Type B, C, D.

** Hepatitis C is the commonest cause of post-transfusion hepatitis.

*** Hepatitis A, B and C viruss are transmitted through saliva.

**** Type A and Type B hepatitis were previously known as infective hepatitis and serum hepatitis respectively. Hepatitis C and hepatitis D are also known as non-A non-B hepatitis and delta virus hepatitis respectively.

Describe hepatitis G virus (HGV) :

It is a RNA virus (hepatitis A, C, D, E and G are RNA virus; hepatitis B virus is a DNA virus). HGV is transmitted through blood transfusion (risk factors are like HCV). It is the sixth heterotropic viral agent. Extensive investigations have failed to show that HGV plays a causal role in acute or chronic liver disease and thus, it does not seem to be a serious human pathogen. HGV coinfection may improve survival in HIV infected patients.

Hepatitis TT virus (initials of name of a Japanese patient; DNA virus) is also unlikely to be a significant cause of liver diseases.

Type of jaundice in your case :

It is hepato-cellular jaundice.

Complications of acute viral hepatitis :

1. 'Serum sickness-like' syndrome (described previously).
2. Fulminant hepatitis (massive hepatic necrosis)—the most feared complication.
3. Cholestatic viral hepatitis (protracted cholestatic jaundice).
4. Relapsing hepatitis (biochemical/clinical)—return of symptoms and signs of acute hepatitis during recovery phase.
5. Post-hepatitis syndrome (symptoms persist though LFT remains more or less normal).
6. Chronic carrier state.
7. Chronic hepatitis (lobular, persistent and active).
8. Cirrhosis of liver (postnecrotic variety).
9. Hepato-cellular carcinoma.
10. Rare—Pancreatitis, myocarditis, aplastic anaemia, peripheral neuropathy, atypical pneumonia, transverse myelitis, papular acrodermatitis in childern, renal failure, polyarteritis nodosa.

Stages of acute viral hepatitis :

There are three stages :

1. Prodromal stage,
2. Icteric stage (i.e., stage of clinical jaundice), and
3. Recovery stage.

Clinical types of viral hepatitis :

1. Acute icteric hepatitis—common type.
2. Anicteric hepatitis.
3. Fulminant hepatitis.
4. Relapsing hepatitis.
5. Cholestatic hepatitis.
6. Post-hepatitis syndrome.
7. Chronic hepatitis.

What is anicteric hepatitis ?

Here, the jaundice is not clinically evident, and symptoms are few though the liver becomes enlarged and tender. It Is a mild illness though there is bilirubinuria and elevation of aminotransferases. These patients usually suffer from chronic liver disease (e.g., chronic active hepatitis) later in life. The diagnosis is difficult and requires a high index of suspicion.

Differential diagnosis you will consider in this case :

1. Differentiate among the 5 types of viral hepatitis (the present case suffers from type B infection. There is H/O receiving blood transfusion and urticaria, arthralgia at the onset of the disease).
2. Hepatic amoebiasis or amoebic liver abscess —
   a) H/O amoebic dysentery may be present.
   b) Liver is enlarged and very tender.
   c) Intercostal tenderness is present.
   d) Fever with chill and rigor, excessive sweating at night.
   e) Parient looks toxic.
   f) Jaundice, splenomegaly, marked anorexia are not very common features.
3. Alcoholic hepatitis—
   a) H/O chronic alcoholism.
   b) Stigmata of alcoholic liver disease (read the section on 'Cirrhosis of liver').
   c) Jaundice with enlarged, tender liver.
   d) Anorexia, weight loss.
4. Carcinoma of liver—
   a) Commonly affects middle aged or older persons.
   b) Progressive jaundice may be present (commonly in secondary malignancy of liver).
   c) Liver feels hard, tender and nodular.
   d) Anaemia, hard lymph nodes in neck and cachexia are prominent features.
   e) Fever and splenomegaly are usually absent.
   f) Ascites is not uncommon.
5. Drug-induced hepatitis—
   a) H/O intake of hepatotoxic drugs (rifampicin, INH, oral contraceptive pills).
   b) Malaise before onset of jaundice.
   c) Occasionally arthralgia, rash and fever are present.
   d) Liver is enlarged and may be tender.

   * It is often very difficult to differentiate this entity from acute viral hepatitis.
6. Haemolytic jaundice—
   a) Anaemia with mild jaundice.
   b) Freshly voided urine is acholuric (not yellow).
   c) Leg ulcers may be present.
   d) Typical fades may be revealed (vide Thalassaemia').
   e) Splenomegaly in almost all the cases.
   f) Non-tender liver, if at all palpable.
7. Congestive cardiac failure—
   a) Cardiomegaly with underlying heart disease.

b) Features of CCF.
e) Liver is enlarged, soft and tender.
d) Clinical jaundice is not commonly seen (latent jaundice may be present).

8. Acute malaria—
   a) Fever with chill and rigor. Typical paroxysm with cold, hot and sweating stage.
   b) Anaemia.
   c) Anorexia and jaundice are not so common.
   d) Splenomegaly is more prominent than hepatomegaly.
9. Cirrhosis of liver—
   a) Long H/O dyspeptic symptoms.
   b) H/O G.I. bleeding.
   c) Signs of portal hypertension and hepato-cellular failure.
   d) Liver is enlarged but non-tender.
   e) Splenomegaly.
10. Chronic hepatitis (see below).
11. Yellow fever, Weil's disease, infectious mononucleosis, obstructive jaundice etc.

Enumerate the causes of 'prolonged jaundice' :

Jaundice present for more than 6 months may be arbitrarily called as 'prolonged jaundice'. The common causes are,

1. Cholestatic viral hepatitis.
2. Chronic hepatitis.
3. Cirrhosis of liver.
4. Carcinoma of liver (secondary commonly).
5. Thalassaemia.
6. Drug-induced hepatitis (e.g., rifampicin, INH, chlorpromazine).
7. Extrahepatic biliary obstruction (e.g., stone, stricture, carcinoma of the head of pancreas).
8. Alcoholic hepatitis.
9. Wilson's disease.
10. Other causes like Gilbert's syndrome, primary biliary cirrhosis, hereditary spherocytosis, sickle cell anaemia, autoimmune haemolytic anaemia, sclerosing cholangitis etc.

* 'Prolonged jaundice' may be given as a long **case.**

Causes of enlarged and tender liver :

Read the section on 'Hepatosplenomegaly'.

What is cholestatic viral hepatitis ?

It is commonly associated with type A (more common) or type B infection. The jaundice gradually deepens and intense pruritus appears. Jaundice, hepatomegaly and LFT abnormalities may persist for many months but ultimately the recovery is complete (i.e., prognosis is good). It is often very difficult to differentiate this condition from surgical cholestasis (read the section on 'Jaundice').

Give an out line of chronic hepatitis ?

(***A*) *Definition***—

It is a chronic inflammatory reaction in the liver present on clinical or other grounds (biochemical/ serological) without improvement for more than 6 months.

(B) Aetiology—

1. Autoimmune hepatitis.
2. Hepatitis B, C, and D.
3. Drugs (methyl dopa, INH, oxyphenisatin, ketoconazole, nitrofurantoin).
4. Wilson's disease, a,-antitrypsin deficiency, alcoholic liver disease, non-alcoholic steatohepatitis (NASH) and ulcerative colitis.
5) Cryptogenic.

(C) Types—

1. Chronic lobular hepatitis—Histology resembles unresolved acute viral hepatitis.

2. Chronic persistent hepatitis—The limiting plate between hepatocytes and portal zones is intact, and piecemeal necrosis is not seen. There is expansion of the portal zone by infiltration with mononuclear cells.
3. Chronic active hepatitis (severe form)—There is erosion of limiting plate, presence of piecemeal necrosis, formation of 'rosette' and 'bridging necrosis'; prognosis of this disease is very bad.

* No. 1 and 2 are milder forms.

** The above described 3 categories are not very helpful for prognostication. The new classification of chronic hepatitis is based on 1. Aetiology, 2. Clinical grade, 3. Histological grade (evidences of inflammation and necrosis), and 4. The stage (extent of fibrosis and reflects the level of progression of the disease).

(D) Clinical features—

1. Fatigue, malaise, anorexia, fever.
2. Failure to recovery from acute hepatitis.
3. Jaundice (persistent or intermittent).
4. Hepatomegaly with or without splenomegaly.
5. Signs of hepato-cellular failure.

(E) Diagnosis—

1. High bilirubin level with very high aminotransferase levels; prolonged prothrombin time.
2. Antinuclear factor (ANF), anti-smooth muscle antibody may be present.
3. Hypoalbuminaemia with hyperglobulinaemia (autoimmune variety).
4. *Liver biopsy—diagnostic (described above in 'Types').*

Association of lymphadenopathy with jaundice :

Think of :

1. Lymphoma.
2. Leukaemia (ALL).
3. Viral hepatitis (cervical and rarely epitrochlear).
4. Infectious mononucleosis.
5. Disseminated tuberculosis.
6. Disseminated carcinomatosis.

How do you like to investigate a case of viral hepatitis ?

1. Blood for TC, DC and ESR—Leucopenia, lymphopenia and neutropenia. Blood picture becomes normal as jaundice appears. Atypical lymphocytes (virucytes) may be seen. ESR is high in pre-icteric phase and returns to normal with jaundice.
2. Liver function tests—
   a) Serum bilirubin—High (in most instances the total bilirubin is equally divided between the conjugated and unconjugated fraction, or conjugated fraction is increased).
   b) SGOT (AST) and SGPT (ALT)—Increased (normal value is 10-40 IU/L).
   c) Prothrombin time—If increased, indicates extensive hepato-cellular necrosis and a worse prognosis. Prothrombin time is the best prognostic indicator of hepato-cellular failure.
   d) Alkaline phosphatase—Slight increase (moderately increased in cholestasis; normal value is 35-130 IU/L).
   e) Serum proteins—Mild elevation of gamma-globulin is common in acute viral hepatitis.
3. Urine and stool examination—
   a) Urobilinogen in urine appears in pre-icteric phase, disappears as jaundice is evident and reappears with recovery.
   b) Bilirubin appears in urine before clinical jaundice develops.
   c) Rarely proteinuria may be present.
   d) Stool—May reveal steatorrhoea.
4. Serological diagnosis—
   a) HB_sAg (Australia antigen)—Positive in Type B (appears 6 weeks after infection and usually disappears by 3 months).
   b) Anti-HAV of IgM class — Positive in Type A variety.
   c) Anti-HCV (+ve after 6 weeks of infection; detected by third generation ELISA) and HCV RNA—Positive in Type C variety.
   d) Anti-HDV and anti-HEV antibody of IgM type are present in hepatitis D and E respectively.
   e) Serology for cytomegalovirus or Epstein-Barr virus.
5. Blood glucose level may be low (vomiting, i intake, poor hepatic glycogen).

6. Imaging—Ultrasonography (commonly used to differentiate other causes of jaundice) or CT scan of liver (USG is superior to CT scan).
7. Liver biopsy—Usually it is not required to diagnose acute viral hepatitis. It is important in differentiating cirrhosis, chronic hepatitis, drug-induced hepatitis from acute viral hepatitis.
8. Work-up to differentiate from cirrhosis of liver, alcoholic hepatitis (AST : ALT > 2 and high gamma-glutamyl transpeptidase), autoimmune chronic active hepatitis (enzymes >10 times and gamma globulin > 2 times of normal), hepatic amoebiasis (positive indirect haemagglutination test, chest X-ray) should be done.

N.B. : One should always search for K-F ring in the eyes in all cases of recurrent jaundice in young individuals (to exclude Wilson's disease producing cirrhosis of liver).

Common clinical differences between type A and type B infection :

Characteristics of type A infection are :

1. Fever may be high; > 102° F.
2. Onset Is very acute.
3. Cholestasis is more common.
4. Fulminant hepatitis is less common.
5. Less severity of illness with most patients making a complete recovery.
6. Post-hepatitis syndrome is more common.
7. No chronicity, no carrier state.
8. Simultaneous infection of other family members or persons in the same locality.
9. Serum sickness-like syndrome does not occur (very characteristic of type B).
10. Usually there is no past H/O blood transfusion, needle prick etc.

How to recognise that recovery has started in acute viral hepatitis ?

1. Appetite returns.
2. Stool becomes normal coloured (from white or clay colour).
3. Urine and eye become less yellowish.
4. Bilirubin and enzymes level return towards normal.

Who is a 'carrier' of type B infection ?

Persistence of HB_sAg for more than 6 months is known as 'carrier'.

How the ongoing infectivity and / or ***chronicity is diagnosed in type B infection*** ?

a) Ongoing infectivity (viral replication) is diagnosed by the presence of HB_eAg and positive serum HBV DNA.
b) Chronicity is diagnosed by the presence of positive serum IgG anti-HBc.

Discuss the post-exposure prophylaxis :

(A) Hepatitis A—It is often necessary for household and institutional 'intimate' contacts. Immune globulin is administered in a dose of 0.02 ml/kg of body weight by I.M route. Hepatitis A vaccine (Havrix) can be given (0.5 ml), I.M, in 2 doses at 0, 6-12 months in 2-18 years age group; over 18 years, it is given (1 ml) by 2 injections in the same schedule of 0, 6-12 months.

(B) Hepatitis B—
   (i) HBIG—0.5 ml (neonates) or 0.06 ml/kg (adults) as single dose immediately by I.M route, plus
   (ii) Hepatitis B vaccine (Engerix-B, hepavax)—3 doses (each of 1 ml) are given by I.M route (always in deltoids) at 0, 1 and 6 months; accelerated schedule of 0, 1, 2, and 12 months are also approved (preferred). Booster dose is not considered routinely (protection appears to be excellent in normal schedule) except in immunocompromised and haemodialysis patients.

(C) Hepatitis C or E—No available active or passive protection. Development of vaccine is in progress.

N.B. : Pregnancy is not a contraindication to vaccination against hepatitis B. Vaccination against hepatitis B will give protection from delta virus infection too. HBIG may be repeated at 4 weeks.

Indications for hepatitis B vaccination :

1. Surgical staffs, dental staffs and medical students.
2. Hospital and laboratory staffs in direct contact with blood.
3. Patients and staffs in haematology (haemophilia), oncology, and haemodialysis departments.
4. Mental subnoFmality (e.g., Down's syndrome).

5. I.V drug abusers.
6. Homosexually and bisexually active men; prostitutes; HIV infection or AIDS.
7. Babies bom to HB_gAg + ve mother.
8. Accidental exposure to HB_gAg + ve blood.
9. Close family and sexual contacts of HB_Ag + ve carriers.

* 1 to 6 require pre-exposure prophylaxis (0, 1, 6-month's schedule), and 7 to 9 require post-exposure prophylaxis (accelerated). In post-exposure prophylaxis, HBIG should be given along with the vaccine.

Who discovered Australia antigen ?

In the year 1965, Blumberg discovered the hepatitis B surface antigen (HB_sAG) and was awarded Nobel Prize for his discovery in 1977.

Diagnosis of hepatitis C virus infection :

1. Read the clinical characteristics mentioned earlier.
2. Serological test for HCV antibodies (anti-HCV) is usually positive after 6 weeks of infection.
3. Presence of HCV-RNA is detected by polymerase chain reaction (PCR). 1 -2 weeks after infection.

How will you manage your case ?

There is no specific treatment for acute viral hepatitis.

1. Bed rest with bathroom privileges till jaundice persists. Restrict physical activity.
2. Diet—Low-fat, high carbohydrate, high-calorie diet (a diet containing 2000-3000 Kcal should be given). The food must be palatable. Plenty of fluids to drink.
3. Avoid close physical contacts in acute stage. Avoid alocohol. sharing comb/rajors. Regular surveillance on clinical parameters as well as liver function tests is done. Reassurance, as recovery is the rule in majority.
4. Symptomatic treatment—
   a) Antiemetics—Domperidone, metoclopramide or ondansetron may be used.
   b) Sedatives—Should not be used. If the patient is very restless, oxazepam may be given.
   c) Vitamins—Parenteral injection of vitamin K, 10 mg by I.M route may be given for consecutive 3 days if prothrombin time is high. Other vitamin supplements are not necessary.
   d) Severe vomiting with fluid loss—10% dextrose drip may be given.
   e) Cholestyramine or UDCA (ursodeoxycholic acid) is advocated for intense pruritus from cholestasis. .
5. Treatment of hepato-cellular failure (e.g., in fulminant hepatitis) may be done accordingly.

* Steroids should not be used in acute viral hepatitis. Keep the patient on minimal drugs.

Patient of viral hepatitis becomes drowsy—significance :

Patient is going towards hepatic pre-coma (encephalopathy).

Case 15

Cirrhosis of Liver

What is your diagnosis ?

This is a case of chronic liver disease probably macronodular cirrhosis of liver with features of portal hypertension and hepato-cellular failure following type B hepatitis, and the disease is progressing.

* Chronic liver disease is defined as liver diseases persisting for more than 6 months.

Why do you say so ?

This is a case of cirrhosis of liver because :

(A) From history :

a) Fatigue, weight loss, flatulent dyspepsia, anorexia and low grade fever for last 6 months.
b) Haematemesis, melaena, swelling of legs and progressive distension of abdomen for last 10 days,
[c) Drowsiness, inversion of sleep rhythm for last 2 days (say, if present)].
d) Past H/O hepatitis B infection 12 years back.

(B) Physical examination :

a) General survey—

1. Malnutrition.
2. Anaemia—Moderate.
3. Jaundice—Mild.
4. Hepatic facies.
5. Oedema feet.
6. Obvious swelling of abdomen.
7. K-F ring in the eyes—Absent.
8. Flapping tremor—absent.

Systemic examination —

1. Abdomen—
   (1) Venous prominences over abdomen, specially in the epigastrium with flow of blood away from the umbilicus.
   (ii) Liver is 1 cm palpable, firm, non-tender with sharp and irregular margin; chiefly the left lobe is palpable (liver may not be palpable, specially in late stages, when it shrinks in size due to progressive hepatocyte destruction and fibrosis).
   (iii) Moderate, non-tender splenomegaly.
   (iv) Ascites—Confirmed by shifting dullness.
2. Skin changes—
   (i) Spider naevi.
   (ii) Palmar erythema.
   (iii) Diffuse pigmentation of skin.
   (iv) White nails or leuconychia (due to hypoalbuminaemia).
   (v) Scanty axillary and pubic hair.
3. Gynaecomastia and bilateral testicular atrophy (soft and small testes), [or atrophy of breast (females)].
4. Neurological changes—Nothing abnormal at present (say, if present).

Summary : This is a case of cirrhosis of liver because of—

- Long history
- H/O jaundice, haematemesis, melaena and oedema
- Poor nutritional status, and
- Features of portal hypertension and hepato-cellular failure.

What is your case ?

Build up the summary.

Importance of past history :

1. Jaundice (viral hepatitis).
2. Drugs (rifampicin, INH, anabolic steroids, OC pills; NSAID for melaena) or any herbal remedies taken.
3. Blood transfusion or transfusion of any blood products (viral hepatitis B or C; recent tattooing or acupuncture; drug abuse.
4. Alcohol consumption.
5. Tuberculosis (ascites due to tuberculous peritonitis).
6. Haematemesis or melaena (peptic ulcer, ruptured oesophageal varix, gastric malignancy).
7. Fever (tuberculosis, hepato-cellular failure etc).
8. Haematochezia (lower G. I. malignancy, haemorrhoids).

Queries in personal and family history :

Vide page 5 with special reference to alcohol intake. Dose of alcohol consumption, type of drink, daily/weekly pattern should be mentioned with duration. The patient takes mixed Indian diet Family history may be positive in Wilson's disease.

Importance of family history in ***alimentary system :***

- Similar illness in the family—acute diarrhoea, food poisoning and viral hepatitis.

- Genetic hepatic disorders—Wilson's disease, haemochromatosis and a,-antitrypsin deficiency.
- Familial polyposis coli, inflammatory bowel disease and carciroma of colon.

Features of portal hypertension :

1. Evidences of porto-systemic anastomosis (collateral circulation) at different sites :
   a) Lower end of oesophagus—Rupture of 'oesophageal varix' produces haematemesis and melaena.
   b) Around the umbilicus—Caput medusae (classical caput medusae is rare); and also in the anterior abdominal wall, specially in the epigastrium.
   c) Rectum and anal canal—Haemorrhoids.
2. Splenomegaly (single most bedside cardinal finding), and

3 Ascites.

* It is often said that fetor hepaticus is a feature of portal hypertension (due to porto-systemic shunting of blood) but it should be remembered that underlying hepato-cellular failure must be present. *Portal hypertension is unlikely if splenic enlargement can not be demonstrated clinically or by radiographically.*

****** Caput medusae—looks like Greek Goddess medusae's hair after minerva had turned it into snakes i.e., snakes radiated from head (caput) of Medusae.

Features of hepato-cellular failure :

1. General failure of health (loss of flesh).
2. Jaundice.
3. Skin changes (read the section on 'Palmar erythema' too)
   a) Spider naevi.
   b) Palmar erythema (liver palm).
   c) Diffuse pigmentation.
   d) White nails (due to hypoalbuminaemia).
   e) Clubbing (common in biliary cirrhosis).
   f) Loss of axillary and pubic hair (due to hyperoestrogenaemia); alopecia.
   g) 'Paper money' skin (usually on upper arms).
   h) White spots (arm and buttock).
4. Endocrine changes—
   a) Gynaecomastia (breast atrophy in females)
   b) Testicular atrophy (bilateral).
   c) Menstrual irregularities in females.
5. Bleeding manifestations—Petechiae, ecchymosis (chiefly due to hypoprothrombinaemia and sometimes due to low platelet count).

6 Fever (related to endotoxaemia with production of cytokines).

7. Fetor hepaticus (sweetish-faecal smell of the breath and urine due to methyl mercaptan derived from methionine; the smell resembles that of dead mouse).

8 Hepatic encephalopathy (disturbed consciousness with inversion of sleep rhythm, personality changes intellectual deterioration, psychiatric abnormalities with astenxis)—personality changes e.g., frritability and loss of family concern, and constructional apraxia i.e., inability to reproduce simple diagrams with blocks are common.

9. Ascites and bipedal oedema.
10. Circulatory changes—
    (A) Hyperkinetic circulation—
        a) Capillary pulsation.
        b) Bounding pulse (high pulse pressure with low diastolic BP).
        c) Tachycardia.
        d) Hyperdynamic apex.
        e) Ejection systolic murmur at the apex.
    (B) Cyanosis and clubbing—Due to development of pulmonary arteriovenous shunts.

* To diagnose a case of cirrhosis of liver, one should search for features of **both** portal hypertension and hepato-cellular failure. Pedal oedema (pitting) develops as a result of hypoproteinaemia, and ad - tional factor is functional IVC obstruction due to ascites.

** A female distribution of body hair may be seen in male cirrhotics (e.g., less frequent shav g).

*** Features accountable for both hepato-cellular failure and portal hypertension ; ascites and fetor hepaticus (according to some hepatologists).

What ascites indicates in cirrhosis of liver ?

It indicates hepato-cellular failure with portal hypertension, i.e., it is decompensated cirrhosis with portal hypertension.

Features of 'hyperoestrogenaemia' in hepato-cellular failure :

Diminished hepatic clearance of precursor androstenedione results in peripheral conversion to oesotrogen, and manifests as—

1. Spider naevi.
2. Palmar erythema.
3. Gynaecomastia (breast atrophy in females).
4. Bilateral testicular atrophy and infertility.
5. Loss of beard (H/O less shaving), axillary and pubic hair.
6. Menstrual irregularities.
7. Loss of libido.

Describe 'hepatic fades' :

1. Shrunken eyes.
2. Hollowed temporal fossa.
3. Pinched-up nose with malar prominence.
4. Parched lips.
5. Muddy complexion of skin (blending of pallor, jaundice and melanosis).
6. Shallow and dry face.
7. Icteric tinge of conjunctiva.

Hepatic fades is characteristic of chronic liver disease e.g., cirrhosis of liver.

How to narrate a complete diagnosis in cirrhosis ?

tA) Aetiological Alcohol, type B hepatitis, Wilson's disease etc.

(B) Morphological—Micronodular, macronodular or mixed nodularity.

(C) Functional assessment—

1. Portal hypertension.
2. Hepato-cellular failure.
3. Evolution—Progressing, regressing or stationary.

Morphological classification of cirrhosis :

(B) MlrRONnnmTJr 3 T i,n SlZC) ~Alcoholism' malnutrition, old age, anaemia, haemochromatosis.
defTdenc^ centemeter in size)-Post-HBV, Post-HCV, Wilson's disease, a, -antit-

(C) MIXED—Features both micro- and macronodular cirrhosis e.g., biliary cirrhosis.

** ^'Cronodular = Laennec's cirrhosis, and macronodular cirrhosis = postnecrotic or viral.
When regeneration is slow, micronodules are developed.

Special stigmata of alcoholic cirrhosis :

1. Bilateral enlarged parotids.
2. Gynaecomastia.
3. Testicular atrophy with loss of body hair.
4. Wasting of muscle mass, and
5. Dupuytren's contracture.

* 5nZargC? pfrotids are seen in suppurative parotitis, mumps, cirrhosis of liver, Sjogren's svndrome dirlfxs' (j°S1S' ^ VT1C °r lymphomatous deposits, post-operative patients, calculi, drug-induced (io-dides, guanethidine), parotid neoplasms or amyloidosis.

'Cirrhogenic[1] or danger dose of alcohol :

matelvl^f^vT6 consumption is > 80 g/day. Most alcoholic cirrhotics consume approxi-
inp Pha f 1 ?,r f ? years. ***A steady daily intake is more dangerous*** than intermittent drink
Chance of alcohol-related liver damage is less if the intake is below 40 g/day imermiUent dnnk

Alcohol equivalents :

Whisky	30 ml	=	10 g.
Country liquor	45 ml	=	10 g.
Wine	100 ml	=	io g.
Beer	250 ml	=	io g.

Aetiology of cirrhosis of liver :

1. Alcoholic.
2. Biliary (primary or secondary).
3. Cryptogenic (when no aetiology can be determined).
4. Postnecrotic or postviral (HBV, HCV, HDV).
5. Cardiac or congestive.
6. Metabolic—Wilson's disease, haemochromatosis, type IV glycogenosis, o^-antitrypsin deficiency, galactosaemia, cystic fibrosis.
7. Drugs—Methotrexate, amiodarone, methyldopa, halothane.
8. Miscellaneous—
   (i) Indian childhood cirrhosis.
   (ii) Budd-Chiari syndrome.
   (iii) Intestinal by-pass surgery.
   (iv) Autoimmune hepatitis (lupoid).
   (v) Non-alcoholic steatohepatitis (NASH).
   (vi) Primary sclerosing cholangitis.

Compensated and decompensated cirrhosis :

Chronic liver disease usually passes through a long period of minimum non-specific symptoms like fatigue, flatulent dyspepsia, anorexia—known as 'COMPENSATED' cirrhosis; and appearance of ascites, jaundice, encephalopathy, G.I. bleeding and pre-coma are known as 'DECOMPENSATED' cirrhosis.

Examination of eye in cirrhosis :

1. Icteric tinge (jaundice).
2. Anaemia.
3. Bitot's spot.
4. K-F ring.
5. Subconjunctival haemorrhage (due to hypoprothrombinaemia).

* Always search for K-F ring in a patient with cirrhosis of liver, specially in younger cirrhotics.

Sites for varices :

1. Lower end of oesophagus (commonest).
2. Gastric varices.
3. Colo-rectal.
4. Rarely, duodenal.

Describe the 'liver' in cirrhosis :

The liver may not be palpable in the presence of ascites. Usually the liver is,

1. Palpable, 1 cm below the right costal margin at right MCL (often the left lobe is better palpable in the epigastrium) and moving with respiration. The liver is enlarged in early cirrhosis and may be shrunken in advanced disease.
2. **Firm in consistency.**
3. **Sharp and irregular margin.**
4. Surface is finely irregular (portal or Laennec's cirrhosis) or coarsely irregular (postnecrotic).
5. Non-tender.
6. Upper border of liver dullness may be lowered (in 6th or 7th ICS at right MCL).
7. No bruit.
8. No rub.
9. No pulsation.

* There is **moderate splenomegaly in cirrhosis.**

Aetiology of portal hypertension :

(A) Pre-sinusoidal :

a) EXTRAHEPATIC **(portal vein thrombosis** or extrahepatic obstruction or EHO)— '
   1. Umbilical sepsis in neonates.
   2. Portal pyaemia.
   3. Exchange transfusion in neonates.
   4. Oral contraceptives, pregnancy.
   5. Abdominal trauma.

6. Portal lymphadenopathy (lymphoma, metastasis).
7. Hyperviscosity syndrome (myeloproliferative disorders).
8. Malignancy of liver and pancreas.
9. Protein C or S deficiency, antithrombin III deficiency, factor V Leiden.
10. Secondary to cirrhosis of liver.
11. Idiopathic,

b) INTRAHEPATIC—

1. Schistosomiasis.
2. Congenital hepatic fibrosis.
3. Sarcoidosis.
4. Lymphoma.
5. Leukaemic infiltrations.
6. Primary biliary cirrhosis.
7. Arsenic, vinyl chloride and copper intoxication.
8. Idiopathic portal hypertension.

(B) Post-sinusoidal :

a) INTRAHEPATIC (better known as 'intrahepatic parenchymal')—

1. Cirrhosis of liver (commonest cause of portal hypertension).
2. Acute alcoholic hepatitis.
3. Hypervitaminosis A.
4. Cytotoxic drugs.
5. Veno-occlusive disease (by Jamaica bush tea containing toxic pyrrolizidine alkaloids).
6. Partial nodular transformation of liver.
7. Metastatic malignancy of liver.

b) EXTRAHEPATIC—

1. Budd-Chiari syndrome (obstruction of hepatic veins at any site from efferent vein of the lobule to the entry of the IVC into right atrium)
   (i) Pregnancy.
   (ii) Oral contraceptives.
   (iii) Abdominal trauma.
   (iv) Malignancy of liver, kidney, adrenal, testis etc.
   (v) Membranous obstruction of IVC (webs, diaphragms).
   (vi) Hyperviscosity syndrome (myeloproliferative disorders).
   (vii) Thrombophilic states (antiphospholipid syndrome, protein C or S deficiency).
   (viii) Paroxysmal nocturnal haemoglobinuria.
   (ix) Right atrial myxoma.
   (x) Others—vasculitis (Behcet's disease), liver abscess, sickle cell disease.
   (xi) Idiopathic.
2. Constrictive pericarditis.
3. Severe right heart failure.

* Actually, sinusoidal causes of portal hypertension are 1, 2, 6 and 7 of (B)-a).

** Two rare causes of portal hypertension are tropical splenomegaly syndrome and haematological disorders with massive splenomegaly (increases hepatic blood flow).

*** In Budd-Chiari syndrome, there are added features of inferior vena caval obstruction (distended veins over flanks and back, plus gross pedal oedema) over and above portal hypertension and hepato-cellular failure.

Summary of aetiology of portal hypertension :

- Pre-hepatic—EHO i.e., portal vein thrombosis and splenic vein thrombosis
- Hepatic—
  a) Pre-sinusoidal—non-cirrhotic portal fibrosis
  b) Sinusoidal—cirrhosis of liver
  c) Post-sinusoidal—veno-occlusive disease
- Post-hepatic—Budd-Chiari syndrome, constrictive pericarditis

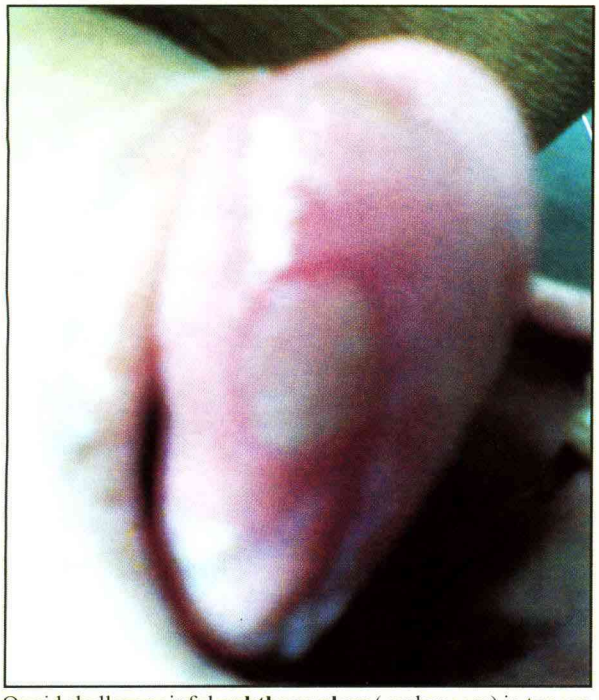

Ovoid shallow painful **aphthous ulcer** (canker sore) in tongue with a white centre and inflammatory halo

Ichthyosis (fish-scale skin) in extremities

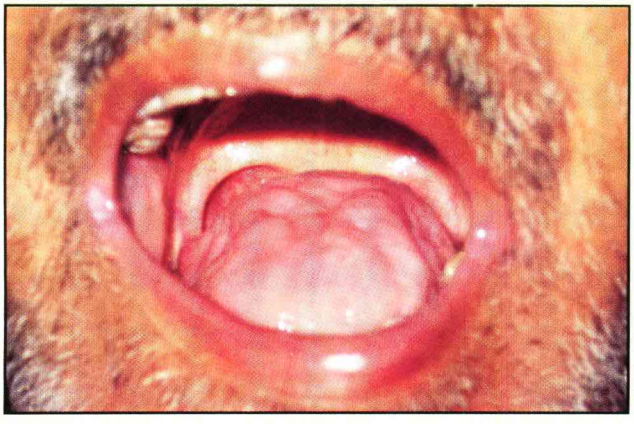

Flaccid and wasted **tongue with fasciculation** in bulbar palsy from chronic motor neurone disease

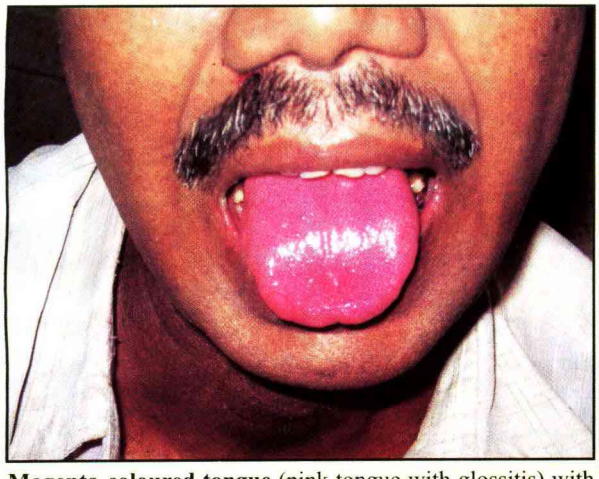

Magenta-coloured tongue (pink tongue with glossitis) with mild angular stomatitis in riboflavin deficiency

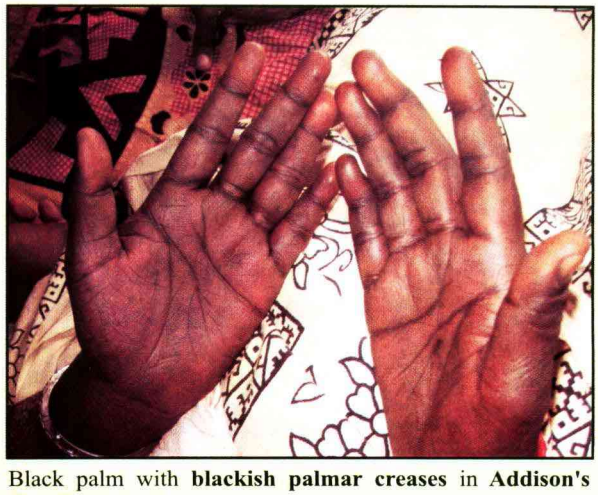

Black palm with **blackish palmar creases** in **Addison's disease**

Dermatomyositis with heliotrope (lilac-coloured) rash in eyelids, periorbital oedema, and purple pigmentation in forehead, nose, chest and upper arm

Systemic lupus erythematosus with classical 'butterfly' rash in the face

Scleroderma showing mask-like facies, pinched up nose, taut and shiny skin over the face. Pigmentation and depigmentation are also noted

A **leprosy** patient showing thickened skin of face and forehead, especially the infiltrated earlobes

Parotid enlargement by leukaemic deposits in right parotid gland in acute lymphoblastic leukaemia; pallor of the face can not be overlooked

What is non-cirrhotic portal fibrosis (NCPF) ?

NCPF is an intrahepatic pre-sinusoidal cause of portal hypertension. The disease is characterised by moderate to massive splenomegaly with anaemia, 'preserved hepato-cellular function' and a benign prognosis in majority though in the late stages, nodular transformation may occur. Though recurrent haematemesis is common and a presenting feature, hepatic encephalopathy is uncommon. Ascites is unusual in NCPF. Endoscopy reveals oesophageal varices, splenoportalvenography (SPV) shows massive dilatation of portal and splenic veins with presence of collaterals; liver biopsy demonstrates varying degree of portal fibrosis with maintained lobular architecture. The possible aetiologies are :

1. Idiopathic portal hypertension (previously known as Banti's syndrome),
2. Schistosomiasis,
3. Congenital hepatic fibrosis, and
4. Chronic arsenic ingestion (mainly through tube-well water; common in India and Bangladesh).

Features of extrahepatic obstruction (EHO) :

Patients presents at an earlier age (causes mentioned in page 123-124) with episodes of haematemesis and/or melaena, not accompanied by hepatic decompensation. Signs of stigmata of cirrhosis, jaundice, ascites, and hepatic coma from bleeding are uncommon. Liver is usually soft, if at all palpable There is massive splenomegaly with signs of portal hypertension. SPV demonstrates the collaterals and feeders vessels.

* Splenomegaly in different types of portal hypertension are :

a) Cirrhosis—moderate, b) NCPF—upto midline, c) EHO—massive.

What is NASH or NAFLD ?

Diffuse accumulation of neutral fat (triglycerides) in hepatocytes may give rise to mild to moderate enlargement of liver, and is known as non-alcoholic steatohepatitis (NASH) or non-alcoholic fatty liver disease (NAFLD). 'Fatty liver' is divided into 2 types :

1. Macrovesicular (large fat droplets in hepatocytes)—alcohol, obesity, diabetes mellitus, starvation. drugs (steroid, oesotrogen, amiodarone), total parenteral nutrition, jejunoileal by-pass, Indian childhood cirrhosis.
2. Microvesicular Reye's syndrome, acute fatty liver of pregnancy, drugs (tetracycline, valproate), toxins (yellow phosphorus).

Most patients are asymptomatic and may only complain of mild right hypochondriac discomfort. Hepatomegaly and mild elevation of aminotransferase are common. Fatty liver is reversible but if untreated there is chance of development of cirrhosis of liver (9-25%) in the long run. Insulin resistance is present in virtually all patients of NASH /NAFLD, and NAFLD is now considered as hepatic component of metabolic syndrome. Ursodeoxycholic acid (UDCA) and pioglitazone/rosiglitazone are used as pharmacotherapy of fatty liver. The patients are encouraged to lose weight.

Pain abdomen in cirrhosis :

1. Tuberculous peritonitis.
2. Spontaneous bacterial peritonitis (SBP) — infection of ascitic fluid without any obvious orimarv source of infection.
3. Peptic ulcer (common in cirrhotics).
4. Chronic cholecystitis (l/3rd of cirrhotics have pigment gall stones).
5. Portal vein thrombosis.
6. Pancreatitis (common in alcoholic cirrhosis).
7. Cirrhosis turned into hepato-cellular carcinoma (hepatoma).
8. Zieve's syndrome (haemolysis, pain abdomen, hyperlipidaemia in an alcoholic patient).

Fever in cirrhosis :

1. Tuberculous peritonitis.
2. Spontaneous bacterial peritonitis (SBP).
3. Hepato-cellular failure.
4. Transformation into hepatoma.
5. Associated chronic active hepatitis.
6. Tuberculosis (pulmonary or intestinal).
7. Other causes of fever like malaria, enteric fever etc.

Haematemesis and / or melaena in cirrhosis :

1. Ruptured oesophageal varices (commonest).
2. Peptic ulcer.
3. Portal hypertensive gastropathy.
4. Gastric erosion (NSAID-induced).
5. Rupture of gastric varices.
6. Mallory-Weiss tear.
7. Bleeding tendency.
8. Ulcer due to sclerotherapy.

* In approximately 50% cases, the source of upper G. I. bleeding in cirrhosis is from peptic ulcer or portal hypertensive gastropathy.

Definition of cirrhosis of liver :

Cirrhosis is a pathological term. It is the chronic and diffuse involvement of liver parenchyma of varied aetiology, and is clinically characterised by features of portal hypertension and hepato-cellular failure in varying combination, and pathologically by irreversible NECROSIS, extensive FIBROSIS as well as REGENERATIVE NODULE FORMATION in such a way that the normal architecture of liver is totally lost.

Importance of examination of other systems in cirrhosis :

(A) RESPIRATORY SYSTEM—
  a) Evidence of hydrothorax (commonly right-sided).
  b) Evidence of pulmonary tuberculosis (common in cirrhosis).

(B) CVS—Evidence of circulatory changes, already mentioned in 'features of hepato-cellular failure .

(C) NERVOUS SYSTEM—Neuropsychiatric manifestations of hepato-cellular failure (hepatic encephalopathy) are described below (see page 128).

(D) GENITOURINARY SYSTEM—
  a) Facial puffiness due to renal failure (hepato-renal syndrome) with oliguria.
  b) Testicular atrophy and loss of pubic hair.

Causes ***of haematemesis :***

(A) ***COMMON CAUSES :***

1. Chronic duodenal ulcer (commonest cause).
2. Erosive gastritis.
3. Variceal bleeding (ruptured oesophageal varices).
4. Chronic gastric ulcer.
5. Carcinoma of the stomach.
6. Mallory-Weiss syndrome.
7. Peptic oesophagitis.
8. Duodenal erosions.
9. Oesophageal carcinoma.
10. Hiatal hernia.

(B) LESS ***COMMON CAUSES :***

1. Leiomyoma and leiomyosarcoma of the stomach.
2. Lymphoma of the stomach.
3. Duodenal diverticula.
4. Blood dyscrasias (leukaemia, thrombocytopenia).
5. Anticoagulant therapy.
6. Rendu-Weber-Osler disease.
7. Pseudoxanthoma elasticum.
8. Uraemia.
9. Amyloidosis.
10.. Vasculitis.
11. Arteriovenous malformations or Dieulafoy's lesion.
12. Corrosive ingestion (e.g., strong acid or strong alkali).
13. 'Spurious' haematemesis (e.g., swallowed nose bleed).
14. Aorto-duodenal fistula; haemobilia.
15. Watermelon stomach (gastric antral vascular ectasia).
16.. Idiopathic.

* All the above mentioned causes may produce **melaena.**

** Dieulafoy's lesion—easily overlooked, small, superficial mucosal defect of stomach that involves an end artery which remains as large as its feeding artery -> pressure erosion of the epithelium by the vessel -> ultimately the vessel ruptures.

Describe the characteristic features of melaena :

Melaena is 'altered blood in stool' with the following characteristics :

1. Black tarry stool (due to production of acid haematin); sticky too.
2. Offensive (acid haematin is altered by bacteria).
3. Semisolid in consistency.
4. Red-coloured fluid comes out from the stool after addition of water in it.
5. Usually associated with vertigo, dizziness or syncopal attack during defecation.

Approximately 60 ml of blood is required to produce a single black stool and blood should remain at least 8 hours within the gut lumen to produce melaena. Haematemesis and melaena usually denote bleeding from the proximal gut **(proximal to the ligament of Treitz)** but bleeding from the lower gut may rarely produce melaena provided the gastrointestinal transit time is sufficiently prolonged. Occult blood test in stool may remain positive for seven days even after the colour of stool becomes normal. Majority of patients with haematemesis usually have melaena but less than 50% patients with melaena have haematemesis. Rarely, 'swallowed blood' may give rise to melaena (spurious) e.g., epistaxis.

What is haematochezia ?

It is the passage of bright red blood per rectum mixed with or without stool. It signifies bleeding from a source which is usually **distal to the ligament of Treitz.** The common examples of lower G. I. tract bleeding are haemorrhoids, anal fissure and fistula, trauma, proctitis, ischaemic colitis, ulcerative colitis, diverticulitis, polyp, malignancy of colon and rectum, angiodysplasia of colon, arteriovenous malformations, pseudomembranous colitis and 'gay bowel syndrome' in male homosexuals. Massive upper G.I. bleed may give rise to bright or dark red 'maroon' coloured stool, if there is hurried peristalsis or the transit time is reduced.

Causes of black stool :

1. Melaena.
2. Ingestion of iron (as a haematinic)—Usually associated with hard stool.
3. Ingestion of bismuth (in the treatment of chronic duodenal ulcer).
4. Intake of licorice, charcoal (used in treatment of poisoining) or black berries.

- No. 2, 3 and 4 stools are non-sticky, and often known as pseudomelaena.

Blood in stool—what are the different forms ?

1) Frank blood or haematochezia.
2) Altered blood or melaena.
3) Invisible blood or occult blood (detected chemically).

Intake of NSAID, hookworm infestation and colo-rectal cancer are common causes of occult blood in stool.

- Obscure G.I. bleeding—where the cause of G.I. bleeding (haematemesis, melaena and haematochezia) is not found after proper and extensive investigations.

Prerequisites for occult blood test (guaiac test) in stool :

Bleeding from G.I. tract may be intermittent and thus the test should be performed for several (usually three) consecutive days.

1. 3 days high-fibre and meat-free diet (to avoid false positive result) is advocated.
2. Patient should not have been taking vitamin C (may result in false negative test).
3. Intake of NSAID and iron should be stopped. The patient may avoid tooth-brush for 3 days.

Indications of blood transfusion* in *haematemesis and / or melaena :

Transfusion is required if,

1. Patient is in persistent shock.
2. There is H/O syncope.
3. Pulse rate is > 100/minute.
4. Systolic BP is < 100 mm of Hg.
5. Haemoglobin concentration is < 10 g/dl.

Definition of portal hypertension :

Portal vein is a 5.5-8 cm long vein formed by the union of superior mesenteric vein and splenic vein, behind the head of the pancreas at about the level of L_2 vertebra. Approximately, 2/3rd of hepatic blood flow and 1 / 2 of the 0_2 supply to the liver are provided by the portal vein.

Normal pressure in the portal vein is 7-10 mm of Hg or 10-15 cm of saline. Portal hypertension is defined as sustained elevation of portal pressure > 30 cm of saline (measured at surgery) or a direct percutaneous transhepatic portal vein pressure >12 mm of Hg.

How the oesophageal varices, caput medusae and haemorrhoids are formed in cirrhosis ?

- **Oesophageal varices :**
  - (A) Portal venous system—Left gastric vein, short gastric vein and posterior gastric veins communicate with,
  - (B) Caval venous system—Intercostal veins, diaphragmo-oesophageal vein and azygos minor vein.
- **Caput medusae (around umbilicus) :**
  - (A) Portal venous system—Paraumbilical veins communicate with,
  - (B) Caval venous system—Superficial veins of the anterior abdominal wall.
- **Internal haemorrhoids :**
  - (A) Portal venous system—Superior rectal vein communicates with,
  - (B) Caval venous system—Middle and inferior rectal veins.

'Predictors' of bleeding from varices and variceal 'grading' :

(A) Best predictors of bleeding from varices are :

1. Size of the varix (larger the size, the more likely it is to bleed),
   * 2. Presence of red signs (red colour correlates with the flow of blood through the varix), and
3. Hepato-cellular function (hepatic failure promotes bleeding).

(B) Grading of varices (endoscopic) :

1. Grade 1 — the varices can be easily depressed by the endoscope.
2. Grade 2 — the varices can not be depressed by the endoscope.
3. Grade 3 — the varices are confluent around the circumference of the oesophagus.

* 'Cherry-red spots' viewed on endoscopy suggest imminent rupture of varices.

What is Child-Pugh classification in cirrhosis ?

In cirrhosis, Child's grade is used to assess the hepato-cellular function. The determining 5 factors are : serum bilirubin, serum albumin, ascites, hepatic encephalopathy and prothrombin time. Every patient is assigned a class (A, B and C). Class A is 'prognostically' better and class C is the worst. Child-Pugh scoring system (scores 5-15 encompassing class A, B, C) is used to assess prognosis and is a reliable predictor of survival.

Anaemia in cirrhosis :

The possible explanations are—

1. Haematemesis and/or melaena.
2. Anorexia producing malnutrition.
3. Malabsorption.
4. Hypersplenism.
5. Haemolysis in alcoholic cirrhosis (along with hyperlipidaemia, it is known as Zieve's syndrome).

Jaundice in cirhosis :

1. Impaired bilirubin metabolism (commonest).
2. Intrahepatic cholestasis.
3. Haemolysis (rare).
4. Viral hepatitis from blood transfusion (given to combat haematemesis or melaena).

How to suspect that cirrhosis has transformed into hepatoma ?

1. Rapid deterioration of general health.
2. Pain in right upper abdomen appears; fever may be there.
3. Rapidly developing huge ascites, not responding to conventional therapy.
4. Progressive hepatomegaly with hard and nodular liver.
5. Bruit may be audible (due to T vascularity); rub is not uncommon.
6. Increase in serum alkaline phosphatase and a-fetoprotein.

Features of hepatic encephalopathy :

(A) STAGE OF PRE-COMA :

a) Symptoms—

(i) Alteration in behaviour (may be restless or violent initially).
(ii) Impairment of memory and other intellectual functions.
(iii) Inability to concentrate, apathy, slowness and brevity of response.
(iv) Inversion of sleep rhythm (daytime sleep with arousal at night) and hypersomnia (one of the early changes).
(v) Change of personality.
(vi) Drowsiness, disorientation and confusion.
(vii) Slurred and monotonous speech.
(viii) Rarely, convulsions.

b) Signs—

(i) Higher function—Disorientation in time, place and person; dysarthria.
(ii) Flapping tremor (asterixis); handwriting—Micrographia.
(iii) Constructional apraxia (elicited by positive Reitan trail-making test).
(iv) Rigidity.
(v) Ankle clonus—May be present.

(vi) Plantar response—Flexor.
(vii) Gait—Ataxic.

(B) STAGE OF HEPATIC COMA :

a) Patient is in deep coma.
b) Tone of muscles—Flaccid.
c) Jerks or deep reflexes—Absent.
d) Plantar response—Extensor.
e) Flapping tremor — Absent.

* EEG (electroencephalogram) shows symmetric high voltage triphasic waves changing down to the delta ranges (slow activity).

** 'Minimal' hepatic encephalopathy : few patients are clinically normal but show significant impairment in their psychometric performance and electrophysiological variables including the EEG.

Precipitating factors for hepatic encephalopathy in cirrhosis :

1. Gastrointestinal bleeding (from ruptured varices or peptic ulcer).
2. Excess protein in diet.
3. Overzealous use of diuretics (produces hypokalaemia alkalosis; NH_3 can not be converted into NH_4+; so, hypokalaemia is very dangerous in cirrhotic patient).
4. Infection (sepsis).
5. Surgery (even in an operation on a small abscess).
6. Paracentesis abdominis (volume > 3-5 litre).
7. Sedatives, hypnotics.
8. Acute alcoholic bout.
9. Porto-systemic shunts made surgically or formed spontaneously (large shunts).
10. Constipation; vomiting and diarrhoea (produces dyselectrolytaemia).
11. Uraemia.

* Anaemia, hypoxia, hypoglycaemia and hypotension are also important precipitating factors.

Aetiopathogenesis of hepatic encephalopathy :

The different hypothesis are :

1. Increase ammonia level in blood (most important)—$NH_{;1}$ combines with a-ketoglutaric acid in the Kreb's cycle and forms glutamic acid. So there is substrate deficiency in Kreb's cycle. NH_3 is the most readily identified toxin though it is not solely responsible for altered mental status.
2. Increase in short-chain fatty acids.
3. Rise in false neurotransmitters like octopamine.
4. Rise in methionine level.
5. Increased sensitivity of CNS neurones to gamma-aminobutyric acid (GABA), an inhibitory true neurotransmitter in the CNS.
6. Increased conversion of tryptophan to inhibitory neurotransmitter serotonin.
7. Ratio of aromatic amino acids (phenylalanine, tyrosine and tryptophan) to branched-chain amino acids (leucine, isoleucine and valine) is raised.
8. Excessive manganese deposition in the basal ganglia.
9. Increased circulating levels of endogenous benzodiazepines.

* Two general factors responsible for hepatic encephalopathy are liver failure and shunting of portal blood directly to the systemic circulation by-passing the liver.

** NH_3 also depresses cerebral blood flow and glucose metabolism.

Define fulminant hepatic failure :

It is a clinical syndrome resulting from massive necrosis of liver cells with sudden and severe impairment of hepatic function (it is virtually a medical hepatectomy). The definition usually includes a time frame of 12 weeks from the onset of jaundice, in patients without pre-existing liver disease.

1. Fulminant—hepatic failure develops within 2 weeks from the onset of jaundice.
2. Sub-fulminant—hepatic failure develops between 2-12 weeks of the appearance of jaundice.

Hepatic failure has been recently classified as,

a) Acute (0-4 wks)
   (i) Hyperacute (0-7 days),
   (ii) Acute (8 days - 4 wks)
b) Subacute (29 days - 12 wks)
c) Chronic (> 24 wks)

Common causes of acute (fulminant) hepatic failure :

The causes vary throughout the world and they are—

1. Acute viral hepatitis (commonest).
2. Drug-induced (halothane, rifampicin-INH combination, paracetamol overdose).
3. Mushroom or copper sulphate poisoning.
4. Weil's disease.
5. Acute Budd-Chiari syndrome.
6. Shock and multi-organ failure
7. Wilson's disease.
8. Acute fatty liver of pregnancy.
9. Reye's syndrome.
10. Autoimmune hepatitis.

D/D you like to consider in your case :

(A) On aetiological basis :

a) Cryptogenic cirrhosis—This term is now used interchangeably with postnecrotic cirrhosis (the case described at the outset) but the terminology should be reserved for the patients where the aetiology is not known (10% of all cirrhotics). Clinical presentation in both the types are almost same. In many cases of cryptogenic cirrhosis, unrecognised NASH/NAFLD may play a role.

b) Alcoholic cirrhosis—Male preponderance, H/O intake of alcohol in cirrhogenic dose (commonly one pint or more of alcohol taken daily for 10 years), jaundice is less persistent, mild ascites, alcoholic stigmata present, H/O pancreatitis and peptic ulcer; spleen is less commonly palpable.

c) Primary biliary cirrhosis—Commonly in middle-aged woman with persistent generalised pruritus, dark urine and pale stool, jaundice, clubbing, pigmentation, xanthelasma and xanthomas, gradual development of ascites, oedema and hepato-cellular failure.

d) Wilson's desease—Young patient with hepatosplenomegaly and K-F ring in cornea; neurological manifestations like chorea, slurred speech, tremor are not uncommon. Positive family history may be obtained.

e) Indian childhood cirrhosis—Age group is 6 months to 3 years, onset around first year of life with progressive distension of abdomen, irritability, low grade fever, firm liver with 'sharp leafy margin', splenomegaly with progressive hepato-cellular failure.

f) α_1-antitrypsin deficiency—Young age group, patient (PiZZ phenotype) usually suffers from respiratory distress due to emphysema or bronchiectasis along with chronic liver disease.

g) Secondary biliary cirrhosis—H/O previous surgery in biliary tract with H/O ascending cholangitis. There is presence of pain in the right hypochondrium. This type of cirrhosis results from partial or total obstruction of the CBD for more than one year. Other clinical features are like that of primary biliary cirrhosis.

(B) D/D done by :

a) Hepatomegaly.
b) Splenomegaly.
c) Ascites (never forget to make D/D with constrictive pericarditis).
d) Causes of haematemesis and melaena.
e) D/D of jaundice.

* Mention the D/D of your case according to the findings elicited and then apply your judgement. Cirrhosis of liver should be read along with the section on 'Ascites'.

What is cardiac cirrhosis ?

Prolonged passive venous congestion to liver from valvular heart disease, constrictive pericarditis or long-duration congestive cardiac failure may lead to cirrhotic changes in liver, and is known as cardiac cirrhosis. Clinical examination shows firm, non-tender and non-pulsatile hepatomegaly, features of right-sided heart failure, and stigmata of chronic encephalopathy with waxing and waning. This is a very rare cause of cirrhosis in clinical practice.

Can it be a case of carcinoma of liver ?

No. Characteristics of carcinoma of liver are :

1. Cachexia, loss of weight, very rapid course.
2. Large, tender, grossly nodular, hard liver with bruit or hepatic rub.
3. **Absence of splenomegaly.**
4. Jaundice is of variable degree (secondary carcinoma of liver may be present with jaundice; hepatoma usually presents without jaundice).
5. Ascites (often tender) with pedal oedema.
6. Neck glands may be palpable.
7. Usually there is no porto-systemic venous collaterals.

* Secondary carcinoma of liver is seen in the aged patients while hepatoma may affect persons between 40-50 years of age.

Nodular ***liver, jaundice, splenomegaly, ascites : can it be carcinoma of liver*** ?

In carcinoma of liver there is absence of splenomegaly. Rarely, this case may be a primary hepatocellular carcinoma (hepatoma) superimposed on cirrhosis of liver. Presence of splenomegaly indicates the origin from cirrhosis of liver.

Portal hypertension with massive splenomegaly :

Portal hypertension is usually associated with moderate splenomegaly. Massive splenomegaly may be seen in,

1. Extrahepatic obstruction (i.e., presinusoidal-extrahepatic causes).
2. Cirrhosis with hypersplenism.
3. Non-cirrhotic portal fibrosis (NCPF).
4. Rarely in tropical splenomegaly syndrome.

Complications of cirrhosis :

1. Portal hypertension (variceal bleeding, congestive gastropathy, hypersplenism etc.).
2. Hepato-cellular failure and hepatic encephalopathy.
3. Ascites and spontaneous bacterial peritonitis (SBP).
4. Hepato-renal syndrome (functional renal failure with normal tubular functions develop due to circulatory or haemodynamic changes).
5. Acute and chronic pancreatitis.
6. Cholecystitis with pigment stone.
7. Peptic ulcer.
8. Septicaemia (gram-negative) and tuberculosis.
9. Portal vein thrombosis.
10. Hepato-cellular carcinoma (hepatoma) as a late complication.
11. Coagulopathy (factor deficiency, thrombocytopenia).
12. Hepato-pulmonary syndrome (HPS).
13. Porto-pulmonary hypertension.
14. Haematological complications (anaemia, haemolysis, thrombocytopenia).

* Hepato-pulmonary syndrome (HPS)—Cirrhotics may be hypoxaemic due to hepato-pulmonary syndrome (due to intrapulmonary shunting through direct arteriovenous communications -> may be a result of NO overproduction), porto-pulmonary hypertension (pulmonary hypertension as a result of vasoconstriction and obliteration of pulmonary arterial system —• leading to dyspnoea and fatigue), and hydrothorax. HPS is manifested by orthodeoxia, breathlessness, clubbing, cyanosis and spider naevi.

How do you suspect that spontaneous bacterial peritonitis (SBP) has developed?

SBP is suspected by appearance of fever, abdominal pain, increasing ascites not responding to diuretics, diminished bowel sounds and appearance of features of hepatic encephalopathy. It is an acute emergency and should be treated urgently.

Sudden worsening (decompensation) of stable cirrhosis—reasons behind :

1. Consider the precipitating factors for hepatic encephalopathy e.g., bleeding, hypokalaemia.
2. Development of spontaneous bacterial peritonitis or tuberculous peritonitis.
3. Transformation into hepatoma.
4. Formation of chylous ascites as a result of rupture of dilated abdominal lymphatics.
5. Portal vein thrombosis.

Possible causes of death in cirrhosis :

1. Hepatic encephalopathy.
2. Cerebral oedema.
3. Intercurrent infection (septicaemia).
4. Respiratory failure.
5. Coagulopathy.
6. Renal failure.
7. Hypoglycaemia, hypokalaemia.
8. Acid-base imbalance.

Renal failure in cirrhosis :

Renal failure in a patient with hepato-cellular failure may De due to various factors, e.g.,

1. Acute tubular necrosis precipitated by infection, haemorrhage or drugs (e.g., neomycin),
2. If associated with primary kidney disease.

3. Hepato-renal syndrome—When there is change in blood volume or shifting of fluid within the body compartment, this syndrome precipitates. The syndrome is due to increased pre-glomerular vascular resistance and thus the blood flow is diverted away from the renal cortex with resultant reduced GFR. The kidney are structurally normal but functionally abnormal.

Investigations you like to perform in your case :

1. Blood examination—TC, DC, ESR, Hb%.
   a) Microcytic-hypochromic anaemia due to haematemesis and melaena.
   b) Pancytopenia may be seen in hypersplenism.
   c) ESR is increased in the presence of infection (like tuberculosis, SBP).
2. Stool for occult blood test—May be positive.
3. Rectal examination and proctoscopy for demonstration of internal haemorrhoids; slit-lamp examination of cornea for detection of K-F ring.
4. Chest X-ray—May show tuberculosis or hydrothorax.
5. Liver function tests—
   a) *Total protein is diminished with low albumin and high globulin.* Albumin and globulin ratio is altered (normal albumin level is 3.5-5.5 g/dl and that of globulin is 2-3.5 g/dl). lalbumin is due to impairment of hepatic protein synthesis whereas T globulin results from non-specific stimulation of reticulo-endothelial system.
   b) Serum bilirubin—Normal or raised.
   c) SGOT and SGPT (AST and ALT)—Mild elevation.
   d) Alkaline phosphatase—Slightly increased.
   e) Serum cholesterol—Low.
   f) Prothrombin time—Increased and does not return to normal level with vitamin K therapy (it is a very important 'prognostic marker' of hepato-cellular damage. Normal prothrombin time is 12-16 seconds). Increased prothrombin time is a bad prognostic sign.
6. Serum autoantibodies—antinuclear antibody, anti-smooth muscle antibody and anti-mitochondrial antibody may be present in varying percentage in autoimmune hepatitis, primary biliary cirrhosis and cryptogenic cirrhosis.
7. Serum immunoglobulins are increased, e.g., IgG in autoimmune hepatitis, IgA in alcoholic cirrhosis and IgM in primary biliary cirrhosis.
8. Barium swallow X-ray of oesophagus demonstrates 'worm-eaten appearance' (mutiple filling defects) at the lower part of oesophagus due to the presence of oesophageal varices. Sometimes, gastric varices may be seen by barium meal examination.
9. Endoscopy of upper G.I. tract—Shows oesophageal or gastric varices, peptic ulcer or congestive gastropathy (looks beefy-red: mosaic pattern of red and yellow mucosa with petechial haemorrhage). It is a very important and reliable primary investigation for portal hypertension.
10. Straight X-ray of abdomen—Usually not informative. It may show increased hepatic and splenic size or ground-glass opacity of ascites.
11. Examination of ascitic fluid—Transudate in nature if not complicated by tuberculosis or SBP. Serum-ascites albumin gradient (SAAG) is >1. lg/dl (indicates underlying portal hypertension).
12. Ultrasonography (or CT scan) of liver, spleen, portal vein (size), any collaterals, presence of thrombosis (in portal vein, splenic vein, hepatic vein, IVC), and for any free fluid in the abdomen—in cirrhosis of liver, there is heterogenous echo-pattern of liver, splenic enlargement, presence of ascites and increase in diameter of portal vein (>13 mm). USG is superior to CT scan in cirrhosis.
13. **Liver biopsy—The gold standard test and confirms the diagnosis of cirrhosis of liver** (by Vim-Silverman, Menghini or Trucut' needle). Biopsy specimen can be specially stained for copper and iron.
14. Percutaneous intrasplenic pressure measurement—increased in portal hypertension.
15. Percutaneous transhepatic portal venography or splenoportalvenography (SPV)—For the demonstration of site of obstruction and nature of collaterals. The intrahepatic pattern in cirrhosis is. known as 'tree in winter' appearance; 'cut off sign is observed in NCPF.
16. Wedged hepatic venous pressure—Increased in cirrhosis of liver (never increased in NCPF).
17. Special investigations where facilities are available :
    a) Visualisation of portal venous system by doppler ultrasound.

b) Duplex doppler for measurement of portal blood flow,

e) Portal venography by digital subtraction angiography.

18. Electroencephalogram (EEG)—Triphasic waves are seen in fulminant hepatic failure.

* Serum copper and ceruloplasmin estimation may be done for detection of Wilson's disease, serum iron for haemochromatosis, and serum a ^antitrypsin for aetiological diagnosis.

Management of cirrhosis of liver :

1. Rest—Absolute bed rest in decompensated stage (reduction of physical activity reduces metabolic demands of liver and increases the renal perfusion).
2. Diet—Salt-free high protein diet (> lg/kg/day). Protein is restricted judiciously at the onset of hepatic encephalopathy.
3. Treatment of infection by proper antibiotics. SBP is treated by co-amoxyclav (amoxycillin lg, clavulinic acid 200 mg, I.V, 8-12 hourly), or cefotaxime (1 g, I.V, 12 hourly) plus gentamycin (60 mg, I.V, 8 hourly), or piperacillin-tazobactum (4.5 g, I.V. 6 hourly) for 5-7 day.
4. Treatment of variceal haemorrhage by,
   a) Blood transfusion.
   b) Vasopressin, terlipressin, octreotide or infusion of somatostatin.
   c) Sengstaken tube.
   d) Endoscopic sclerotherapy of varices or band ligation.
   e) Transjugular intrahepatic portosystemic stent shunting (TIPSS).
   f) Lastly, oesophageal transection.
5. Treatment of hepatic encephalopathy by,
   a) Protein-restricted diet. Vegetable protein is less ammoniagenic, better tolerated and more laxative.
   b) Lactulose—10-30 ml three times daily (at least two to three semisolid stools per day). Lactitol may be used in lactulose-intolerant patients.
   c) Neomycin—4g/day or metronidazole 200 mg, QDS, orally daily for 5-7 days. Rifaximin (1200 mg/day) is also effective.
   d) Enemata : neutral phosphate, magnesium sulphate, mannitol; administer 8-12 hourly for 2-3 days.
   e) L-omithine L-aspartate (LOLA) given parenterally or orally promotes hepatic removal along with detoxification of NH_3.
   f) Maintenance of calorie, fluid and electrolytes.
6. Injection of vitamin K for coagulopathy—1 amp. of inj. vit. K, I.M daily for consecutive 3 days.
7. Judicious use of sedatives, if necessary—**safe sedatives** in liver disease are oxazepam, temazepam, heminervin, phenobarbitone etc (morphine or paraldehyde are absolutely contraindicated).
8. Management of ascites by paracentesis, diuretics; control of oedema.
9. Control of aetiological factors :
   a) Abstinence from alcohol intake.
   b) Penicillamine in Wilson's disease.
   c) Phlebotomy or desferrioxamine in haemochromatosis.
10. Management of fulminant hepatic failure in an 'intensive care unit' with experienced management team.

* Inj. ranitidine 50 mg, I.V, 6-8 hourly is given; dialysis is done for renal failure. Fresh frozen plasma is given if prothrombin time is > 1.5 times more than mormal.

** Safest analgesic in cirrhosis is paracetamol. Neomycin is available as 350 mg tablet and avoided in the presence of renal failure.

*** Gross protein restriction as first-line treatment is not recommended now-a-days as it may lead to deteriorating nutritional state in already malnourished patients.

**** Prevention of recurrent variceal haemorrhage is done by sclerotherapy, banding, TIPSS, propranolol and porto-systemic shunt surgery.

How lactulose acts in hepatic encephalopathy?

Lactulose is a synthetic disaccharide. In the caecum, it is broken down into acetic acid and lactic acid, and thus the fecal p^H drops. Its mechanism of action are ;

1. Produces acidic diarrhoea (acts as an enema or bowel wash).
2. As intestinal p^H is acidic, NH_3 absorption is less ($NH_{,i}$ is converted into NH_4^+).

3. Promotes incorporation of N_2 within the intestinal bacteria.
4. The drop in fecal P^H helps in the growth of lactose-fermenting organisms and suppresses the NH_3 forming bacterias (bacteroides).
5. It may detoxify short-chain fatty acids.

* Now-a-days, some clinicians use lactitol (30 g/day) instead of lactulose. Lactitol is available in powder form; it is less sweet, produces less flatulence and having quicker action.

Newer drugs in hepato-cellular failure :

a) Acute—Flumazenil (benzodiazepine receptor antagonist), I.V branched-chain amino acid, levodopa, L-ornithine-L-aspartate (LOLA), sodium benzoate, probiotics.
b) Chronic—Bromocriptine (dopamine agonist).

Drugs causing reduction of portal hypertension :

1. Vasopressin 2. Glypressin (terlipressin) 3. Somatostatin and octreotide 4. Propranolol (commonly used for prevention of recurrent bleeding) 5. Nitroglycerin 6. Nitrates, and 7. Verapramil.

Identification points for cirrhosis of liver :

1. Features of portal hypertension, and
2. Signs of hepato-cellular failure.

Always palpate the liver and spleen by 'dipping method' in the presence of ascites. *Splenomegaly is a very important bedside clinical finding to diagnose a case as cirrhosis of liver.* Never forget to examine for spider naevi, palmar erythema, gynaecomastia, scanty pubic hairs and testicular atrophy.

------ O------

Section 4

NERVOUS SYSTEM

The ***cardinal symptoms of nervous system*** comprise of :

(A) HIGHER FUNCTIONS :

1. Unconsciousness or alteration of consciousness, delirium, photophobia
2. Loss of memory; illusion, delusion or hallucination
3. Behavioural abnormality with speech defects

(B) CRANIAL NERVES :

1. Abnormal sensation of smell
2. Visual abnormality, diplopia (double vision), squint
3. Difficulty in mastication; loss of sensation over face
4. Deviation of angle of the mouth: facial asymmetry: epiphora
5. Loss of taste sensation
6. Vertigo, deafness, tinnitus
7. Nasal intonation or regurgitation
8. Hoarseness of voice
9. Dysphagia
10. Wasting of tongue, dysarthria

(C) MOTOR SYSTEM :

1. Loss of power or weakness, or clumsiness of movements*
2. Wasting / thinning, or swelling (pseudohypertrophy) of limbs
3. Fasciculation
4. Flexor spasms
5. Abnormal (involuntary) movements
6. Pain in the muscles
7. Unsteady gait

(D) SENSORY SYSTEM :

1. Anaesthesia
2. Paraesthesia
3. Tingling or numbness
4. Analgesia
5. Hyperaesthesia, hypoaesthesia
6. Root pain
7. Girdle-like sensation
8. Sensation of walking on cotton wool (e.g., tabes dorsalis)

(E) INCREASED INTRACRANIAL TENSION (IIT) :

1. Headache
2. Vomiting (projectile)
3. Convulsions
4. Blurred vision
5. Behavioural changes
6. Coma

(F) CEREBELLAR SYSTEM :

1. Swaying while walking, unsteadiness of gait or H/O falling (ataxia)
2. Weakness (as a result of hypotonia)
3. Difficulty in shaving, taking food to mouth and incoordination of speech
4. Tremor of hands while reaching for objects

(G) AUTONOMIC NERVOUS SYSTEM (INCLUDES BLADDER AND BOWEL FUNCTION) :

1. Retention of urine; feeling of sensation of bladder fullness
2. Incontinence (overflow or true)
3. Precipitancy
4. Hesitancy
5. Burning micturition [(signifies UTI); H/O catheterisation]
6. Impotence
7. Diarrhoea or constipation
8. Abnormal sweating (increased or diminished)

* For other features of autonomic nervous system, read the section on Trophic changes'

(H) MISCELLANEOUS :

1. Fever (meningitis, brain abscess)
2. Pain in the neck (meningitis, subarachnoid haemorrhage, cervical spondylosis)
3. H/O fall or seizure (epilepsy): H/O migraine; head injury; faintness (pre-syncope)
4. Psychological changes like depression or euphoria, agitation, sleep disorder
5. Discharge of pus from the ear (e.g., bacterial meningitis)
6. Bleeding tendency (e.g., thrombocytopenia)
7. H/O birth injury or anoxic injury

* Regarding **loss of power** in **the motor system,** enquire about involvement of :

I. Upper limbs —
   a) Proximal (lifting of arm above the head, combing, placing an object on a high shelf).
   b) Distal (writing, sewing, typing or objects falling off the hand).

II. Lower limbs —
   a) Proximal (climbing upstairs and going downstairs, squatting and getting up from squatting position).
   b) Distal (slipper falling from the feet).

III. Trunk muscles—Ask the patient to sit up from supine position.

Moreover, ask about the ability of standing (with or without support), walking (with or without support), running etc. Predominant distal weakness is due to pyramidal tract involvement or peripheral neuropathy.

** Anaesthesia—loss of sensation, paraesthesia—tingling sensation (may be so intense as to be painful), analgesia—loss of pain sensation, hyperaesthesia—increased touch sensation, hyperalgesia increased pain sensation, allodynia—perception of pain evoked by non-painful stimulus, hyperpathia—perception of pain that spreads out and outlasts the stimulus in time.

Scheme of Examination

(A) WHETHER THE PATIENT IS CONSCIOUS. ALERT AND CO-OPERATIVE :

(B) HIGHER FUNCTIONS :

1. Level of consciousness
2. Appearance and behaviour
3. Emotional state (euphoria, depression, hostile) i.e., the mood; sleep and dream.
4. Orientation with time, place and person
5. Illusion, delusion or hallucination
6. Memory
7. Intelligence
8. **Speech** (with handedness)

(C) CRANIUM and SPINE :

(D) NECK RIGIDITY. KERNIG'S SIGN. BRUDZINSKI'S SIGN. STRAIGHT LEG RAISING (SLR) TEST and EXAMINATION OF CAROTID ARTERIES :

(E) CRANIAL NERVES :

1. Olfactory—Test the smell sensation with common bedside objects like soap, toothpaste etc.
2. Optic—
   - (i) Acuity of vision
   - (ii) Field of vision
   - (iii) Colour vision
   - (iv) Ophthalmoscopy or fundoscopy (not done)
3. Oculomotor, trochlear and abducens—
   - (i) Ptosis
   - (ii) Squint
   - (iii) Enophthalmos or exophthalmos
   - (iv) Power of extraocular muscles—External ocular movements on follow and on command
   - (v) Nystagmus
   - (vi) Pupil— Size,
     Shape,
     Reaction (light reflex, consensual light reflex and accommodation reflex)
4. Trigeminal—
   - (i) Motor function (masseter, pterygoids and temporalis)
   - (ii) Sensory function (sensation over the face)
   - (iii) Corneal reflex—Right and left side
   - (iv) Jaw jerk
5. Facial—
   - (i) Palpebral fissure, frowning, symmetry of blinking, eye closure, nasolabial folds, angle of the mouth, blowing, whistling, showing the teeth, epiphora, dribbling of saliva
   - (ii) Power of individual facial muscle
   - (iii) Upper half of face escaped or not
   - (iv) Taste sensation of anterior 2/3rd of the tongue
6. Vestibulocochlear—
   - (i) Hearing—Watch test, Rinne's test, Weber's test
   - (ii) Positional nystagmus (not done)
7. Glossopharyngeal and vagus—
   - (i) Soft palate—Movements (on saying 'aah')
   - (ii) Pharyngeal or gag reflex
   - (iii) Taste sensation of posterior 1 /3rd of the tongue
8. Spinal accessory—
   - (i) Power of sternomastoids
   - (ii) Power of trapezius
9. Hypoglossal—
   - (i) Power of tongue muscles

(Ii) Deviation
(iii) Atrophy (size, shape, wasting)
(iv) Fasciculation (or any abnormal movement)

(F) MOTOR FUNCTIONS :

a) Nutrition (inspection and palpation of muscles)—Attitude, atrophy or hypertrophy etc.

	Right	Left
b) Tone—		
(i) Upper limb :	—	
(ii) Lower limb :	—	
c) Power—		
(i) Upper limb :	—	
(ii) Lower limb :	—	
d) Coordination—		
(i) Upper limb :	—	
(ii) Lower limb :	—	
e) Involuntary movements	—	

(G) SENSORY FUNCTIONS :

a) Superficial or exteroceptive—
(i) Pain
(ii) Touch
(iii) Temperature (hot and cold)—not done; a rough assessment may be carried out at the bedside by using the metal of a tuning fork or metal part of stethoscope (cold perception) and by rubbing both palms (hot perception)

b) Deep or proprioceptive—
(i) Vibration sense
(ii) Muscle sense
(iii) Pressure sense
(iv) Joint sense
(v) Position sense

c) Cortical—
(i) One point localisation
(ii) Two point discrimination
(iii) Stereognosis
(iv) Graphaesthesia
(v) Sensory extinction (perceptual rivalry)

* Is there a definite line of demarcation of sensory loss in the trunk ?

** Both fine and crude touch sensations should be tested.

(H) REFLEXES :

	Right	Left
a) Superficial—		
1. Abdominal		
(i) Upper	—	
(ii) Middle	—	
(iii) Lower	—	
2. Cremasteric	—	
3. PLANTAR RESPONSE —		
b) Deep—		
1. Biceps jerk	—	
2. Triceps jerk	—	
3. Supinator jerk	—	
4. Knee jerk	—	
5. Ankle jerk	—	
6. Clonus	—	

c) Visceral (sphincteric)—
1. Swallowing—The patient should be asked for dysphagia (with liquids, solids or both)
2. Bladder—The patient is asked regarding bladder and urethral sensation, retention, incontinence, urgency, or difficulty in controlling or initiating micturition

3. Bowel Whether facing any difficulty with defecation (constipation or incontinence). *Anal reflex* (gentle pricking of the skin on either side of the anus causes brisk contraction of the external anal sphincter which can be felt with a gloved finger at the anus; root value $S_{3,4}$) may be tested

d) Other reflexes—
   1. Glabellar tap
   2. Grasp reflex
   3. Palmo-mental reflex

(I) TROPHIC CHANGES :

Bed sore, trophic ulcer, Charcot joint, changes in skin and hair

(J) CEREBELLAR FUNCTIONS :

Titubation, scanning speech, pendular knee jerk, intention tremor, finger-nose test, dysdiadochokinesia, nystagmus and reeling gait

(K) AUTONOMIC FUNCTIONS :

Temperature regulation, postural hypotension, impotence, abnormal sweating, nocturnal diarrhoea Horner's syndrome, trophic changes.

(L) STANCE AND GAIT (including Romberg's sign) :

* **Peripheral nerves** (this may be an added point in neurology) are examined for thickening and tenderness. Commonly examined peripheral nerves are :

a) Great auricular nerve in neck
b) Ulnar nerve at elbow
c) Radial nerve at wrist
d) Common peroneal nerve at the neck of fibula
e) Sural nerve at the ankle

These nerves are commonly thickened in reference to leprosy. Read the causes of 'thickened peripheral nerves' from the section on 'Leprosy'.

Case 16

HEMIPLEGIA

What is your diagnosis ?

This is a case of left-sided complete hemiparesis (or hemiplegia) in the stage of recovery due to cerebral thrombosis probably involving the lenticulostriate branch of middle cerebral artery and the lesion is in the right internal capsule.

Why do you say so ?

This right-handed male patient aged 66 years was complaining of weakness of the left side of his body for last 15 days. At the onset when he was about to go to bathroom at about 5 a.m. he suddenly felt weak and could not move his left side. The episode was sudden in onset and the evolution of paralysis was completed within 6 hours. The patient complained of headache and vertigo at the beginning of the attack but neither he lost consciousness nor there was any difficulty in speech though there was some behavioural abnormalities present at that moment. He was immediately hospitalised. The patient also said that the weakness was marked in the left upper limb in comparison to left lower limb.There was no loss of bladder and bowel control. He had no H/O vomiting, convulsions, double vision, nasal regurgitation or nasal intonation; but he complained of deviation of face to the right side during eating, speaking or attempted smiling. Though the disease started acutely, he was gradually improving in the hospital.

There was no H/O fever, head injury. palpitation, chest pain, breathlessness, previous neurodeficit of this type which recovered completely (e.g., TIA); no family H/O diabetes mellitus, hypertension or tuberculosis was obtained. There was no H/O contact with tuberculosis, no H/O exposure to STD (sexually transmitted diseases). He did not give any H/O diabetes mellitus; a non-smoker by habit There was no H/O waxing and waning. For the last few days he was on physiotherapy.

On examination, it shows that the patient is conscious and co-operative. He is hypertensive but neither there is any valvular heart disease present nor there is presence of any bruit over the carotids. He is suffering from UMN paralysis of left upper and lower limbs including the paralysis of lower half of left UMN type of facial paralysis in the left) i.e., left-sided complete hemiparesis (or hemiplegia). The paralysis of left side of the body is suggested by the presence of clasp-knife spasticity, loss of superficial reflexes, brisk tendon reflexes and presence of extensor plantar response. The neurological examination of right side of the body was essentially normal.

What is your case ?

Say the summary as above.

Importance of 'past history' in hemiplegia :

1. Similar type of attacks or monoplegia in the past which recovered completely (indicates TLA).
2. Head injury (subdural haematoma).
3. H/O exposure to STD (neurosyphilis).
4. Hypertension (TLA, cerebral thrombosis or haemorrhage, lacunar infarction).
5. Diabetes mellitus (often associated with hypertension and accelerates the atherosclerosis).
6. Rheumatic fever (valvular heart disease and cerebral embolism).
7. Epilepsy (Todd's palsy) or migraine (neurologic migraine).
8. Tuberculosis (tuberculoma, tuberculous arteritis or tuberculous meningitis).
9. Intake of oral contraceptives with duration (may predispose to strokes in females, if used for more than 5 years), anticoagulants or aspirin; any bleeding tendency.
10. Fever (meningitis, cerebral abscess, encephalitis, leukaemia or lymphoma).
11. Dyspnoea or pain chest (mitral stenosis or recent acute myocardial infarction).
12. Intermittent claudication (atherosclerosis, arteritis).
13. Recent weight loss (tuberculosis).

* ***Todd's palsy*** — following epileptiform convulsions there may be development of paralysis (commonly monoplegia, rarely hemiplegia) due to exhaustion of cerebral neurones, and is known as Todd's palsy. Todd's palsy usually recovers within 24 hours.

Importance of 'family history' in hemiplegia :

1. Hypertension.
2. Diabetes mellitus.
3. Similar illness among other members of the family, specially in young patients (cerebral diplegia, spinocerebellar degeneration etc.)
4. Epilepsy or migraine.

Importance of 'personal history' in hemiplegia :

1. Obesity.
2. Sedentary habit.
3. Smoking.

Chief complaints (clinical presentations) of your patient :

1. Weakness of the left side of body for last 15 days,
2. Deviation of the face to right side while eating or speaking, for last 15 days, and
3. Difficulty in speech for last 15 days.

Enquiry regarding paralysis (in H/O present illness) :

(A) Date of onset : Note the specific date and time of onset of paralysis.

(B) Mode of onset : a) Sudden—Vascular, infective, traumatic and demyelinating

b) Gradual—Space occupying lesion (SOL).

N.B. ; (i) Cerebral embolism—develops in seconds (stormy).

(ii) Cerebral thrombosis—develops in minutes and hours.

(iii) Cerebral haemorrhage—very sudden in onset which relentlessly progress.

(iv) Infective—develops in hours and days.

(v) Demyelinating disease (multiple sclerosis)—develops in days and weeks.

(C) **Precipitating factors :**

(i) During sleep or soon after rising from bed—Cerebral thrombosis.

(ii) During exertion, activity—Cerebral embolism.

(iii) At the height of emotion—Cerebral haemorrhage.

(iv) During activity, exertion or height of emotion—Subarachnoid haemorrhage.

(v) Following fever—Cerebral abscess, encephalitis, meningitis.

(vi) Following convulsions—Todd's palsy.

(D) Evolution of paralysis :

(i) Paralysis extends over hours to days ('stroke in evolution').

(ii) Paralysis is 'total' or maximal from the beginning ('completed stroke')—Usually completed within 6 hours.

(iii) Increase in a step-wise manner i.e., repeated episodes of TIA leading to fully evolved stroke ('stuttering stroke').

(E) Progress of paralysis :

(i) Improving, stationary or deteriorating (a complete recovery usually indicates cerebral embolism or demyelinating disease).

(ii) Waxing and waning (means exacerbations and remissions)—In demyelinating diseases.

(F) Degree and duration of paralysis : Weakness or total loss of power, with duration.

(G) **Motor symptoms** : See the symptomatology.

Meaning offew terminologies in clinical neurology :

'Plegia' means complete or near complete paralysis, and 'paresis' means weakness or partial paralysis.

1. Hemiplegia : Paralysis of one half of the body (specially of face, arm and leg) i.e., it is a facio-brachio-crural paralysis. The trunk is exempted due to bilateral innervation.
2. Hemiparesis : Weakness of one half of the body (specially of face, arm and leg).
3. Paraplegia : Paralysis of both the lower limbs (mostly due to spinal cord lesion).
4. Paraparesis : Weakness of both the lower limbs.
5. Diplegia : Bilateral hemiplegia of cortical origin where the lower limbs are more affected than the upper limbs.
6. Quadriplegia or tetraplegia : Paralysis of all the four limbs, and also the trunk (a feature of cervical cord disease).
7. Monoplegia : Paralysis of one limb—
   (i) Brachial monoplegia—Paralysis of one upper extremity.
   (ii) Crural monoplegia—Paralysis of one lower extremity.
8. Crossed hemiplegia : Paralysis of ipsilateral cranial nerves (LMN type) with contralateral hemiplegia (a feature of brainstem disease).
9. Cruciate hemiplegia : Brachial monoplegia of one side with contralateral crural monoplegia.
10. Bi-brachial paralysis : Paralysis of both upper extremities.
11. Bilateral hemiplegia : paralysis of all the four limbs, trunk, and total face.
12. Paraplegia with right brachial monoplegia : 3 limbs are involved (triplegia) i.e., paralysis of right upper limb and both the lower limbs.

Features of upper motor neurone (UMN) and lower motor neurone (LMN) lesion :

UMN Pyramidal cells (generally the Betz cells of area 4) and their axons upto the cranial nerve nuclei or anterior horn cells are called UMN (i.e., corticobulbar or corticonuclear, and corticospinal tracts).

LMN—The anterior horn cells and its dendrite upto the motor end plate, and cranial nerve nuclei with the cranial nerves constitute the LMN. LMN is the final common pathway for all motor impulses, both voluntary and automatic.

Table 8 : Features of UMN and LMN palsy

	UMN palsy		LMN palsy
1.	Muscle groups or limbs are affected	1.	Paralysis of individual muscle supplied by that segment or nerve
2.	Paralysis of voluntary movements*	2.	Paralysis of muscles
3.	Wasting is minimal and usually due to disuse atrophy	3.	Atrophy and wasting are cardinal features
4.	Clasp-knife spasticity (hypertonia)	4.	Flaccidity (hypotonia)
5.	Fasciculation is absent	5.	Fasciculation may be present
6.	Power is less affected than LMN type	6.	Power is very much affected (may be Grade 0)
7.	a) Superficial reflexes — Lost or diminished b) Deep reflexes or jerks — Brisk c) Clonus—May be present	7.	a) Superficial reflexes—Lost b) Deep reflexes or jerks—Lost or diminished c) Clonus—Absent
8.	Trophic changes in skin—rare	8.	Trophic changes in skin—common
9.	**Plantar response—Extensor**	**9.**	**Plantar response—Flexor or no response**
10.	Reaction of degeneration in the muscles—Absent	10.	Reaction of degeneration—Present

* Actually, there is no paralysis of muscles in UMN palsy and it can be proved by the fact that the hemiplegic patient may run away from the room if the room suddenly catches fire.

What are 'strokes' ?

The term 'stroke' is used to identify all forms of cerebrovascular accidents (CVA). A stroke or CVA is defined as 'focal neurological deficit of abrupt onset due to a vascular lesion, lasting longer than 24 hours, and is manifested, either as brain infarction or haemorrhage'.

Diseases under CVA i.e., types of CVA :

1. Cerebral thrombosis.
2. Cerebral embolism.
3. Cerebral haemorrhage.
4. Subarachnoid haemorrhage.
5. Hypertensive encephalopathy.
6. Others (inobvious stroke)—Multiple sclerosis, Todd's palsy, cerebellar haemorrhage, venous sinus thrombosis, subdural or epidural haematoma, cerebral metastasis etc.

N.B. : ***Gradual onset hemiplegia*** occurs due to :

1. Cerebral tumour.
2. Chronic subdural haematoma.
3. Cerebral abscess.
4. Meningitis and encephalitis.
5. AIDS (due to toxoplasmosis or primary CNS lymphoma).
6. General paralysis of insane (GPI).

* Stroke may be haemorrhagic or ischaemic. Cerebral thrombosis and cerebral embolism result in cerebral ischaemia, and ultimately lead to **cerebral infarction.** Cerebral vasculitis (e.g., SLE) may also give rise to cerebral infarction. Cerebral infarction is the commonest cause of hemiplegia in the elderly. Cerebral infarction literally means death of brain tissue.

** 'Stroke mimickers' are multiple sclerosis, hemiplegic migraine, cerebral tumour or abscess, and head injury.

*** Stroke is a better term than CVA.

What is lacunar infarction ?

These are small, deep infarcts developed as a result of atherothrombotic or lipohyalinotic occlusion of perforating or penetrating arteries within the brain substance. The 'lacuna' (cavity after healing of infarction) measures 3 mm to 2 cm in diameter. The major risk factor remains hypertension. It may be present as 1) Pure motor hemipareisis, 2) Pure sensory stroke, 3) Ataxic hemiparesis, and 4) Clumsy hand, dysarthria syndrome.

Importance of examination of CVS in hemiplegia :

I. Method of examination :

1. Pulse—Rate, rhythm (regular or irregular), volume, condition of the arterial wall (thickened or not), comparison with opposite side, radio-femoral delay (whether there is any delay present or not, specially when the patient gives H/O intermittent claudication) and any special character.
2. Peripheral arterial pulses—
   - (i) **Carotids**—Kinking, diminished pulsation, or any bruit present over carotids or not.
   - (ii) Brachial—Locomotor brachialis (a feature of atherosclerosis).
   - (iii) Femoral,
   - (iv) Arteria dorsalis pedis, and
   - (v) Any bruit over the eyeballs (for arteriovenous malformation).
3. Blood pressure—High in cerebral haemorrhage and cerebral thrombosis (may be high in sub-arachnoid haemorrhage).
4. Jugular veins.
5. Apical impulse.
6. Heart sounds.
7. Murmur—Always search for a mitral diastolic murmur, specially in a patient with cerebral embolism.

II. Rheumatic heart disease—Cerebral embolism.

III. Hypertensive heart disease—TLA, lacunar Infarction, cerebral thrombosis and haemorrhage.

IV. Ischaemic heart disease—Mural thrombus may dislodge.

V. Subclavian steal syndrome—The patient complains of dizziness, diplopia, ataxia and/or collapse after use of one arm (no neurodeficit is produced but one should search for difference between pulse and BP in two upper limbs, and a bruit over the suprascapular area), resulting from stenosis of subclavian artery proximal to origin of vertebral artery. The syndrome results from stolen blood from the brain via the vertebral artery when the said arm is in use.

VI. Cyanotic congenital heart disease—May give rise to cerebral abscess, paradoxical embolism.

VII. Syphilitic heart disease—Tabes dorsalis and GPI (not seen now-a-days).

Different sources in the heart for cerebral embolism :

1. Atrial fibrillation (from IHD, MS or MI)—Left atrial thrombus may dislodge.
2. SBE (always search for mild splenomegaly).
3. Left atrial myxoma.
4. Right-to-left shunt in the heart (paradoxical embolism in Fallot's tetralogy).
5. Left ventricular thrombus or mural thrombus in recent acute myocardial Infarction.
6. Left ventricular aneurysm.
7. Mitral valve prolapse.
8. Prosthetic heart valve.

Special points in the physical examination in hemiplegia :

(A) GENERAL SURVEY :

a) The patient is conscious and co-operative.

b) Facies—Angle of the mouth is deviated to the right side on attempted talking.

c) Decubitus—Supine position in bed at present.

(i) Upper limb (left)—Flexed, adducted and semipronated; lying helplessly.

(ii) Lower limb (left)—Extended, adducted and plantiflexed; lying helplessly.

(iii) Right side (upper plus lower limbs)—Within normal limit.

d) Neck veins—neither engorged nor pulsatile.

e) Pulse—Mention all the points; condition of the arterial wall may be thickened.

f) BP—It is compulsory to record the BP in all long cases; it is better to record BP on non-paralysed limb to avoid recording of low BP due to vasomotor paralysis on paralysed side; 185/ 100 mm of Hg In the present case.

g) Respiration—Record rate, rhythm, type, depth and breathing pattern.

h) Temperature—Record the axillary temperature (do not take oral temperature in facial palsy).

i) Oedema—May present on the paralysed side due to prolonged immobility (1 venous + lymphatic flow) as well as affection of vasomotor nerves (reflex sympathetic dystrophy) .

j) Any obvious deformity—Absent.

* Mention all the points in general survey.

(13) NERVOUS SYSTEM :

a) The patient Is conscious, alert, oriented and co-operative.

b) Higher functions including speech : Mention all the subheadings like level of consciousness, appearance and behaviour, memory etc.—NAD (no abnormality detected) or WNL (within normal limit); a bit dysarthric; right-handed person.

c) Cranium and spine : Within normal limit.

d) Neck rigidity, Kernig's sign : Absent; carotids—Within normal limit.

e) Cranial nerves :

(i) Vllth cranial nerve—There is UMN type of paralysis on the left side of face as evidenced by,

Epihora (left).

Flattened nasolabial fold (left).

Deviated angle of the mouth (right) while showing teeth.

Weakness of buccinator, orbicularis oris, platysma (left).

Upper face on left side (frontal belly of occipitofrontalis, corrugator superciliaris and upper part of orbicularis oculi) escaped paralysis.

(11) Other cranial nerves—Fundoscopy for papilloedema. Mention the subheadings under the different cranial nerves : NAD.

Football-like **distension of abdomen by ascites** in cirrhosis of liver. Venous prominence of portal hypertension is also evident; distance between xiphisternum to umbilicus is more than distance between umbilicus to symphysis pubis

Divarication of recti (bulging of linea alba in between two recti) and Malgaigne's bulgings (abdominal wall bulging above the iliac crests due to poor tone of external oblique muscles) seen on attempted 'rising test'

Bilateral pitting pedal **oedema** in congestive cardiac failure

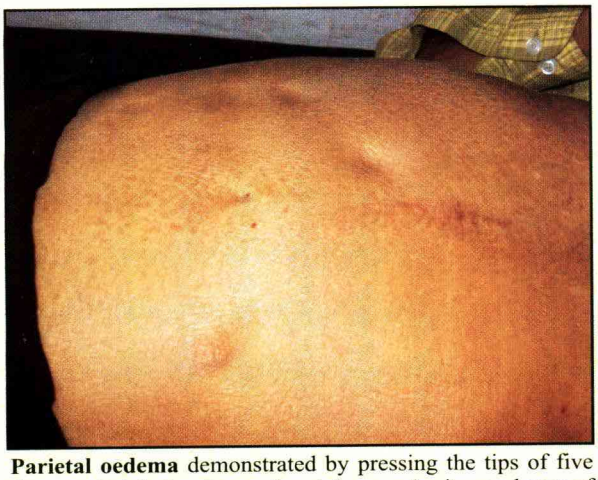

Parietal oedema demonstrated by pressing the tips of five fingers of right hand over the abdomen. Ascites and scar of past abdominal operation are also evident

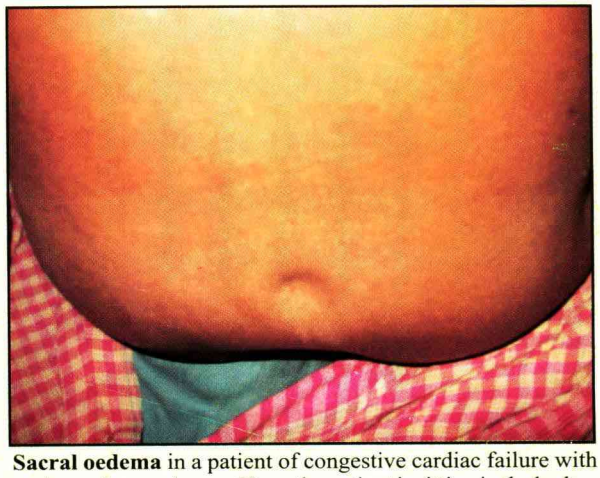

Sacral oedema in a patient of congestive cardiac failure with prolonged recumbency. Here, the patient is sitting in the bed.

Haemorrhagic spots like **petechiae, purpura** and **ecchymoses** are visible over anterior chest and abdomen in septicaemia

Shades of colours in **haemorrhagic spots** – bright red (fresh), blue (of some duration), and blackish-blue or black (old)

Herpes simplex virus infection **(herpes labialis)** leading to ulcerative stomatitis, in a patient recovering from meningitis

Purple striae developed after long-continued corticosteroid therapy

White striae noted after repeated paracentesis abdominis in ascites

f) Motor functions :

	Right	Left
(i) Nutrition	Normal. No wasting seen	Normal plus write down the attitude of left side from the 'Decubitus'. No wasting seen
(ii) Tone	a) Upper limb—Normal b) Lower limb—Normal	Clasp-knife spasticity in both the limbs. Flexor tone is increased more in upper limb and extensor tone is increased more in lower limb
(iii) Power	a) Upper limb—Grade V b) Lower limb—Grade V	Grade III in both the limbs
(iv) Coordination	a) Upper limb—Normal b) Lower limb—Normal	Could not be tested properly
(v) Involuntary movements	None	None

g) Sensory functions :

(i) Superfical
(ii) Deep — NAD
(iii) Cortical

* Mention the subheadings.

h) Reflexes :

(i) Superficial—

a) Abdominal—

x) Upper
y) Middle — Normal Lost
z) Lower

b) Cremasteric — Normal Lost

c) Plantar response — Flexor **Extensor**

(ii) Deep—

a) Biceps jerk
b) Triceps jerk
c) Supinator jerk
d) Knee jerk
e) Ankle jerk — Normal Brisk

f) Clonus — Absent Absent (say, if present)

(iii) Visceral—

a) Bladder
b) Bowel — Within normal limit
c) Swallowing

(iv) Other reflexes—

a) Glabellar tap — Normal
b) Grasp reflex — Absent
c) Palmo-mental reflex — Absent

i) Trophic changes : Absent.

j) Cerebellar functions : Within normal limit,

k) Autonomic functions : Normal.

1) Gait : Classical hemiplegic gait. The patient walks by tilting the pelvis while the left leg is making 'circumduction'. Read the section on 'Abnormal gait'.

(C) CVS : See the answer of the question 'Importance of examination of CVS in hemiplegia' mentioned earlier (write the points from 1 to 7 under I).

(D) RESPIRATORY SYSTEM :

(i) Shape of the chest
(ii) Movement of the chest
(iii) Trachea and apex beat
} within normal limit

(iv) Percussion—normal resonant note on both sides.
(v) Breath sound—vesicular.
(vi) Vocal resonance—normal on both sides.
(vii) Adventitious sound—none.

(E) G.I TRACT AND GENITOURINARY SYSTEM :

(i) Mouth, tongue, teeth, gum — NAD.
(ii) Shape of the abdomen — NAD.
(iii) Umbilicus — Inverted.
(iv) Rigidity — Absent.
(v) Hepatosplenomegaly — Not present.
(vi) Any lump felt — None.
(vii) Fluid thrill and shifting dullness—Absent. Percussion for bladder fullness done.
(viii) Auscultation — Normal peristaltic sound.
(ix) Genitalia — NAD
(x) P/R examination—not done.

(F) LYMPHORETICULAR SYSTEM :

(i) Lymphadenopathy — Absent.
(ii) Sternal tenderness — Absent.
(iii) Haemorrhagic spots — Absent.

Clinical types of hemiplegia :

1. Complete hemiplegia (with UMN type Vllth nerve palsy in the side of hemiplegia).
2. Incomplete hemiplegia (hemiplegia without affection of Vllth cranial nerve).
3. Crossed hemiplegia (when the site of lesion is in the brainstem) Ipsilateral LMN type cranial nerve paralysis (i.e., at the side of brainstem lesion) with contralateral hemiplegia.

Importance of headache, convulsions and coma (features of IIT) in strokes :

(A) HEADACHE—

(i) Severe headache accompanying the paralysis—Subarachnoid haemorrhage (occipital headache), cerebral haemorrhage, hypertensive encephalopathy.
(ii) Headache preceding the paralysis for months—SOL (space occupying lesion), subdural haematoma.
(iii) Mild headache—cerebral thrombosis or embolism.

(B) CONVULSIONS—

(i) Generalised convulsions preceding the paralysis—Todd's palsy (post-epileptic), hypertensive encephalopathy or SOL.
(ii) Focal or generalised convulsions occuring few months prior to paralysis — SOL.
(iii) Convulsions just prior to the paralysis may be seen in cerebral haemorrhage, thrombosis or embolism. Convulsions do not occur in subarachnoid haemorrhage.

(C) UNCONSCIOUSNESS—

1. From the beginning—Commonly cerebral haemorrhage.
2. In cerebral thrombosis, cerebral embolism, subarachnoid haemorrhage or hypertensive encephalopathy—Usually the patients remain conscious but may be drowsy.

What is projectile vomiting of increased intracranial tension (IIT) ?

It is the sudden vomiting which is not preceded by nausea (common in children).

Enquiry regarding the bladder and bowel symptoms in neurology :

Following questions are put to a hemiplegic or paraplegic patient :

1. Is there any increased frequency or urgency ?
2. Do you feel burning sensation during micturition ?
3. Is there any problem in initiation of micturition (hesitancy or precipitancy) ?

4. Can you feel the urine passing ?
5. Can you stop the flow of urine in the midstream at will ?
6. Is there any dribbling of urine ?
7. Is there any sense of bladder fullness ?
8. Is there any associated rectal disorder (incontinence of stool, diarrhoea or constipation etc) ? or any difficulty in anal sensation ?
9. Is there any disorder of potency (in males) ?
10. Have you ever catheterised in recent past ?

N.B. 1, 2, 3 and 10 are important in hemiplegia. In paraplegia, all the points are important.

Type of bladder involvement in your patient :

The chief complaint of the patient is burning micturition at present (seen in many cases) as he was catheterised on admission (and now suffering from UTI). There is no loss of bladder control.

Point out the signs of UMN lesion in your patient :

Demonstrate the points mentioned below :

1. Vllth cranial nerve—UMN palsy (as upper face on the left side escaped paralysis).
2. Power—Loss of power.
3. Tone—Clasp-knife spasticity (hypertonia).
4. Reflexes—
   a) Abdominal—Lost.
   b) Jerks—Brisk.
5. ***Plantar response—Extensor.***

- All the features are left-sided in this patient. Add clonus, if present.

Why there is Vllth nerve palsy (UMN type) in hemiplegia ?

Remember the principle : The Vllth cranial nerve nuclei are divided into upper and lower part by an arbitrary horizontal line, and the upper part supplies muscles of upper face while the lower part supplies the lower face. All cranial nerve nuclei are bilaterally supplied by pyramidal fibres (corticonuclear fibres) except the lower part of the Vllth cranial nerve nuclei which receive pyramidal fibres only from the opposite side. So the lower face is easily affected (i.e.. UMN type of Vllth nerve palsy) in a patient of hemiplegia.

Trunk and abdominal muscles in hemiplegia :

These are not involved in classical hemiplegia (lesion at internal capsule) due to their bilateral representation at the cortex.

- Abdominal muscles (T_5 - L,) : Do the 'rising test' and analyse "Beevor's sign".
- Intercostal muscles (T_rT_{12}) : During respiration, observe the movements of intercostals as well as the ribs.
- Extensors of spine (all segments of spinal nerve) : Patient lies prone and tries to raise his shoulder from the bed against examiner's resistance. Back muscles (e.g., erector spinae) are seen to contract.

Stages of hemiplegia and their clinical diagnosis :

1. Stage of neural shock (for few hours to days, and may extend upto 2-3 weeks).
2. Stage of recovery.
3. Stage of residual paralysis.

Diagnosis :

(A) STAGE OF NEURAL SHOCK (a stage when all reflex activity is suppressed) :

(i) Patient may be drowsy or in coma.
(ii) Aphasia.
(iii) Hypotonia of muscles or flaccidity with gross diminution of power.
(iv) Jerks are usually absent.
(v) Retention of urine and there may be spontaneous evacuation of faeces.
(vi) Plantar response—No response or equivocal.

(B) STAGE OF RECOVERY :

Recovery usually occurs in the following order :

(i) Face earliest.

(ii) Lower limb (first the extensors recover).
(iii) Upper limb (first the flexors recover).
(iv) Dorsiflexion of foot (minimally recovered).
(v) Finer movements of fingers (usually do not recover).

(C) ***STAGE OF RESIDUAL PARALYSIS :***

Patient lives with some residual paralysis and walks in classical hemiplegic gait. During recovery ol UMN lesion reflex recovers first, then comes tone and lastly power (proximal earlier than distal power). Plantar response maiy remain extensor on the affected side throughout life.

Importance of examination of cranial nerves in hemiplegia :

It helps in localisation of the site of lesion. The olfactory and optic nerves are actually built up of central nervous tissue rather than peripheral nerves. The disposition of other cranial nerve nuclei in the brainstem are as follows :

a) Midbrain — Illrd and IVth.
b) Pons - Vth, Vlth, Vllth and VUIth.
c) Medulla - IXth, Xth, Xlth and Xllth.

Different 'brainstem syndromes' are :

1. Weber's syndrome—Paralysis of Illrd crainal nerve of one side (LMN type) with contralateral hemiplegia (crossed hemiplegia)—lesion is at mldbrain.
2. Millard-Gubler syndrome—Paralysis of Vlth cranial nerve (LMN type) ± Vllth cranial nerve palsy (LMN type) with contralateral hemiplegia (crossed hemiplegia)—lesion is at pons.
3. Avellis syndrome—Paralysis of Xth cranial nerve of one side (LMN type) with contralateral hemiplegia (crossed hemiplegia)—lesion is at medulla.

* *Crossed hemiplegia always indicates the lesion in the brainstem.*

Importance of Vllth cranial nerve examination in hemiplegia :

It helps in localisation of the site of lesion in hemiplegia. For example :

a) UMN type of Vllth cranial nerve palsy in the side of hemiplegia (as this case is)—Lesion is 'above' the pons (opposite side).
b) LMN type of Vllth cranial nerve palsy with contralateral hemiplegia i.e., crossed hemiplegia (lesion is at Vllth cranial nerve nucleus)—Lesion is 'at' pons on the side of Vllth nerve palsy.
c) No facial nerve involvement (incomplete hemiplegia)— Lesion is below the level of pons.

* ***UMN type of Vllth cranial nerve palsy is always associated with same-sided hemiplegia while hemiplegia, if at all present with LMN type of Vllth cranial nerve palsy, is always crossed.***

Eye position in hemiplegia :

(A) Hemisphere lesion : eyes deviated towards the side of lesion in cerebral hemisphere.
(B) Pontine lesion : eyes deviated to the paralysed side.
(C) Putamen lesion : loss of conjugate lateral gaze.
(D) Thalamic lesion : loss of upward gaze, down or skew deviation, lateral gaze palsies, unequal pupil.

Functions of pyramidal and extrapyramidal system :

(A) Pyramidal tract—Helps in volitional movements, specially the skillful movements (movement of fingers and hands e.g., writing, buttoning, playing piano etc).
(B) Extrapyramidal tract—
  (i) Maintains muscle tone and posture.
  (ii) Maintains emotional, automatic and associated movements (i.e., swinging of the hands during walking).
  (iii) Checks abnormal involuntary movements.

Blood supply of the brain in a nutshell :

(A) Anterior cerebral artery (ACA)—Supplies branches to frontal and parietal lobes, to part of internal capsule; it also supplies the paracentral lobule i.e., the centre for movements of the lower limbs plus the centre for micturition and defecation.
(B) Middle cerebral artery (MCA)—Supplies the motor, sensory and speech areas.
(C) Posterior cerebral artery (PCA)—Supplies the visual cortex, occipital lobe and part of the temporal lobe; part of the posterior limb of the internal capsule.

Blood supply of the internal capsule :

(A) Anterior limb
- Upper half — MCA
- Lower half — ACA

(B) Posterior limb
- Upper half — MCA
- Lower half—Anterior choroidal and posterior communicating artery

N.B. : Pyramidal fibres take origin from Betz cells of cerebral cortex and descend towards corona radiata. While descending from corona radiata, pyramidal tract occupies the anterior $^{2}/_{3}$rd of the posterior limb of the internal capsule and genu. Anterior limb contains the fibres for the face while fibres for the tongue and mouth lies at the genu. Pyramidal fibres occupying the anterior $^{2}/_{3}$rd of the posterior limb continue downwards and occupy the middle $^{3}/_{\&}$th of the peduncles of midbrain. Then the fibres descend through pons and medulla, and majority of the fibres cross to the opposite side to occupy the lateral column in the spinal cord.

* As pyramidal tract has contralateral supply, hemiplegia occurs contralateral to the side of lesion in brain.

Features of anterior cerebral artery involvement :

If it is blocked 'distal' to the anterior communicating artery, there is :

1. Hemiplegia and hemisensory loss of the opposite side of body where lower limbs are much more involved (crural dominance) than upper limbs (in hemiplegia due to blocked middle cerebral artery, the weakness is more marked in upper limbs i.e., there is brachial dominance).
2. Face is not involved.
3. Urinary incontinence is very common.
4. Presence of mental symptoms (emotional disturbance).
5. Presence of'released reflexes'.

* If anterior cerebral artery is blocked 'proximal' to anterior communicating artery, there is development of complete hemiplegia (hemiplegia + face involvement) on the opposite side with or without aphasia.

** In Heubner's artery involvement (a branch of anterior cerebral artery), opposite sided facio-brachial (face + hand) paralysis occurs.

Possible sites of lesion in hemiplegia :

1. Cortical and subcortieal.
2. Internal capsule.
3. Brainstem.
4. Spinal.

Characteristics of each site of lesion :

(A) CORTICAL :

1. As the fibres are widely distributed, an extensive lesion (outcome is obviously grave) is necessary to produce contralateral hemiplegia. Usually cortical lesion produces **monoplegia.**
2. Jacksonian convulsions and headache are common at the onset. Speech abnormality is present.
3. Flexors and extensors of both the upper and the lower limbs are equally involved, and so the involvement of tone of muscles.
4. There may be cortical type of sensory loss (e.g., astereognosis).

(B) *SUBCORT1CAL (OR AT THE LEVEL OF CORONA RADIATA)* **:**

1. Subcortical lesion involves more fibres than the cortical lesion of equal size. Usually it produces **monoplegia** but hemiplegia on the opposite side may occur. There is absence of cortical signs like convulsions or dysphasia.
2. Involvement of adjacent thalamocortical fibres result in impairment of postural sensibility, tactile localisation and discrimination in the affected limbs.

(C) INTERNAL CAPSULE :

1. It is the most common site of lesion in a CVA.
2. As the fibres are densely packed, a small lesion may produce **complete hemiplegia on the opposite side.**

3. Hemianaesthesla and homonymous hemlanopia occur as a result of damage to the sensory and the visual fibres respectively which lie posterior to the pyramidal tract at internal capsule.
4. Global aphasia (in left-sided lesion) or * apractagnosia (in right-sided lesion).
5. Flexor tone is more in upper limb and the extensor tone is more in lower limb (in hemiplegic side). Classical position of the hemiplegic limb :
   a) Upper limb—Flexed (elbow, wrist and fingers), adducted and semipronated.
   b) Lower limb—Extended, adducted and plantiflexed.
6. Cranial nerve involvement—Only UMN type of the Vllth cranial nerve involvement on the side of paralysis, as discussed earlier.

* A type of agnosia marked by inability to use objects or perform skilled motor activities.

(D) BRAINSTEM :

1. Dizziness, vertigo and vomiting may be present.
2. Always **crossed hemiplegia.**
3. See the different brainstem syndromes discussed earlier and localise the site of lesion.
4. Gaze paralysis.
5. Change in pupil is common, even Horner's syndrome may be seen.
6. Involvement of the cerebellum may be there.

(E) SPINAL HEMIPLEGIA :'

Though rare, lesion lying below the medulla but above the C_5 spinal segment may produce **'ipsilateral' hemiplegia** (as the pyramidal fibres have already crossed in medulla) without any cranial nerve involvement (i.e., incomplete hemiplegia).

Classical features of cerebral thrombosis, embolism, haemorrhage etc :

(A) CEREBRAL THROMBOSIS :

1. Middle aged or elderly; commonest cause of CVA.
2. Very often hypertensive and atherosclerotic.
3. Onset is less rapid than cerebral embolism or haemorrhage; usually with step-wise progression.
4. Mild headache and convulsions may occur. There may be transient loss of consciousness.
5. Often there is past history of TLA (single or multiple).
6. Occurs during sleep or soon after rising from bed.
7. Carotid bruit with diminished pulsation highly supports cerebral thrombosis.

(B) CEREBRAL EMBOLISM :

1. Commonly in young females.
2. Valvular heart disease or sources of embolism (discussed earlier) may be evident.
3. Pulse may be irregularly irregular (atrial fibrillation).
4. Develops in seconds (dramatic, stromy or 'bolt from the blue') during exertion, activity or any time; warning sign of TIA may be present.
5. Headache and convulsions are usually absent; there may be transient loss of consciousness.
6. Shifting hemiplegia may occur. Recovery may be very rapid.
7. Evidence of systemic embolisation may be present.

(C) CEREBRAL HAEMORRHAGE :

1. Usually above the age of 40 years.
2. Develops acutely at the height of emotion or excitement. Develops over minutes and hours which progresses relentlessly.
3. Almost all are hypertensive.
4. Headache, recurrent vomiting or convulsions are present in most of the patients. Unconsciousness gradually progresses to deep coma. Early recovery is unuusual.
5. Heart may show features of LVH.
6. Features of atherosclerosis may be present (as in thrombosis).
7. Conjugate deviation of eyes and Cheyne-Stokes breathing are common.
8. Very rarely, neck rigidity may be elicited.

* Lenticulostriate branch of MCA is commonly involved in hypertensive haemorrhage.

** Features of pontine haemorrhage are pin-point pupil, pyrexia and paralysis (3P).

*** Common sites of intracerebral haemorrhage in order of frequency are : Putamen -> thalamus -> frontal or parietal lobes -> pons -» cerebellum.

(D) SUBARACHNOID HAEMORRHAGE :

1. Usually in young adults (also known as 'apoplexy of the young'). It may occur in older age group. Subarachnoid haemorrhage occurs as a result of rupture of berry aneurysm or arterio-venous malformations.
2. Bursting occipital headache commonly precedes (often called 'as the worst headache of my life'); usually does not give rise to convulsions but loss of consciousness (50%) may be present.
3. Occurs during activity or at the height of emotion.
4. Neck rigidity and Kernig's sign are present (cardinal signs at bedside).
5. Hemiplegia or aphasia is absent in most of the patients.
6. Sometimes, there is paralysis of Illrd, IVth, Vlth cranial nerves, or monoplegia or hemiplegia (due to local pressure effect of berry aneurysm or vascular spasm).

(E) CAROTID HEMIPLEGIA :

1. Middle aged or elderly.
2. Very often hypertensive and atherosclerotic.
3. History of TIA is commonly found.
4. There may be H/O claudication of the jaw.
5. Kinking of the carotid artery, inequality of the pulse volume in two carotids or a bruit may be heard at the site of the block.
6. Ipsilateral visual disturbances (amaurosis fugax—transient mono-ocular blindness) and contralateral sensory-motor deficit.

* HYPERTENSIVE ENCEPHALOPATHY is an acute syndrome where severe hypertension is associated with nausea, vomiting, excruciating headache, transient abnormalities in speech or vision, convulsions, mental confusion and coma. Focal neurological signs are rarely seen but papilloedema is usually present. The symptom complex results from constriction of cerebral arterioles and cerebral oedema. Neurodeficit is fully correctable if acute hypertension is properly controlled.

** Following events are **common in hypertensive patients** like cerebral haemorrhage or thrombosis, TIA, carotid atheroma, subarachnoid haemorrhage and hypertensive encephalopathy.

Features of 'atherosclerosis' :

1. Age of the patient is usually above 50 years.
2. There may be H/O IHD, TIA. intermittent claudication or hypertension.
3. Risk factors like diabetes mellitus, smoking, hyperlipidaemia, central obesity may be present.
4. Condition of the arterial wall—Thickened (arteriosclerosis), feels like a cord and often tortuous (Monckeberg's medial sclerosis), and may be associated with :
   (i) Locomotor brachialis.
   (ii) Tortuous temporal arteries, and
   (iii) Kinked carotids.
6. There may be presence of suprasternal pulsation.
7. Features of hyperlipidaemia like xanthelasma is seen around the eyes.
8. Often associated with comeal 'arcus' and diagonal ear lobe crease.
9. Change of arterial and venous ratio, and arteriovenous nipping in ophthalmoscopy.
10. Chest X-ray may reveal unfolding of aorta or aortic calcification.

Risk factors in CVA :

1. Systemic hypertension.
2. Diabetes mellitus.
3. Hyperlipidaemia.
4. Smoking.
5. Obesity.
6. Cardiac diseases (valvular and ischaemic).
7. Severe carotid stenosis.
8. Oral contraceptive pills.
9- High alcohol consumption.
10. Hyperviscosity syndrome (polycythemia, thrombocythemia etc.), bleeding diathesis.
H- Trauma.
12. Strong family history (heredity).
13. Sleep apnoea.

* Increased age, male sex (except in extremes of ages) and hyperhomocysteinaemia are other risk factors.

** Major risk factors : 1- 7, and 10; minor risk factors : 8, 9 and 11-13.

Common causes of 'strokes in young' (<40 years of age) :

(A) CAUSES :

1. Cerebral embolism (from cardiac sources like rheumatic heart diseases; vide page 142).

2. Subarachnoid haemorrhage (rupture of berry aneurysm, arteriovenous malformations).
3. Arteritis or vasculitis (tuberculosis, syphilis, Takayasu's disease, collagen vascular diseases).
4. Accelerated atherosclerosis (secondary hypertension, familial hypercholesterolaemia, hypertriglyceridaemia, diabetes mellitus, nephrotic syndrome, SLE).
5. Hyperviscosity syndrome (polycythemia, thrombocytosis).
6. Demyelinating disease (multiple sclerosis).
7. Intracranial neoplasm (primary or secondary).
8. Encephalitis.
9. Head injury (trauma).
10. Anticoagulant therapy, ITP. or treatment with oral contraceptive pills.
11. Cerebral abscess, tuberculoma.
12. Hemiplegic migraine.
13. *'Procoagulant states'* e.g., Protein C and S deficiency, antithrombin III deficiency, hyperhomocystinaemia, activated protein C resistance, factor V Leiden, prothrombin mutations, antiphospholipid syndrome (Hughes syndrome).
14. Venous sinus thrombosis—Specially in the setting of puerperium.
15. Cerebral malaria.
16. Drug abuse (e.g., cocaine).

(B) SPECIAL INVESTIGATIONS IN YOUNG PATIENTS :

a) Full blood count will platelet. ESR, VDRL test, sugar, urea; X-ray, ECG and echocardiography.
b) Antinuclear factor (ANF); antibodies to double-stranded DNA.
c) Antl-cardiolipin antibodies (antiphospholipid syndrome may be a cause of stroke in young patients), protein C and S, antithrombin III.
d) Prothrombin time (PT), activated partial thromboplastin time (aPTT).
e) Lupus anticoagulant.
f) Lipid profile.

* Atherosclerosis, the chief cause of cerebral ischaemia in the aged is seen less commonly in young patients with stroke. The causes of 'strokes in young' are a bit different from the aged population.

Possible causes of thrombo-embolism :

(A) Arterial : systemic hypertension, infected or sterile emboli of cardiac or vascular origin, septicaemia, hyperhomocystinaemia, thrombotic thrombocytopenic purpura, myxoma, Takayasu's arteritis, polyarteritis nodosa.

(B) Venous : venous insufficiency/obstruction, prolonged immobility, nephrotic syndrome, antiphospholipid syndrome, oral contraceptive pills, plus the 'procogulant states' for both the categories (described above).

Causes of recurrent / transient hemiplegia :

1. Transient ischaemic attack (TIA).
2. Post-epileptic or Todd's palsy.
3. Hypertensive encephalopathy.
4. Hemiplegic migraine.
5. Multiple sclerosis.
6. Hysterical hemiplegia.

* *'Reversible' neurodeficit* is common in 1, 2, 4 and 6.

Major side effects of prolonged use of oral contraceptive pills :

1. Obesity or weight gain.
2. CVA (thrombo-embolic strokes commonly).
3. Deep vein thrombosis and pulmonary embolism.
4. Hypertension.
5. Increased Incidence of acute myocardial infarction.
6. Cholestatic jaundice.
7. Increased incidence of cholelithiasis and cholecystitis.
8. Impairment of glucose tolerance and worsened lipid profile.
9. Depression.
10. Breast discomfort, chloasma, increased clotting tendency, migraine, loss of libido, drug interactions (e.g., rifampicin) and abnormal liver biochemistry.

* Recently, in OC pills, low dose oestrogens have been combined with newer progestational agents, which cause less deleterious effects on carbohydrate and lipid metabolism, coagulation profile, vascular apparatus and liver function.

Mention few causes of monoplegia :

(A) BRACHIAL MONOPLEGIA (UPPER LIMB) :

1. CVA (cortical or subcortical lesion).
2. Multiple sclerosis.
3. Encephalitis.
4. Poliomyelitis.
5. Mononeuropathy.
6. Brachial plexus lesion.
7. Motor neurone disease (MND)
8. Hysterical.

(B) CRURAL MONOPLEGIA (LOWER LIMB)

1. Thrombosis of paracentral artery.
2. Multiple sclerosis.
3. Cauda equina lesion.
4. Sciatic nerve palsy.
5. Prolapsed intervertebral disc (PID).
6. Mononeuropathy.
7. Hysterical.

Causes of hemiplegia :

1. Cerebrovascular accidents (page 141).
2. Strokes in young (page 149).
3. Gradual onset hemiplegia (page 141).
4. Recurrent and reversible hemiplegia (page 150).

Actually, these are sumtotal causes of hemiplegia.

Why do you consider cerebral thrombosis in this case ?

1. As the onset was dramatic, I think the pathology is a 'vascular catastrophy.
2. Though there is presence of hypertension, neither the patient gave any H/O vomiting and convulsions at onset nor he was unconscious. So I am not thinking of cerebral haemorrhage in this case. As there is no neck rigidity, no H/O bursting occipital headache but there is presence of hemiplegia, I am not thinking of subarachnoid haemorrhage in this patient.
3. The CVS is within normal limit. The patient is not suffering from any valvular heart disease or atrial fibrillation. So chance of cerebral embolism is less.
4. So, I say it is a case of CVA due to thrombosis which is the 'most common' cause of stroke.

Why do you say the site of lesion is in the internal capsule ?

It is known that in a patient of hemiplegia if there is,

1. UMN type of Vllth nerve palsy to the side of hemiplegia—the lesion lies in the opposite internal capsule.
2. LMN type of Vllth nerve palsy with contralateral hemiplegia—the lesion lies in the brain stem (pons) opposite to hemiplegic site.
3. Hemiplegia without any cranial nerve involvement (known as spinal hemiplegia) lesion lies in ipsilateral upper spinal cord (in between medulla to C_5 spinal segment).

As it is a case of left-sided complete hemiparesis, most likely the site of lesion is in the right internal' capsule. It is the 'commonest site' of involvement in a patient with CVA.

* Cortical and subcortical lesions usually produce monoplegia.

'Clinical' classification of stroke :

1. TIA (transient-ischaemic attack)—Abrupt neurological dysfunction (neurodeficit) due to cerebral ischaemia where symptoms last for < 24 hours and the patient recovers completely.
2. Stroke in evolution (progressive stroke)—The symptoms worsen gradually or in a step-wise pattern over hours or days. This is due to increasing size of infarction, haemorrhage or cerebral oedema.
3. Completed stroke—The neurodeficit is complete from the beginning (usually within 6 hours) and persists for weeks and months, and often permanently.
4. Minor stroke—Usually the patient recovers within a week, without significant deficit.

* Most neurologists still believe that TIA is a stroke; the definition of TIA is unsatisfactory as clinical studies reveal that after J hour, ishaemic damage occurs. TIA of (a) *carotid territory* manifests as transient weakness (monoparesis), hemisensory loss, aphasia and transient mono-ocular blindness (amaurosis fugax) whereas, (b) *vertebro-basilar TIA* is manifested by vertigo, dysarthria, diplopia, vomiting,

ataxia, dysphagia or sudden fall (drop attack). In TIA, the source of embolus may be clinically evidenced by carotid arterial bruit (i.e., stenosis), valvular heart disease/SBE, atrial fibrillation, recent acute myocardial infarction or difference between BP of left and right arm.

The older term RIND (reversible ischaemic neurological deficit) where the neurodeficit persists for > 24 hours but recovers usually within 24-96 hours, is not preferred by neurologists now-a-days.

Classical 'signs of meningeal irritation' :

1. **Neck rigidity (stiffness)—**

a) In *supine position* of the patient, stand on the right side of the bed and place your left hand behind and below the patient's head; try to lift the head from the bed until the chin touches the chest and feel the resistance while flexing the head. Normally, the neck is supple and can be easily flexed passively. In the presence of neck rigidity, it is not possible to passively flex the neck fully. Neck rigidity occurs due to spasm of extensor neck muscles and in an attempt to do the test, the whole body may be raised up; head retraction represents an extreme form of neck rigidity (alternative method : support the back of the head with both hands and gently try to flex the neck so that the chin touches the chest).

b) In *sitting position* of the patient, ask him to touch the chin to the sternum (always with closed mouth). Neck rigidity and Kernig's sign are present in,

(i) Meningitis.
(ii) Meningism.
(iii) Subarachnoid haemorrhage.
(iv) Meningoencephalitis.
(v) Meningomyelitis.
(vi) Tetanus, rabies, hysteria.
(vii) Rarely in intracerebral haemorrhage.
(viii) Spinal epidural abscess.
(ix) Sometimes in posterior fossa tumour.
(x) Cerebellar tonsillar herniation at foramen magnum.

* In clinical practice, No. 1, 2, and 3 are most important.

N.B. : Sometimes, the *neck rigidity is absent* in deep coma or in infants. Passive resistance to head flexion may be present in cervical spondylosis (side to side movement is more restricted than antero-posterior movement), traumatic injury of cervical spine, Klippel-Feil anomaly or cerebral malaria.

2. **Kernig's sign—**In supine position of the patient, flex his hip to 90° and then extend the knee to 90 . Now try to straighten the leg maintaining the hip in flexion. In the presence of meningeal irritation, it is impossible to straighten the leg because of the painful spasm of hamstring muscles (normally the leg can be easily straightened). This sign is positive in the conditions mentioned above. Testing of neck rigidity is a more sensitive test of meningeal irritation than Kernig's sign.

3. **Brudzinski's sign**—

It is a very *helpful sign of meningeal irritation in children.* It has two components :

a) Neck sign—Patient will lie supine with extended legs. Try to lift the head from the bed. There will be reflex flexion of the hip, or knee of one or both the limbs.

b) Leg sign— While passively flexing the thigh of any one limb, the other thigh or knee automatically becomes flexed.

* Kemig s and Brudzinski's sign are due to the presence of inflammatory exudate around roots present in the lumbar theca, which results in muscle spasm.

How to differentiate meningism from meningitis ?

Presence of neck rigidity and rise in CSF pressure are found in both the conditions but,

1. If along with neck rigidity, there is presence of pain in the neck — Probably it is meningitis (sign of inflammation). Meningism usually does not produce pain.
2. Kernig's sign is less pronounced in meningism.
3. Convulsions and coma are rare in meningism, and cranial nerve paralysis never occurs.
4. If after lumbar puncture, CSF is seen to be turbid — It is meningitis. Clear CSF may be seen both in meningism and meningitis (viral or tuberculous).
5. CSF shows absence of cellular changes in meningism. and the fluid is always sterile on culture. Meningitis will always have changes in cell count and cell type.

Diseases producing meningism in clinical practice :

1. Enteric fever.
2. Pneumonia (commonly atypical variety).
3. Empyema thoracis.
4. Diphtheria.
5 Acute pyogenic tonsillitis.
6. Viral encephalitis; any viral infection.
7 Leukaemia, lymphoma, malignancy.
g Weil's disease.

* *Meningism (meningeal irritation)* is usually due to some local or systemic infection but there is absence of any direct infection or inflammation of CNS.

What is straight leg raising (SLR) test ?

While the patient lies supine, try to elevate patient's 'extended' leg, keeping the hand behind the patient's heel. This movement is possible upto 90° in a normal person. The test is positive i.e., restricted movement with pain is present in sciatica and prolapsed intervertebral disc (PID). Tight hamstring muscles often interfere with the test.

Lasegue's sign—extension of the leg at knee, after flexing the thigh, will induce pain in PID.

Features of increased intracranial tension (IIT) :

(A) SYMPTOMS :

1. Headache (intense deep-seated dull aching pain, worsened by exertion or change of posture; headache may be severe on early morning hours).
2. Vomiting (sometimes, projectile; absence of nausea; unrelated to food).
3. Convulsions (usually generalised; focal due to SOL itself).
4. Altered consciousness to coma (retarded cerebration).
5. Drowsiness and mental deterioration may be present; visual problems like deterioration of visual acuity and peripheral constriction of visual field.

(B) SIGNS :

1. Pulse—Bradycardia; if the intracranial pressure continues to increase, the pulse becomes very rapid; there may be irregular pluse.
2. BP—There may be hypertension.
3. Respiration—Slow and deep respiration; later on it becomes rapid and shallow, and lastly Cheyne-Stokes breathing appears.
4. Papilloedema; pupil—unequal or abnormally reacting, may be fixed pupil.
5. False localising signs (signs which do not have localising value)—
   (i) Unilateral or bilateral, Vlth or lllrd nerve palsy.
   (ii) Bilateral Babinski's sign.
   (iii) Bilateral grasp reflex.
6. Bulged anterior fontanelle in infants.
7. A 'chronic' IIT may produce features of 'hypopituitarism' e.g., loss of body hairs, hypothyroidism, hypoadrenalism etc.

* Examine—Pulse, pressure, plantar response, papilloedema and paralysis, if any (5P).

** Bradycardia, hypertension and irregular respiration are collectively known as "Cushing's triad" (due to cerebral herniation).

(C) CAUSES :

1. Cerebrovascular accidents (CVA).
2. Intracranial tumour.
3. Meningitis, meningism, encephalitis, cerebral abscess.
4. Benign intracranial hypertension (commonly from Addison's disease, corticosteroid withdrawal. COPD, overdose of vitamin A, hypoparathyroidism).
5. Circulatory block like aqueduct stenosis, 4th ventricle block in hydrocephalus.
6. Miscellaneous—Head injury, cerebral oedema, hypoxic encephalopathy etc.

(D) INVESTIGATIONS :

1. X-ray of skull —
   (i) Silver-beaten appearance (in children),
   (ii) Sutural diastasis (in children),
   (iii) Erosion of clinoid process,
   (iv) Deepened sella turcica,
   (v) Enlargement of internal auditory meatus.
2. CT or MRI scan — Diagnoses IIT (dilatation of ventricles and effacement of cisterns) with the aetiology.

(E) TREATMENT :

It is done by propped-up position at 30°, I.V mannitol (20%), glycerol (oral or I.V), I.V steroid (dexamethasone in vasogenic oedema surrounding a tumour or abscess, but not in CVA), frusemide (I.V), rentention enema of magnesium sulphate, or hyperventilation.

* As a false localising sign, Vlth cranial nerve is commonly involved because it has the longest intracranial course and thereby easily compressed at the bony prominences. Lumbar puncture is contraindicated in IIT with papilloedema because of the risk of development of 'cerebellar pressure cone syndrome' (sudden death due to compression of vital medullary centres as a result of descent of cerebellar tonsil).

What are the common causes of coma ?

1. CVA (specially cerebral haemorrhage and massive cerebral infarction).
2. Encephalitis, meningitis, cerebral malaria, epilepsy, head injury, subdural or extradural haematoma, intracranial SOL, tentorial herniation.
3. Hypoglycaemia. diabetic ketoacidosis, renal failure, hepato-cellular failure, myxoedema coma, pituitary apoplexy, adrenal crisis.
4. Stokes-Adams syndrome, tight aortic stenosis, arrhythmias, respiratory failure (Type II).
5. Alcohol overdose, drug overdose, poisoning (barbiturate, opiate, organophosphorus), snake bite, hypothermia, heat stroke.
6. Psychogenic.

How do you like to investigate a case of hemiplegia ?

1. Blood (routine examination)—TC, DC, ESR.
2. Blood biochemistry—Sugar, lipid profile (cholesterol, LDL, VLDL, HDL, triglyceride), urea and creatinine.
3. ECG to diagnose myocardial ischaemia, chamber enlargement in heart, arrhythmia (atrial fibrillation) etc.
4. Chest X-ray (cardiac chamber enlargement, to diagnose pneumonia as a complication).
5. Echocardiography (to identify the source of emboli).
6. Carotid angiography and CSF study are not routinely done (carotid angiography may precipitate thrombosis in another territory of brain). Magnetic resonance (MR) angiography, digital subtraction angiography and lumbar puncture are diagnostic in subarachnoid haemorrhage.
7. Doppler flow studies in carotids (if facilities are available).
8. CT **scan of the brain**—For proper initial evaluation, CT scan is mandatory to categorise the stroke into either ischaemic (thrombosis or embolism) or haemorrhagic origin. Cerebral haemorrhages are detected immediately whereas infarction may take 48 hours or more. CT scan helps to decide the line of management (e.g., aspirin, anticoagulants or antiplatelet drugs). It also helps to diagnose the conditions which may simulate stroke e.g., ICSOL, vascular malformation etc. MRI scan may be done, though CT scan is preferred to MRI in acute stage.

* Read the special investigations from 'common causes of strokes in young' mentioned earlier.

What is the ideal line of management in hemiplegia ?

After initial evaluation of neurological deficit, cardiovascular status, metabolic status (blood sugar, urea, creatinine and electrolytes) and haematological parameters (Hb%, coagulation profile) one may start management of hemiplegia with general supportive measures, anti-oedema management, and care of the co-morbid conditions.

1. Patient should lie in a railed cot; insert Ryle's tube, put a self-retaining catheter and take care of the airway. Nursing cares should be started by trained persons. 0_2 therapy, if necessary.
2. Treat **cerebral oedema** by,
   a) 20 ^ mannitol 100 ml I.V thrice daily (reduces cerebral oedema by osmotic diuresis).
   b) Oral glycerol—6 tsf thrice daily (usually taken with fruit juice).
   [c) Inj. dexamethasone (if not hypertensive) — 4-6 mg, I.M or I.V, every 4-6 hourly may be tried in selected cases e.g., chronic subdural haematoma *(contraindicated in* CVA}.]
   d) Inj. frusemide—40 mg I.V stat. and as and when necessary.
3. Treatment of diabetes mellitus, stress ulcer (by H_2RA or PPI), hypertension (maintain the BP at or just below 180 / 115 mm of Hg in cerebral infarction; and in cerebral haemorrhage, keep the BP a bit lower than the above reading), hyperlipidaemia; avoid smoking; maintain fluid balance. Do not lower the BP much in acute stage because it will hamper the cerebral autoregulation, diminish the perfusion of ischaemic zones, and may exacerbate infarction.
4. Antiplatelet drugs (in thrombosis)—Aspirin (75-300 mg daily) or dipyridamole (50 mg thrice daily) or ticlopidine (250 mg twice daily) for long term prophylaxis. Aspirin 300 mg daily should be started immediately as soon as the inchaemic stroke is confirmed, and reducing the dose to 75 mg daily after several days. Pentoxifylline (haemorrheology modifier, i.e., changes viscosity

of blood) may be beneficial in cerebral infarction if used within 12 hours of onset of stroke (not accepted by all). Newer antiplatelet drugs are clopidogrel (75 mg daily), lamifiban and abciximab. Aspirin is contraindicated in cerebral haemorrhage and very large infarction.

5. Role of cerebral vasdodilators are contradictory (5% $C0_2$ with 95% 0_2, cyclandelate, nicotinic acid, papaverine, aminophylline etc.) due to steal phenomenon.
6. Treatment of atrial fibrillation (in embolism) and valvular heart disease is done accordingly.
7. Anticoagulant therapy may be given (heparin and warfarin) in an 'evolving stroke' if cerebral haemorrhage is ruled out by early CT scan. Anticoagulant therapy is not of value in the treatment of completed stroke. Anticoagulation is mandatory in cardiogenic embolic stroke.
8. Recombinant tissue plasminogen activator (rTPA) may be beneficial if started within the first 3 hours of onset of an ischaemic stroke.
9. Surgery—Certain intracerebral haematomas are amenable to surgery (e.g., cerebellum); carotid endarterectomy is performed in carotid TIA.
10. Physiotherapy—Is done by an expert physiotherapist or physiatrist. **It should be started as soon as the patient recovers from the neural shock stage.** Change of posture in bed must be done to avoid bed sores. Physiotherapy is advised to prevent joint contractures and oedema of the limb, and to promote recovery of strength. Compression stockings should be applied to paralysed leg to prevent deep vein thrombosis. Passive movement of the limb also prevents venous stasis and pulmonary embolism. Chest physiotherapy should be started to promote coughing out of expectorations.
11. Rehabilitation; speech and occupational therapy should be tried.

* Avoid hypoxia, 5% dextrose infusion and corticosteroid in the treatment of CVA.

** Always take care of bladder, bowel, back (bed sore), base of the lungs, and boost the morale.

Case 17

Paraplegia

What is your diagnosis ?

This is a case of spastic paraparesis (or paraplegia) in extension due to compressive myelopathy caused by caries spine and the lesion is at the level of T_{10} segment of the spinal cord.

Why do you say so ?

This young male patient aged 28 years was complaining of severe weakness of both the lower limbs with loss of sensation for last one month. He also complained of anorexia, cough with evening rise of temperature for last five months. One month back, he noticed gradual weakness of the left leg which was followed by weakness of the right leg after 2 days. He also noticed numbness or loss of superficial sensations like touch, pain and temperature below the level of umbilicus for the same duration. The fever was intermittent in nature and associated with night sweats. On repeated enquiry, he gave H/O ***root pain,*** i.e., sharp, constant, stabbing, electric shock-like pain which was distributed in the region below the umbilicus and both the lower limbs. The pain used to aggravate by the change of posture, coughing, sneezing, jolting and movement of spine. He also complained of a special type of sensation, i.e., girdle-like sensation at the level of umbilicus. For the last 25 days, there was almost total and more or less, symmetrical paralysis of both the lower limbs; there was no H/O diurnal variation of weakness (vide myasthenia gravis). The patient did not complain of any involvement or weakness of the upper limbs. It seems that the disease started insidiously and was progressing gradually.

Initially, he was also suffering from hesitancy of micturition and was catheterised in the hospital on admission (he was admitted in the hospital 25 days back). He was unable to hold faeces for the same duration (rectal incontinence). He specifically complained of bone pain at his back. Since his admission, there was no sign of recovery. The patient did not give any H/O flexor spasm.

There was no H/O headache, vomiting, convulsions, speech difficulty, facial weakness or any abnormal movements. No family H/O diabetes mellitus, hypertension or tuberculosis was found. There was no positive H/O exposure to STD, trauma to the spine or similar episodes in the past. He was not vaccinated in the recent past. He is neither diabetic nor hypertensive. On repeated enquiry, he gave H/O haemoptysis 3 months back which he ignored and did not attend any physician at that time.

On examination, it shows that the patient is conscious and co-operative. He is suffering from UMN paralysis of both the lower limbs. There is loss of superficial sensations below the umbilicus. A gibbus is

seen at the level of 7th thoracic vertebra which is tender on palpation. The UMN paralysis of both the lower limbs is suggested by bilateral clasp-knife spasticity, brisk tendon reflexes, presence of clonus and extensor plantar response.

* Paraplegia is basically of two types : Spastic and flaccid.

What is your case ?

Say the summary as above.

Importance of 'past history' in paraplegia :

1. H/O tuberculosis.
2. H/O fever (tuberculosis, acute transverse myelitis, G. B. syndrome, lymphoma, leukaemia).
3. Primary chancre (exposure to STD).
4. Similar episodes in the past (may signify multiple sclerosis).
5. Spinal injury (produces compressive myelopathy).
6. Hypertension, diabetes mellitus as a routine.
7. H/O any lymphadenopathy (tuberculosis, lymphoma, malignancy) or vaccination (may precipitate acute transverse myelitis-like features).
9. Alcoholism or drugs like INH, vincristine (peripheral neuropathy producing weakness of both lower limbs).
10. Pain in the spine (caries spine, metastasis in the spine).
11. Occupational history : H/O exposure to chemicals and toxins

Importance of family history' in paraplegia :

1. Hypertension (as a routine).
2. Diabetes mellitus (as a routine).
3. H/O paraplegia in other members of the family (if present, may indicate hereditary spastic paraplegia, paraplegia with hereditary ataxia, or lathyrism).
4. Tuberculosis.

Chief complaints (clinical presentations) of your patient :

1. Weakness of both the lower limbs for 1 month.
2. Loss of sensations of both the lower limbs for 1 month.
3. Hesitancy of micturition and loss of bowel control for 1 month.
4. Cough with evening rise of temperature for last 5 months.

Enquiry regarding paralysis (in H/O present illness) :

(A) DATE OF ONSET **:** Note the specific date and time of onset of paralysis.

(B) MODE OF ONSET : Sudden (acute transverse myelitis, spinal injury etc) or gradual (caries spine).

(C) PRECIPITAING FACTORS :

(i) Spinal injury.

(ii) Vaccination (commonly anti-rabies nervous tissue vaccine).

(D) EVOLUTION OF PARALYSIS **:** Whether both the limbs are affected simultaneously or one after the other.

(E) PROGRESS OF PARALYSIS :

(i) Increasing in severity and extent—Cord compression.

(ii) Improving—Inflammatory, acute transverse myelitis or multiple sclerosis.

(iii) Static but progressing very slowly—Degenerative lesion (Friedreich's ataxia).

(iv) Waxing and waning—Multiple sclerosis.

(F) DEGREE AND DURATION OF PARALYSIS—Weakness or total loss of power, with duration.

(G) MOTOR SYMPTOMS—See the symptomatology.

Enquiry regarding sensory symptoms (in H/O present illness) :

1. Loss of sensation (superficial and/or deep)—find out the upper border.
2. Girdle-like sensation or sense of constriction (find out the level).
3. Zone of hyperaesthesia (find out the level).
4. Root pain (ask for distribution and precipitating factors).
5. Sensation of pins and needles in the lower extremities (test for sensory functions).

Cerebral paraplegia :

(A) Causes : The lesion in paraplegia lies either in cerebral cortex, spinal cord, nerve roots, peripheral nerves, myoneural junction, or in muscles. Cerebral causes are extremely rare and always give rise to paraplegia in extension. The causes are,

1. Cerebral diplegia (Little's disease) — Cortical cause of paraplegia.
2. Superior sagittal sinus thrombosis.
3. Parasagittal meningioma.
4. Thrombosis of unpaired anterior cerebral artery.
5. Hydrocephalus.
6. Bullet injury at paracentral lobule.

(B) Features :

1. Extremely rare. H/O jacksonian fits and cortical sensory loss present.
2. Spastic paraplegia in extension (may be flaccid in shock stage but never produces paraplegia in flexion).
3. Features of IIT may be present (headache, vomiting, convulsions).
4. Abnormalities in higher function, speech difficulty, cranial nerve affection may be present.

Table 9 : Differentiation between 'paraplegia in extension' and 'paraplegia inflexion'

Spastic paraplegia is of two types : Paraplegia in extension and paraplegia in flexion.

	Features		**Paraplegia in extension**		**Paraplegia in flexion**
1.	Definition—	1.	Lower limbs take an extension attitude and the extensor muscles are spastic	1.	Lower limbs take an attitude of flexion due to **'flexor spasm'** (even the heel may strike the back of ipsilateral thigh)
2.	Pathology—	2.	Only pyramidal tracts are involved	2.	Both pyramidal and extrapyramidal tracts (e.g., reticulospinal tract) are involved (thus, prognostically worse). Occurs in late stages of paraplegia or progressive lesion
3.	Evolution—	3.	Early	3.	Late
4.	Clinical features—				
	a) Attitude	a)	Hip extended and adducted, knee extended, and feet plantiflexed	a)	Thigh and knee flexed, feet dorsiflexed. Adopts lateral decubitus posture in bed
	b) Tone	b)	Clasp-knife spasticity in extensor group of muscles	b)	Tone is increased in flexor group of muscles
	c) Jerks	c)	Brisk	c)	Present but diminished
	e) Plantar response	e)	**Extensor**	e)	**Extensor but may be associated with flexor spasms**
	f) Reflex evacuation of bladder and bowel	f)	Absent	f)	Present
	g) Mass reflex	g)	Absent	g)	May be present

** **Mass reflex** : If the skin of the lower limbs or the lower abdominal wall is stimulated, there is reflex flexion of the lower trunk muscles and the lower limbs (ie, flexor spasm), piloerection and penile erection, evacuation of the bladder, bowel and semen, and sweating. Mass reflex indicates severe spinal cord lesion. It is a reflex of spinal automatism.

*** Flexor spasm may be severe in posterior column lesion (e.g., multiple selerosis), in the presence of bed sores or urinary tract infection (as a result of constant stimulation of small unmyelinated nerve fibres) with cord lesion.

Causes of 'spastic' paraplegia (UMN type lesion) :

(A) GRADUAL ONSET :

I. Cerebral causes—Cerebral diplegia, parasagittal meningioma, hydrocephalus.

II. Spinal causes—

a) Compressive or transverse lesion in the spinal cord—Cord compression (see below).

b) Non-•compressive or longitudinal lesion or systemic diseases of the spinal cord

(i) Motor neurone disease (MND) e.g., amyotrophic lateral sclerosis.

(ii) Multiple sclerosis, Devic's disease.

(iii) Friedreich's ataxia.

(iv) Subacute combined degeneration (i.e., from vitamin B_{12} deficiency).

(v) Lathyrism.

(vi) Syringomyelia.

(vii) Hereditary spastic paraplegia.

(viii) Syphilitic meningomyelitis (rare).

(ix) Tropical spastic paraplegia.

(x) Paraneoplastic myelitis.

(xi) Antiphospholipid antibody syndrome.

(xii) Radiation myelopathy.

(B) SUDDEN ONSET:

I. Cerebral causes—Thrombosis of unpaired anterior cerebral artery, superior sagittal sinus thrombosis, bullet injury at paracentral lobule.

II. Spinal causes—

a) Acute transverse myelitis.

b) Injury to the spinal cord (fracture-dislocation or collapse of the vertebra).

c) Thrombosis of anterior spinal artery (myelomalacia).

d) Haematomyelia (from arteriovenous malformations, angiomas, or endarteritis).

e) Post-vaccinal.

f) Prolapsed intervertebral disc (PID).

g) Spinal epidural abscess or haematoma.

h) Radiation myelopathy.

* Compressive—II b), f) and g); Non-compressive—II a), c), d), e) and h).

Causes of 'cord compression' (compressive aetiology in paraplegia) :

I. Intramedullary (5%) :

a) Glioma.

b) Ependymoma.

c) Chordoma.

d) Syringomyelia, haematomyelia.

n. Extramedullary :

a) **Intradural (15%)**—

(i) Meningioma.

(ii) Neurofibroma.

(iii) Patchy arachnoiditis (tuberculosis, syphilis, sarcoidosis).

(iv) Arteriovenous malformations.

b) **Extradural (80%)**—

(i) Caries spine (Pott's paraplegia).

(ii) Myeloma, lymphomatous or metastatic deposits in the vertebra; osteomyelitis.

(iii) Patchy meningitis.

(iv) Prolapsed intervertebral disc (PID).

(v) Degenerative joint disease (spondylosis).
(vi) Fracture or dislocation of the vertebra, osteoporosis, paget's disease.
(vii) Extramedullary haematopoiesis in thalassaemia.
(viii) Spinal epidural abscess or haematoma.

* Cord compression produces paraplegia by : 1. Pressure effect, 2. Ischaemia (arterial), and 3. Congestion (venous).

** Intradural lesion (e.g., neurofibroma) gives a history of long duration while extradural lesion (e.g., malignancy) gives a short history.

Causes of flaccid' paraplegia (LMN type lesion) :

(A) UMN LESION IN SHOCK STAGE—i.e., sudden onset spastic paraplegia in 'neural shock' stage e.g., acute transverse myelitis, spinal injury.

(B) LESION INVOLVING ANTERIOR HORN CELLS —

a) Acute anterior poliomyelitis.
b) Progressive musclular atrophy (variety of MND).
c) Trauma.

(C) DISEASES AFFECTING NERVE ROOTS—Tabes dorsalis, radiculitis, G.B. syndrome.

(D) DISEASES AFFECTING PERIPHERAL NERVES—

a) Acute infective polyneuropathy (G.B. syndrome).
b) High cauda equina syndrome.
c) Disease of peripheral nerves involving both the lower limbs.
d) Lumbar plexus injury (e.g., posas abscess or haematoma).

(E) DISEASES AFFECTING MYONEURAL JUNCTION—

a) Myasthenia gravis, Lambert-Eaton syndrome.
b) Periodic paralysis due to hypo- or hyperkalaemia.

(E) DISEASES AFFECTING MUSCLES—Myopathy.

(F) HYSTERICAL PARALYSIS.

* Note that paraplegia may be produced due to lesion in cerebral cortex, spinal cord (compressive or non-compressive myelopathy), nerve roots, peripheral nerves, myoneural junction or muscles. In clinical practice, we are more concerned with paraplegia due to lesions in the spinal cord (myelopathy).

* *Common causes of paraplegia are 5T: Trauma, tuberculosis, tumour, thrombosis and transverse myelitis.*

Classical features of acute transverse myelitis :

Though a common cause of non-compressive myelopathy (acute onset total transection of the cord), clinically somewhat **it behaves like compressive variety.**

1. Very often follows a viral illness (neurotropic virus) or post-vaccinal.
2. Onset is acute or subacute (evolve over several days to 2-3 weeks).
3. **Fever may be present before paralysis develops.**
4. Bladder involvement is early.
5. Though behaves like compressive variety, usually there is absence of root pain, spinal tenderness or spinal deformity. Back pain and progressive paraparesis are presenting complaints. Girdle constriction at the level of lesion with zone of hyperaesthesia just above may be obtained. Mid-thoracic region is the most common site.
6. Plantar response is extensor and there is partial or complete sensory loss (all modalities), with a definite upper level (very important **point of difference with acute infective polyneuropathy** where these two features are, flexor and no demonstrable sensory loss respectively).
7. MRI scan is often required to exclude cord compression.
8. Majority (70%) recovers within 12 weeks.

* Plantar response may not be extensor, in the stage of neural shock.

** All the reflexes are usually lost below the level of lesion in the stage of neural shock (first 2-3 weeks). Thereafter, spasticity with brisk reflexes develop.

*** Other causes of acute transverse myelopathy are multiple sclerosis, vasculitis (MCTD), HIV, sarcoidosis, radiation, syphilis and anterior spinal artery occlusion.

Features of acute infective polyneuropathy (Landry-Guillain-Barre syndrome) :

1. There is an association with Epstein-Barr virus, measles, campylobacter jejuni (causing diarrhoea), HIV, cytomegalovirus, post-vaccinal and post-surgical events. The current hypothesis is in the favour of immunological reaction due to hypersensitivity, perhaps as a result of unidentified allergen directed against the myelin sheath of peripheral nerves. Truely speaking, it is an acute post-infective ***polyradiculoneuropathy*** (i.e., inflammatory demyelination involves spinal roots and peripheral nerves). Severe forms show secondary axonal degeneration.
2. a) Common history :

   Viral illness (e.g., respiratory catarrh) -> after 2 weeks, paralysis with sensory symptoms (paraesthesia) starts -> paralysis progresses for 3 weeks and then stops -> paralysis becomes static for 2 weeks -> after 2 weeks recovery starts which is usually completed within 6 months -> in incomplete recovery, residual disability persists,

   b) Incidence — in either sex; peak incidence is in between 20-50 years.
3. Monoplegia, paraplegia or quadriplegia **(proximal muscles are more affected).** It is an acute (evolved over hours to days) **ascending LMN type of paralysis usually beginning in the legs.** Upper extremities may also be involved leading to quadriplegia. There may be bulbar palsy or respiratory muscle paralysis.
4. Bilateral Vllth (LMN type) cranial nerve palsy (present in approximately 50% cases), though this is occasionally unilateral.
5. No sensory abnormalities demonstrated (very characteristic) though sometimes the patients complain of distal paraesthesia.
6. Jerks are invariably absent (i.e., there is diffuse weakness with widespread loss of reflexes). Gross hypotonia is evident.
7. Bladder and bowel are rarely involved.
8. Plantar response—Flexor or no response.
9. Autonomic disturbances (tachycardia, arrhythmia, postural hypotension/hypertension) are not uncommon.
10. Sensorium (consciousness)—Clear throughout the disease process.

* **There is subjective sensory symptoms (paraesthesia) without any objective sensory loss.**

** G.B. syndrome is also known as acute inflammatory demyelinating polyneuropathy (AIDP).

*** Outcome : 1. Complete or near complete recovery - 80%, 2. Residual disability - 15%, and 3. Death - 5% (respiratory paralysis or lung infection).

**** It is an areflexic, atonic ascending motor paralysis.

Features of "atypical' G.B. syndrome :

1. Distal muscle involvement.
2. Objective sensory impairment.
3. Papilloedema.
4. Descending paralysis.
5. Early bladder and bowel involvement.
6. Babinski's sign.
7. Glomerulonephritis.
8. Miller Fisher syndrome (ataxia, areflexia and external ophthalmoplegia) without significant limb weakness.
9. SIADH (syndrome of inappropriate ADH secretion).

What is Brown-Sequard syndrome ?

It is the hemisection of the spinal cord (e.g., bullet or stab injury) and the features are :

1. Sensory—Loss of proprioception (joint, position, vibration sense) on the same side, and loss of pain and temperature sensations on the opposite side, 1-2 segment below the level of lesion.
2. Motor—Segmental LMN signs at the level of lesion; monoplegia of the lower limb or hemiplegia on the same side may occur below the level of lesion.
3. Reflexes—Below the level of lesion, there are features of UMN lesion, i.e., superficial reflexes lost, brisk deep reflexes with extensor plantar response.

* There may be a band of hyperaesthesia on the same side just above the level of lesion.

** In lesion above T_t level ; patient presents with Horner's sydrome.

*** ***Maximum*** motor loss on the same side and maximum sensory loss on the opposite side.

Localisation of the level of lesion in a compressive myelopathy :

Localisation of the level of compression is done by :

1. Distribution of root pain—Ask for specific dermatomes involved (it is due to involvement of posterior nerve roots).

2. Upper border of sensory loss—Examine the patient from below upwards (i.e., from legs to thorax) for demonstration of upper border of sensory loss (due to affection of spinothalamic tract).
3. Girdle-like sensation or sense of constriction at the level of lesion (usually due to involvement of posterior column).
4. Zone of hyperaesthesia or hyperalgesia—This will localise the level of lesion one segment below i.e., zone of hyperaesthesia is present just above the level of girdle-like sensation, and is due to compression of posterior nerve roots.
5. Analysis of abdominal reflex—i.e., if upper abdominal reflex is intact with loss of middle and lower one, the site of lesion is probably at T_{10} spinal segment.
6. Atrophy of the muscles in a segmental distribution (due to involvement of anterior horn cells).
7. Loss of deep reflexes, if the particular segment is involved. The reflexes will be brisk below the involved segment.
8. Analysis of *Beevor's sign* (do the 'rising test'. In paralysis of lower part of rectus abdominis, umbilicus moves upwards and in paralysis of upper part of rectus, umbilicus goes downwards)—Beevor's sign detects the weakness of abdominal muscles.
9. Deformity or any swelling in the vertebra.
10. Tenderness in the vertebra.
11. The area of sweating may help (lack of sweating below the level) in localising the level of lesion.
12. The level can also be localised by X-ray of the spine, myelography, CT scan or MRI.

* The question of localisation of the level of lesion does not arise in non-compressive myelopathy.

Determination of spinal segments in relation to vertebra :

The spinal segments do not lie exactly under the overlying vertebra. The following formula determines the spinal segments related to a vertebral body.

1. For cervical vertebrae—add 1.
2. For 1-6 thoracic vartebrae—add 2.
3. For 7-9 thoracic vertebrae—add 3.
4. The T_{10} arch overlies L, and L_2 segments.
5. The T_n arch overlies L_3 and L_4 segments.
6. The T_{12} arch overlies L_5 segment.
7. The L, arch overlies the sacral and coccygeal segments.

N.B.: In the patient described at the outset, the T_y vertebra is involved and thus, the spinal segment involved is T_{10} (by adding 3). Remember, in lower thoracic region the tip of a spinous process marks the vertebral body below.

* Altogether 31 pairs of spinal nerve roots emerge from the spinal cord. The segments in the cord are : cervical 8, thoracic 12, lumbar 5. sacral 5 and coccygeal 1. The lower end of spinal cord tapers to form 'conus medullaris' at lower border of Lj vertebra. The spinal roots below L_1 vertebra pass down in the spinal canal to emerge at their respective foramina, and thus form 'cauda equina'.

Points to note in spine examination in ***paraplegia :***

I. 1. Kyphosis.
2. Scoliosis.
3. **Gibbus** (with paraspinal muscle spasm).
4. Tenderness.
5. Spina bifida.

II. Any scar (indicates old trauma), tuft of hair over sacrum (spina bifida occulta), bed sore or sacral oedema.

'Paraplegia in extension' progressing to 'paraplegia inflexion' : How to diagnose?

1. Appearance of flexor spasms.
2. Diminution of deep reflexes (jerks).
3. Diminution of ankle clonus in duration.

* In additon to pyramidal tract, there is involvement of extrapyramidal tracts like reticulospinal, rubrospinal, tectospinal or vestibulospinal tract in patients with paraplegia in flexion.

** Pathophysiology : when the pyramidal tract alone is at jeopardy, the extrapyramidal system takes

the upper hand, resulting in increased tone of the antigravity muscles (i.e., paraplegia in extension). When the extrapyramidal system is at fault too, the spinal arc becomes dominant and there is relative increase in tone of the flexors (e.g., hamstrings) more than the extensors (i.e., paraplegia in flexion).

Table 10 : Differentiation between compressive and non-compressive myelopathy

	Features	Compressive	Non-compressive
1.	Bony deformity	+	-
2.	Bony tenderness	+	-
3.	Girdle-like sensation	+	-
4.	Upper level of sensory loss	+	-
5.	Zone of hyperaesthesia	+	-
6.	Root pain	+	-
7.	Onset and progress	Gradual	May be acute
8.	Symmetry	Asymmetrical	Majority are symmetrical
9.	Flexor spasm	Common	Usually absent
10.	Pattern of neurodeficit	** U-shaped	Bilaterally symmetrical
11.	Bladder and bowel involvement	Early	Late (early in acute transverse myelitis)
12.	Classical example	Caries spine	Motor neurone disease

* No. 3, 4 and 5 are sometimes present in acute transverse myelitis.

** March of neurodeficit pattern : U-shaped, i.e., first ipsilateral upper limb (UL), next ipsilateral lower limb (LL), next contralateral LL, and finally contralateral UL (Elsberg's phenomenon). In a slow cord compression the pyramidal tract is affected first, followed by the posterior column, and finally the spinothalamic tract.

Table 11 : Discriminate between extramedullary (intradural) and intramedullary lesions

	Features	Extramedullary	Intramedullary
1.	Root pain	Early and common	Root pain is rare; pain is burning in type and poorly localised
2.	Sensory deficit	No dissociation of sensation; contralateral loss of pain and temperature with ipsilateral loss of proprioception	Dissociation of sensation common; spotty changes
3.	Sacral sensation	Lost (early)	Sacral sparing
4.	LMN involvement	Segmental	Marked with widespread atrophy; fasciculation seen
5.	UMN involvement	Early and prominent	Less pronounced; late feature
6.	Reflexes	Brisk, early feature	Less brisk, late feature
7.	Autonomic involvement (bladder and bowel)	Late	Early
8.	Trophic changes	Usually not marked	Common
9.	Vertebral tenderness	May be sensitive to local pressure	No bony tenderness in vertebrae
10.	Changes in CSF (i.e., raised proteins)	Frequent	Rare

* Sacral sensation : in extramedullary lesion (e.g., cauda equina lesion) lower sacral sensations are impaired (i.e., saddle anaesthesia), and in intramedullary lesion sensation is preserved in sacral dermatomes (sacral sparing).

Table 12 : Differentiation between cauda equina syndrome and conus medullaris lesion

	Features	Cauda equina syndrome	Conus medullaris lesion
1.	Onset	Gradual and unilateral (or asymmetrical involvement of both lower limbs)	Sudden and bilateral
2.	Aetiology	PID, metastases	Intramedullary SOL (e.g., glioma)
3.	Root pain	Severe low backache	Usually absent
4.	Motor involvement	Asymmetric limb weakness	Muscle changes are not marked
5.	Sensory loss	Asymmetric sensory loss (i.e., unilateral saddle anaesthesia)	Bilateral saddle anaesthesia
6.	Bladder and bowel function	Late and less marked	Early and marked
7.	Anal reflex ($S_{3\ 4}$)	Areflexia if roots are involved	Anal reflex absent
8.	Deep reflexes	Ankle and knee jerks are lost	Ankle and knee jerks are usually preserved
9.	Trophic changes	Less	Early
10.	Plantar response	Flexor or no response	Extensor (not always)

* Cauda equina lesion usually gives rise to LMN signs whereas conus medullaris lesion have UMN signs.

Abdominal reflex and its interpretations :

It is a polysynaptic nociceptive reflex. The clinical method goes like this :

1. The patient lies supine with exposed abdomen. The procedure is explained to him. Now the **stroke is given bilaterally in 3 places**—below the costal margins, at the level of the umbilicus and above the inguinal ligaments. Always compare right with the left side. Stroke is done lightly by a needle, a key or by the shaft of the hammer.
2. Stroke is given from outside to the centre on both the sides sequentially (the dermatomes are criss-crossed at the midline and if the stroke starts from midline, eventually by chance, the opposite side may be stimulated). The hammer stick should be placed at an acute angle with the abdominal skin and it should not caste any abrasion in the skin.
3. The normal reflex involves contraction of anterior abdominal musculature with movement of umbilicus in that direction. The reflex can be read by observing the movement of umbilicus (elevation, depression or lateral deviation) which is known as Beevor's sign.

   Root value : T_8 - T_{12}.

Loss of abdominal reflex :

(a) Physiological :

(i) Anxiety.
(ii) Obesity.
(iii) Lax abdominal wall.
(iv) Multiparous woman.
(v) Aged patient.
(vi) In the presence of ascites or pregnancy.
(vii) Previous abdominal surgery.

(b) Pathological :

(i) LMN type of lesion affecting the corresponding reflex arc.
(ii) Peripheral neuropathy.
(iii) UMN type of lesion above the level of the reflex arc (hemiplegia or myelopathy).

* Abdominal reflex is lost early in multiple sclerosis, and retained long in MND and cerebral diplegia. In hemiplegia, the abdominal reflex is lost in the paralysed side only. Over-response occurs in psycho-neurosis. Abdominal reflex (superficial reflex) is a local reflex arc modified by a 'cerebral arc' i.e., the pyramidal tract.

How cremasteric reflex is elicited ?

Scratch the medial side of upper thigh in a downward and inward direction (thigh remains abducted and externally rotated), and the response is upward movement of ipsilateral scrotum and testicle due to contraction of cremasteric muscle. Alternatively, this reflex can be easily elicited by pressing over the sartorius in the lower third of Hunter's canal. The spinal segment responsible are L_1 and L_2. This reflex

is lost in either UMN lesion or damage to L_2 spinal segments, or with hydrocele/hernia. It is also a polysynaptic reflex. Often it is very difficult to elicit this reflex in the elderly.

* Different superficial reflexes are : corneal and conjunctival reflex, abdominal reflex, cremasteric, and plantar reflex.

Special points in the physical examination in paraplegia :

(A) GENERAL SURVEY :

a) The patient is conscious and co-operative.

b) Decubitus—Lying helplessly without any movement of the lower limbs and with extension of all joints (lower limb). Upper limbs are within normal limit.

c) Lymph nodes—Not palpable (ref : tuberculosis, lymphoma, malignancy or HIV infection).

d) Pulse—Mention all the points.

e) BP—It is compulsory to record the BP (in all long cases); 125/85 mm of Hg in the present case.

f) Respiration—18/min, regular, abdominal in type (ref. : respiratory depression in G. B. syndrome).

g) Temperature—Record the oral temperature (tuberculosis, acute transverse myelitis, UTI etc.).

h) Oedema—Not present (may be present due to prolonged recumbency). Look for sacral oedema.

i) Skin—Absence of neurofibroma or cafe-au-lait spot.

* Mention all the points in general survey.

(B) NERVOUS SYSTEM :

a) The patient is conscious, alert, oriented and co-operative.

b) Higher functions : Mention all the subheadings—All are normal here; speech—Normal.

c) Cranium and spine ; Cranium is normal and there is presence of gibbus (T_7) with spinal tenderness.

*** One must examine the spine in all patients with paraplegia.**

d) Neck rigidity, Kernig's sign ; Absent; straight leg raising test—negative.

e) Cranial nerves ; No paralysis detected. Always search for optic atrophy (e.g., Friedreich's ataxia, multiple sclerosis) and Vllth nerve palsy (G.B. syndrome). Leukaemic or lymphomatous deposits may produce unilateral or bilateral Vllth nerve palsy (LMN type) with cord compression. Papilloedema may be found in G. B. syndrome. Mention the subheadings under the different cranial nerves.

f) Motor functions :

Both the upper limbs are within normal limit in all respect.

(i) Nutrition—Helpless attitude of both the lower limbs; no atrophy at present.

(ii) Tone—Clasp-knife spasticity in both the lower limbs; extensor tone > flexor tone.

(iii) Power—Grade I in left leg and Grade II in right leg.

(iv) Coordination—Upper limbs ; Normal.

Lower limbs : Could not be tested,

v) Involuntary movements—None present (search for fasciculation in the upper and lower limbs—MND). No flexor spasm seen.

g) Sensory functions :

Both the upper limbs are normal.

(i) Superficial—Pain, touch and temperature
(ii) Deep—Joint sense, position sense, muscle sense, pressure sense and vibration sense
(iii) Cortical sensation—Point localisation, stereognosis

} All are lost in both the lower limbs

*** There is a definite line of demarcation of sensory loss at the level of umbilicus (T_{10}). Below the level of umbilicus, there is no sensation present.**

h) Reflexes :

(i) Superficial—

a) Abdominal—

x) Upper—Present bilaterally,

y) Middle—Lost bilaterally,

z) Lower—Lost bilaterally.

b) Cremasteric—lost bilaterally.

c) Plantar response—**Extensor in both the lower limbs.**

Deep—	Right	Left
a) Biceps jerk	Normal	Normal
b) Triceps jerk	Normal	Normal
c) Supinator jerk	Normal	Normal
d) knee jerk	Brisk	Brisk
e) Ankle jerk	Brisk	Brisk
f) Clonus (ankle and patellar)	Present	Present

* Mention the jaw jerk under Vth cranial nerve.

(iii) Visceral—

a) Bladder—Catheterised at present. A self-retaining catheter with continuous drainage into a urosac is seen.

b) Bowel—Incontinence at present.

c) Swallowing—Normal at present.

(iv) Other reflexes—Glabellar tap, grasp reflex, palmo-mental reflex are WNL.

* Percuss the urinary bladder and confirm whether it is distended or not. Always see the colour of the urine present in the tube or urosac (chalky or turbid urine is seen in UTI, orange coloured urine is a clue to intake of rifampicin).

i) Trophic changes : Bed sore present over sacrum **(one must search for the trophic changes in paraplegia).**

j) Cerebellar functions : Normal (examinations involving lower limbs could not be performed),

k) Autonomic functions : Loss of sweating below the level of umbilicus.

1) Gait : Could not be tested.

*** Sacrum should be examined in paraplegia for the presence of oedema and/or bed sore.**

(C) RESPIRATORY SYSTEM : SEARCH FOR—

(i) Tuberculosis—Crepitations at the apex, consolidation or pleural effusion.

(ii) Bronchogenic carcinoma—Mass or collapse, pleural effusion, SVC syndrome.

(iii) Lymphoma—SVC syndrome or pleural effusion.

* Format of examination of 'Respiratory system' is similar to 'Hemiplegia'.

(D) G.I. TRACT AND GENITOURINARY SYSTEM **:** Palpate liver, spleen and examine for ascites (carcinoma, tuberculosis, lymphoma). Percuss for bladder fullness.

(E) CVS **:** As in 'Hemiplegia'.

(F) LYMPHORETICULAR SYSTEM **:** Examine for sternal tenderness, haemorrhagic spots, lymphadenopathy etc.

N.B. : Special points in nervous system (may be added in history sheet) : Structures involved in this patient—corticospinal tract, lateral spinothalamic tract, posterior column and T_{10} nerve roots (posterior).

Grading of muscle power in neurology (by Medical Research Council Scale) :

Grade 0 — Complete paralysis.

Grade 1 — A flicker of contraction only (visible or palpable) without any movement of joint.

Grade 2 — Movements possible only after elimination of gravity (side to side movement of a limb).

Grade 3 — Movements possible against gravity but not against resistance.

Grade 4 — Movements possible against gravity plus resistance but weaker than normal.

Grade 5 — Normal power.

* Often, "+' or '-' symbols are used to improve the sensitivity of the grading.

** Weakness of small muscles of hand and foot does not require grading.

How do you assess motor functions in neurology ?

Motor system is assessed by these 5 points :

1. Nutrition or bulk of muscles (i.e., inspection and palpation of muscles).
2. Tone of muscles.
3. Power of muscles.
4. Coordination of movement.
5. Involuntary movements.

* Examination of ***reflexes*** and ***gait*** are additional points in motor function.

Assessment of the nutrition of muscle :

Note the nutrition of muscles and observe the 'attitude' of the limb. It is assessed by :

(A) **Inspection—**

(i) Wasting or atrophy of muscles (e.g., convexity of deltoid or calf muscle is lost in wasting).

(ii) Flattening of overlying skin or hollowness over the area.

(iii) Prominent knuckles and other bony prominences.

(iv) Prominent interosseous gutters (in hand and foot).

(v) Prominent extensor/flexor tendons (in hand or foot).

N.B. : Examine the big muscles like biceps, quadriceps, calves plus small muscles of the hands and feet. During inspection, other than ***'attitude' of a limb,*** one should look for atrophy, hypertrophy, fasciculations, contracture, deformity or flexor spasm.

(B) **Palpation**—Atrophied muscles are small, soft and flabby on palpation. Normal muscle is elastic in feel.

(C) **Measurement**—Measure the girth of the specific muscle by a tape from a fixed bony point and compare it with the identical point on the other side **(compulsory).** For the upper limb, the fixed bony point is the elbow (olecranon process) and for the lower limb, it is the tibial tuberosity. The difference in the circumference (comparing with the opposite side) will give objective evidence of wasting or hypertrophy. Remember, in a right-handed person the girth of right upper limb may be slightly more than that of left upper limb.

* Muscles feel doughy (rubbery) in pseudohypertrophic muscular dystrophy, semi-elastic in true hypertrophy, tender in myositis, hard and inelastic in polymyositis, firm in spasticity, and 'woody' in rhabdomyolysis.

** If a patient have muscle atrophy in limbs, it is mandatory to measure the circumferance of limbs in long or short cases.

Table 13 : Differentiation between muscle 'atrophy due to LMN lesion' and 'disuse atrophy'

Atrophy (LMN lesion)	Disuse atrophy
1. Usually atrophy occurs from distal to proximal muscles of a limb	1. Occurs in antigravity muscles of a limb (e.g., in hemiplegia)
2. Muscle power is very much reduced	2. Power loss is less than LMN lesion
3. Fasciculations may be evident	3. Fasciculations are never seen
4. Trophic changes may develop	4. Trophic changes are usually absent.
5. Deep reflexes or jerks are lost or diminished	5. Deep reflexes or jerk may be brisk

Causes of hypo- and hypertonia :

Tone—It is defined as the resistance felt when a joint is moved passively through its range of movement, or it is the partially contracted condition of a muscle. Tone is of three types : normal (elastic type of resistance), hypotonia and hypertonia. Muscle tone is basically regulated by pyramidal and extrapyramidal pathways.

(A) **Hypotonia** (diminished resistance to passive movements) :

1. LMN lesion.
2. Posterior column lesion (tabes dorsalis).
3. UMN lesion in shock stage.
4. Chorea (the only extrapyramidal lesion with hypotonia).
5. Cerebellar lesion.
6. Myopathy (terminal stage).
7. Myasthenic crisis.
8. Down's syndrome.
9. Rickets.
10. Deep sleep.
11. Drugs—Hypnotics, sedatives, muscle relaxants and anaesthetics.
12. Periodic paralysis, cataplexy, sleep paralysis.

13. Hypokalaemia or hypercalcaemia.
14. Emaciation.

* ***LMN lesions*** include anterior horn cell disease (poliomyelitis), anterior nerve root lesion or radiculopathy (arachnoiditis, radiculitis, G. B. syndrome), nerve trunks and plexus lesion (metastasis, trauma), disorders of peripheral nerves (leprosy), diseases of myoneural junction (myasthenia gravis) and muscle disease (late stage of myopathy). Hypotonia is also known as **'FLACCIDITY'.** Hypotonia is usually associated with hyporeflexia, muscle wasting and weakness.

** Affection of anterior horn cells is known as 'neuronopathy', and that of plexus (brachial/lumbosacral) is termed as 'plexopathy'.

(B) **Hypertonia** (increased resistance to passive movements) :

1. UMN lesion (clasp-knife spasticity).
2. Extrapyramidal lesion except chorea (lead pipe or cogwheel rigidity)—e.g., parkinsonism.
3. Tetanus.
4. Hysterical hypertonia (resistance to passive movement increases in an irregular, jerky fashion in proportion to the effort applied by the examiner).
5. Sometimes in non-cooperative patients.
6. Tetany.
7. Myotonia during the contraction phase.
8. Strychnine poisoning.
9. Gegenhalten phenomenon (variable resistance found in catatonic states e.g., encephalopathy, carbon monoxide poisoning, phenothiazine-induced; dementia)—classically a manifestation of frontal lobe disease where flexors and extensors are equally affected.
10. Decerebrate regidity (there is marked contraction of all extensor muscles in the body).
11. Catatonia—a form of psychosis where the patient is hypomobile and mute. There is 'waxy flexibility' of the limbs.
12. Muscles around a painful joint.

*** In health, tone is being inhibited by pyramidal tract, and vestibulospinal and reticulospinal tracts; thus hypertonia occurs in UMN and extrapyramidal lesions.

**** Hypertonia is of two types—**SPASTICITY** (pyramidal lesion) and **RIGIDITY** (extrapyramidal lesion). Spasticity is usually associated with brisk tendon reflex, clonus, Babinski's sign and classical pattern of weakness. Rigidity (e.g., as seen in parkinsonism) is frequently associated with bradykinesia, static tremor and postural abnormality. 'Reflex rigidity' is the muscle spasm in response to pain e.g., neck rigidity in meningitis, board-like rigidity in peritonitis.

Features of hypotonia :

1. Unusual flexibility of joints leading to ***increased*** range of passive movement.
2. Inability to maintain sustained posture.
3. Muscles are soft and flabby, and smaller than normal.

* In **hypertonia** : Muscles feel stiff and there is ***diminished*** range of passive movement.

Clinical assessment of tone of muscles :

Tone may be **assessed at the bedside by the following methods** :

1. Classical method—By handling the limbs and moving them passively at their various joints (to feel the resistance to passive movement***)—best method.*** While testing the 'tone', ask the patient to relax and be comfortable, and
   (i) Expose the muscle fully.
   (ii) Passively move the joint concerned.
   (iii) Feel the resistance to stretching during the passive movement and see the contraction of the muscle.
2. Attitude of the patient—By seeing the attitude or decubitus, one can say that flexor tone has increased in the upper extremity and extensor tone has increased in the lower extremity on the affected side in a hemiplegic patient.
3. Hypotonic muscles are abnormally soft and flabby on palpation.
4. When lifted up and released, a hypotonic limb falls like a log of wood (i.e., it behaves in such a way as if the limb does not belong to the patient).
5. Ask the patient to outstretch the upper limbs and spread the fingers : Hypotonic limb may assume an abnormal posture i.e., hyperextended at elbow, hyperpronated at forearm, flexed at wrist and hyperextended fingers at MCP joints is known as 'dinner-fork deformity'.

Always compare with the opposite side while assessing tone.

Patient must be fully relaxed and comfortable before assessing tone.

Causes of cord compression at multiple levels :

1. Neurofibromatosis.
2. Patchy arachnoiditis.
3. Prolapsed intervertebral disc (PID).
4. Secondary deposits.
5. Cervical spondylosis.
6. Arteriovenous malformations.

Causes ***of pure motor paraplegia :***

1. Hereditary spastic paraplegia.
2. Lathyrism.
3. G. B. syndrome.
4. Amyotrophic lateral sclerosis (MND).
5. Fluorosis.
6. Erb's spastic paraplegia (syphilitic).

Recognition of minor weakness in a limb :

By early and easy fatiguability.

Sudden onset of 'generalised weakness' without loss of consciousness :

1. Transient ischaemic attack (TIA).
2. Hypoglycaemia (subjective weakness).
3. G. B. syndrome.
4. Acute transverse myelitis.
5. Acute anterior poliomyelitis.
6. Poisoning (botulinum).
7. Electrolyte imbalance (1K\ iCa*', TMg''
8. Snake bite (Elapidae group).
9. Myasthenic crisis.
10. Periodic paralysis.
11. Sleep paralysis/cataplexy.
12. Hysterical.

Patient with hypoglycaemia may go into coma, if not diagnosed in time.

Possible causes ***of funny turns' :***

Episodes of lost or altered consciousness may be called as 'black-out', 'funny turns' or 'going dizzy'.

1. Hypoglycaemia.
2. Temporal lobe epilepsy.
3. Phobic anxiety states.
4. Narcolepsy.
5. Hyperventilation.
6. Amnesic episodes.

Spastic paraplegia with loss of deep reflexes :

1. In shock stage.
2. Sometimes seen in the presence of bed sore, urinary tract infection (UTI) or malnutrition—the reflex arc may be suppressed leading to loss of jerks.
3. Haematomyelia (sudden bleeding from a vascular malformation)/myelomalacia (thrombosis of a spinal artery with infarction).
4. Associated radiculitis.
5. INH therapy in caries spine causing peripheral neuropathy.
6. If contracture is developed in lower limbs.

* Bed sore, UTI or malnutrition may result in persistent flaccid paraplegia in UMN lesions.

Causes ***of quadriplegia :***

Weakness of all the four limbs can occur in the lesion from cortex to C_5 level of spinal cord :

1. Cerebral palsy.
2. Bilateral brainstem lesion (glioma).
3. Cranio-vertebral anomaly.
4. High cervical cord compression.
5. Multiple sclerosis.
6. Acute anterior poliomyelitis.
7. Motor neurone disease.
8. G.B. syndrome.
9. Peripheral neuropathy.
10. Myopathy or polymyositis.
11. Myasthenia gravis (crisis).
12. Periodic paralysis.

* For monoplegia, read the section on 'Hemiplegia'.

What are cranio-vertebral anomalies ?

These are the anomalies around the cranio-vertebral junction, some of which may not produce any disability in life. They are :

1. Platybasia (increase in the basal angle of the skull).

2. Basilar invagination (elevation of floor of posterior fossa of the skull).
3. Atlanto-axial dislocation.
4. Occipitalisation of atlas.
5. Klippel-Feil anomaly (fusion of cervical vertebrae).
6. Arnold-Chiari malformation (medulla and cerebellum are extended downwards through foramen magnum).
7. Hypoplastic or separate odontoid process.

The usual **manifestations** of cranio-vertebral anomaly are :

1. Short neck, restricted cervical movements and low posterior hairline (Feil's triad).
2. Spastic quadriparesis of gradual onset; hypertonia, brisk jerks in all the limbs, presence of Babinski's sign.
3. Wasting of the small muscles of hands.
4. Cerebellar signs.
5. Mirror-image movement, impaired position and vibration sense etc.

* Low hairline = hairline below C_4 vertebra.

** Short neck = Ratio of length of the body to length of the neck is > 13 : 1.

Features of 'high' cervical cord lesion :

High cervical cord lesion is seen in cranio-vertebral anomaly, fracture-dislocation of upper cervical spine, haematomyelia, cervical spondylosis and cervical cord tumours. The common features are :

1. Horner's syndrome.
2. Features of injury to spinal accessory nerve (paralysis of sternomastoid and trapezius).
3. Features of injury to spinal tract of trigeminal nerve (i.e., analgesia and thermo-anaesthesia may be limited to ophthalmic and maxillary division in face).
4. Vertical nystagmus (down-beating).
5. Mirror-image movement (sometimes seen in Arnold-Chiari malformation).

* Plus there is quadriplegia.

Possible aetiology of episodic paralysis :

1. Myasthenia gravis.
2. Hyperthyroidism.
3. Periodic paralysis (hypokalaemic, hyperkalaemic, normokalaemic).
4. Botulinum poisoning.
5. Primary hyperaldosteronism.
6. G. B. syndrome.

What is lathyrism ?

It is a slowly evolving epidemic pure motor paraplegia (spastic) due to consumption of 'Khesari dal' (lathyrus sativus; a drought-resistant pulse) for long period. Ultimately, the patients develop into disabling spastic paraplegia when they have to crawl on hands. It is common in U.P, Bihar, Rajasthan and M.P in India, and many persons either of the same family or of the same locality may be affected. The causative factor is a neurotoxin and is known as BOAA (Beta Oxalyl Amino Alanine).

What is arachnoiditis ?

A non-specific term referring to inflammation of arachnoid, usually of unknown origin, which may result from tuberculosis, syphilis, sarcoidosis or a post-operative event (e.g., spinal surgery). Constant and severe bilateral asymmetric radicular limb pain is characteristic. Features of radiculopathy is pronounced than features of spinal involvement. Slight fever, features of root compression (e.g., areflexia) may be present. Lumbosacral region is commonly affected. Lumbar puncture may reveal partial or total spinal block. No satisfactory treatment is available.

What is tropical spastic paraplegia ?

It is the HTLV-I associated non-compressive myelopathy where the patient (commonly women) at her third to sixth decade of life complains of gradual onset of weakness of legs (paraparesis), and usually confined to wheel-chair within 10 years. Signs of UMN lesion are found in legs; sensory symptoms and signs are rarely obtained. Bladder involvement with constipation are common. Usually the patient needs myelogram or MRI scan to exclude compressive myelopathy. Affected persons become seropositive for HTLV-I. Few patients show minor response to corticosteroid therapy.

Possible causes of paraplegia with optic atrophy :

The second cranial nerve should always be examined in paraplegia. Optic atrophy is found in :

1. Hereditary—Friedreich's ataxia.
2. Demyelinating—Multiple sclerosis, Devic's disease.
3. Infections like tuberculosis, arachnoiditis, syphilis.
4. Subacute combined degeneration, pellagra.
5. Eale's disease.
6. Subacute myelo-optic neuropathy (SMON). alcohol-induced.

Why do you say compressive myelopathy in this patient ?

The features of **cord compression** are :

1. Usually of gradual onset but may be sudden.
2. Presence of root pain.
3. Symptoms start in one leg and then gradually involve the other leg. Both sensory and motor symptoms are present, and there is progressively increasing course of the disease.
4. Asymmetrical signs and symptoms between two lower limbs are very suggestive.
5. Spastic paraplegia with loss of superficial and deep sensation in varying degree and combination. There is presence of girdle-like sensation in the trunk with zone of hyperaesthesia above.
6. Bladder disturbance is common.
7. Deformity or tenderness in the spine goes in favour of cord compression.

All the above mentioned features are present in this patient.

How caries spine causes ***paraplegia*** ?

1. Compression of the spinal cord by cold abscess (extradural)—Commonest.
2. Tuberculous myelitis (involvement of the spinal cord from the bone).
3. Tuberculous endarteritis or thrombosis of the radicular artery—Responsible for the sudden onset of paraplegia or acute exacerbation of existing paraplegia.
4. Pachy meningitis or arachnoiditis.
5. Granulation tissue encircling the dura matter.
6. Compression by sequestrated bone.
7. Dislocation of vertebra—Rare.
8. Combination of multiple factors.

*** Caries spine should always be thought as the first cause of paraplegia in India, irrespective of age and sex of the patient. Mid-thoracic region is the commonly involved site.**

Can it be a case of metastasis in the spine ?

'Metastasis in the spine' is unlikely in this case as :

1. Age of the patient is only 28 years (though leukaemic and lymphomatous deposits may be seen in the young).
2. Commonly there is sudden onset of paraplegia though gradual onset paraplegia may be seen.
3. No evidence of primary growth is found (like bronchogenic carcinoma, gastric carcinoma, prostatic carcinoma). No lymphadenopathy is detected.
4. If I am allowed to do the X-ray of the spine, it would show that there is (caries spine) diminution of intervertebral space, collapse of the adjacent vertebrae and paravertebral cold abscess ('Metastasis in the spine' shows destruction of the vertebra without any narrowing of the intervertebral disc space).

* Root pain is more common in malignancy than in caries spine. Tenderness and deformity of the spine are present in both though the tenderness is more common in malignancy. Metastasis causes paraplegia by (i) Compression by the deposits, and (ii) Collapse of the vertebra.

Synopsis of bladder dysfunction in neurological diseases :

The conscious control of micturition have its centre within pre-frontal cortex. The urinary bladder receives nerve supply from sympathetic ($L_{1\ 2\ 3}$— the nerve of filling) and parasympathetic ($S_{2\ 3\ 4}$— the nerve of evacuation) nerves. Bladder dysfunction arising out of neurological disorders is known as ***neurogenic bladder.***

(A) UNINHIBITED (CORTICAL) BLADDER — Found in frontal lobe tumours, parasagittal meningioma, dementia. There is urgency at low bladder volume (like a child) with sudden uncontrolled evacuation of urine in inappropriate time and place. It is also known as 'mental incontinence' (loss of social control of micturition).

(B) SPINAL BLADDER (with or without autonomic dyssynergia)—

a) Incomplete lesion :

(i) Precipitancy—Due to involvement of inhibitory fibres e.g., multiple sclerosis.

(ii) Hesitancy—Due to involvement of facilitatory fibres e.g., incomplete cord compression.

b) Complete lesion :

(i) Retention of urine with overflow incontinence -— Commonly seen in 'neural shock stage' of acute transverse myelitis. Evacuation of the bladder is always incomplete.

(ii) AUTOMATIC BLADDER (UMN bladder)—The evacuation is always complete. It is commonly seen when the 'neural shock stage' is over and evacuation occurs by local reflex arc. The bladder is small, spastic and the patient complains of frequency, urgency and urge incontinence.

c) Lesion in the local reflex arc —

(i) Sensory paralytic bladder—There is loss of awareness of fullness of bladder e.g., tabes dorsalis, diabetes mellitus, multiple sclerosis. Large volume of urine collects in the bladder with a huge residual volume.

(ii) Motor paralytic bladder—Inability to initiate and continue micturition. It is commonly seen in pelvic neoplasm, trauma, polyradiculopathy etc.

(iii) AUTONOMOUS BLADDER (LMN bladder)—Commonly seen in cauda equina lesion, pelvic malignancy, spina bifida etc. There is no sensation of bladder fullness but having continual dribbling. UTI is very common.

* Symptoms of neurogenic bladder are urgency, hesitancy, precipitancy, incontinence and retention of urine. Other causes of hesitancy and precipitancy are CVA, head injury, cerebral tumour, BHP, bladder neck obstruction etc.

** ***Urinary incontinence*** (involuntary urinary leak) is of four types :

Urge incontinence (uncontrolled passage of urine preceded by strong urge to void—due to overactivity of detrusor muscle; may have UTI), stress incontinence (urinary leak after stress i.e., coughing, sneezing), overflow incontinence (urinary leak due to chronic urinary retention), and true incontinence (voids urine at any time and at any position due to loss of sphincteric function).

How do you like to investigate paraplegia ?

1. Blood (R/E)— TC, DC, ESR; sugar, urea and creatinine.
2. Urine—Routine examination and culture-sensitivity test are done.
3. Mantoux test—Positive in tuberculosis and may be negative in lymphoma.
4. Chest X-ray—To exclude tuberculosis, bronchogenic carcinoma, lymphoma or metastasis.
5. X-ray **of the spine** (antero-posterior and lateral view)—Helps in the diagnosis of caries spine, metastasis, fracture or dislocation of vertebra. It helps in detection of the site of spinal lesion.
6. Lymph node biopsy (if possible).
7. CSF examination—Features of the Froin's loculation syndrome (below the level of cord compression) are :

   (i) Low CSF pressure.

   (ii) Xanthochromia.

   (iii) Clot formation on standing.

   (iv) High protein content.

   (v) Positive Queckenstedt's test (i.e., no rise in CSF pressure following compression of the internal jugular vein).

   CSF examination may also be helpful in multiple sclerosis, arachnoiditis and G.B. syndrome. For the CSF findings in G. B. syndrome, read the section on 'Peripheral neuropathy'.
8. Myelography (by myodil or metrizamide)—Helps in detection of the level and nature of obstruction. Many a time, combined **CT myelography** is done. Now-a-days, it has been replaced by MRI **scan** of the spinal cord.
9. Miscellaneous—Muscle biopsy, muscle enzymes, EMG (demyelination in G. B. syndrome), blood for vitamin B_{12} estimation, VDRL and Kahn test, blood for HIV (these tests are done for non-compressive myelopathy), or albumino-cytological dissociation in G. B. syndrome.

* Froin's loculation syndrome usually results from spinal block as a result of spinal tumour.

Common causes of xanthochromia :

'Yellowish discolouration of the CSF' (xanthochromia) is due to :

1. Old subarachnoid haemorrhage (due to presence of old blood).
2. Guillain-Barre syndrome (due to high protein).
3. Acoustic neurofibroma (due to high protein).
4. Froin's loculation syndrome (spinal subarachnoid block and is due to high protein).
5. Deep jaundice (due to high bilirubin).
6. Massive old intracerebral bleed or haemorrhagic infarction (due to presence of old blood).

Causes of albumino-cytological dissociation in CSF :

It means there is increased protein in CSF without any rise in cell count. The causes are :

1. Guillain-Barre syndrome.
2. Froin's loculation syndrome.
3. Acoustic neurofibroma.

Complications of paraplegia :

1. Pressure sores (trophic changes).
2. Urinary tract infections.
3. Faecal impaction.
4. Contracture of limbs.
5. Chronic renal failure (a common cause of death).

How do you like to manage paraplegia :

1. Nutritious diet—In an adult, 3500 calories/day shquld be given. There is no need to put the patient on Ryle's tube. Arrange for an alarm bell at the bedside.
2. **Care of the bladder, bowel and trophic ulcers**—
   a) Bladder—Put a self-retaining catheter under aseptic technique, change the catheter regularly at 2-3 weeks interval, bladder wash, to help in bladder control by application of clip to the drainage tube, R/E and C/S of urine—as and when necessary, antibiotics in UTI.
   b) Bowel—Treatment of constipation is done by laxatives; manual evacuation may be necessary. Rectal incontinence is difficult to treat.
   c) Skin—Bed sores are formed due to loss of sensation and diminished blood supply. So the patient should be re-positioned every 2-4 hourly (change of posture) and the skin should be kept dry and clean. Specialised beds (air or water cushioned bed), ripple mattresses, and soft bed coverings prevent development of bed sores. Trophic ulcers (if formed) are cleaned by hydrogen peroxide, dressed by sofra tulle. Aseptic care should always be taken. Plastic surgery - if necessary.
3. Muscle spasms are treated by diazepam, baclofen (5 mg, thrice daily, orally), tizanidine (2mg, thrice daily, orally) or botulinum toxin.
4. The underlying cause should be treated e.g.,—
   a) In caries spine—Application of traction in early stage. Later on 'plaster jacket' is applied for immobilisation. Antituberculosis chemotherapy is usually continued for at least 9 months to 1 year.
   b) Treatment of carcinoma or lymphoma by radiotherapy and/or chemotherapy.
   c) Acute transverse myelitis—High dose corticosteroids (1 mg/kg/day) for two weeks with gradual tapering; high dose methyl prednisolone is very effective.
   d) G. B. syndrome—Read the last question in section on 'Peripheral neuropathy'.
5. Physiotherapy—Aim is to obtain the maximum development of all those muscles in which voluntary power remains and prevention of flexor contractures in the lower limbs. Passive movements are carried out in the lower limbs once or twice daily. Later on arrangement of wheel chair, walking callipers are done according to the necessity (rehabilitation).
6. Surgery—Drainage of cold abscess, fusion of the verterbra, laminectomy for caries spine, skin grafting for bed sore are rarely needed.

* **Acute transverse myelitis and G.B.syndrome are given as long cases.**

(iv) Power—

Lower limbs—Proximal muscles are of grade V but extensors of legs are of Grade II; flexor of legs are of Grade III.

Upper limbs—Proximal muscles are of Grade V but the distal muscles are of grade IV.

No involvement of trunk or respiratory muscles.

(v) Coordination —

Upper limbs—Within normal limit.

Lower limbs—Could not be tested.

(vi) Involuntary movements—Nil.

g) Sensory functions—

1. Superficial—Pain, temperature and touch sensations are lost in the distal part of the limbs and it is rather bilaterally symmetrical involvement. Proximal sensations are relatively intact. No involvement of face and neck, and the sensory involvement is 'glove and stocking' in distribution (there is no 'definite' line of demarcation between normal and anaesthetic skin); patchy involvement.

2. Deep—

(i) Vibration sense—Lost distally, impaired proximally.

(ii) Muscle sense—Calf muscles are tender on palpation and squeezing (Abadie's sign).

(iii) Position sense—Lost distally.

(iv) Joint sense—Lost distally.

3. Cortical—

(i) One point localisation ^ 1

(ii) Two point discrimination

(iii) Stereognosis 1 f All are impaired

(iv) Graphaesthesia

(v) Sensory extinction *

* In a patient of peripheral neuropathy, cortical sensations can not be tested properly,

h) Reflexes—

1. Superficial—	**Right**	**Left**
(i) Abdominal	No response	No response
(ii) Cremasteric	No response	No response
(iii) Plantar response	**No response**	**No response**
2. Deep—		
(i) Biceps jerk	Normal	Normal
(ii) Triceps jerk	Normal	Normal
(iii) Supinator jerk	Diminished	Diminished
(iv) Knee jerk	Diminished	Diminished
(v) Ankle jerk	Lost	Lost
(vi) Clonus	Absent	Absent

3. Visceral—

(i) Bladder 1

(ii) Bowel f Within normal limit

(iii) Swallowing)

4. Other reflexes—Glabellar tap, grasp reflex and palmo-mental reflex revealed no abnormality.

* *Plantar response is never extensor in peripheral neuropathy.*

i) Trophic changes—A trophic ulcer is seen in the ball of the great toe of right foot; a large bed sore is seen over the sacrum. Charcot joint is not present,

j) Cerebellar functions—Normal.

k) Autonomic functions—Within normal limit (important in diabetes mellitus and G.B. syndrome).

1) Gait—Could not be tested (there will be high-stepping gait if the patient could walk).

Romberg's sign—Could not be tested.

(C) CVS :

(i) Pulse and BP—Describe the pulse in details; BP isl40/80 mm of Hg (supine).

(ii) Neck veins—Neither engorged nor pulsatile.

(iii) Shape of precordium—Within normal limit.

(iv) Apex beat—Present in left 5th ICS, 1 /2" inside the left MCL.

(v) Pulsation in different areas—No pulsation seen.

(vi) Palpation of different areas—No thrill, no pulsation felt, no plapable heart sound.

Case 18

PERIPHERAL NEUROPATHY

What is your diagnosis ?

This is a case of peripheral neuropathy resulting from chronic alcoholism.

How your patient presented himself ?

The 55 years male patient presented in the hospital 2 weeks back with the chief complaints of :

1. Sensation of pins and needles (tingling and numbness) in the distal parts of the upper and lower limbs for last 5 months, with
2. Loss of power or weakness in all the four limbs for last 3 months which was more pronounced distally, and
3. Wasting (thinning) of the distal part of the limbs with pain in the limbs for last 1 month.

The onset of the disease was insidious and it was gradually progressive. The tingling sensation started distally and it was limited in the 'glove and stocking' distribution (feet earlier than hands). The weakness started in the distal part of all the four limbs on different dates. According to the patient, there was no weakness in the proximal muscles and the weakness was not related to repetitive use of muscles (vide myasthenia gravis). He also complained of weakness in the grip and difficulty in holding objects. However, according to the patient, legs are weaker than hands. There was no H/O waxing and waning (vide multiple sclerosis). He had no H/O respiratory distress (vide G.B. syndrome). He is now facing difficulty in standing and walking. The patient is not complaining of any bladder and bowel symptoms at present.

He did not suffer from haematemesis or melaena (due to alcoholism), headache, vomiting, convulsions, speech difficulty, diplopia, nasal regurgitation or intonation. There was neither any past H/O spinal trauma, fever, H/O contact with tuberculosis, H/O exposure to STD, vaccination in recent past, exposure to arsenicals or INH or vincristine, nor the patient was suffering from ***diabetes mellitus.*** The patient was taking alcohol in a dose of 60-90 ml of whisky, more or less, daily for last 15 years.

* Preceding the 'glove and stocking' type of paraesthesia, there may be hyperaesthesia. The distal paraesthesia usually affects the feet first and then the hands are affected.

Special points in the physical examination in peripheral neuropathy :

(A) GENERAL SURVEY :

a) The patient is conscious and co-operative.
b) Anaemia—Moderate.
c) Jaundice—Absent.
d) Oedema—Nil.
e) Parotid glands—***A*** bit swollen (due to chronic alcoholism).
f) Gynaecomastia—Absent.
g) Facies—A bit flushed and anxious (due to chronic alcoholism).
h) BP—140/80 mm of Hg.
i) Skin—No white spots detected (vide leprosy).
j) All the limbs are lying helplessly with bilateral foot drop.
k) Ulnar and common peroneal nerves—Not thickened (vide leprosy).
l) Decubitus—Dorsal decubitus at present; lying helplessly with bilateral foot drop

* Mention all the points in general survey.

(B) NERVOUS SYSTEM :

a) The patient is conscious, alert, oriented and co-operative.
b) Higher functions—Normal; speech is not affected.
c) Cranium and spine—Within normal limit.
d) Neck rigidity, Kernig's sign—Absent; straight leg raising test—negative.
e) Cranial nerves—There is neither palatal palsy (diphtheria) nor Vllth nerve palsy (G.B. syndrome). Ophthalmoscopy—Not done.
f) Motor functions—
   (i) Attitude—Bilateral foot drop with paucity of spontaneous movements in the limbs.
   (ii) Nutrition—Wasting of small nuscles of the feet and hands. Wasting is clearly seen in extensors of legs.
   (iii) Tone—Diminished in all the limbs, specially in the distal muscles.

Claw hand deformity

Pes cavus (claw foot). The foot is high-arched; callosity has developed in the sole

Flat foot deformity (pes planus) in Marfan's syndrome

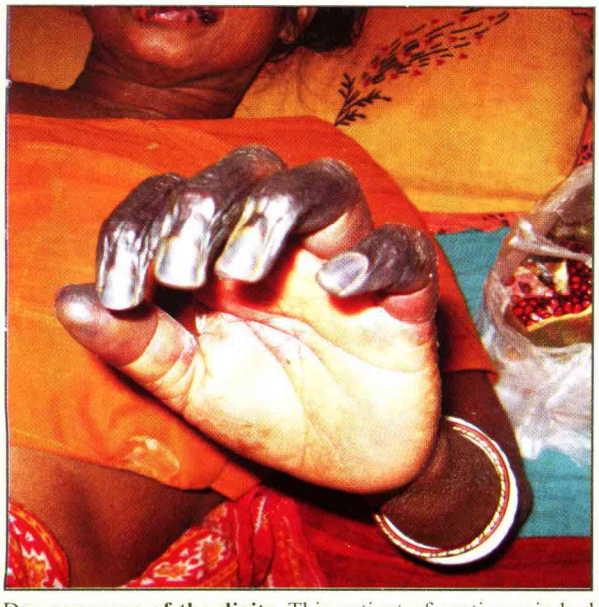

Dry **gangrene of the digits.** This patient of septicaemia had gangrene of all the digits of four limbs – 'symmetrical peripheral gangrene'

Diabetic foot in a patient of irregularly treated T_2DM

Infiltrated ear in **lepromatous leprosy**

Acute swelling of left first metatarsophalangeal joint in **gout** – hot, red, swollen, painful joint with shiny overlying skin

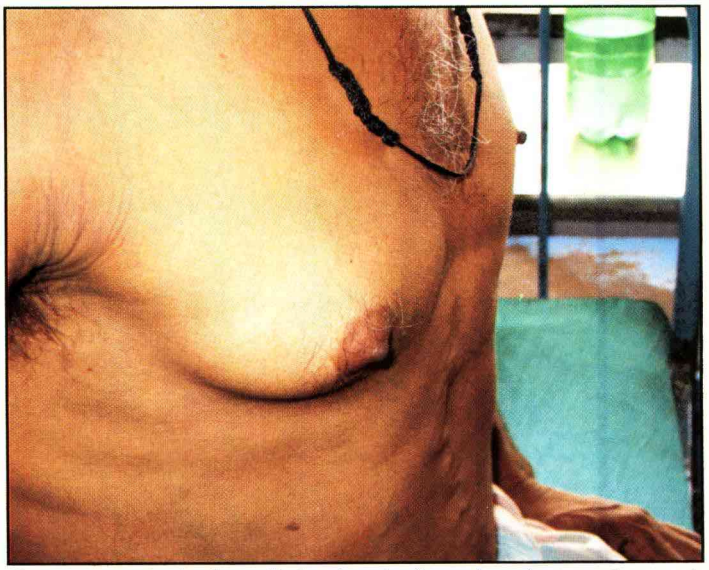

Gynaecomastia (unilateral) developed after spironolactone therapy in cirrhosis of liver. Venous engorgement in the abdomen due to portal hypertension is seen

Locomotor brachialis seen in a paient of thrombotic stroke

Visible, inflamed and tender temporal artery in **temporal arteritis** (giant cell arteritis); the patient presented with severe headache and claudication of the jaw

(vii) Heart sounds—Within normal limit.
(viii) Murmur—Absent.

D) G. I. TRACT AND GENITOURINARY SYSTEM :

(i) Angular stomatitis—Present.
(ii) Glossitis—Present.
(iii) Epigastrium—Tender on palpation.
(iv) No venous prominence over abodomen.
(v) Spleen—Not palpable.
(vi) Liver—Mild enlargement, soft and tender.
(vii) Ascites—Absent.
(viii) Testes—Within normal limit.
(ix) P/R examination—Not done.

* All the G.I. features are due to chronic alcoholism (vitamin and iron deficiency).

(El RESPIRATORY SYSTEM :

(1) Shape of the chest ^
(ii) Movement of the chest I Within normal limit
(iii) Trachea and apex beat **J**
(iv) Percussion—Normal resonant note on both sides of the chest.
(v) Breath sound—Vesicular.
(vl) Vocal resonance—Normal on both sides.
(vii) Adventitious sound—None.

(F) LYMPHORETICULAR SYSTEM :

(i) Lymphadenopathy—Absent.
(ii) Sternal tenderness—Absent.
(iii) Haemorrhagic spots—Absent.

Why do you say peripheral neuropathy ?

Discuss the presenting symptoms plus important signs elicited. Give stress on power of muscles, details of sensory functions and trophic changes.

Importance of 'past history' in peripheral neuropathy :

1. H/O chronic alcohol intake.
2. Diabetes mellltus, renal failure or leprosy.
3. Spinal trauma.
4 H/O contact with tuberculosis, vaccination in recent part, H/O exposure (HIV infection).
5. Exposure to drugs (INH, vincristine), solvents, pesticides or heavy metals.
6. Fever (areflexic paralysis in G.B. syndrome).

Common causes of peripheral neuropathy :

(A) Toxic—

1. Alcohol.
2. Pb, As, Hg, TOCP poisoning.
3. Drugs—Vincristine, nitrofurantoin (NFT), INH (by causing pyridoxine deficiency).
4. Radiation.

(B) Metabolic—

1. Diabetes mellitus.
2. Chronic renal failure (CRF).
3. Porphyria.
4. Hypothyroidism.
5. Amyloidosis.

(C) Injective or *inflammatory—*

1. Leprosy.
2. Diphtheria.
3. Landry-Guillain-Barre syndrome.
4. Viral hepatitis.
5. Enteric fever.
6. HIV infection.

(D) Deficiency—Thiamine, nicotinic acid, pyridoxine, vitamin B_{12}, pantothanic acid, vitamin E and iolate

(E) Connective tissue diseases—

1. SLE.
2. Rheumatoid arthritis.
3. Polyarteritis nodosa.
4. Cryoglobulinaemia.
5. Sjogren's syndrome.

(F) Disseminated malignancy, paraneoplastic syndrome, lymphoma, multiple myeloma.

(G) Hereditary or idiopathic (e.g., Charcot-Marie-Tooth disease).

Pathogenesis of peripheral neuropathy is classified into two types : demyelination and axonal Acquired demyelinating polyneuropathy falls into two major groups : acute form, i.e., G. B. syndrome (AIDP), and more chronic forms, i.e., chronic inflammatory demyelinating polyneuropathy (CIDP- , steroid-dependent).

** ***Small fibre neuropathy*** : muscle power and deep reflexes are less affected than the affection of pain and temperature sensations.

Large fibre neuropathy : significant motor disturbance and loss of deep reflexes with minimal sensory loss.

Five common causes of peripheral neuropathy in clinical practice :

1. Leprosy (commonest cause globally).
2. Diabetes mellitus.
3. G.B. syndrome.
4. Chronic renal failure (CRF), and
5. Toxin-induced : alcohol-induced or INH therapy.

Classification of neuropathy by evolution :

- Acute : G. B. syndrome, diphtheria, porphyria, malignancy, drugs (TOCP, As)
- Subacute : alcoholic, nutritional, toxic (hexacarbon)
- Chronic : diabetes, CRF, CIDP, paraneoplastic
- Longstanding : Charcot-Marie-Tooth disease
- Recurrent : relapsing CIDP, porphyria, occupational toxic neuropathy, alcoholic

Sensations carried by long tracts :

a) The spinothalamic tract (lateral column) carries :

(i) Pain.
(ii) Temperature (hot and cold), and
(iii) Crude touch.

Lateral column also contains pyramidal tract (motor pathway).

The tract of Goll and Burdach (posterior column) carries :

(i) Vibration sense
(ii) Muscle sense
(iii) Pressure sense , Proprioception or deep sensation
(iv) Joint sense
(v) Position sense «
(vi) Fine touch (well-localized touch), and
(vii) Cortical sensations (assay parietal lobe functions)

* Testing of sensory functions are described in the section on 'Charcot joint'.

Peripheral neuropathy with hypertension :

1. G. B. syndrome.
2. Polyarteritis nodosa.
3. Lead poisoning.
4. Chronic renal failure.
5. Porphyria (acute Intermittent variety).
g. Amyloidosis.

Predominantly motor neuropathy :

1. G. B. syndrome.
2. Porphyria.
3. Connective tissue diseases.
4. Diphtheria.
^ . . Paraneoplastic.
g Infectious mononucleosis.
7. Lead poisoning.
8. HIV/AIDS
g Hereditary neuropathy.
10. Dapsone-induced.

r,ath Thefe <;auses of Proximal motor weakness > distal motor weakness in peripheral neuropathy, also in diabetic amyotrophy, proximal muscles are predominantly affected.

Predominantly sensory neuropathy :

1. Leprosy.
2. Drugs (vincristine, NFT, INH).
3. Diabetes mellitus.
4. Renal failure (initially).
5. Hereditary sensory neuropathy.
6. HIV infection.
7. Paraneoplastic syndrome.
8. Thalidomide toxicity.

Peripheral neuropathy with cranial nerve involvement :

1. G. B. syndrome (VII): Miller Fisher syndrome (III, IV).
2. Leprosy (VII).
3. Diabetes mellitus (III, VI).
4. Diphtheria (III, VI, IX. X).
5. Sarcoidosis (VII).

Painful peripheral neuropathy :

1. Diabetes mellitus.
2. Alcoholic polyneuropathy.
3. Carcinomatous neuropathy.
4. Vitamin B, and B_{12} deficiency.
5. Porphyria.
6. Arsenic-induced.

Drugs causing peripheral neuropathy :

1. INH
2. Nitrofurantoin (NFT).
3. Vincristine.
4. Paclitaxel.
5. Thalidomide.
6. Cisplatin.
7. Suramin.
8. Amiodarone.
9. Pentamidine.
10. Pyridoxine (high dose).
11. Stavudine.

Causes of mononeuritis multiplex :

It is the asymmetrical involvement of multiple non-contiguous peripheral nerves serially or at a time over days to years, and is usually due to arteritic involvement of vasa nervorum (i.e., multiple mononeuropathy). Diagnosis is done clinically and is supported by electrical studies (nerve conduction velocity). It gives a picture of distal symmetric neuropathy and is commonly found in :

1. Leprosy.
2. Diabetes mellitus.
3. Polyarteritis nodosa.
4. Sarcoidosis.
5. Rheumatoid arthritis.
6. Amyloidosis.
7. Vasculitis.
8. Trauma.
9. HIV infection.
10. G. B. syndrome.

The involvement is usually asymmetrical with predominant affection of the lower limbs.

N.B. :
- Neuropathy—pathological process affecting peripheral nerve or nerves.
- Peripheral neuropathy or polyneuropathy—a diffuse symmetrical disease process of peripheral nerves (peripheral means that the disorder is outside the CNS) involving the peripheral parts of body and gradually progresses proximally.
- Mononeuropathy—focal involvement of a single nerve trunk (e.g., ulnar, radial or median nerve).
- Mononeuritis multiplex—already described above.
- Radiculopathy—a pathological process which affects the nerve roots.

Which distal sensation is lost early in peripheral neuropathy ?

Vibration sense is lost early in peripheral neuropathy (very common feature in diabetic neuropathy). Peripheral neuropathy follows the rule—'the longer the nerve fibre (i.e., axon length), the earlier is the involvement', and this is why the distal part of the body ('glove and stocking' distribution) is affected earliest and most.

How diphtheritic neuropathy presents ?

1. Paralysis of the soft palate and posterior pharyngeal wall may occur very early (within 10 days).
2. Then paralysis of accommodation follows (difficulty in reading small objects).
3. Polyneuropathy usually develops 2-6 weeks after the onset of the disease. Weakness involves all the four limbs and descends from arms to legs.

* Among all cranial nerves the Illrd, Vlth, IXth and Xth nerves are commonly affected.

Presentations of diabetic neuropathy :

1. Distal, symmetrical, mixed sensory-motor polyneuropathy (commonest)—mainly small fibre, mixed type or large fibre neuropathy.
2. Asymmetrical, proximal motor neuropathy (diabetic amyotrophy).
3. Distal, symmetrical, sensory polyneuropathy.
4. Asymmetric mononeuritis multiplex (painful).
5. Acute mononeuropathy (isolated, painless Illrd, IVth and Vlth cranial nerve palsy; affection of ulnar, median, femoral nerves rarely).
6. Radiculopathy (usually involves spinal nerves, over the chest wall or abdomen).
7. Autonomic neuropathy.

Neuropathy with predominant upper limb involvement :

1. Dipththeria.
2. Porphyria.

Peripheral neuropathy with significant autonomic involvement :

1. Diabetes mellitus.
2. G. B. syndrome.
3. Acute intermittent porphyria.
4. Peroneal muscular atrophy.
5. AIDS.
6. Amyloidosis.
7. Botulism.
8. Sjogren's syndrome.

Table 14 : Differentiation between myelopathy, neuropathy and myopathy

Features	Myelopathy	Neuropathy	Myopathy
1. Onset	1. Any age	1. Any age	1. Childhood
2. Tingling and numbness	2. Very rare	2. Present	2. Never occurs
3. Bladder & bowel involvement	3. Occurs	3. Usually absent	3. Never occurs
4. Atrophy and pseudohypertophy	4. Only atrophy	4. Only atrophy	4. Both present
5. Bilaterally symmetrical involvement	5. May be present	5. Initially asymmetrical	5. Present
6. Cranial nerve involvement	6. None	6. May be present (G.B. syndrome and diphtheria)	6. Never occurs
7. Girdle-like sensation	7. Present in compressive myelopathy & acute tr. myelitis	7. Absent	7. Never occurs
8. Sensory involvement	8. Upper border of sensory loss may present	8. Patchy	8. Never occurs
9. Motor involvement	9. According to involvement of myotome	9. Mainly distal	9. Predominantly proximal
10. Tone of muscles	10. Spasticity (except in shock stage)	10. Hypotonia (flaccidity)	10. Hypotonia (terminal stage)
11. Deep reflexes	11. Brisk (except In shock stage)	11. Lost or diminished	11. Usually normal
12. Plantar response	12. Extensor	12. Flexor or no response	12. Flexor
13. Confirmation	13. Myelography, CT. MRI	13. Nerve conduction velocity (NCV)	13. Electromyography (EMG)

Features of root lesion (radiculopathy) :

(A) Anterior root — Muscle atrophy and weakness in root distribution; rare.

(B) Posterior root — Root pain, hyperalgesia and hyperaesthesia corresponding to the segments compressed. Different types of sensory abnormalities (e.g., hyperaesthesia) with an upper level which is usually a bit above the segmental level of the site of compression; commonly seen.

What are the differential diagnosis of your case ?

I. Aetiological differentiation :

a) Diabetes mellitus :

1. H/O polyphagia, polydipsia and polyuria.
2. H/O taking oral hypoglycaemic agents or insulin.
3. Retinopathy invariably present; there may be nephropathy.
4. Susceptibility to infections and delayed wound healing.

b) Leprosy :

1. Typical hypopigmented and anaesthetic skin lesion.
2. Palpable peripheral nerves.
3. Trophic changes.
4. 'Leonine' facies may be present.

c) G. B. Syndrome :

Read the section on 'Paraplegia'.

d) Drug-induced :

1. H/O prolonged intake of INH, NFT or vincristine.
2. Predominantly sensory neuropathy.
3. Presence of primary disease for which the drugs are taken, e.g., tuberculosis, leukaemia etc.

e) Arsenical polyneuropathy :

1. Early sensory symptoms; later on sensory-motor polyneuropathy.
2. Rain-drop skin lesions with hyperkeratosis of palm and sole.
3. People of known geographical area (different districts of West Bengal and Bangladesh) using deep tube-well water are predominantly affected.
4. Mee's line in nail (white transverse banding of nails).
5. Presence of anaemia with or without jaundice (due to hepatic involvement). There may be portal hypertension.
6. Estimation of arsenic in hairs, nails, urine confirms the diagnosis.

II. Similarities in clinical features :

a) Tabes dorsalis :

1. H/O exposure at least 10 years back.
2. Lightning pain; sensation of walking on cotton wool.
3. Muscle sense is lost (calf muscles and even testicles are insensitive on squeezing).
4. Loss of all modalities of posterior column sensations.
5. Tabetic facies; Argyll Robertson pupil and optic atrophy may be seen.
6. Romberg's sign is positive.

b) Subacute combined degeneration (SCD) :

1. Anaemia.
2. Glossitis.
3. Lhermitte's sign—Positive.
4. Ankle jerk — Lost.
5. Plantar response — Extensor.

* SCD is the demyelination of pyramidal tract and posterior column of the spinal cord as a result oi vitamin B_{12} deficiency. Distal paraesthesia, spastic weakness and difficulty in walking are common.

c) Myopathy :

1. History from childhood.
2. No sensory loss.
3. Predominantly proximal muscle weakness.
4. Pseudohypertrophy plus atrophy.
5. No bladder and bowel involvement.
6. Plantar response — Flexor.

What is TOCP neuropaty ?

Triorthocresylphosphate (TOCP) poisoning is also known as 'ginger paralysis'—owing to the consumption of fluid extract of ginger which was used in the manufacture of bootleg alcohol and was adulterated with TOCP. Symptoms of TOCP polyneuropathy usually develops 10-20 days after the consumption of adulterated food (cooking-oil) or drink, and produces bilateral wrist and foot drop with wasting of distal muscles of the limbs.

Causes of foot drop :

It is due to paralysis of the extensors of foot and peronei muscles. The common causes are,

1. Peripheral neuropathy (e.g., leprosy, diabetes mellitus).
2. Common peroneal nerve palsy (commonest cause of unilateral foot drop).
3. Prolapsed intervertebral disc (PID)—Due to lesion in L_5 root.
4. Motor neurone disease.
5. Sciatic nerve lesion.
6. Peroneal muscular atrophy.

* For 'wrist drop', read the section on 'Claw hand'.

Altered muscle sense :

Method : Muscles of calf or forearm are squeezed. Normally patient feels some discomfort.

(A) Diminished :

1. Tabes dorsalis.
2. Syringomyelia.
3. Carcinomatous neuropathy.

(B) Increased :

1. Polyneuropathy (Abadie's sign).
2. Myositis.
3. Subacute combined degeneration.

Investigations you like to perform in peripheral neuropathy ?

1. **Nerve conduction velocity** (lowered in neuropathy but not in myelopathy or myopathy).
2. Nerve biopsy (usually sural nerve is selected at the ankle; specially in inflammatory pathology).
3. Blood for R/E, sugar, urea, creatinine, VDRL, autoantibodies, serum folate and B , and thyroid and liver function tests. 12
4. EMG (to differentiate neuropathy from myopathy and diseases of myoneural junction).
5. CSF (done in G.B. syndrome).

* Electrodiagnosis in neurology is done by NCV and EMG. NCV shows features of demyelination or axonal injury; EMG reveals features of denervation.

CSF features in G.B. syndrome :

1. Pressure—Normal.
2. May be xanthochromic.
3. Clots formation on standing.
4. High protein, normal sugar, and
5. No rise in cell count (i.e., albumino-cytological dissociation).

How do you like to manage your patient ?

1. Complete abstinence from intake of alcohol.
2. Rest in bed.
3. Inj. vitamin B_{lt} B_6 and B_{12} — twice weekly, deep I.M.; inj. methylcobalamin may be tried. For paraesthesia—carbamazepine (300-1200 mg/day), aspirin (350-1200 mg/day) or amitriptyline (25-50 mg/day) may be given. For painful peripheral neuropathy pregabalin. tramadol, gabapentin may be helpful.
4. Physiotherapy and occupational rehabilitation in profound weakness.
5. Splinting of the foot (to manage foot drop); care of the foot-ulcer and bed sore.
6. Empirical treatment with steroid is usually disappointing.

Management of G.B. syndrome :

Treatment should be initiated as early as possible to get the maximum benefit.

1. Intravenous high-dose immunoglobulin therapy (0.4 g/kg/day for 5 days)—total dose 2 g/kg.
2. Plasmapheresis.
3. Physiotherapy.
4. Respiratory assistance in 'Respiratory Care Unit (RCU)' by intubation and positive pressure ventilation when the vital capacity falls below one litre. Good supportive care is given.
5. Corticosteroids or ACTH has shown no beneficial effects; it is better not to use them.

Case 19

PARKINSONISM

What is your diagnosis ?

This is a patient of idiopathic parkinsonism.

* James Parkinson, a physician from London, described the disease in 1817. Idiopathic perkinsonism is also known as 'shaking palsy'.

How your patient presented himself ?

This male patient aged 75 years presented himself with difficulty or paucity of movements (bradykinesia), tremor, and stiffness of limbs and joints (three cardinal symptoms of parkinsonism) for last 3 years. The difficulties started gradually and progressing slowly without any waxing and waning.

1. He is complaining of difficulty in initiation of movement*. To start with there is clumsiness of movement and now he is unable to perform day to day activities. He feels difficulty in getting up from sitting position, walking, doing finer activities like combing or fastening buttons and writing (the letters tend to be smaller at the end of a line — micrographia).
2. Tremor is persisting for last 3 years which is mainly present in hands and occurs mostly at rest (static tremor). Recently the patient has noticed tremor of the legs, jaw and tongue. He has also complained of increasing tremor with emotional stress and diminution temporarily by willed movement (and diminution also during sleep as told him by family members).
3. Rigidity made him stiff and is responsible for his flexed attitude or 'stooped posture'. He knows from his relatives that his voice has turned into slow (dull) and monotonous type. Recently, he is feeling weakness of upper and lower extremities.

He was absolutely normal before 3 years. There is neither any H/O headache, vomiting, convulsions, diplopia, nasal intonation, nasal regurgitation nor there is any bladder and bowel disturbances. He has no complain regarding the sensory system. About the higher function, he is a bit depressed though there is no intellectual deterioration.

* *There is delay in initiation, slowness in expression and paucity in execution in parkinsonism.*

****** Parkinsonism is known as akinesia-tremor-rigidity syndrome.

*** *Postural instability,* the most disabling feature, is usually present in advanced disease contributing to falls and resulting injuries.

**** Bradykinesia is common in parkinsonism, myxoedema and depression.

Importance of past, family, personal and treatment history :

(A) PAST HISTORY — H/O

a) Fever, convulsions, coma (indicates post-encephalitic variety; though there may be a long interval, usually parkinsonism develops during the subsequent 12 months).
b) Head injury (punch drunk syndrome).
c) Exposure to STD (neurosyphilis).
d) Jaundice (Wilson's disease).
c) High BP (multiple infarction in brain).
f) CO or Mn intoxication.
g> Headache, vomiting and convulsions — Brain tumour.

(B) FAMILY HISTORY — H/O hypertension, diabetes mellitus or similar type of illness within the family.

(C) PERSONAL HISTORY — Whether 'boxer' or not.

(D) TREATMENT HISTORY— Whether there is any H/O prolonged intake of phenothiazines, butyrophenones, reserpine etc.

Special points in the physical examination in parkinsonism :

(A) GENERAL SURVEY :

a) The patient is conscious and co-operative.
b) Masked facies characterised by,
   (i) Infrequent blinking with staring look (spontaneous ocular movements are lacking),
   (ii) Loss of facial expression (looks blank), and
   (iii) Widened palpebral fissure.

* There may be associated titubation of head.

c) Pulse — Write all the points. Condition of the arterial wall is normal (excludes atherosclerosis).

d) BP— 135/85 mm of Hg (excludes atherosclerotic variety).
e) Jaundice — Absent (for Wilson's disease).
f) Cornea — K-F ring is absent (for Wilson's disease).
g) Seborrhoea (greasy skin), sialorrhoea — Absent (excludes post-encephalitic variety).
h) Outstanding features — Coarse and static tremor of hands; jaw tremor. Rate of eye blinking is reduced to <10/minute.
i) Posture—flexed posture with impaired postural reflex.

* Mention all the points in general survey.

(B) NERVOUS SYSTEM :

a) Higher functions —
   (i) The patient is conscious, alert, oriented and co-operative.
   (ii) Normal intelligence and memory.
   (iii) A bit depressed.
b) Speech — Slow, Indistinct and monotonous speech without any fluctuation or modulations (bradylalia as well as hypophonia, and In advanced disease, speech is reduced to muttering).
c) Neck rigidity and Kernig's sign — Absent.
d) Cranium and spine — Within normal limit.
e) Cranial nerves — Normal; Jaw jerk — Normal; oculogyric crisis — Absent.
f) Motor functions —
   (i) Attitude — Flexed attitude in all the limbs with a stooped posture.
   (il) Nutrition — No wasting seen.
   (iii) Tone -— Increased in all the four limbs; flexor and extensor tone are equally Increased; **rigidity** is mainly of lead pipe (plastic) in type. In the hands (i.e., at wrist joint), they are of cogwheel in type (due to static tremor).
   (iv) Power—Grade IV in both upper and lower limbs.
   (v) Coordination —- Could not be tested properly.
   (vi) Involuntary movements — Tremor is present. It is,
      1. **Static tremor** and does not increase at goal-point of an action.
      2. Coarse In type (4-6/second).
      3. More prominent in hands; bilateral and symmetrical.
      4. The patient can control the tremor temporarily by voluntary movement.
      5. There is predominantly contraction of flexor and extensors alternately with a prominent rotatory component between finger and thumb (pill-rolling, bread-cutting or drum-beating tremor); often changing to supination and pronation of forearm.
      6. Tremor is increased by emotion and disappear during sleep.
      7. Tremor is mainly present in the distal part of upper limb; and is also present in the jaw and tongue.
g) Sensory functions —
   (i) Superficial
   (ii) Deep
   (iii) Cortical
   } NAD

* Mention the subheadings.

h) Reflexes —
   (i) Superficial —
      1. Abdominal
      2. Cremasteric
      3. Plantar response
      } iVithin normal limit
   (ii) Deep —
      1. Biceps jerk
      2. Triceps jerk
      3. Supinator jerk
      4. Knee jerk
      5. Ankle jerk
      6. Clonus—Absent
      } Within normal limit

(iii) Visceral —
1. Bladder
2. Bowel, and
3. Swallowing

} Within normal limit

(IVJ utner renexes —
1. **Glabellar tap — Present.**
2. Grasp reflex—Absent.
3. Palmo-mental reflex—Absent,

i) Trophic changes — Nil.
j) Cerebellar functions — Normal,
k) Autonomic functions — Within normal limit.

I) Gait **—** There is **'festinant' gait.** The features are **:**

(i) Stance—Patient bends forward (universal flexion)— known as 'simian attitude'.
(ii) Difficulty in initiation of movetnent; the patient may freeze suddenly i.e., glued to the floor.
(iii) Starts walking with rapid, short, shuffling steps as if the patient is trying to catch up his centre of gravity.
(iv) Paucity of automatic movements of both the upper limbs (i.e, swinging movement of arms).
(v) Steps become more and more rapid with a tendency to run (festination) and the patient may ultimately fall like a telegraphic pole.
(vi) There is presence of propulsion (tendency to fall forward), retropulsion (walking backwards uninhibited, if pulled backwards) and lateropulsion (walking sideways better).
(vii) Impaired balance on turning.
(viii) Difficult to stop suddenly if pushed or pulled.
(ix) Can run faster than walking during emergency (kinesia paradoxa).

(C) CVS — Within normal limit (search for the signs of atherosclerosis).

(Dj RESPIRATORY SYSTEM—Within normal limit.

(E) G.I. TRACT AND GENITOURINARY SYSTEM — Normal (search for hepatosplenomegaly due to Wilson's disease, specially in a young patient).

(F) LYMPHORKTICULAR SYSTEM — Normal.

* Mention the subheadings in all the systems.

** Write Plantar response as 'bilaterally flexor'.

Chief complaints of your patient :

1. Difficulty of movements for 3 years,
2. Tremor in hands for 3 years,
3. Stiffness (rigidity) of muscles for 3 years, and
4. Postural instability lor last 2 years.

Causes *of masked fades :*

See the section on 'Scleroderma'.

What is glabellar tap reflex (Myerson's sign) ?

In health, if a series of sharp finger tap (by index finger) is applied over the glabella (root of the nose), it evokes three or four blinks (bilateral closure of eyes) before the response is inhibited.

Precautions :

1. Tap should be light and done at a rate of 1 /second upto 5 taps at a time.
2. Tap should be applied on standing behind the patient and the tapping finger is kept above the visual field (so that menace reflex does not play).
3. Eyes should be kept open.

The afferent fibres are carried through Vth cranial nerve while the efferent fibres go through Vllth cranial nerve, and the centre for this reflex lies in pons.

Prolongation of glabellar tap (i.e., eyes continue blinking with each tap) response is seen in parkinsonism, diffuse cortical damage and senile dementia. This reflex tests the integrity of 'nigro-strial pathway'.

Differentiation between spasticity and rigidity :

Hypertonia is of two types : spasticity and rigidity.

(A) SPASTICITY :

1. Alaways in UMN lesion. Spasticity takes some time to develop.

2. Tone is of clasp-knife in type [hypertonia is felt maximally at the beginning of passive movement when the limb is fairly flexed or extended, and the resistance is decreased (gives away) if the movement is continued]—quick movement is better to elicit spasticity.
3. Hypertonia is marked in flexors of upper limbs and extensors of lower limbs, i.e, more in anti-gravity muscles.
4. Jerks or deep reflexes — Brisk; clonus may by present. Abdominal reflexes are lost.
5. Plantar response—Extensor.
6. Involuntary movements are not seen.

* Clasp-knife spasticity is the lengthening and shrotening reactions in muscles originally described by Sherrington.

(B) RIGIDITY:

1. Seen in extrapyramidal lesions.
2. Tone is of lead pipe or cogwheel in type—slow movement is better to elicit rigidity.
   a) Lead pipe — Uniform resistance present throughout the entire range of passive movement, and is mostly appreciated in legs and trunk; also known as plastic type rigidity.
   b) Cogwheel — Fluctuant resistance to passive movement due to presence of static tremor (as if a lever is rubbing on the teeth of a cogwheel); best observed in wrist joint and neck.
3. Hypertonia is marked in both the limbs equally, i.e, flexors and extensors of all the four limbs are equally affected.
4. Jerks of deep reflexes — Normal; clonus — Absent. Abdominal reflexes are preserved.
5. Plantar response — Flexor.
6. Very often associated with involuntary movements (e.g., tremor).

Aetiology of parkinsonism :

1. Idiopathic (Parkinson's disease or paralysis agitans)—may be due to environmental toxin.
2. Atherosclerotic (vascular).
3. Post-encephalitic (von Economo's disease)—becoming increasingly rare.
4. Punch drunk syndrome in boxers (traumatic or head injury).
5. Wilson's disease.
6. CO, CS_2, methyl-phenyl-tetrahydropyridine (MPTP; used for recreational purposes) and manganese dust intoxication.
7. Neurosyphilis.
8. Drug-induced (reversible parkinsonism) — Phenothiazines, butyrophenones, tetrabenazine, reserpine, metoclopramide.
9. Cerebral tumour (rare).
10. Huntington's disease.

N.B. : 1, 2 and 3 are the most common causes. According to few neurologists, vascular or atherosclerotic variety does not exist, and thus remains a topic of controversy.

Components of extrapyramidal system :

1. Caudate nucleus.
2. Putamen.
3. Globus pallidus.
4. Red nucleus.
5. Substantia nigra.
6. Subthalamic nucleus of Luys.
7. Dentate nucleus (of cerebellum).
8. Reticular formation (of brainstem).

Eye signs in parkinsonism :

1. Infrequent blinking; staring look.
2. Impaired pursuit movement of eyeball.
3. Reflex blepharospasm (Myerson's sign)
4. Oculogyric crisis (post-encephalitic).
5. Reversed Argyll Robertson pupil.
6. On closing the eyes, there is fluttering of eyelids (blepharoclonus).
7. Hypometric saccades.

Symptoms of extrapyramidal diseases ;

(A) HYPERKINESIA :

1. Tremor (static).
2. Chorea.
3. Athetosis.
4. Hemiballismus.
5. Myoclonus.
6. Dyskinesia.
7. Dystonia.

(B) HYPOKINESIA OR AKINESIA : Poverty and slowness of movement (e.g., parkinsonism).

(C) ATAXIA (POSTURAL DISORDER).

(D) RIGIDITY.

* Hyperkinesia, hypokinesia and akinesia are collectively known as ***'movement disorders'.***

What are the stages of parkinsonism ?

Stage I — Unilateral involvement ('hemiplegic' parkinsonism).

Stage II — Bilateral involvement but no postural abnormality.

Stage III — Bilateral involvement with mild postural abnormality.

Stage IV — Stage 3 plus severe postural abnormality requiring substantial help.

Stage V — Severe, fully developed disease; patient Is restricted to bed and wheel chair.

What is 'Parkinsonism-plus' syndrome ?

Classical parkinsonian features (akinesia-rigidity) are seen in combination with autonomic, cerebellar, oculomotor and cortical dysfunction in various neuro-degenerative diseases like,

1. Progressive supranuclear palsy (Steele-Richardson syndrome)—commonest.
2. Multisystem degeneration e.g., Shy-Drager syndrome, striatonigral degeneration, olivopontocerebellar atrophy.
3. Wilson's disease.
4. Huntington's chorea.
5. Normal-pressure hydrocephalus.
6. Alzheimer's disease. Pick's disease.

Table 15 : Differentiation between idiopathic and post encephalitic parkinsonism

Features	Idiopathic	Post-encephalitic
1. Age	1. Elderly or late middle-aged	1. Relatively younger
2. Onset	2. Insidious	2. Sudden
3. Past history	3. Nothing particular	3. Gives history of encephalitis
4. Presentation complaint	4. Mainly tremor	4. Rigidity with impaired higher function
5. Higher function	5. Normal	5. Often mentally dull
6. Cranial nerves	6. Normal	6. ***Oculogyric crisis*** (involuntary upward conjugate deviation of eyeballs)
7. Rigidity	7. Usually of cogwheel in type	7. Lead pipe in type (due to absence of tremor)
8. Tremor	8. Most prominent feature i.e., tremor > rigidity	8. Less prominent; rigidity is the main feature i.e., rigidity > tremor
9. Reflexes	9. Normal	9. Jerks are brisk and plantar response is extensor due to involvement of pyramidal tract
10. Autonomic features	10. None	10. Flushing of skin, seborrhoea, sialorrhoea (excessive salivation), behavioural disturbances, hiccoughs and orthostatic hypotension
11. L-dopa therapy	11. Good response	11. Poor response

* ***Oculogyric crisis*** may be seen in drug-induced dyskinesia, petit mal epilepsy and in post-encephalitic parkinsonism. The head may tilt back and body may take a posture of opisthotonus.

Features of atherosclerotic parkinsonism :

1. Age—Usually above 60 years.
2. Higher function —Loss of memory is very common (due to multiple infarction in brain).
3. Bradykinesia is the prominent feature. Tremor and rigidity are less pronounced.
4. Clinical evidences of atherosclerosis (see the section on 'Hemiplegia').
5. Bilateral UMN signs may be seen e.g.,
   (i) Jaw jerk—Present.
   (ii) Plantar response—Bilaterally extensor.

6. Course of the disease is more rapid in comparison to other types.
7. Little or no response to L-dopa therapy.

What are the differential diagnosis of your case ?

(A) Causes of tremor—Read the section on 'tremor'.
(B) Causes of hypertonia—Read the section on 'Paraplegia'.
(C) Causes of 'parkinsonism-plus' syndrome (described above).

What is the pathology in parkinsonism ?

Melanin is lost from the dopaminergic nerve cells in substantia nigra, and there is nerve cell loss with gliosis and formation of Lewy body (intracytoplasmic inclusion body). It is seen that the nigro-strial pathway utilise dopamine as a neurotransmitter and subsequently dopamine loss produces parkinsonism (nerve cell loss elsewhere in the basal ganglia is also responsible lor depletion of dopamine). It is a disease of extrapyramidal system (basal ganglia) due either to an increase in acetylcholine or decrease in dopamine.

Investigations you like to perform in a case of parkinsonism :

Diagnosis of parkinsonism is essentially made on clinical grounds though investigations may be required in exceptional situations.

(A) Blood—Serum copper, ceruloplasmin, VDRL, Kahn test.
(B) Urine—Urinary copper estimation (in 24 hours).
(C) Liver function tests (for detection of Wilson's disease).
(D) CT or MRI scan of brain is done in,
  (i) Patients < 50 years.
  (ii) Unilateral disease.
  (iii) Signs of UMN, cerebellar or autonomic involvement.
  (iv) Diagnosis in doubt.

* Patients < 50 years of age are screened for Wilson's disease.

Outline of treatment of parkinsonism :

(A) Stage I and II (mild)—Medication may be required. Only anticholinergic drugs and selegiline are used; amantadine may be tried.
(B) Stage II, III and IV (moderate and severe) —
  a) Levodopa, carbidopa, bromocriptine, pergolide, lisuride, pramipexole, ropinirole, cabergoline, different COMT inhibitors (tolcapone, entaeapone).
  b) Stereotactic surgery.
  c) Physiotherapy and speech therapy.

* Tremor and rigidity are best controlled by anticholinergic drugs. Akinesia and postural instability are improved by levodopa. Selegiline reduces the iree-radicai formation generated from the oxidation of catecholamines. COMT stands for catechol-o-methyl-transferase; COMT inhibitors (tolcapone, entaeapone) enhance the benefits of levodopa therapy and are useful in patients with response fluctuation to levodopa.

** OLher drugs used ; rasagiiine. rivastigmine, antioxidants (vitamin C and E).

Name some anticholinergic drugs used in parkinsonism :

1) Trihexyphenidyl 2) Benztropine 3) Orphenadrine 4) Biperiden 5) Benzhexol.

Indications of surgery in parkinsonism :

Stereotactic surgery is done in globus pallidus or ventrolateral thalamus. Indications of operation are (obviously with no response to drugs) :

1. Relatively young patient.
2. Good general health with sound mental health.
3. Unilateral tremor or rigidity (akinesia is less responsive to surgery).

* Neural transplant techniques like adrenal medullary transplant to striatum or glial cell-line neurotrophie releasing factor into cerebral ventricles or basal ganglia are tried; not of much value.

Side ***effects of drugs used in parkinsonism :***

I. Levodopa—Nausea, vomiting, dyskinesia, posturai hypotension, on-off phenomenon', hallucinations.
II. Anticholinergic drugs—Dry mouth, constipation, blurring of vision, glaucoma, retention of urine, involuntary movements and confusion (use anticholinergic drugs cautiously in aged).

III. Amantadine—Mental confusion, ankle oedema, livido reticularis, seizures, urinary retention.
IV. Selegiline (deprenyl)—Postural hypotension, involuntary movements, psychosis.

* Now-a-days carbidopa (levodopa with DOPA decarboxylase inhibitor in a ratio of 10 :1. DOPA decarboxylase inhibitor prevents destruction of levodopa in the blood stream) is preferred to levodopa. Propranolol is sometimes used to treat tremor.

What is on-off phenomenon ?

After 3-5 years of treatment with levodopa, a short period of dyskinesia may develop (e.g., athetosis of the neck). Akinesia and weakness may last for few minutes to hours and may alternate with dyskinesia. These symptoms are due to narrow therapeutic index of levodopa. The patients are benefited by lowering the dose of levodopa or giving levodopa with selegiline (selective MAO-B inhibitor).

------ O------

Section 5

GENITOURINARY SYSTEM

The cardinal symptoms of (genito-) urinary system are :

1. Swelling of the face, legs or whole body (i.e., anasarca)
2. Anuria
3. Oliguria
4. Polyuria
5. Haematuria (bloody urine)
6. Nocturia (all polyuric states, oedema-forming states, prostatism, salt-losing nephropathy, cystitis, vesico-ureteric reflux, and insomnia even without renal disease produce nocturia). In CCF and other oedema-forming states, there is increase in renal blood flow during recumbency.
7. Dysuria (pain or discomfort during micturition), strangury, burning micturition, frequency of micturition (passing urine more often than usual) and urgency (sudden urge or need to pass urine); hesitancy (delay in initiation) or precipitancy (sudden voiding of urine), post-micturition dribbling (e.g., benign hypertrophy of prostate—BHP), impaired flow or urine, or urethral discharge
8. Retention of urine
9. Incontinence of urine (stress, urge, true or overflow incontinence)—vide page 171
10. Enuresis (bed-wetting at night or during sleep)
11. Increased nocturnal frequency (BHP, diabetes mellitus, nocturia)
12. Fork urine (bifid) in stricture urethra; pneumaturia (bubbly urine) in vesico-enteric fistula (e.g., in Crohn's disease) or in gas producing organisms in the urinary tract in diabetes mellitus.
13. Passage of milkly urine—Chyluria; smoky urine (AGN); foul smell in urine (UTI)
14. Swelling of abdomen (ascites, renal lump)
15. Loin pain
16. Renal colic
17. Sexual problems like lack of libido, impotence, trouble with ejaculation; dyspareunia and menstrual problems in female. Any symptom related to sexually transmitted diseases (STD).
18. Any complaint regarding male or female genitalia
19. Fever (UTI, renal tuberculosis, pyelonephritis)
20. General symptoms—nausea/vomiting/hiccough (renal failure), appetite, weight loss/gain (i.e., oedema), sleep, fatigue, bowel etc.
21. Miscellaneous—pruritus, breathlessness, paraesthesia. restless legs are features in renal failure.

* BHP is manifested by nocturia, increased frequency, reduced size and force of urinary stream, straining to urinate and dribbling at the end.

** ***Dysuria*** is difficulty in passing urine which may be associated with pain or discomfort. ***Strangury*** is painful (severe) passing of urine drop by drop.

Scheme of Examination

This system may be written separately though few clinicians prefer the combined system of G.I. tract plus genitourinary system. While writing this system, proforma of G.I. system should be followed with special reference to :

(A) GENERAL SURVEY :

1. Pallor with yellow complexion (e.g., CRF).
2. Face—Puffiness of the face or moon face, present or not.
3. **Oedema**—Pitting or non-pitting, localised or generalised, parietal oedema present or not.
4. Nutrition—Cannot be assessed properly due to presence of anasarca (if present).
5. Pulse—Condition of the arterial wall may be thickened rarely in nephrotic syndrome (due to accelerated atherosclerosis). Sometimes, an arteriovenous fistula (Brescia-Cimino fistula; vascular access artificially made for haemodialysis) with a continuous thrill may be present in the anterior aspect of lower part of forearm.
6. BP measurement is a must in all patients.
7. Skin—Whether scabies with **pyoderir** a present (acute nephritis) or not.

(B) G.I. SYSTEM : In details **(tonsils** should bi examined in a patient with acute nephritis; **prostate** should be examined per rectally in suspected ol ructive uropathy).

(C) GENITOURINARY SYSTEM :

I. Inspection :

Genitalia—Penile swelling, vulval oedema, scrotal swelling, contact ulcer etc. Observe the skin for renal biopsy mark (benzene seal or leucoplast strap in the lion), nephrectomy scar (in the loin), renal transplant scar (in either of iliac fossa), and small scar or catheter in situ in the centre of lower abdomen for peritoneal dialysis.

*** Testis :**

Small—hypogonadism, absence—cryptorchidism, tenderness—orchitis, tumour teratoma, seminoma; also look for hydrocele and inguinal hernia.

**** Penis :**

Adult size is approximately 8-12 cm in length. In hypogonadism, the size is < 2.5 cm.

II. Palpation :

1. Examination of genitalia for **phimosis,** scrotal oedema, hydrocele, contact ulcer in genitalia, palpation of **testes** etc.
2. Parietal oedema.
3. Fluid thrill.
4. Detailed examination of kidneys (palpation) with special reference to bimanual palpation and ballottement to find out a **renal mass.**
5. **Renal angle—**Tender or not; fullness of renal angle in perinephric abscess.

III. Percussion :

1. Shifting dullness in abdomen.
2. Upper border of liver dullness (as hydrothorax may be present).
3. Band of colonic resonance over the renal mass.
4. Percussion of the urinary bladder.

IV. Auscultation :

1. Peristalsis.
2. Renal artery bruit (heard on either side of the midline in the mid-abdomen in renal artery stenosis).
3. Venous hum.

V. In detail examination of genitalia, hernial orifices, per rectal or per vaginal examination (if indicated).

(D) CVS:

1. Neck veins may not be properly visualised due to anasarca, or neck veins remain engorged due to fluid overload or pericardial tamponade.
2. Apex—Site (for LVH arising out of renal hypertension), murmur, gallop etc.
3. **Pericardial rub** (uraemia).
4. Pericardial effusion (percussion of the heart may be necessary).

* CCF due to renal diseases are common as a result of fluid overload and hypertension.

(E) RESPIRATORY SYSTEM :

1. Hyperpnoea due to metabolic acidosis in renal failure.
2. Parietal oedema in the chest wall (i.e, intercostal fullness).
3. Type of respiration-May be thoraco-abdominal due to the presence of ascites
4. Features of **hydrothorax.**
5. Features of lower respiratory tract infection.

(F) NERVOUS SYSTEM :

(G) •URINE EXAMINATION' (OPTIONAL, : For the presence of albumin and sugar

foresk,n ma, be respo“lb",or “”-""S TM l.'p5,rltu P,

*II** look for bi°Psy mark in loin (for kidney) in a patient with nephrotic syndrome.

n history taking, past history (diabetes, hypertension, anaemia, recurrent infection) family histnry

sv„?or,'s syndrome''and drug hist^

Case 20

ACUTE GLOMERULONEPHRITIS

What is your diagnosis ?

It is a case of acute glomerulonephritis probably poststreptococcal in aetiology.

Why do you say so ?

This is a case of acute glomerulonephritis (AGN) because :

1. This boy aged 12 years presented with swelling of his face, scanty micturition with haematuria (r smoky urine) for last four days. The disease was acute in onset and progressive in nature He was absolutely normal prior to four days. His mother first noticed the puffiness of her son's face (mainly periorbital) in the morning after getting up from the bed. He complained of oliguria and haematuria from the same day. There was no H/O respiratory distress convulsions nr anuria. He did not complain of any burning micturition or loin pain'(due to stretching of renal capsule). There was presence of low grade fever at the initial period with anorexia headache and malaise but H/O vomiting was absent. ’
2. Though he did not suffer from any sore throat (e.g., tonsillitis, pharyngitis) 1-3 weeks back he gave H/O generalised itching all over the body for last 3 weeks which was probably due to cables infection. There was neither any H/O viral hepatitis B, chickenpox, mumps measles infection in the recent past nor there was any past history suggesting collagen vascular disease drug hypersensitivity, type I diabetes or hypertension. disease,
3. On examination the face is pale and puffy **(nephritic facies).** The swelling is seen more in the eyelids (periorbital) causing narrowing of the palpebral fissure. There is presence of mild pitting, pedal oedema at present. Pyoderma (infected scabies) is seen in the classical distribution like webs of fingers, elbow, below the nipple, umbilicus and groin regions. Pulse shows tachv cardia and the BP is 150/90 mm of Hg (definitely hypertensive at the age of 12 years). Jugullr veins are engorged (due to hypervolaemia).
4. Neither scrotal oedema nor ascites is detected. Liver, spleen and kidneys are not palpable and the renal angles are non-tender. p p ’ la
5. Other systems are within normal limit.
6. Urine examination done at the bedside revealed presence of albumin but there is absence of

con-oboratlon° b'°°d “mP'e * US"a"y n°' be P^rtomed for

* Sometimes, a patient of AGN may present with anasarca. The 'latent period’ in case of pharyngeal infection is usually 1-3 weeks and in cutaneous infection (pyoderma from scabies, furunculosis or impetigo), it is averaging about 2-6 weeks. p

What is your case ?

Say the summary as mentioned above.

What is acute glomerulonephritis (AGN) or acute nephritic syndrome ?

It consists of sudden onset symptom complex like :

1. Periorbital puffiness.
2. Oliguria.
3. Haematuria.
4. Oedema and hypertension.
5. Proteinuria (non-nephrotic range).
6. RBC and RBC cast in urine.
7. Tendency of early renal failure (acute).

Possible pathogenesis of symptomatology in AGN :

1. Oedema (periorbital, legs or sacral)
   - Retention of salt and water, and
   - Hypoproteinaemia.
2. Hypertension—
   - Stimulation of renin-angiotensin-aldosterone axis, and
   - Hypervolaemia due to salt and water retention.
3. Haematuria (microscopic)—
   - Glomerular inflammation
4. Periorbital swelling or puffiness—
   - Collection of oedema fluid in loose periorbital tissue.
5. Oliguria—
   - Reduction in glomerular filtration rate (GFR).
6. Uraemia or renal failure—
   - Retention of urea, creatinine and other nitrogenous waste products.

Relevant 'past history' in acute nephritis :

1. Sore throat (streptococcal). \ poststreptococcal glomerulonephritis (PSGN)

3. fnfectionsh'ke—Hepltms^, mumps, measles, chickenpox, infectious mononucleosis, malaria, pneumococcal pneumonia, infective endocarditis, syphilis (secondary).
4. Collagen vascular diseases (SLE, vasculitis, Henoch-Schonlein purpura etc.)
5. Drug hypersensitivity, G.B. syndrome.
6. 'Shunt nephritis' (infection of ventriculo-atrial shunt done in hydrocephalus).
7. H/O diabetes and hypertension.
8. H/O prolonged steroid therapy (D/D of moon face) or urticaria (angioneurotic oedema as a D/D of moon face).

* Actually 1 to 6 are the different causes of AGN and poststreptococcal aetiology is the commonest among them.

Physical findings* in *other systems in acute nephritis :

(A) CVS:

(i) JVP may be raised; systemic hypertension.

(ii) Apex may shift down and out (due to LV dilatation), and forceful in nature.

(iii) **loud** A, (due to hypertension).

(iv) There may be presence of mitral systolic murmur (functional murmur due to LV dilatation).

(v) Gallop rhythm may be present (LVF).

(vi) Rarely, pericardial rub in acute renal failure.

(Li) RESPIRATORY SYSTEM :

(i) Bilateral basal crepitations (due to LVF).

(ii) Usually, there is absence of hydrothorax (to differentiate it from nephrotic syndrome).

(C) NERVOUS SYSTEM :

(i) Features of hypertensive encephalopathy.

(ii) Fundoscopy—Usually normal (not done).

(D) G.I. TRACT : Tonsils may be enlarged with tender cervical adenopathy due to acute streptococcal tonsillitis. Ascites may be vident.

(E) SKIN (in general survey) : Scabies with pyoderma.

* Never froget to examine the patient for phimosis.

Common features in adults with AGN :

1. There may not be any H/O preceding infection.
2. Oedema is not marked.
3. Hypertension may or may not be present.
4. Presence of oliguria, haematuria and proteinuria (as occurs in a child).

Pathogenesis and types of streptococci involved in AGN :

Poststreptococcal AGN is produced due to infection by group A beta-haemolytic streptococci (nephritogenic strains). *Remember, streptoccocal pharyngitis may produce AGN or acute rheumatic fever while streptococcal skin infection produces AGN only.*

M types of streptococci (nephritogenic strains), e.g., types 2, 47, 49, 55, 57 and 60 are seen following skin infections, and types 1, 2, 3, 4, 12, 25 and 49 after pharyngitis (throat infection).

Actually, AGN or acute nephritic syndrome is an immune complex glomerulonephritis where there is production of antibodies against glomerular antigen and thereby leads to deposition of immune complexes in the walls of glomerular capillaries, which ultimately develops into inflammation of the glomeruli.

Causes of acute glomerulonephritis :

I. Infectious diseases :
   - (A) Poststreptococcal glomerulonephritis.
   - (B) Non-poststreptococcal glomerulonephritis.
     - a) Bacterial—staphylococcal and pneumococcal infection, infective endocarditis, meningo-coccaemia, typhoid.
     - b) Viral—hepatitis B, mumps, measles, varicella, infectious mononucleosis, coxsackievirus.
     - c) Parasitic—malaria.

II. Systemic disorders :
   Vasculitis, SLE, Henoch-Schonlein purpura, Goodpasture's syndrome.

III. Primary glomerular disease : membranoproliferative glomerulonephritis, mesangial proliferative glom-erulonephritis, IgA nephropathy (Berger's disease).

IV. Miscellaneous : G.B. syndrome, serum sickness, DPT vaccination.

Causes of red urine in clinical practice :

1. Hematuria (presence of intact RBC under microscope).
2. Haemoglobinuria (in haemolytic disorders; urine gives chemical tests for haemoglobin but there is no RBC present in the centrifuged deposit of fresh sample of urine) and myoglobinuria (in rhabdomyolysis; very dark urine; no RBC on M/E)*.
3. Ingestion of beet root, senna and dyes used to colour sweets.
4. Phenolpthalein (used in purgatives) in alkaline medium (after use of systemic alkaliser) of urine.
5. Acute intermittent porphyria (presence of porphobilinogen may be detected by addition of Ehrlich's aldehyde reagent. Freshly voided urine appears normal but may take dark red colour on stand-ing for few hours).
6. Drugs—Phenazopyridine (pyridium), phenindione, clofazimine, rifampicin (it actually changes the urine to dark orange colour).
7. Alkaptonuria (becomes black, if kept for long time).

* If blood from these patients are kept in a test-tube for few minutes, the supernatent serum will be reddish in myoglobinuria while it will be clear in patients with haemoglobinuria.

Medical causes of haematuria :

1. Acute glomerulonephritis.
2. SBE (generally microscopic haematuria).
3. Malignant hypertension.
4. Snake bite.
5. Henoch-Schonlein purpura or other coagulation disorders.
6. Weil's disease.
7. Anticoagulant therapy.
8. Renal tuberculosis.
9. Papillary necrosis (diabetes, sickle cell disease, analgesic-induced).
10. SLE (microscopic haematuria).
11. Goodplasture's syndrome.

* ***Painless haematuria :*** AGN, SBE, IgA nephropathy, hypernephroma, coagulation disorder, renal tuberculosis, hypertension. ***Painful haematuria :*** urinary tract infection, renal calculus and trauma.

Definition of polyuria, oliguria and anuria :

1. **Polyuria**—Urine output persistently above 3 litres per day. The normal urine output for a healthy adult is approximately 1.5 litre (400 ml- 3 litre) per day. The common causes are :
   a) Chronic renal failure.
   b) Diabetes mellitus.
   c) Diabetes insipidus.
   d) Psychogenic polydipsia (compulsive water drinking).
   e) Use of diuretics in patients with oedema.
   f) Diuretic phase of ARF.
   g) Hypercalcaemic nephropathy.
   h) Hypokalaemic nephropathy.
   i) 'Post-obstructive uropathy'.
   j) Drugs—alcohol, caffeine.
   k) Transient polyuria (after epileptic seizure, paroxysmal atrial tachycardia)
2. **Oliguria**—Urine volume < 400 ml per day. Common causes are acute gastroenteritis, high fever, acute glomerulonephritis, congestive heart failure (decompensated), renal failure (acute and chronic), hypovolaemia and shock, 'third space' loss in acute peritonitis and pancreatitis.
3. **Anuria**—No urine formation for 12 hours (some nephrologists define anuria as < 50 ml urine output per day). Complete anuria, i.e., no urine formation by catheterisation occurs in bilateral ureteric obstruction, rapidly progressive glomerulonephritis, diffuse cortical necrosis and bilateral renal artery stenosis.

* Passing of more than one-third of the total daily output by night is **nocturia,** and diabetes mellitus and benign hypertrophy of prostate are two prime causes in clinical practice.

Why this is not a cose ***of nephrotic syndrome*** ?

As there is :

1. History of scabies with secondary infection.
2. 'Acute onset' of oliguria.
3. Absence of anasarca.
4. Presence of haematuria.
5. Presence of hypertension.
6. A classical history.
7. Microscopical examination of urine (if allowed to do) shows presence of mild to moderate proteinuria, RBC and RBC cast.

Differential diagnosis of your case :

1. Angioneurotic oedema—Itchy swelling of eyelids, lips and tongue; absence of pyrexia, hypertension, oliguria and haematuria. H/O atopy present.
2. Acute pyelonephritis—Fever with chill and rigor; H/O loin pain with tender renal angles. Oedema is absent and there is no hypertension. Increased frequency of micturition is often present.
3. Other causes of haematuria are to be differentiated.
4. Nephrotic syndrome—Already mentioned above.
5. Acute exacerbation of chronic nephritis—H/O previous attacks of nephritis, severe hypertension and renal functional impairment are present.

Investigations you like to do :

1. Urine examination—
   (i) Smoky urine.
   (ii) 300-600 ml In 24 hours.
   (iii) High specific gravity (due to increased tubular reabsorption).
   (iv) **Moderate albuminuria.**

(v) Presence of RBC, RBC cast, WBC, granular cast (present lately), epithelial cell and cast **(RBC cast is diagnostic of acute nephritis).**

(vi) Urine is sterile on culture.

2. Blood—
   (i) Anaemia (haemodilution).
   (ii) Leucocytosis.
   (iii) Raised ESR.
   (iv) Raised ASO titre in poststreptococcal AGN (more common with throat infection).
   (v) Hypocomplementaemia C_3 and C_4.
3. Blood biochemistry—
   (i) Urea and creatinine levels may be elevated (if progresses to acute renal failure).
   (ii) Normal cholesterol (differentiates nephrotic syndrome).
4. Chest X-ray—
   (i) Cardiac enlargement, or
   (ii) Features of pulmonary congestion (indicates hypervolaemia).
5. Renal function test—Diminished GFR.
6. Cultures of throat swab or swab from infected skin may grow group A beta-haemolytic streptococci.
7. Ultrasonography of kidneys shows normal or large kidneys.

*** Characteristic cast in AGN is RBC cast, in nephrotic syndrome it is fatty cast, granular cast in CRF, and WBC cast in chronic pyelonephritis.**

** Azotaemia' is the increase in the concentration of urea and creatinine in blood resulting from a fall in the glomerular filtration rate (GFR).

*** Renal biopsy is usually not done in acute glomerulonephritis.

Complications of acute nephritis :

1. Acute renal failure (ARF).
2. Hypertensive encephalopathy.
3. Acute left ventricular failure (LVF).
4. Infections—Urinary tract, respiratory tract etc.
5. Fluid and electrolyte imbalance, nephrotic syndrome, chronic glomerulonephritis.
6. Fluid overload.
7. Rapidly progressive glomerulonephritis (RPGN).

How to recognise the major complications of AGN ?

(A) ACUTE RENAL FAILURE :
   (i) Severe oliguria to anuria.
   (ii) Drowsiness, confusion, delirium and even coma may supervene.
   (iii) Hypertension.
   (iv) Acidotic breathing (deep sighing, rapid breathing at a regular rate and with a hissing sound is called Kussmaul's breathing).
   (v) Blood urea, creatinine and potassium levels are invariably high with acidosis.

(B) HYPERTENSIVE ENCEPHALOPATHY :
   (i) Features of increased intracranial tension, i.e., headache, vomiting, convulsions or coma.
   (ii) Hypertension.
   (iii) Confusion, delirium.
   (iv) Though rare, focal neurological signs like temporary blindness, aphasia, hemiparesis or extensor plantar response may be present.
   (v) Papilloedema with retinal exudates and haemorrhages may be evident.

(C) ACUTE LEFT VENTRICULAR FAILURE :
   (i) Acute respiratory distress, orthopnoea; H/O PND.
   (ii) Cough with copious, pinkish, frothy sputum.
   (iii) Central cyanosis.

(iv) Hypertension.

(v) Gallop rhythm, crepitations at lung bases and pulsus altemans.

* ***These 3 are the major complications of AGN.*** Prognosis of (A), (B) and (C) are very bad. All the complications should be treated promptly as soon as they are recognised.

What is RPGN ?

It is known as rapidly progressive glomerulonephritis (RPGN). This term is often applied to a group of acute nephritis patients who develop persistent renal failure in a period of weeks to months and show little tendency for spontaneous recovery. Usually the pathology is extensive extracapillary (crescentic) glomerulonephritis. Clinically there are presence of nausea, vomiting, weakness, persistent hypertension, haematuria, proteinuria and azotaemia. Common causes are systemic vasculitis, SLE, poststreptococcal AGN, Goodpasture's syndrome. The prognosis is poor. Steroids, cytotoxic agents or intensive plasma exchange may be useful. Fifty percent of patients may require dialysis within 6 months.

Common causes of acute renal failure (ARFj in your hospital :

1. Hypovolaemia due to acute gastroenteritis, severe haemorrhage, pancreatitis, peritonitis or extensive burns.
2. Acute glomerulonephritis.
3. Septicaemia, endotoxic shock.
4. Malignant hypertension.
5. Mismatched blood transfusion
6. Snake bite.
7. Septic abortion, eclampsia.
8. Acute myocardial infarction.
9. Hepato-renal syndrome.
10. Acute interstitial nephropathy.

Prognosis of acute nephritis :

1. Complete recovery—85% of children and 50% of adults (within 2 weeks).
2. Complications—5% cases produce complications mentioned above; few suffer from RPGN.
3. Apparent recovery—10% cases live with persistent proteinuria and haematuria for long periods.

* As a whole, the prognosis is excellent and the prognosis in children is better than adults.

How do you like to manage a case of AGN ?

1. Strict bed rest—Continued until the signs of glomerular inflammation and circulatory congestion subside (i.e., disappearance of oedema, oliguria, haematuria, hypertension, high blood urea, RBC cast in urine).
2. Diet—Mild protein restriction is done in azotaemic patients. When oliguria is moderate, 0.5 mg/kg/day of protein should be given. Mainly carbohydrate diet is preferred.
3. Salt and water balance—Salt-free foods are given. The fluid intake is restricted to previous days urine output plus 500 ml of fluid. Salt and fluid restriction are most important.
4. Diuretics—Tablet frusemide (40 mg/tab) 1 tab daily is given to relieve oedema and hypertension.
5. Antihypertensives—nifedipine, amlodipine, hydralazine and diazoxide may be of help.
6. Antibiotics—7 to 10 days course of crystalline penicillin (5 lakhs, I.M, BD) or erythromycin (250 mg QDS, orally) is given if streptococcal infection is documented.
7. Treatment of complications.
8. Dialysis may be required in severely azotaemic or fluid overloaded patients.
9. Steroid, cytotoxic drugs, long-term chemoprophylaxis like rheumatic fever are not needed.
10. Tonsillectomy may be done afterwards.

Conclusion :

1. Always measure the BP of the patient.
2. Examine for phimosis, scabies infection and swelling of tonsils.
3. Percuss the urinary bladder for retention of urine (to make D/D with oligo-anuria).
4. Search for gallop rhythm and pericardial rub.
5. Note the colour of the urine carefully (red, smoky or coca-cola urine)—send the patient to toilet with a test tube to collect urine.

N.B. : Acute glomerulonephritis in also known as acute nephritis. Type I nephritis, acute glomerulonephritis syndrome or acute nephritic syndrome.

Case 21

NEPHROTIC SYNDROME

What is your diagnosis ?

The diagnosis may be delivered in one of the two ways :

1. This is a patient of nephrotic syndrome probably due to minimal lesion nephropathy, or
2. This is a patient of anasarca probably due to nephrotic syndrome.

Why do you say so ?

This is because of :

1. This male child aged 14 years and 2 months presented with gradual swelling of the whole body for last one month. He was absolutely normal one month back. The disease was insidious in onest and gradually progressive. His father first noticed the puffiness of his son's face (mainly periorbital) one morning where the swelling gradually involved the whole body (descending oedema) in course of time. The swelling was a bit posture-dependent. Lately, swelling involved the abdomen and the scrotum; it was painless and pitting in nature according to the patient. The boy also complained of increasing weakness. The output and colour of urine were within normal limit, and there was no H/O haematuria, burning micturition, renal colic. He did not give any H/O respiratory distress.
2. There was no past H/O sore throat, skin infection, diabetes mellitus, drug intake or jaundice; no family H/O diabetes or hypertension was present, and no other family member was suffering from the same type of illness.
3. On examination, the face is puffy with baggy lower eyelids and It seems a 'moon face' (also there is waxy pallor in the face). There Is presence of generalised, massive, posture-dependent, descending pitting oedema. BP is within normal limit (110/80 mm of Hg). Scrotal oedema with contact ulcers, and parietal oedema are present. Huge swelling of penis is seen. There is mild anaemia.
4. Fluid thrill and shifting dullness are present, i.e.. there is presence of ascites. Liver, spleen, gall bladder and kidneys are not palpable. Renal angles are non-tender.
5. On examination of the other systems there is no pericardial rub, hydrothorax or pericardial effusion present.
5. Urine examination done at the bedside revealed presence of albumin but there is absence of sugar in the sample—may be performed for corroboration.

* Renal oedema : periorbital + genital + generalised oedema.

Causes of anasarca and moon face :

Read the sections on 'Oedema' and 'Moon face' respectively.

What is nephrotic Syndrome ?

It is a clinical syndrome characterised by :

a) Massive proteinuria (albuminuria).
b) Hypoalbuminaemia (hypoproteinaemia),
c) Generalised oedema or anasarca, and
d) Hyperlipidaemia (e.g., hypercholesterolaemia).

* Proteinuria > 3.5 g/ 1.73 m^2 per day is considered to be in the nephrotic range. Normal body surface for a reference man is 1.73 m^2. *Proteinuria is the hallmark of nephrotic syndrome.*

** Now-a-days, lipiduria and hypercoagulability are new additions in the clinical complex of nephrotic syndrome.

Importance of 'past history' in nephrotic syndrome :

(A) Relating to aetiology :

1. Jaundice (hepatitis B infection).
2. Sore throat (poststreptococcal).
3. Diabetes mellitus.
4. Diseases like leprosy, syphilis, malaria.
5. Drug Intake—Anti-snakevenom, penicillamine, troxidone, probenecid, organic gold.
6. Swelling in the neck (lymphoma).
7. Skin rash, arthralgia, arthritis, alopecia (collagen vascular disease).

(B) Relating to cause of anasarca :

1. Jaundice, alcoholism, H/O haematemesis or melaena (indicates cirrhosis of liver).
2. H/O respiratory distress or palpitation (cardiac disorder).
3. H/O chronic diarrhoea (malabsorption and malnutrition).
4. H/O tuberculosis (tuberculous pericardial effusion or constrictive pericarditis).
5. Hoarseness of voice and constipation (hypothyroid).
6. H/O long-standing corticosteroid therapy (D/D with moon face and swelling of body).

How nephrotic syndrome is classified ?

1. Primary glomerular diseases :
   a) Minimal lesion or minimal change disease. r
   b) Membranous glomerulonephritis.
   c) Focal and segmental glomerulosclerosis.
   d) Membranoproliferative glomerulonephritis (or mesangiocapillary glomerulonephritis).
   e) Mesangial proliferative glomerulonephritis.
2. Secondary to other diseases :
   a) Infections—Poststreptococcal, hepatitis B, malaria, lepromatous leprosy, secondary syphilis, infectious mononucleosis, infective endocarditis, HIV infection and AIDS.
   b) Drugs—Anti-snakevenom, penicillamine, troxidone, probenecid, bismuth, gold, mercury, captopril, a-interferon, street heroin, contrast media.
   c) Multisystem disease—SLE, Henoch-Schonlein purpura, vasculitis due to any cause, rheumatoid arthritis, Goodpasture's syndrome.
   d) Neoplasm—Lymphoma, leukaemia, carcinoma, melanoma.
   e) Heredo-familial—Diabetes mellitus, congenital nephrotic syndrome, Alport's syndrome, sickle cell disease, nail-patella syndrome.

   fj Miscellaneous—Pre-eclamptic toxaemia, amyloidosis, snake bite, bee-stings.

What is Kimmelstiel-Wilson (K-W) syndrome ?

1. It is a variety of nephrotic syndrome commonly arising from type I diabetes mellitus (30-40% in Type I and 3-10% in type II diabetes mellitus).
2. Histological lesion is nodular glomerulosclerosis.
3. Usually develops in a long standing diabetes mellitus (>10 years approximately).
4. Commonly starts with proteinuria.
5. The requirement of insulin becomes less with the development of K-W syndrome (as with development of nephropathy, insulin antibodies come out with urine).
6. Lately hypertension may be present.
7. End-stage renal disease can be expected to occur within 5-7 years.

* K-W lesion : Nodular glomerulosclerosis (K-W nodules, reasonably specific for diabetes mellitus).

K-W disease : Any manifestation of glomerulonephropathy in diabetes mellitus.

K-W syndrome : Nephrotic syndrome from diabetes mellitus.

Common causes of nephrotic syndrome in different age group :

(A) Children—

1. Minimal lesion (70%).
2. Mesangial proliferative (15%).
3. Focal glomerulosclerosis (10%).
4. Secondary—5%.
5. Membranous, membranoproliferative—Rare.

children, primary disease is 95% and secondary is 5%:

(B) Adults—

1. Membranous—35 %.
2. Secondary—30 %.
3. Minimal lesion—15%.
4. Focal glomerulosclerosis—10%.
5. Mesangial proliferative—5%.
6. Membranoproliferative—<5 %.

; In adults, primary disease is 70% and secondary is 30%.

Possible pathogenesis of different features in nephrotic syndrome :

- Proteinuria—Either due to change in pore size or J- in anion barrier in lining of foot process of the epithelium.
- Hypoalbuminaemia—Proteinuria plus renal catabolism of filtered albumin.

- Oedema and anasarca—Hypoalbuminaemia in oncotic pressure ->T in extracellular fluid volume. Moreover, there is ***I*** in intracellular fluid ->T renin-angiotensin-aldosterone axis ->T Na and water retention -> oedema and anasarca.
- Hyperlipidaemia and lipiduria—Hypoalbuminaemia ***->l*** oncotic pressure -> stimulate liver for lipoprotein synthesis ->T cholesterol, t LDL, T TG and T VLDL ^hyperlipidaemia may be responsible for accelerated atherosclerosis and progression of renal disease.
- Hypercoagulability— -I antithrombin III, protein C and S, ***i*** fibrinolysis, hyperfibrinogenaemia and t platelet aggregation ->T coagulability of blood with thromboembolic manifestations.

Differential diagnosis of nephrotic syndrome :

(A) Causes of anasarca :

1. CCF—Read the section on 'Oedema'.
2. Cirrhosis of liver—
   (i) H/O haematemesis and melaena may be present.
   (ii) Usually the face is not puffy.
   (iii) Ascites appears first; pedal oedema appears next.
   (iv) Splenomegaly and venous prominence in the abdomen with venous flow away from the umbilicus.
   (v) Signs of hepato-cellular failure may be present.
3. Anaemia with hypoproteinaemia— -
   (i) Pallor.
   (ii) Signs of malnutrition like glossitis, angular stomatitis, cheilosis, koilonychia may be present.
   (iii) Oedema appears first in ankles: ascites appears late.
   (iv) Systolic murmur may be present over the pulmonary area.
4. Constrictive pericarditis—Read the section on 'Examination of neck veins .
5. Pericardial effusion—Read the section on 'Pericardial rub'.
6. Myxoedema—
   (i) Absence of urinary problem.
   (ii) Hoarseness, constipation, cold sensitivity, lethargy, menorrhagia.
   (iii) Bradycardia, hypertension.
   (iv) Oedema is non-pitting in nature.
   (v) Delayed relaxation of ankle jerk.

(B) Causes of moon face : Read the sections on 'Moon face' and 'Acute glomerulonephritis'.

Common complications of nephrotic syndrome :

1. Protein catabolism—May lead to wasting, striae and osteoporosis.
2. Impaired resistance to infection like cellulitis, respiratory tract infection, peritonitis.
3. Thromboembolic manifestations (due to loss of antithrombin III in urine, hyperfibrinogenaemia, impaired fibrinolysis, reduced activity of protein C or protein S, hyperlipidaemia, and enhanced platelet aggregation)—Arterial thrombosis (pulmonary artery thrombosis specially), venous thrombosis (renal vein thrombosis specially).
4. Hypovolaemia may produce syncope, postural hypotension, renal failure.
5. Renal failure (chronic).
6. Accelerated atherosclerosis (may lead to 'strokes in young and early coronary artery disease).
7. Fluid retention, hydrothorax, pericardial effusion.
8. Consequences of loss of specific binding proteins (see below).

Renal vein thrombosis in nephrotic syndrome :

Previously it was thought to be a cause of nephrotic syndrome but now-a-days it is regarded as a consequence. The condition is treated by long-term oral anticoagulation. It is commonly found in :

1. Membranous nephropathy,
2. Membranoproliferative glomerulonephritis, and
3. Amyloidosis.

It is diagnosed by :

a) Unilateral or bilateral loin pain.
b) Haematuria.
c) Left-sided varicocele.
d) Widely fluctuating urine volume.
e) Asymmetry of renal size in ultrasonography.
f) Best documented by renal venous angiography.

Nephrotic syndrome with hypertension :

Usually hypertension is not a feature of nephrotic syndrome. If present, one should think of :

1. K-W syndrome (i.e., diabetic nephropathy).
2. SLE as an aetiology.
3. Polyarteritis nodosa as an aetiology.
4. The patient is on long-term corticosteroid therapy.
5. Nephritic-nephrotic syndrome'—nephrotic syndrome with atypical features of hypertension, microscopic or gross haematuria, early renal failure and low complement C_3. The common aetiologies are SLE and Henoch-Schonlein purpura.
6. The patient has developed early CRF.

* Focal glomerulosclerosis is commonly associated with hypertension,

i** Interstitial nephritis usually have normal blood pressure].

Physical signs in different systems in nephrotic syndrome :

1. G.I. **tract and renal system—**Skin of the abdomen is shiny, ascites, neither hepatosplenomegaly nor any renal lump felt, non-tender renal angle, scrotal (or vulval) oedema or presence of hydrocele; urinary bladder is generally empty. Phimosis should be looked for.
2. **Respiratory system** Respiration is thoraco-abdominal in type (due to presence of ascites), parietal oedema in the chest wall, bilateral hydrothorax, crepitations at lung bases may be audible. Sometimes, evidences of pneumonia is present.
3. **CVS—**The patient may be orthopnoeic. BP is usually normal. Neck veins may not be properly visualised due to oedema (usually JVP is not raised); presence of pericardial rub (in renal failure), rarely pericardial effusion; condition of the arterial wall (in peripheral pulse) may reveal thickening of arteries due to accelerated atherosclerosis (press the oedema fluid for few seconds for better palpation of peripheral pulse).
4. **Nervous system—**Nothing particular (patient may be lethargic or drowsy in the presence of renal failure).
5. **Reticulo-endothelial system**—Examine the patient for lymphadenopathy (as lymphoma, SLE and infectious mononucleosis may be the aetiology). Absence of sternal tenderness.

* Xanthelasma around the eyes may be occasionally seen because of hypercholesterolaemia.

In nephrotic syndrome, consequences of plasma proteins lost in urine :

1. Albumin (oedema, anasarca and increased susceptibility to infections).
2. Antithrombin III (causes increased coagulability and thromboembolic complications).
3. Thyroxine-binding globulin (produces abnormal thyroid function tests).
4. Cholecalciferol-binding protein (osteomalacia may be precipitated).
5. Transferrin (produces iron-resistant microcytic-hypochromic anaemia).
6. Metal binding proteins (may produce Zn and Cu-deficiency states).
7. Globulin (severe IgG deficiency may lead to bacterial peritonitis).
8. Drug-binding proteins (may result in altered drug pharmacokinetics).

How do you classify proteinuria ?

Normal adults may excrete upto 150 mg protein in 24 hours of which 15 mg is albumin and 25 mg is Tamm-Horsfall mucoprotein' produced by the renal tubules. Proteinuria (pathological) is classified into :

a) Mild—150-500 mg/day (+)
b) Moderate—500 mg-2g/day (++)
c) Massive >2g/day (+++); if crosses 3.5 g/day, it is designated as 'nephrotic range'.

* Proteinuria may be divided into selective (responsive to corticosteroid) and non-selective types.

** **Microalbuminuria** : It is defined as daily excretion of albumin of 20-200 microgram/min (i e 30-300 mg/day) and is commonly found in diabetes mellitus with early renal involvement.

*** Proteinuria often makes the urine frothy.

Characteristics of minimal change disease :

1. It is also known as lipoid nephrosis, nil lesion or foot process disease. No alterations are demonstrable by light microscopy (so, nil lesion) but electron microscopy shows diffuse epithelial foot process effacement.

2. It is the commonest cause of nephrotic syndrome in children (70%); male > female.
3. Highly selective proteinuria.
4. Progression to acute renal failure is rare and the prognosis is good as 10 years survival rate exceeds 90%.
5. Generally steroid or cytotoxic drug responsive.

Characteristics of membranous nephropathy :

1. It is the commonest form of nephrotic syndrome in adults (35%).
2. Commonly due to SLE, carcinoma of lung or penicillamine therapy.
3. Light microscopy shows thickening of glomerular basement membrane (GBM)—so called 'membranous'.
4. Non-selective proteinuria. Haematuria may be evident.
5. Renal vein thrombosis is common, as common is the progression to chronic renal failure.
6. Prognosis is bad.
7. Treated by steroid but the response is inconsistent.

Neuromuscular complications of chronic renal failure (azotaemia) :

1. Fatigue 2. Headache 3. Lethargy 4. Difficulty in concentration 5. Drowsiness 6. Muscular irritability 7. Flapping tremor (asterixis) 8. Hallucinations 9. Convulsions 10. Peripheral neuropathy 11. Myoclonus 12. Muscle cramps 13. Restless leg syndrome 14. Coma.

How do you like to investigate your case ?

(A) Urine examination—Urine volume is normal or low, **massive proteinuria** (24-hours urinary protein estimation is essential for diagnosis), normal specific gravity, shows hyaline and **fatty cast.**

(B) Blood examination—
   (i) Mild normocytic normochromic anaemia.
   (ii) Albumin level < 3 g/dl (normal level of albumin is 3.5 to 5.5 g/dl and that of globulin is 2 to 3.5 g/dl). Often the a_2 and P globulin are elevated inspite of low total globulin level.
   (iii) Urea and creatinine levels are usually normal but may be elevated in renal failure.
   (iv) Serum cholesterol is high and is usually > 300 mg/dl (normal desirable value <200 mg/dl).
   (v) Others—Blood sugar, ANF, HB_gAg, anti-HCV, complement C_3; selective protein clearance.

(C) Chest X-ray—May show evidence of hydrothorax or pneumonitis.

(D) Ultrasonography of kidneys reveal normal, small or enlarged kidney size. Kidneys in glomerulonephritis are small while diabetic and amyloid kidneys are large in size.

(E) Renal biopsy—For histological diagnosis, and also in assessing the treatment and prognosis.

How to diagnose that CRF has developed from nephrotic syndrome ?

1. Beginning of polyuria.
2. Diminution of anasarca.
3. Appearance of hypertension.
4. Development of anaemia.
5. Specific gravity of urine becomes low and fixed (1010).
6. Blood urea and creatinine levels increase.

Conditions associated with hypercholesterolaemia :

1. Pregnancy.
2. Diabetes mellitus (uncontrolled).
3. Myxoedema.
4. Nephrotic syndrome.
5. Obstructive jaundice.
6. Familial hypercholesterolaemia.
7. Prolonged intake of glucocorticoids, (3-blockers, thiazides and oral contraceptive pills.

Overall outcome of nephrotic syndrome :

The course may vary from complete recovery to death.

1. 30% recover completely.
2. 40% may die within a year or two after relapses and remissions (due to renal failure commonly).
3. 30% pass on to chronic renal failure.

* The long-term prognosis for minimal lesion nephropathy is excellent.

Common causes of CRF :

1. Chronic glomerulonephritis. nephrotic syndrome.
2. Malignant hypertension.
3. Diabetes mellitus.
4. Chronic pyelonephritis.
5. Polycystic kidney disease.
6. Collagen vascular diseases
7. Obstructive uropathy.
8. Interstitial nephritis.
9. Analgesic nephropathy.
10. Renal tuberculosis.
11. Gout, multiple myeloma.

How do you like to manage your patient (minimal lesion) ?

1. To maintain an intake-output chart; intake = previous days urine output+ 500 ml.
2. High protein intake is not advised. Increased intake of protein may cause hyperfiltration in the living nephrons which may end in glomerulosclerosis and renal failure. Now-a-days, modest protein restriction (e.g., 0.6 mg/kg of body weight/day) is advocated, particularly in an azotaemic patient. Dietary proteins should be of high biological value and can be supplemented by amino acids.
3. No added salt in diet, i.e., 100 meq of sodium/day is allowed and often it may be as low as 30-50 meq/day.
4. Diureties—Bendrofluazide 5-10 mg/day (in mild oedema), frusemide 80-120 mg/day or bumetanide (2-3 mg/day) or spironolactone (100-200 mg/day) in moderate oedema may be used singly or in combination (in severe oedema). The targeted weight loss should be <lkg/day as aggressive diuretic therapy may lead to ARF as a result of contraction in intravascular volume.
5. I.V salt-free albumin is given to increase the plasma oncotic pressure—20 g in 100 ml is used in 1 hour. It is costly and in hospitals, 'plasma' or blood transfusion is used for this purpose.
6. Corticosteroids and cytotoxic drugs—prednisolone 60 mg/m^2 in children and 1-1.5 mg/kg of body weight in adults is used daily for 4 weeks or until proteinuria disappears. After the urine is totally protein-free, the dose of prednisolone is gradually tapered to zero over next 4 weeks. But for those who show no response to initial 4 weeks' therapy, alternate-day prednisolone (35-40 mg/m^2 in children. 1 mg/kg in adults) for 4 additional weeks is advocated. Majority responds by the initial 4 weeks' treatment. Absence of response within 8 weeks is usually indicative of error in diagnosis and should be reviewed by a renal biopsy. Those who show relapse (within first year mainly), may be continued with low dose prednisolone i.e., 5-10 mg daily or on alternate days for 3-6 months. Those who have frequent relapses or show side-effects with prednisolone, may be given a brief course of cyclophosphamide (2-3 mg/kg daily) or chlorambucil (01- 0-2 mg/kg daily) daily for 2-3 months to induce subsequent remissions.
7. 'Statins' for the treatment of hypercholesterolaemia (e.g., atorvastatin 10 mg daily at bed time).
8. General measures—Multivitamins, antibiotics for secondary infection (as a result of hypogammaglobulinaemia), paracentesis of hydrothorax or ascitic fluid, metoclopramide for nausea and vomiting, packed red cells transfusion for aneamia, long-term oral anticoagulation in renal vein thrombosis, vitamin D supplementation in biochemical deficiency.
9. Emotional and psychological support to the child and his parents.

[10. In other histological varieties—Steroids, cytotoxic drugs, anticoagulants and antiplatelet drugs are tried. Dialysis is advised if the patient goes into renal failure.]

Decoding of few terminologies in minimal lesion nephropathy :

1. Steroid resistant—Poor response with full dose of corticosteroid for 8 weeks.
2. Steroid dependent—When symptoms appear after withdrawal of steroid.
3. Steroid toxic—When side-effects of corticosteroid appear (like moon face, hypertension, peptic ulcur, stunted growth, behavioural changes etc). This is the commonly encountered complication while treating rephrotic syndrome.
4. Steroid responsive—Urine is free of protein within 3-4 weeks.

Conclusion :

1. Always measure the BP of the patient.
2. Take the H/O diabetes and hypertension routinely (past and family history).
3. Never forget to see the scrotal or vulval oedema, hydrocele, contact ulcers and phimosis. Examination of sacral oedema is mandatory.
4. Always percuss the urinary bladder for retention of urine (to make D/D with oligo-anuria).
5. Palpate the abdomen by 'dipping method' in the presence of ascites.
6. Examine for presence of hydrothorax (often bilateral).
7. Accurate drug history should be taken in all renal patients.

-------- O--------

Section 6

LOCOMOTOR SYSTEM (OPTIONAL)

The locomotor system (or musculoskeletal system) comprises of muscles, bones, joints and soft tissue structures (e.g., ligaments and tendons).

Cardinal points in the history :

1. Onset, duration; pain and swelling of joint (arthritis) or only pain (arthralgia); axial or appendicular skeleton involved; big joints or small joints; mono-, pauci- or polyarticular; fleeting, additive or intermittent; morning stiffness, any pain during walk up and down the stairs, any associated H/O fatigue, weight loss, conjunctivitis, iritis, skin rash, skin nodule, mouth or penile ulcer, lymphadenopathy, alopecia, dry mouth, previous miscarriage.
2. H/O trauma, tuberculosis, bacillary dysentery, bleeding diathesis, enteric fever, sore throat, sexual exposure (STD-induced arthritis or reactive arthritis), fever, urethritis.
3. Family H/O tuberculosis, ankylosing spondylitis, haemophilia or gout; occupational history

Scheme of Examination

(A) Inspection :

a) Mono-, pauci- or polyarticular — Joint/joints involved; 'attitude' of the limb.
b) Swelling.
c) Deformity (fixed or reducible; varus, valgus, ulnar, radial, flexion).
d) Signs of Inflammation over the involved joint (e.g., erythema).
e) Wasting of muscles.
f) Skin changes.

(B) Palpation :

a) Temperature of the local part (T warmth in inflammation, e.g., synovitis).
b) Tenderness (in joint line or periarticular).
c) Corroboration of the findings of inspection.
d) Any swelling — Fluctuant or non-fluctuant; boggy feeling of thickened synovium.
e) Muscle power e.g., grip strength.

(C) Movements (passive as well as active) :

a) Restricted movement, instability or excessive mobility.
b) Any pain on movement.
c) Crepitus or grating sensation on movement.
d) Any associated muscular spasm.

(D) Measurements ;

a) Length and circumference of the limb.
b) Measurement in relation to various body points.
c) Thoracic ankylosis by chest expansion measurement and lumbar ankylosis by Schober's test.
d) To measure joint movement with the help of goniometer.

(E) Examination of the spine for tenderness, mobility, kyphoscoliosis, lordosis, gibbus.

(F) Gait.

(G) Systemic examination—To search for evidences of pleurisy, pericarditis, vasculitis, hepatosplenomegaly, iritis, aortic incompetence or lymphadenopathy.

* Schober's test : It is performed to make out flexion movement of lumbar spine. The patient stands erect. Give two skin marks at the back, one 10 cm above and the other 5 cm below the lumbosacral junction (marked by a horizontal line joining the postero-superior iliac spines). On full forward flexion, these marks distract > 5 cm but no distraction of skin marks is seen in ankylosed spine.

** Read gout, different arthritis like rheumatic, rheumatoid, septic and osteoarthritis from standard text book. Vide the sections on 'Aortic stenosis', 'Examination of the hands' and 'Charcot joint' too.

Case 22

POLYARTHRITIS

Clinical pressentation :

A young female presents with H/O long-duration of joint pain, disability and deiormity. She has bilaterally symmetrical involvement of small as well as large joints with active synovitis in few joints along with deformity of hands and feet. It is an additive arthritis of peripheral joints where the axial joints are not affected.

The most probable provisional diagnosis is rheumatoid arthritis.

How to approach in a patient of musculoskeletal (MSK) disorder?

Pain is the commonest manifestation and a near universal feature of MSK disorders. Since a wide variety of conditions give rise to MSK complains (i.e., arthralgia, myalgia, or bone pain), a systemic approach is necessary to make a provisional diagnosis. A careful history, meticulous clinical examination and judicious use of laboratory investigations help to arrive at a definitive diagnosis. The approach should be:

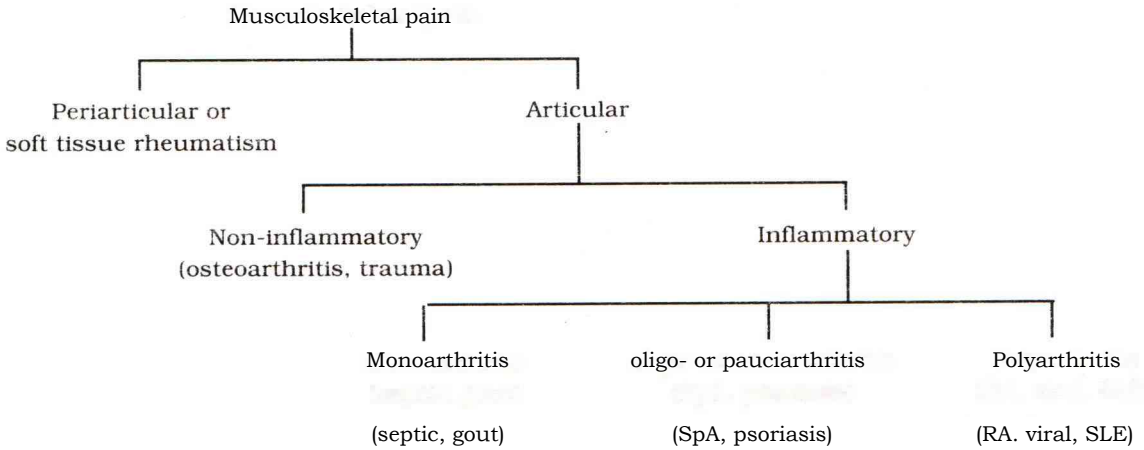

* RA - rheumatoid arthritis, SpA - spondyloarthropathy, ReA - reactive arthritis, SLE - systemic lupus erythematosus, CRP - C-reactive protein, ANA - antinuciear antibodies, RF - rheumatoid factor, MCP - metacarpophalangeal, MTP - metatarsophalangeal, PIP - proximal interphalangeal, DIP - distal interphalangeal, DMARDs - disease-modifying anti-rheumatic drugs, NSAIDs - non-steroidal anti-inflammatory drugs

Characteristics of inflammatory joint disorders :

Inflammatory joint disorders (RA, SpA, ReA) will have:

1. Significant early morning stiffness > 30 minutes.
2. Pain aggravation on resting the joints.
3. Symptomatic improvement on gentle use of joints.
4. Spontaneous flares (up-and-down course) are common.
5. Constitutional symptoms - fatigue, loss of appetite, weight loss, low-grade fever, night sweats are very often present.
6. Increased acute phase reactants e.g., high ESR and CRP.

* In non-inflammatory disorders, from 1 to 6, respectively they are <30 minutes, pain on moving the joints, no improvement, uncommon, absent, and normal.

What is soft tissue rheumatism (STR) ?

'Soft Tissue Rheumatism' is a term restricted to inflammatory or painful conditions which are, in general, non-articular in origin, and refers to aches or pains arising from structures surrounding the joint such as muscles, tendons, ligaments and bursae. This group accounts for the major chunk of musculo-skeletal disorders in any general outpatient clinic.

The anatomical basis of pain in MSK system could be due to:

Joint:

- Synovium - synovitis
- Joint capsule - capsulitis

Periarticular soft tissue:

- Bursa - bursitis
- Tendon - tendonitis
- Tendon sheath - tenosynovitis
- Insertion of tendon, ligament - enthesltis

Bone:

- Osteoporosis, osteomalacia, multiple myeloma, osteonecrosis

Differentiation of articular from non-articular/periarticular disorders ?

A careful clinical examination should be performed to differentiate soft tissue rheumatism from articular disorders. Bedside examination should follow:

1. Inspection: 'local' swelling around a joint (periarticular) favours STR rather than articular disorders whereas the joint (articular) swelling looks globular or fusiform surrounding a joint.
2. Palpation: In STR, tenderness is localised and usually away from joint-line margin. Articular disorders are conspicuous by the presence of joint-line tenderness, crepitus over the joint and/ or joint effusion.
3. Movements: Active (the patient moves the joint) and passive (the physician moves the joint while the patient relaxes the limb) movements are equally impaired in articular disorders. In STR, pain is aggravated on active than on passive movement, and limitation of motion is always greater in active movement rather than passive one.

Common types of soft tissue rheumatism :

Shoulder: frozen shoulder, rotator cuff syndrome, bicipital tendonitis

Elbow (epicondylitis): tennis elbow, golfer's elbow

Bursitis: pre- and infrapatellar bursitis, olecranon bursitis, trochanteric bursitis

Tenosynovitis: De Quervains' tenosynovitis

Entrapment syndromes: carpal tunnel syndrome (median nerve), tarsal tunnel syndrome (posterior tibial nerve), meralgia paraesthetica (lateral femoral cutaneous nerve)

Pattern recognition in MSK disorders :

Pattern recognition in MSK disorders or rheumatological diseases is of immense importance to have a clean-cut diagnosis. Often features of two or more MSK disorders are present in a single patient to build up a diagnosis of 'overlap syndrome'. If the pattern of involvement is not recognized clinically, it is very difficult to clinch a diagnosis of rheumatological diseases only by ordering of RF, ANA, autoantibodies or other immunological markers.

1. Mode of onset: acute or insidious.
2. Duration of joint pain: acute (<6 weeks) or chronic (>6 weeks).
3. Number of joints affected: monoarthritis, oligo- or pauciarthritis, polyarthritis.
4. Pattern of involvement: axial (spine, sacroiliac, anterior chest wall, and shoulder and hip joint) or appendicular (peripheral joints). Shoulder and hip joints are known as root joints.
5. Distribution of joint involvement: symmetrical or asymmetrical, small or large joint, lower limbs or upper limbs, involvement of any specific joint (e.g., 1st metatarsophalangeal joint in gout, haemarthrosis of knee joint in haemophilia, DIP joints of hands in osteoarthritis).
6. Order or sequence of affection: intermittent (gout) or progressive (classical RA), migratory (rheumatic arthritis. SLE, serum sickness) or additive (RA, ReA).
7. Extra-articular manifestations: constitutional symptoms (e.g., fever), skin rash, subcutaneous nodule, oral ulcer, conjunctivitis or episcleritis, penile ulcer, nail changes (e.g., psoriasis), Raynaud's phenomenon (e.g., scleroderma).

Possible causes of polyarthritis, oligoarthritis and monoarthritis :

(A) Polyarthritis - RA, viral arthritis (Parvoviris B19, hepatitis B, HIV, chikungunya), SLE, psoriasis, juvenile idiopathic arthritis (JIA), ReA, ankylosing spondylitis, systemic sclerosis, adult-onset Still's disease, generalized osteoarthritis, rheumatic arthritis, chronic gout, sarcoidosis (chronic), hypertrophic osteoarthropathy.

(B) Oligo- or pauciarthritis - JIA, gout, SpA, psoriatic arthropathy, oligoarticular presentation of polyarthritis.

(C) Monoarthritis - septic arthritis (S. aureus, N. gonorrhoea), crystal arthropathy (gout and pseudogout), tuberculous arthritis, osteoarthritis, SpA, traumatic, haemarthrosis (e.g., trauma, haemophilia), monoarticular flare of polyarticular disease, Charcot joint.

* **Few terminology** : Arthralgia - joint pain without obvious inflammation (i.e., only pain, no swelling), arthritis - pain and swelling in the joints, i.e., demonstrable features of inflammation; monoarthritis - affection of single joint, oligo- or pauciarthritis - affection of 2-4 joints, polyarthritis - involvement of 5 or more joints, synovitis - clinically apparent inflammation of synovium, enthesopathy / enthesitis - inflammation of an enthesis (i.e., the site of ligament, tendon, or articular capsule insertion into periosteum and bone), GALS screen - it is a quick reliable screen of gait, arms, legs and spine (GALS) of the locomotor system

Small and large joint involvement in MSK diseases :

(A) Small joint arthropathy: RA, SLE, ReA, gout, nodular osteoarthritis, psoriasis, enteropathic arthritis (i.e., associated with inflammatory bowel disease or IBD, i.e., ulcerative colitis and Crohn's disease), sarcoidosis.

(B) Large joint arthropathy: RA, ReA, ankylosing spodylitis. rheumatic arthritis, generalized osteoarthritis, psoriatic and enteropathic arthritis.

(C) Both large and small joints arthropathy: RA, SpA, osteoarthritis.

Symmetrical versus asymmetrical involvement :

Symmetrical involvement refers to affection of same joints on both the sides though it may not be mirror-image symmetry. For example, involvement of left-sided 2nd and 3rd, and right-sided 4th MCP joints of hands in RA is deemed symmetrical involvement of MCP joints.

(A) Symmetrical - RA, SLE, PSS, nodular osteoarthritis of hands, JIA and haemochromatosis

(B) Asymmetrical - gout, SpA, metabolic arthropathy (acromegaly)

* Psoriasis may be symmetric or asymmetric at presentation.

Arthritis in relation to age and sex of the patient :

(A) Age:

a) Children: JIA, haemophilia, trauma

b) Adolescents: RA, SpA. JIA, trauma, poststreptococcal reactive arthritis

c) Young: Trauma, gonococcal

d) Adults: SpA. ReA, SLE, psoriasis, gout

e) Middle age: RA, gout, osteoarthritis, scleroderma

(B) Sex: Majority of arthritides are dominant in females except gout, ankylosing spondylitis, ReA (Reiter's syndrome) and polyarteritis nodosa which are common in males

Define rheumatoid arthritis and criteria for its diagnosis :

Rheumatoid arthritis is an autoimmune disorder of unknown aetiology characterized by chronic symmetrical polyarthritis, joint erosions and destruction. It is the commonest inflammatory joint disease seen in clinical practice, and in its world-wide distribution it affects 0.5-3% of the population. The course is extremely variable and sometimes associated with extra-articular features. RA is notorious for development of joint deformities, specially the small joints of hands and feet. The age of onset is commonly in between 30-50 years, and in gender predilection F:M = 3:1 before menopause while F:M =1:1 post-menopause. RA is diagnosed by **ACR criteria** (American College of Rheumatology, 1987 revision), which are as follows:

- Morning stiffness > 1 hour
- Arthritis of 3 or more joints
- Arthritis of hand joints
- Symmetrical arthritis
- Rheumatoid nodules
- Rheumatoid factor
- Radiological changes (erosions and/or periarticular osteopenia)
- Duration of 6 weeks or more

* Presence of 4 or more criteria is necessary for diagnosis of RA

How a patient of rheumatoid arthritis presents ?

To diagnose a case as RA, one has to wait for 6 weeks (ref: ACR criteria). It starts with:

1. Aches and pains in the joints.
2. Insidious onset of polyarthritis.

3. Prolonged early morning stiffness.
4. Bilaterally symmetrical involvement.
5. Small joints of hands and (feet) are always involved in addition to large joint involvement. In small joints of hand (and feet), MCP (MTP) and PIP joints are commonly involved; DIP joints are virtually spared in RA. Large joints commonly involved are wrists, elbows, shoulders, knees and ankles.
6. Signs of inflammation may be seen in joints in the early part of the disease e.g., swelling (synovitis), erythema, warmth, and pain and tenderness.
7. As the disease progresses, deformity of hand and foot joints may develop in the absence of treatment.
8. The patient may suffer from different **extra-articular manifestations** along with joint involvement. They may be systemic (fever, weight loss, fatigue), musculoskeletal (tenosynovitis, bursitis, wasting of muscles), dermatological (nodules, pyoderma gangrenosum, leg ulcer, vasculitis), pulmonary (pleural effusion, bronchiolitis, fibrosing alveolitis, pulmonary nodules, Caplan's syndrome), cardiac (pericarditis, myocarditis, endocarditis, aortic regurgitation, conduction defects), ophthalmic (episcleritis, scleritis, keratoconjunctivitis sicca, scleromalacia), neurological (mononeuritis multiplex, cervical cord compression, entrapment neuropathy, peripheral neuropathy), lymphoreticular (anaemia, eosinophilia, thrombocytosis, Felty's syndrome, splenomegaly), and miscellaneous (amyloidosis, dry mouth, lymphadenopathy) involvement.

'A must' to remember in diagnosing rheumatoid arthritis :

A clinician should always remember that RA is:

- Entirely a clinical diagnosis.
- Typically bilaterally symmetrical.
- Classically presents as polyarthritis (may present as oligoarthritis).
- Don't diagnose if hands are not involved.
- DIP joint involvement is extremely rare.
- Lumbar spine is not involved in RA; cervical spine affection is very rare
- Presence of mucocutaneous rash, high pyrexia and active urinary sediments are against the diagnosis.

What is 'early' rheumatoid arthritis and what is its importance ?

It is the early disease having duration of persistent synovitis of around 3 months to 2 years. Different studies show that 10-26% patients of RA have radiographic bone erosion at 3 months, while 60% have it at 1 year, and 75% within 2 years. Unfortunately, bony erosions and deformities are largely irreversible. Hence, early disease represents a potential 'window of opportunity' for therapeutic interventions with DMARD, which has shown beneficial short and long term effects. So, present day goal is to diagnose RA as early as possible i.e., 'catch them young'. Early RA is diagnosed by RF, antibodies to cyclic citrulinated peptide (anti-CCP), high resolution ultrasonography (USG) with power and colour Doppler, and MRI scan of joints.

Describe different hand deformities in rheumatoid arthritis :

Read the section on 'Examination of hands'.

What are 'seronegative spondyloarthropathy' (SpA) ?

These are group of inflammatory joint diseases which are characterized by inflammatory low back pain in addition to peripheral arthritis. They suffer from asymmetrical oligoarthrits (lower limb affected more than upper limb), sacroiliitis and inflammatory spondylitis. There may have a positive family history and an **association with** HLA-B27 allele. The rheumatoid factor is always negative (seronegative). SpA encompasses 5 disorders like,

1. Ankylosing spondylitis (prototype of SpA),
2. Rreactive arthritis (including Reiter's syndrome),
3. Psoriatic arthropathy,
4. Arthritis associated with inflammatory bowel disease (enteropathic arthritis), and
5. Undifferentiated SpA.

* The sixth group (according to some rheumatologists) is juvenile-onset SpA

Differentiate arthritis according to serology :

(B) Seropositive (RF positive) - Sjogren's syndrome, RA, SLE, polymyositis-dermatomyositis, systemic sclerosis, sarcoidosis, vasculitis (polyarteritis nodosa). The higher the titre of RF, the more severe is the disease.

(C) Seronegative (RF negative) - SpA (the whole group), gout, osteoarthritis, juvenile idiopathic arthritis (JIA; majority are RF negative), RA (30%), rheumatic arthritis, Still's disease:

* RF is also positive in certain non-rheumatic diseases like fibrosing alveolitis, leprosy, tuberculosis, infectious mononucleosis, syphilis, kala-azar, chronic hepatitis, infective endocarditis, cryoglobulinaemia, malignancy, and in normal population (5% women aged above 60 years).

Polyarthritis affecting hands — pattern of involvement :

1. Rheumatoid arthritis - MCP, PIP but spares DIP.
2. Osteoarthritis - DIP but spares MCP; affects 1st carpometacarpal joint (base of thumb).
3. Psoriatic arthropathy - commonly DIP.
4. Chronic gout - MCP, interphalangial joints.
5. SLE - MCP joints commonly (Jaccoud's arthritis).

- DIP joints in hands are affected in osteoarthritis (Heberden's node), psoriasis, scleroderma, sarcoidosis, gout and adult-onset Still's disease.
- PIP joints in hands are affected in RA, SLE, scleroderma and osteoarthritis (Bouchard's node).
- MCP joints are commonly involved in RA, SLE, scleroderma and haemochromatosis.

Arthritis with nodule formation :

Rheumatoid arthritis (commonest), rheumatic fever and gout (tophi)

* Sarcoidosis (granuloma) and xanthoma (from hyperlipidaemia) may also have nodules.

What are Reiter's syndrome, Felty's syndrome. Still's disease and Caplan's syndrome ?

Reiter's syndrome — In the year 1916, Hans Reiter, the physician leader of the Nazi party in Germany during World War II, first described this syndrome. At present, the older term Reiter's syndrome is being used less frequently, and has been replaced by 'reactive arthritis . The *classical triad* ***of*** *urethritis, conjunctivitis and arthritis* following a gastrointestinal (mainly Salmonella, Shigella, Campylobacter, Yersinia-induced) or genitourinary infection (non-gonococcal urethritis or sexually acquired infection with Chlamydia), previously referred to as Reiter's syndrome, is now considered part of the spectrum of reactive arthritis. The extra-articular manifestations are circinate balanitis (painless superficial ulceration of glans penis), keratoderma blenorrhagica (painless, red, raised pustules and plaques in sole of feet and palmar surface of hands), nail dystrophy (onycholysis and hyperkeratosis) and buccal erosions.

Felty's syndrome - It is a variety of long-standing rheumatoid arthritis which is common in females in the age group of 50-70 years, and is associated with splenomegaly, lymphadenopathy, neutropenia, and occasionally anaemia and thrombocytopenia. The patients remain strongly seropositive.

Still's disease - This is the seronegative variant of RA in children and rarely in young adults. The presenting features are high rise of swinging pyrexia associated with evanescent maculopapular rash, arthralgia and arthritis, myalgia and generalized lymphadenopathy. Hepatosplenomegaly and pleurisy / pericarditis are also evident. Anaemia, neutrophilia, thrombocytosis with high ESR and CRP are common. Serum ferritin may be enormously elevated in adult onset Still's disease.

Caplan's syndrome - This is the coexistence of seropositive rheumatoid arthritis and pneumoconiosis of the lung (shows rounded fibrotic nodules 0.5-5.0 cm in diameter in lung).

Common laboratory findings in rheumatoid arthritis :

No tests are specific for RA; however, following tests are commonly performed:

1. Anaemia (normocytic-normochromic), eosinophilia, thrombocytosis.
2. Raised ESR and CRP.
3. RF is positive in approximately 70% patients.
4. Positive antibodies to cyclic citrulinated peptide (anti-CCP) - having high specificity (90-98%); commonly done in seronegative patients to confirm the diagnosis of RA.
5. Acute phase response - High ferritin, reversed albumin/globulin ratio, moderate elevation of alkaline phosphatase. Raised ESR and CRP are also acute phase responses.
6. Radiology - Early RA may show only soft tissue swelling in X-ray. Stages of radiological (X-ray) progression in RA are periarticular osteopenia, marginal erosions, loss of articular cartilage.

Short stature, webbed neck, low hair line, low set ear, 'shield-like' chest with mild mental subnormality in **Turner's syndrome** (girl aged 18 years)

Shadows of respiratory distress in face, central **cyanosis,** clubbing and **polycythemia** (suffused conjunctiva) in Fallot's tetralogy

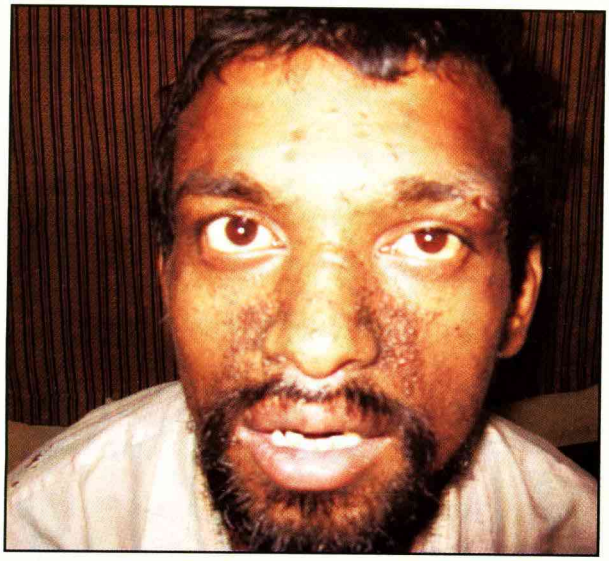

Adenoma sebaceum, low intelligence and H/O epilepsy (injury in left eyebrow due to fall from convulsions) – classical triad in **tuberous sclerosis**

Moon face with facial plethora, excessive hair growth in forehead, double chin and obesity – an effect of long-continued steroid therapy

Jaundice, subconjunctival haemorrhage and dendritic ulcer in cornea – an AIDS patient with disseminated **herpes simplex virus infection**

Extensive **desquamation of palmar skin** during convalescence from toxic shock syndrome

Mycosis fungoides (cutaneous T-cell lymphoma) – multiple tumour like lesions in ulcerated base

Haemorrhagic blister, necrotising skin lesion, cellulitis and brawny induration – a complication of extravasation of cytotoxic drug while injected through intravenous canula

and sublaxation and ankylosis. High resolution USG with colour and power Doppler picks up synovitis, effusion and erosion earlier than conventional X-ray. The MRI scan exhibit bone marrow oedema, synovitis and tendonitis. USG and MRI are rarely performed.

7. Joint fluid study (in effusion) - This is rarely performed. Due to presence of white cells, the aspirate often looks cloudy.

Hou> the disease activity is monitored in rheumatoid arthritis ?

This is assessed by,

1. Duration of early morning stiffness (measured by minutes).
2. Visual analogue scale for general health (eg, pain) as subjectively estimated by the patient.
3. Global assessment by observer as well as patient.
4. Joint count (number of swollen and tender joints).
5. Acute phase response - ESR and CRP.
6. NSAID pill count.
7. DAS (disease activity score) - a complex formula encompassing 28 tender joint count, 28 swollen joint count. ESR, and general health assessment by the patient on a visual analogue scale (VAS) from 0 to 100. It is measured by a DAS calculator.

Common imaging modalities done in musculoskeletal disorders :

1. X-ray: to demonstrate fracture, bony erosion, osteophytes, ankylosis etc.
2. Ultrasonography: to visualize soft tissue / periarticular structures / tendon. Baker's cyst, rotator cuff tear, thickened Achilles tendon.
3. Radionuclide scintigraphy: ^{99m}Tc-bisphosphonate (metastases, bone tumour, Paget's disease); ^{67}-gallium and ^{11} '-indium scans are occasionally used to localize infections.
4. CT scan: for sacroiliitis, prolapsed intervertebral disc, trauma to the spine etc.
5. MRI scan: to visualize vessel, nerve, fascia, muscle, cartilage, ligament, synovial effusion, bone marrow oedema (e.g., early RA). Commonly used in spinal cord compression, prolapsed intervertebral disc, early avascular necrosis etc.
6. Bone mineral density (BMD) measurement: dual energy X-ray absorptiometry (DEXA) is the current method of choice to diagnose osteopenia and osteoporosis (T-score and Z-score).

Outline of management of rheumatoid arthritis :

The treatment paradigms of RA have shifted much from the past. In the past, traditional pyramidal approach (empirical) was go slow, go low but the present era is for early and universal use of DMARDs (evidence-based) though the future is waiting for combination therapy with DMARDs and biological agents (mechanism-based). Treatment needs coordination of a team of medical specialists (rheumatologist, orthopedic surgeon, physiatrist, physiotherapist, social worker, occupational therapist) who deliver an integrated programme of multidisciplinary care and rehabilitation. The **goal** is achieved by drugs, rest, physiotherapy, surgery, aids and appliances, and occupational and social services.

Aim of treatment - relief of symptoms, restoration of function and control of systemic involvement.

Different **modalities of management** are:

I. Pharmacological -

a) NSAIDs (for relief of pain).

b) Corticosteroids (for 'bridge therapy' before the onset of action of DMARDs, in rheumatoid flare, for extra-articular manifestations, and pregnancy).

c) DMARDS - commonly used drugs are sulphasalazine, hydroxychloroquine, methotrexate and leflunamide. Less frequently used drugs are azathioprine. gold (oral and parenteral), cyclosporine A, chloroquine, cyclophosphamide, D-penicillamine, minocycline, chlorambucil and levamizole.

d) Biological response modifiers (biologies) - these are genetically engineered trteatment which basically acts by blocking TNF-a. The commonly used agents are etanercept, infliximab and adalimumab. Rituximab (causes lysis of CD-20 B cells) is also promising.

II. Surgical -

Decompression (in carpal tunnel syndrome), synovectomy, osteotomy, arthrodesis, arthroplasty, replacement of joints, joint fixation (atlanto-axial subluxation) etc.

-------O-------

Section 7

LYMPHORETICULAR SYSTEM

The cardinal symptoms of lymphoreticular system are :

1. Painless or painful enlargement of lymph nodes
2. Pallor (resulting in weakness, palpitation, dizziness, ankle oedema, lassitude, anorexia, lightheadedness, breathlessness etc.)
3. Dragging pain or heaviness in the left hypochondrium (massive splenomegaly)
4. Haemorrhagic spots in the mucous membrane or skin
5. Epistaxis, gum bleeding, menorrhagia, haemarthrosis, H/O prolonged bleeding
6. Bone pain (multiple myeloma, acute leukaemia) and joint pain (Henoch-Schonlein purpura)
7. Jaundice (e.g., haemolysis)
8. Recurrent respiratory tract infection
9. Loss of body weight
10. Mass in the abdomen (abdominal lymphoma)
11. Sore throat (agranulocytosis), non-healing wounds (leucopenia)
12. Fever (leukaemia, lymphoma, neutropenia, infection with immunosuppression)

Scheme of Examination

1. Anaemia.
2. Haemorrhagic manifestations (haemorrhage into skin, conjuctival or buccal mucosa, epistaxis, gum bleeding, haemarthrosis, menorrhagia.
3. Oral cavity (gum for bleeding or hypertrophy, tongue, tonsil, involvement of Waldeyer's ring) and skin (e.g., skin infiltration in lymphoma and leukaemia; telangiectasis).
4. Lymph nodes (in details).
5. Liver and spleen (in details).
6. *Sternal tenderness.*
7. Ophthalmoscopy or fundoscopy (for retinal haemorrhage, papilloedema, Roth spots etc.).

* This system is also known as **haemopoietic system** or **reticulo-endothelial system.**

N.B. : While examining haemopoietic system, examine the other systems for :

I. CVS : haemic murmur and ejection systolic murmur for progressive anaemia, venous hum from severe anaemia, venous/arterial thrombosis from polycythemia vera.

II. Nervous system : LMN type Vllth nerve palsy (leukaemic deposits), spinal cord compression from multiple myeloma, subacute combined degeneration from vitamin B_{12} deficiency.

III. Respiratory system ; Pleural effusion (e.g., lymphoma), pneumonia (due to immunocom-promization).

IV. Locomotor system : bone pain, joint swelling (haemophilia, gout).

V. Gonitourinary system : with special reference to examination of testes (ALL or NHL).

VI. Skin and appendages ; pruritus (lymphoma), pigmentation (lymphoma, busulphan therapy in CML), leg ulcers (sickle cell anaemia, paraproteinaemia), splinter haemorrhage (acute leukaemia), koilonychia (iron deficiency anaemia).

Case 23

T HALASSAEMIA

What is your diagnosis ?

The diagnosis may be stated in one of the four ways. This is a case of,

1. Congenital haemolytic anaemia probably due to thalassaemia major, or
2. Moderate anaemia with hepatosplenomegaly probably from thalassaemia major, or

3. Huge splenomegaly probably due to thalassaemia major, or
4. Hepatosplenomegaly for discussion (if aetiological diagnosis can not be reached).

Why do you say so ?

This is a case of thalassaemia major because of the following :

a) Young patient (18 years male patient) with positive family history, and there are presence of,
b) Anaemia (moderate to severe).
c) Jaundice (mild).
d) Stunted growth.
e) Mongoloid facies.
n Mild (to moderate) hepatomegaly with huge splenomegaly, and
g) Past H/O repeated blood transfusions.

* **Features of chronic haemolytic anaemia are : anaemia, jaundice and splenomegaly.**

Chief complaints of your patient :

1. Respiratory distress since childhood and more for last 2 weeks.
2. Dragging pain in the left hypochondrium for last 4 years.
3. Yellowish discolouration of the eyes (from time to time) for last 5 years.
4. Repeated cough and cold, palpitation, ill-health and weakness since childhood.

What is the H/O present illness ?

1. Insidious in onset and gradually progressive illness.
2. Blood transfusion alleviates his sufferings.
3. Respiratory distress is exertional and often associated with purulent expectoration. There is neither any H/O PND nor any H/O seasonal variations.
4. Palpitation is exertional. There is no H/O fainting (black-out).
5. Dragging pain in the left hypochondrium is associated with a palpable mass in that region. Anorexia is profound.
6. Mild jaundice which increases from time to time.
7. There is no H/O gum bleeding, epistaxis, haematemesis, melaena or haemoptysis. The patient does not give any H/O leg ulcers or bipedal swelling. Occasionally he suffers from fever without any chill and rigor.
8. He has left school at 10 years of age. Till now he has been admitted several times in different city hospitals and each time he has been treated with blood transfusions by different doctors.

* Irregular fever in thalassaemia is due to increased metabolic activity and intercurrent infections.

What 'past history' you have enquired into ?

1. Whether the patient was admitted previously in any hospital for the same ailments.
2. Whether he has received blood transfusion during his past admissions in hospital.
3. Past H/O fever (chronic malaria and kala-azar).
4. Any H/O pain abdomen (pigment stone-induced or haemolytic crises).
5. Had he ever resided in Bihar or U.P of India (chronic kala-azar)?
6. As a routine the H/O diabetes mellitus, hypertension, rheumatic fever (joint pain, dyspnoea, palpitation), past history of jaundice, malaria or kala-azar (due to hepatosplenomegaly), tuberculosis should be enquired for.

* In thalassaemia, one should enquire the presence of similar disorder in brothers, sisters, parents and other family members. Is there any H/O death in the family due to jaundice?

What is a hereditary or familial disease ?

This is caused by ,

a) Mutant genes.
b) Follows the Mendelian law of inheritance and is transmitted from one generation to other.
c) May not be present at brith.

Examples are—Diabetes mellitus, hypertension, bronchial asthma, schizophrenia.

What is a congenital disease ?

a) Not produced by mutant genes.
b) Does not follow Mendelian law of inheritance.
c) Present since birth.

Examples are—Congenital heart disease, cleft lip.

Points noted in the treatment history of thalassaemia :

1. H/O blood transfusion.
2. Any specific drug used for the present disease (e.g., desferrioxamine).
3. Any surgery done in the past (pigment stone removal or splenectomy).

'General survey' in thalassaemia major :

In the **'general survey',** the important points in favour of thalassaemia are :

1. Apparent age (often looks younger than actual age).
2. Build (there may be stunted growth).
3. Facies (mongoloid facies).
4. Anaemia (moderate to severe).
5. Jaundice (mild).
6. Pulse (may get water-hammer pulse due to severe anaemia).
7. Neck veins (may be engorged and pulsatile due to CCF),
8. Legs—Leg ulcer over malleoli (common in sickle cell anaemia),
9. Secondary sexual characters (there may be delayed development), and
10. Splenectomy scar (if there is absence of splenomegaly).

What is thalassaemia ?

This is an inherited (autosomal co-dominant) impairment of haemoglobin synthesis, in which there is partial or complete failure in the synthesis of a specific type of globin chain. It is a quantitative defect in the production of haemoglobin (qualitative defect is seen in sickle cell anaemia).

Thalassaemia is of two types :

a) a (reduction or absence of a-chain synthesis), and
b) (i (reduction or absence of P-chain synthesis)—**Commonest amongst thalassaemic patients.**

(A) a-thalassaemia—4 types (seen in South East Asia, Middle East),

(i) Silent carrier.
(ii) a-thalassaemia trait.
(iii) HbH disease.
(iv) Hydrops fetalis (Hb Barts).

(B) [Vthalassaemia—3 types (seen in mediterranean area),

(i) Heterozygous (thalassaemia minor)—One of the parents has thalassaemia minor.
(ii) Homozygous (thalassaemia major) or double heterozygous — Both parents have thalassaemia minor.
(iii) Intermedia (homozygous who survive into adulthood are likely to have this milder from of disease. Haemolysis occurs but the patient is not transfusion-dependent).

* 'Intermedia' is more severe than 'minor' but milder than transfusion-dependent 'major'. Usually the patients suffer from moderate anaemia.

** HbE disorders and HbD Punjab are common in India.

Normal haemoglobin pattern in human being :

(A) Adult haemoglobin :

1. HbA (97%) — $a_2(3_2$
2. HbA_2 (1.5-3.5%) — $a_2 5_2$
3. HbF (< 2%) — $\boldsymbol{a_2 y_2}$

(B) Abnormal haemoglobin (in intrauterine life and neonates) :

1 ■ HbF — $\boldsymbol{a_2 y_2}$
2. Hb Barts — y_4
3. HbH — P_4
4. Hb portland — $Z_2 y_2$

* *At term, HbF accounts for 70-90% of total Hb. HbF then falls rapidly and it becomes 25% at 1 month, and 5% at 6 month. The adult level (< 2%) may not be reached in some children until puberty.*

** *In an adult, the major haemoglobins seen are HbA and HbA_2 while in foetus, it is HbF and Hb Barts.*

Why HbF is increased in thalassaemia major ?

Thalassaemia is an inherited abnormality in haemoglobin production, where there is partial or toal

failure to synthesise a specific type of globin chain. In (3-thalassaemia major, there is reduction or absence of (3-chain production (defect within globin part) and thus, relative excess of a-chain synthesis occurs. Free a-chains have decreased solubility and will form inclusions within the RBC precursors in bone marrow. As a result of this, there is abnormality in membrane permeability as well as destruction of RBC by the macrophages. So thalassaemia major is characterised by both intramedullary erythroid destruction (ineffective erythropoiesis) and also a marked shortening of the life span of circulating RBC (peripheral haemolysis). Double injury to RBC results in expansion of red marrow (produces typical facial changes) and extramedullary haematopoiesis in the liver and spleen. There is also compensatory increase in synthesis of '/-chain which combines with excess of free a-chains and form a stable tetramer of HbF (a y_2). It is seen that patients with thalassaemia major who have relatively high rate of a-chain synthesisV.e., more HbF), have less severe clinical course. A patient suffering from thalassaemia major may have HBF upto 98%. Thalassaemia major patients may prove fatal, if left untreated.

How do you classify haemolytic anaemia ?

(A) ACQUIRED—

I. Environmental factors :
   a) Antibody—Immune haemolytic anaemia (lymphoma, SLE, drugs).
   b) Mechanical trauma—Microangiopathic haemolytic anaemia (prosthetic valves, haemolytic-uraemic syndrome).
   c) Direct toxic effect—Malaria, claustridial infection.
   d) Splenomegaly.

II. Membrane abnormalities :
   a) Spur cell anaemia (associated with portal cirrhosis).
   b) Paroxysmal nocturnal haemoglobinuria (PNH).

(B) HEREDITARY:

I. Membrane abnormalities :
   a) Hereditary spherocytosis.
   b) Hereditary elliptocytosis.

II. Haemoglobinopathies :
   a) Thalassaemia (quantitative defect).
   b) Sickle cell disease (qualitative defect).

III. Enzymopathies (metabolic defects) :
   a) G_6PD deficiency.
   b) Pyruvate kinase deficiency.

* Extracorpuscular defects—all 'acquired' causes except PNH; Intracorpuscular defects—all 'hereditary' causes plus PNH.

Describe thalassaemic or mongoloid facies :

in thalassaemia. there is t 0_2 affinity of HbF resulting in tissue hypoxia -> which in turn, stimulates erythropoiesis ^ expansion of marrow space gives rise to characteristic facial appearance.

1. Frontal bossing (prominent forehead due to marrow hyperplasia).
2. Depressed bridge of the nose (due to hyperplasia of lesser wing of sphenoid).
3. Hypertelorism (widely set eyes).
4 Apparent mongoloid slant ot the eyes (mimics the eyes of Hindu Goddess Durga).
5. Malar prominence (due to marrow hyperplasia)—'Chipmunk' facies.
6. Dental malocclusion with prominent upper incisors (due to expansion oi marrow).
7. Associated with mild icteric tinge of the conjunctiva, and pallor.

Why there is anaemia in thalassaemia major ?

1. Impaired haemoglobin production.
2. Ineffective erythropoiesis.
3. Haemolysis.
4. Haemodilution.
5. RBC destruction from hypersplenism.

Why there is jaundice in thalassaemia major ?

1. Haemolysis (classically it is haemolytic jaundice).

2. Viral hepatitis (type C or B infection due to repeated blood transfusions).
3. Rarely, due to iron deposition in liver.

Why there is cardiomegaly or heart failure seen in thalassaemia major ?

1. Persistent hypoxia (as progressive anaemia is always present).
2. Volume overload due to repeated blood transfusions.
3. Rarely, there is cardiomyopathy by haemosiderosis/haemochromatosis.

Description of splenomegaly in your patient :

1. Enlarged 16 cm below the left costal margin along its long axis (or along the splenic axis) and has crossed the umbilicus. It has enlarged towards the right iliac fossa.
2. Non-tender (rarely it may be tender due to splenic infarction, specially in a very big spleen).
3. A notch is present in the anterior border.
4. Firm in consistency.
5. It is freely moving with respiration.
6. Surface is smooth.
7. Margin is sharp.
8. Fingers cannot be insinuated between the spleen and the left costal arch.
9. It is neither bimanually palpable nor ballottable.
10. There is no colonic resonance over the mass.
11. No palpable splenic rub (present in case of splenic infarction).

* Never forget to auscultate over a hugely enlarged spleen for audible splenic rub.

Describe the hepatomegaly in your patient :

1. Enlarged 5 cm below the right costal margin at right MCL.
2. Moving with respiration.
3. Firm in feel.
4. Non-tender.
5. Smooth surface.
6. Margin is sharp and regular.
7. Left lobe is not palpable.
8. Upper border of liver dullness is at right 5th ICS at right MCL.
9. No pulsation, no rub, no bruit.

Splenohepatomegaly in thalassaemia is mainly due to extramedullary haematopoiesis and rarely transfusional haemosiderosis.

Features in other systems in thalassaemia major :

(A) CVS Effect of anaemia on CVS with special reference to haemic murmur. Read the section on 'Anaemia'. There may be features of heart failure. Look for neck veins carefully.

(B) RESPIRATORY SYSTEM—

1. Occasional rhonchi, and
2. Crepitations due to respiratory tract infection.

(C) NERVOUS SYSTEM— Rarely, there may be spastic paraplegia due to 'extramedullary haematopoiesis' in the paravertebral region in thorax.

(D) RETICULO-ENDOTHELIAL SYSTEM—

a) Anaemia.
b) Tonsils may be enlarged.
c) No lymphadenopathy.
d) No bleeding manifestations into skin.
e) Hepatosplenomegaly.
f> Rarely, sternal tenderness may be present (due to severe anaemia)

Ascites is not a feature of thalassaemia. In a **long case of thalassaemia.** first examine the G. I. system, next the CVS, respiratory system and so on. One may examine the reticulo-endothelial system after the examination of G.I. system.

How thalassaemia minor (trait) presents ?

They are rarely associated with significant clinical manifestations i.e., the patients can lead normal life with normal life expectancy. Usually they spend their life without diagnosis. 20% patients have splenomegaly and few may have pallor or mild icterus. The diagnosis is generally made when they are evaluated for persisting mild anaemia or pre-marital check up. Reticulocyte count is normal. HbA_2 is usually 5%; 50% patients have HbF elevated.

Differential diagnosis you will consider :

Basically one has to consider the **causes of huge splenomegaly.** For the discussion, read the section on 'Hepatosplenomegaly'. Actually, the task is to differentiate thalassaemia from chronic kala-azar, chronic malaria. CML. cirrhosis of liver (with hypersplenism) and tropical splenomegaly syndrome.

'Crises' described in haemolytic anaemias :

The 'crises' are very common in sickle cell anaemia. There are 4 types :

1. Haemolytic crisis (sudden hepatosplenomegaly with rapidly developing anaemia).
2. Aplastic crisis or aregenerative crisis (temporary marrow suppression)—Occurs in the presence of infection and/or folic acid deficiency, and may be seen even in thalassaemia major.
3. Vaso-occlusive crisis (commonest)—Acute and severe bone pain results from plugging of small vessels in bone. Various part of the body like hands and feet in children (resulting in dactylitis), or humerus, femur, ribs, vertebrae and pelvis in adults may be affected. Sweating, pyrexia and tachycardia are associated with.
4. Sequestration or infarction crisis—Thrombosis of the venous outflow results in crisis in an organ. Splenic infarction in sickle cell anaemia is a classical example.

* In haemolytic crisis, reticulocyte count increases but in other crises reticulocyte count does not increase from the basal level. By about 8 years of age, in sickle cell disese, spleen is no longer palpable due to repeated episodes of splenic infarcts leading to 'autosplenectomy'.

Pain abdomen in thalassaemia major :

1. Dragging pain due to huge splenomegaly.
2. Vaso-occlusive crisis (rare).
3. Biliary colic (due to production of pigment stones from haemolysis).
4. Rarely due to splenic infarction.

How to establish the diagnosis of thalassaemia major ?

1. Peripheral blood smear—
   (i) Anisocytosis (variation in size), poikilocytosis (variation in shape), **microcytic hypochromic anaemia, target cells,** tear-drop cells, cigar-shaped cells, basophilic stippling, polychromasia, normoblasts. Small number of immature myelocyte or metamyelocyte may be present.
   (ii) **Reticulocytosis** (indicates haemolysis and increased production of new red cells; normal reticulocyte count is 0.2-2% of RBC).
2. Haemoglobin concentration, ESR and bilirubin —
   (i) Hb—Low (usually between 2-6 g/dl).
   (ii) ESR—High.
   (iii) Serum bilirubin is raised (unconjugated hyperbilirubinaemia).
3. Radiology—
   (i) **X-ray of skull—'Hair on end' appearance** due to the separation of two tables of skull (i.e., widened diploic space) with perpendicular trabeculae in between.
   (ii) **X-ray of small bones of hands—'Mosaic-patterns'** due to widening of medullary space with thinning of cortex and criss-cross trabeculae in between.
   (iii) Chest X-ray (PA view) —Cardiomegaly, pneumonitis or paravertebral shadow as a result of extramedullary haematopoiesis.
4. **Haemoglobin electrophoresis is diagnostic**—Shows presence of **HbF** (> **2% of total Hb)** and variable amount of HbA_2 and HbA (HbA_2 is increased more in thalassaemia minor than in major, and is usually > 3.5%).
5. Alkali denaturation test — HbF is resistant to alkali denaturation (i.e., the test is positive).
6. Osmotic fragility test—It Is decreased, i.e., there is increased resistance of red cells to osmotic lysis (osmotic fragility is increased in hereditary spherocytosis).
7. Ferrokinetics—**Serum iron concentration is increased,** and TIBC usually remains normal or reduced.

8. Red cell survival study.
9. Bone marrow—Hyperplastic bone marrow with hyperplasia of erythropoietic and leucopoietic tissue. Myeloid and erythroid ratio (M : E) becomes 1 or less. Granulopoiesis and thrombopoiesis are preserved.
10. Both the parents have thalassaemia minor.

N.B. : The other names of thalassaemia major are Cooley's anaemia, target cell anaemia, mediterranean anaemia *(Greek 'thalassa' means sea)* and splenic anaemia.

Laboratory features of haemolysis :

1. **High serum bilirubin, usually < 6 mg/dl (unconjugated > conjugated).**
2. **High urinary urobilinogen.**
3. Low plasma haptoglobin and haemopexin.
4. Haemoglobinaemia and haemoglobinuria.
5. Increased methaemalbumin in blood (detected by Schumm test).
6. High urinary haemosiderin.
7. Fragmented red cells in peripheral blood.
8. **Reticulocytosis.**
9. Hyperplastic bone marrow (i.e., erythroid hyperplasia).

* 4,5 and 6 are classically seen in intravascular haemolysis.

Features of iron overload in thalassaemia major :

Here, iron overload is due to :

a) Haemolysis, and
b) Repeated blood transfusions.

Features of iron deposition (haemosiderosis) in different systems are :

1. CVS—Pericarditis, cardiomyopathy, ventricular ectopics, heart blocks, pump failure.
2. Hepatic—Hepatomegaly (prothrombin time and liver enzymes may increase), rarely cirrhosis of liver.
3. Endocrine—
   (i) Pancreas—Diabetes mellitus.
   (ii) Adrenal gland—May have adrenal crisis.
   (iii) Due to diminished gonadotropin release— Delayed development of secondary sexual characters (due to impaired hypothalamo-pituitary-gonadal function), i.e., features of hypogonadism.

* Liver biopsy in thalassaemia major shows both reticulo-endothelial and parenchymal iron.

Causes of iron overload in internal medicine :

1. P-thalassaemia major 2. Haemochromatosis 3. Sideroblastic anaemia 4. Alcoholic liver disease
5. Repeated blood transfusions 6. Iron-dextran infusions 7. Chronic haemodialysis.

Complications of thalassaemia major :

1. Stunted growth with facial disfigurement.
2. Pigment gall stones.
3. Iron overload complications (described above)—Haemosiderosis.
4. Leg ulcers.
5. Hypersplenism.
8. Repeated respiratory tract infection.
7. Compressive myelopathy (due to extramedullary haematopoiesis).

Table 16 ; ***Differences between haemosiderosis and haemochromatosis***

	Features		Haemosiderosis	Haemochromatosis
I.	Inheritance	1.	Always acquired 1.	Genetic or acquired
2.	Tissues affected	2.	R-E cells 2.	Parenchymal cells
3.	Damage	3.	Less tissue damage 3.	Obvious tissue damage
4.	After desferrioxamine application	4.	Urinary excretion of iron 4. does not exceed 4 mg/24 hrs	Exceeds 4 mg/24 hrs

Causes of microcytic hypochromic anaemia :

1. Iron deficiency anaemia.
2. Thalassaemia.
3. Sideroblastic anaemia (often responses to pyridoxine).
4. Sometimes seen in lead poisoning.
5. Anaemia of chronic diseases (e.g.. rheumatoid arthritis).

* Sideroblast—These are nucleated RBC having excess of iron-containing granules in the cytoplasm.

MCV, MCH, MCHC in thalassaemia :

1. Normally MCV is 87 ± 7 cubic (low in thalassaemia).
2. Normally MCH is 29.5 ± 2.5 pico-gram (low in thalassaemia).
3. Normally MCHC is 35 ± 3 g/dl (low in thalassaemia).

Severe anaemia without splenomegaly—possibilities in clinical medicine :

1. Anaemia due to acute or chronic blood loss.
2. Aplastic anaemia.
3. Sickle cell anaemia (spleen shrinks due to repeated infarction).
4. Anaemia due to hookworm infestation.
5. Chronic renal failure.

What is the treatment of thalassaemia major ?

1. **No oral or parenteral iron therapy.**
2. **Repeated transfusions** to keep the haemoglobin in the range of 10 g/dl with desferrioxamine therapy.
3. Folic acid—5 mg daily, orally.
4. Antibiotics for infections.
5. Splenectomy in some cases.

* Thalassaemia minor needs no treatment. The patient should be reassured and genetic counselling is explained to the patient.

Recent trends in the management of thalassaemia major :

To maintain the most beneficial Hb level, it requires an individualised programme of transfusion with iron chelation and careful attention to the development of skeletal, endocrine and cardiac abnormalities.

1. Transfusion therapy—
   (i) **Hypertransfusion**—Hb level is kept > 10 g/dl.
   (il) **Supertransfusion**—Hb level is kept >12 g/dl.
2. Iron chelation is achieved by desferrioxamine which delivers drug by a small portable pump. The dose is 20-40 mg/kg/day and is given by subcutaneous continuous Infusion. 1 g of desferrioxamine chelates 85 mg of iron. Now-a-days, It is started at 5 years of age when the child can use the 'infusion pump' of his own. Infusion lasts 10-12 hours (overnight) and is given for 5-7 nights per week with a goal to keep serum ferritin < 1000 ng/ml. Common side effects are pruritus, local swelling, sore arm etc. Excessive doses may give rise to cataract, optic neuritis, nerve deafness and retinal damage.
3. Splenectomy (see below) which is preceded 4-6 weeks by pneumococcal, H. influenzae and meningococcal vaccine.
4. Vitamin E—Can be used as an antioxidant drug; excretion of iron is enhanced by vitamin C (low dose, i.e., usually 3 mg/kg daily is used to avoid caraiotoxicity).
5. Vitamin D and calcium may be used to control osteoporosis.
6. Local irradiation of face to minimise facial disfigurement.
7. Neocyte transfusion i.e., transfusion of young low-density RBC (average life span 90 days); the neocytes reduce the rate of iron accumulation. Gerocytes (old RBC) may be removed by pneresis to reduce iron load.
8. Genetic manipulation is done by azacitidine or butyrate which Increases the production of HbF (increased HbF in thalassaemia Is associated with less severe clinical course).
9. Allogenic bone marrow transplantation from HLA compatible sibling (definitive therapy).
10. Folic acid supplement and antibiotics, as and when necessary. Chronic leg ulcers may be managed with elevation of the affected leg and daily dressings with zinc sulphate.
11. Prevention is possible by Identifying a foetus with p-thalassaemia by DNA analysis of chorionic villus in early pregnancy (8-10 week) and also by amniocentesis (14-18 week). Fetal cord blood

In the womb can also be tested In 18-20 weeks of pregnancy. This is appropriate if both the parents are known to be carriers, i.e., p-thalassaemia minor, and always terminate the pregnancy in these cases. Genetic counselling is a must.

* In both the parents are thalassaemia minor :
  - 25% chance to have thalassaemia major
  - 50% chance to have thalassaemia minor
  - 25% chance to have a normal child

Advantages of hyper- and supertransfusion :

1. Gastrointestinal iron absorption is less.
2. Growth and development are increased.
3. Less chance of facial disfigurement.
4. Less chance of hypersplenism.
5. Less need for early splenectomy.

Indications for splenectomy in thalassaemia major :

1. Mechanical problems due to massive splenomegaly (dragging pain, early satiety).
2. Requirement of excessive transfusions (normal requirement is 1 unit / 4-6 weeks to maintain the Hb level in the range of 10 g/dl) e.g., double of normal requirement.
3. Features of hypersplenism.

* Splenectomy should be done in a child who is > 5 years of age.

** If spleen is not palpable in thalassaemia, always look for the splenoctomy scar.

Peripheral blood film after splenectomy :

1. Marked anisocytosis, poikilocytosis.
* 2. Howell-Jolly bodies.
3. Target cells.
4. Thrombocytosis.
5. Pappenheimer bodies (sideroblastic granules).
** 6. Heinz bodies.
7. Nucleated RBCs.
8. Basophilic stippling.

* Remnants of nuclear material in RBC; ** Formed from denatured aggregated Hb.

Indications (medical) of repeated blood transfusions in your hospital :

1. Thalassaemia.
2. Aplastic or hypoplastic anaemia.
3. Haemophilia.
4. ITP (immune thrombocytopenic purpura).
5. Recurrent haematemesis or melaena.
6. Chronic renal failure.

Drawbacks of repeated blood transfusions :

1. Risk of iron overload and heart failure.
2. Chance of isoimmunisation.
3. Entry of infections through blood like malaria, hepatitis C and B; AIDS, toxoplasmosis, brucellosis, cytomegalovirus infection, syphilis; citrate toxicity.

* Acute (< 72 hrs) complications are anaphylaxis, transfusion reactions (chills, urticaria, breathlessness etc), febrile reactions, fluid overload resulting in LVF, mismatch (haemolysis), hypothermia. Delayed (> 72 hrs) complications are thrombophlebitis and entry of different infections.

Causes of target cell in peripheral blood film :

1. Thalassaemia.
2. Iron deficiency anaemia.
3. Cholestatic jaundice.
4. After splenectomy.

Common causes of refractory anaemia in clinical practice :

1. Aplastic anaemia.
2. Sideroblastic anaemia (pyridoxine-responsive).
3. Erythroleukaemia (M_e variety of AML).
4. Aleukaemic leukaemia.
5. Myelodysplastic syndrome.
6. Chronic renal failure.

Conclusion :

H/O repeated blood transfusions and previous hospital admissions should always be enquired. Menstrual history should be taken with care as in many patients menarche may not be attained. Never forget to examine for cardiomegaly, CCF and systolic murmur over the precordium.

Case 24

CHRONIC MYELOID LEUKAEMIA

What is your diagnosis ?

The diagnosis may be delivered in one of the three ways :

1. This is a patient of huge splenomegaly and moderate hepatomegaly probably due to chronic myeloid leukaemia (CML), or
2. This is a patient of anaemia with hepatosplenomegaly probably due to chronic myeloid leukaemia, or
3. Huge splenomegaly probably due to chronic myeloid leukaemia.

Why do you say so?

This is a case of CML because of the following :

1. This is an adult patient (majority are in the age group of 30-80 years with peak age at 55 years) who complains of gradual onset of dragging pain in the abdomen, mainly the left upper quadrant with a palpable, non-tender swelling present there. This is associated with loss of appetite and early satiety, vague ill-health, abdominal fullness, tiredness, marked weight loss and occasional rise of temperature with night sweats but without chill and rigor for last 5 months. The onset of the disease is insidious and the progress is slow.
2. There is neither any past H/O haematemesis, melaena, jaundice, blood transfusion, oedema feet nor it is associated with positive family history with similar type of illness.
3. On examination there is mild anaemia, absence of jaundice, moderate hepatomegaly with huge splenomegaly as well as there is presence of sternal tenderness. Lymphadenopathy, signs of hepato-cellular failure or bleeding manifestations into skin are absent.

Chief complaints of your patient :

1. Gradually progressive swelling with dragging pain in the left upper abdomen, specially in upright posture for last 5 months.
2. Loss of appetite, tiredness, weakness and loss of weight for the same duration.

Presence of sternal tenderness—conditions associated :

Clinical method—Press the upper part of the body of sternum with the **ball of the right thumb** for 2-3 seconds. In the presence of sternal tenderness, the patient winces with pain (also see the facial grimace) or complains of pain. Sternal tenderness is found in :

1. Acute leukaemias (AML and ALL).
2. Chronic myeloid leukaemia.
3. Severe anaemia due to any cause (except aplastic anaemia).
4. Multiple myeloma.
5. Rarely in osteomalacia and osteoporosis.
6. After sternal puncture.

N.B. : When sternal tenderness is present, examine the patient for tenderness in other bones like pelvic bones, ribs, vertebrae, long bones (press the upper part of shin bone) and frontal bone (press the forehead). Look for the evidence of sternal puncture (benzene stain or cotton seal in the sternum) in these cases. Sternal tenderness is usually due to *proliferation as well as hypercellularity of bone marrow.*

Remember, diffuse bone pain is common is osteomalacia and multiple myeloma.

* 1 and 2 are most common causes.

Causes of swelling in the left upper abdomen :

1. Splenomegaly.
2. Kidney lump (left).
3. Tumour of splenic flexure.
4. Growth from stomach.
5. Tumour of left ademal gland.
6. Rarely, tumour of the tail of pancreas.
7. Enlarged left lobe of liver.
8. Omental mass.

'Past history' you have enquired for :

1. Haematemesis or melaena.
2. Jaundice.
3. Fever (ref : malaria or kala-azar).
4. Repeated blood transfusions.
5. Bone pain.
6. Ankle oedema.
7. Bleeding manifestations, e.g., purpura.
8. Haematuria (ref : kidney lump).
9. Diabetes mellitus.
10. Systemic hypertension.

Causes of huge splenomegaly :

Read the section on 'Hepatosplenomegaly'.

What is the classical description of the spleen of CML :

Splenomegaly in CML is present in 90% cases and approximately in 10%, the enlargement is massive and the spleen goes towards the right inguinal ligament. Splenic rub may be present.

For typical description—Read the section on Thalassaemia' as the description of splenic enlargement is the same in both the conditions.

* The spleen of CML is very hard and is known as *'cast iron spleen'.* Hepatomegaly occurs in 50% cases.

Phases of CML :

1. Chronic or stable phase—Easily controlled by treatment. Usually lasts for 3-5 years.
2. Accelerated phase—Control of the disease is difficult (progressive anaemia, organomegaly, fever, thrombocytosis or thrombocytopenia develop).
3. Blastic (blast crisis) phase—-It is a dreadful condition where the patient transforms into acute leukaemia (AML in 70% and All in 30%). **The blast cell of AML contains Auer rods which are not seen in blast crisis of CML.** This is the cause of death in majority of patients.

* *CML is a monoclonal stem cell disorder or myeloproliferative disorder characterised by an overproduction of rnyeloid cells with fairly normal maturation.*

Why it is not a case of chronic malaria, chronic kala-azar or thalassaemia ?

Read the sections on 'Hepatosplenomegaly' and Thalassaemia".

Why it is not a case of chronic lymphocytic leukaemia (CLL) ?

The salient features of CLL are :

1. Peak age for the disease is 65 years.
2. Onset is very insidious.
3. Anaemia develops slowly and lately.
4. Absence of sternal tenderness.
5. Presenting complaint is painless, discrete, firm and moderate enlargement of lymph nodes all over the body.
8. Moderate splenomegaly.

These features are absent here and this is why it is not a case of CLL.

How will you recognise the 'blast crisis' ?

The features of blast crisis are :

1. The stable patient will deteriorate (there is refractoriness to treatment).
2. Anaemia progresses rapidly; bone pain and sternal tenderness increase.
3. Severe bleeding starts e.g, petechiae, purpura, bruise, epistaxis, gastro-intestinal bleeding, bleeding from urogenital tract; fever appears.
4. Generalised lymphadenopathy may be present (due to transformation into ALL).
5. Abrupt increase in splenic size and tenderness.
6. Peripheral blood film shows > 10% blast ceils.

Manifestations at the late stage of CML :

1. Bleeding into the skin or from mucous membrane of internal organs.
2. Acute pain in the left hypochondrium—Due to splenic infarction with audible splenic rub.
3. Persistent rise of temperature.
4. Leukaemic infiltrations in cranial nerves with their paralysis, pleural effusion, ascites or peripheral neuropathy.
5. Respiratory tract infection.

Differential diagnosis you will consider in this case :

Consider causes of massive splenomegaly.

How your diagnosis will be established ?

1. Blood examination—
   a) Hb and RBC—RBC count is low with anisocytosis, poikilocytosis, few normoblasts, normocytic normochromic anaemia, low Hb (mean Hb level is 10.5 g/dl).

b) WBC—

(1) Average total count (TC) Is 1.5 lacs to 2.5 lacs /mm^3 (1 to 5 lacs/mm^3).

(ii) Differential count (DC) includes myelocytes 20-30%, metamyelocytes 25%, promyelocytes 2-3%, polymorphs 40%, eosinophils 4%, basophils 2%, lymphocytes 5%, monocytes 1%, myeloblasts 1-2% (usually < 10%).

c) Platelets—Initially normal or increased but diminished gradually.

N.B. : In the accelerated phase, more primitive cells appear and in the blastic phase, there is dramatic increase in blast cells (>10%) in the peripheral blood film.

d) ESR—Increased.

2. Bone marrow examination—It is not mandatory (though gives definitive diagnosis) because **peripheral blood picture is the most useful diagnostic aid.** It shows increased myelocyte series with increased myeloid and erythroid ratio (as high as 20:1). Often prominent megakaryocytes are seen (In acute leukaemias, bone marrow is hypercellular and there is presence of more than 30% of leukaemic blast cells). Cytogenetics show t(9;22) translocation.
3. Philadelphia (ph) chromosome is seen in myeloid and erythroid series of blood and bone marrow.
4. Other findings-

a) High serum uric acid and LDH level (due to increased cell breakdown).

b) High serum vitamin B_{12} level (due to T in transcobalamin III present in neutrophil granules).

c) Low leucocyte alkaline phosphatase (LAP score).

5. Special investigation—Fluorescein-in-situ hybridization (FISH) or reverse transcriptase polymerase chain reaction (RT-PCR) helps demonstrating cytogenetic/molecular abnormality.

* A hypermetabolic state is found in CML, lymphoma, tuberculosis, malignancy and myelofibrosis.

** LAP score is diminished in CML and paroxysmal nocturnal haemoglobinuria. It is increased in infection (leukaemoid reaction), pregnancy, after steroid administration, stress, Hodgkin's disease, polycythemia vera and myelosclerosis.

*** The mean haemoglobin level is 10.5 g/dl (i.e., mild anaemia). Anaemia in CML is never severe in degree. Basophilia often points towards the diagnosis and tends to increase as disease progresses.

**** RNA analysis in CML demonstrates the presence of the chimeric BCR-ABL oncogene. ABL stands for abelson (named after the abelson murine leukaemia virus), and BCR for breakpoint cluster region (BCR gene on chromosome 22).

Hypercatabolic (hypermetabolic) symptoms of CML :

1. Weight loss (wasting).
2. Fever.
3. Sweating (night).
4. Malaise and anorexia.
5. Gout.
6. Heat intolerance.

What is philadelphia (Ph) chromosome ?

1. Diagnostic of CML.
2. Shortening of long arms of chromosome G 22 (due to balanced reciprocal translocation of genetic material with chromosome 9).
3. Found in 90% cases of CML. Thus, 10% patients are Ph-chromosome -ve.
4. Ph-chromosome +ve cases have a better prognosis than Ph-chromosome -ve cases.
5. Found in myeloid and erythroid series of blood and bone marrow (never seen in lymphocytes).
6. Present in all the phases throughout the course of the disease and even after therapy; however Ph +ve cells decrease with a-interferon and imatinib therapy.
7. Helps in differentiation between AML and blast crisis of CML.

* By polymerase chain reaction (PCR), Ph-chromosome is present in almost all patients of CML.

Confirmation of diagnosis of CML :

1. Peripheral blood film with bone marrow examination.
2. Ph-chromosome—Pin-points the diagnosis.
3. RNA analysis for presence of BCR-ABL oncogene.
4. Low LAP score.

Aleukaemic and subleukaemic leukaemia :

In acute leukaemia, an increase in total WBC count is expected but in —

a) Aleukaemic leukaemia—The total WBC count remains normal or subnormal, and there is absence of abnormal cells in the peripheral blood.

b) Subleukaemic leukaemia—The total WBC count is within or below normal limit but few immature cells are seen in the peripheral blood.

Both a) and b) present as acute leukaemia. The confused **diagnosis is confirmed by bone marrow examination.**

What is juvenile CML ?

This rare form of CML is characterised by :

1. Affection below 4 years of age.
2. Absence of Ph-chromosome.
3. Increased level of HbF.
4. Normal cytogenetic karyotype.
5. Paucity of blastic transformation.
6. Presence of prominent monocytosis and thrombocytopenia.

What is myelodysplastic syndrome (MDS) ?

These are a group of acquired clonal abnormalities of haematopoietic stem cells with varying degrees of cytopenia which represent steps in the pathway of development of leukaemia. Often it is called 'preleukaemia' or oligoblastic leukaemia as these patients are at increased risk of developing acute leukaemia. People over 50 years of age are usually affected (median age 69 years). Blast cells in marrow are increased but never corss 30% (> 30% blast cells in marrow indicates acute leukaemia). Bone marrow examination shows hypercellularity with evidence of dysplasia. Though the exact cause is unknown, exposure to benzene or chemotherapeutic agents, or radiation may lead to MDS. Chromosomal abnormality is seen in up to 80% of cases. There is high morbidity and mortality due to bone marrow failure (symptoms of anaemia, bleeding or recurrent infections) or transformation into acute leukaemia.

The *Jive distinct clinical syndromes* under MDS (FAB subtypes) are refractory anaemia, refractory anaemia with excess of blasts (RAEB), refractory anaemia with ring sideroblasts (RARS), chronic myelomonocytic leukaemia (CMML), and refractory anaemia with excess of blasts in transformation (RAEB-t). The WHO classification is a bit different. In the combined (FAB and WHO) classification, CMML is not included in MDS.

Prognosis of CML :

1. Median survival of treated CML is 3 years (in imatinib era, it is 4 years).
2. Median survival is about 1 year after blast crisis and < 1 year in Ph-ve variety.
3. Few patients survive over 10 years.

Complications of CML :

1. Blast crisis.
2. Haemorrhage into skin or mucous membrane of internal organs.
3. Recurrent infection (commonly in respiratory tract).
4. Hyperuricaemia (C/O joint pain due to gout).
5. Leukaemic infiltrations in cranial nerves, pleura (effusion), bones (paraplegia).
6. Rupture of the spleen.
7. Infarction of the spleen.
8. Priapism (persistent painful erection of penis).

* 'Leucostasis' in CML may produce priapism, blurred vision or respiratory distress.

Physical findings in different systems in CML :

(A) GENERAL SURVEY—Mild anaemia, emaciation; pedal oedema due to anaemia or pressure over IVC by big spleen, haemorrhagic spots into skin may be present; very rarely jaundice may appear due to hepatic involvement, or type B or C hepatitis from blood transfusion.

(B) G.I. TRACT—Huge splenomegaly, mild to moderate hepatomegaly. Usually there is absence of ascites. *The hallmark physical finding in CML is huge or massive splenomegaly.*

(C) LYMPHORETICULAR SYSTEM—Presence of sternal tenderness; rarely lymphadenopathy in blastic transformation into ALL. Bone pain due to infiltration of marrow by leukaemic cells may be present.

(D) RESPIRATORY SYSTEM—Basal crepitations due to pulmonary congestion; pleural effusion or rarely pneumonic consolidation.

(E) CVS—Rarely, pericardial effusion.

(F) NERVOUS SYSTEM—Cranial nerve involvement (search for Bell's palsy), paraplegia; rarely meningeal signs may be seen. Retinal haemorrhage due to leucostasis may be evident on fundoscopy.

(G) GENITOURINARY SYSTEM—Sometimes there is presence of priapism.

Table 17 ; Bedside differentiation between acute leukaemias

	Features	AML	ALL
1.	Symptoms	Fever, tiredness, haemorrhagic manifestations, ulcers in the mouth, recurrent infection	Same as AML. Bone and joint pain are more common. Bleeding as presentation is less common
2.	Age	Relatively uncommon in children (common in adults); median age at presentation is 60 years	Mainly a disease of childhood (peak incidence : 3-7 years)
3.	Lymphadenopathy and enlarged tonsils	Rare	Common
4.	Gum hypertrophy	Seen (specially in M_5 variety)	Not seen
5.	Splenomegaly	Less common (50%)	More common (70%)
6.	Chloroma (localised greenish tumour masses in orbit, skin and other tissues)	Common	Usually not seen
7.	Anaemia	+ +	+ + +
8.	Leukaemic meningitis	Less common	More common

* Sternal tenderness is present in both the types of acute leukaemia.

How do you like to manage this case ?

(A) IMATINIB MESYLATE—It is recommended as first-line treatment in chronic or stable CML, which results in complete 'cytogenetic' response (proved by disappearance of Ph-chromosome) in approximately 76% patients at 18 months of therapy. The complete 'haematologic' response with imatinib is 97% as compared to 69% in patients treated with interferon (IFN)-a and cytarabine at 18 months of therapy. Imatinib inhibits BCR-ABL tyrosine kinase activity and thereby reduces the proliferation of white blood cells. This drug is also indicated in patients presenting in accelerated or blastic phase, and in those who are resistant to IFN-a. The recommended daily dose is 400 mg/day. The side effects encountered are nausea, diarrhoea, skin rash, muscle cramps, fluid retention, periorbital swelling and myelosuppression; in the first year, 3% of the patients may progress to accelerated/blastic phase with imatinib. Newer drugs like nilotinib and dasatinib are now being used in many countries.

(B) INTERFERON-a—It was the treatment of choice before introduction of imatinib, and patients treated with IFN-a survive longer than patients who are treated with busulphan or hydroxyurea. It is used in doses of 1.5 million unit, subcutaneously on alternate days. It can induce control and maintain the control in chronic phase. There may be elimination of Ph-chromosome in 20% cases. Common side effects are flu-like syndrome, myelosuppression and neurotoxicity (fatigue, depression, myalgia, severe weight loss).

(C) CHEMOTHERAPY—Hydroxyurea (1-4 g/day) and busulphan (2-4 mg/day) are usually reserved for patients for rapid lowering of WBC, reduction of symptoms and reversal of symptomatic splenomegaly. As cytogenetic remissions with hydroxyurea is uncommon and busulphan produces serious side effects, these drugs are not recommended now-a-days to treat CML. However, hydroxyurea is still being used in many countries.

(D) SPLENECTOMY (or irradiation of the spleen)—Done to alleviate symptoms of discomfort and pain as a result of repeated splenic infarction, and to correct prolonged thrombocytopenia.

(E) BLOOD TRANSFUSION—Low platelet count may be raised by repeated fresh blood transfusions.

(F) BONE MARROW TRANSPLANT (BMT)—Allogenic or syngenic BMT from a matched sibling donor could potentially cure CML. However, in the era of imatinib, the role of BMT in CML is not very clear. Hopefully, long-term results of imatinib will throw some light on it in future.

(G) Good nutrition, antibiotics for infections and maintenance of proper oral hygiene.

(H) OTHERS—Oral hydroxycarbamide (used in palliative situations), arsenic trioxide, leukapheresis for symptomatic leucostasis (pulmonary failure or CVA).

(I) ACCELERATED OR BLASTIC PHASE—

(a) Accelerated phase—imatinib, hydroxycarbamide, low-dose cytarabine.

(b) Blast crisis—Blastic transformation to ALL responses better than AML. Most patients have s short-lived response to imatinib. However, ultimatily BMT may be necessary. Blast crisis have a poor response with all modalities of treatment.

Complications of busulphan ***:***

1. Increased skin pigmentation.
2. Sterility.
3. Dryness of skin and mucous membrane.
4. Pancytopenia (myelosuppression as it acts on early progenitor cells).
5. Interstitial pulmonary fibrosis (busulphan lung) and retroperitoneal fibrosis. Endocardial and marrow fibrosis have been reported.
6. A wasting syndrome similar to that seen in adrenal insufficiency.

* Complications of hydroxyurea are diarrhoea, mucositis or rash.

Features of aplastic anaemia :

It is characterised by hypocellular bone marrow with pancytopenia :

a) Precipitating factor or the aetiological factor is very often present (drugs, chemicals, radiation).

b) Severe anaemia and its manifestations—Fatigue, lassitude, vertigo, black-out, tingling and numbness of extremities, palpitation, dyspnoea, chest pain, anorexia.

c) Leucopenia and its manifestations—Sore throat, fever with chill and rigor due to infection. fatigue, features of depressed immunity.

d) Thrombocytopenia and its manifestations—Bleeding manifestations into skin as petechiae, purpura, bruise; epistaxis; gum bleeding.

e) There is absence of splenomegaly, lymphadenopathy, jaundice or sternal tenderness in aplasic anaemia.

Drugs producing agranulocytosis :

1. Chloramphenicol 2. Sulphonamides 3. Chlorpropamide 4. Chlorpromazine 5. Propylthiouracil 6. Cytotoxic drugs 7. Oxyphenbutazone 8. Phenytoin 9. Carbimazole.

Identification points for ***CML :***

1. Usually an adult person without any suggestive facies.
2. Huge splenomegaly (usually feels hard).
3. Fever (neither double quotidian like kala-azar nor associated with chill and rigor like malaria).
4. Presence of sternal tenderness.
5. Absence of hepato-cellular failure, no jaundice, no lymphadenopathy.
6. Mild anaemia.

Case 25

LYMPHOMA

What is your diagnosis ?

The diagnosis may be told in one of the two ways :

1. It is a case of lymphoma, probably Hodgkin's disease, or
2. It is a patient of generalised lymphadenopathy (for discussion).

Why do you say so ?

This is a patient of lymphoma because of the following :

1. There is presence of fever, malaise, fatiguability, night sweats, loss of body weight and pruritus for last 6 months.
2. Gradual painless swelling of lymph nodes on both sides of the neck, right axilla and both inguinal regions for last 4 months.
3. On examination there are presence of,
   a) Anaemia (moderate).
   b) Lymph node enlargement—Cervical, axillary and inguinal nodes are enlarged. The lymph nodes are discrete (not matted), non-tender, rubbery in feel, neither fixed to deeper structures nor to the overlying skin, and without any sinus formation. Local temperature over the lymph nodes are not raised.
   c) Spleen—Moderately enlarged and non-tender.
   d) Liver—Moderately enlarged and non-tender.
   e) Absence of features of superior mediastinal syndrome, bone pain, paraplegia, intestinal obstruction, lump in the abdomen, ascites, pleural effusion at present.
   f) Absence of sternal tenderness.

Can you specify the type of lymphoma ?

No. Final diagnosis can be given after biopsy of the lymph nodes but the clinical features in this patient suggest that probably it is a case of Hodgkin's disease (see the differentiation between two types).

What is lymphoma?

These are heterogenous group of malignant diseases of lymphoreticular origin (previously, known as reticulosis). The major types are Hodgkin's disease (HD) and non-Hodgkin's lymphoma (NHL).

B-symptoms of lymphoma :

1. Presence of fever above 38°C,
2. Drenching night sweats, and
3. Unexplained loss of more than 10% of body weight within the previous 6 months.

N.B. : 'A' indicates absence of these symptoms. B-symptoms indicate bad prognosis too.

Describe the different patterns of fever in lymphoma :

1. Usually it is a low grade fever unaccompanied by chill and rigor. The fever may be remittent in type like tuberculosis or continued in type resembling enteric fever.
2. Occasionally it is a swinging fever (with ups and downs).
3. Classical 'Pel-Ebstein' fever (10% cases of Hodgkin's disease) is not seen now-a-days. It is a cyclical fever where several days or weeks of fever alternates with afebrile period.

* Pel-Ebstein fever is also noted in brucellosis and hypernephroma.

How to examine the lymphoreticular system ?

This system should be **examined first** in lymphoma. Follow the 'Scheme of examination' in 'Lymphoreticular system'. Ophthalmoscopic examination, though essential, is not in the curriculum of undergraduate students; only mention the heading and write 'not done.'

Method of lymph nodes examination :

Normal adults have approximately 400-450 lymph nodes. In health, usually the lymph nodes are not palpable (inguinal nodes are sometimes palpable) unless it is enlarged. Nodes are palpated symmetrically on **both sides** of the body from above downwards.

(A) LYMPH NODES IN THE NECK—

Mothod—These lymph nodes are **always palpated from 'behind'** when the patient is sitting or standing with the head bending forward (to relax the muscles in the anterior part of neck).

a) The upper circular group is palpated symmetrically by both hands (using right hand for right side and left hand for left side) in the following order from front to back :
   (i) Submental,
   (ii) Submandibular (under the jaw near the angle),
   (iii) Tonsillar.
   (iv) Preauricular,

(v) Postauricular, and

(vi) Occipital gland (e.g., sclap infection, pediculosis capitis, rubella).

N. B.: —if one side of the neck is palpated at a time, the neck should be flexed to that side.

b) Lower horizontal or supraclavicular group of lymph nodes—These are divided into medial, intermediate and lateral groups. Special attention should be paid in palpating left-sided medial group of nodes **(Virchow's)** and **scalene nodes** (present above and behind the head of clavicles, deep to sternomastoids on both sides of neck).

c) The vertical chain in the middle of the neck—The glands in the (i) anterior triangle, arid (ii) posterior triangle are palpated (the triangles are divided by the ipsilateral sternomastoid muscle).

* For palpation of **scalene nodes,** standing behind the sitting patient ask him to shrug his shoulder, and then dip down the palpating index finger behind the clavicle through the clavicular origin of sternomastoid with the patient's neck slightly flexed to that side. Scalene nodes lie in a pad of fat on the surface of scalenus anterior muscle. These nodes are enlarged in bronchogenic carcinoma.

** Few clinicians prefer that glands in the posterior triangle, postauricular and occipital group of nodes are better palpated from front. Occipital nodes are present in the apex of the posterior cervical triangle.

(B) AXILLARY LYMPH NODES—

There are 5 groups. The patient sits on a stool and the examiner sits in front of the patient (only the subscapular group is palpated from behind).

a) Central group—The left side is palpated by right hand and vice versa for the right side. The patient's arm is abducted and the hand of the examiner is placed in the axilla in such a way that the palm is directed towards the chest. Now the arm is adducted and allowed to rest 'comfortably' (complete relaxation of muscles is necessary) on the examiner's forearm. The other hand of the examiner is placed on the patient's same shoulder. The central group is palpated by sliding the fingers upwards to reach the highest limit of axilla.

b) Apical group—The same method as described above is applied here but the fingers are pushed as high as possible.

c) Pectoral (anterior) group—These glands are situated under the anterior axillary fold. For the left axila, the fingers of right hand are insinuated under the pectoralis major and vice versa for the right axilla. The nodes are palpated with the help of the thumb and fingers.

d) Brachial (lateral) group—Here the left hand is used for the left side and the right hand for the right side. This group of nodes are palpated against the upper part of the humerus when the examiner's palm directs laterally.

e) Subscapular (posterior) group—This group lies on the posterior axillary fold. It is palpated from behind when the hand insinuates within the latissimus dorsi, keeping the patient's arm horizontally forward (during palpation examiner's palm looks backwards).

N.B. : Relaxation of muscles is a must during palpation of all the groups of axillary nodes. After examination of one axilla, start examining the other side.

(C) EPITROCHLEAR LYMPH NODES—Make the elbow slightly llexed and forearm supinated. The epitrochlear group of nodes are palpated under the thumb if the patient's left elbow is grasped by the examiner's left hand and vice versa for the right. It is better to fix the patient's forearm at the wrist by the examiner's opposite hand. The glands are palpated in the anterio-medial region of the lower part of arm (in between the groove of biceps and brachialis muscle) adjacent to the elbow. Both the sides should be examined. Palpable epitrochlear nodes almost always indicate some pathology.

(D) INGUINAL LYMPH NODES—This group is commonly enlarged and specially palpable in bare-footed persons due to repeated trauma and infections of the lower limbs. Horizontal chain lies below inguinal ligament and vertical chain lies along saphenous vein. Both the sides are palpated one after another in supine position after extending the thighs.

(E) POPLITEAL GROUP OF LYMPH NODES—The patient lies in supine position with semiflexed legs. The popliteal fossa is felt with the fingertips of either hand, when the fingers of both hands being curled into the popliteal fossa and both thumbs rest on tibial tuberosity.

(F) MEDIASTINAL GROUP OF LYMPH NODES—It is not possible to physically examine this group of nodes. Their presence can be detected indirectly by percussion of the sternum (read the section on 'Percussion of the sternum or base of the heart'). This group comprises of para tracheal, subcarinal, tracheobronchial and hilar lymph nodes.

(G) ABDOMINAL LYMPH NODES (pre- and para-aortic, retroperitoneal)—This group, if enlarged will present as lump in the abdomen, or felt as nodular discrete or matted mass (read the section cn Abdominal lump').

* Local examination is incomplete without the examination of the lymph nodes draining the affected area.
** Rudolf Virchow (1821-1902) was a German physiologist, and anatomist of Wurzburg and Berlin.

Description of a lymph node enlargement :

In lymphadenopathy, points to be noted are :

1. Position or anatomical region affected (situation and extent).
2. Number and size.
3. Discrete or matted (margin).
4. Tenderness.
5. Consistency (texture)—Soft (cold abscess), rubbery and elastic (Hodgkin's disease), firm and shotty (syphilis), hard (malignancy).
6. Surface.
7. Mobility—Fixity to skin and surrounding structures (muscles, vessels, nerves or with any viscus) should be examined, i.e., flexed or mobile.
8. Rise of local temperature.
9. Skin changes [sinus, peau d'orange (orange skin appearance) or any sign of inflammation],
10. Lymphangitis (red, linear, tender lymph vessels radiating proximally)—present or not.
11. Draining area (e.g., in epitrochlear lymphadenopathy, examine the hand)—it is a must.

* Matted (means periadenitis) nodes are ***most commonly found in tuberculosis,*** and rarely in chronic lymphadenitis and NHL.

Common causes of cervical lymphadenopathy :

1. Infection (tonsillitis or impacted wisdom tooth), malignancy or ulcer in the oral cavity.
2. Infection in the ear, eye and nose.
3. Scalp infection by louse, dandruff.

* These are common causes of cervical adenopathy which are very often missed.

4. Lymphoma.
5. Lymphatic leukaemia (acute and chronic).
6. Miliary tuberculosis.
7. Metastasis in lymph nodes (from head, neck, breast, thyroid, stomach and lung malignancy).
8. Infectious mononucleosis, cytomeglovirus infection, HIV infection.
9. Sarcoidosis.
10. Rubella infection (postauricular and occipital nodes mainly).

** '***Bull-neck***' — This is classically seen in malignant diphtheria where the spat e between the mandible and the clavicles bulges with enlarged lymph nodes and oedema.

Causes of axillary and epitrochlear lymphadenopathy :

(A) Axillary adenopathy —

1. Breast carcinoma.
2. Infections of the upper extremity.
3. Lymphoma, melanoma.
4. ALL or CLL.
5. Tuberculosis.
6. Brucellosis.
7. Cat-scratch disease.

(B) Epitrochlear adenopathy —

1, Hand infections.
2. Lymphoma (specially NHL)
3. ALL or CLL.
4. Sarcoidosis.
5. Cat-scratch disease.
6. Tularaemia.
7. Secondary syphilis.

Causes of inguinal lymphadenopathy :

1. Infection, injury or cellulitis of lower limb.
2. Filariasis.
3. Syphilis, tuberculosis, plague.
4. Metastasis from genital malignancy, carcinoma of uterus and rectum.
5. Chancroid, lymphogranuloma venereum (bilateral inguinal 'bubo').
6. Acute lymphoblastic or chronic lymphocytic leukaemia i.e., ALL or CLL.
7. Lymphoma,

Mediastinal, abdominal. auricular and occipital lymphadenopathy :

(A) Medistinal and hilar adenopathy—

1. Metastasis from bronchogenic carcinoma, breast, stomach, pancreas, colon.

2. Lymphoma (commonly Hodgkin's variety).
3. Sarcoidosis (hilar glands 1).
4. Tuberculosis (rare) and fungal disease of lung (rare).

(B) Abdominal and retroperitoneal adenopathy—
1. Lymphoma.
2. Carcinoma of stomach, pancreas, colon.
3. Intestinal tuberculosis.

(C) Auricular adenopathy—
a) Preauricular : Conjunctivitis, rodent ulcer, primary oral chancre, herpes zoster ophthalmicus.
b) Postauricular : leprosy, rubella.

(D) Occipital adenopathy—Scalp infection, rubella, secondary syphilis.

What is *Virchow's node (or sentinel* ***node ! Ewald's node)*** ?

These are medial group of left-sided supraclavicular lymph nodes which lie in between two heads of stemomastoid muscle. They receive lymphatics from,

1. Upper limb (left),
2. Breast (left),
3. Lung (left),
4. Stomach (Troisier's sign), and
5. Testes.

Clinical method for palpation :

Stand behind the patient. Put your right hand over the right side of patient's face and ask him to turn the face to right against your resistance. Two heads of left stemomastoid become prominent and now put your left index finger in between the two heads.

N.B. : Bronchogenic carcinoma commonly produces scalene node enlargement. Supraclavicular nodes (e.g., Virchow's node) are important in relation to malignancy of lung, breast, G. I. tract and genitals.

* **Breast** should be examined for symmetiy, ulcers, redness, peau d'orange appearance, dimpling of skin and nipple discharge. Palpate all the quadrants with flat of the hand, and lastly examine the axillary and cervical lymph nodes.

When the enlarged nodes are ***of pathological significance*** ?

It is said that lymph nodes are pathologically significant when they are,

1. (Usually) greater than 1 cm in diameter,
2. Firm in consistency,
3. Round in shape,
4. Matted (nodes become adherent), and
5. Tender on palpation.

However, in assessing the significance of enlarged lymph nodes, following factors should always be considered like a) age of the patient, b) the physical characteristics of the nodes, c) anatomical sites involved, and d) the clinical setting.

* Inguinal lymph nodes > 2 cm in size may be considered as 'significant'.

Lymph *nodes fixed to* ***surrounding structures :***

1. Metastases in the lymph nodes (i.e.. malignancy).
2. Tuberculosis.

Painful and tender lymph ***nodes :***

1. Pyogenic infections, diphtheria, infectious mononucleosis, fungal infections.
2. Metastases in the lymph nodes (may or may not be tender).

Lymphadenopathy with sinus formation :

1. Tuberculous lymphadenitis.
2. Actinomycosis.

What is Waldeyer's ring ?

It is the ring of lymphoid tissue within the oral, cavity and is composed of,

1. Adenoids,
2. Faucal tonsils, and
3. Lingual tonsils.

What is generalised lymphadenopathy ?

Lymphadenopathy is defined as inflammatory or non-inflammatory enlargement of lymph nodes. 'Generalised lymphadenopathy' is characterised by the involvement of three or more non-contlguous lymph node areas: for example, when the right axilla and both sides of the neck (contiguous affection) are Involved, it is not designated as generalised lymphadenopathy. The present case on discussion has involvement of neck, axillary and inguinal lymph nodes, and thus It Is a case of generalised lymph-adenopathy.

When a single anatomical area is involved, it Is known as 'localised (regional) lymphadenopathy'.

* Each side of neck is considered as single lymph node area.

Description of lymph node enlargement in lymphoma :

(A) HODGKIN'S DISEASE (HD)—Cervical nodes are Initially affected. Other nodes are involved In course of time and rarely, abdominal and Inguinal nodes are involved.

Description—Enlarged, non-tender with *India-rubbery feel,* smooth surface, not fixed to skin or deeper structures, discrete, no sinus or no rise of temperature in the overlying skin, and there is no softening or any suppuration.

(B) NON-HODGKIN'S LYMPHOMA (NHL}—Enlargement of lymph nodes may affect any area initially. There is more chance of involvement of epitrochlear nodes and Waldeyer's ling.

Description—Enlarged, non-lender (rarely tender) with *firm or variegated feel,* smooth or nodular surface, may fix to deeper structures, discrete, without any sinus in the overlying skin, sometimes with elevated local skin temperature; and there is neither softening nor any suppuration.

* Thomas Hodgkin (1798-1866) was the curator of the museum of Guy's Hospital, London, UK.

Table 18 : Clinical differentiation between HD and NHL

	Feature	Hodgkin's disease	Non-Hodgkin's lymphoma
].	Frequency	Less common (30%)	More common (70%)
2.	Age	Bimodal peaks seen; larger peak between 15-35 yrs and smaller peak over 50 yrs	Any age; more frequent with increasing age
3.	B-svmptoms	Early and prominent	Late and non-prominent (only in 20% cases)
4.	Anaemia	Late	Early
5.	Dissemination	Unifocal in origin; well localised at diagnosis	Multicentric in origin; widespread at diagnosis
6,	Lymph node involvement:		
	a! Presentation	90% nodal and 10% extranodal	60% nodal and 40% extranodal
	b) Size	Smaller	Larger
	c) Rate of growth	Slow	Fast
	d) Consistency	Rubbery elastic	Variegated or firm
	e) Matting	Rare	May be seen
	f) Local temperature	Normal	May be raised
	g) Tenderness	Absent	May be present
	h) T Epitrochlear nodes	Less common	Common
	i) t Waldeyer's ring	Less common	Common
	j) t Mediastinal lymph node	More common	Less common
	k) T Abdominal lymph nodes	Early involvement of paraaortic nodes	Early involvement of mesenteric nodes
7.	Pruritus	Common	Less common
8.	Splenomegaly	More common	common
9.	G.I. tract involvement	Uncommon	Common
10.	CNS involvement	Uncommon	Common
11.	Bone marrow involvement	Late	Early
*12	Alcohol test	Common	Uncommon

* After Intake of alcohol, there may be pain In the area of nodal involvement.

** In HD, the disease spreads by contiguity and in NHL, it is non-contiguous (haematogenous) spread.

Pathological classification of lymphoma :

(A) HODGKIN'S DISEASE (WHO pathological classification, which is a minor modification of previous Rye classification) :

- Nodular lymphocyte-predominant HD (5%; slowly growing, localised, rarely fatal)
- Clasical HD
  - □ Nodular sclerosis HD (70%)
  - □ Mixed cellularily HD (20%)
  - □ Lymphocyte-rich HD (5%)
  - □ Lymphocyle-depleted HD (rare)

* The prognosis of a), b), c) and d) are respectively a) very good, b) good, c) fair, and d) poor.

** Nodular sclerosis variety is most commonly encountered, followed by mixed cellularity, lymphocyte-rich and lymphocyte-depleted type.

(B) NON-HODGKIN'S LYMPHOMA (Rappaport s classification.) :

a) Nodular—
   (i) Lymphocytic : poorly differentiated
   (ii) Mixed: lymphocytic and 'histiocytic'
   (iii) 'Histiocytic'

b) Diffuse—
   li) Lymphocytic : well differentiated and poorly differentiated
   (ii) Mixed: lymphocytic and 'histiocytic'
   (iii) 'Histiocytic'
   (iv) Lymphoblastic
   (v) Undifferentiated: Burkitt's and non-Burkitt's lymphoma

N.B. : Lukes and Collins made the most modem classification of NHL according to cytologic types**—** T cell, B cell, U cell, histiocytic. NHL in 1982 was classified into high-grade, intermediate-grade and low-grade lymphoma (International Working Formulation). Nodular lymphomas are mainly of low-grade (prognostically better) and diffuse lymphomas are mostly of high-grade (prognosiically worse).

*** REAL (Revised European-American Lymphoma), a new pathologic classification of NHL, was introduced in 1984, and the new entries over International Working Formulation are mucosa-associated lymphoid tumours (MALT), mantle cell lymphoma and anaplastic large cell lymphoma (Ki-1 lymphoma).

****The classification of NHL is most controversial and has been changed 6 times in past 40 years, like—

1. Rappaport's classification (1966)
2. Lukes and Collins classification (1972)
3. Kiel's classification (1981)
4. International Working Formulation (1982)
5. REAL classification (1984)
6. WHO classification (2001)—most accepted worldwise (based on precursor B, mature B, precursor T and mature T/NK cell)

Describe the spleen in lymphoma :

Spleen has no afferent lymphatics and its involvement indicates vascular invasion even in an apparently localised disease. In 30% patients with normal spleen, Hodgkin's disease was found in the spleen removed at surgery. Again, it is said that splenomegaly does not always indicate involvement by Hodgkin's disease (25% patients with splenomegaly have only reactive hyperplasia). As a whole, spleen is enlarged in 45% patients of Hodgkin's disease. It is of moderate enlargement, firm to hard in consistency, non-tender and at times with irregulai surface (previously known as 'hard bake spleen').

In NHL, spleen is often enlarged at the onset of the disease and subsequently may show marked enlargement with leatures ot hypersplenism. *Splenomegaly in NHL usually indicates splenic involvement.* The description *ot* palpable spleen is more or less same in both HD and NHL. Spleen is less commonly involved in NHL than in HD.

Clinical staging (Ann Arbor classification) of your case :

In stage IIIB (as both sides of diaphragm are involved with systemic symptoms).

Ann Arbor staging classification of lymphoma (specially Hodgkin's disease) :

Stage I—Involvement of a single lymph node region (I) or of a single extralymphatic organ or site (IE).

Stage II—Involvement of two or more lymph node regions **on the same side of the diaphragm** (II), or localised affection of an extralymphatic organ or site and of one or more lymph node regions on the same side (above or below) of diaphragm (IIE).

Scage III—Involvement of lymph node regions **on both sides of the diaphragm** (III), which may also be associated with splenic involvement (IIIS) or by localised involvement of an extralymphatic organ or site (HIE) or both (IIISE).

Stage IV—Diffuse or disseminated involvement of one or more extralymphatic organs or tissues, with or without associated lymph node involvement (e.g., involvement of ***extralymphatic organ or site*** like lung, liver, pleura, bone, bone marrow, skin and subcutaneous tissue).

N.B. : All the four stages are associated with A or B-symptoms. The ***lymphatic structures*** are lymph nodes, spleen, Waldeyer's ring, thymus, Peyer's patches and appendix. Recently few modifications of this classification has been done (Cotswolds modification). A' (no symptoms) and 'B' (presence of fever, drenching night sweats and weight loss) are added accordingly.

Importance of staging in lymphoma :

Staging is important to establish the extent of the disease and to plan for therapeutic approach. There are two types of staging (i.e., extent of the disease)—clinical stage and pathologic stage. The **clinical** stage (Ann Arbor staging classification) is based on physical examination and different noninvasive tests. The pathologic stage is determined by the informations obtained from invasive tests which include the collection of biopsy specimens from different sites (usually during a staging laparotomy). As NHL frequently disseminate haematogenously and becomes widespread at the time of diagnosis, Ann Arbor staging system has little impact on this variety of lymphoma. One should never forget that the treatment and prognosis in HD depend largely on stage of the disease, whereas In NHL the therapy Is usually based on its histological type.

Staging evaluation for NHL is done by :

« Physical examination
a Presence of B-symptoms
® Laboratory tests (CBC, LFT, uric acid, LDH, p_2-microglobulin)

- Chest X-ray
- CT scan (abdomen, pelvis, chest)
- Bone marrow biopsy
- Lumbar puncture

Confirmation : HD or NHL ?

It is done by biopsy of the lymph nodes. Presence of Reed-Sternberg (R-S) cells confirms the diagnosis of Hodgkin's disease (absence of R-S cells does not exclude Hodgkin's disease).

How to diagnose Reed-Sternberg (R-S) cell or Dorothy Reed cell ?

(A) Features of R-S cell (a giant cell which looks like owi's eye) :

1. Large giant cell with abundance of acidophilic cytoplasm.
2. Mirror image nuclei with vesicular pattern.
3. Chromatin is loosely wooven.
4. Multiple nucleoli with perinuclear halo.
5. On immunophenotyping, they are usually CD 15+ and CD 30+.

(B) R-S cells or cells simulating R-S cells are found in:

1. Hodgkin's disease (hallmark of diagnosis) 2. Infectious mononucleosis 3. Breast carcinoma 4. Burkitt's lymphoma 5. Mycosis fungoides 6. Malignant melanoma.

Importance of examination of other systems in lymphoma :

RESPIRATORY SYSTEM—Pleural effusion (often bilateral), collapse of the lung due to mediastinal lymphadenopathy. Always perform the 'mediastinal percussion' and look for the features of superior mediastinal syndrome.

2. CVS—Pericardial effusion.
3. NERVOUS SYSTEM—Cranial nerves involvement, paraplegia, LMN type facial palsy.

G.I. TRACT—Other than hepatosplenomegaly there may be lump abdomen (lymph node lump), jaundice, ascites or signs of intestinal obstruction.

5. BONES—Diffuse bone pain; swelling of bones.

6. SKIN—Skin lesions of lymphoma (lymphoma cutis), signs of generalised pruritus, herpes zoster, erythroderma etc.
7. GENITOURINARY SYSTEM—Haematuria, renal lump, hydronephrosis; occlusion of renal vein may produce nephrotic syndrome; renal failure from ureteric obstruction; testicular mass.

Drugs producing lymphadenopathy (pseudolymphoma) :

1. Phenytoin 2. Cyclosporin A (used in organ transplantation) 3. Carbamazepine 4. Cephaloridine 5. PAS (used in multi-drug resistant tuberculosis) 6. Primidone 7. Hydralazine 8. Allopurinol.

Anaemia in lymphoma :

1. Ineffective erythropoiesis.
2. Haemodilution.
3. Haemolysis (rare).
4. Hypersplenism.

How paraplegia is produced in lymphoma ?

Involvement of thoracic vertebrae is common. It may be produced by :

1. Involvement of body of the vertebra with collapse.
2. Invasion of the epidural space from retroperitoneal lymph nodes with cord compression.
3. Jeopardized vascular supply of the spinal cord.

Jaundice in lymphoma :

1. Hepatic involvement.
2. Hepatitis due to repeated blood transfusion (type B or C).
3. Extrahepatic biliary obstruction (lymph nodes pressing porta hepatis).
4. Haemolysis (autoimmune and rare).

Symptoms relating to G.I. tract :

These symptoms are common in NHL variety. Symptoms may be,

1. Anorexia.
2. Nausea, vomiting.
3. Haematemesis and melaena.
4. Diarrhoea (malabsorption syndrome).
5. Swelling of the abdomen (lump abdomen formed due to adenopathy, or presence of ascites).

Is it possible to have lymphoma without lymphadenopathy ?

Yes, it is possible in abdominal lymphoma.

Possible associations of 'night sweats' in clinical medicine :

1. Tuberculosis.
2. Lymphoma.
3. Chronic myeloid leukaemia.
4. Giant ceil arteritis.
5. Brucellosis.
6. AIDS.
7. Amoebic liver abscess.
8. Nocturnal (sleeping) hypoglycaemia.

* ***Excessive sweating*** is characteristic of hypoglycaemia (drenching sweat), acute myocardial infarction (drenching sweat), thyrotoxicosis, acromegaly, pheochromocytoma (paroxysmal), arecholine sensitivity (present in betel nut) and gustatory hyperhidrosis (autonomic neuropathy).

History with special findings in lymphadenopathy pointing towards a disease :

- fever lymphoma, tuberculosis, ALL, SLE, infectious mononucleosis, AIDS.
- Petechial haemorrhage in palate in a young boy with cervical adenopathy—infectious mononucleosis.
- Hard lump in breast associated with ipsilateral axillary' adenopathy—breast carcinoma.
- Swelling of feet/legs, non pitting or solid oedema along with inguinal adenopathy—filariasis.
- fever, weight loss, loss of appetite ± night sweats associated with adenopathy—tuberculosis, lymphoma, malignancy, AIDS, At.I.
- Prolonged medication-induced lymphadenopathy—commonly phenytoin-induced (search for gum hypertrophy and acne).
- Lymphadenopathy with skin lesion—SLE (butterfly-rash in face), sarcoidosis (lupus pemo in face), secondary syphilis, amyloidosis.

Causes of generalised lymphadenopathy :

Lymphadenopathy may be an incidental finding. Majority of generalised lymphadenopathy are non-malignant in nature. The causes are :

1. Lymphoma (HD and NHL).
2. Acute lymphoblastic leukaemia.
3. Chronic lymphatic leukaemia.
4. Disseminated or miliary tuberculosis.
5. Secondary' metastasis to lymph nodes.
6. Secondary syphilis.
7. Infectious mononucleosis.
8. Collagen vascular disease, e.g., SLE
9. Sarcoidosis.
10. Filariasis.
11. Chronic lymphadenitis.
12. HIV infection (AIDS).
13. Amyloidosis.
14. Drug-induced.

* Brucellosis, blast crisis in CML and Still's disease may give rise to generalised lymphadenopathy.

** Dermatopathic lymphadenopathy—generalised lymphadenopathy from psoriasis or eczema evolving as a reactive process.

Differential diagnosis oj generalised lymphadenopathy :

(A) LYMPHOMA—

1. Any age.
2. Usually cervical group is Involved first.
3. SVC obstruction.
4. Fever, night sweats, loss of weight.
5. Hepatosplenomegaly.
6. Pleural effusion (often bilateral) or ascites.
7. Discrete, rubbery or firm, non-tender lymphadenopathy.

(B) ACUTE LYMPHOBLASTIC LEUKAEMIA (ALL)—

1. Children or young adults.
2. Fever may be very high.
3. Descrete, non-tender adenopathy.
4. Moderate splenomegaly with hepatomegaly; severe anaemia.
5. Very short course of disease.
6. Haemorrhagie manifestations (purpura, gum bleeding, epistaxis), mouth ulcers, sore throat.
7. Presence of sternal tenderness.

(C) CHRONIC LYMPHOCYTIC LEUKAEMIA (CLL) —

1. Over the age of 45 years (peak 65 years) and M>F; insidious onset.
2. Firm, discrete, painless generalised lymphadenopathy.
3. Moderate splenomegaly with hepatomegaly.
4. Gradual onset of weakness, slowly developing pallor and presence of irregular fever.
5. Haemorrhagie manifestations into the skin in late stages.
6. Increased frequency of infections.
7. Absence of sternal tenderness.

(D) DISSEMINATED OR MILIAR Y TUBERCULOSIS —

1) Children or young adults.
2) High rise of temperature with drenching sweats, loss of weight, progressive anaemia, cough and rarely breathlessness.
3) Glands are palpabie, matted (means periadenitis), usually painless but may be painful, firm, without any rise of local temperature: rarely there may be a sinus present in the skin with formation of cold abscess underneath. Hard and craggy nodes are found in healed and calcified tuberculosis. Upper deep cervical group of nodes are commonly affected.
4. Paucity of signs in the chest (miliary). Often few crepitations are heard late in the disease.
5. Mild hepatomegaly with mild, tender splenomegaly.

* 6. Choroidal tubercles may be seen (25%) in the retina by ophthalmoscopy (miliary).

7. Mantoux test may be negative, miliary mottlings may be seen in chest X-ray, and caseating granuloma in lymph node biopsy may be found.

* Choroidal tubercles are yellowish and slightly shiny lesions with a diameter of < ! / . th of optic disc.

(El SECONDARY *METASTASIS IN THE LYMPH NODES—*

1. Middle or old age commonly.
2. Lymph nodes are stony hard or craggy, fixed, non-tender; generally localised, rarely generalised.

3. H/O haemoptysis, melaena, sore throat, breast lump etc.
4. Anaemia with emaciation (cachexia).
5. Presence of primary source like carcinoma of head, neck, thyroid, lung, breast or stomach.

* Though initially non-tender, pain and tenderness of variable intensity may appear lately.

(F) SECONDARY SYPHILIS—

1. Usually in young adults.
2. Past H/O exposure and primary syphilis (e.g., genital ulcers).
3. Moderately enlarged, discrete, *firm and shotty*, painless and non-tender adenopathy. Though the distribution is generalised, there is predilection for affection of occipital and epitrochlear nodes.
4. Skin rash, condylomata lata and snail track ulcers (mucous patches) in mouth may be seen.

N.B. : Secondary syphilis is not commonly seen now-a-day? because of the early use of antibiotics in the treatment of 'chancre'. There may be hepatosplenomegaly.

(G) INFECTIOUS MONONUCLEOSIS—

1. Children or young adults.
2. Adenitis is mostly cervical (posterior cervical group), may be generalised. Glands are palpable, a bit tender with moderate enlargement.
3. Fever of short duration, malaise, headache, sore throat may be present.
4. Acute onset with a maculopapular rash (like drug rash).
5. Petechial haemorrhages may be seen at the junction of the hard and soft palate.
6. Spleen is often palpable.
7. Atypical lymphocytes in peripheral blood. Positive Paul-Bunnell and and Monospot tests.

(H) SYSTEMIC LUPUS ERYTHEMATOSUS (SLE)—

1. Young or middle-aged female patients.
2. Present with arthralgia, arthritis, PIJO, myalgia, butterfly-rash in face, oral ulcers or oliguria.
3. Moderate splenomegaly with hepatomegaly.
4. Non-tender, discrete adenopathy.
5. Pleurisy, pleural effusion, pericarditis or renal failure may develop.

(II SARCOIDOSIS—

1. Usually in children or young adults.
2. Generalised adenopathy with frequent involvement of pre- and postauricular, submandibular, epitrochlear and paratracheal nodes.
3. Mild splenomegaly.
4. Classical skin lesions (lupus pernio), uveitis or parotid swelling may be seen. Patient may have cough, dyspnoea, fatigue or presence of erythema nodosum.
5. Bilateral hilar adenopathy in chest X-ray, positive Kveim test, elevated serum angiotensin-converting enzyme (SACE) and negative Mantoux test are characteristic features.

(J) FILARIAS1S—

1. Any age.
2. Fever with chill and rigor intially with every full moon and new moon. There may be pain felt in the scrotum, breast, vulva, or erythematous and painful cord like swelling in the limbs. Spermatic cord may be thick and tender. Non-pitting oedema of legs with peau d'orange appearance of the skin may be seen.
3. In the chronic stage *elephantiasis* (lymphoedema as well as increased thickness of skin) of scrotum, vulva or legs with pleural effusion (chylous), ascites (chylous) and chyluria may develop.
4. Discrete, non-tender palpable lymph nodes in the inguinal region; may be generalised.

* Peau d'orange appearance and lymphoedema are often associated with filariasis and malignancy.

(K) CHRONIC LYMPHADENITIS—

1. Common in cervical and inguinal lymph nodes.
2. Primary focus is usually present in the oral cavity, scalp, genitalia or in the neighbourhood of the affected glands.
3. Moderately enlarged, firm, mildfy tender (rarely matted).
4. There may be rise of body temperature.

(L) HIV INFECTION (AIDS)—

1. Any age; young adults commonly.
2. H/O homosexuality, promiscuous sex or receiving blood transfusion.
3. Patient may present with infectious mononucleosis-like illness with pyrexia, rash and lymphadenopathy.

4. A subgroup of patients with asymptomatic infection may present with ***persistent generalised lymphadenopathy (PGL)*** or AIDS-related complex (ARC). Patient with ARC may have chronic diarrhoea, night sweats, fever, weight loss and oral candidosis. PGL is defined as the presence of enlarged lymph nodes (>lcm) in two or more extrainguinal non-contiguous sites for more than 3 months. Lymphadenopathy in AIDS may be due to diseases like tuberculosis or lymphoma.
5. Rapid downhill course.
6. Biopsy of the lymph nodes show reactive hyperplasia.
7. ELISA test for HIV antibody (screening test) and Western Blot test to identify antibodies to specific viral protein (confirmatory test) are positive.

(M) AMYLOIDOSIS—Read the section on 'Hepatosplenomegaly'.

(N) DRUG-INDUCED—See page 230; also known as pseudolymphoma.

How do you like to investigate a case of lymphoma?

1. Blood examination—
   a) Anaemia (normocytic normochromic).
   b) Leukaemoid reaction may be seen (common in Hodgkin's disease).
   c) Mild eosinophilia (10-15% cases) in Hodgkin's disease.
   d) Lymphocytopenia (bears a bad prognosis)
   e) High ESR (indicates disease activity).
2. Lymph node biopsy—
   a) FNAC (fine needle aspiration cytology)—Often not informative. CT-guided biopsy (FNAC) may be performed in abdominal lymphoma. For FNAC, preferred items are : cervical area (inguinal area avoided), discrete node with the largest gland available.
   b) **Excision (open) biopsy**—'Most important' investigation. **It gives the accurate diagnosis** and helps in evaluation of prognosis (R S cells are hallmark of Hodgkin's disease).
3. Chest X-ray—May show mediastinal widening (HD mainly), pleural effusion or involvement of lung.
4. Ultrasonography or CT scan of abdomen, chest and pelvis—CT scan is the investigation of choice for staging although PET scan is increasingly being used.
5. Pleural aspiration, paracentesis abdominis or lumbar puncture (in paraplegia).
6. Biopsy of pleura, liver or skin lesions.
7. Endoscopy of upper G.I. tract (for haematemesis and melaena) or barium meal X-ray of stomach and duodenum with follow through.
8. Bone marrow examination (aspiration or trephine biopsy)—Helps in the diagnosis and staging of the disease (bone marrow involvement indicates stage IV disease).
9. Bipedal lymphangiography will demonstrate pre- and paraaortic, or retroperitoneal lymph nodes involvement.
10. Liver function tests (may be abnormal with or without hepatic involvement).
11. Biochemical—
    a) Serum calcium or alkaline phosphatase may be elevated due to involvement of bones.
    b) Serum copper, LDH and uric acid are often increased in NHL variety.
    c) Blood surgar, urea and creatinine as a routine investigation.
12. IVP for renal involvement.
13. Skeletal survey by X-ray or Gallium scan (usually osteosclerotic lesion is seen in HD—'ivory vertebra', and osteolytic lesion in NHL variety).
14. Laparotomy (mainly for staging purpose)—rarely required.

* As high-grade NHL may be associated with AIDS, do the HIV testing. For modern classification, send the lymph node biopsy material for immunophenotyping and cytogenetic/molecular analysis.

** In leukaemia, peripheral blood smear and bone marrow examination are more important than lymph node biopsy.

How do you treat a case of lymphoma ?

(A) HODGKIN S DISEASE :

Therapeutic guidelines are,

a) Indication of radiotherapy—
   (i) Stage I, and II A with 3 or less areas of involvement.
   (ii) To lesions causing serious pressure symptoms e.g.. SVC syndrome.

b) Indication of **chemotherapy**—

(i) All patients with B-syinptoms

(ii) Stage II with > 3 areas of involvement, stage III and stage IV diseases.

Radiotherapy is used in a dose of 3600 to 4400 cGy (daily dose of 200 cGy over 4 weeks). Different modes like involved-field radiotherapy (IF), inverted Y field radiotherapy, mantle-iield radiotherapy, extended-field radiotherapy (EF) and total axial lymph node irradiation (TANI) are used.

Regimens of chemotherapy are,

1. MOPP (mustine hydrochloride, vincristine, prednisolone and procarbazine).
2. MVPP (only vinblastine replaces the vincristine of MOPP regimen).
3. ABVD (adriamycin, bleomycin, vinblastine and dacarbazine)—preferred regimen.
4. SCAB (streptozotocin, CCNU. adriamycin and bleomycin).
5. ChlVPP (chlorambucil, vinblastine, prednisolone and procarbazine)—preferred regimen.

* Combined modality (chemotherapy followed by radiotherapy) is applied in bulk disease.

(B) NON-HODGKIN'S LYMPHOMA :

Radiotherapy is usually given by involved-field treatment (IF) or total body irradiafion (stage I).

Chemotherapy is used in stages II, III, IV in high-grade NHL and in stages IIB, III, IV in low-grade NHL. Regimens of chemotherapy are,

1. Chlorambucil—as single drug oral therapy (in low-grade NHL).
2. CVP (cyclophosphamide, vincristine and prednisolone).
3 CHOP (cyclophosphamide, hydroxyadriamycin, vincristine and prednisolone).
4. BACOP (bleomycin, adriamycin, cyclophosphamide, vincristine and prednisolone).

******* R-CHOP therapy is rituximab combined with CHOP regiment. Addition of retuximab increases the complete response rates and improves overall survival.

N.B. : These drugs are given on a 28-day cycle (one pulse) fo. a total of 6-8 'pulses' in both HD and NHL. Autologous bone marrow transplantation is a new modality of treatment in NHL. Blood is transfused in severely anaemic patients.

Conclusion :

1. Palpate all the anatomical areas for lymph node enlargement.
2. In a patient with lymphadenopathy, one should be careful about examination of Waldeyer's ring, *breast, testes,* non-pitting oedema in legs, sternal tenderness, hepatosplenornegaly. ascites, pleural effusion and tenderness in spine (i.e., paraplegia in a case of lymphoma).
3. All the systems should be examined.
4. In a patient with inguinal lymphadenopathy, examine the legs and sole of (he foot for the presence of any ulcer, infection etc.

***** A **case of** lymphoma may **be given** as **superior mediastmal** syndrome.

------- O-------

BBB333I

MISCELLANEOUS

Case 28

CHRONIC KALA-AZAR

What ?*; ***your diagnosis*** ?

The diagnosis may be delivered in one of the two ways :

1. It is a case of huge (sometimes, moderate) splenomegaly with mild (to moderate) hepatomegaly and fever, probably due to chronic kala-azar, or
2. It is a patient of hepatosplenornegaly with pyrexia for discussion (if not properly diagnosed).

Why do you say so ?

This is a case of chronic kala-azar because,

1. The patient comes from an endemic zone (kala-azar is endemic in Bihar, Gangetic belt of West Bengal, along the coast of Brahmaputra in Assam, coastal Orissa and in eastern part of U.P.).
2. Intermittent rise of temperature for last 6 months which occasionally peaks twice in 24 hours.
3. Weakness, malaise, easy fatiguability with loss of body weight (6 kgs over last 6 months) for the same duration in spite of good appetite and persistent fever.
4. Massive non-tender, 'soft' to firm (often with doughy feel) splenomegaly.
5. Moderate enlargement of liver which is firm and non-tender.
6. The ratio of liver and spleen is 2 : 5 or 1 : 2*/$_2$.
7. Presence of moderate anaemia, alopecia and diffuse blackish pigmentation (forehead, perioral and temple region mainly).
8. Received 16 injections of sodium antimony gluconate so far in another city hospital (according to the patient).

Pattern of fever in kala-azar :

1. May be of any type but usually intermittent in nature.
2. To start with, it is of quotidian variety but without definite chill and rigor (mild chill may be present). Fever is usually nocturnal and without signs of toxaemia.
3. Later on, the fever may be of double quotidian (camel hump fever; 20% cases) in nature (i.e., double rise in 24 hours). This type of fever is very specific for kala-azar.
4. The fever is not very high and ranging between 101°-102°F.
5. Chronic cases may be apyrexial.
6. Though the fever is associated with tachycardia, pallor and weight loss, the patient remains ambulatory (in spite of fever).

Table 19 : Relationship of appetite with weight loss

Weight loss + appetite?	Weight loss + appetitei
1. Diabetes mellitus (uncontrolled)	1. Malignancy (advanced)
2. Thyrotoxicosis	2. Infections (tuberculosis, HIV)
3. Chronic kala-azar	3. Depression (endogenous)
4. Malabsorption syndrome	4. Anorexia nervosa
5. Worm infestation in children	5. Addison's disease
6. Pheochromocytoma	6. Chronic renal failure

* T appetite is also characteristic of hypothalamic disorder and bulimia nervosa.

Chief complaints of your patient :

1. Fever and weakness for 6 months, and
2, Heaviness in the left upper abdomen for 2 months.

Other features of chronic kala azar :

1. G. I. Tract—Diarrhoea or dysentery; rarely jaundice in late stage; gingivitis.
2. Respiratory system—Dry cough, chest pain or bronchopneumonia due to superadded infection. Haemoptysis, if complicated by pulmonary tuberculosis.
3. CVS—Palpitation.
4. Haemorrhagic manifestations—Bleeding gum or epistaxis (due to pancytopenia).
5. Skin—Cancrum oris and diffuse blackish pigmentation of the whole body.
6. Reticulo-endothelial system—May present with lymph node swelling (very rare in India).

Physical findings in ***different systems :***

1. General appearance—Dry rough pigmented skin, emaciation, moderate anaemia, scanty hair in scalp, protuberant abdomen, thin legs with occasional oedema feet.
2. G.I. tract—Hepatosplenomegaly, jaundice (in late stage).
3. Respiratory system—Occasionally crepitations are heard in the presence of secondaiy infection.
4 cvS—Tachycardia, low BP, murmur in the pulmonary area due to anaemia.
5. Haemorrhagic manifestations—Examination of gum and nose is necessary (for gum bleeding and epistaxis).

6. Skin—Increased black pigmentation (so the name kala-azar, which is Hindi version of 'black-sickness') or rarely cancrum oris (ulcerative lesion around mouth).
7. Reticulo-endothelial system—Rarely, there are presence of sternal tenderness (due to severe anaemia) and palpable lymph nodes (very rare in India, found in African form).

What is cancrum oris (noma) ?

This is a form of sloughing ulcerative gingivitis which spread to buccal mucosa, cheek, mandible or maxilla resulting in widespread destruction of bone and soft tissue. It is thought to be due to invasion of tissues by Bacteroids. Fusobacterium and other normal commensals of the mouth. The causes are,

1. Kala-azar (due to neutropenia) 2. Acute leukaemia 3. Measles 4. Enteric fever 5. Immuno-suppression.

Points in the past history you have enquired for :

1. Jaundice (as cirrhosis of liver and thalassaemia may be present with hepatosplenomegaly).
2. Repeated blood transfusions (indicates thalassaemia).
3. Haematemesis or melaena (indicates cirrhosis of liver).
4. Tuberculosis (kala-azar may be complicated by tuberculosis).
5. Swelling anywhere in neck, axilla or groin (indicates lymphoma).
6. I.V drug abuse (may give rise to prolonged fever).
7. Diabetes mellitus and hypertension as a routine enquiry.

Importance of treatment history :

Whether the patient has received any injection for 21-28 days (sodium antimony gluconate) or directly ask the patient if he knows the name of the drugs used so far. Usually a patient of chronic kala-azar is treated by too many doctors with too many drugs.

Describe the splenic enlargement :

It is just like thalassaemic spleen (read the section on Thalassaemia'). The difference is that the spleen of chronic kala-azar is 'soft' to firm in consistency and not very firm like thalassaemia. At the end of 1 month of illness, splenic enlargement is about 2-3 cm below the left costal margin and then the spleen enlarges at the rate of 1 cm per month. Spleen may be tender; in splenic infarction. [In case of acute malaria, spleen is usually palpable after second paroxysm of fever (i.e.. after 3rd day of illness) and the spleen of enteric fever is palpable after 7 days of illness. 1 The spleen of chronic kala-azar is not so firm like chronic malarial spleen.

The spleen of acute kala-azar (and acute malaria) is always soft in consistency.

Anaemia in kala-azar :

1. Hypoproteinaemia (malnutrition).
2. Bone marrow depression (due to proliferation of parasitised reticulo-endothelial cells).
3. Haemolysis (autoimmune and rare).
4. Hypersplenism (sequestration and splenic pooling).

Causes of jaundice in kala-azar (though rare) :

1. Blood transfusion causing jaundice by hepatitis B or C virus.
2. Portal hypertension with cirrhotic change in liver.

Why there is bleeding kala-azar ?

X. Before treatment : due to thrombocytopenia.

2. During treatment : with sodium stibogluconate.

How kala-azar is produced ?

I) Kala-azar is also known as visceral leishmaniasis and is caused by Leishmania donovani.

II) Incubation period averages 1-2 months, but may be several years.

III) Transmitted by—

1. Bite of female sand fly (Phlebotomus argentipes, the Indian vector).
2. Blood transfusion (very rare).
3. Rarely, inoculation of cultures of Leishmania donovani.

* The term 'leishmaniasis' encompasses multiple clinical syndromes, i.e., visceral, cutaneous and mucosal leishmaniasis.

What are the differential diagnosis ?

Discuss the differential diagnosis of moderate or huge splenomegaly as your case is. Read the section on 'Hepatosplenomegaly'.

How will you diagnose (chronic) kala-azar?

(A) INDIRECT EVIDENCES :

1. Blood examination—Low Hb with normocytic normochromic anaemia. Leucopenia (neutropenia and eosinopenia) with relative lymphocytosis and monocytosis. Agranulocytosis and thrombocytopenia may occur. *Pancytopenia is seen.* If repeated, there is progressive leucopenia.
2. Aldehyde test (Napier's}—Positive after 3 months of illness. About 1-2 ml of serum is taken and one to two drops of 40% formalin is added to it. A positive result is indicated by 'jellification of milk white opacity' within 20 minutes. This test is falsely positive in multiple myeloma and cirrhosis of liver. Positivity depends upon increase in serum gamma globulin.
3. Antimony test (Chopra's)—Positive after 6 weeks of illness (due to high IgG).
4. Complement fixation test (CFT) with WKK (Witebsky, Klingenstein and Kuhn) antigen becomes positive within 3 weeks. Now-a-days, Kedrowsky's antigen is preferred to WKK antigen.
5. Immunofluorescence test.
6. Haemagglutination test (indirect).
7. Counterimmunoelectrophoresis.
8. ELISA (enzyme-linked immunosorbent assay) test.
9. Others—Direct agglutination test (DAT) with freeze-dried antigen is simple, cheap and a quick test which can be used in the field conditions. Dot-enzyme immunoassay (EIA) and reverse Western blotting also detect antigen. DNA detection by PCR may be done. Another field-tested technique is immunochromatographic dipstick testing of fingerstick blood for antibody to recombinant Leishmanial antigens or synthetic peptides (e.g., rK 39). Detection of leishmanial antigen in urine is being evaluated.
10. Serum electrophoresis—*Hypoalbuminaemia with marked hyperglobulinaemia (IgG).*

IB) DIRECT EVIDENCES (DEFINITIVE DIAGNOSIS) :

L.D. bodies (Leishman-Donovan bodies) may be demonstrated by,

1. Preparation of buffy coat in blood—The yield is better (83%) if a thick blood film is made or a straight leucocyte edge is produced in the slide, or by using centrifuged citrated blood. The smear is stained by Giemsa's or Romanowsky's stain and examined under oil-emersion lens to see the arnastigote form of the parasite containing nucleus and kinetoplast.
2. Splenic puiscuhire or aspiration—Yield is maximum (95-98%), and *gold standard in diagnosis.*
3. Bone marrow aspiration or biopsy—Either taken from sternum or iliac crest (carefully observe for evidence of marrow puncture in your patient)—Yield is 64-85%.
4. Hepatic aspiration (yield is 75-85%).
5. Lymph node biopsy (if palpable) or FNAC—Yield is 64%.
6. Culture in NNN (Novy-MacNeal-Nicolle) medium in a cool incubator at 22°C.
7. Skin biopsy in cases of Post Kala-azar Dermal Leishmaniasis (PKDL).

N.B. : Multiplication of leishmania takes place in macrophages in the liver, spleen and bone marrow. Culture shows promastigote (flagellar) form and stained films show arnastigote (non-flagellar) form. The fully developed promastigote form looks like long slender spindle-shaped bodies while the arnastigote form is round or oval. Leishmanin skin test is not much informative (negative in acute kala-azar).

HIV patients may be infected with Leishmania donovani if ever been in leishmaniasis-endemic areas. The sensitivity of serologic tests is lower in HIV-infected patients than in non-HIV-infected patients.

What is acute kala-azar and how it is diagnosed?

Early kala-azar of 2 6 weeks duration is 'acute kala-azar'. which is diagnosed by,

1. Blood examination—Progressive leucopenia with relative lymphocytosis and monocytosis.
2. Complement fixation test (CFD.
3. Direct agglutination test (detects IgM antibody and a sensitive indicator of acute disease).
4. Counterimmunoelectrophoresis.
5. Demonstration of L.D. bodies from,
   a) Buffy coat preparation, and
   b) Bone marrow aspiration or biopsy, from sternum or iliac crest.

N.B. : *Aldehyde test is negative in acute kala-azar.*

Why splenic puncture is not advocated in acute kala-azar?

In acute kala-azar, spleen is not sufficiently enlarged to be punctured.

Complications of kala-azar?

1. Pulmonary tuberculosis or intercurrent infection (pneumococcal pneumonia) in lung.
2. Cancrum oris.
3. Pancytopenia with its consequences.
4. PKDL (post kala-azar dermal leishmaniasis)—skin lesions (macules, papules, nodules, patches) are most prominent in face that develops during or after therapy. D/D of PKDL are syphilis, leprosy and yaws.
5. Portal hypertension (10%).
6. Malabsorption syndrome, bacillary dysentery.
7. Splenic rupture (rarely).
8. Amyloidosis.
9. Measles.
10. Severe epistaxis, malnutrition, uveitis.

* Death is usually due to bacterial infection or uncontrolled bleeding.

How do you like To treat kala-azar?

1. Sodium antimony gluconate or sodium stibogluconate (pentavalent antimonial)—It is the drug of choice; 1 ml of injection contains 100 mg of the drug. The dose is 20 mg/kg in I.V (preferred) or deep I.M route as single daily dose, for minimally 28 days (maximum daily dose 850 mg). The dose may be repeated after 2-4 weeks for 40-60 days in patients with relapse or incomplete responses.
2. Meglumine antimonate (pentavalent antimonial)—50 mg/kg daily for 15 days (alternative drug).
3. For resistant cases ;
   (i) Amphotericin B (deoxycholate)—0.5-1 mg/kg, I.V by slow infusion daily or on alternate days (for 20 days). The drug is nephrotoxic.
   (ii) Pentamidine isethionate—2-4 mg/kg, three times a week for 5-25 weeks depending on the response (usually 15-30 injections are given).
4. Recent advances :
   (i) AmBisome, the lipid formulation of amphotericin B or liposomal amphotericin B may be used, I.V in resistant kala-azar in a dose of 3 mg/kg/day over a short period of time (given on days 1 to 5, and 14 to 21; may be repeated). This expensive drug takes the advantage of 'target-specific drug delivery system'.
   (ii) Miltefosine—it is a cytotoxic drug which is used in a daily dose of 2.5 mg/kg/day, orally in two divided doses for 28 days (i.e., 50 mg capsule twice daily). The drug gives excellent results in areas resistant to antimonials, specially in India (particularly in Bihar and North-East parts).
   (iii) Aminosidine (aminoglycoside paromomycin)—15-20 mg/kg, I.M for 21 days.
   (iv) Sitamaquine (an 8-aminoquinoline)—being field-tested in various regions and have a narrow therapeutic window.
   (v) Addition of allopurinol—20-30 mg/kg, dally in three divided doses with sodium antimony gluconate.
   (vi) Recombinant human interferon-y (in seriously ill patients or treatment failures) in a dose of 100 pg/m^2 body surface/day given by S.C route for 28 days along with standard dose of sodium antimony gluconate. -
   (vii) Fluconazole or ketoconazole may be used in a dose of 3 mg/kg daily.
   (viii) Adjunctive splenectomy is done in some drug-resistant kala-azar.
5. Treatment of anaemia, secondary infections in lung, pulmonary tuberculosis, intercurrent bacterial infections, bleeding manifestations and malnutrition are done accordingly.

* Urea stibamine [discovered by Dr. (Sir) Upendra Nath Brahmachari], the first drug for kala-azar, is not used now. Remember, incomplete therapy of initial illness results in relapse with drug-resistant organisms, which is a burning problem in India.

** First line drugs are pentavalent antimonials and lipid formulation of amphotericin B.

*** ***Relapse*** (reappearance after cure) : Sodium stibogluconate for 40-60 days (i.e., same dose with doubling the duration. ***Resistant*** kala-azar (no response to therapy): pentamidine isethionate, liposomal amphotericin B, miltefosine, interferon-y and ketoconazole.

Left-sided **partial ptosis** with **lateral squint** due to IIIrd cranial nerve palsy (recovering); increased **frowning of forehead** is noted to overcome the drooping of upper eyelid

Motor component of **Vth Cranial nerve paralysis resulting** in wasting of muscles of mastication, eg, temporalis (suprazygomatic portion) and masseter (infrazygomatic portion)

Angular stomatitis due to vitamin B-complex and iron deficiency in a chronic debilitated patient; excoriation and crusting of skin around nostrils are seen

Red-brown flat-topped papules or plaque-like hyperpigmented lessions over both shins in type 2 diabetes mellitus – the **diabetic dermopathy**

Cyanosis of the fingers in a patient of systemic lupus erythematosus – the **Raynaud's phenomenon;** numbness, burning and pain in the fingers are associated with

Digital infarction, painful **digital ulceration,** periungual erythema in **vasculitis** due to microscopic polyangiitis

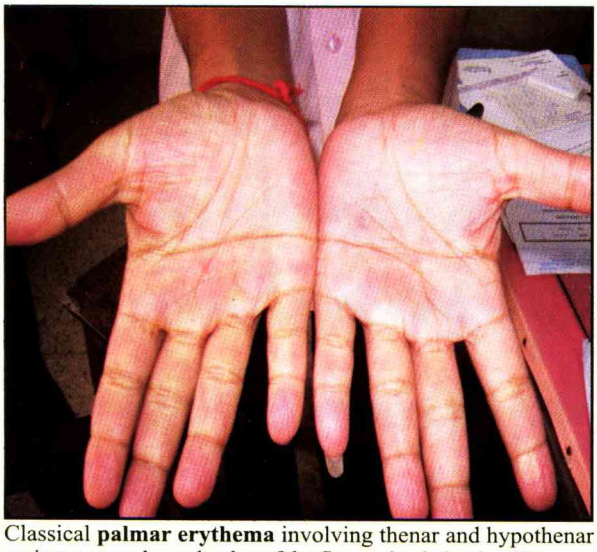

Classical **palmar erythema** involving thenar and hypothenar eminences, webs and pulps of the fingers in cirrhosis of liver

Bilateral **wrist** and **foot drop** resulting from consumption of adulterated mustard oil

Side ***effects of different drugs used in kala-azar :***

(A) Antimony preparations—nausea, vomiting, diarrhoea, arthralgia, myalgia, fever, metallic taste, hepatitis, pancreatitis, arrhythmias, Q-Tc prolongation (monitoring should include ECG) or even death; cyanosis, rapid and irregular pulse, dyspnoea and shock are known as 'Nitritoid crisis'; anaphylaxis after 6th or 7th injections.

(B) Amphotericin B—fever with chills, hypokalaemia, arrhythmias, renal toxicity, myocarditis.

(C) Pentamidine isethionate—hypoglycaemia, hypotension, tachycardia, irreversible induction of diabetes mellitus and even sudden death.

(D) Miltefosine—G. I. symptoms like vomiting and diarrhoea, reversible hepatotoxicity and nephrotoxicity. It should be used with caution in females as it is abortifacient and teratogenic in animals.

(E) Sitamaquine—Methaemoglobinaemia, nephropathy.

Assessment of progress in kala-azar :

It is assessed by, 1. Symptoms 2. Splenic size 3. Hb estimation, and 4. Serum albumin level.

Case 27

DIABETES MELLITUS

What is your diagnosis ?

This is a case of type 2 diabetes mellitus (DM) with evidences of renal involvement (K-W syndrome) and peripheral neuropathy.

What are the chief complaints?

1. Gradual swelling of the whole body for last 6 months, and more for last 2 weeks.
2. Tingling and numbness of the extremities for last 2 years.
3. Dimness of vision for last 4 years.
4. Increased volume with frequency of urine, increased thirst and appetite for last 15 years.

what is the H/O present illness?

This obese male patient aged about 55 years was normal till 15 years back. The onset of the disease was insidious and it was gradually progressive. He was admitted in this hospital 10 days back and has improved slightly with treatment.

All the symptoms regarding increased appetite, thirst and urination started 15 years back. The patient used to drink 3-4 litres of water daily. He had to wake up 3-4 times every night for urination and total urinary output per day was approximately 3.5 litres. There is absence of burning sensation during micturition at present. Though he had a good appetite, he had lost substantial body weight for the last few years. He also complained of increased fatiguability and exhaustion even while at rest.

For last 6 months (more for last two weeks), he observed gradual swelling of the whole body which started from the face. The swelling was a bit posture-dependent and pitting in nature. There was no H/O rise of temperature. For the last two weeks, the total daily urine output was approximately 1.5 litres. The patient was admitted in the hospital for these ailments.

For last four years, he had dimness of vision and after using spectacles it was not corrected much. He complained of tingling sensation of the extremities (hands and feet) with weakness of the limbs for last two years. For last fifteen years, he was on oral hypoglycaemic agents (not too regularly) prescribed by different physicians. Once he received inj. insulin for treatment of perianal abscess.

There was no H/O fever, palpitation (thyrotoxicosis), tremor (thyrotoxicosis), haemoptysis (pulmonary tuberculosis), cough (respiratory tract infection), leg pain during walking (large vessel involvement), skin lesions (diabetic dermopathy). chest pain (IHD), impotence or nocturnal diarrhoea (autonomic neuropathy), itching or any foot ulcer. He suffered from repeated attacks of burning micturition during the last fifteen years (UTI). He did not give any H/O unconsciousness (hypoglycaemia, CVA etc.).

* Add past, personal and family history as described below.

** Exclude the causes of substantial weight loss (e.g., thyrotoxicosis).

Importance of past, personal, family and treatment history :

(A) PAST HISTORY :

1. No H/O tuberculosis (as a complication of DM).

2. No H/O recurrent pain abdomen (occurs in chronic pancreatitis).
3. No other significant serious illness in the past (IHD, lower respiratory tract infection. TIA etc.).
4. All the symptoms started when he was on 40 years (type 2 DM).
5. H/O frequent boils and abscess at various parts of body; delayed wound healing.
6. H/O frequent change of refractory error in eye.

(B) PERSONAL HISTORY :

1. Married with three children (two daughters and one son)—All are well at present.
2. No addiction (non-smoker, non-alcoholic).
3. Sedentary habit; obese.

(C) FAMILY HISTORY:

1. Father was diabetic and died of IHD, 10 years back. Mother is not suffering from DM.
2. Brothers (two) and sisters (one) are healthy and not suffering from DM.
3. No H/O hypertension in the family.

(D) TREATMENT HISTORY :

1. Received glipizide, pioglitazone and metformin in varying combinations for last 15 years; the intake of drugs was not too regular. He was once prescribed inj. insulin.
2. Treated by norfloxacin during the attacks of UTI.
3. Received multivitamins for tingling sensation of the extremities.
4. He had never received corticosteroid and thiazides (may cause secondary diabetes).

Special points in the physical examination of your patient :

(A) GENERAL SURVEY:

1. Decubitus—Of choice.
2. Facies—Moon face (puffy with baggy lower eyelids).
3. Nutrition—Could not be assessed properly due to the presence of oedema.
4. Thyroid—Not enlarged.
5. Neck veins—Could not be properly visualised due to the presence of oedema.
6. Oedema—Pitting; generalised; parietal oedema present.
7. Skin—Within normal limit.
8. Pulse Condition of the arterial wall is thickened. All the peripheral pulses are palpable (press the oedema fluid for few seconds for better palpation of pulse and describe all the points in pulse).

9- BP (i) 180/100 mm of Hg—in lying position.
(ii) 170/95 mm of Hg—in standing position.

10. Respiration—20/mln, thoraco-abdominal in type; other points—within normal limit.
11. Temperature—Normal at present.
12. Scrotum Absence of scrotal oedema and hydrocele at present; penis—within normal limit.
13. Feet—Absence of trophic ulcer; presence of oedema.
14. Dehydration—Absent (to exclude ketoacidosis).
15. Height and weight—essential to calculate body mass index (BMI).

* Mention all the points in general survey.

(B) GENITOURINARY SYSTEM :

1. No renal lump felt.
2. Renal angle—Non-tender.
3. Urinary bladder—Empty (by percussion).
4. Scrotal oedema—Absent.
5. Prepuce, glans penis, anus—within normal limit.
6. Genital discharge per urethra—absent.

[7. Examine vulva, vagina, and perform per vaginal examination in females]

(C) NERVOUS SYSTEM :

a) The patient is conscious, alert, oriented and co-operative.
b) Higher functions with speech—Normal.
c) Cranium and spine—Within normal limit.
d) Neck rigidity—Absent.

e) Cranial nerves—Normal (sometimes, there is Illrd, IVth or Vlth nerve palsy In diabetes). Ophthalmoscopy—Not done.

f) Motor functions—

1. Nutrition—Could not be assessed properly due to the presence of oedema. No foot drop.
2. Tone—A bit diminished in all four limbs.
3. Power—Grade IV in all four limbs.
4. Coordination—Within normal limit.
5. Involuntary movements—None.

g) Sensory functions—

1. superficial—Pain, touch and temperature sensations are lost over the distal parts of all limbs. Impaired sensation in the proximal part of all limbs and the involvement is rather patchy in nature.
2. Deep—
   (i) Vibration sense—Lost (mostly over the medial malleoli).
   (ii) Joint sense—Impaired distally.
   (iii) Position sense—Impaired distally.
   (iv) Muscle sense—Calf muscles are tender on palpation and squeezing (Abadie's sign).
3. Cortical—Impaired (in a patient of peripheral neuropathy, cortical sensations can not be tested properly).

h) Reflexes—

1. Superficial reflex :
   (i) Abdominal—No response (due to peripheral neuropathy/ascites).
   (ii) Cremasteric—No response.
   (iii) Plantar response—No response.

* Superficial reflexes showed 'no response' bilaterally.

2. Deep reflex :	Right	Left
(i) Ankle jerk	Lost	Lost
(ii) Knee jerk	Diminished	Lost
(iii) Biceps jerk	Normal	Normal
(iv) Triceps jerk	Normal	Diminished
(v) Supinator jerk	Normal	Normal
(vi) Clonus	Absent	Absent

3. Visceral reflex : Within normal limit.

i) Trophic changes—Absent (no bed sore, no trophic ulcer in sole of feet). Charcot joint absent,

j) Cerebellar functions—Normal.

k) Autonomic functions—

(i) Tachycardia - Absent.
(ii) Postural hypotension - Absent.
(iii) Sweating - Normally present all over the body.

1) Gait—Could not be tested.

Romberg's sign — Could not be tested properly (due to anasarca and weakness).

(D) G.I. SYSTEM :

1. Teeth, gum. tongue, oral cavity and breath (odour)—within normal limit.
2. No hepatosplenornegaly.
3. Ascites — Present.
4. Parietal oedema in abdomen—Present.
5. Venous prominence over abdomen—Absent.

(E) CVS :

1. Precordium—No deformity.
2. Thrill—Absent.
3. Apex—Left 5th ICS, on the left MCL with normal character.
4. Heart sounds—Normal.

5. Murmur—Absent.
6. Pericardial rub/opening snap/split/click—Absent.

(F) RESPIRATORY SYSTEM :

1. Respiration—20/min, thoraco-abdominal (due to ascites), regular; absence of air hunger.
2. Trachea—Central in position.
3. Parietal oedema in the chest wall—Present.
4. Percussion—Normal resonant note on both sides.
5. Breath sound—Vesicular in type.
6. Added sounds—Nil.
7. Vocal resonance—Normal on both sides.

(G) LYMPHORETICULAR SYSTEM :

1. Sternal tenderness—Absent.
2. Lymphadenopathy—Absent.

(H) EXAMINATION OF THE SKIN :

Abscess, balano-posthitis, candidosis, xanthoma, xanthelasma or trophic ulcers are absent; diabetic dermopathy is present over shins bilaterally.

(I) EXAMINATION OF THE EYES :

1. No stye.
2. Pseudo Argyll Robertson pupil—Absent.
3. Cataract (early) in both eyes.
4. Glaucoma—Absent.
5. Ophthalmoscopy—Not done.

(J) URINE EXAMINATION DONE AT THE BEDSIDE :

1. Sugar—Present.
2. Protein—Present.

N.B. : Ophthalmoscopy (fundoscopy)—though not required in undergraduate curriculum, it should always be performed in postgraduate examinations.

What is diabetes mellitus ?

It is a clinical syndrome characterised by high blood sugar level (hyperglycaemia) **and glycosuria** due to relative or absolute deficiency of insulin secretion and/or action, or insulin **resistance that leads** to disturbances in carbohydrate, protein, fat metabolism, and water and electrolyte **homeoStasis.**

The diagnostic criteria for diabetes mellitus :

- Symptoms of diabetes plus 'random' blood glucose concentration > 200 mg/dl, or
- 'Fasting' plasma glucose > 126 mg/dl, or
- '2h-postload' plasma glucose > 200 mg/dl during an oral GTT.

The **new diagnostic criteria for pre-diabetes and diabetes are** :

In the new criteria, the categories of FPG are :

FPG <100 mg/dl = Normal fasting glucose

FPG >100 mg/dl and <126 mg/dl = Impaired fasting glucose (IFG)

FPG >126 mg/dl = Provisional diagnosis of diabetes (on more than one occasion)

The corresponding categories when the oral GTT is used, are as follows :

2 hPG <140 mg/dl = Normal glucose tolerance

2 hPG > 140 mg/dl and < 200 mg/dl = Impaired glucose tolerance (IGT)

2 hPG > 200 mg/dl = Provisional diagnosis of diabetes (must be confirmed on a subsequent day)

* FPG = Fasting plasma glucose; 2 hPG = 2-h postload glucose

** The prognostic significance and outcome (i.e., accuracy) are same whether it is the FPG > 126 mg/dl or 2 HPG > 200 mg/dl (i.e., in diabetes). This is why, in clinical practice, the FPG test is now mostly preferred because of ease of administration, convenience, acceptibility to patients and its lower cost.

*** 2-h postload glucose is done by taking 75 g of glucose dissolved in 300 ml water.

**** Results are for venous plasma, the whole blood values are lower.

***** 'Fasting' is defined as no calorie intake (i.e., overnight) for at least 8 hours. 'Random' is defined as any time of the day without regard to time since the last meal.

Classification of diabetes mellitus :

Read the modern aetiological classification from 'Bedside Clinics in Medicine, Part II'. In the recent classification, IDDM has been replaced by the term typel and NIDDM by type 2 diabetes mellitus.

Who is a potential diabetic ?

These patients usually have no symptoms, and show no abnormality on examination or by GTT but are susceptible to develop diabetes in any time of their life.

1. When one parent is diabetic and the other have a family history of diabetes.
2. Diabetes present in both the parents.
3. Mother of a 'Herculean baby' (> 9 lbs).
4. Non-diabetic member of a monozygotic twin, where the other is diabetic.

* Patients with IGT(140-199 mg/dl)and / or IFG (100-125 mg/dl)are now regarded as **'pre-diabetes'.**

Latent diabetic* are persons who show impaired GTT under stressful conditions like pregnancy, infections, physical and mental stress or when over-weight.

Characteristics of Type 1 DM :

1. Age of onset is usually below 30 years.
2. Usually wasting is prominent (or lean patients).
3. Abrupt onset with rapid progress.
4. Pancreatic Islet cells (of Langerhans) are almost destroyed. Plasma insulin Is low to absent.
5. Polyphagia, polyuria and polydipsia are classically present.
6. Always responsive to insulin.
7. Unresponsive to oral hypoglycaemic agents.
8. Diabetic ketoacidosis occurs very often.
9. Family H/O diabetes mellitus is usually absent.
10. Presence of other autoimmune diseases with autoantibodies.
11. HLA-DR3 or DR4 in > 90%.
12. Disappearance of C-peptide.
13. High mortality, if untreated.

Characteristics of type 2 DM :

1. Usually starts after the age of 30 years.
2. Obese persons (or overweight).
3. Insidious onset with gradual progress.
4. Pancreatic islet cells are not totally destroyed. Plasma insulin is normal to high.
5. Polyphagia, polyuria and polydipsia—Not so classically seen as in type 1 DM.
6. Responsive to oral hypoglycaemic agents.
7. Insulin therapy—Responsive to resistant.
8. Hyperosmolar hyperglycaemic non-ketotic coma occurs very often.
9. Family H/O diabetes mellitus is usually present.
10. Absence of other autoimmune diseases and autoantibodies.
11. No HLA links; 50% concordance in idential twins.
12. C-peptide persists.
13. Low mortality, if untreated.

Causes of polyuria :

Read the section on 'Acute glomerulonephritis-.

Causes of polyphagia :

1. Diabetes mellitus 2. Thyrotoxicosis 3. Obesity 4. Hungry individuals 5. Binge eating (bulimia) 6. Sometimes, in malabsorption syndrome.

Causes of polydipsia :

1. Polyuria 2. Psychogenic polydipsia (compulsive water drinking) 3. Anxiety, tension, phobia 4. Orators 5. Anticholinergic or antidepressant medication 6. After heavy protein meal.

* Pathophysiology of P_3 symptoms : In diabetes, there is hyperglycaemia —> glycosuria -> osmotic diuresis -> **polyuria** -> **polydipsia.** Continuous glycosuria leads to neoglucogenesis from protein which results in wasting of muscles (resulting in loss of weight). Non-utilisation of sugar (in the presence of hyperglycaemia) for energy expenditure is responsible for **polyphagia** or excessive hunger. The classic triad of DM is often polyuria, T thirst and weight loss.

Drugs provoking hyperglycaemia :

Corticosteroids, thiazides, diazoxide, dopexamine, protease inhibitor, clozapine, non-selective beta blockers, cyclosporin, pentamidine, nicotinic acid, a-interferon.

How to suspect DM in an outdoor patient?

1. Classical triad of symptoms (polyphagia, polyuria and polydipsia—the P., ***symptoms).***
2. Recurrent abscess, boils, carbuncles or fungal infections; recurrent urinary tract infections.
3. Recurrent stye or chalazion.
4. Unexplained emaciation; undue tiredness or fatigue.
5. Delayed wound healing.
6. Frequent change of glasses due to error of refraction.
7. Cataract appearing at an early age.
8. Sudden, isolated Illrd cranial nerve palsy.
9. Resistant pulmonary tuberculosis.
10. Non-resolving pneumonia.
11. Silent myocardial infarction.
12. Generalised pruritus, balanitis or pruritus vulvae.

Effects of diabetes on pregnancy :

1. Hydramnios 2. Toxaemia of pregnancy 3. Maternal infections 4. Difficult labour 5. Recurrent abortions 6. Postpartum haemorrhage 7. Puerperal sepsis.

Effects of diabetes on the foetus :

1. Prematurity 2. Stillbirth 3. Macrosomia (large baby) 4. Postpartum hypoglycaemia 5. Respiratory distress syndrome 6. Hyperbilirubinaemia 7. Congenital heart diseases, open neural tube defects.

Differential diagnosis (D/D) of your case :

If the history and presentation are so classical, no D/D are required. Otherwise, differentiate among the causes of polyuria, nephrotic syndrome or peripheral neuropathy.

Complications of DM :

The life-history of diabetes mellitus is full of complications. The patient presents to different specialists or superspecialists with different organs/systems involvement. The common cause of death in treated patients are cardiovascular ailments (70%), followed by renal failure (10%) and infections (6%).

(A) ACUTE (EARLY) :

1. **Hypoglycaemia.**
2. **Diabetic ketoacidosis.**
3. Hyperosmolar hyperglycaemic non-ketotic coma.
4. Lactic acidosis (rare).
5. Infections.
6. Acute circulatory failure.

(B) LATE :

1. **Circulatory abnormalities (macro- and microangiopathy).**
2. **Retinopathy (microangiopathy).**
3. **Neuropathy (peripheral and autonomic).**
4. **Nephropathy.**
5. Gastrointestinal disorders.
6. Recurrent infections.
7. Diabetic foot.
8. Dermatological complications.
9. Miscellaneous — Malignant otitis externa, emphysematous cholecystitis, rhinocerebral mucormycosis, hypertriglyceridaemia, platelet aggregate abnormality etc.

Ocular complications of DM ;

(A) NON-RETINOPATHIC :

1. Recurrent stye and chalazion.
2. Signs of dyslipidaemia (corneal arcus and xanthelasma) may be present.
3. Anterior uveitis (hypopyon).
4. Rubeosis iridis (moth-eaten appearance of iris).
5. Pseudo Argyll Robertson pupil.
6. Frequent change of glasses due to error of refraction.
7. Snow flake cataract (specific of DM)—Rare.
8. Senile cataract—Accelerated senile cataract.
9. Glaucoma.
10. Illrd, IVth and VIth cranial nerve palsy.

(B) RETINOPATHY :

I. Simple, background or non-proliferative—

a) Increased capillary permeability.
b) Capillary closure and dilatation.
c) Microaneurysms (earliest change observed by ophthalmoscopy and is known as dots).
d) Arteriovenous shunts.
e) Venous dilatation.
f) Haemorrhages (occur in deeper layer of retina and is known as blots').
g) Hard exudate (due to leakage of protein and lipids from damaged capillaries, and is very characteristic of DM).
h) Cotton-wool spots (superficial exudates formed due to 'microinfarction' and is usually seen in diabetes with hypertension).

* c) and f) are collectively known as 'dots and blots'.

II. Proliferative —

a) Neovascularisation (new vessel formation in response to retinal ischaemia).
b) Pre-retinal haemorrhage (sub-hyaloid).
c) Retinitis proliferans.
d) Vitreal haemorrhage.
e) Retinal detachment.

** Other causes of microaneurysms are systemic hypertension, SLE, hyperviscosity syndrome and Coats disease (rare). *Microaneurysms are the hallmark of diabetic retinopathy***.** Neovascularisation is also seen in sickle cell retinopathy, central retinal vein occlusion and Eales' disease.

What is maculopathy ?

When the macula is involved, there is sudden loss of visual acuity. Macula may be involved by,

1) Oedema, 2) Haemorrhage, or 3) Exudate (hard).

* Microaneurysm, venous abnormality, haemorrhage or exudate do not interfere with vision unless they are associated with maculopathy. Sudden loss of vision in DM may also be due to vitreal haemorrhage, haemorrhage in iris or retinal detachment.

Neurological complications of DM :

(A) PERIPHERAL NEUROPATHY :

1. Distal, symmetrical, mixed sensory-motor polyneuropathy (commonest).
2. Asymmetrical, proximal motor neuropathy (diabetic amyotrophy)—commonly affects qudriceps, adductor magnus muscles.
3. Distal, symmetrical, sensory polyneuropathy.
4. Asymmetric mononeuritis multiplex (painful).
5. Acute mononeuropathy (paralysis of Illrd, IVth or VIth cranial nerves, or sudden foot drop and wrist drop).
6. Radiculopathy (usually involves spinal nerves, over the chest wall or abdomen).

(B) AUTONOMIC NEUROPATHY :

1. Hypoglycaemic unresponsiveness (dangerous, due to lack of warning symptoms).

2. Tachycardia (resting), absence of sinus arrhythmia, sudden cardio-respiratory arrest.
3. Postural or orthostatic hypotension (sustained drop in systolic pressure by > 20 mm of Hg or diastolic pressure by > 10 mm of Hg in standing condition than in lying down position—BP should be measured after standing for at least 3 minutes).
4. Sleep apnoea.
5. Gustatory sweating (circumoral sweating during eating), or disturbance of sweating.
6. Gastroparesis diabeticorum (abdominal fullness, vomiting), biliary dyskinesia.
7. Nocturnal and post-prandial diarrhoea.
8. Anhidrosis (loss of sweating).
9. Impotence (erectile dysfunction), loss of libido and absence of testicular sensation.
10. Retrograde ejaculation, hesitancy or precipitancy in urination.
11. Charcot joint; cold feet (dut to loss of vasomotor response).
12. Pseudo Argyll Robertson pupil.

* DM never affects brain. Deep-seated, lancinating pain in the lower limbs as a result of peripheral neuropathy is known as diabetic pseudotabes.

Postural (orthostatic) hypotension is commonly due to fluid depletion, autonomic neuropathy, drugs (vasodilators, diuretics) and idiopathic orthostatic hypotension.

*** Causes of **impotence** (erectile dysfunction) in clinical practice are psychological, diabetes mellitus (autonomic neuropathy), atherosclerosis (vascular), pituitary and testicular failure (endocrinopathy), [3-blockers and antidepressants (drug-induced), and miscellaneous (CRF, motor neurone disease, prostatectomy or substance abuse).

Other causes of autonomic neuropathy :

Other than diabetes mellitus (commonest cause), they are :

1. G.B. syndrome.
2. Porphyria.
3. Amyloidosis.
4. Uraemia.
5. Peroneal muscular atrophy.
6. Shy-Drager syndrome (orthostatic hypotension with central nervous system disorder).
7. Riley-Day syndrome (familial dysautonomia).
8. AIDS.

Causes of coma in a diabetic :

1. Hypoglycaemia (commonest cause).
2. Diabetic ketoacidosis.
3. Hyperosmolar hyperglycaemic non-ketotic coma.
4. Lactic acidosis (rare).
5. Other causes of coma (may or may not be associated with diabetes) like,
   a) CVA.
   b) Renal failure.
   c) Hepatic coma.
   d) Drug-induced coma.

* Except No.2, all are causes of non-ketotic coma in a diabetic.

Renal lesions in diabetes (diabetic nephropathy) :

1. Diffuse glomerulosclerosis (commonest lesion).
2. Nodular glomerulosclerosis (K-W lesion).
3. Arterionephrosclerosis.
4. Chronic interstitial nephritis.
5. Pyelonephritis, perinephric abscess.
6. Papillary necrosis.
7. Various tubular lesions like fibrin cap, capsular drop and glycogen in renal tubules.

* The 'sequence of events' in diabetic nephropathy are :

Glomerular hyperperfusion and renal hypertrophy result in increase in GFR within 1 year -> structural

change in glomerulus and mesangium occurs within 5 years with returning of GFR to normal → at 5-10 years some patients develop 'microalbuminuria' (incipient proteinuria) → clinical nephropathy with 'overt proteinuria' develops at 18-20 years → 'end stage renal disease (ESRD)' is reached at 22-25 years.

In DM, recurrent UTI is very common. ACE-inhibitor therapy may delay the onset of nephropathy.

** *Diabetic nephropathy* (microvascular complication) includes all the lesions occuring in the kidneys of patients suffering from DM; No. 1 and 2 may lead to K-W syndrome.

Clinical features due to renal involvement :

1. Oedema.
2. Hypertension.
3. K-W syndrome (nephrotic syndrome).
4. Chronic renal failure.
5. UTI (usually recurrent).
6. Acute renal failure (due to acute papillary necrosis—rare).

Insulin requirement in renal involvement :

Insulin requirement in DM is reduced with advancing renal insufficiency and is due to :

1. Excretion of insulin binding antibodies (with albumin) in the urine.
2. Reduced rate of degradation of insulin.
3. Uraemia tends to impair neoglucogenesis.

* *Daily insulin production in a normal healthy non-obese adult is 25 units.*

Gastrointestinal manifestations in DM. :

1. Fungal infection within the oral cavity (e.g., candidosis).
2. Gastroparesis diabeticorum (gastric atony and stasis).
3. Motility disturbance of gall bladder, oesophagus, stomach and colon.
4. Chronic gastritis.
5. Diabetic enteropathy (diarrhoea).
6. Chronic pancreatitis (steatorrhoea).
7. Fatty liver and increased incidence of pyogenic liver abscess.
8. Acalculous cholecystitis.
9. Periodontitis; rectal and ischiorectal abscess in poor control of blood sugar.

Why there is diarrhoea and steatorrhoea in DM ?

1. Exocrine pancreatic insufficiency,
2. Coexistant coeliac disease,
3. Abnormal bacterial proliferation in intestine, or
4. Autonomic neuropathy ('diabetic diarrhoea').

Skin lesions in diabetes :

1. Recurrent boils, abscess and carbuncles.
2. Balano-posthitis (inflammation of glans penis and prepuce respectively).
3. Vulval moniliasis (pruritus vulvae).
4. Delayed wound healing.
5. Candidosis of skin.
6. Blisters (usually on feet or hands), bullae (bullosis diabeticorum), granuloma annulare, vitiligo.
7. *Diabetic dermopathy*—Small rounded brown plaques with a raised border, which is hyperpigmented and scaly; located over anterior tibial surface (shin spots or spotted leg syndrome).
8. Xanthomas (eruptive).
9. Necrobiosis lipoidica diabeticorum (NLD)— Yellowish plaque-like lesion with a brownish border and atrophic centre over the shin.
10. Lipoatrophy and lipohypertrophy (due to insulin injection), or drug rash.
11. Diabetic foot (due to ischaemia and / or neuropathy)—ulcer or gangrene.
12. Dupuytren's contracture.
13. Scleroderma-like skin lesion (tight waxy skin over shoulder and upper back)—scleroderma diabeticorum.

14. Prayer sign—'Cheiroarthropathy' (stiff hand syndrome or limited joint mobility) i.e., mild, fixed curvature of the fingers which makes it impossible to place the hand and fingers flat on a surface.
15. Acanthosis nigricans in type 2 DM (in case of insulin resistance).
16. Ulcers (neuropathic or due to arterial disease), specially in legs or sole of feet.

* Lipoatrophy or lipohypertrophy—localised atrophy or hypertrophy of subcutaneous fat respectively.

Importance of examination of foot in DM :

1. Ulceration, callosity in skin of sole, cracks and fissures, colour of skin (may have cyanotic hue), anhidrosis, clawed-up toes (a feature of neuropathy), digital gangrene, fungal infection in nails and in between toes.
2. Temperature of the skin (in ischaemia, feet become cold).
3. Pulsation in arteria dorsalis pedis and posterior tibial artery (↓ pulsation in angiopathy).
4. Ankle jerk—lost in peripheral neuropathy.
5. Vibration sense—lost early in DM with neuropathy.
6. Oedema—present in nephropathy.
7. Foot deformity in Charcot's arthropathy.

* Diabetic foot ulcer is due to ischaemia (microangiopathy ± associated atherosclerosis)/neuropathy/ both inchaemia and neuropathy ± secondary infection.

Causes of 'leg ulceration' and their basic investigations :

When the leg ulcers are present on the lower leg, usually it is due to vascular diseases. The site of ulcer on the lower leg often gives an indication of the underlying aetiology. The common causes are :

(A) Venous disease : Varicose veins, deep venous thrombosis, deep venous obstruction (e.g., from pelvic growth), incompetent valves.
(B) Arterial diseases : Atherosclerosis, Buerger's disease, vasculitis.
(C) Small vessel disease : Diabetes mellitus, vasculitis.
(D) Neuropathy : Diabetes mellitus, leprosy, polyneuropathy due to any cause, syphilis (rare).
(E) Haemorrheological : Sickle cell disease, hereditary spherocytosis, chronic haemolytic anaemia (e.g., thalassaemia), cryoglobulinaemia, immune complex disease.
(F) Tumour : Squamous cell carcinoma, Kaposi's sarcoma, melanoma, basal cell carcinoma.
(G) Trauma : Trophic ulcer, injury, contact dermatitis, self-inflicted, chronic atopic eczema.
(H) Infections : Tuberculosis, leprosy, syphilis, yaws, mycotic, tropical ulcer.
(I) Miscellaneous : Pyoderma gangrenosum, osteomyelitis, lymphoedema.

Basic clinical examination : Temperature of the local skin, site of ulcer (venous—lower leg, ankle with pigmentation; arterial—shin, foot; vasculitis—shin, upper leg, and painful; neuropathy—heel, ball of the great toe; painless), peripheral arterial pulses, ankle jerk, vibration sensation, oedema, local cyanotic hue, blood pressure, thickened peripheral nerves.

Basic investigations :

1. Blood—For anaemia, blood dyscrasias; VDRL; sugar, lipid profile, ANF, ANCA.
2. Urine—For sugar.
3. Bacterial swab—For detection of pathogens.
4. Doppler ultrasound of lower extremities (both venous and arterial system).
5. Ankle : brachial pressure index, or ABPI (in health, the value is ≥ 1.0 in supine position)—ABPI in intermittent claudication is 0.4-0.9; ABPI of < 0.4 is found in critical limb ischaemia.
6. Venography.
7. Nerve conduction study.

* Treatment : stoppage of smoking, control of DM/hypertension/dyslipidaemia, local care, antibiotics in infection, advice of chiropodist, and surgery (balloon dialatation) or amputation in selected cases.

Importance of 'hand examination' in DM :

1. Pulp infection, blisters, digital gangrene, fungal infection in nails and in between fingers (intertrigo).
2. Cheiroarthropathy or limited joint mobility—the patient is asked to join the hands as if in prayer, and the hands can not be apposed (prayer sign).

3. Thickened, tight, waxy skin on the back of the fingers (sclerodactyly-like).
4. Dupuytren's contracture.
5. Trigger finger (flexor tenosynovitis).
6. Carpal tunnel syndrome is common in diabetics.
7. Small muscle wasting (due to emaciation or peripheral neuropathy).

* **Rheumatological complications** : Cheiroarthropathy, flexor tendinopathy, adhesive capsulitis, osteoarthropathy, Charcot arthropathy and diffuse idiopathic skeletal hyperostosis (DISH).

Circulatory and CVS ***complications in DM*** .

1**. Microangiopathy** (responsible for **'triopathy',** i.e., retinopathy, nephropathy and neuropathy).
2 Intermittent claudication due to accelerated atherosclerosis **(macroangiopathy;** macrovascular ' disease includes coronary artery disease, peripheral vascular disease, cerebrovascular disease, diabetic foot and hypertension).
3. Gangrene (peripheral vascular disease).
4. Impotence (on a vascular basis).
5. Resting tachycardia and postural hypotension (autonomic neuropathy); cardiac failure.
6. Angina pectoris.
7. Silent myocardial infarction.
8. CVA is common in diabetics.
9. Cardiomyopathy.
10. Hypertension (macroangiopathy, or following renal involvement).

* In DM, BP should idealy remain < 130/80 mm of Hg.

Causes of painless (silent) myocardial infarction :

It is known that 15-20% of myocardial infarcts are painless. The common causes are,

1. Diabetes mellitus with autonomic neuropathy.
2. Patient under general anaesthesia.
3. Elderly patients with cerebrovascular disease or dementia.
4. Few patients may not have pain (greater in women).
5. Inability to recognise the symptom by the patient.

Symptoms of hypoglycaemia :

Prolonged hypoglycaemia may produce permanent brain damage. The symptoms (usually blood glucose becomes less than 55 mg/dl) are due to excessive secretion of catecholamines and dysfunction of CNS Thus they are divided into two groups like 'autonomic' and 'neuroglycopenic' symptoms :

1 Weakness 2. Hunger 3. Sweating (drenching) 4. Tremor (trembling) 5. Palpitation (pounding heart) 6. Dizziness, yawning 7. Headache 8. Clouding of vision 9. Abnormal behaviour (aggression) 10. Confusion, inability to concentrate and incoordination 11. Diplopia 12. Convulsions 13. Coma.

Autonomic — 2, 3, 4, 5; neuroglycopenic — 6, 8, 9, 10. 11, 12, 13; non-specific—1 and 7.

* Remember, autonomic symptoms predominate in rapid onset hypoglycaemia whereas neuroglycopenic symptoms are the chief complains in gradual onset hypoglycaemia.

** Diurnal hypoglycaemia : nervousness, sweating, hunger and tremor mainly.

Nocturnal hypoglycaemia : night sweats, bad dreams and early morning headache.

*** Hypoglycaemia is traditionally classified into a) Fasting hypoglycaemia (occurs in the presence of diseases like hyperinsulinism, liver disease, renal disease, endocrine causes and drug-induced), and) Reactive (post-prandial) hypoglycaemia (occurs in response to meals like Dumping syndrome. galactosaemia).

Important points to diagnose hypoglycaemic coma (or D/D with diabetic ketoacidosis) :

Hypoglycaemic coma is always confused with diabetic coma (ketoacidosis). The characteristic fea - tures of 'hypoglycaemic coma' are :

1. History of overdose of insulin or oral hypoglycaemic agents, vigorous exercise or missing a meal.
2. Classical symptoms of hypoglycaemia may be present (already discribed)—Drenching sweat is very important.
3. Sudden onset of unconsciousness.

4. a) Dehydration—Absent (rather pallor plus cold sweat are is present).
   b) Pulse—Normal volume or full pulse.
   c) BP—Normal or high.
   d) Air hunger Absent; rather shallow or normal respiration.
   e) Smell of acetone—Absent.
   f) Convulsions—May be present.
   g) **Jerks—May be brisk.**
   h) **Plantar response—Often bilaterally extensor.**
5. Urine—Absence of sugar and ketone bodies.
6. Blood—Blood sugar is low; $HC0_3$ level is normal.
7. Lump of sugar (given orally) or infusion of glucose (given in an unconscious patient) helps in regaining consciousness.

* In diabetic ketoacidosis — The patient will have polyuria, polydipsia, anorexia, vomiting and abdominal pain. Dehydration +; pulse is usually weak, BP is low with dry skin and tongue; air hunger is present with smell of acetone in the breath (Kussmaul's breathing); deep reflexes are dull with flexor plantar response. Sugar and ketone bodies are present in urine; high blood sugar with low HCO , level.

Bedside clinical tests for autonomic neuropathy :

There are battery of tests to diagnose autonomic neuropathy but the commonly practised cardiovascular reflexes are described below. In autonomic neuropathy, there will be :

1. Response of Valsalva manoeuvre on R-R interval in ECG (absence of T in R-R interval).
2. Change of heart beat and BP, in response to change of posture (absence of slight T in pulse and BP on standing).
3. Blood pressure response to sustained handgrip (absence of normal T in BP during handgripping).
4. Heart rate response to deep breathing (absence of ***I*** heart rate on deep inspiration).
5. Resting tachycardia (i.e., tachycardia at rest).

* Simply one can examine at the bedside for light reflex, accommodation reflex, pupillary resistance to mydriatics, or sweating.

What are the causes of sudden death in diabetes ?

Probably it is due to autonomic neuropathy and the different hypothesis put forward are :

a) Patients do not respond normally to hypoxia and sustain cardio-respiratory arrest.
b) Apnoea.
c) Cardiac arrhythmias.

Investigations you like to perform in a case of DM :

1. Blood—
   a) Sugar (fasting and PP; for diagnosis and monitoring) and glycosylated Hb (HbA or HbA — comprising 4-6% of total Hb and reflects blood glucose concentration for preceding 6-8 weeks).
   b) TC, DC and ESR; triglycerides, LDL, VLDL, HDL and cholesterol (lipid profile); urea and creatinine; uric acid.
2. Urine (R/E)—with special reference to specific gravity, RBC. pus cells, protein, sugar, ketone bodies, casts. Culture and sensitivity tests are done, and 24-hours protein excretion is measured, if indicated (i.e., in nephrotic syndrome developing as a complication).
3. EGG—To diagnose IHD or to observe the changes due to hypertension (associated).
4. Chest X-ray—Pulmonary tuberculosis and fungal infection of lung are very common in diabetics. Cardiomegaly from hypertension should be looked for. Straight X-ray of abdomen is done to exclude pancreatic calcification (fibro-calculous pancreatic **disease—**commonly seen in T **DM.**
5. Ophthalmoscopic examination (fundoscopy)—for diabetic retinopathy.
6. Barium meal examination of G.I. tract and endoscopy are done to study motility of the G.I. tract.
7. Nerve conduction study (in peripheral neuropathy).
8. Doppler studies of peripheral vessels, if indicated.

* Glycosylated haemoglobin is a parameter for assessing long-term glycaemic control, and for tight control of DM it should be kept below 7%. ESR may be high in the presence of infection, commonly tuberculosis. Glycated (glycosylated) fructosamine, which measures the amount of glycated serum protein (mainly albumin) gives an indication of glycaemic control for over the last 2-3 weeks.

How to classify oral hypoglycaemic agents (OHA) ?

(A) SULPHONYLUREAS :

a) 1st generation—Chlorpropamide, tolbutamide, tolazamide, acetohexamide.

b) 2nd generation—Glimepiride, Glipizide, gliclazide, glibenclamide, glyburide.

(B) NON-SULPHONYLUREA AGENTS :

a) Biguanides : Phenformin (not used now-a-days), metformin, buformin.

b) Meglitinide analogues (prandial glucose regulators) : Repaglinide, nateglinide.

c) Alpha-glucosidase inhibitors : Acarbose, voglibose. miglitol.

d) Thiazolidinediones (also known as 'glitazones' or PPARy agonist (peroxisome proliferator-activated receptor-y)]. : Troglitazone (no longer used), ciglitazone, pioglitazone, rosiglitazone.

e) Dipeptidyl peptidase-4 (DPP-4) inhibitors : Sitagliptin, vildagliptin.

* *The OHAs are divided into three categories :*

1. Insulin sensitizers : metformin, pioglitazone, rosiglitazone.
2. Insulin secretagogues : glimepiride, glipizide, gliclazide, tolbutamide, chlorpropamide, glibenclamide, meglitinide analogues.
3. Inhibitors of glucose absorption : alpha-glucosidase inhibitors, guar gum

** Parenteral hypoglycaemic agents are :

- Insulin
  - Glucagon-like peptide (GLP-1) analogue—Incretin mimetics like exenatide and liraglutide.
- Amylin agonist—Pramlintide.

How will you correct the fluid loss in ketoacidosis ?

In an established case, the patient usually suffers from a fluid deficit of 7-8 litres. It is advisable to correct the fluid loss in this way :

Normal saline volume	**Time**
1 litre	in 30 min
1 litre	in next 1 hour
1 litre	in next 2 hours
1 litre	in next 4 hours
4 litres	in next 16 hours

Fluid of choice is normal saline until the blood sugar falls below 250 mg/dl when it may be changed to 5% glucose.

Dawn phenomenon :

When DM patients (type 1 DM mainly) are closely monitored during insulin therapy, it is seen that hyperglycaemia develops in between 3-7 AM. This increase in the insulin requirement in known as Dawn phenomenon and is due to increase in the counterregulatory hormones like cortisol, growth hormone, glucagon and catecholamines. During sleep, there is a surge in the secretion of these hormones. Treatment is aimed at to **increase** the overnight insulin dosage.

Somogyi phenomenon :

This is a manifestation of early morning rebound hyperglycaemia following, possibly unrecognised, hypoglycaemia. Often it is seen that the previous night time dose of insulin was in excess. Treatment it aimed at to **decrease** the overnight insulin dosage. This is commonly seen in children.

* Early morning (3 AM) blood sampling is necessary to differentiate both the conditions. In Dawn phenomenon, both the 3 AM and morning fasting blood show hyperglycaemia. In Somogyi phenomenon, 3 AM blood sample shows hypoglycaemia and morning fasting blood documents hyperglycaemia.

Chronic complications in type 1 versus type 2 DM (with approximate incidence) :

		Type 1	***Type 2***
1.	Retinopathy	90% (after 20 yrs)	15-20% (after 15 yrs)
2.	Nephropathy	30-40%	3-16%
3.	Neuropathy	60% (after 30 yrs)	60% (after 30 yrs)
4.	Ischaemic heart disease	Increases after 30 yrs	2-3 times of normal
5.	Peripheral vascular disease	30%	45% (after 20 yrs)
6.	Hypertension	50% (after 30 yrs)	50%

* The cumulative risk of nephropathy in type 2 DM varies with ethnic origin (may be 50%).

** Though microvascular diseases are the main cause of death in type 1, many patients of type 2 succumb to macrovascular disease prior to development of significant microvascular disease. Advanced age. development of atherosclerosis as a result of co-morbid conditions like physical inactivity, smoking, hypertension and hyperlipoproteinaemia are important causes of death in type 2 diabetes.

*** Majority of diabetics (90-95%) in India suffer from type 2 DM.

**** $_{ln}$ x_tDM, microalbuminuria is an early predictor of nephropathy while in T_2DM, it usually predicts future development of malignant angiopathy and cardiovascular complications.

Define metabolic syndrome or 'syndrome X' :

The **NCEP ATP III criteria** goes like this—

Presence of three or more among five of the following :

- High blood pressure > 130/85 mm of Hg
- Hypertriglyceridaemia > 150 mg/dl
- Low HDL cholesterol < 40 mg/dl in men and < 50 mg/dl in women
- Abdominal obesity : waist circumferance >102 cm in men and > 88 cm in women
- High fasting blood glucose >110 mg/dl

* NCEP = National Cholesterol Education Programme; ATP = Adult Treatment Panel

The International Diabetes Federation (IDF) criteria (needs large waist + any other 2 features) are

- High blood pressure > 130/85 mm of Hg
- Hypertriglyceridemia > 150 mg/dl
- Low HDL cholesterol < 40 mg/dl in men and < 50 mg/dl in women
- Waist circumferance > 94 cm in men and > 80 cm in women
- High fasting glucose > 100 mg/dl.

N.B. : WHO criteria of metabolic syndrome requires insulin resistance to fulfil the criteria. **'Insulin resistance'** is clinically suspected by the presence of acanthosis nigricans, skin tags (acrochordons). central obesity, lipodystrophy and features of polycystic ovarian disease.

Outline of management of your patient (T_2DM) :

1. Diabetic diet.
2. Insulin (insulin requirement is low as there is renal involvement) Used to improve the glycaemic
3. Oral hypoglycaemic agents (reduction or modification of dosage may be necessary in azotaemia).
4. Treatment of hypertension, obesity, dyslipidaemia and coronary heart disease..
5. Treatment of oedema.
6. Management of nephrotic syndrome. Even dialysis may be needed, if azotaemia develops.
7. Control of muscle pain (due to neuropathy) by :
   Phenytoin, carbamazepine, pregabalin, codeine or tricyclic antidepressants.
8. Control of UTI and skin lesions, if develops.
9. Care of the feet to prevent 'diabetic foot' (consult cheiropodist).

Conclusion :

1. Examine all the systems in a patient of DM.
2. Palpate all the peripheral pulses (specially pedal pulses). Measure BP both in lying down and upright position.
3. Search for trophic ulcer in foot.
4. Give attention to retinopathy, nephropathy and neuropathy.
5. Do not forget to test the urine sample for sugar and protein, if possible.

O

CHAPTER II : SHORT CASES

Case 28

CYANOTIC CONGENITAL HEART DISEASES

Clinical presentation :

A young male with H/O anoxic spells, breathlessness and syncope is presented. On examination, it reveals central cyanosis, polycythemia, clubbing, tachypnoea and an ejection systolic murmur in the pulmonary area.

The most probable provisional diagnosis is Fallot's tetralogy.

How do you classify congenital heart disease ?

(A) Cyanotic:

With increased pulmonary blood flow-

- Transposition of great vessels
- Truncus arteriosus
- Total anomalous pulmonary venous connection (TAPVC)
- Double-outlet right ventricle
- Hypoplastic left heart

Normal or decreased pulmonary blood flow-

- Tetralogy of Fallot (TOF)
- Tricuspid atresia
- Ebstein's anomaly
- Pulmonary atresia
- Single ventricle

(B) Acyanotic :

With shunt (le/t-to-right)-

- Atrial septal defect (ASD), ventricular septal defect (VSD), patent ductus arteriosus (PDA)
- Partial anomalous pulmonary venous connection
- Rupture of sinus of Valsalva
- Coronary arteriovenous fistula
- Aortopulmonary window

Without shunt-

- Coarctation of aorta
- Congenital aortic stenosis
- Congenital pulmonary stenosis
- Left heart malformation (congenital mitral stenosis, congenital mitral regurgitation)
- Idiopathic dilatation of the pulmonary trunk

* Common cyanotic congenital heart diseases include 5 T: Tetralogy of Fallot Tricuspid atresia Transposition of great vessels, TAPVC and Truncus arteriosus. .....

** Commonest congenital cardiac anomaly is bicuspid aortic valve (affecting 1-2% of the population) which goes unnoticed until later in life when the valve is stenosed due to fibrosis or calcium deposition or results in significant aortic regurgitation. VSD is the commonest congenital heart disease.

Components of tetralogy of Fallot (TOF) :

It is the commonest cyanotic congenital heart disease in children above the age of 1 year i e who do survive infancy and is commonest among adults. A baby who is cyanotic at birth is unlikely to have TOF. It has 4 distinct abnormalities:

1. Ventricular septal defect (large, non-restrictive, infracristal) - VSD,
2. Right ventricular outflow tract obstruction - infundibular pulmonary' stenosis (PS),

3. Overriding of aorta (aorta arises from both left and right ventricles), and
4. Right ventricular hypertrophy - RVH.

Give a brief account of tetralogy of Fallot :

Children with TOF may present with H/O dyspnoea, fatigue, deep cyanosis, hypoxic spells (see below), squatting, syncope (due to severe right ventricular outflow tract obstruction resulting in increased right-to-left shunt with admixture of venous and arterial blood leading to reduced cerebral oxygenantion), recurrent respiratory tract infection, haemoptysis or impaired growth. Physical examination reveals prominent a-wave in neck veins, central *cyanosis* (commonest clinical manifestation and depends on the severity of PS; the more severe the PS is, the more is the right-to-left shunt through V . Cyanosis is also due to mixing of blood in overridden aorta), *clubbing,* polycythemia (secondary to chronic hypoxaemia), *quiet precordium,* normaf sized heart (no cardiomegaly), mild parasternal impulse (due to VSD there is absence of heave), systolic thrill (rarely felt) and ejection systolic murmur (due to PS) along the left sternal border and in the pulmonary area. *The intensity and duration of the systolic murmur are inversely proportional to the severity of PS.* S, is normal, and S_2 is single, loud and represents aortic valve closure (A). Continuous murmurs of bronchial collaterals may be heard over the back. As the VSD is large, the systolic pressure difference between two ventricles remains very low, and thus the VSD murmur remains inconspicuous (silent). The right ventricle is effectively decompressed by VSD. and this is why CCF does not occur in TOF unless complicated by infective endocarditis or anaemia.

The patient may be complicated by syncope (hypoxic spell), paradoxical embolism with brain abscess, infective endocarditis, and complications following marked secondary polycythemia, e.g intravascular thrombosis developing at different sites. Chest X-ray (PA view) shows normal-sized heart with a characteristic appearance known as 'Coeur en Sabot' (boot-shaped heart with an upturned apex) with oligaemic lung fields. ECG and cardiac catheterization are also done, while echocardiography is diagno .

* Mild case—loud and prolonged murmur, severe case—reduced murmur.

Common associations with tetralogy of Fallot :

Other cardiac anomalies associated with TOF are:

1. Patent foramen ovale (present in all).
2. Right-sided aortic arch (25%).
3. Persistent left-sided superior vena cava (10%).
4. Aortic regurgitation.
5. PDA.
6. ASD.
7. Anomalous origin of coronary arteries.
8. Absent left pulmonary artery.

Other connotations regarding Fallot's type of defects :

- Fallot's triology - PS + reversed interatrial shunt (ASD) + RVH.
- Fallot's pentalogy - Fallot's tetralogy + ostium secundum ASD.
- Acyanotic (pink) Fallot's - Where right ventricular outflow tract obstruction (PS) is mild, i.e., mild Fallot's.
- Acquired Fallot's - In 5% cases of VSD, jet of blood comes to infundibulum and results in its hypertrophy, and thus the right ventricle is enlarged.

Complications of TOF:

1. Anoxic spells, syncope, seizure.
2. Paradoxical embolism (thrombus from systemic veins may enter into arterial system through communication between ventricles and results in CVA or infective endocarditis).
3. Infective endocarditis (common).
4. Polycythemia (may produce CVA), cerebral thrombosis, cerebral abscess.
5. Proneness to pulmonary tuberculosis.
6. 'Growth retardation.

What is hypoxic, anoxic or cyanotic spells?

The child hyperventilates, suddenly becomes more cyanosed and may develop apnoea, syncope, seizures or even sudden death (thus, potentially fatal), specially during waking up, feeding, crying, pyrexia or exercise. Cyanotic spells (Fallot's spells) are common between 2 months and 2 years of age.

Systemic vasodilatation follows feeding, crying etc resulting in an increased right-to-left shunting of blood through VSD with associated decreased pulmonary blood flow. The child adopts *squatting* posture, i.e.. sits with flexed hips and knees (knee-chest position) to reduce the cyanotic spells, and thus peripheral systemic vascular resistance is increased which reduces right-to-left shunting with improvement in arterial oxygen saturation and improved cerebral oxygenation; squatting also increases venous return to the heart and thereby increasing pulmonary blood flow. Squatting following physical exertion is almost always pathognomonic of TOF. The hypoxic spells may vary from once in a fortnight / month to multiple attacks in a day.

Management of TOF :

Medical: Iron supplement for anaemia and antibiotic prophylaxis for infective endocarditis are essential. Cyanotic spells are managed by,

1. Squatting or knee-chest position.
2. Humidified 100% oxygen.
3. Morphine (0.1-0.2 mg/kg, I.V).
4. Propranolol (0.1 mg/kg, I.V).
5. Methoxamine (vasopressor) drip.
6. IV infusion of sodium bicarbonate (2 ml/kg) to combat acidosis.
7. If medical therapy is ineffective, emergency surgical shunts may be considered.

Surgical:

1. Blalock-Taussig shunt (preferred operation) - Left subclavian artery-pulmonary artery anastomosis.
2. Waterston-Cooley shunt - Ascending aorta-right pulmonary artery anastomosis.
3. Pott's shunt - Descending aorta-left pulmonary artery anastomosis (not used now).

What is atrial septal defect (ASD)?

It is the most common congenital heart disease in adults and 2-3 times more common in females. There are two main types of ASD, *ostium secundum* (90%, commonest type; at the level of fossa ovalis) and *ostium primum* (5%, rare; antero-inferior to foramen ovale). The third type of ASD is sinus venosus type (5%, posterior to foramen ovale). ASD is an acyanotic congenital heart disease where there is a defect in the atrial septum with shunting of blood from left atrium to right atrium. ASD should never be confused with patent foramen ovale (PFO). PFO is a normal variant, usually remains asymptomatic and not a true septal defect. In ASD, the right atrium not only receives blood from SVC and IVC but also from the left atrium, and thus enlarged in size.

Most of the children are asymptomatic but may complain of weakness, dyspnoea (effort intolerance), palpitations (due to atrial arrhythmia); the patients are prone to respiratory infections. The pulmonary vascular resistance which is low or normal at childhood goes high up as the patient reaches third or fourth decade, giving rise to pulmonary hypertension. As pulmonary hypertension develops, the initial left-to-right shunt reverses to right-to-left shunt (Eisenmenger syndrome). The patient may develop right heart failure or atrial fibrillation in the adult life.

* In ASD, atrial fibrillation is common, and infective endocarditis is rare (due to slow flow of blood).

Associated diseases / anomalies with ASD :

1. Down's syndrome (ostium primum).
2. Marfan's syndrome (ostium secundum).
3. Partial anomalous pulmonary venous connection.
4. Persistent left-sided superior vena cava.
5. Pulmonary stenosis.
6. Lutembacher's syndrome (ASD with rheumatic mitral stenosis).
7. Mitral valve prolapse or floppy-valve syndrome (mitral regurgitation).
8. Holt-Oram syndrome (upper limb dysplasia, hypoplastic thumb, fingerisation of thumb, absent radius, accessory nipple, pectus excavatum).

Basic physical findings in ASD :

1. ASD may have a systolic thrill (10%) in the pulmonary area. If the thrill is very prominent, think of associated PS.
2. Prominent left parasternal lift.
3. Wide *and fixed splitting of* S_2 (hallmark of diagnosis) with a loud P_2. 'Fixed' means that the splitting does not varies with the phases of respiration.

4. Mid-systolic pulmonary ejection murmur (grade II or III) due to increased flow across the normal-sized pulmonary valve, which is best audible at left 2nd or 3rd intercostal space. No murmur is produced across the septal defect due to low pressure gradient between two atria.
5. A mid-diastolic flow murmur across the tricuspid valve and right-sided S„ are audible in lower left parasternal region.
6. If pulmonary hypertension develops, few of the auscultatory findings change (Eisenmenger's syndrome) - see below.

* Pulmonary stenosis (PS) is the closest D/D of ASD. PS will have systolic thrill in the pulmonary area, soft P_2 and left parasternal heave.

Investigations performed in ASD :

Chest X-ray - It shows a prominent pulmonary artery (a big pulmonary artery segment is seen and can be traced upto diaphragm; end-on view of juicy pulmonary artery is seen as white dots) and pulmonary plethora. ASD also reveals hypoplastic aortic knuckle, mild to moderate cardiomegaly, prominent right atrium and right ventricle.

ECG - Usually right axis deviation (85%); left axis deviation in ostium primum, and 10% having normal axis. RBBB is seen, which is partial or complete. Complete heart block may be revealed in ostium primum type; large ASD may have prolongation of P-R interval.

Cardiac catheterization is performed while echocardiography is diagnostic, which demonstrates the defect and the size of the chambers.

Management of ASD :

Medical **:** Treatment of respiratory infections, arrhythmias, heart failure and infective endocarditis (though rare).

Surgical **:** Upto 2 years of age, ASD can close spontaneously. However, children in the age group of 3-5 years without complications and having a significant shunt (i.e., pulmonary to systemic flow is > 1.5:1) are best candidates for surgery. The defect is repaired by Dacron patch or direct suturing.

What are the characteristics of ventricular septal defect (VSD)?

Excluding bicuspid aortic valve, VSD is the commonest cardiac malformation occurring once in approximately 500 live births or accounting for 30% of all congenital cardiac defects, either in isolation or with a range of other malformations. VSD is an acyanotic congenital heart disease where there.is a defect in the ventricular septum with shunting of oxygenated blood from high-pressure left ventricle to low-pressure right ventricle. When pulmonary blood flow becomes very large and pulmonary arterial pressure increases, there is reversed shunting of blood from right-to-left (Eisenmenger's complex) with development of central cyanosis. The septal defects may vary in size, shape and number, and can be either in membranous part or in muscular portion of the ventricular septum; perimembranous defects are most common (80%), and may be supracristal (subpulmonic) or infracristal (subaortic or behind the tricuspid valve).

Basic physical findings in VSD :

The apex beat is hyperdynamic. A systolic thrill may be palpable at the left parasternal region. Left parasternal lift or heave may be felt. The S, and S_2 are usually masked by the murmur. The murmur is typically rough and pansystolic / holosystolic, best heard in left 3rd and 4th intercostal space close to the sternum but radiating all over the precordium. A mid diastolic flow murmur across the mitral valve may be audible at the apex in large VSD.

Small VSD ('maladie de Roger') - Very often found in routine examination. It is the asymptomatic, small haemodynamically insignificant VSD where thrill and pansystolic murmurs are very prominent. Majority (90%) closes spontaneously by the age of 10 years.

Moderate VSD - The patient comes with fatigue, dyspnoea or pulmonary infections. Cardiac size is enlarged (LVH). Palpable systolic thrill and pansystolic murmur radiated towards right chest are prominent.

Large VSD - Usually develops CCF at 1 year; at 9 - 10 years of age, eventually Eisenmenger's complex develops. There is cardiac enlargement. Usually, there is no thrill and murmur is not so rough-.

* Signs of closing VSD - Holosystolic murmur gets shorter, softer and gradually disappear.

Chest X-ray reveals enlargement of LA and LV along with pulmonary plethora. *ECG* features biventricular hypertrophy in larger defects. A small VSD shows no abnormality in chest X-ray or in ECG. *Echocardiography* identifies the site, size and haemodynamic consequences of VSD.

*** ***Management*** - Medical treatment is done against infective endocarditis and CCF, Surgical closure of moderate and large VSDs (by Dacron patch or direct suturing) is ideally performed before 2 years of age or before the development of severe pulmonary hypertension.

What is patent ductus arteriosus (PDA) ?

The ductus arteriosus connects the ***left pulmonary artery*** just after the bifurcation of the main pulmonary artery with the ***descending aorta*** just distal to the origin of left subclavian artery. In the fetus, the channel (ductus arteriosus) diverts blood from the pulmonary to systemic circulation. Physiological closure occurs soon after birth (due to high oxygen concentration in lungs and reduced pulmonary vascular resistance), and anatomical closure is completed within 1-2 weeks after birth. In a malformed duct with less elastic tissue, the patient may live with patent ductus arteriosus (PDA). As pressure in aorta is higher than pulmonary artery, blood shunts in PDA from aorta-to-pulmonary artery (left-to-right). Thus, venous return to left heart is increased resulting in left ventricular volume overload and ultimately its failure. Over the time, pulmonary hypertension with reversed shunting (right-to-left), i.e., Eisenmenger's syndrome develops.

PDA is common in females, premature babies, babies born at high altitudes or in continual prenatal hypoxaemia, and with maternal rubella in first trimester of pregnancy.

Basic physical findings in PDA :

Pulse - High-volume, bounding or water-hammer in character; wide pulse pressure.

Apex beat - Hyperdynamic.

Thrill - Systolic or systolo-diastolic thrill may be palpable at the left 2nd intercostal space.

Heart sounds - S, and S_2 are loud, and S_3 may be audible at the apex.

Murmurs - The typical continuous 'machinery' murmur (Train in tunnel' murmur, Gibson's murmur) with late systolic accentuation is best audible in left infraclavicular area and left 2nd intercostal space A mid-diastolic apical rumbling murmur may be audible due to increased flow across the mitral valve.

* ***Chest X-ray*** reveals LVH, LAH, big pulmonary artery, calcification of ductus (in elderly), and rarely huge aneurismal dilatation of ductus (due to infection in ductus).

** ECG shows LVH and LAH; RVH in pulmonary hypertension.

*** ***Management*** - Premature infants with PDA are treated medically with indomethacin or ibuprofen (prostaglandin inhibitor) in the first week of life to stimulate ductal closure. Surgery is done by ligation (< 5 years), and ligation as well as excision of the patent duct (> 5 years).

Associated anomalies with PDA :

1. Coarctation of aorta.
2. Congenital aortic stenosis.
3. TAPVC and TOF may be associated with.
4. Tricuspid atresia.
5. Pulmonary stenosis.
6. VSD.

PDA is lifesaving in :

1. Aortic atresia 2. Pulmonary atresia 3. Severe coarctation of aorta 4. Incomplete aortic arch syndrome 5. Hypoplastic left heart syndrome.

Eisenmenger's syndrome :

Pulmonary hypertension with reversal of shunt (right-to-left) from an initial left-to-right shunt is known as Eisenmenger's syndrome and the causes are:

1. VSD (Eisenmenger's complex) - occurs earlier in life.
2. pda - develops a little later than VSD.
3. ASD - develops late in adult life.

Mechanism: Persistently elevated pulmonary flow (left-to-right shunt) raised pulmonary resistance -> pulmonary hypertension -> progressive, obliterative and irreversible changes occur in the pulmonary vasculature persistent pulmonary hypertension -> reversed right-to-left shunting of blood.

The **symptoms** are breathlessness, fatigue, syncope, angina, haemoptysis or features of CCF.

The **developing signs** are:

1. Central cyanosis (not corrected even by giving 100% oxygen).
2. Polycythemia.
3. Clubbing.
4. Prominent a-wave in neck veins.

5. Features of RVH (outward apex, left parasternal heave and epigastric pulsation) or RVF.
6. Loud and palpable P_2.
7. Ejection click and ejection systolic murmur due to pulmonary hypertension.
8. Occasionally pansystolic murmur of tricuspid incompetence may be audible.
9. Original murmur (VSD, PDA, ASD) decreases in intensity, duration and may disappear.

Conditions provoking systemic vasodilatation like pyrexia, exercise, hot climate may trigger the right-to-left shunt and worsen the systemic desaturation. Pregnancy and anaesthesia are tolerated very badly by these patients. Haemoptysis is a bad sign in Eisenmenger's syndrome though not very common. The ***chest X-ray*** is characteristic which reveals enlarged central pulmonary arteries and peripheral 'pruning' of pulmonary vessels (i.e., peripheral '/$_3$rd of lungs have less arterial markings). The ECG shows features of RVH. Heart-lung transplantation remains the only curative treatment.

* PDA with reversal of shunt produces differential cyanosis (feet blue and hands red).

** Remember, Right-to-left shunt gives rise to cyanosis, left-to-right shunt does not.

N.B. : Cyanotic congenital heart diseases are usually given as short and spot cases.

Case 29

FIBROSIS OR COLLAPSE OF THE LUNG

Clinical presentation :

1. Respiratory distress.
2. Dry cough.
3. Pain in the affected chest.
4. Pyrexia (may or may not be present).

Symptomatology basically depends on :
- Rapidity of development.
- Amount of lung parenchyma involved.
- Presence or absence of infection.

Describe the outline of findings in this case :

(A) GENERAL SURVEY—

1. Dyspnoea, orthopnoea (if a major bronchus is suddenly obstructed).
2. Central cyanosis.
3. Clubbing Fibrosing alveolitis or collapse developing from bronchogenic carcinoma.
4. Tachypnoea.
5. Tachycardia.

(B) INSPECTION—

1. Flattening of the chest with supraclavicular hollowing, infraclavicular flattening and supra-scapular wasting.
2. **Crowding of ribs and narrowing of intercostal spaces**—Specially in long standing cases.
3. Restricted movement on affected side.
4. Drooping of the shoulder in case of involvement of apex (seen from back).
5. Shifting of apical impulse towards the affected side.
6. Kyphoscoliosis resulting from extensive fibrosis.

(C) PALPATION—

1. **Shifting of trachea and apex beat towards the affected side.**
2. Movement of the chest Diminished movement and reduced expansion on the diseased side.
3. Vocal fremitus—
   (i) Fibrosis—Diminished.
   (ii) Collapse Diminished or absent if the bronchus is obstructed, and increased if the bronchus is patent.

(D) *PERCUSSION*—Impaired resonance or dull note.

(E) AUSCULTATION—

a) Collapse with obstructed bronchus or fibrosis—Diminished vesicular (fibrosis) or absent breath sound (collapse), diminished or absent vocal resonance, fine crepitations and occasionally rhonchi are heard in fibrosis; rhonchi and crepitations are absent in collapse with obstructed bronchus.

b) Collapse with patent bronchus—Tubular breath sound, bronchophony with whispering pectoriloquy, and occasionally coarse crepitations are heard.

* *Injlbrosis, the onset is chronic and the chest wall is retracted in comparison to collapse of the lung where the onset is acute and the chest wall is flattened. Drooping of the shoulder, flattening of chest or crowding of ribs (on affected side) are commonly found in fibrosis, and may be seen in collapse of prolonged duration.*

****** Past history—Tuberculosis, mumps/measles/whooping cough in childhood, joint pain, symptoms regarding bronchogenic carcinoma should be enquired into.

Types of fibrosis of the lung :

a) Focaljibrosis—Coal-worker's pneumoconiosis, asbestosis, silicosis.

b) Replacement fibrosis—Tuberculosis, bronchiectasis, radiation fibrosis, lung abscess, pulmonary infarction, necrotizing pneumonia.

c) Interstitialjlbrosis—This is the fibrosis of the alveolar walls, which affects both lungs diffusely (fibrosing alveolitis). It is commonly associated with systemic collagen diseases like rheumatoid arthritis, scleroderma etc.

* Patient is more symptomatic in a) and c) but physical signs are more pronounced in b).

** Fibrosis of the lung of cardiac origin are mitral stenosis and multiple pulmonary infarcts.

What is 'diffuse fibrosis' of the lung ?

1. Acute—Hamman-Rich disease (acute onset, progressive course, unknown aetiology).
2. Chronic—Fibrosing alveolitis.

Diffuse fibrosis of the lung (chronic) is diagnosed clinically but confirmed by lung biopsy. The findings are bilateral and diffuse (not localised).

Classical features of fibrosing alveolitis at the bedside :

1. Progressive disabling dyspnoea, orthopnoea; tachypnoea; persistent dry cough; weight loss and fatigue.
2. Constitutional symptoms like arthralgia (rare).
3. Central cyanosis, polycythemia.
4. Clubbing.
5. Bilateral diminution of chest movement; diminished vesicular breath sound.
6. Leathery crepitations (velcro crepitations linked to unzipping of velcro)—Chiefly end-inspiratory crepitations, uninfluenced by cough, heard particularly over both the lower zones at back (bibasal crepitations).
7. Signs of pulmonary hypertension, RVF or chronic cor pulmonale in late stages.

* These patients are usually corticosteroid-responsive.

How do you classify collapse of the lung ?

(A) ABSORVriON OR ACTIVE COLLAPSE—The bronchus is either obstructed by mucus plugs or bronchial casts, foreign body, blood, neoplasm (endobronchial), or compressed from outside by enlarged glands, aneurysm, neoplasm (exobronchial), or by neoplasm arising within the bronchial wall (intrabronchial). The trachea is shifted to the same side due to more negative intrapleural pressure.

(B) COMPRESSION OR PASSIVE COLLAPSE—The bronchus remains patent, and is developed as a result of pleural effusion, empyema, pneumothorax, hydropneumothorax, pyopneumothorax or very large neo plasm. The trachea is pushed to the opposite side as a result of positive intrapleural pressure.

* Previously absorption collapse was known as atelectasis of lung'.

** In clinical practice, unless or otherwise qualified, collapse means absorption collapse (i.e., the model case described above). Whereas, signs of compression collapse literally means signs of pleura! effusion/ pneumothorax/hydropneumothorax where the underlying lung remains silent.

*** Collapse may again be divided by ;

- Central (mass lesion)—bronchus is obstructed: all signs of collapse are dampened.
- * Peripheral—bronchus remains patent; bronchial breath sound and bronchophony +.

Common causes of absorption collapse in relation to age :

a) Neonates—meconium aspiration, b) Children—foreign body aspiration,

c) Adults—bronchial adenoma, d) Old age—bronchogenic carcinoma.

What is 'middle lobe syndrome'?

It is the recurrent or persistent atelectasis of right middle lobe caused by compression of bronchus as a result of enlarged lymph nodes arising out of tuberculosis or malignancy. The diagnosis is confirmed by CT scan or bronchoscopy.

Clinical features of bronchiectasis :

1. Symptoms—
   a) Cough with expectoration—Copious, purulent, foetid, often related to change of posture, most prominent in the early hours of the morning while arising from bed or at the time of retiring to bed.
   b) Haemoptysis.
   c) Systemic symptoms like febrile episodes, malaise, anorexia, loss of weight.
   d) Breathlessness.
   e) Pain in the chest (due to pneumonia or dry pleurisy).
2. General survey—
   a) Dyspnoea.
   b) Clubbing.
   c) Anaemia, fever, halitosis.
   d) Central cyanosis in bilateral and extensive disease.
   e) Undernutrition.
3. Examination of the chest—There may be no abnormal sign in the chest. The signs depend on the size of affected bronchi, airway patency and viscosity of secretions. One may get the signs of (i) bronchitis (ii) fibrosis iii) consolidation (iv) collapse (v) cavitation or, rarely vi) pleural effusion.

The physical signs often **change after a large bout of cough.** Breath sound may be vesicular with prolonged expiration to high-pitched bronchial (tubular) in type. Sharp metallic or bubbling 'leathery', coarse crepitations are characteristic. All the **signs are predominantly basal and bilateral.**

Clinical features of pulmonary tuberculosis (post-primary) :

(A) Symptoms :

a) Evening rise of temperature, anorexia, loss of weight, lassitude, night sweats, palpitation.
b) Persistent cough; sometimes there is sputum production (in advanced stage).
c) Haemoptysis.
d) Chest pain (due to pleurisy).
e) Breathlessness.

(B) Signs :

Initially there may be no abnormal physical sign in the chest. The earliest sign is often post-tussive crepitations heard in the apex of the lung. Gradually the physical signs of tuberculous consolidation, cavitation, fibrosis, pleurisy, pleural effusion or spontaneous pneumothorax may develop.

Clinical stigmata of evidence of past or present tuberculous infection :

- Erythema nodosum.
- Phlyctenular keratoconjunctivitis.
- Old scar or sinus reflecting the foot prints of tuberculous lymphadenopathy.
- Scrofuloderma.
- Beaded and thickened sparmatlc cord.
- Gibbus

Effects of asbestos exposure in respiratory system :

At least 10 years of moderate to severe exposure to asbestos has occured before the disease becomes overt. It affects persons working in asbestos mines, textile industries, manufacturer of fireproof and shipyard workers. The manifestations are :

1. Asbestosis (progressive pulmonary fibrosis)—Dry cough, chest tightness, dyspnoea on exertion, clubbing and end-inspiratory crepitations at lung bases.
2. Benign pleural plaques, diffuse pleural fibrosis.
3. Benign pleural effusion.
4. Bronchogenic carcinoma—Usually adenocarcinoma.
5. Mesothelioma of pleura (and peritoneum)—Produces malignant pleural effusion.
6. Laryngeal carcinoma.

* So, proper attention must be paid while enquiring for occupational history, both present and past.

** One year's exposure to asbestos in teens may even result in mesothelioma in the fifth decade.

What is 'pack year' ?

It is the duration of smoking in years multiplied by number of packets of cigarettes smoked per day, e.g., one pack of cigarette (containing 20 cigarettes) smoked per day for 30 years make 30 pack years. The'importance lies in the fact that risk for development of bronchogenic carcinoma is much increased when the pack years exceed 40. Pack year has also direct relationship with development of COPD.

Position of mediastinum in collapse of the lung :

In a wider sense, collapse of the lung means absorption collapse.

(A) Absorption collapse—Mediastinum is pulled to the affected side.

(B) Compression collapse—Mediastinum is pushed to the opposite side.

* Read the section on 'Pleural effusion' for better understanding.

Bronchopulmonary segments in the lung :

Bronchopulmonary segment is a part of lung tissue supplied by one segmental bronchus, along with corresponding pulmonary artery and pulmonary vein. There are 3 lobes (upper, middle and lower) in right, and 2 lobes (upper and lower) in left side of lung. Right lung have 10 and left lung have 9 bronchopulmonary segments (medial basal segment is usually missing in left side).

Investigations you like to perform (fibrosis or collapse) :

1. Blood—Raised ESR, polycythemia; rheumatoid factor, antinuclear antibodies or circulating immune complexes may be found in fibrosing alveolitis.
2. Chest X-ray (PA view; lateral view is also required to determine the segment or lobe involved)—
   (i) Homogeneous shadow of the collapsed lung.
   (ii) Displacement of mediastinum towards the affected side.
   (iii) Retraction of hemithorax on the affected side.
   (iv) 'Honeycomb lung' in fibrosing alveolitis,
   (v) Tenting of diaphragm in basal collapse or fibrosis in the base.
   (vi) In compression collapse—The aetiology of compression is seen in the X-ray plate e.g., pneumothorax, pleural effusion.
3. High resolution CT scan—Shows honeycombing and scarring, which are marked peripherally in both the lungs. CT scan helps in early and confirmed diagnosis.
4. Lung function tests (specially in fibrosis)—Shows restrictive type of defect i.e., FEV/FVC is approximately 90% (in obstructive defect i.e., in bronchial asthma, FEV/FVC is near about 40-50%).
5. Bronchoscopy—To identify the cause of obstruction or to get a biopsy.
6. Rarely lung biopsy is needed to diagnose fibrosing alveolitis (i.e., the biopsy specimen shows patchy foci of interstitial fibrosis).

NB In a 'Short case', a student has to examine the patient for **general survey and one particular system asked for:** the candidate is usually not allowed to take the history and thus, need not write the case history sheet. Commonly, the time alloted is 10-15 minutes.

Case 30

SUPERIOR MEDIASTINAL SYNDROME

Synonyms :

1. Superior vena caval (SVC) syndrome.
2. Superior vena caval obstruction.
3. Reversed congestive cardiac failure (i.e.. as upper half of the body is swollen).

What is SVC ***syndrome*** ?

There is obstruction of SVC due to compression and/or infiltration by superior mediastinal tumours which result in characteristic features like headache, breathlessness, plethora with oedema of the face, dilatation of collateral veins in upper thorax and conjunctival oedema.

Common causes of SVC ***syndrome :***

Malignant diseases are the principal cause of this syndrome and therefore, the prognosis is very bad. The causes are,

1. Bronchogenic carcinoma (75%).
2. Lymphoma (20%).
3. Giant aortic aneurysm.
4. Retrosternal goitre.
5. Tumours of the thymus.
6. Fibrosing mediastinitis (methysergide-induced).
7. Metastatic tumour e.g., from carcinoma of breast.
8. Dermoid cyst.
9. Persistent left-sided SVC.
10. Thrombosis of SVC.
11. Teratoma.
12. Pericardial cyst.

Different modes of presentation (symptoms) :

The mediastinal mass usually compresses three tubes, three nerves and three vessels. In bronchogenic carcinoma and lymphoma, the mediastinal structures are involved by spread to mediastinal lymph nodes and sometimes by dii ect extension of the tumour itself.

(A) TUBES :

a) Oesophagus—The patient may present with dysphagia and as it is a mechanical compression of the oesophagus, patient complains of difficulty in swallowing food mainly with solids (later on solid plus liquid).

b) Trachea Respiratory distress, stridor and paroxysmal cough.

c! Bronchus—As such, obstruction of the bronchus from a mediastinal mass (due to bronchogenic carcinoma) is not very common. *The manifestations of obstruction depend on the nature of obstruction (complete or partial), absence or presence or secondary infection, and its effect on pulmo nary Junction.* When a large bronchus is 'completely' obstructed, there is absorption collapse or atelectasis, and the patient may complain of breathlessness and pain chest. If the collapse involves a smaller portion of lung, there may be no respiratory difficulty. In case of 'partial' obstruction ol bronchus, there is development of obstructive emphysema (the airflow resistance is incr eased in expiration than during inspiration and causes overdistension of the lung, lobe or segment) and thus, respiratory embarrassment may be present. Secondary infection of the lung is very common in this situation and the patient may present with features of pneumonia

(B) NERVES:

aj Recurrent laryngeal nerve The left-sided nerve is commonly involved due to its lower station than the right. The right-sided recurrent laryngeal nerve remains high up and is usually not compressed by the mediastinal mass. The patient presents with,

(i) Hoarseness of voice,

(ii) Bovine cough (explosive nature of cough is lost), and

(iii) Stridor (common in bilateral palsy).

b) Phrenic nerve—There may be breathlessness (mainly in supine position) and sometimes, respiratory failure is present due to diaphragmatic paralysis.

U C ervical sympathetic trunk (Homer's syndrome)—Patient complains of partial drooping of the upper eyelid and loss of sweating on the affected side of face

(C) VESSELS :

a) Superior vena cava—the patient usually complains of,

(i) Swollen and puffy face,

(ii) Headache,

(iii) Visual disturbances,

(iv) Alteration in the state of consciousness, black -out, and

(iv) Rarely convulsions.

b) Azygos vein—Symptoms of pleural effusion (on the side of compression, i.e., right-sided).

c) Lymphatics—Thoracic duct or small lymph channels may be obstructed. There are presence of,

(i) Parietal oedema of upper thorax, and

(ii) Symptoms of pleural effusion (chylothorax).

* Pericardial effusion may develop.

Physical findings in a case of SVC syndrome (signs) :

(A) TUBES :

a) Oesophagus—Dysphagia may be demonstrated if the patient is allowed to eat some biscuits.

b) Trachea—There may be intercostal suction, central cyanosis and presence of stridor.

c) Bronchus—

(i) Signs of absorption collapse (in obstructed bronchus) is found, i.e., there is diminished movement on the affected chest, shifting of the mediastinum to the affected side, impaired note on percussion, absent breath sound with diminished or absent vocal resonance, and usually without any adventitious sound.

(ii) Rarely, the cause of SVC syndrome (e.g., bronchogenic carcinoma or lymphoma! may produce pleural effusion and thus, there may be compression collapse. The signs are diminished movement on the affected chest, shifting of the mediastinum to the opposite side, stony dullness on percussion, diminished vesicular or tubular breaLh sound, diminished vocal resonance or bronchophony, aegophony, whispering pectoriloquy with few coarse crepitations (usually the mediastinum remains in the middle or on the same side, and rarely on the opposite side — for better understanding, read the section on Pleural effusion').

(iii) Rarely, a large mediastinal lymph node (at bifurcation of trachea) in lymphoma or the mass in bronchogenic carcinoma may transmit the tracheal sound and as a result of this, there is production of tubular (bronchial) breath sound, whispering pectoriloquy and rarely aegophony (heard in the interscapular region). This Is known as D' **Espine's sign (posterior).**

* Dull note on percussion over 2nd intercostal space anteriorly (right or left) with presence of tubular (bronchial) breath sound is anterior D' Espine's sign.

(B) NERVES :

a) Recurrent laryngeal nerve—

(i) Ask the patient his name or address, and observe the hoarseness of voice.

(ii) Ask the patient to cough for demonstration of bovine cough.

(iii) Indirect layftgoscopy shows the position of the affected vocal cord (commonly left-sided) in paramedian position (i.e., cadaveric position) during phonation.

b) Phrenic nerve—Read the section on 'Hydropneumothorax' for phrenic nerve palsy.

c) Cervical sympathetic trunk—Horner's syndrome is characterised by,

(i) Pseudoptosis,

(ii) Constriction of pupil (miosis),

(iii) Anhidrosis (lack of sweating) of ipsilateral face, neck, arm and upper chest,

(iv) Enophthalmos, and

(v) Loss of ciliospinal reflex.

(C) VESSELS :

a) Superior vena cava—

(i) **Dilatation** of **tortuous** collateral **veins** in **upper chest, arm, neck** and often in temple region of the face; even small venules may be prominent over chest wali.

(ii) Oedema of the face (moon face), neck, arm and upper thorax; engorged sublingual veins.

(iii) Plethora of the face (often there is cyanotic hue of face, neck, arm and hands).

(iv) **Engorged and non-pulsatile internal jugular vein (with negative hepato-juguiar reflux;.**

(v) Conjunctival oedema (chemosis), and subconjunctival haemorrhage.

(vt) The flow of blood in the collateral veins is from 'above downwards' (read the section on 'Prominent veins with venous hum' for demonstration of venous flow).

(vii) There may be disturbed sensorium.

b) Azygos vein—Rarely, there may be pleural effusion (on the side of compression of the azygos vein, i.e., right-sided).

c) Lymphatics—

(i) Chylothorax.

(ii) Non-pitting oedema of upper thorax (front and back).

* Rarely, there is presence of pericardial effusion in SVC syndrome. On an anatomical basis, right-sided tumours produce this syndrome much more frequently.

** Two other features of SVC syndrome are bilateial papilloedema and exophthalmos. Remember, ail the features in this syndrome increase after leaning forward (rel : breathlessness in pericardial effusion often diminishes after adopting Mahammedan's prayer position.

*** Chest wall veins are not prominent if SVC obstruction occurs above die joining of azygos vein.

**** $Q_{ne\ m}$ust look for cervical lymphadenopathy, clubbing, radiation mark in chest and pulsus paradoxus.

Differential diagnosis you will consider :

Mention the causes of 'Moon face'. Other D/D of SVC syndrome are constrictive pericarditis, CCF and chronic cor pulmonale.

How do you like to investigate the patient ?

1. Blood examination—Hb, TC, DC, ESR, sugar (F).
2. Chest X-ray—PA view (lateral view helps to identify the anatomical site of the tumour).
   (i) **Mediastinal widening.**
   (ii) Atelectasis.
   (iii) Dense irregular hilar opacity which is extending peripherally (bronchogenic carcinoma).
   (iv) Pulmonary parenchymal opacity (bronchogenic carcinoma).
   (v) Pleural effusion, elevation of the hemidiaphragm (phrenic nerve palsy), rib erosion.
   (vi) Rarely, pericardial effusion.
3. Indirect laryngoscopy to see the paramedian position of left-sided vocal cord on phonation in a patient with hoarseness of voice.
4. Cytologicai examination of sputum, bronchial brushings or washings for malignant cells.
5. FNAC or excision biopsy of scalene node, Virchow's gland or any palpable lymph node.
6. Pleural fluid aspiration and pleural biopsy.
7. Scanning of lung or thyroid (by using I^{131} or technetium 99m for retrosternal goitre), or ***CT scan of the thorax with FNAC,*** if possible.
8. Barium swallow examination shows oesophageal displacement or compression.
9. Bronchoscopy, oesophagoscopy and mediastinoscopy are usuaily contraindicated in the acute stage due to risk of bleeding. If the obstruction is relieved by treatment (radiotherapy or corticosteroid), one skilled clinician may go through, the investigations for tissue diagnosis.

How you are going to manage a patient of SVC syndrome ?

The SVC syndrome is a serious medical problem and should be managed promptly. Unless the clinicai examination and non-invasive diagnostic procedures suggest a benign cause of obstruction, or unless there is availability of tissues elsewhere in the body for biopsy (e.g., lymph node biopsy), the patient should receive irradiation or chemotherapy (cyclophosphamide) before attempts are made to come to a tissue diagnosis. Elevation of head and oxygen therapy may give temporary symptomatic relief; ventilatory support may be necessary. Corticosteroids and diuretics are often used initially to reduce oedema at the site of obstruction. Tracheal obstruction needs emergency radiotherapy. When a tissue diagnosis is made afterwards, the patient is managed accordingly.

What is inferior vena caval (IVC) syndrome ?

a) Extraluminal compression—Ascites, tumours in the abdomen and pelvis, tuberculous plastic peritonitis, pregnancy.

b) Intraluminal compression — Malignancy of kidney or adrenals, thrombosis extending from pelvic veins, membranous obstruction of IVC, OC pills, myeloproliferative diseases, hypercoagulable states.

Clinical features—

1. Pitting oedema of legs with dilated varicose veins; local cyanotic hue.
2. Collateral veins are seen over the abdomen, flanks and back.
3. Swollen and oedematous buttocks and groin.
4. Sometimes there is presence of ascites (ascites follows pedal oedema).
5. Direction of blood flow is from 'below upwards'.
6. Stasis ulcer on the legs with pigmentation in chronic cases.

Conclusion :

In a patient of SVc. syndrome, obstruction of bronchus is rarely seen in comparison to compression of vein and nerve (very common). In the SVC syndrome, both direct (dull note on sternal percussion and D Espine's sign) and indirect (vein and nerve compression) effects are observed though the indirect effects are more commonly encountered. Engorged and non-pulsatile neck vein is a very important clinical clue. Always percuss the sternum in a suspected case of SVC syndrome.

ibe typical patient may have dyspnoea, stridor, puffy and plethoric face with periorbital oedema, and tortuous veins over chest wall.

Case 31

ASCITES

What is ascites ?

Ascites refers to collection of 'free' fluid within the peritoneal cavity. Normally, there is virtually no fluid present in the peritoneal cavity. The Greek word 'askitos' means bag or sac.

Causes of ascites :

(A) ASCITES WITH ANASARCA—

1. Congestive cardiac failure (CCF).
2. Nephrotic syndrome.
3. Hypoproteinaemia with severe anaemia (nutritional).
4. Pericardial effusion.
5. Constrictive pericarditis.
6. Myxoedeina.
7. Filariasis.
8. Protein-losing enteropathy (due to hypoproteinaemia).
9. Epidemic dropsy.

(B) ASCITES WITHOUT ANASARCA (ONLY ASCITES)—

1. Cirrhosis of liver (may lead to anasarca).
2. Peritonitis—
   - (i) Acute pyogenic peritonitis.
   - (ii) Tuberculous peritonitis.
   - (iii) Malignant peritonitis.
   - (iv) Spontaneous bacterial peritonitis (SBP).
3. Portal vein thrombosis.
4. Meig's syndrome.
5. Pancreatic ascites (e.g., from acute pancreatitis).
6. Hepatic vein thrombosis (Budd-Chiari syndrome).
7. Rupture of hollow viscus within abdomen.
8. Lymphoma or leukaemias.
9. Chylous ascites.
10. Haemoperitoneum following trauma.

IX. Rare - Vasculitis, peritoneal dialysis, IVC obstruction.

* Common causes of ascites are 1, 2, 3 of (A) and 1, 2 of (B).

** In hypoproteinaemia with severe anaemia, oedema is out of proportion to ascites.

**** Ascites in cirrhosis of liver is mainly due to hepato-cellular failure (i.e., hypoalbuminaemia) and partly due to portal hypertension.*

Points to be asked in history in a patient with ascites :

1. Onset (sudden or gradual) and progress (slowly growing, stationary or progressive).
2. Past history of jaundice, haematemesis or melaena, alcoholism, fever (see below).
3. Pain and tenderness (tuberculous peritonitis, acute pancreatitis).
4. Loss of appetite.
5. Loss of weight.
6. Cough with or without haemoptysis.
7. Swelling of legs or face.
8. Respiratory distress (huge ascites, CCF, pericardial diseases).
9. Prolonged diarrhoea (protein-losing enteropthy), alteration of bowel habit (large gut malignancy) or alternate diarrhoea and constipation (intestinal tuberculosis).
10. Any sort of oliguria, paraesthesia in lateral thigh, or heart bum present or not.

Important past history in a patient with ascites :

1. Alcoholism.
2. Jaundice.
3. Haematemesis or melaena.
4. Alteration in bowel habit.
5. Tuberculosis.
6. Haematochezia.
7. Pain abdomen (acute pancreatitis).
8. Loss of weight (malignancy).
9. Past H/O rheumatic fever or respiratory distress.
10. Fever (tuberculous or pyogenic peritonitis).

Why do you say ascites in this case ?

1. There is generalised swelling of abdomen; particularly the flanks are full; umbilicus is everted (or flushed with the abdominal wall) with a transverse slit. Maximum girth of abdomen is at the level of umbilicus.
2. Fluid thrill is present.
3. Shifting dullness confirms the diagnosis of ascites.

What are the clinical features of ascites ?

Symptoms—

1. Progressive swelling of abdomen with gain in weight.
2. Aching pain all over the abdomen due to stretching; bloated feeling in abdomen.
3. Dyspnoea and even orthopnoea (in massive and rapid collection of fluid).
4. Swelling of lower limbs (due to CCF, cirrhosis of liver or functional IVC obstruction).
5. Paraesthesia in the distribution of lateral femoral cutaneous nerve (meralgia paraesthetica).
6. Oliguria.
7. Dyspepsia, heart burn (due to GERD).

Signs —

(A) GENERAL SURVEY—

1. The patient may be in propped-up position due to dyspnoea.
2. Obvious swelling of abdomen.
3. Neck veins may be engorged (due to hypervolaemia).
4. Bipedal pitting oedema.

(B) ABDOMEN—

1. Swelling of abdomen and there is fullness in the flanks. The skin looks stretched and shiny.
2. Divarication of recti (if the patient tries to get up from supine position against resistance, the linea alba bulges between the two recti) may be present; there may be presence of abdominal (umbilical) herniation or abdominal striae (striae albicantes). Subcostal angle is wide, and lower ribs are pushed upward and outward. There is prominence of hypogastrium in erect posture.
3. There may be prominent veins around umbilicus or in epigastrium where the blood flow is away from the umbilicus (portal hypertension—in case of cirrhosis of liver)—more common. Prominent veins in flanks of abdomen may also be seen where the blood flow is from below upwards {functional IVC obstruction by ascites itself—less common).
4. Umbilicus—Flushed or everted with transverse slit; may have umbilical hermia.
5. Fluid thrill—Present.
6. Shifting dullness—Present.
7. Measurements—
   a) Maximum girth of abdomen is at the level of umbilicus.
   b) Spino-umbilical distance (line joining anterior superior iliac spine and umbilicus) is more or less equal on both sides.
   c) The distance between xiphisternum and umbilicus is more than the distance between umbilicus and symphysis pubis.
8. Auscultation—Venous hum over the distended veins around umbilicus may be audible in cirrhosis with portal hypertension.

;C) RESPIRATORY SYSTEM—

1. Basal collapse—Diminished movement, impaired note on percussion, diminished vesicular breath sound and crepitations may be heard in the lower part of chest on both sides.
2. Hydrothorax (commonly right-sided) due to leakage of ascitic fluid through defects (pores) in the right dome of diaphragm for lymphatic channels; may be bilateral.

(D) ***CVS—***

1. Apex beat—Deviated upward and outward.
2. There may be diffuse pulsation over the precordium.
3. Soft systolic murmur in pulmonary area may be present (due to associated severe anaemia).

(E) NERVOUS SYSTEM—

Nothing particular. There may be features of hepatic encephalopathy.

(F) GENITOURINARY SYSTEM—Scrotal oedema or hydrocele may be evident as secondary effects of ascites (rare) or as a clue to aetiological (e.g., nephrotic syndrome) diagnosis of ascites.

N.B. : With the above mentioned signs (for ascites per se), there are presence of other features due to

specific aetiology of ascites. Thus, one should always be careful in searching the other stigmata of cirrhosis of liver, CCF etc in a case of ascites. P/R and P/V examinations should be done.

* A **long-standing ascites** is recognised by striae albicantes, divarication of recti (may be associated with visible peristalsis underneath), umbilical hernia and puncture marks.

** Palpate liver, spleen or any other abdominal viscera by dipping method, in the presence of ascites.

Examination for fluid thrill :

1. The patient lies supine with thighs flexed. Either the patient or a third person (in the case of a child patient) will *put his ulnar border of right hand vertically, with fingers directing caudally, over the abdomen in the midline* (sagittal plane) firmly to prevent transmission of impulse or vibration through the abdominal parietis. The impulse passing through the posterior abdominal wall is dampened by the bed.
2. Place the left palm over the left flank and sharply tap or flick the right flank with the fingers of right hand; a fluid thrill or 'shock wave' is felt by the left palm as a definite impulse. The same manoeuvre is now done by tapping the left flank while the impulse is felt over the right flank.

* Preferably, the bladder should be evacuated before performing the test.

Where do you get fluid thrill ?

Fluid thrill is present in the presence of fluid in the peritoneal cavity **whether it is encysted or free.** Thus, fluid thrill may be found in,

1. Ascites (tense),
2. Ovarian cyst,
3. Hydramnlos,
4. Rarely in large hydronephrosis,
5. Any large intra-abdominal cyst,
6. Obesity (false positive).

Essential criteria for positive fluid thrill :

1. Fluid should remain **under tension** (most important).
2. Large amount of fluid (it is often said that at least 2 litres fluid is necessary to elicit fluid thrill).

N.B. ; Fluid thrill may not be present if there is small collection or the fluid is not under tension.

Is fluid thrill a definite sign for ascites ?

No.

Surest sign for presence of free fluid in the peritoneal cavity (ascites) :

'Shifting dullness' (in addition, paracentesis abdominis also confirms the diagnosis).

How do you elicit shifting dullness ?

Principle ; The presence of ascites can be confirmed by altering the posture of the patient and demonstrating a change in the position of air-fluid interface (i.e., the distinct transition zone between tympany and dullness). Shifting dullness has both good sensitivity and specificity.

This method may also be called as 'shifting tympanicity'.

1. The patient lies supine with thighs flexed. The patient is asked to evacuate his/her bladder (full bladder will unnecessarily hamper the midline percussion). Try to exclude pregnancy.
2. Now palpate the abdomen (by dipping method) for any visceromegaly (liver, spleen, kidney lump etc.). If any viscus is enlarged, try to avoid percussion over them.
3. Starting from the eigastrium, percuss (usually light to medium percussion) in the midline from above downwards. Note the maximum point of tympanicity. Usually it is somewhere around the umbilicus.
4. Now percuss laterally to one side (suppose, the right side) from the maximum point of tympanicity noted in the midline, keeping the pleximeter finger parallel to long axis of abdomen or arbitrary border of the fluid level. When you get a dull note, mark it with a skin pencil but keep on percussing towards the flanks to diagnose that the dullness is continuous and not a localised one due to colonic growth, faecolith etc., and again return to the first noted point of dullness.
5. Now turn the patient to left lateral position, keeping the fingers in the point of dullness noted in the right flank. Turning is done in such a way that your fingers in the right flank become the highest point of the patient's body. Now wait for few seconds (at least 10 seconds, usually 30 seconds) for the intestine to float up.
6. Percuss the dull point noted in the right flank, which will reveal tympanitic resonance. Go on percussing upto the end point of the right flank which also shows tympanitic resonance; next go upto the midline and now the midline which was tympanitic initially will be dull on percussion.

So, the dullness in the right flank changes to tympanitic note and the midline becomes dull from the original tympanicity. This is shifting dullness.

7. The same procedure is repeated in the left flank starting from the midline.

Minimal fluid required for demonstration of shifting dullness :

It is said that at least 1 / 2 to 1 litre of fluid is required to demonstrate shifting dullness.

Absent shifting dullness in the presence of fluid in the abdomen :

The possibilities are :

1. Fluid is encysted i.e., ovarian cyst or loculated ascites in tuberculous peritonitis.
2. Small collection of free fluid.
3. Rarely in massive tense ascites.

Massive splenomegaly or hepatomegaly with ascites : how to elicit fluid thrill ?

It is often very difficult to form an opinion regarding fluid thrill in the presence of visceromegaly. One should not place the palm over the enlarged organ (may dampen the 'shock wave' of positive fluid thrill), rather one should tap from that side while the palpating hand is kept on the other side (patient's hand remains vertically in the midline). In gross hepatosplenornegaly, fluid thrill may remain inconclusive.

Shifting dullness present but there is no free fluid in the abdomen :

False positively in paralytic ileus (rare).

What is meant by free fluid' in ascites :

The fluid shifts or changes its position with the intestinal air with change of posture which never occurs in encysted fluid and thus, shifting dullness is never found in encysted fluid in the abdomen.

In performing shifting dullness why do we percuss the midline first ?

While the patient lies supine, the intestine floats in the midline (in health as well as in ascites), which gives tympanitic note on percussion. To follow the cardinal rules of percussion, we percuss the midline first (tympanitic) and then the flanks (dull) —i.e., we percuss from 'more resonant to less resonant' area.

Result of percussion over an ovarian cyst :

Fluid thrill may be present but shifting dullness is always absent. In a large ovarian cyst, the midline will be totally dull on percussion. But in a moderate ovarian cyst, upper part of the midline may be tympanitic though the shifting dullness is always absent. In an ovarian cyst, flanks are resonant on percussion.

* If the midline is totally dull on percussion (e.g., large ovarian cyst), it is not necessary to perform the next steps of shifting dullness i.e., if the midline is dull on percussion, shifting dullness will be absent.

** Absence of fluid thrill and/or shifting dullness does not exclude the presence of ascites.

Clinical detection of'small amount' of free fluid :

(A) PUDDLE SIGN— First percuss the abdomen in supine position where you will get a tympanitic note in the midline.-Now place the patient on the hands and knees (knee-elbow position) for 5 minutes and percuss (with difficulty) over the dependent part of abdomen (near umbilicus) which now reveals a dull note due to shifting of fluid. Generally 300-400 ml of fluid may be clinically elicited by puddle sign and even as little as 120 ml of fluid can be detected by this method. This sign is actually elicited by auscultopercussion (placing the stethoscope over the dependent part and flicking the abdominal wall repeatedly to elicit changes in character of percussion note) which is a very complicated method. Puddle' literally means 'a small pool of muddy water'.

(B) PER RECTAL EXAMINATION—Boggy and fluctuant swelling in the dependent part due to presence of free fluid.

(C) SAME-SIDED SHIFTING DULLNESS—Very difficult to demonstrate. During the examination by conventional method of shifting dullness, turn the patient to the side of flank percussion and not to the opposite side. Now percuss the flank with difficulty which gives a dull note (here, flanks are originally resonant in supine position due to 'small' collection of free fluid).

Massive hepatosplenornegaly with ascites : how to elicit shifting dullness ?

First percuss the midline in supine position, which will elicit a tympanitic note. Now ask the patient to sit and again percuss the midline from above downwards. In the presence of free fluid in the abdomen, the lower part of midline will be dull on percussion in sitting position (bladder must be evacuated). Actually, in the presence of gross visceromegaly, clinical detection of ascites becomes very difficult.

What is 'horse shoe shaped' dullness in ascites ?

In moderate ascites, the distribution of fluid in supine position of the patient is confined to the flanks, dependent parts and the hypogastrium. Thus, in supine position the epigastrium and umbilical areas are tympanitic on percussion (due to floating of intestine) but a horse-shoe shaped dullness with concave upper broder is elicited due to dull flanks and dull hypogastrium. Percuss the abdomen in various directions from the central area of tympanicity (i.e., the umbilical region) to outwards, and demonstrate the horse-shoe shaped dullness.

Unilateral shifting dullness :

This is found in splenic rupture and is known as Ballance's sign. The blood present in the left flank becomes clotted (near the spleen) and does not shift to right side in right lateral position but the blood present in the right side (haemoperitoneum) is shifted to the left side.

Table 20 : Bedside differentiation between ascites and ovarian cyst

Features	Ascites	Ovarian cyst
1. Uniformity of swelling	1. Symmetrical	1. Asymmetrical
2. Any border seen	2. Never	2. Definite upper border is visible
3. Measurements	3.	3.
(i) Maximum girth	(i) Around umbilius	(i) Usually below the umbilicus
(ii) Spino-umbilical distance	(ii) Equal on both sides	(ii) Not equal
4. Distance between : a) Xiphisternum to umbilicus, and b) Umbilicus to symphysis pubis	4. a > b	4. b > a
5. Flanks	5. Full	5. Not full
6. Umbilicus	6. Everted and the slit is transverse	6. Everted and the slit is vertical
7. To 'get above' the swelling	7. Not possible	7. Usually possible
8. Percussion over flanks	8. Dull	8. Tympanitic
9. **Shifting dullness**	9. **Present**	9. **Absent**
10. Per vaginal examination	10. Nothing characteristic	10. Ovarian cyst is diagnosed

* Rarely, it is seen that midline percussion evokes dull note in a case of very tense ascites where the intestine is compressed (may have short mesentery too) and can not come in front. Remember, the maximum bulge in ascites is transverse in contrast to ovarian cyst where it is antero posterior.

** 'Laughing umbilicus'—When the slit of umbilicus becomes transversely stretched.

*** Ascites may be classified into mild, moderate, or tense according to the amount of fluid collected.

Abdominal measurements in ascites :

1. Abdominal girth at the level of umbilicus (maximum girth is at this level in ascites; in ovarian cyst, it is below umbilicus)—periodic measurement is helpful to assess prognosis in ascites.
2. Spino-umbilical distance—measurement is taken from umbilicus to anterior superior iliac spine on either side. Normally they are equidistant (also in ascites). Unequal distance is characteristic of tumour originating from pelvic organ (e.g., ovarian cyst).
3. Distance between xiphisternum to umbilicus, and umbilicus to symphysis pubis—in health, umbilicus lies in midposition of xiphisternum and symphysis pubis. Umbilicus is displaced down is ascites and upper abdominal mass, and displaced up in ovarian cyst or pelvic tumours.

D/D of bulging or distension of abdomen :

Commonly this is due to "7 F"—

1. Fat—Obesity (inverted umbilicus with absent fluid thrill and shifting dullness).
2. Faeces—Megacolon or low gut obstruction (symmetrical enlargement with visible peristalsis).
3. Foetus—Pregnancy (foetal parts are palpable; central dullness).
4. Flatus—Gaseous distension (flanks are not bulged; tympanitic note all over the abdomen).
5. Fluid—Ovarian cyst, ascites.

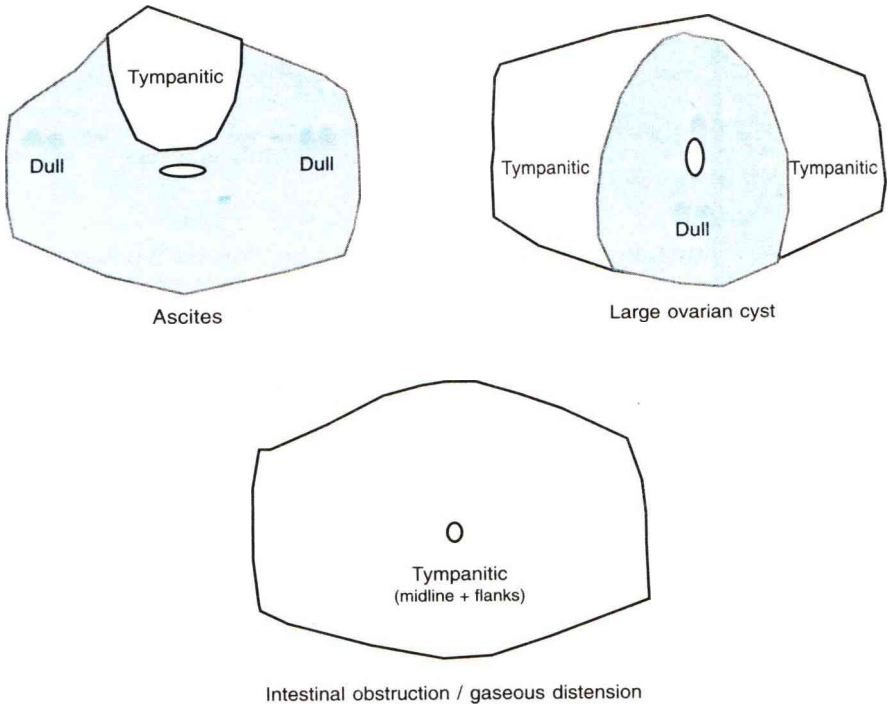

Fig. 1 : Diffuse enlargement of abdomen

6. Full (urinary) bladder (flanks are tympanitic, palpation causes pain or discomfort and desire for micturition; usually rounded cystic swelling in hypogastrium which is dull on percussion; shifting dullness is absent).
7. Fibroid or fatal tumour (e.g., polycystic kidney or massive splenomegaly).

* Distension of abdomen is of two types :
   a) Generalised (mentioned above), and
   b) Localised (visceromegaly, neoplasm).

Percussion note in different clinical conditions :

1. Ascites—Midline tympanitic, flanks dull.
2. Ovarian cyst, distended bladder and gravid uterus—Midline dull, flanks tympanitic.
3. Gaseous distension (e.g., intestinal obstruction)—Midline as well as flanks are tympanitic.
4. Obesity—Midline as well as flanks are dull.

Ascites appearing before oedema feet, or ascites > oedema feet (ascites precoax):

1. Cirrhosis of liver.
2. Tuberculous or malignant peritonitis.
3. Constrictive pericarditis or restrictive cardiomyopathy.

* In other conditions (CCF, nephrotic syndrome etc) oedema precedes ascites.

Describe the normal position of umbilicus :

1. Umbilicus lies more or less in the midway between xiphistemum and symphysis pubis.
2. Normally it is inverted and slightly retracted.
3. Normal umbilicus is a puckered depressed scar and the slit is circular, i.e., neither horizontal nor vertical (the slit is transverse in ascites, and vertical in the presence of ovarian cyst).

Causes of ***inverted and everted umbilicus*** ;

(A) **Everted**—Seen in any condition giving rise to increased intra-abdominal tension like ascites, ovarian cyst, pregnancy, umbilical hernia, hydramnios, severe gaseous distension etc.

(B) Inverted—Normally in health and in obesity (in obesity, umbilicus is buried in fat).

Observations on skin over abdomen (inspection) :

1. Moles, seborrhoeic warts, angiomas (considered normal changes).

Diagonal ear lobe crease – a strong morphological feature of coronary artery disease

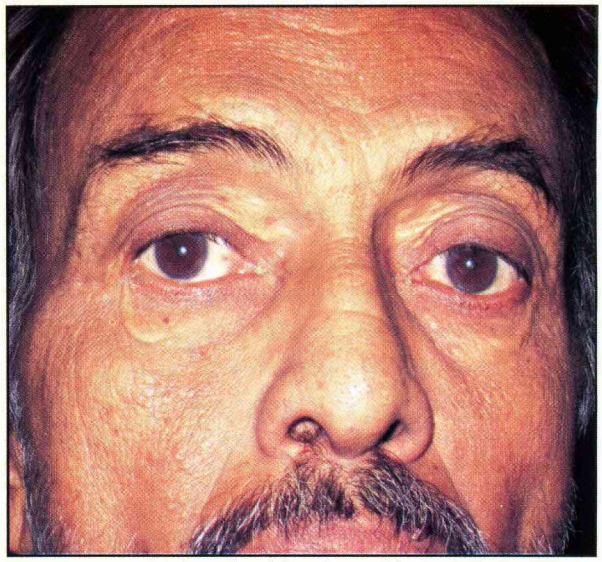

Xanthelasma (soft, yellowish, plaque-like lesion) around the eyes and cataract are seen in a patient with ischaemic heart disease; xanthelasma is regarded as a physical sign of underlying hyperlipidaemia

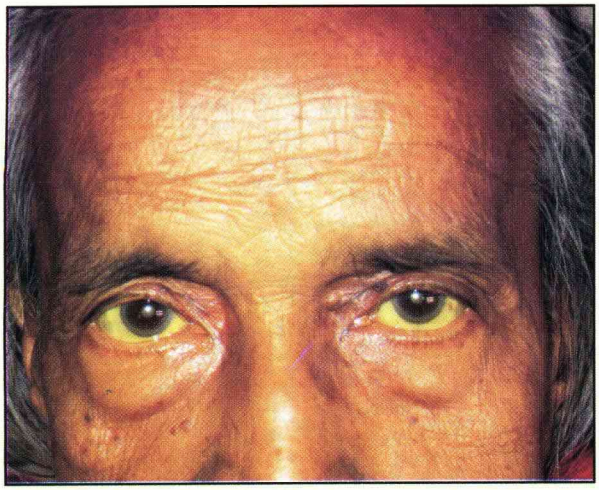

A patient having **deep jaundice** with signs of senilities, eg, **arcus senilis,** cataract and **'bags under the eyes';** few seborrhoeic warts are seen around the eyes

Bilateral **sabre tibia** in osteopetrosis (marble bone disease) – 'sabre' literally means sword with its convex curved blade

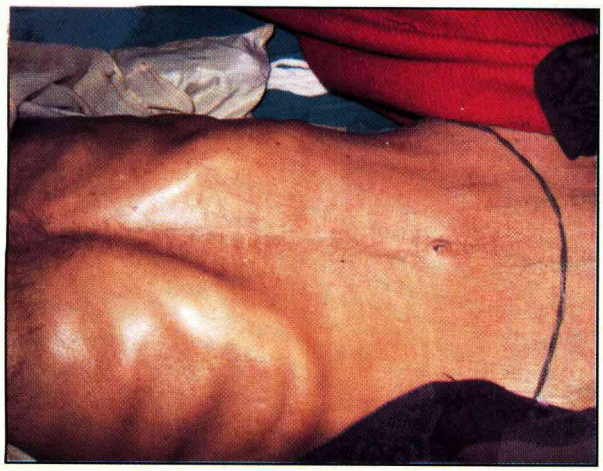

Scaphoid abdomen (sunken or boat-shaped) in advanced starvaton; wasting of intercostal muscles (due to loss of subcutaneous fat) is also noted

Flaccid bullae of **pemphigus;** rupture of blisters / bullae resulted in denuded areas in places

Erythematous, sharply-defined, plaque-like, coin-shaped, scaly (in places) lesions of **psoriasis** in anterior surface of legs in a young female

Bed sores (trophic changes) with exposed deeper tissues are seen over buttock and inferior angle or right scapula in a paraplegic patient

2. Scars, haemorrhagic spots, hypo- or hyperpigmentation (e.g., linea nigra—midline pigmentation below umbilicus seen in pregnancy), bruising periumbilically (Cullen's sign) and in flanks (Grey Turner's sign) in acute pancreatitis, vesicles of herpes zoster (may produce abdominal pain), marking for paracentesis abdominis (benzene stain or cotton seal), parietal oedema, shininess etc.
3. Striae : ***White*** striae or striae albicantes (obese persons who lost weight rapidly, following pregnancy or relieving ascites); ***purple*** striae usually represent the rupture of subepidermal connective tissue, Cushing's syndrome or prolonged steroid therapy); broad silvery lines (striae gravidarum) are stretch marks following repeated pregnancies.

Signs of 'peritonitis' :

The bedside findings are :

a) Inspection : Distension, absence of abdominal movements, absent visible peristalsis.
b) Palpation : Tenderness, rebound tenderness, 'board-like' rigidity.
c) Percussion : Loss ofliver dullness (e.g., in perforation of hollow viscus); very tender abdomen (avoid percussion).
d) Auscultation : Absence of bowel sounds.

Table 21 : Differentiation between transudate and exudate

Features	Transudate	Exudate
1. Appearance	Clear, thin; does not clot on standing	Turbid, straw-coloured, haemorrhagic, chylous, mucinous or purulent. Often clots on standing
2. Specific gravity	<1.016	> 1.016
3. Proteins	<2.5 g/dl	> 2.5 g/dl
4. Cells	< 250/mm^3 (i.e., low). Endothelial cells or mesothelial cells, and occasionally or malignant cells	> 250/mm^3 (i.e., high). Lymphocytes, neutrophils or lymphocytes are seen

* In pancreatic ascites, amylase activity in the fluid is >1000 U/L; and low glucose concentration is found in tuberculous and malignant peritonitis.

Causes of transudative and exudative ascites :

(A) Transudate— (B)

1. Cirrhosis of liver.
2. CCF.
3. Nephrotic syndrome.
4. Hypoproteinaemia with severe anaemia.
5. Protein-losing enteropathy.
6. Constrictive pericarditis.
7. Pericardial effusion.
8. Meig's syndrome.
9. Myxoedema.
10. IVC obstruction.

Exudate—

1. Peritonitis—
   (i) Pyogenic
   (ii) Tuberculous
   (iii) Malignant
   (iv) Spontaneous bacterial
2. Pancreatic ascites.
3. Budd-Chiari syndrome.
4. Lymphoma or leukaemias.
5. Rupture of hollow viscus.
6. Injury or obstruction to the thoracic duct.

***** Myxoedema, Meig's syndrome and chylous ascites may be exudative.

What is chylous ascites ?

1. Chylous—Turbid, creamy or milky peritoneal fluid due to presence of lymph. It shows Sudan Ill-staining fat globules and contains a large amount of triglycerides. Ether dissolves the turbidity of fchylous ascites.
2. Chyliform ascites—Turbid fluid due to large number of leucocytes, degenerated cells or tumour cells. Addition of alkali clears the turbidity.
3. Pseudochylous ascites—Turbid fluid due to increased amount of lecithin, globulin and calcium phosphate in the ascitic fluid.

Causes of chylous ascites :

1. Tuberculosis 2. Filariasis 3. Trauma to the abdomen 4. Intra-abdominal malignancy 5. Nephrotic syndrome 6. Congenital lymphangiectasia or obstruction to the thoracic duct (e.g., lymphoma).

Ascites with lymphadenopathy :

1. Disseminated tuberculosis,
2. Disseminated malignancy.
3. Lymphoma, and
4. ALL and blast crisis of CML.

Causes of purulent and haemorrhagic ascites :

(A) Purulent ascites—

1. Pyogenic peritonitis.
2. Pyaemia and septicaemia.
3. Ruptured amoebic liver abscess.
4. Penetrating injury to the abdomen.
5. Rarely, from pelvic inflammatory disease.

(B) Haemorrhagic ascites—

1. Abdominal trauma or traumatic tap.
2. Intra-abdominal malignancy.
3. Tuberculous peritonitis.
4. Bleeding diathesis.
5. Acute haemorrhagic pancreatitis,
6. Thrombosis of mesenteric artery.

Rapidly developing ascites :

1. Malignant peritonitis.
2. Tuberculous peritonitis.
3. Budd-Chiari syndrome.
4. Spontaneous bacterial peritonitis.
5. Lymphoma and leukaemia.
6. Chylous ascites.

Hepatomegaly with ascites :

1. Cirrhosis with portal hypertension.
2. Malignancy of liver.
3. Congestive cardiac failure (CCF).
4. Constrictive pericarditis.
5. Disseminated tuberculosis.
6. Budd-Chiari syndrome.
7. Lymphoma.

Splenomegaly with ascites :

1. Cirrhosis of liver with portal hypertension.
2. Lymphoma.
3. Systemic lupus erythematosus (SLE).
4. Disseminated tuberculosis.
5. Acute leukaemia.

Possible causes of refractory ascites :

Medical therapy does not give relief in 10-20% cases of ascites. The conditions contributing to refractory ascites are :

1. Non-compliance (not following the adequate restriction of sodium) 2. Functional renal failure in cirrhosis of liver 3. Infection 4. Spontaneous bacterial peritonitis 5. Conversion to hepatoma 6. G. I. bleeding 7. NSAID (depress diuretic effect of frusemide and spironolactone) 8. Portal or hepatic vein thrombosis. 9. Superimposed cardiac or renal disease.

Management : insufficient response to dietary and diuretic regime indicates development of refractory ascites, and is managed by salt-free albumin infusion (25 g in 3 hours), large volume paracentesis abdominis, Le Veen shunt or side to side portocaval shunt, and liver transplantation.

Ascites formation in cirrhosis :

1. Hypoalbuminaemia (principal cause)—Decreases the plasma oncotic pressure.
2. Portal hypertension (only localises the fluid in the peritoneal cavity).
3. Secondary hyperaldosteronism.
4. Increased level of ADH.
5. Increased oozing of 'hepatic lymph' from the surface of liver ('weeping liver').

Recent theory — Cirrhotic patients are always in a state of peripheral arterial vasodilatation -> diminished arterial blood volume -> rise in renin, aldosterone, vasopressin and noradrenaline -> leads to renal vasoconstriction, and sodium plus water retention. Moreover, the combination of splanchnic arterial vasodilatation and portal hypertension -> alters intestinal capillary permeability -^> promoting formation of ascites. Vasodilators are of intestinal origin (NO, substance P) and are produced in response to endotoxin and cytokines.

* It is important to remember that in the absence of concomitant hypoalbuminaemia. portal hypertension alone does not lead to ascites in cirrhosis.

Important physical findings for aetiological diagnosis in ascites :

1. Virchow's gland—Gastrointestinal malignancy; gland in other areas in lymphoma.
2. Skin changes of hepato-cellular failure—Usually from cirrhosis of liver.
3. Engorged and pulsatile neck vein—CCF, pericardial effusion, constrictive pericarditis.
4. Prominent abdominal veins—Portal hypertension.
5. Sister Marie Joseph's nodule around umbilicus—Intra-abdominal malignancy.
6. Non-pitting oedema in feet—Myxoedema, filariasis.
7. Splenomegaly—Favours the diagnosis of portal hypertension (cirrhosis of liver) mainly; also found in lymphoma, leukaemias, Budd-Chiari syndrome.

8. Hepatomegaly—Firm liver indicates cirrhosis, and a hard, tender liver indicates malignancy.
9. Tenderness in ascites—Peritonitis (tubuculous, pyogenic, malignant ascites or SBP).
10. Rectal and vaginal examination—For any rectal or pelvic malignancy, haemorrhoids.

Ascitic fluid in cirrhosis and tuberculous peritonitis :

(A) Cirrhosis of liver—it is transudate in nature.

1. CLEAR, straw-coloured, light green or bile-stained fluid.
2. Specific gravity < 1.016.
3. Protein content < 2.5 g/dl.
4. Cells < 250 cells/mm^3, mostly endothelial; Gram stain and culture—negative.
5. Serum-ascites albumin gradient (SAAG) > l.lg/dl.

(B) Tuberculous peritonitis—it is exudate in nature.

1. Straw-coloured, haemorrhagic, mucinous or chylous fluid.
2. Specific gravity > 1.016.
3. Protein content > 2.5 g/dl.
4. RBC may be present.
5. Cells—1000/mm^3, > 70% lymphocytes.
6. Serum-ascites albumin gradient (SAAG) <1.1 g/dl.
7. Centrifused deposits stained by Ziehl-Neelsen's method may show tubercle bacilli. The tubercle bacilli may be cultured from ascitic fluid. The adenosine deaminase level in fluid is increased. The diagnosis is confirmed by peritoneal biopsy under laparoscopy.

What is 'serum-ascites albumin gradient' (SAAG) ?

(A) It is the difference of albumin between serum and ascitic fluid. If the 'serum albumin' minus 'ascitic fluid albumin' (gradient) is equal to or greater than 1.1 g/dl, it suggests underlying portal hypertension. Other than cirrhosis of liver SAAG > 1.1 is a feature of CCF, Budd-Chiari syndrome, portal vein thrombosis, myxoedema and constrictive pericarditis.

(B) If the gradient is less than 1.1 g/dl, it suggests malignant ascites, tuberculous ascites, pyogenic peritonitis, pancreatic ascites or nephrotic syndrome.

* SAAG is based on oncotic-hydrostatic balance and the gradient directly correlates with portal pressure. SAAG >1.1 and ascitic protein < 2.5 g/dl is usually suggestive of portal hypertension.

Indications of abdominal paracentesis :

Paracentesis literally means removal of fluid. Actually this is divided into ***diagnostic (No. 1 below) and therapeutic (No. 2, 3. 4, 5 below) indications.*** As a whole, they are :

1. Diagnostic paracentesis (approximately 20-50 ml fluid is required).
2. Marked abdominal discomfort or cardio-respiratory embarrassment.
3. Refractory to medical therapy.
4. Danger of strangulation of umbilical hernia, if present.
5. Paracentesis may allow better abdominal examination, needle biopsy of liver, scanning or USG.

Dangers of abdominal paracentesis :

1. Sudden cardio-respiratory distress or shock in sudden and rapid withdrawal of large amount of fluid (if appears during the paracentesis, immediately stop tapping the fluid).
2. Introduction of infection (peritonitis).
3. Precipitation of hepatic coma (the compressed porto-caval shunts open up and nitrogenous materials reach the brain by-passing the liver).
4. Perforation of hollow viscus.
5. Protein depletion (5 litre of ascitic fluid may contain 50-100 g of protein).
6. Constant oozing of fluid (specially in tense ascites or malignant ascites).

Complications of ascites :

1. Collection of fluid in the pleural sac (commonly right-sided)
2. Spontaneous bacterial peritonitis.
3. Hernia (umbilical, inguinal, femoral); divarication of recti in tense and long-standing ascites.
4. Mesenteric venous thrombosis.
5. Functional renal failure.

How USG of abdomen helps in the diagnosis of aetiology of ascites ?

USG diagnoses the presence of free fluid in the abdomen and also detects the,

1. Presence of any mass, enlarged pre- or para-aortic lymph nodes.

2. Splenic enlargement.
3. Liver—Heterogenous echo-pattem (cirrhosis of liver) or diagnose malignancy of liver; oedema or inflammation of pancreas in acute pancreatitis.
4. Increased size of portal vein (>13 mm) in portal hypertension; presence of collaterals.
5. Any cyst—There may be malignant ascites with malignant ovarian cyst.
6. Enlargement of caudate lobe—Seen in Budd-Chiari syndrome.

Investigations you like to perform in a case of ascites :

1. Routine blood examinations—Hb, TC, DC, including ESR; neutrophilia indicates infection.
2. Urine examination—High albumin in urine is found in nephrotic syndrome.
3. Stool for occult blood—For abdominal malignancy and cirrhosis of liver.
4. Serum cholesterol—It is increased in nephrotic syndrome and myxoedema; diminished in cirrhosis of liver.
5. Plasma proteins—Low albumin level is seen in nephrotic syndrome, cirrhosis of liver, hypoproteinaemia with anaemia and protein-losing enteropathy.
6. X-ray of the abdomen in erect posture—Ground-glass opacity i.e., diffuse abdominal haziness with loss of psoas margins in ascites (minimally requires 800 ml fluid); not much informative.
7. **Ultrasonography of the abdomen is the best means to confirm ascites** / CT scan of the abdomen provides similar information. USG can detect as little as 30 ml of ascitic fluid.
8. Examination of ascitic fluid (physical, biochemical, cytological and bacteriological study)—Gram's stain, acid-fast stains and culture should be performed. SAAG should be determined.
9. Biopsy of Virchow's gland or any palpable lymph node — Informative in tuberculosis, lymphoma and malignancy.
10. Tests of portal hypertension—See the section on 'Cirrhosis of liver.'
11. Liver function tests (bilirubin, AST, ALT, alkaline phosphatase, albumin, globulin etc).
12. Laparoscopy (peritoneoscopy)—May reveal peritoneal deposits of tuberculosis or malignancy.
13. Liver biopsy or needle biopsy of peritoneum (in exudative ascites specially).
14. Laparotomy.

* Routine investigations like chest X-ray (pulmonary tuberculosis, cardiomegaly from CCF), ECG and echocardiography (CCF, pericardial effusion, constrictive pericarditis) should also be performed.

How to manage a case of ascites ?

Maximally, 500-700 ml fluid can be mobilised in 24 hours by the following :

1. Rest in bed mobilises ascitic fluid and helps in diuresis as renal perfusion increases in recumbency.
2. Diet—Salt restricted diet is given.
   In severe cases, sodium in the diet should be less than 10 meq/day, i.e., 200 mg (in an average case 22 meq or 440 mg of sodium Is allowed daily i.e., no extra salt, only minimum addition of salt during cooking is allowed). Total calories given dally are 2000-2200. One must be cautious while giving high protein diet if the patient shows features of neuro-psychiatric manifestations (from cirrhosis of liver). 1 g/kg of body weight of protein (only vegetable protein) is allowed unless there is any evidence of hepatic pre-coma.
3. Diuretics : they are introduced In a step-wise manner—
   - (i) Spironolactone (drug of choice)—100-400 mg/day in divided doses. Start with 25 mg thrice daily and gradually increase the dose (remember, it may produce hyperkalaemia).
   - (ii) Frusemide—40-80 mg/ day, if good response is not obtained by spironolactone alone.
   - (iii) Combination of i) and ii)
   - (iv) Other drugs like amiloride, bumetanide (1 mg/day), torasemide (5-10 mg/day) maybe tried.
4. Water intake—Restrict the intake to 1-1.5 litre daily.
5. Salt-free albumin infusion may be helpful.
6. Paracentesis abdominis—Where indicated (now-a-days, large volume paracentesis is done In cirrhosis of liver; 3-5 litre fluid is aspirated in one sitting with 6-8 g/L of salt-free albumin infusion). Dextran 8 g/L of ascitic fluid or haemaccel 125 ml/L of ascitic fluid may be infused instead of albumin to maintain the circulation.
7. Antituberculosis treatment is started in tuberculous peritonitis.
8. Treatment of other aetiologies—CCF, pericardial effusion, myxoedema, nephrotic syndrome, malignancy etc.
9. Peritoneo-venous shunt—Ascitic fluid is drained directly into Internal jugular vein and is known as Le Veen shunt.

10. Transjugular intrahepatlc portosystemic stent shunting (TIPSS) may relieve resistant ascites in cirrhosis — a stent is placed between portal vein and hepatic vein in liver under radiological control.
11. Liver transplantation—In patients with cirrhosis of liver refractory to medical treatment.

* **Guide to progress**—By weighing the patient (should not fall >1 kg /day if ascites and oedema are present, and should not fall >0.5 kg/day in ascites alone) with measuring the girth of abdomen daily (often unreliable due to gaseous distention) and checking the serum electrolytes twice weekly.

Case 32

ABDOMINAL LUMP

How do we divide the abdomen for clinical examination ?

Abdomen is conveniently divided by two horizontal and two vertical lines into **nine distinct areas.**

The **vertical lines** pass from the femoral artery below to cross the lower costal margins close to the tip of the ninth costal cartilage (or midinguinal point below to midclavicular point above). The two **horizontal lines** are:

(i) Subcostal or transpyloric (upper one), and
(ii) Inter-tubercular (lower one).

The subcostal line is formed by joining the tips of the tenth costal cartilages on either side, the transpyloric plane lies midway between suprasternal notch and symphysis pubis, and the inter-tubercular line is formed by joining the tubercles on the iliac crests.

The different areas with contents are (clockwise)—

1. Right hypochondrium (right lobe of liver, gall bladder, hepatic flexure of colon).
2. Epigastrium (left lobe of liver, stomach, transverse colon, lower and of oesophagus).
3. Left hypochondrium (fundus of stomach, spleen, tail of pancreas, splenic flexure of colon).
4. Left lumbar (left kidney and adrenal gland, left ureter, descending colon).
5. Left iliac fossa (part of descending and sigmoid colon, left ovary and fallopian tube).
6. Hypogastrium or suprapubic (urinary bladder, uterus, sigmoid colon, rectum).
7. Right iliac fossa (caecum, appendix, part of ascending colon, right ovary and fallopian tube).
8. Right lumbar (right kidney and adrenal gland, right ureter, ascending colon).
9. Umbilical area in the middle (aorta, IVC, part of stomach, duodenal loop, small intestine, head and body of pancreas, and mesentery).

What is midclavicular line (MCL) ?

It is a vertical line drawn from the centre of the clavicle i.e., *above,* the line is passing midway between the middle of the suprasternal notch and the acromioclavicular joint; the *lower* point is the midinguinal point (midpoint between anterior superior iliac spine and symphysis pubis).

In males, the MCL is approximately in the line with the nipple.

Normal shape or contour of the abdomen :

It is neither scaphoid nor distended. Some clinicians describe the shape as globular.

Causes of scaphoid (sunken) abdomen :

1. Severe dehydration.
2. Emaciation or cachexia.
3. Advanced starvation.
4. Tuberculous peritonitis.
5. Malignant peritonitis.
6. Meningitis.

* For causes of 'distension' of abdomen, read the section on 'Ascites' (page 269).

Points noted during superficial palpation of abdomen :

Prerequisites :

1. Warm your hands by rubbing (specially in winter) and trim your nails for satisfactory abdominal palpation. Stand on the right side of the patient.
2. Use the flat of the right hand (don't poke with fingers —wrist and foearm should be in same horizontal plane).
3. Prepare the patient with thigh flexed, face turned to the opposite side. The patient should breathe quietly. Exposure of abdomen is the same as done during palpation of liver.

4. Movements of the right hand should be gentle and come from slight flexion of metacarpophalangeal joints. The hand is held flat and 'moulded' to the abdominal wall.
5. Start from left iliac fossa (or from an area which is far away from site of pain) and move anti-clockwise to end in suprapubic and umbilical region. Try to examine the tender area (according to the patient) at the last.

Points to note :

1. Surface temperature.
2. Tenderness.
3. Parietal oedema.
4. Hyperaesthesia.
5. Consistency (normal elastic feel, muscle guard or rigidity).
6. Any localised lump.
7. Divarication of recti (detected by rising test).
8. Pulsation (transmitted or expansile).
9. To determine the direction of blood flow in prominent abdominal veins, and
10. Fluid thrill with girth of the abdomen at the level of the umbilicus.

Normal consistency of the abdomen :

Normally the abdomen is elastic in feel (doughy in tuberculous peritonitis); 'board-like' rigidity in peptic perforation, tetanus and black widow spider bite.

- Local guarding—tender, inflammed viscus underneath (e.g., acute cholecystitis) or localised peritonitis.
- Generalised guarding—due to anxiety.
- Rigidity—indicative of peritonitis.

How to describe the lump or mass present in the abdomen ?

Preliminary preparations of the patient are the same as done during palpation of liver. Palpation of a lump falls within the purview of'deep palpation' of the abdomen. Following points are to be described:

1. Site.
2. Size.
3. Shape.
4. Overlying skin (whether red. tense, shiny or pigmented).
5. Consistency (soft, firm, hard or cystic).
6. Margin (sharp or rounded).
7. Surface (smooth or nodular).
8. Mobility.
9. Tenderness.
10. Movement with respiration.
11. Parietal or intra-abdominal.
12. Pulsatile or not.
13. Bimanually palpable or not; ballottable or not.

(14. Lastly palpate the liver, spleen and other viscera areawise, and examine the deep tender spots (McBurney's point, duodenal point, renal angle, gall bladder point). Also examine the hernial sites, detect the presence of free fluid in the abdomen and do the P/R, P/V examinations].

An abdominal mass is palpable : what to do ?

So far as lump abdomen is concerned, the abdomen is a temple of surprise. First **aim** is to decide the organ of origin and secondly, the pathological nature of the lump.

1. **Intra-abdominal or parietal ?**
   (i) Ask the patient to raise the shoulders from the bed with arms over the chest, and then press firmly against the forehead **(rising test),** or
   (ii) Ask the patient to raise both extended legs from the bed (leg lifting test).

   Now one has to observe whether the swelling becomes less visible or disappears (intra-abdominal), or becomes more prominent or remains same (parietal). Parietal swelling like lipoma, fibroma, neurofibroma or large sebaceous cyst are of surgical interest.

   Now place the patient on **knee-elbow position.** An intra-abdominal swelling becomes more prominent but not a retroperitoneal one.
2. Next, note the **region** where the swelling is present and think of the anatomical organs which are normally present there. For example, a mass palpable in the right hypochondrium may arise from liver, gall bladder, right kidney or hepatic flexure of colon.

3. Now try to **'get above the swelling'** if the mass is in the upper abdomen and try to 'get below the swelling' If it is present in the lower abdomen. For example, in case of a hepatic, splenic, renal or gastric mass, one cannot 'get above' the swelling. Similarly one cannot 'get below' a lower abdominal mass if it arises from uterus, urinary bladder, or upper rectum.
4. **Size and shape**—Swelling arising from liver, spleen, kidney, uterus or urinary bladder do not produce any problem for diagnosis in majority of cases. But if the swelling arises from stomach, small or large gut, pancreas (retropertioneal structure) or peritoneum, it may be very difficult to diagnose; a large mass growing from the above mentioned organs usually distort their normal anatomical configuration. Note the site, shape, size by proper deep palpation.
5. **Margin, surface, tenderness, consistency and pulsation**—Smooth, round, non-tender, regular and tense swelling is usually cystic and benign whereas a hard, irregular, nodular and tender swelling is likely to be malignant in nature. A solid, ill-defined very tender mass suggests an inflammatory lesion. Note the overlying skin (any ulcer, sinus, peau d'orange appearance, redness, pigmentation) and examine for any pulsation (transmitted or expansile, judged by "Two fingers' test") present in the swelling.
6. **Movement with respiration and mobility**—Place the hand over the lower margin of the swelling and ask the patient to take deep breath. If the swelling moves up and down with respiration, it is obviously an intra-abdominal swelling (never parietal). Swelling arising from fixed organs like liver, spleen, kidneys, gall bladder and distal stomach show downward movement with respiration, however one cannot move the structures with the hand. But the swelling arising from structures having a broad base (mesentery or peritoneum) can be made to move freely by hands but they show no movement with respiration e.g., tumour of small and large gut, mesenteric cyst, secondary deposits in greater omentum.

   A totally fixed mass is usually of retroperitoneal origin, like the pancreatic mass. A side to side mobility is present in fibroid uterus which is not a feature of full bladder or swelling arising from ovary. An ovarian tumour with long pedicle is mobile in all directions.
7. **Bimanually palpable or ballot table**—Renal mass is always bimanually palpable and ballottable. Even rarely a posteriorly situated gall bladder or a mass in the postero-inferior part of right lobe of liver may be bimanually palpable.

* For palpation of viscera of pelvic origin, empty the urinary bladder.

** For a pulsatile mass, perform "Two finger's test"—Place two index fingers on two sides of the mass as far apart as the mass allows and observe whether the fingers are raised and separated (expansile pulsation due to aortic aneurysm), or only raised (transmitted pulsation due to mass in the abdomen).

D/D of cystic swellings in the abdomen :

1. Ovarian cyst—See the section on 'Ascites'.
2. Encysted ascites (commonly seen in a patient with abdominal tuberculosis).
3. Mesenteric cyst—It is a well defined cystic swelling in the abdomen, usually lying in the umbilical region. It *moves freely at right angles to the line of attachment of the mesentery* than along the line. The line of attachment of the mesentery is an oblique line starting 1 inch left from the midline and 1 /2 inch below the transpyloric plane (above), and extending upto the right sacroiliac joint (below) for 6 inches.
4. Pseudopancreatic cyst—The smooth and round cyst has no mobility and often feels very firm rather than cystic one. Fluctuation may be absent. It is usually placed centrally above the umbilicus. Past history of trauma or acute pain abdomen (i.e., acute pancreatitis) is very important clue to diagnosis.
5. Hepatic (hydatid) cyst—The mass is present predominantly in the right hypochondrium. There may be presence of **'hydatid thrill'** (place three fingers firmly over the swelling and percuss the middle finger, when an 'after-thrill' produced by displacement of daughter cysts is felt by the index and ring fingers).
6. Renal cyst and hydronephrosis—The swelling is bimanually palpable and bailottable.
7. Splenic cyst—Should be differentiated from left-sided renal lump (read the section on 'Hepatosplenomegaly'); rarely bimanually palpable.
8. Choledochal cyst—Infant or an adult patient; commonly suffers from intermittent jaundice, fever and colicky pain in right upper abdomen. The mass feels cystic and is located in right hypochondrium.
9. Hydramnios—Associated with pregnancy.
10. FULL BLADDER—Last but not the least (read the section on 'Ascites' and see page 278).

Other important physical examination in 'lump abdomen' :

1. Anaemia.
2. Jaundice.

3. Assessment of nutrition.
4. Lymph nodes (specially Virchow's gland).
5. Pedal oedema. Any free fluid present in abdomen?
6. Temperature.
7. Examination of testes (one should not forget to palpate both testes).
8. Auscultation of the abdomen for signs of intestinal obstruction.
9. Palpation of other abdominal viscera.
10. Examination of CVS, respiratory, nervous and renal system.
11. P/RorP/V examinations.

Mass or lump in the right iliac fossa :

1. Ileocaecal tuberculosis.
2. Amoebic typhlitis (inflammation of caecum).
3. Appendicular lump.
4. Carcinoma of caecum or ascending colon.
5. Tubo-ovarian mass.
6. Crohn's disease.
7. Impaction of roundworms.
8. Intussusception.
9. Dropped or unascended right kidney.
10. Lymphoma.
11. Carcinoid syndrome.
12. iliac aneurysm.
13. Malignant undescended testicle.
14. Psoas abscess.

Mass or lump in the left iliac fossa :

1. Amoebic colitis.
2. Carcinoma of colon.
3. Diverticulitis.
4. Tubo-ovarian mass.
5. Colon loaded with stool (pits on pressure).
6. Dropped or unascended left kidney.
7. Lymphoma, psoas abscess.

Discharging 'sinuses' over abdomen :

2. Faecal fistula (post-operative).
3. Tuberculosis of the intestine.
4. Intra-abdominal malignancy.
6. Crohn's disease.
5. Scrofuloderma.
6. Actinomycosis.

* ***Skin nodules*** over abdomen : neurofibroma, lipoma, malignant deposits (e.g., sister Marie Joseph's noduie around umbilicus), calcinosis, sarcoidosis.

Classification of abdominal tuberculosis :

1. Tuberculosis of gastro-intestinal tract :
   a) Ulcerative type (produces malabsorption).
   b) Hyperplastic type (produces gut obstruction).
   c) Ulcero-hyperplastic type.
2. Mesenteric lymph node tuberculosis (± tuberculosis of the mesentery).
3. Tuberculous peritonitis :
   a) Plastic type.
   b) Ascitic or exudative type; or encysted ascitic type (locuiated).
   c) Fibrous or adhesive type.

[4. Tuberculosis of other abdominal solid organs like liver, pancreas, spleen etc.l

* When the exudate is small and more fibrinous, it binds trie intestine, mesentery with or without involvement of lymph nodes, and is known as "tabes mesenteries'.

'Lymph node lumps' in the abdomen :

These lumps feel variegated (firm to hard), surface may be nodular (due to individual large lymph nodes), occasionally tender (haemorrhage within) and may be present anywhere in the abdomen but in majority of cases they are present in epigastrium, umbilical area and right iliac fossa. They show restricted movement with respiration and there is absence of mobility. The common causes are,

1. Lymphoma (commonly pre- and para-aortic nodes).
2. Mesenteric lymph node tuberculosis.
3. Metastasis from carcinoma of neighbouring organs.
4. Metastasis from carcinoma of testes (always palpate the testes).
5. Filariasis (causes retroperitoneal IjTTiphadenitis)—rare.

Cystic swelling in hypogastrium : is it urinary bladder ?

Following points should be noted carefully in a full bladder :

(A) Midline oval swelling above symphysis pubis which may reach upto umbilicus.

SB) Palpation—Normally the urinary bladder is not palpable, it feels firm or elastic in retention of urine. Application oi pressure induces pain and desire for micturition. Side to side movement of

the mass is not possible. In distension, upper and lateral borders are palpable but the lower border of the swelling can not be reached.

(C) Percussion—It is done from above downwards and the swelling is dull on percussion.

(D) Confirmation—When a simple rubber catheter is introduced through the urethra, urine comes out and the swelling disappears.

* D/D are gravid uterus (firm, side to side mobility, vaginal signs +), ovarian cyst (not truely midline, right- or left-sided), and fibroid uterus (firmer, often knobbly, vaginal signs +).

Common causes of palpable kidney :

(A) Unilateral:

1. Dropped kidney (can be pushed to its normal position).
2. Hydro- or pyonephrosis.
3. Wilms' tumour.
4. Hypernephroma.
5. Large cyst (solitary) in kidney.
6. Compensatory hypertrophy (other kidney damaged).

(Bj Bilateral:

1. Polycystic kidney (irregular surface).
2. Bilateral hydronephrosis.
3. Bilateral dropped kidney.
4. Diabetic nephropathy in early stage.
5. Amyloidosis.
6. Scleroderma.
7. Acromegaly.

How to palpate the kidneys ?

The lower pole of right kidney is commonly palpable in thin patients for obvious reasons. The right kidney is palpated from right side though the left kidney may be palpated from either side. The method of palpation goes like this :

1. Preliminary preparations of the patient are the same as done during palpation of liver. Always sit on a stool for palpation of kidneys.
2. To palpate the right kidney, place the right hand horizontally in the right lumbar region anteriorly and the left hand is placed posteriorly in the right loin region to trap the kidney bimanually with inspiration (bimanual palpation).
3. Push the right hand in a backward, upward and inward direction, and ask the patient to take deep inspiration. A firm mass may be felt in between the two hands (if kidney is enlarged).
4. Next, a sharp tap is given by the left hand placed in the loin region. The anteriorly placed right hand now feels the kidney, and the kidney then falls back (by gravity) on the posterior abdominal wall which is felt again by the left hand. This is 'ballottement' *(confirmatory for kidney lump).* Ballottement demonstrates the mobility of the kidney.
5. The left kidney is then palpated by placing the right hand anteriorly in the left lumbar region and the left hand posteriorly in the left loin (from right side); place left hand anteriorly and right hand posteriorly in palpation of left kidney from left side.

Points to note in a renal lump :

1. Site
2. Size.
3. Shape (ovoid normally).
4. Consistency (resilient or firm in feel).
5. Margins (rounded).
6. Surface (normally smooth surface; irregular in polycystic kidney).
7. Tenderness.
8. Movement with respiration (normally kidney shows slight movement with respiration).
9. Whether bimanually palpable and bailottable.
10. Tenderness over the renal angle—Patient will be seated, and the angle formed by the 12th rib and lateral border of erector spinae muscle is pressed by the ball of the thumb or thrust given by ulnar aspect of closed fist—"Murphy's kidney punch". The test is done on both sides.
11. In left-sided renal lump—Examine for band of colonic resonance over the lump (by percussion).

* Renal angle is tender in acute pyelonephritis, perinephric abscess, nephrolithiasis, tuberculosis of the kidney. *Remember, a kidney lump is bimanually palpable and bailottable.* The kidney is bailottable because it is a posterior abdominal organ.

** A transplanted kidney is diagnosed by a) (transplanted) kidney in right or left iliac fossa, b) arterio-venous fistula in forearm (i.e., vascular access for haemodialysis), and c) laparotomy scar.

D/D of renal lump :

1. Enlarged spleen.
2. Carcinoma of bowel.
3. Carcinoma or cyst of the pancreas.
4
5
6

How to palpate the gall bladder ?

The gall bladder Is palpated In the same way as the palpation of liver i.e., start palpation from right iliac fossa and move towards right hypochondrium. Normal gall bladder is not palpable. In pathological conditions, it is palpable just lateral to right rectus abdominis muscle near the tip of ninth costal cartilage. When palpable it feels firm, smooth and globular. When there is hepatomegaly, an enlarged gall bladder may be palpable in right lumbar or right iliac fossa. The comparative mobility on respiration and rounded borders differentiate it from right kidney lump.

Causes of palpable gall bladder :

1. Mucocele/empyema of the gall bladder (firm and regular swelling).
2. Carcinoma of the head of pancreas (firm and globular sweeling).
3. Carcinoma of the gall bladder (stony, hard, irregular swelling).
4. Carcinoma of the common bile duct (firm and globular swelling).

* With jaundice : 2, 3 and 4; without jaundice : 1.

D/D of gall bladder lump :

1. Hepatomegaly (specially, Riedel's lobe of liver).
2. Right-sided kidney lump or suprarenal tumour.
3. Carcinoma of the hepatic flexure of coion.
4. Carcinoma of the pyloric region of stomach.

Case 33

HEPATOSPLENOMEGALY

Common causes of hepatosplenomeg ily :

1. Chronic malaria.
2. Chronic kala-azar.
3. Haemolytic anaemia
4. Cirrhosis of liver.
5. Chronic myeloid leukaemia.
6. Lymphoma.
7. Acute viral hepatitis.
8. Enteric fever.
9. Polycythemia vera.
10. Collagen vascular diseases like SLE.
11. Tropical splenomegaly syndrome.
12. Myelofibrosis or myelosclerosis.
13. Felty's syndrome.
14. Miliary tuberculosis or disseminated tuberculosis.
15. Amyloidosis.

* ALL, AML, chronic lymphatic leukaemia, sarcoidosis, brucellosis, storage disorders (Gaucher's disease and glycogen storage disease) and polycystic disease are other important causes.

What is your diagnosis ?

1. Give the provisional diagnosis (aetiological e.g., it is a case of lymphoma), or say,
2. It is a case of hepatosplenomegaly probably due to chronic malaria, or say,
3. It is a case of hepatosplenomegaly for discussion (if aetiological diagnosis is not possible).

Different methods for palpation of liver :

During palpation of abdomen one must follow (mandatory) the undermentioned rules :

1. Always stand on the right side of the patient (as mostly we are right-handed).
2. Flex the thighs (to relax the abdominal musculature).
3. Turn the patient's face to the left (so that patient can not breathe on your face).
4. Ask the patient to breathe deeply but regularly with open mouth (liver, spleen, gall bladder and kidneys move with respiration).
5. Hands of the patient will lie by the side of his/her trunk (helps to relax the abdomen).

Remember, the patient should lie flat comfortably on his back, on a firm mattress with the head supported by a pillow. There should be good light for the purpose of examination. In the winter season,

the hands of the examiner should be made warm by rubbing together vigorously. The patient should be relaxed and reassured. A gentle and unhurried palpation with care of the painful sites gain confidence of the patient and helps in extraction of maximal informations.

Exposure of abdomen from the xiphisternum to upper thigh (in males), or to just above the inguinal ligament (in females) is usually carried out in *inspection* of abdomen.

* Exposure of abdomen (for *palpation*) :

Above — The xiphisternum.

Below — Just above the inguinal ligament (do not embarrass the patient by exposing genitalia).

There are three techniques for palpation of liver. **Most of the clinicians in India are well conversant with the conventional method.**

I. Conventional method—

Place the flat of right palm firmly over the right iliac fossa and press the hand inwards and upwards. The HAND IS PLACED PARALLEL TO THE ARBITRARY LOWER BORDER OF LIVER (or the right subcostal margin) lateral to the right rectus abdominis muscle. At the height of inspiration press the fingers firmly inwards and upwards when the radial border of the right index finger will slip over the lower border of the liver, if it is palpable. At the phase of expiration, place the right palm on a higher level, by 1 cm at a time, over the anterior abdominal wall until you reach the right lower costal margin or detect the edge of liver. *Now palpate the epigastrium for the left lobe of liver (move the hand from right hypochondrium to midline).*

II. Preferred method (according to few clinicians) —

Place BOTH HANDS side by side flat on the anterior abdominal wall in the right hypochondriac region lateral to the right rectus abdominis muscle with the fingers pointing upwards. If any resistance is felt. MOVE THE HANDS FURTHER DOWNWARDS UNTIL THE RESISTANCE DISAPPEARS. The patient is then asked to inspire deeply, and at the height of inspiration press the fingers upwards and inwards to confirm the edge of liver. The manoeuvre is repeated from lateral to medial side in search of the lower border of liver. When the hand is moved downwards, the loss of resistance demarcates the lower border of liver.

III. Alternative method (according to few clinicians) —

The right hand is placed flat in the right iliac fossa WITH THE FINGERS DIRECTING UPWARDS, lateral to right rectus muscle (the finger tips lie parallel to rectus sheath). Now press the hand firmly upwards and inwards (index and middle one are the sensing fingers). At the height of inspiration, try to release the inward pressure while maintaing the upward pressure; with the inspiration, the tips of fingers will slip over the margin of the liver, if palpable. Now palpate the liver for surface, consistency etc as a routine. This manoeuvre is less sensitive than previous two methods.

* Dipping method is always applied in the presence of ascites.

** During palpation of liver, don't press patient's shoulder or bed by your left hand (a common mistake). Let it hang normally by the side of your body.

Points ***to note if liver is palpable :***

1. Degree of enlargement—Expressed by centimetres / inches (preferable) or in number of examiner's fingers placed between the right costal margin and the lower border of the palpable liver at right MCL. Measurement is taken during natural expiration, preperably by a ruler. Some clinicians prefer to describe 'liver span' in this heading (see page 283).
2. Consistency—Soft, firm or hard.
3. Tenderness—Tender or non-tender.
4. Surface—Smooth or irregular (finely irregular or coarsely irregular).
5. Margin or border—Sharp or rounded. Usually a soft liver has rounded margin, and firm or hard liver has a sharp margin. The margin may be irregular in cirrhosis of liver.
6. Movement with respiration—Liver always moves 1 to 3 cm downwards with deep inspiration.
7. Left lobe enlarged or not (examine in the midline in the epigastrium between xiphoid process and umbilicus, and measure in mid-sternal line).
8. Any pulsation—Pulsatile or not (see below).
9. Upper border of liver dullness (normal or shifted)—Percuss the right side of chest from above downwards along the right MCL. Normally the upper border of liver dullness in found in right 5th ICS at right MCL. For further details read the section on Hydropneumothorax'.
10. Palpable hepatic rub.
11. Place the stethoscope over the liver and auscultate carefully for any hepatic bruit or hepatic rub.

* *Right lobe* of the liver is palpated by keeping the hand lateral to the right rectus abdominis muscle while the left lobe is examiried in the midline. Caudate lobe enlargement (e.g., in Budd-Chiari syndrome) is also appreciated in epigastrium.

** During palpation, observe the facial grimace of the patient (for tenderness).

How to examine for pulsatile liver ?

1. Stand on the right side of the patient. While the patient is sitting in a chair (preferably), place your right palm over the liver (or right hypochondrium) and the left palm over the back, just opposite to the right palm (bimanual palpation).
2. Ask the patient to hold his breath after taking deep inspiration*.
3. Look from the side and observe the separation of the hands along with expansile pulsation of the liver, if there is any, and appreciate the pulsation.

Remember, the most common cause of pulsatile liver is CCF (produces functional tricuspid incompetence - TI). Thus, while examining the pulsatile liver, always look for engorged and pulsatile neck veins, and bipedal oedema (indirect evidence of CCF). Common causes of pulsatile liver are :

1. CCF (functional TI)
2. Organic TI (systolic pulsation).
3. Tricuspid stenosis (presystolic pulsation).
4. Haemangioma of liver or arteriovenous flslula in liver.
5. Transmitted epigastric pulsation from RVH.

* Inspiration helps in desent of liver and increases venous return to right heart.

Causes of tender liver :

1. Acute viral hepatitis.
2. Congestive cardiac failure.
3. Carcinoma of liver.
4. Pyogenic or amoebic liver abscess.
5. Drug-induced hepatitis.
6. Infected hydatid cyst of liver.
7. Budd-Chiari syndrome (acute).
8. Cholangio-hepatitis.

* Inflammation (perihepatitis) or stretching of the Glisson's capsule makes the liver painful and tender.
** Congestive hepatomegaly due to any cause (see below) makes the liver tender.

In an enlarged and tender liver, what else you will examine?

1. Jaundice (acute viral hepatitis).
2. Engorged and pulsatile neck veins, dependent bipedal oedema and CVS (for CCF).
3. Intercostal oedema as well as tenderness in right lower chest (liver abscess).

Causes of left lobe enlargement of liver :

1. Amoebic liver abscess.
2. Hepatoma.
3. Metastasis in liver.
4. Gumma of liver (not seen now-a-days}—hepar lobatum.

Causes of soft, firm and hard liver (alteration in consistency) :

(A) Soft liver *[feels like lips}-*

1. **Congestive cardiac i'ailue.**
2. Acute viral hepatitis.
3. Fatty liver.
4. Acute malaria.
5. Visceroptotic normal liver.
6. Extrahepatic obstruction (EHO).

(B) Firm liver *[feels like tip of the nose)~*

1. **Cirrhosis of liver.**
2. Chronic malaria.
3. Chronic kala-azar.
4. Hepatic amoebiasis.
5. Lymphoma.
6. Chronic congestive cardiac failure (nutmeg liver).

(C) Hard liver *feels likeforeheadf-*

1. **Hepatoma (hepato-cellular carcinoma) j Rock-hard ii$_{ve}$r**
2. **Metastasis in liver** ∫
3. Chronic myeloid leukaemia.

* 'Congestive hepatomegaly' is commonly found in CCF, constrictive pericarditis, dilated (congestive) cardiomyopathy and Budd-Chiari syndrome.

Liver enlargement with irregular surface :

(A) **Finely irregular** (granular surface)—Portal cirrhosis.

(B) **Grossly or coarsely irregular** (nodular liver)—

1. Postnecrotic cirrhosis (macronodular).
2. Metastasis in liver (large nodules with umbilication due to central softening).
3. Hepatoma.
4. Hepatic cysts (congenital, hydatid).
5. Multiple liver abscess.
6. Gumma of liver.

* No. 1, 2, 4 and 5 produce 'knobbly liver'.

Causes of hepatic bruit :

1. Hepato-cellular carcinoma (hepatoma).
2. Acute alcoholic hepatitis.
3. Haemangioma of liver.
4. Arteriovenous fistula in liver.

Causes of hepatic rub :

1. After recent biopsy of liver (transient).
2. Perihepatitis (e.g., liver abscess).
3. Carcinoma of liver (secondary or primary).

Degree of enlargement of liver :

Enlargement is expressed as :

- Mild enlargement (1 -2 fingers)
- Moderate enlargement (2-5 fingers)
- Massive or huge enlargement (> 5 fingers)

Causes of huge hepatomegaly :

1. Metastasis in liver or hepatoma.
2. Polycystic disease of liver.
3. Gross fatty change.
4. Amoebic liver abscers.
5. Chronic malaria or chronic kala-azar.
6. Amyloidosis of liver.

* Mild to moderate hepatomegaly occurs in malaria, kala-azar, enteric fever, miliary tuberculosis, leukaemias, fatty liver, cirrhosis (postnecrotic), congestive hepatomegaly, haemolytic anaemia, carcinoma, haemangioma and storage disorders (Gaucher's disease).

Hepatomegaly with jaundice :

1. Acute viral hepatitis.
2. Haemolytic anaemia.
3. Carcinoma of liver (secondary).
4. Cirrhosis of liver.
5. Cholangio-hepatitis.
6. Weil's disease.
7. Lymphoma.

Hepatomegaly with heart failure :

1. Right ventricular failure.
2. Constrictive pericarditis.
3. Haemochromatosis.
4. Alcoholic liver disease with cardiomyopathy
5. Rarely, amyloidosis.

What is the 'liver span'?

It is the vertical distance between the uppermost and lowermost points of hepatic dullness. It is detected by percussing the upper and lower borders of liver at the right MCL. The anterior liver span is usually 10-14 cm (mean 12 cm) in an adult in the right MCL and is related to patient's age, sex, body mass, height etc (females having liver span less than males). Serial measurement is helpful to detect shrinkage or enlargement. Liver span in children is much smaller.

* Liver span is increased in true enlargement of liver and not when it is displaced (e.g., palpable liver in downward displacement in emphysema).

Causes of rapid change in size of liver :

(A) Rapid enlargement —

1. Carcinoma of liver.
2. Amoebic liver abscess.

(B) Rapid decrease —

1. Fulminant hepatic failure.
2. Correction of CCF.
3. Cirrhosis of liver.
4. Relief of cholestatic jaundice.

Conditions erroneously suggest upward hepatic enlargement :

1. Pleural effusion (right).
2. Basal pneumonia (right)
3. Subdiaphragmatic effusion or abscess (right).

D/D of hepatomegaly :

1. Carcinoma of the stomach.
2. Malignancy in right kidney.
3. Carcinoma of the transverse colon or hepatic flexure of colon.
4. Omental mass (generally from tuberculosis or malignancy).
5. Large gall bladder lump.

What is Riedel's lobe of liver ?

It is a downward tongue-like projection of the right lobe of liver and is commonly found in females. It moves with respiration. It is usually mistaken with gall bladder or right kidney. It lacks the spherical contour of the distended gall bladder and always remains asymptomatic. It is a congenital variation and not a true accessory lobe of liver. Often ultrasonography is done for differentiation.

N.B. : Palpable liver may be due to downward displacement of the liver without any enlargement and may be seen in conditions like right-sided pleural effusion, emphysema, in normal children, thin and lean persons, or in severe thoracic deformity. So, **a palpable liver may not be an enlarged liver.** Never forget to palpate the left lobe of liver, to percuss the upper border of liver dullness and to palpate bimanually for hepatic pulsation. Auscultation over the liver (for hepatic bruit and rub) is optional and should be done if you are asked to 'examine the liver'.

Different methods for palpation of spleen :

There are several methods for palpation of spleen. Preliminary preparations of the patient are the same as done during palpation of liver.

I. Standing on the right side of the patient, **place the flat of the left palm firmly over the left costal margin** posterolaterally and press it forward and medially, so as to enable a slightly enlarged soft spleen closer to the palpating right hand. Ask the patient to breathe in deeply and start palpating the spleen with the right hand. **Starting from the right iliac fossa,** move upwards and laterally towards the left hypochondrium, 1 cm at a time between each breath. If the spleen is not palpable, move the right hand more upwards with each inspiration until the fingertips reach under the left costal margin. Start well out to the left of costal margin and gradually move more medially. It is better to palpate the spleen with the fingertips but few clinicians prefer to use the radial border of right index finger.

II. If spleen is not palpable (or in a just palpable spleen) by the method mentioned above, turn the patient to **right lateral decubitus position** and palpate the spleen by hooked fingers of right hand placed under the left costal arch or by the same palpatory method mentioned above (palm lying flat) begining close to the left costal margin while the patient is breathing in and out deeply. Patient will flex his left hip and knee while in right lateral decubitus position. The examiner's left hand should remain over the lowermost rib cage posterolaterally on the left side as before.

III. In case of a just palpable spleen, finally stand on the left side of the supine patient, facing the foot end of the bed. Palpate the spleen by **hooked fingers of left hand** below the left costal margin while the patient breathes in and out deeply (classical hooking method). Hooking method may be done from the left side in sitting position of the patient.

* **If the spleen is not palpable by method I, go for method II and then, for method III. Phases of respiration are very important in palpation of spleen.** While palpating spleen, do not be hasty and rash, rather show endurance—a just palpable spleen will definitely touch your fingers at the height of inspiration. Method I and II may be called as bimanual palpation.

N.B. : Dipping method is always applied in the presence of ascites.

Different methods for palpation of abdominal viscera :

There are four methods :

1. Conventional, direct or classical method e.g., palpation of liver.
2. Hooking method — classically used in palpation of spleen.
3. Dipping method — palpation in the presence of ascites.
4. Bimanual palpation — classically for the palpation of kidneys.

What is dipping method ?

It is difficult to palpate the abdominal viscera by direct method in the presence of significant ascites While performing dipping method, mould the palpating right hand to the shape of the abdomen and then tap the abdomen sharply and quickly. The sudden and rapid displacement of fluid gives a tapping sensation over the surface of the enlarged liver or spleen which is comparable to patellar tap The right hand is placed flat over the abdomen and **sharp tap is given by flexing the metacarpophalangeal joints suddenly.** One or two sudden thrust displaces the fluid and the displaced fluid pushes the organ forward towards the palpating fingers. Many a time full description of an organ is not possible by dipping method (one can go upto palpable or not, tender or non-tender, small or big lump). Preliminary preparations of the patient are the same as done during palpation of liver. It is better to start palpation from right iliac fossa by dipping method and proceeding anticlockwise.

While palpating the spleen by dipping method, it is better to place the left palm over the left costal margin as done in the conventional method.

How to percuss the upper border of splenic dullness ?

The anatomical position of the spleen is behind and below the left 9th. 10th and 11th rib, and its **long axis is lying along the direction of the left 10th rib.** Its antero-inferior end extends maximally upto the midaxillary line and the postero-superior end lies 4 cm lateral to the T_{10} spine. The upper border of normal splenic dullness is present in left 9th rib and for this reason the 8th ICS (space above the 9th rib) in left midaxillary line is always resonant on percussion.

Percuss the left axilla from above downwards along the midaxillary line (either the patient lies supine or being seated while keeping the left hand over the head to expose the axilla) in the search of upper border of spleen.

If the same percussion is done in lowest intercostal spaces (like 8th or 9th ICS) along the anterior axillary line and the spaces reveal dull percussion note, even on full inspiration, it is said that splenomegaly is present **(Castell's method).**

* Remember, splenic enlargement first takes place in superior and posterior direction before it becomes palpable per abdomen (i.e., subcostally).

Percussion of the lower border of liver :

1. Start percussion from below upwards i.e., from right iliac fossa to right hypochondrium along the right MCL. &
2. It is a light percussion (as lower border of liver is not covered by any organ).
3. Place the pleximeter finger parallel to right subcostal margin and the line of percussion will be perpendicular to that margin.

Percussion of the upper border of liver :

1. Start percussion from above downwards in the right chest along the right MCL.
2. It is a heavy percussion (as upper border of liver lies under cover of the right lung).
3. Place the pleximeter finger in the right 2nd ICS parallel to arbitrary upper border of liver and the line of percussion will be perpendicular to that border.

* For shifting of upper border of liver dullness, read the section on 'Hydropneumothorax'.

Percussion of the lower border of right lung :

1. Start percussion from above downwards in the right chest along the right MCL.
2. It is a light percussion (as it is a superficial organ).
3. Place the pleximeter finger in the right 2nd ICS (parallel to arbitrary lower border of lung) and the line of percussion will be perpendicular to that border.

Points to note if spleen is palpable :

1. Degree of enlargement—Expressed by centimetres / inches (preferable) or in number of examiner's fingers placed below the left costal margin upto the most distal point of spleen, along the splenic axis (spleen becomes just palpable when it is enlarged to 2-3 times more than its normal size. **Spleen usually enlarges towards the right iliac fossa.** In children, spleen may enlarge vertically towards the left iliac fossa). The measurement is taken along the splenic axis from a point on left costal margin (where crossed by left MCL) to the furthest extent of the spleen. Measurement is taken during natural expiration. A spleen, which is palpable, is always pathological.
2. Splenic notch—Very characteristic and felt on its anterior or medial border.
3. Margin—Usually the margin is sharp.
4. Consistency—Soft, firm or hard.
5. Tenderness—Tender or non-tender.

6. Surface—Smooth or irregular.
7. Movement with respiration—Spleen always moves downwards and medially with respiration.
8. Fingers can not be insinuated between the left costal arch and the enlarged spleen. Spleen has a tendency to bulge orward.
9. Palpable splenic rub—Present or not (for its detection, the patient must breathe in and out deeply).
10. Auscultation of splenic rub.
11. Upper border of splenic dullness.

N.B. : No. 10 & 11 are optional and should be done if you are asked to 'examine the spleen'. Some clinicians prefer that a student should always percuss the spleen (D/D with renal swelling) fqr any band of colonic resonance, at the time of palpation of spleen.

* It is not clearly known, why the spleen in children enlarges vertically towards the left iliac fossa. Probably, it may be one of the reason that in a child other organs are not much enlarged (in comparison to adults) and thus the spleen makes its room vertically downwards towards the left iliac fossa.

** In the examination, do not delineate borders of spleen/liver by pen or pencil over patient's body.

Table 22 : Differentiation between enlarged spleen and renal lump

Spleen	Left kidney
1. Spleen enlarges downwards, forwards and towards the right iliac fossa, and moves well with respiration	1. Kidney enlarges towards the left iltac fossa and having restricted movement with respiration
2. *Notchfelt*	2. No notch felt
3. Sharp margin	3. Rounded margin
4. It Is neither bimanually palpable nor ballottable	4. *Bimanually palpable and ballottable*
5. *Fingers cannot be insinuated between left costal margin and the enlarged spleen*	5. Fingers can be insinuated
6. Percussion note is always dull over spleen	6. *Band of colonic resonance anterior to enlarged kidney may be elicited*
7. Tendency to bulge forward	7. Tendency to bulge into the loin
8. Renal angle is non-tender	8. Renal angle may be tender
9. Cannot 'get above the swelling'	9. May 'get above the swelling' (e.g., in dropped kidney)
10. Can cross midline	10 Does not cross midline

* A massive splenomegaly may be bimanually palpable but never ballottable.

D/D of splenomegaly :

1. Enlaged left kidney.
2. Enlarged left lobe of liver.
3. Carcinoma of the stomach.
4. Carcinoma of the splenic flexure of colon.
5. Omental mass (generally from tuberculosis or malignancy).
6. Malignancy of the tail of pancreas.

Different degrees of enlargement of spleen :

(A) Mild (upto 2 fingers) or just palpable spleen ('spleen tip') —

1. Acute malaria.
2. Acute kala-azar.
3. Enteric fever.
4. Acute viral hepatitis.
5. Subacute bacterial endocarditis (SBE).
6. Miliary tuberculosis.
7. Acute leukaemias.
8. Haemolytic anaemia.
9. Immune thrombocytopenic purpura (ITP)
10. Felty's syndrome.
11. Infectious mononucleosis.
12. Weil's disease.

(B) Moderate (2-5 fingers or upto the umbilicus)—

1. Chronic malaria.
2. Chronic kala-azar.
3. Portal hypertension.
4. Lymphoma.
5. Chronic lymphocytic leukaemia.
6. Collagen vascular diseases like SLE.
7. Congenital haemolytic anaemia, e.g., thalassaemia.

(C) Huge or massive (> 5 fingers, or > 7 cm, or when the spleen crosses the umbilicus)—

1. Chronic kala-azar or chronic malaria.
2. Thalassaemia major.
3. Chronic myeloid leukaemia.
4. Tropical splenomegaly syndrome.
5. Polycythemia vera.
6. Portal hypertension with hypersplenism (in cirrhosis).
7. Extrahepatic portal vein obstruction (EHO).
8. Myelofibrosis or myelosclerosis.
9. Storage disorders (Gaucher's disease), amyloidosis.
10. Splenic cyst, tumour or abscess.

* Normal spleen weighs < 250 g; in massive splenomegaly, it weighs > 1000 g in adults.

** Remember, all the causes of massive splenomegaly were mild to moderate splenomegaly one day, and all moderate splenomegaly were mild in nature to start with.

*** Spleen may be palpable without having actual enlargement in tall and lean persons, emphysema (hyperinflated lung pushes spleen), visceroptosis and sometimes in children.

When do you search for splenic rub ?

Splenic rub is heard in the situations where the patient complains of acute pain in left upper quadrant of abdomen (often with radiation of pain to the tip of left shoulder) due to splenic infarction resulting in perisplenitis (with acute splenic tenderness). It is produced in conditions like,

1. Subacute bacterial endocarditis (SBE).
2. Chronic myeloid leukaemia.
3. Sickle cell anaemia.
4. After splenic puncture (e.g., in diagnosis of chronic kala-azar).
5. Vasculitis.
6. Splenic torsion.

* Acute splenic tenderness indicates splenic infarction or abscess formation.

The characteristics of splenic rub are :

1. It is a scratchy to-and-fro sound heard with respiration i.e., during movement of the spleen.
2. If the patient holds his breath, the rub stops.
3. The diaphragm of stethoscope should be placed over the spleen or left lower chest.

It should be differentiated from left-sided pleural rub (spleen is always tender in splenic rub) which is often very difficult. Treatment is by rest and analgesia. Repeated splenic infarction may be an indication for splenectomy.

** Always auscultate for spelnic rub over a hugely enlarged spleen. Splenic rub may be palpable.

*** Spleen may be mildly tender in acute malaria, infectious mononucleosis, SBE and enteric fever.

**** ***Splenosis***—peritoneal seeding of splenic rupture (traumatic) fragments not connected to portal circulation, and giving rise to abdominal pain later (like endometriosis).

What do you mean by hypersplenism ?

It is the splenic hyperactivity with increased blood cell destruction. Diagnostic criteria are :

1. Splenomegaly (of any size).
2. Pancytopenia (anaemia, leucopenia and/or thrombocytopenia).
3. Normal or hypercellular bone marrow.
4. Reversibility by splenectomy.

Causes — Either primary (no underlying disease) or secondary hypersplenism (connective tissue disorders, lymphoma, myeloproliferative disorders, cirrhosis of liver or congestive splenomegaly).

Causes of 'hyposplenism' :

It means absence of spleen or nonfunctioning spleen. It is usually associated with :

1. Dextrocardia (spleen is absent congenitally or asplenia).

2. Sickle cell disease (due to repeated splenic infarcts leading to autosplenectomy).
3. Coeliac disease.
4. Dermatitis herpetiformis with enteropathy.
5. Fanconi's anaemia (aplastic anaemia with hypoplasia of spleen, kidney, thumb, or radii).
6. Surgical removal.

* Splenectomised or hyposplenic patients are prone to be infected with capsulated organisms like pneumococcus, meningococcus, H. influenze or E. coli, and thus vaccination against these organisms is recommended to them.

Myeloproliferative disorders :

Here, there is uncontrolled clonal proliferation of one or more of the cell lines in the bone marrow, and are classified as :

1. Chronic myeloid leukaemia.
2. Polycythemia vera.
3. Essential thrombocythemia.
4. Myelofibrosis (myeloid metaplasia).

Hepatosplenomegaly with ascites :

1. Cirrhosis with portal hypertension.
2. Lymphoma.
3. Disseminated tuberculosis.
4. Acute leukaemia.
5. Acute viral hepatitis with hepato-cellular failure.
6. Systemic lupus erythematosus (SLE).

Splenomegaly with jaundice :

1. Cirrhosis of liver.
2. Acute malaria (P. falciparum commonly).
3. Haemolytic anaemia (e.g., thalassaemia).
4. Lymphoma.
5. Acute viral hepatitis (uncommon).
6. Miliary tuberculosis.

Splenomegaly with purpura or petechiae :

1. Acute leukaemia.
2. SBE.
3. Blast crisis of CML and CLL.
4. SLE.
5. ITP.
6. Felty's syndrome.

Hepatosplenomegaly with lymphadenopathy:

1. Lymphoma.
2. Leukaemia (ALL and CLL).
3. Disseminated tuberculosis.
4. SLE.
5. Sarcoidosis.
6. Felty's syndrome.
7. Infectious mononucleosis.
8. Amyloidosis.
9. AIDS.
10. Toxoplasmosis, CMV infection.
11. CML with blast crisis.
12. Kala-azar (African variety).

Hepatosplenomegaly with pyrexia :

1. Malaria (acute).
2. Kala-azar (acute or chronic).
3. Enteric fever.
4. SBE.
5. Miliary tuberculosis
6. Acute viral hepatitis.
7. Acute leukaemias, CML.
8. Lymphoma.
9. Collagen vascular diseases.
10. Brucellosis.
11. Still's disease.

Hepatosplenomegaly with anaemia :

1. Chronic malaria.
2. Chronic kala-azar.
3. Haematological malignancies e.g., lymphomas and leukaemias.
4. Cirrhosis of liver.
5. Haemolytic anaemia (e.g., thalassaemia).
6. Severe iron deficiency anaemia.
7. Hypersplenism.
8. SBE.
9. SLE.
10. Still's disease.

Reliable methods for measuring actual splenic size :

These are imaging procedures like,

1. Radionuclide scan,
2. Ultrasonography (USG),
3. Computerised tomography (CT), and
4. Nuclear magnetic resonance imaging (MRI).

If a maximal cephalocaudad diameter of spleen by these techniques (especially USG) crosses 13 cm, spleen is said to be enlarged.

Causes ***of rupture of spleen :***

1. Trauma in normal spleen.
2. By trivial trauma in a diseased spleen. The pathological conditions responsible are infectious mononucleosis, acute and chronic leukaemias, myelofibrosis, congestive splenomegaly (portal hypertension due to cirrhosis of liver or Budd-Chiari syndrome).

Important physical signs in hepatosplenomegaly :

1. Anaemia (cirrhosis, thalassaemia).
2. Jaundice (cirrhosis of liver, thalassaemia).
3. Fades — Mongoloid or hepatic fades; butterfly rash in SLE.
4. Polycythemia (i.e, plethoric appearance).
5. Lymphadenopathy (lymphoma, lymphocytic leukaemia, infectious mononucleosis).
6. Spider naevi and palmar erythema (hepato-cellular failure from cirrhosis of liver).
7. Kayser-Fleischer ring in cornea (Wilson's disease).
8. Tremor (Wilson's disease).
9. Pigmentation (haemochromatosis).
10. Leg ulcers (congenital haemolytic anaemia).
11. Sternal tenderness (acute leukaemias and CML).
12. Haemorrhagic spots (acute leukaemias, SBE).
13. Fundoscopy—Roth spots (SBE), choroidal tubercle (miliary tuberculosis).

Investigations you like to perform in a case of hepatosplenomegaly :

(A) Blood — Hb, TC, DC, ESR and some special tests :

a) Leucocytosis—Pyogenic infections, polycythemia, leukaemia.
b) Leucopenia—Malaria, kala-azar, enteric fever, Felty's syndrome.
c) Pancytosis—Polycythemia.
d) Pancytopenia—Hypersplenism.
e) Reticulocytosis—Haemolytic anaemias.
f) Thrombocytopenia—Leukaemia, hypersplenism.
g) ESR—Increased in infective aetiologies, SLE, lymphoma, severe anaemia due to any cause; diminished in polycythemia and congestive cardiac failure.
h) Blood culture—Often informative in SBE, enteric fever.
i) Blood smear—For the diagnosis of malaria, kala-azar (buffy coat preparation), leukaemia (acute and chronic), hereditary spherocytosis, thalassaemia.
j) Special tests—(i) Paul-Bunnell test - for infectious mononucleosis, (ii) Serum iron - increased in thalassaemia, haemochromatosis. (iii) Serum copper - low in Wilson's disease, (iv) Serum bilirubin - for cirrhosis with hepato-cellular failure, haemolytic anaemias, malaria, viral hepatitis. (v) Serum electrophoresis - increased HbF in thalassaemia. (vi) Congo red test for amyloidosis. (vii) Aldehyde test - for chronic kala-azar. (viii) LE cell and phenomenon - collagen vascular disease (not done routinely), (ix) Red cell survival time - decreased in hereditary spherocytosis, (x) Antinuclear factor - positive in SLE. (xi) Rose-Waaler test - positive in Felty's syndrome, (xii) Serum proteins - high globulin with low albumin is observed in cirrhosis of liver, chronic kala-azar, disseminated lupus, (xiii) Blood for HB_sAg. (xiv) Serology—for CMV, EBV, HIV, and VDRL test for syphilis.

(B) X-ray or radiology —

a) Chest (PA view)—For miliary tuberculosis (miliary mottling), lymphoma or sarcoidosis (mediastinal widening), extramedullary haematopoiesis in thalassaemia.
b) Bones —
   (i) Mosaic-pattern seen in small bones of hand in patients with thalassaemia.
   (ii) Increased bone density in myelofibrosis or myelosclerosis.
   (Iii) Expansion of lower end of long bones (Erlenmeyer flask)—Seen in Gaucher's disease.
c) Skull— 'Hair on end' appearance in thalassaemia.
d) Straight X-ray of abdomen—Not informative .

(C) Lymph node biopsy (excission biopsy is always preferred to FNAC because it delivers more tissue for diagnosis)—May be of value in tuberculosis, sarcoidosis and lymphoma.

(D) USG of liver, spleen, free fluid in abdomen and for any mass (pre- and para aortic lymph nodes)—

a) Hepatosplenomegaly is confirmed.
b) Ascites may be present in portal hypertension, tuberculosis or lymphoma.
c) Heterogenous echopattern of liver with splenomegaly and ascites—Portal hypertension due to cirrhosis of liver.

d) Enlarged abdominal lymph nodes —Lymphoma or tuberculosis.

(E) Liver biopsy—May be of value in cirrhosis of liver, lymphoma, haemochromatosis or amyloidosis.

(F) Bone marrow examination—For leukaemia, lymphoma, hypersplenism, Gaucher's disease, polycythemia etc.

(G) Skin test—

(1) Mantoux test—For tuberculosis (may be negative in lymphoma).

(Ii) Kveim test—For sarcoidosis (not done now-a-days).

(H) Investigations for portal hypertension—See the section on 'Cirrhosis of liver'.

(I) Splenic puncture—For the diagnosis of chronic kala-azar.

(J) CT scan of whole abdomen may be done.

(K) Lymphangiography—For lymphoma (for demonstration of involvement of retroperitoneal nodes).

D/D of hepatosplenornegaly :

I. Chronic malaria :

a) Patient comes from an endemic zone with high rise of temperature associated with chill and rigor. Fever may come on alternate days periodically.

b) Severe anaemia, mild jaundice may be present.

c) Spleen—Moderate to massive enlargement, firm to hard and non-tender.

d) Diagnosis is confirmed by demonstration of malaria parasites in the peripheral blood. There ' may be leucopenia.

II. Chronic kala-azar :

a) Patient comes from an kala-azar endemic zone.

b) Double rise of temperature (double quotidian) in 24 hours may be present (20% cases).

c) Appetite is preserved inspite of fever and loss of body weight.

d) Spleen—Massively enlarged, soft to firm (often a doughy feel) and non-tender (spleen of chronic kala-azar is softer than chronic malarial spleen).

e) Liver—Moderate enlargement, firm and non-tender. Ratio of liver and spleen is 2 : 5.

f) Alopecia, pigmentation.

g) Diagnosis is made by neutropenia, positive aldehyde test, direct agglutination test (DAT), or by demonstration of L.D. bodies in buffy coat preparation of blood or bone marrow smear or splenic puncture.

m. Thalassaemia (Cooley's anaemia) :

a) The patient is usually a child or young adult with positive family history.

b) Stunted growth, typical mongoloid facies, massive splenomegaly with moderate hepatomegaly, severe anaemia, mild jaundice, leg ulcers over malleoli of foot.

c) Diagnosis is done by,

(i) Microcytic hypochromic anaemia, reticulocytosis, anisocytosis, polkilocytosis, target cells,

(il) Haemoglobin electrophoresis (HbF >2%).

(iii) Radiological study of skull and small bones of hand.

* Acquired haemolytic anaemia (e.g., autoimmune) may produce hepatosplenornegaly.

IV. Cirrhosis of liver (postnecrotic) :

a) Features of chronic liver disease e.g., dyspepsia, malaise, wasting, severe weakness. There may be past H/O jaundice.

b) Symptoms and signs of hepato-cellular failure.

c) Features of portal hypertension—Haematemesis, melaena, splenomegaly, venous prominences over abdomen, ascites.

d) Mild to moderate hepatomegaly with moderate splenomegaly. Both are firm and non-tender.

e) Presence of other stigmata of cirrhosis of liver.

f) Diagnosis is done by demonstration of oesophageal varices, splenoportalvenography, liver biopsy.

V. ***Chronic myeloid leukaemia :***

a) The patient is around 30 to 80 years (peak - 55 years) with fever, dragging pain in the left hypochondrium and profound weakness. Weight loss and sweating are due to increased metabolic rate.

b) Anaemia —Mild.

c) Sternal tenderness —Present.

d) Spleen —Hugely enlarged, hard with occasional splenic rub (may be tender).

e) Liver •—Mild to moderate enlargement.

f) Diagnosis is confirmed by 1.5-2.5 lacs WBC/mm^3 with myelocytes, metamyelocytes, promyelocytes and few myeloblasts.

* (AML - mild splenomegaly; ALL - moderate splenomegaly
CML - huge splenomegaly; CLL - moderate splenomegaly]

VI. Lymphoma :

a) Progressive painless enlargement of cervical, axillary or inguinal lymph nodes, fever, loss of weight, pruritus, weakness, drenching night sweats.

b) Superior mediastinal syndrome may be present — Dyspnoea, engorged non-pulsatile neck vein, swelling of face, tortuous veins over chest wall.

c) Spleen — Moderately enlarged, non-tender.

d) Liver — Moderate enlargement.

e) Anaemia, eosinophilia in blood may be present. The lymph node biopsy is confirmatory.

VU. Acute viral hepatitis :

a) H/O jaundice preceded by anorexia, profound nausea, fever and occasional vomiting. Urine is yellow and stool may be of white coloured.

b) There may be urticarial rash, arthralgia.

c) Hepatosplenomegaly—Mild to moderate, tender hepatomegaly with mild splenomegaly (soft).

d) Diagnosis is done by—

(i) High serum bilirubin, high SGPT (ALT), alkaline phosphatase (slight rise), prothrombin time estimation (may rise).

(ii) HB Ag, LM anti-HAV or anti-HEV, anti-HCV in blood.

VUJ. Enteric fever :

a) H/O rise of temperature in step-ladder pattern, frontal headache, constipation, epistaxis, rose spots in skin, relative bradycardia.

b) Tongue—Red margins with central coating (angry-looking tongue).

c) Spleen—Soft and tender just palpable spleen at the end of first week.

d) Liver—Soft, non-tender, mild enlargement.

e) Diagnosis is done by neutropenia, blood culture and Widal test.

IX. Polycythemia vera :

a) Symptoms like headache, fullness in head, pruritus, peripheral vessel thrombosis (due to increased viscosity of blood), visual disturbances commonly in a middle aged male patient.

b) Epistaxis, haematemesis or melaena, pruritus, peptic ulcer, peripheral vascular bleeding.

c) Face is plethoric, conjunctivas are congested and palms are red.

d) Spleen is enlarged in 75% cases and may be massive; hepatomegaly in 30% cases.

e) Diagnosis is made by raised haematocrit, low ESR, hyperplasia of all marrow elements in bone marrow examination. Erythropoietin level is decreased.

X. Collagen vascular disease (SLE) :

a) The patient is mostly a woman with fever, arthralgia, alopecia, oral ulcer, skin rash or lymphadenopathy.

b) Renal, lung or cardiac involvement—Oliguria, pleurisy, pericarditis, dyspnoea (i.e., multisystem disease).

c) Spleen—Usually there Is moderately enlarged, firm, non-tender spleen,

d) Diagnosed by high ESR, positive antinuclear factor, antibody to double-stranded DNA and anti-Sm antibody (SLE), renal biopsy etc.

XI. Tropical splenomegaly syndrome (previously known as Banti's syndrome) :

a) The patient comes from a hyperendemic area with an exaggerated immune response to malaria. The disease is common in females, and has familial and racial predisposition. Adults have high malarial antibody titres with low parasitaemia.

b) Spleen—Massive splenomegaly.

c) Liver—Mild to moderate enlargement.

d) Signs of portal hypertension may be present without any evidence of cirrhosis of liver (due to increased portal blood flow).

e) Chronic low grade haemolytic anaemia may be seen; low grade pyrexia.

f) Diagnosed by increased level of I_gM, 'sinusoidal lymphocytosis' in liver biopsy (diagnostic).

* The modem nomenclature of the disease is ***'hyperreactive malarial splenomegaly'.***

XII. Myelofibrosis or myelosclerosis :

a) This may be primary, or develops from toxins, malignancy, lymphoma, irradiation (secondary).

b) Spleen—Massive, tender spleen; splenic rub may be present.

c) Hepatomegaly—Mild to moderate enlargement.

d) Leucoerythroblastic blood picture with high platelet count.

e) Bone marrow examination may not yield any result (dry tap) and often trephine biopsy is needed to demonstrate the fibrotic changes. X-ray shows ground-glass appearance (osteosclerosis) of all bones of axial skeleton.

f) There may be signs of haemorrhage into the skin.

XIII. Felty's syndrome :

a) It is a subgroup of rheumatoid arthritis with splenomegaly and neutropenia.

b) Age of onset is around 50-70 years and more common in females.

c) Features like weight loss, joint pain with deformity, lymphadenopathy, pigmentation, leg ulcers, vasculitis, chest infection, keratoconjunctivitis sicca, rheumatoid nodules may be present.

d) Spleen — Mild splenomegaly.

e) Diagnosis is done by anaemia, neutropenia, thrombocytopenia, and strongly positive rheumatoid factor.

XIV. ***Miliary tuberculosis :***

a) Gradual onset with vague ill-health, high fever with drenching sweats, pallor, loss of weight.

b) Cough, breathlessness, anorexia, headache may be present.

c) Tachycardia, paucity of signs in the chest (few crepitations in late stages).

d) Mild, non-tender hepatomegaly with small palpable spleen.

e) Signs of meningeal irritation may be found.

f) Choroidal tubercle may be visible (25%) on ophthalmoscopy (diagnostic). Chest X-ray shows miliary mottling bilaterally. Leucocytosis is usually absent. Mantoux test may be negative. Sputum examination may or may not demonstrate AFB.

XV. ***Amyloidosis :***

a) Presence of long standing suppurative focus in the form of lung abscess, bronchiectasis, chronic osteomyelitis or may develop from tuberculosis, Crohn's disease, multiple myeloma, lymphoma, leprosy, rheumatoid arthritis.

b) Visceromegaly—Macroglossia (tongue becomes stiff and firm to palpation), hepatosplenomegaly.

c) Evidence of nephrotic syndrome—Albuminuria, hypoproteinaemia, anasarca and hypercholesterolaemia.

d) Malabsorption, lymphadenopathy, peripheral neuropathy, cardiomyopathy may be present.

e) Liver, gingival, abdominal fat or rectal biopsy is done and gives positive Congo red test.

Differential diagnosis of hepatosplenomegaly in children :

1. Thalassaemia major.
2. Acute leukaemias (ALL > AML).
3. Indian childhood cirrhosis.
4. Acute viral hepatitis.
5. Enteric fever.
6. Miliary tuberculosis.
7. Chronic malaria, chronic kala-azar.
8. Wilson's disease.
9. Storage disorders like Gaucher's disease, glycogen storage disease.
10. Still's disease.
11. Congenital syphilis.

N.B.: Always try to say that liver and spleen are 'palpable' below the costal margin. If you say they are enlarged, it means that the upper border of liver and splenic dullness are in normal position. If you detect the upper borders in normal position, you may say 'they are enlarged'.

There may be scar marks (rounded) present in the left and/or right hypochondrium in a chronic patient of hepatosplenomegaly due to application of counter-irritants by the quacks (used in remote villages) in a false attempt to treat the disease.

Case 34

CEREBELLAR DISORDER

Functions of cerebellum :

Cerebellum has ipsllateral control over body and,

1. Regulates the rate, rhythm, range and force of muscular contraction.
2. Facilitatory action on tone and reflex activity of the body.
3. Maintains posture and equilibrium.
4. Integrates the voluntary and automatic movements — 'coordination'.

Morphological and functional division of cerebellum :

1. Archicerebellum (oldest part)—Maintains locomotion and equilibrium (vestibular).
2. Palaeocerebellum (old part)—Maintains the muscle tone and posture (spinocerebellar).
3. Neocerebellum (youngest part)—Integration and coordination of fine muscular movements (corticocerebellar).

Bedside assessment of the cerebellar function :

A cerebellar hemispheric lesion will produce ipsilateral signs. Cerebellar function is assesed by :

1. **Titubation—**Nodding of head either in antero-posterior ('yes-yes') or side to side ('no-no') direction. Sometimes, there is 'head tilt' towards the side of lesion.

* Head-nodding may also be seen in aortic regurgitation (syphilitic), parkinsonism, mannerisms, anticonvulsants-induced and mental retardation.

2. **Speech (dysarthria)—**Dysarthria of staccato or scanning type. The speech is usually slow, slurred and irregular, and expressed with varying force. Often the patient scans the speech, i.e., he speaks syllable by syllable with undue emphasis on a particular syllable. Ask him to say 'artillery' or 'Motiur Rahaman' : he will pronounce it as ar-til-ler-y or Mot-i-ur-Ra-ha-man.
3. **Hypotonia**—Elicit the tone of the muscle and it will be flaccid both at rest (flopy limbs) and on passive movements of the parts.
4. **Pendular knee jerk**—The patient will sit on a chair with legs hanging free side by side. Apply a sharp tap on the patellar tendon on each side, one after another. In health, contraction of quadriceps with extension of knee occurs. In case of cerebellar lesion, the knee jerks are very often diminished or pendular in nature. The first movement is followed by a series of diminishing oscillations (pendular) before the leg finally comes to rest. According to some clinicians, at least 3 to and fro movements in the leg are known as 'pendular'. If no response occurs, never forget to do the reinforcement test. Pendular knee jerk happens to be due to hypotonia.
5. **Intention tremor**—When tremor appears at the goal-point of an action, it is known as intention tremor. Ask the patient to hold a glass which is kept on the table or to hold your index finger which is kept away from him. The movements will be clumsy as he approaches the object. Finger-nose test also elicits intention tremor.
6. **Dysmetria—**It means inability to arrest the movements at desired point and is elicited by ***finger-nose test'.*** The patient is asked to touch the tip of his nose with the tip of his index finger, first with eyes open and then with eyes closed (at the beginning of the test, the patient is directed to outstretch his arm and the procudure is demonstrated to him by the examiner). Instruct him to look straight ahead and not to focus on the index finger. Ask the patient to repeat the test as quickly as possible. This test can be modified by asking the patient to touch your index finger after touching his nose (finger-nose-finger test). First do the test on one side, then examine the other. The index finger of the patient may 'falls short' (hypometria) or 'overshoot' (hypermetria or past pointing) his nose. By this simple test one can assess the presence of :

   (i) Intention tremor,

   (il) Coordination, and

   (iii) Side of lesion (by seeing the past pointing).

7 **Dyssynergia**—It is the inability to perform movements as a coordinated temporal sequences when the movements may be broken down into their component parts (decomposition of movements) producing small, jerky and clumsy movements (like the modern break-dance). The patient feels difficulty in performing complex movements.

8. **Dysdiadochokinesia** The patient can not execute rapid and repeated movements smoothly. He is asked to flex his elbows at right angle, and then pronate and supinate his forearm very rapidly 'as though screwing in a light bulb'. It can also be tested by asking the patient to supinate and pronate his right hand over the left palm very rapidly, and then the left hand over the right palm in the same way. In cerebellar lesion the movements are slow, clumsy, awkward, incomplete and often stops after few attempts (on the side of cerebellar lesion).
9. **Rebound phenomenon**—The limb overshoots beyond the normal range after sudden release of the resistance. Ask the patient to flex his elbow against resistance offered by you. As soon as you withdraw the resistance suddenly, the patient's hand tends to strike his face (because the antagonistic muscle like triceps can not contract promptly). This phenomenon is due to muscular hypotonia.
10. **Nystagmus** Horizontal, jerky nystagmus is present and the direction of nystagmus (fast component) is towards the side of lesion.
11. **Romberg's sign—**Actually it a test of sensory ataxia. The test is negative in cerebellar disease (see below).
12. **Gait—**
    a) This is a 'reeling;, 'drunken' or 'lurching' gait due to presence of truncal 'ataxia'. The patient walks on a broad base, the feet being placed widely apart and irregularly; at times, the head is tilted towards the side of lesion (try in those patients, who are able to walk).
    b) Now the patient is asked to walk along a straight line (cracks already present in the floor or you draw a line there). The patient sways and often falls towards the side of lesion during walking.
    c) Tandem gait' (heel to toe gait) —The patient is asked to walk along a straight line with the heel of one foot touching the toes of the one behind. The patient is then told to turn backwards qujckly. It is very difficult for a patient with cerebellar lesion to walk steadily by tandem gait. This gait is a sensitive test of early ataxia (a test of vermis of cerebellum).

Presentation with cerebellar lesion :

Connections : Afferent fibres reach the cerebellum frorn spinai cord, vestibular system, basal ganglia arid cerebrum. Cerebellum influences the LMN through its connections with the basal ganglia and cerebral cortex, via the thalamus. The common presentations are :

a) Hemispherical lesion—**Paralysis is** not a feature of cerebellar disease rather the patient presents with ipsilateral hypotonia (weakness), incoordination (ataxia), and difficulty in walking or swaying while walking.

b) Lesion at vermis--Produces truncal ataxia and the patient feels difficulty in sitting up or standing. Lesion at flocculonodular region produces vertigo, vomiting and gait ataxia, if they extend to the roof of 4th ventricle.

Features of lesion at vermis (midline lesion) :

In a midhne cerebellar lesion there is little or no incoordination, no nystagmus and no hypotonia But there are presence of :

(i) Titubation (head-nodding),
(ii) Truncal ataxia (ataxia of the body),
(iii) Positive 'heel to toe' gait (tandem gait), and } 3 'T'
(iv) Difficulty in sitting, standing and unassisted walking (swaying and unsteadiness).

What is sensory ataxia ?

Por the production of a purposeful coordinated movement the cortex, the cerebellum, the reflex arc, impulses from eyes, labyrinth and cervical spine are required to function together. If such coordination is imperfect, motor performance becomes difficult. **Clumsiness of the movement {clinically manifested by unsteady gait) is known as ataxia provided, there is no motor and sensory deficit** Ataxia is mainly of four types :

a) Cerebellar — Vascular lesion, cerebellar tumour, cerebellitis, cerebellar degeneration, hereditary ataxias, alcohol or phenytoin-induced.
b) Sensory — Peripheral neuropathy, tabes dorsalis.
c) Labyrinthine — Acute labyrinthitis, streptomycin-induced, Meniere's disease.
d) Central — Affection of vestibular nucleus as a result of vascular lesion in the medulla.
e) Miscellaneous — Severe muscular weakness, hypotonia, alcoholism.

Sensory ataxia results from defective proprioception (due to posterior column involvement) and can sometimes be alleviated with the help of vision. Thus sensory ataxia is increased when the eyes are closed, in contrarst to cerebellar ataxia which is not affected by vision. Tabes dorsalis Is a classical example of sensory ataxia.

Sensory ataxia is usually due to affection of :

a) Peripheral sensory nerves —Peripheral neuropathy (e.g., leprosy, diabetes mellitus).
b) Posterior nerve roots —Tabes dorsalis, disc prolapse.
c) Posterior column —Multiple sclerosis, syringomyelia.
d) Post-central convolution —Diseases of parietal lobe (vascular, SOL).

* [**Apraxia** Inability to perform certain purposive well-organized voluntary movement in the absence of motor weakness, sensory loss, cerebellar or extrapyramidal impairment, or ataxia. It develops in frontal and parietal lobe lesions. Ask the patient to light a cigerette with a matchstick, or copy a simple diagram. It seems, in apraxia, the person has forgotten to perform the motor act.

** **Agnosia**—Inability to recognise the nature of sensory' input in spite of intact sensory organ, e.g., visual agnosia, tactile agnosia and auditory agnosia.)

What is Romberg's sign ?

It is important to remember that **it is a sign of sensory ataxia** (i.e., a test of posterior column function) and not a test for cerebellar function.

The patient is asked to stand with his feet close together (convergent heels with divergent toes). If he can do this, he is then asked to close his eyes. Romberg's sign is said to be present or positive when the patient begins to sway or about to fall as soon as he closes his eyes. **The cardinal feature of this sign is that** "the **patient is more unsteady standing with his eyes closed than when the eyes are kept open** . A patient with cerebellar ataxia or labyrinthine lesion shows little or no increase in instability after closing the eyes (though the patient may show some unsteadiness at the beginning of the test with open eyes). False positive Romberg's sign is observed in hysteria (hips sway more in comparison to ankles).

Prerequisites :

1. Patient will stand bare-footed,
2. Feet placed close to each other.
3. The examiner will stand very close to the patient and assure the patient of his safety.

Table 23 : Differentiation betweens cerebellar and sensory ataxia

	Features	Cerebellar ataxia	Sensory ataxia
1.	Power of muscles	Normal	May be diminished (rarely)
2.	Jerk (deep reflexes)	Pendular	Lost
3.	Cerebellar signs	Present	Absent
4.	Proprioceptive sensations	Present	Lost
5.	Charcot joint and trophic changes	Absent	Present
6.	Romberg's sign	Negative	Positive
7.	Gait	Reeling gait	Stamping gait
8.	Examples	Friedeich's ataxia. multiple sclerosis	Tabes dorsalis, peripheral neuropathy

Features of posterior column lesion :

1. Motor functions :
   a) Nutrition — Mild wasting.
   b) Tone — Diminished.
   c) Power — Normal (i.e., preserved).
   d) Involuntary movements — Absent; rarely pseudo-athetotic movements are seen.
   e) Coordination — Usually normal.
2. Sensory functions :
   a) Touch (crude), pain and temperature -— Unaffected.
   b) Deep sensations (joint, position, vibration sense) with fine touch — Lost.
   c) Girdle-like sensation at the level of compression—Present.

d) Cortical sensations—Lost.

e) Lhermitte's sign — momentary electric shock-like sensation on the back (the spine and into the legs) evoked by neck flexion, and is also known as "Barber s chair sign (causes of Lhermitte's sign are multiple sclerosis, cervical spondylosis, subacute combined degeneration, cervical cord tumour and syringomyelia).

3. Reflexes :
   a) Superficial — Normal.
   b) Deep reflexes or jerks — Diminished or may remain normal.
   c) Plantar response — Flexor.
   d) Bladder and bowel — Normal.
4. Trophic changes — May be present.
5. Romberg's sign - present. Sensory ataxia and stamping gait.

* Loss of proprioception = 'Rombergism'.

Diseases involving the posterior column :

Tabes dorsalis, subacute combined degeneration, cervical spondylosis, compressive myelopathy (posteriorly located), acute transverse myelitis etc.

How to test for coordination :

(A) In the upper limbs :

1. Watch the patient while dressing or undressing, picking up pins from the table, combing etc.
2. Threading a needle.
3. Finger-nose test.
4. Dysdiadochokinesia.

(B) In the lower limbs :

1. To make a circle in the air with the foot while in lying down position.
2. Walking along a straight line and tandem gait.
3. Heel-knee test.
4. Romberg's sign.

* Remember, muscular weakness may be accompanied by clumsiness of movement which may pose difficulty in interpretation of coordination.

What is heel-knee (heel-shin) test ?

The patient lies in bed. Ask him to raise one leg high in the air and then place the heel of the flexed leg on the opposite knee and to then slide the heel down the anterior surface of leg (shin) towards the ankle upto the great toe. Before doing the test, demonstrate it clearly to the patient. Now ask the patient to do the test on the other side. In health, the movement of the heel is smooth and uniform throughout. In cerebellar disorder, the test becomes irregular, and there are errors in the direction and speed of movement.

¥

Common cerebellar disorders :

1. Cerebellar neoplasm (medulloblastoma, haemangioblastoma).
2. Multiple sclerosis.
3. Viral cerebellitis (e.g., post chicken-pox cerebellitis).
4. Cerebellar abscess.
5. Friedreich's ataxia.
6. Other spinocerebellar degeneration (signs of pyramidal tract lesion along with cerebellar signs).
7. Vascular—Thrombosis of the posterior inferior cerebellar artery, cerebellar haemorrhage.
8. Cerebello-pontine angle tumours.
9. Paraneoplastic syndrome.

Acquired causes of cerebellar degeneration :

1. Myxoedema.
2. Phenytoin toxicity.
3. Alcoholic degeneration (chronic alcoholism).
4. Neoplasm anywhere in the body e.g., bronchogenic carcinoma (paraneoplastic^syndrome).
5. Infection (HIV, abscess).

Case 35

BULBAR PALSY

What is bulbar palsy ?

Paralysis or loss of function of the muscles supplied by the cranial nerves arising from the bulb (old name for medulla oblongata) i.e., it is a palato-labio-glosso-pharyngo-laryngeal paralysis. Truely speaking, the motor nuclei of the IXth, Xth, Xlth and Xllth cranial nerves are affected in bulbar palsy. So it is a **LMN type of paralysis.**

What are the major symptoms ?

1. Dysarthria (slurring of speech),
2. Dysphonia or nasal intonation,
3. Dysphagia, and
4. Nasal regurgitation.

* Chocking is another common symptom.

What is pseudobulbar palsy ?

It is the bulbar paralysis due to involvement of bilateral pyramidal tracts in the brain stem or above. So in this **UMN type of lesion,** the voluntary control of the muscles supplied by the IXth, Xth, Xlth and Xllth cranial nerves will be impaired.

Clinical features of IXth, Xth, Xlth and Xllth cranial nerves palsy :

THE RULE OF THREE' :

(A) Glossopharyngeal nerve—

1. Loss of sensation over the mucous membrane of pharynx.
2. Loss of taste sensation in the posterior 1/3rd of the tongue.
3. Do the 'gag reflex' (the afferent is IXth and the efferent is Xth cranial nerve; centre for the reflex lies in medulla) and examine for taste sensation in the posterior 1/3rd of the tongue. ***Gag reflex***— Depress the tongue with a spatula. Touch the posterior wall of pharynx or tonsil by a piece of cotton wrapped in a broom-stick and note its reflex contracion. Normally there is bilaterally symmetrical contraction of posterior pharyngeal wall and fauces of mouth. Test each side seperately, and ask for appreciation of touch sensation. This reflex is lost in bulbar palsy.

(B) Vagus nerve—

a) Soft palate—
   1. Ask the patient for nasal intonation (twang) and hoarseness of voice.
   2. Ask the patient for nasal regurgitation of liquids.
   3. Ask the patient to say 'aah' ! and observe whether both the sides of the palate arch upwards or not.

b) Pharynx—
   1. Dysphagia—Maximum to liquid and minimum to semisolid food, in contrast to mechanical dysphagia where dysphagia is maximum with solid food (liquid food needs immediate muscular contraction to swallow and this is why neurogenic dysphagia occurs earlier with liquid food).

      Moreover, pooling of secretions in the posterior pharynx is noted with drooling of saliva; there may be sensation of choking.
   2. Nocturnal cough—During sleep, saliva goes into the respiratory tract and may precipitate death due to pneumonia.
   3. Test the 'gag reflex'.

c) Larynx—
   1. Hoarseness of voice (adduction of vocal cord is not possible); bovine cough.
   2. Inspiratory dyspnoea (abduction of vocal cord is not possible).
   3. Examine the vocal cord by indirect laryngoscopy.

(C) Spinal accessory nerve—

1. In bilateral paralysis of stemomastoid muscle, head tends to fall back.
2. Test the power of sternomastoids from front.
3. Test the power of trapezius from behind.
   Read the section on 'Myotonia' for proper testing of these muscles.

(D) Hypoglossal nerve—

1. Ask the patient to protrude the tongue — Look for any deviation (deviated to the side of paralysis due to unopposed action of genioglossus of healthy side). The patient may not be able to protrude the tongue much beyond the teeth in bilateral Xllth nerve palsy.
2. Ask the patient to curl his tongue up and down, and sideways. Test the power of the tongue muscles (ask the patient to bulge his cheeks with the tongue against resistance offered by the examiner from outside).
3. While the tongue is kept within the oral cavity, observe for wasting and fasciculation.

Causes *of pseudobulbar and bulbar palsy :*

(A) **Pseudobulbar palsy :**

1. Diffuse cerebral ischaemla (multi-infarct dementia) — Lacunar infarction.
2. Diffuse atherosclerosis (cerebral atrophy).
3. Chronic motor neurone disease (MND).
4. Sometimes in multiple sclerosis (a late event).
5. Cerebral vasculitis.
6. Following severe brain injury.

(B) Bulbar palsy :

a) Acute —

1. Poliomyelitis (bulbar variety).
2. Diphtheria.
3. G. B. syndrome.
4. Rabies.
5. Organophospliorus poisoning.
6. Encephalitis.
7. Snake bite (Elapidae),
8. Botulism.
9. Myasthenic crisis.
10. Medullary infarction.

b) Chronic —

1. Chronic motor neurone disease (MND).
2. Syringobulbia.
3. Neoplasm in the medulla or pontine glioma.
4. Basal meningitis.
5. Neurosyphilis.
6. Fracture of the posterior cranial fossa.
7. Multiple metastasis involving lower cranial nerves.

* Intermittent bulbar palsy—may be seen in myasthenia gravis and multiple sclerosis.

** MND can develop into both pseudobulbar (UMN) and bulbar (LMN) palsy.

Other features to note in bulbar palsy :

The features developing due to involvement of vital centres in the medulla should be carefully monitored (mainly in acute variety).

1. Cardiac centre-—Tachycardia, different arrhythmias.
2. Respiratory centre—Tachypnoea, ataxic breathing, respiratory failure.
3. Vasomotor centre—Hypotension or hypertension.

There may be damage to fibre tracts like pyramidal tract (crossed hemiplegia or decerebrate rigidity), sympathetic trunk (ipsilateral Horner's syndrome), spinothalamic tract (loss of touch, pain, temperature sensation on the opposite side), medial lemniscus (ipsilateral loss of proprioception), vestibulospinal tracts (vertigo), descending tract and nucleus of the Vth cranial nerve (Ipsilateral touch, pain and loss of temperature sensation in the face), and nystagmus.

Reflexes in pseudobulbar and bulbar palsy :

1. Superficial reflex i.e., plantar response is always extensor in pseudobulbar palsy and usually flexor in bulbar palsy (may be extensor, depending on the aetiology e.g., in motor neurone disease).
2. Deep reflex I.e., Jaw jerk is brisk in pseudobulbar palsy and absent in bulbar palsy (a very important sign for differentiation at bedside).

Table 24 : Differentiation between pseudobulbar and bulbar palsy

Features	Pseudobulbar palsy	Bulbar palsy
1. Age	1. Usually above 60 years	1. Depends on the aetiology (usually middle aged)
2. Site of lesion	2. Cortex and subcortex	2. Medulla
3. **Type of lesion**	3. UMN type	3. LMN type
4. Onset	4. Always gradual	4. Acute or gradual
5. Memory loss and emotional instability	5. Present	5. Absent
6. Blood pressure	6. May be high	6. Often normal
-7. Facies	7. Masked facies	7. Nothing suggestive
8: Dysarthria	8. Spastic	8. Flaccid
9. **Tongue**	9. 'Spastic' and firm with pointed tip, there is neither wasting nor any fasciculation seen; small tongue	9. 'Flaccid', wasted, flabby with rounded tip, movements grossly diminished (may occupy one corner of the mouth); fasciculation +
10. **Jaw jerk**	10. Brisk	10 Absent
11. **Plantar response**	11. Extensor	11 Flexor or extensor (depends on aetiology)
12. Bulbar muscle involvement	12. Milder degree	12. Moderate to severe involvement

Disease with combined bulbar and pseudobulbar palsy-^features :

Chronic motor neurone disease (amyotrophic lateral sclerosis) may have combined palsy and is characterised by wasted tongue with brisk jaw jerk.

Management of respiratory paralysis with or without bulbar palsy :

A patient suffering from respiratory paralysis should be treated by artificial respiration which may be required for weeks or months, or indefinitely :

1. Intermittent positive pressure ventilation through a nasal or oral endotracheal tube (when needed for 2-3 days) or through a cuffed tube inserted via a tracheostomy, preferably in a respiratory care unit (RCU) with regular monitoring of blood gases to avoid over- or under-ventilation. Cuffed tube prevents the passage of pharyngeal secretions into the lungs.
2. Appropriate antibiotics to prevent pneumonia.
3. Care of the skin, bladder and bowel.

* Treatment of bulbar palsy requires :

4. Nasogastric suction by mechanical sucker.
5. Postural drainage — Foot end of the bed should be raised and the patient is turned in the semi-prone position.
6. Proper fluid balance.
7. Chest physiotherapy.

Causes of nasal regurgitation of fluid :

1. Paralysis of vagus nerve.
2. Bulbar and pseudobulbar palsy.
3. Polymyositis or dermatomyositis.
4. Myopathy.
5. Cleft palate.
6. Perforation or destruction of palate (syphilis, tuberculosis, leprosy).
8. Malignant disease of nasopharynx.

* Common causes of bulbar palsy : G. B. syndrome, MND, snake bite, diphtheria and poliomyelitis.

** The gag and palatal reflexes are preserved in pseudobulbar palsy.

N.B. : Bach of the long cases e.g., valvular heart diseases, pleural diseases, lymphoma, thalassaemia etc may be treated as short cases.

CHAPTER III : SPOT CASES

Case 36

ANAEMIA

Definition :

It is defined as the qualitative or quantitative diminution of RBC and / or haemoglobin concentration in relation to standard age and sex, and is clinically manifested by pallor. It is not a disease but denotes manifestation of some disease, and thus a cause must be searched for.

Where will you look for anaemia ?

Sites :

1. Lower palpebral conjunctiva (retract the lower eyelids downward and ask the patient to look upwards — both eyes at a time).
2. Tongue, specially the tip and the dorsum.
3. Mucous membrane of palate.
4. Nail-beds (press the pulp to see the redness of nail-bed).
5. Palms, soles and general skin surfaces.

* Nail-beds are the windows of the cutaneous capillary network.

Clinical types of anaemia and its bedside assessment :

Anaemia is clinically classified as mild, moderate and severe types. It is totally a clinical assessment (highly subjective sign) and may not correspond with laboratory findings. Clinically we see the paleness of the skin/mucous membrane, or pallor. The colour of the tongue as well as the conjunctiva are more reliable than other sites in this respect (in adults). In children, palms and soles are to be specially looked for.

Clinical classification :

Mild anaemia — 60-80% of Hb (9-12 g/dl).

Moderate anaemia — 40-60% of Hb (6-9 g/dl).

Severe anaemia — < 40% of Hb (< 6 g/dl).

The normal haemoglobin concentrations in case of males and females are.

Males — 14.6 to 15.5 g/dl, and females — 13.3 to 14.6 g/dl.

* Clinically, 14.5 g/dl may be taken as 100%.

Causes of 'pallor without anaemia' :

See the section on 'Myxoedema'.

* **Pallor** (paleness) is the waxy appearance of skin and mucous membrane. It depends on thickness and quality of skin, and quality and amount of blood in the capillaries. Thus, pallor and anaemia are not interchangeable terms. There are many causes of pallor, and anaemia is commonest of them. Pallor of mucous membrane is commonly due to anaemia; very often generalised pallor is attributed to severe anaemia. It is difficult to detect pallor in deeply pigmented individuals.

** Anaemia is a pathological condition while pallor is a clinical entity. A person without losing a drop of blood may become deadly pale (shock and collapse), and similarly a person looking severely pale may not be grossly anaemic (Sheehan's syndrome).

*** Facial pallor is commonly seen in shock and low cardric outputs state.

general survey, one may write pallor (probably a better terminology) instead of anaemia.

Examination of the hands in anaemia :

1. Colour nail-beds and palms give an indication of presence of anaemia.
2. Koilonychia gives a clue to the type of anaemia, such as iron deficiency anaemia.
3. In severe anaemia, there may be capillary pulsation.
4. Presence of splinter haemorrhage or Osier's node points towards SBE.

5. Anaemia with finger deformities may indicate rheumatoid arthritis.
6. Colour of palmar creases gives a clue to the degree of anaemia. When they are as pale as the surrounding skin, the patient usually has haemoglobin level < 7 g/dl.

* In ophthalmoscopy if the retina seems very pale, the haemoglobin concentration is usually < 4 g/dl.

** Jaundice associated with anaemia points towards haemolytic anaemia.

Haemoglobin concentration is 81%-99% : is it anaemia ?

Yes, it is anaemia but the pallor may not be clinically evident (so this group is not included in the clinical classification of anaemia).

Symptoms referable to anaemia :

Weakness, fatigue, lassitude, light-headedness, giddiness, fainting or syncope, anorexia, palpitation, breathlessness, anginal pain, insomnia, tinnitus, lack of concentration, intermittent claudication, tingling sensation in the extremities and menstrual irregularities are common symptoms.

Importance of 'history taking' in a patient of anaemia :

1. Present history—commonly complaining of easy fatiguability, shortness of breath and decreased effort intolerance.
2. Past history—H/O bleeding (e.g., menorrhagia or haemorrhoids), H/O blood transfusion in the past or diarrhoea (tropical sprue).
3. Personal history—alcohol consumption, walking bare-footed (e.g., hookworm infestation).
4. Family history—similar type of illness in the family suggests genetic inheritance, e.g., thalassaemia, HbE disease, haemophilia.
5. Dietary history—should be taken to diagnose nutritional anaemia (e.g., ture vegetarians may suffer form vitamin B_{12} deficiency anaemia); less intake due to anorexia, dysphagia or poverty.
6. Treatment history—Bone marrow suppresant drugs, NSAID-intake or H/O radiation.
7. Occupational history—H/O exposure to chemical solvents, lead, benzene, insecticides should be taken; a cultivator working bare-footed may suffer from hookworm infestation.
8. Geographic background and ethnic origin—Important to diagnose thalassaemia, sickle cell anaemia, G_6PD deficiency.

Important history to evaluate anaemia :

H/O chronic blood loss (bleeding peptic ulcer, haemorrhoids, menorrhagia), malabsorption (diarrhoea/steatorrhoea), nutritional intake, worm infestations, exposure to drugs/chemicals/radiation, bleeding tendencies, bowel habits, anorexia and loss of weight.

Common causes of severe anaemia in your hospital :

1. Nutritional.
2. Hookworm infestation.
3. Haematemesis and melaena.
4. Chronic bleeding haemorrhoids.
5. Aplastic anaemia.
6. Acute leukaemias.
7. Thalassaemia.
8. Uraemia.
9. Menorrhagia.
10. Carcinoma of stomach, lung, colon.

Importance of stool examination in anaemia ;

1. Presence of occult blood.
2. To diagnose hookworm ova.

Classify anaemia (working classification) :

(A) Based on morphology : normocytic, microcytic, macrocytic.

(B) Based on aetiology :

a) Blood loss, which may be acute or chronic.
b) Inadequate production of RBC.
c) Excessive destruction of RBC.

* It seems anaemia may result from nutritional deficiency, haemorrhage, haemolysis or hypoplasia of the bone marrow.

Cardiovascular (CVS) features in severe anaemia :

1. Tachycardia.

2. Capillary pulsation.
3. Water-hammer pulse.
4. Cervical venous hum.
5. Cardiomegaly (cardiac dilatation) and later signs of heart failure.
6. Hyperdynamic apex beat.
7. Mitral systolic murmur due to functional MI (ring dilatation).
8. Haemic murmur over the pulmonary area.
9. Rarely mid-diastolic (non-rumbling) murmur in mitral area may be auscultated (due to relative stenosis at mitral valve) secondary to Increased blood flow.

* No. 1, 3, 5 and 8 are most important.

Features in other systems in severe anaemia :

1.	General survey	a) Pallor b) Dyspnoea c) Ankle oedema or anasarca.
2.	CVS	Already described above.
3.	G.I. tract	Hepatosplenornegaly may be present.
4.	Respiratory system	Basal crepitations.
5.	Nervous system	Features of polyneuropathy; sometimes, there is papilloedema
6.	Lymphoreticular system	There may be presence of sternal tenderness.

Ankle oedema in anaemia :

1. Severe anaemia per se (renal retention of salt and water).
2. Congestive cardiac failure may be associated with.
3. Associated renal or hepatic disorders, hypoalbuminaemia, myxoedema.

Common causes ***of anaemia in this part of world :***

1. Nutritional anaemia (so, dietary history is important).
2. Hookworm infestation.
3. Chronic malaria, chronic kala-azar, tuberculosis.
4. Thalassaemia.
5. Tropical sprue.

* Transfusion is usually required when Hb level goes below 7 g/dl. One unit (2 units in India) of packed red cells elevates the haemoglobin by approximately 1 g/dl.

** Globally, 'chronic blood loss' is probably the commonest cause of anaemia.

Common causes of iron deficiency anaemia :

1. Nutritional deficiency.
2. Bleeding peptic ulcer.
3. Gastric erosion by NSAID.
4. Bleeding haemorrhoids.
5. Hookworm infestation.
6. Malabsorption syndrome.
7. Menorrhagia.
8. Pregnancy, lactation.

* This Is why stool is examined for ova/parasite/cyst/occult blood, upper and lower G.I. endoscopy are performed with barium study, and gynaecological evaluation are done for 'chronic blood loss'.

Clinical diagnosis of iron deficiency anaemia :

1. H/O 'pica' (eating of strange non-nutrient items such as clay—geophagia, ice—pagophagia, cornstarch—amylophagia, or coal) or chronic blood loss from G. I. tract.
2. Pallor (pearly white sclera).
3. ***Glossitis*** (bald or depapillated tongue)
4. *Angular stomatitis,* cheilosis.
5. Brittle finger nails, flat nails (platynychia) or even *koilonychia.*
6. Brittle hairs.
7. Dysphagia (Plummer-Vinson syndrome or Paterson-Kelly syndrome) as a result of post-cricoid web which can be demonstrated endoscopically or by barium swallow.
8. Mild splenomegaly, rarely.

* 'Pica' (i.e., perverted appetite) is also observed in pregnancy and some psychiatric disorder.

Enucleation of the left eye

Enophthalmos (right) – phthisis bulbi of the right eye resulting from smallpox in childhood

Massive **cervical adenopathy** producing bull-neck from lymphoma; infiltration of chest and anterior abdominal skin resulted in 'lymphoma cutis'

Cavernous sinus thrombosis in the left side resulting in proptosis, ptosis and ophthalmoplegia

A moribund patient showing **proptosis** due to involvement of the right eye from lymphoma (NHL); cervical adenopathy is also noted

SVC syndrome. Note the prominent external jugular veins, and veins over the anterior chest wall. The face is puffy, and chest and upper limbs are swollen. The patient had moderate degree of respiratory distress

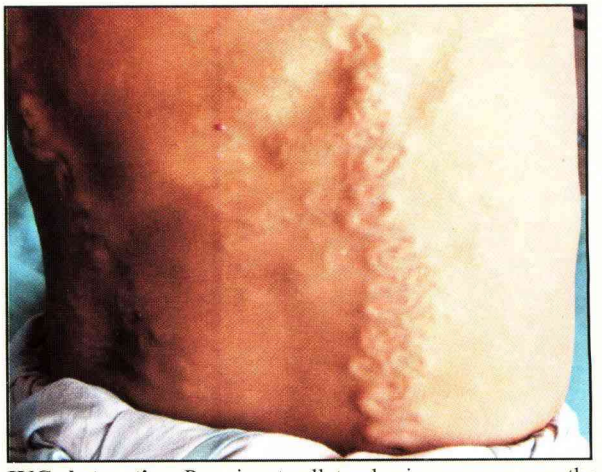

IVC obstruction. Prominent collateral veins are seen over the anterior abdominal walls and flanks. There is absence of ascites

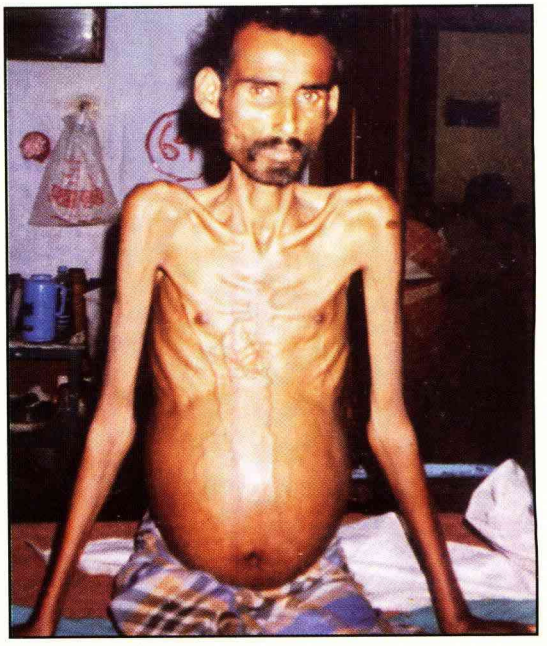

Portal hypertension. Prominent and tortuous veins over the abdomen as well as ascites are present. The patient is grossly emaciated – a classical case of cirrhosis of liver

Portal venous obstruction showing prominent collaterals. Venous hum is audible over the visible veins

Engorgement of both external and internal **jugular veins** in a patient with congestive cardiac failure

Causes of glossitis and angular stomatitis :

(A) Glossitis (inflammation with red and sore tongue) :

a) Riboflavin deficiency—Magenta-coloured tongue.

b) Iron deficiency anaemia.

c) Nicotinic acid or vitamin B_{12} deficiency—The tongue is red, swollen, painful and is known as *raw-beefy tongue'.

d) Folic acid deficiency.

e) Bald tongue (complete atrophy of papillae)—Found in severe iron deficiency anaemia, tropical sprue, pernicious anaemia, pellagra and syphilis.

f) Median rhomboid glossitis— A lozenge-shaped denuded area in the middle of the tongue posteriorly. It is a congenital abnormality and as it feels nodular, it should be differentiated from carcinoma of the tongue.

g) Miscellaneous—cirrhosis of liver, tuberculosis.

(B) Angular stomatitis (inflammation of the skin at the angle or corner of the mouth) :

a) Excessive use of tobacco, alcohol or betel-leaf.

b) Improperly-fitted denture.

c) Iron deficiency anaemia.

d) Riboflavin, nicotinic acid, folic acid and pyridoxine deficiency.

e) Starvation or malnutrition.

f) Herpes labialis, candidiasis or streptococcal infection at the angle of mouth.

g) 'Perleche', in children, are infective in origin.

Causes oj dimorphic anaemia :

Dimorphic anaemia is macrocytic hypochromic in type (mixture of iron deficiency and megaloblastic anaemia). Common causes are,

1. Pregnancy.
2. Hookworm anaemia with nutritional deficiency.

Causes of haemolytic anaemia i

See the sections on 'Jaundice' and Thalassaemia'.

How do you diagnose hookworm infestation ?

1. Occupation e.g., patients working in tea-garden, coal mines or a farmer who walks bare-footed.
2. Presence of ground itch at the site of entry in the skin.
3. Perversion of taste sensation with 'pica' (often they eat earth, mud or lime).
4. Blotting paper like tongue (very pale tongue) with puffy face and swelling of lower eyelids. Koilonychia and pedal oedema are frequently observed. There is lustreless hair with protuberant abdomen. Other features of iron deficiency anaemia may be present.
5. Pain in the epigastrium mimicking chronic duodenal ulcer.
6. Steatorrhoea or fatty diarrhoea.
7. Passage of small worms in stool.

Causes of anaemia due to chronic systemic diseases :

(A) Anaemia of chronic inflammation :

a) Infection—SBE, lung abscess, tuberculosis, osteomyelitis, pyelonephritis.

b) Collagen vascular disorders—SLE.

c) Malignancy.

d) Rheumatoid arthritis.

(B) Uraemia.

(C) Endocrine disorders—Myxoedema, Addison's disease, panhypopituitarism.

(D) Liver disease—Specially in alcoholics.

The whole spectrum is associated with normocylic normochromic anaemia. Group (A) may have microcytic anaemia. Group (B) may have Burr cells, and Group (C) and (DJ may show macrocytic RBCs. The total gorup will have low serum iron, low TIBC, and normal or elevated serum ferritin level.

What is 'leucoerythroblastic' blood picture ?

When normoblasts and myelocytes both are seen In the peripheral blood of patients suffering from myelophthisic anaemia (infiltration of bone marrow by tumour or granuloma), M_6 variety of AML, myelofibrosis or myelosclerosis, it is said that leucoerythroblastic blood picture is present.

Outline of investigations in anaemia :

The investigations are directed to see the type and aetiology of anaemia :

(A) The type of anaemia is ascertained by peripheral blood smear, blood indices and serum values

a) Peripheral blood smear—RBC morphology, reticulocytes, malaria parasite.

b) Blood indices—MCV, MCH, MCHC.

c) Serum values—serum iron concentration, TIBC, serum ferritin.

(B) The cause of anaemia is determined by meticulous history taking, clinical examination, haematological tests (described above), examination of stool/urine, chest X-ray, spetial haematological tests (Coombs' test, osmotic fragility test, Hb-electrophoresis etc), and in selective cases by bone marrow study.

How do you examine a patient for polycythemia ('ruddy cyanosis') ?

Polycythemia is the increase in red blood cells above normal.

It is examined in the same way as done for the clinical detection of anaemia i.e, look for the lower palpebral'conjunctiva, tongue, palate, nail-beds, palms and soles, and general skin surface. The colour of the mucous membrane turns dusky-red. Patients of polycythemia usually have facial plethora, suffused conjunctiva, increased redness of lower palpebral conjunctiva and palmar erythema.

Common causes of polycythemia in tertiary care hospitals :

1. COPD.
2. Cyanotic congenital heart diseases e.g., Fallot's tetralogy.
3. Right-to-left shunt in the heart.
4. Polycythemia vera.

* High altitude and severe dehydration (relative polycythemia) are also common causes of polycythemia. Thrombosis, peptic ulceration (often with bleeding) and hyperuricaemia are noted complications of polycythemia vera.

Anaemia and polycythemia in a single patient—is it possible ?

Sometimes it is seen in Fallot's tetralogy where anaemia (iron deficiency) is not clinically evident in the presence of polycythemia. If Hb% is < 18 g/dl, PCV is < 55%, and MCHC is < 28 g/dl, one should be suspicious about anaemia in the presence of polycythemia in a case of Fallot's tetralogy.

Normal reticulocyte count, reticulocyte index and red cell mass (volume) :

(A) Reticulocyte count— 0.2-2% of RBCs (increased in haemolytic anaemia).

(B) Reticulocyte index— $\text{Reticulocyte \% x} \frac{\text{Patient's PCV}}{\text{Normal PCV}}$

(C) Red cell mass— (i) Male - 30 ml/kg of body weight.
(ii) Female - 25 ml/kg of body weight.
(increased in polycythemia vera).

Conclusion :

Always examine both the lower palpebral conjunctiva because the presence of conjunctivitis in one eye may interfere with the interpretation of anaemia if anyone examines the infected eye only. While examining the tongue for anaemia, very often magenta-coloured tongue (riboflavin deficiency) misguides a clinician. By retracting the lower eyelids downwards, one can diagnose two other conditions e.g., polycythemia (increased redness of conjunctiva) and scleroderma (increased tightness of the skin during retraction). Do not examine the eyes for anaemia if it is rubbed or washed just before testing.

Earliest sign of acute blood loss is tachycardia and postural hypotension, and not anaemia because haemodilution (resulting anaemia) is completed in 24-36 hours.

Case 37

CYANOSIS

What is cyanosis ?

It is defined as bluish discolouration of the skin and mucous membrane due to presence of increased amount of reduced haemoglobin (> 5 g/dl), or of haemoglobin derivatives in the capillary blood. Absolute concentration of reduced haemoglobin above 5 g/dl in the capillaries makes the blood dark and gives the tissue a bluish hue ('kyanos' means dark blue colour and 'osis' means condition). According to few clinicians, > 4 g/dl of reduced (desaturated) haemoglobin in the capillary blood produces cyanosis (recent view).

Cyanosis is a grave sign and needs immediate evaluation as well as intervention.

Types of cyanosis :

It is principally of two types : Central and peripheral cyanosis.

* Other clinical types of cyanosis are : enterogenous, mixed and differential cyanosis.

Peripheral cyanosis and sites to be examined :

In peripheral cyanosis, the arterial blood is normally saturated ***(arterial PaO_2 is normal)*** but there is oxygen unsaturation at the venous end of capillary. Peripheral cyanosis results^from excessive extraction of oxygen from the normally saturated arterial blood. The different mechanisms play in its production are,

a) Reduced cardiac output.
b) Peripheral vasoconstriction.
c) Slow speed of circulation in the extremities.

Sites to be looked for (in good natural light)—

1. Tip of the nose.
2. Ear lobules.
3. Outer aspect of lips, chin and cheek.
4. Tip of fingers and toes.
5. Nail-bed of fingers and toes.
6. Palms and soles.

Tongue remains unaffected. Mechanism : stagnant as well as over-utilisation hypoxia.

Causes of peripheral cyanosis :

1. Exposure to cold air or cold water (possibly the most common cause).
2. Congestive cardiac failure (reduced cardiac output).
3. Frost bite.
4. Raynaud's phenomenon (read the section on 'Scleroderma')—only seen in fingers.
5. Shock or peripheral circulatory failure due to any cause.
6. Venous obstruction—produces local cyanosis (e.g., SVC syndrome).
7. Hyperviscosity syndrome (e.g., multiple myeloma, polycythemia, macroglobulinaemia).
8. Arterial obstruction e.g., peripheral vascular disease (atherosclerosis, Buerger's disease, atheroembolism).
9. Cryoglobulinaemia (abnormal globulin which forms gel at low temperature e.g., lymphoma).
10. Mitral stenosis (lips, tip of the nose and cheeks may be cyanosed in mitral facies).
11. Septicaemia (gram negative organisms commonly).

Central cyanosis and sites to be examined :

There is decreased arterial oxygen saturation as a result of marked reduction in oxygen tension in the arterial blood ***(arterial PaO_2 is reduced)*** either due to imperfect oxygenation of blood in lung or admixture of venous and arterial blood. This is usually detected when the oxygen saturation of arterial blood goes below 80-85%.

Sites to be looked for (in good natural light)—

1. Tongue (mainly the margins as well as the undersurface).
2. Inner aspect of lips.

3. Mucous membrane of gum, palate, cheeks.
4. Lower palpebral conjunctiva.
5. **Plus,** the sites mentioned in the peripheral cyanosis (one must examine these sites)—as same deoxygenated blood circulates everywhere in the body i.e., patients with central cyanosis will also be cyanosed peripherally.

* Mechanism : hypoxic hypoxia.

** In dark-skinned persons, examination of oral mucous membrane and conjunctiva are more helpful.

Causes of central cyanosis :

1. Cyanotic congenital heart diseases e.g., Fallot's tetralogy, transposition of great vessels.
2. Acute pulmonary oedema (due to left-sided heart failure)—most common 'cardiac cause.
3. Eisenmenger's syndrome (ASD, VSD or PDA with reversal of shunt due to development of pulmonary hypertension).
4. Acute severe asthma.
5. COPD, cor pulmonale, respiratory failure; respiratory depression (e.g., opium poisoning).
6. Lobar pneumonia.
7. Fibrosing alveolitis.
8. Tension pneumothorax.
9. Acute laryngeal oedema.
10. Acute pulmonary thromboembolism.
11. Pulmonary arteriovenous fistula (congenital, or acquired due to cirrhosis of liver).

* Never forget, high altitude (due to low partial pressure of 0_2) as a cause of central cyanosis.

** In arterial blood, 95% of Hb is saturated with 0_2 (i.e., only 5% reduced) whereas in venous blood the 0_2 saturation is 70% (i.e., 30% reduced). Hence normally a mean of the two (5% to 30%, i.e., 0.75 g/dl to 5 g/dl reduced Hb) is present in the capillaries, and skin and mucous membrane remain pink. If the level crosses > 5 g/dl, the skin becomes blue or dusky.

What is 'enterogenous cyanosis' or pigment cyanosis ?

When cyanosis is produced due to the presence of excessive sulphaemoglobin (> 0.5 g/dl) or methaemoglobin (> 1.5 g/dl) in the blood, it is known as enterogenous cyanosis. Few clinicians include it within central cyanosis. The causes are :

1. Hereditary haemoglobin M disease.
2. Poisoning by aniline dyes (often added in sweets).
3. Drugs like nitrates and nitrites (nitroglycerin, sodium nitroprusside, amyl nitrite), phenacetin, sulphonamides, dapsone; nitrite may be present in well-water.
4. Carboxyhaemoglobinaemia (a cherry-red flush common in smokers; not true cyanosis).

* Diagnosis is confirmed by spectroscopic examination of the blood.

Differential diagnosis of bluish discolouration of body :

1. Cyanosis.
2. Carbon monoxide poisoning—Actually it is a cherry-red flush due to carboxyhaemoglobin.
3. Argyria—Deposition of silver salts in the skin due to silver poisoning. The skin does not blanch on pressure (cyanosed skin blanches on application of pressure). It gives a slatey-grey hue.
4. Osteogenesis imperfecta—Only the sclera is blue. Due to thinness of the sclera, the choroid with its vessels give rise to blue tinge in the eyes. Cardinal features of this disease are fragile bones with multiple fractures, blue sclera, loose-jointedness and deafness.
5. Drug like amiodarone (used in ventricular arrhythmias) may produce bluish hue in the skin (ceruloderma).

Central plus peripheral (mixed) cyanosis :

1. CCF due to left-sided heart failure.
2. Acute myocardial infarction (cardiogenic shock) with acute LVF.
3. Rarely in polycythemia (red cyanosis).

What is differential cyanosis ?

1. Hands red (i.e., less blue) and feet blue—seen in PDA with reversal of shunt (differential cyanosis).

2. Hands blue and feet red (i.e., less blue)—seen in coarctation of aorta with transposition of great vessels (reverse differential cyanosis).

* Intermittent cyanosis is seen in Ebstein's anomaly.

What is orthocyanosis ?

It is the development of cyanosis only in upright position due to hypoxia occuring in erect posture as a result of associated pulmonary arteriovenous malformations.

Table 25 : Bedside differentiation between central and peripheral cyanosis

	Features		Central cyanosis		Peripheral cyanosis
1.	Sites	1.	As described above. Commonly seen in warm mucous membranes like **tongue** and oral cavity	1.	As described above. Tongue remains unaffected
2.	Handshake	2.	Hand feels warm (due to increased blood flow)	2.	Hand feels cold (due to diminished blood flow)
3.	Application of warmth (by rubbing two palms) and cold (ice)	3.	No change	3.	Warmth—cyanosis decreased Cold—cyanosis increased
4.	Application of pure oxygen for 10 minutes	4.	Cyanosis may improve	4.	No response
5.	**Clubbing** and polycythemia	5.	Usually present	5.	Absent
6.	Pulse volume	6.	Normal or high (due to arteriovenous shunt) volume	6.	Usually low volume
7.	**Dyspnoea**	7.	Patient is often breathless	7.	No respiratory distress

* It very difficult to diagnose cyanosis in the presence of polycythemia.

** Clubbing is absent in peripheral cyanosis and acutely developing central cyanosis.

Facts to be remembered :

- Cyanosis with clubbing—cyanotic congenital heart disease, pulmonary arteriovenous fistula, fibrosing alveolitis, extensive bronchiectasis, cystic fibrosis.
  - Cyanosis without clubbing—peripheral cyanosis and acutely developing central cyanosis.
- Clubbing without cyanosis—SBE, ulcerative colitis, normal healthy persons.

How to diagnose enterogenous cyanosis ?

1. H/O ingestion of blue sweets or drugs (mentioned earlier).
2. Skin and mucous membrane (tongue) are blue but the patient is not breathless.

Vou ***are allowed to see only one site in cyanosis : what to do*** ?

One should examine the tongue. **If the tougue is blue, the cyanosis must be central** but if the fingertips are blue, it may be either of central or peripheral in type.

Other sites looked for central cyanosis :

1. Nasal mucous membrane examined by nasal speculum.
2. Rectal mucous membrane seen by proctoscopy.
3. Retina examined by ophthalmoscopy.

Both cyanosis and polycythemia are commonly present in :

1. Cyanotic congenital heart diseases, and
2. COPD.

How hypoxia and cyanosis are related ?

- Hypoxaemia without cyanosis—severe anaemia (Hb < 5 g/dl).
- Cyanosis with hypoxaemia—if reduced Hb is > 5 g/dl.
- Cyanosis without hypoxaemia—polycythemia vera (red cyanosis).

N.B. : After careful examination of the patient for cyanosis, one should examine for the presence of dyspnoea and clubbing. It should be remembered that a severely anaemic patient (Hb level below 5 g/dl) is possibly not cyanosed (though there is decreased 0_2 saturation). For cyanosis to become clinically evident, there must be a minimum quantity of reduced Hb (at least 5 g/dl) in the blood perfusing the skin.

Case 38

JAUNDICE

Definition :

It is defined as yellowish discolouration of the skin and mucous membrane due to excess amount of bilirubin present in the blood.

What is latent jaundice ?

The normal serum bilirubin level is 0.3-1.0 mg/dl. Clinical jaundice is evident when serum bilirubin crosses 3 mg/dl. Jaundice is latent, i.e., clinically non-evident (only detected by serum analysis) when the seruiji bilirubin level is in between 1-3 mg/dl.

Sites to be examined in a patient of jaundice :

Jaundice is always seen in bright natural daylight as it is not possible to detect light yellow colour in the presence of artificial light. **Take the patient in front of an open window** (never put a lighted torch) and look for :

1. ■ Upper bulbar conjunctiva (sclera is examined by retracting the upper eyelids upwards and asking the patient to look downwards - both eyes at a time).
2. Undersurface of tongue (sublingual mucosa).
3. Palate.
4. Palms and soles.
5. 'General skin surface.

Why the upper bulbar conjunctiva is selected ?

1. Sclera contains a lot of elastin (bilirubin has a strong affinity for elastic tissue), and
2. A white background is formed by sclera.

Differential diagnosis of jaundice :

1. Carotenaemia (carotenoderma)—Skin is yellow (mainly the palms and soles) but the sclera and mucous membrane are unaffected. The serum is also yellow in colour; the stool and urine are of normal colour.
2. Atabrine toxicity (previously used in malaria and tapeworm infestations)—Skin, urine and eyes (only the regions of the sclera exposed to light) are yellow.
3. Diffuse xanthomatosis—Skin takes a yellowish-orange tinge.
4. Muddy sclera—Exposed part of sclera looks dirty yellow; non-pathological.

Body secretions where bilirubin is found (in jaundice) :

1. Found in body fluids like CSF, joint fluid, cysts.
2. Absent from true secretions like tears, saliva, pancreatic juice.

* Scar tissue is rarely bilirubin-stained. Bilirubin has a strong affinity for elastic tissue (sclera, skin), nervous tissue (basal ganglia) and as it binds with proteins, it is more evident in exudates.

What is unilateral jaundice ?

It is seen :

1. In patients with hemiplegia.
2. In the presence of unilateral oedema.

Paralysed extremity and oedematous areas tend to remain less coloured as good circulation is necessary to stain the tissues.

3. Rarely, yellowish discolouration is seen in one eye when the other eye is 'artificial'.

* Right palm may look yellowish in health, who cooks at home (after using turmerik, specially in females).

Clinical classification of jaundice :

1. Hemolytic,
2. Hepato-cellular, and
3. Obstructive
   a) Intrahepatic (medical).
   b) Extrahepatic (surgical).

* Jaundice is described clinically as mild(< 6 mg/dl), moderate (6-15 mg/dl) and severe (>15 mg/dl).

** Jaundice may also be classified by chemical nature of bilirubin : conjugated and unconjugated hyperbilirubinaemia.

Features of haemolytic jaundice :

1. **Acholuric urine,** i.e., freshly passed urine is of normal colour as there is absence of bilirubin in urine (unconjugated urine is not water-soluble) but if the urine sample is kept for sometime, it turns dark yellow due to conversion of urobilinogen to urobilin (by oxidation).
2. Stool is high-coloured due to excess amount of stercobilinogen and stercobilin.
3. Jaundice is usually mild and there is **lemon-yellow tinge** of bulbar conjunctiva. Serum bilirubin is usually less than 6 mg/dl and predominantly of unconjugated variety.
4. Anaemia (mild, moderate or severe, according to the degree of haemolytic process).
5. Splenomegaly — Very characteristic (spleen is the slaughter house of RBC in haemolysis).
6. The patient may have typical facies (e.g., chipmunk facies in thalassaemia).
7. Reliculocytosis.

* In health, bilirubin can not be detected in urine. Urochrome and uroerythrin are the pigments which give normal urine its characteristic colour. In health, urinary urobilinogen (detected by Ehrlich's aldehyde test) and faecal stercobilinogen excretion per day are 1-3.5 mg and 40-280 mg respectively.

Features of obstructive jaundice :

1. Urine—Deep yellow or mustard oil-like colour (due to presence of conjugated bilirubin).
2. Stool—Pale or clay coloured (china-clay) with steatorrhoea (steatorrhoea means frothy, bulky, pale, offensive, soft, greasy stool which floats on the water of the pan, and is difficult to flush from the pan) due to absence of bile pigment in the stool.
3. Jaundice— Usually deep jaundice and the bulbar conjunctiva turns **greenish-yellow** due to oxidation of bilirubin to biliverdin (green). Jaundice is gradually progressive or fluctuating. Serum bilirubin is usually very high and predominantly of conjugated variety.
4. Generalised pruritus with scratch marks and shiny nails (bile acids irritate the free nerve endings).
5. Sinus bradycardia—Probably bile salts directly inhibit the sinoatrial node.
6. Xanthelasma around the eyes or xanthoma in the knees, buttocks may be seen due to hypercholesterolaemia.
7. Petechiae, purpura or ecchymosis are seen due to vitamin K deficiency (lack of bile salts produces vitamin K malabsorption as it is a fat soluble vitamin).
8. Gall bladder—May be palpable. This indicates the site of obstruction in the bile duct and is usually due to carcinoma of the head of pancreas (not due to choledocholithiasis)—according to ***Courvoisier's law.***
9. Prolonged obstructive jaundice may produce osteomalacia, bone pain, bone fracture, or night blindness due to vitamin D, or A deficiency respectively (due to malabsorption or steatorrhoea). These type of bony changes in obstructive jaundice is known as 'hepatic osteodystrophy'.

10. Rarely, there may be hepatosplenomegaly. History of fever with chill and rigor, and pain abdomen may be present due to cholangitis. There may be abdominal pain in choledocholithiasis.

* Features of ***chronic cholestasis*** are pruritus with scratch marks, xanthoma, bruising and bone pain.

Features of hepato-cellular jaundice :

1. Urine—Yellowish.
2. Stool—High coloured and becomes pale if there is obstruction due to cellular (hepatocytes) oedema.
3. **Orange-yellow tinge** of the bulbar conjunctiva (conjugated > unconjugated bilirubin).
4. Anorexia, nausea, vomiting, fever with chill and rigor may be present before the appearance of jaundice (e.g.. in viral hepatitis).
5. Tender hepatomegaly is frequent.
6. Variable pruritus.
7. There may be bleeding manifestations as a result of hepato-cellular failure.
8. There may be H/O affection of other members of the family or locality (viral hepatitis), drug intake (rifampicin) or poisoning (copper sulphate).

Bile salts and bile acids :

(A) BILE SALTS— Sodium taurocholate and sodium glycocholate.

(B) BILE ACIDS-

a) Primary—Cholic acid and chenodeoxycholic acid.
b) Secondary—Deoxycholic and lithocholic acid.
c) Tertiary—Ursodeoxycholic acid.

What is Murphy's sign ?

Ask the patient of ***acute cholecystitis*** to breathe in deeply, and now try to palpate the gall bladder in sitting position. There is tenderness and catch in the breath at the height of inspiration with a mass felt there. This sign is not found in chronic cholecystitis. When the examination is performed with the patient lying, it is known as Moynihan's method.

What is Courvoisier's law?

Palpable, non-tender, smooth gall bladder in a patient of obstructive jaundice is due to neoplastic obstruction (usually due to carcinoma of the head of pancreas) of the common bile duct (CBD) and not due to impacted stone in the CBD. In case of choledocholithiasis, the gall bladder is usually small and contracted, and thus non-palpable due to repeated cholecystitis.

Table 26 : Differentiation between surgical and medical jaundice

Features	Extrahepatic (surgical) obstruction	Intrahepatic (medical) obstruction
(A) History :		
(1) Age	(i) Middle aged or old	(i) Usually young
(ii) Antecedent history	(ii) Previous attack, dyspepsia	(U) History of contacts, injections or blood transfusion, or nothing significant
(ill) Rate of development of jaundice	(iii) Slow	(iii) Rapid
(iv) Pain	(iv) Common (H/O colic)	(iv) Uncommon (usually ache over liver)
(v) Type of jaundice	(v) Fluctuates or persistent	(v) Acute onset, slow fall with recovery
(vi) Pruritus	(vi) Characteristically prominent feature	(vi) Often transient
(vii) Anorexia	(vii) Present but not so prominent	(vii) A prominent feature

Features	Extrahepatic (surgical) obstruction	Intrahepatic (medical) obstruction
(B) Examination:		
(i) **Splenomegaly**	[1] **Rare**	(i) **May be present**
(ii) **Hepatomegaly**	(H) **Slightly tender hepatomegaly**	(ii) **Markedly tender hepatomegaly**
(Ui) **Palpable gall bladder**	(iii) **May be palpable due to carcinoma of the head of pancreas**	(iii) **Not palpable**
(iv) **Ascites**	(iv) **Usually absent**	(iv) **May be present in severe & prolonged obstruction**
(v) **Temperature**	(v) **May be raised (due to cholangitis)**	(V) **Raised initially**
(vi) **Anaemia**	(vi) **May be present**	(vi) **Usually absent**
(C) Laboratory investigations :		
[1] **WBC count in blood**	(i) **Increased or normal**	(i) **Diminished or normal**
(ii) **Differential count of WBC**	(ii) **Neutrophilia**	[11] **Increase in lymphocytes or eosinophils (in drug-induced jaundice)**
(iii) **Serum bilirubin**	(iii) **Usually 3-10 mg/dl; may be more**	(iii) **Varies with severity**
(IV) **AST and ALT**	(iv) **< 5 times of normal**	(iv) **> 5 times of normal**
(v) **Alkaline phosphatase**	(v) **> 3 times of normal**	(v) **< 3 times of normal**
(vi) **Ultrasonography or CT scan**	(vi) **May diagnose stones in CBD or carcinoma of the head of pancreas**	(vi) **Splenomegaly**
(D) Therapeutic trial:		
'Prednisolone white wash' test	**No response**	**Often +ve**

Common examples of different types of jaundice in city hospitals :

(A) Haemolytic :

1. Thalassaemia.
2. Mismatched blood transfusion.
3. Snake bite (Viperidae group).
4. Malaria (specially falciparum malaria).
5. Rh incompatibility.
6. Primaquine or sulphonamide-induced (in G_t.PD deficiency)

(B) Obstructive :

a) Intrahepatic (medical) cholestasis :

1. Cholestatic viral hepatitis.
2. Chronic active hepatitis.
3. Cirrhosis of liver (specially, primary biliary cirrhosis).
4. Lymphoma or tuberculosis.
5. Pregnancy in last trimester (recurrent cholestasis).
6. Drugs—Chlorpromazine, chlorpropamide, oral contraceptives, erythromycin oestolate, methimazole, methyl testosterone, anabolic steroids.
7. Secondary carcinoma of liver (jaundice is rarely seen in hepatoma).
8. Dubin-Johnson syndrome.

b) Extrahepatic (surgical) cholestasis:

1. Gall stone impaction in CBD.
2. Carcinoma of the head of pancreas, periampullary carcinoma.
3. Carcinoma of the gall bladder.
4. Enlarged glands at porta hepatis.

5. Stricture of CBD.
6. Sclerosing cholangitis (from inflammatory bowel disease), cholangiocarcinoma.

(C) Hepato-cellular :

1. Viral hepatitis (type A. B, C and E commonly).
2. Drugs — Rifampicin, INH, after halothane anaesthesia, paracetamol overdose.
3. Poisons — Copper sulphate.
4. Pregnancy — Acute fatty liver of pregnancy.
5. Alcoholic hepatitis, chronic hepatitis, cirrhosis of liver.
6. Weil's disease.
7. Right-sided heart failure.
8. Wilson's disease.

* A young person is more likely to have viral hepatitis (take H/O travel, alcohol abuse, male homosexuality, female prostitution, blood transfusion) whereas an elderly person with weight loss is more likely to suffer from carcinoma.

Diseases present as latent jaundice :

1. Mitral stenosis (i.e., passive venous congestion of liver).
2. Acute myocardial infarction.
3. Acute pulmonary thromboembolism.
4. Cirrhosis of liver.
5. Pernicious anaemia.
6. Acute pancreatitis.
7. Congestive cardiac failure.

Fluctuating jaundice :

1. Gilbert's syndrome.
2. Stone impaction in CBD (Charcot's biliary triad).
3. Periampullary carcinoma.
4. Haemolytic anaemias.
5 Chronic parenchymal liver disease (e.g. chronic active hepatitis).
6. Dubin-Johnson syndrome.

What is 'prednisolone white wash' test ?

If 30 mg of prednisolone (reduces cellular oedema) is given daily for 5 days to a patient of hepato-cellular jaundice with features of obstruction (e.g., cholestatic viral hepatitis), there is a 40% fall in serum bilirubin. This test differentiates between medical and surgical obstructive jaundice (in a desperate situation) and gives positive result in medical jaundice. The test should not be used routinely. Before doing the test, hepatitis B and C markers must be negative.

Familial non-haemolytic hyperbilirubinaemias :

1. Gilbert's syndrome — I Unconjugated hyperbilirubinaemia
2. Crigler-Najjar syndrome (type I and II) '
3. Dubin-Johnson syndrome — I Conjugated hyperbilirubinaemia
4. Rotor syndrome — J

Differences between conjugated and unconjugated bilirubin :

	Unconjugated	Conjugated
1. Water solubility	0	+
2. Affinity for lipids	+	0
3. Renal excretion	0	+
4. van den Bergh reaction	Indirect	Direct

Fractionation of normal bilirubin :

Normal serum bilirubin level is 0.3-1.0 mg/dl.

(i) Conjugated fraction is 0.1-0.3 mg/dl, and (ii) Unconjugated fraction is 0.2-0.7 mg/dl.

Predominantly conjugated and unconjugated hyperbilirubinaemias :

(A) Conjugated hyperbilirubinaemia (with > 50% conjugated fraction) :

(i) Viral or drug-induced hepatitis.
(ii) Drug-induced cholestasis.
(iii) Cholestatic jaundice of pregnancy.
(iv) Cirrhosis of liver.
(v) Extrahepatic biliary obstruction (e.g., stone, stricture etc.).
(vi) Dubin-Johnson syndrome.
(vii) Rotor syndrome.
(viii) Secondary carcinoma of liver.

* Among steps of bilirubin metabolism (uptake, conjugation and excretion), excretion is the rate-limiting step and is usually affected most. Thus, conjugated hyperbilirubinaemia predominates in hepato-cellular diseases.

(B) Unconjugated hyperbilirubinaemia (usually with > 80% unconjugated fraction) :

(i) Haemolysis.
(ii) Ineffective erythropoiesis.
(iii) Prolonged fasting (< 300 cal/day).
(iv) Sepsis.
(v) Gilbert's syndrome and rarely, Crigler-Najjar syndrome.
(vi) Neonatal jaundice.

Hepatic disorders uncommonly associated with jaundice :

1. Hepato-cellular carcinoma (hepatoma).
2. Amoebic liver abscess.
3. Cystic disease of liver.

Can you detect jaundice at night ?

As previously discussed, jaundice should always be seen in broad daylight. But in a desperate situation, one has to examine the patient for jaundice at night remembering that in artificial light :

- Mild jaundice may be missed.
- Severely anaemic patient seems to have mild jaundice.
- Fluorescent or tube light gives yellow reflection in normal eye mimicking jaundice.

Medical causes of extrahepatic obstruction :

1. Sclerosing cholangitis in ulcerative colitis.
2. Obstruction by round worm in CBD.
3. Enlarged lymph nodes at porta hepatis in lymphoma.

* *Never put lighted torch inside the oral cavity to diagnose anaemia, cyanosis or jaundice.*

** Highest level of bilirubin is observed in hepato-cellular jaundice (may be in excess of 50 mg/dl). In cholestatic (obstructive) jaundice, bilirubin may reach upto 40 mg/dl and then remains around 30-40 mg/dl as a result of balance between renal excretion and conversion of bilirubin to other metabolites. In hepato-cellular jaundice, this balance is not seen rather high level of bilirubin may be explained by concomitant haemolysis and renal insufficiency.

Case 39

PULSE

Definition :

It is the expansion and elongation of the arterial wall imparted by the column of blood, and is passively produced by the pressure changes during ventricular systole and diastole. Commonly we examine the pulse in the radial artery in hand, which is one of the most accessible peripheral artery. Moreover, as soon as the hand (radial artery) of a patient is touched, it builds the doctor-patient relationship.

Pulse, blood pressure, respiration, temperature and level of consciousness are regarded as **'vital signs'** in clinical medicine.

Points to note in examination of pulse :

1. Rate.
2. Rhythm.
3. Volume.
4. Condition of the arterial wall.
5. Comparison between two radial pulses
6. Radio-femoral delay.
7. Any special character.
8. Palpation of other peripheral arteries.

N.B. : ***Pulse should always be described under these eight points.*** "Tension' Is the indirect estimation of blood pressure. Estimation of tension by palpation is totally unreliable and thus, it is not included within the points under examination of pulse. Tension (i.e., blood pressure) should be accurately measured by sphygmomanometer.

How to examine the pulse ?

The radial pulse at the right wrist of the patient (present lateral to the flexor carpi radialis tendon) is generally examined with the pulp of three fingers (index, middle and ring finger). The patient's forearm will be semipronated and the wrist slightly flexed.

The rate and rhythm are better palpated in the radial artery. To note the volume and character of the arterial pulse, one should examine the carotid artery (It is the nearest pulse to the aorta). Brachial pulse is felt to record blood pressure.

How to count the rate ?

Always count the beats for 15 seconds and multiply by four to get the pulse rate but it is worthwhile to remember that in a patient with arrhythmia, one must count the beats for at least one minute.

What are the variations in pulse rate ?

Definition of rate — Number of beats per minute. Normally it ranges between 60 to 100 beats per minute (average 72 beats per minute in an adult). Usually it remains 140 beats per minute at birth. SA node is the natural pacemaker of the heart (i.e., the normal cardiac rhythm is ***'sinus rhythm').***

(A) Tachycardia — Pulse rate is above 100 per minute. Normally it is found in children.

a) Sinus tachycardia — Pulse rate is above 100 per minute where the impulse is originating from the SA node. The heart rate In sinus tachycardia varies between 100-160 per minute. The common causes are, (i) Exercise, emotion, excitement, intense pain, anxiety, and in children (ii) heart failure (iii) Thyrotoxicosis (Iv) Severe anaemia (v) Pyrexia (vi) Shock (e.g, acute myocardial infarction) (vii) Myocarditis (viii) Acute haemorrhage (ix) Pregnancy (x) Hypoxia (xi) Drugs like salbutamol, nifedipine or atropine.

b) Relative tachycardia — Read the section on Abnormal temperature'.

c) Paroxysmal tachycardia — Pulse rate is above 160 beats per minute. It is divided into two types:
   1) Supraventricular (PSVT) [i.e., atrial (PAT) or nodal (PNT)).
   2) Ventricular (VT).

Common causes of paroxysmal tachycardia are rheumatic carditis, ischaemic heart disease (IHD), thyrotoxicosis, hypertensive heart disease, cardiomyopathy, WPW syndrome.

(B) Bradycardia—Pulse rate is below 60 per minute. It is commonly found in,

(i) Athletes, yoga, meditation or during deep sleep.
(ii) Myxoedema.
(iii) Obstructive jaundice.
(iv) Increased intracranial tension.
(v) Drugs like propranolal or digitalis.
(vi) Hypothermia.
(vii) 2° heart block, complete heart block (CHB)
(viii) Sick sinus syndrome (sino-atrial disease).
(ix) Vasovagal attacks.
(x) Severe hypoxia.

* Athletes, yoga and meditation develop a high vagal tone but during sleep the sympathetic activity is reduced.

N.B. : Regular athletic training and myxoedema are the commonest causes of bradycardia.

a) Sinus bradycardia—Pulse rate is below 60 per minute where the impulse is originating from the SA node. The common causes are : All the causes mentioned above in 'bradycardia' except complete heart block (in CHB, idioventricular rhythm occurs at the rate of 36 per minute).

N.B. : ***Idioventricular rhythm***—when cardiac impulse arises from the ventricle at the rate of 36 per minute, the pulse rate at ventricular rhythm will be 36 (30-40) per minute, and is known as idioventricular rhythm; ***nodal rhythm***—when the SA node fails, often the AV node originates impulse at the rate of 40-60 per minute resulting in a pulse rate of 40-60 per minute.

b) Relative bradycardia — Read the section on 'Abnormal temperature'.

* Tachycardia (Greek takhus = swift, kardia = heart)
Bradycardia (Greek bradus = slow, kardia = heart)

Bradycardia associated with convulsions :

1. Complete heart block (Stokes-Adams syndrome).

2. Increased intracranial tension due to meningoencephalitis, brain tumour, CVA.
3. Prior to development of coma in myxoedema.

Disproportionately rapid pulse in shock :

1. Acute myocardial infarction.
2. Septic shock.
3. Myocarditis.
4. Tachyarrhythmias.

What is pulse deficit (i.e., apex-pulse deficit) ?

Definition—it is the difference between the heart rate and the pulse rate. It is commonly found in atrial fibrillation and multiple ectopic beats. The method of detection of pulse deficit are :

1. First count the heart rate for one minute and then the pulse rate for next one minute (examination in two different cardiac cycles) — commonly practised method, or
2. One examiner counts the heart rare and the other examiner counts the pulse rate at the same time (using single cardiac cycle) for one minute (best method), or
3. One may put his stethoscope at the apex and simultaneously count the dropped beats in the pulse (using single cardiac cycle) for one minute.

* Pulse deficit is obtained in atrial fibrillation (> 10/min) and multiple ectopics (< 10/min).

What is an ectopic beat ?

In ectopic rhythm, the impulse arises from sites other than the SA node, and may arise from the atrial wall, AV node or ventricular wall. The ectopic beat is small, occurs prematurely and followed by a compensatory pause. The compensatory pause results in a 'missed- or 'dropped' beat in pulse.

Pulse felt at the wrist : Small pause followed by small beat, big pause followed by big beat.

Causes : Overindulgence of tea, coffee, cigarettes, alcohol; anxiety, dyspepsia; rheumatic, ischaemic, hypertensive, thyrotoxic and cardiomyopathic heart diseases; digitalis overdose.

Synonym of ectopic beat : Premature beat, extrasystoles.

* Ectopic beats occur as occasional or repeated irregularites superimposed on a regular pulse rhythm.

How can you modify ectopics (supraventricular) in a patient?

Ectopics can be abolished by vagotonic procedures, and vagolytic procedures increase the ectopics. When ectopic pace-maker is situated in the atrium (producing paroxysmal atrial tachycardia), vagotonic produces often terminate the attack. Vagotonic procedures have no effect on ventricular tachycardia.

Vagotonic procedures : Mechanical measures like *carotid sinus massage* (the patient lies flat with extended neck. Exclude occlusive carotid disease, i.e., there should not be any carotid bruit. Now put your left thumb first on the right side of the neck at the level of the upper border of thyroid cartilage and massage for 3-5 seconds at a time; next try on the left side with right thumb), self-induced gagging or vomiting, pressure over the eyeballs, Valsalva manoeuvre, coughing as well as breath holding, head lowering between the knees, stretching the arms and body; drug like digitalis.

Vagolytic procedures : Exercise; drugs like atropine and amyl nitrite.

Irregularities in the rhythm :

Rhythm is the spacing of successive beats (pulse wave) in time. Normal pulse is regular in rhythm and is known as ***sinus rhythm,*** because it is generated by the SA node. *Irregularities* are of two types :

1. **Regularly irregular** — i.e., irregularity comes at regular interval and is seen in extrasystoles, 2° heart block, sinus arrhythmia, pulsus bigeminus etc.
2. **Irregularly irregular** or completely irregular — i.e., irregularity between two pulse beats in every aspect (rate, rhythm, volume etc, i.e., totally chaotic). It is commonly seen in atrial fibrillation, multiple extrasystoles, atrial flutter with varying degrees of heart block etc.

What is sinus arrhythmia ?

Definition — It is the increase in pulse rate with inspiration and decrease in pulse rate with expiration. It is a physiological phenomenon commonly observed in children and athletes.

Mechanism — The increased amount of blood which comes in the left ventricle in expiration increases the stroke volume. This event immediately stimulates the baroreceptors (i.e., vagal stimulation) leading to slowing of the heart rate.

* Sinus arrhythmia may be absent in CCF and autonomic neuropathy.

Differentiation between multiple ectopics and atrial fibrillation (AF) :

Both the conditions present as irregularly irregular pulse. So, they have to be differentiated :

1. First count the pulse rate. If it is > 100 per minute, it is AF but if the pulse rate is < 100 per minute, it may be multiple ectopics or digitalised AF (treated case of AF).
2. The ectopic beat is a small one and occurs prematurely. So one may get the typical phenomenon of : small pause followed by small beat, big pause (compensatory pause) followed by big beat. If this typical cadence is felt, it is ectopic and not a case of atrial fibrillation (totally chaotic).
3. Now **count the pulse deficit.** If it is > 10, it is AF. If the pulse deficit is < 10. again it may be multiple ectopics or digitalised AF. To differentiate between the last two, following measures are adopted.
4. The patient is allowed to do mild exercise (if the condition permits). He will sit and touch the toes with his lingers, and will lie down again. This is done for 5-6 times successively. It is known that the heart of AF becomes more irregular after exercise. If after exercise the pulse deficit goes above 10, it is a case of digitalised AF and if the pulse deficit remains same (below 10) or diminished, the diagnosis of multiple ectopics becomes obvious.
5. Next the patient is examined for :
   a) JVP—a-wave is absent in AF; a-wave is present in multiple ectopics.
   b) Sj—Varying intensity of S_t in AF; no change in multiple ectopics.
   c) Auscultation of the apex—If MS is the aetiology of AF, presystolic component of the murmur will disappear; no change of murmur in multiple ectopics.
6. ECG—'P' waves will be replaced by 'f waves in AF; ectopics are easily diagnosed by ECG.
7. Fluoroscopy—Definite contraction of atria is absent in AF. Atria contracts normally in ectopics.

Irregular rhythm with normal heart rate :

1. Multiple extrasystoles.
2. Digitalised AF.
3. Sinus arrhythmia.

What is volume of the pulse ?

It is the amplitude of the pulse wave or the excursion felt at the wrist, and usually **reflects the width of pulse pressure** (systolic BP minus diastolic BP), which depends on two factors :

(i) Stroke volume, and

(ii) Compliance of the arteries.

The carotid, brachial or femoral arteries are more useful for assessing pulse volume and character than the radial pulse. Normal pulse pressure is 30-60 mm of Hg (i.e., normal pulse volume).

What are the changes in the pulse volume ?

(A) **High volume pulse (i.e., pulse pressure > 60 mm of Hg) :**

1. Hyperkinetic circulatory states like.
   (i) After exercise.
   (ii) Severe anaemia.
   (iii) Pyrexia.
   (iv) Pregnancy.
   (v) Aortic incompetence
   (vi) Thyrotoxicosis.
   (vii) Arteriovenous communications like patent ductus arteriosus (PDA), Paget's disease etc.
   (viii) Chronic cor pulmonale.
   (ix) Hepato-cellular failure.
   (x) Beri-beri.
2. Atherosclerosis (the arteries are rigid, i.e., less compliant; so there is wide pulse pressure as the systolic BP is high).
3. Complete heart block or bradycardia due to any cause.

* In aortic incompetence : systolic BP T and diastolic BP 4-; atherosclerosis : systolic BP T and diastolic BP normal; hyperkinetic circulation : systolic BP t and diastolic BP near normal.

(B) Low volume pulse (pulsus parvus; pulse pressure < 30 mm of Hg) :

1. Shock due to any cause e.g., acute myocardial infarction, massive haemorrhage, hypovolaemia or septicaemic shock (as a result of poor vascular tone).
2. Severe aortic stenosis.
3. Tight mitral stenosis.
4. Pericardial effusion.
5. Constrictive pericarditis.
6. Congestive cardiac failure.

What is a thready pulse ?

This a low volume pulse with rapid pulse rate. This type of pulse is seen in peripheral circulatory failure, e.g., cardiogenic shock, haemorrhage or dehydration.

* 'jerky pulse' is felt in idiopathic hypertrophic subaortic stenosis (IHSS).

How to assess the condition of the arterial wall ?

Normally the arterial wall is impalpable and *may be palpable in old age* due to arteriosclerosis. The artery becomes tortuous, thickened and feels like a cord in arteriosclerosis which is known as "Monckeberg's medial sclerosis" (calcification of the medial coat of large arteries). This is an age-related change; remember, atherosclerosis occurs in intima and often associated with occlusive arterial disease. In the presence of thickened and tortuous artery, one may observe locomotor brachialis. Condition of the arterial wall is assessed by :

a) Compress the brachial artery above the elbow by ball of the left thumb (i.e., making a bloodless column) and now roll the radial artery over radius by index and middle fingers of the right hand, Or

b) First place the index and middle fingers of both the left and right hand over the radial artery side by side and exsanguinate the artery by moving the two middle fingers in opposite direction. The radial artery is now rolled over the radius by two index fingers.

Causes of absent radial pulse :

1. Anatomical abnormality.
2. Severe atherosclerosis.
3. Takayasu's disease.
4. Embolism in the radial artery'.
5. [Death].

* Raynaud's disease doesn't affect the peripheral pulse because it is a disease of arterioles.

Inequality between two radial pulses (radio-radial delay) :

Simultaneously palpate both the radial arteries by both of your hands, using your left hand for patient's right hand and vice-versa for the other hand. Causes of inequality or radio-radial delay are :

1. Normal anatomical variations.
2. Thoracic inlet syndrome e.g., cervical rib.
3. Aneurysm of the arch of aorta.
4. Pre-subclavian coarctation.
5. Supravalvular aortic stenosis (congenital).
6. Pulseless disease (Takayasu's disease).
7. Peripheral embolism or atheromatous plaque.
8. Atherosclerosis of aorta.
9. Pressure over axillary artery by lymph nodes.
10. Iatrogenic—Blalock-Taussig shunt operation in Tetratogy of Fallot.

Causes of radio-femoral delay :

For detection of radio-femoral delay, standing on the right side of the patient, one should palpate the radial artery with the left hand and femoral artery with the right hand simultaneously. **Normally there is no radio-femoral delay** (in health, radial and femoral pulsations are felt equally and synchronously) but it should be remembered that the pulsation of arteria dorsalis pedis comes 0.02 to 0.03 seconds later than the radial artery. In radio-femoral delay, the femoral pulse is of small volume and occurs after the radial pulse. Causes of radio-femoral delay are:

1. Coarctation of aorta (important bedside diagnostic clue in a young hypertensive).
2. Atherosclerosis of aorta.

3. Thrombosis or embolism of aorta.
4. Aortoarteritis.

Basic bedside features of coarctation of aorta :

1. A male patient with headache, claudication, palpitation, anginal pain or cold extremities.
2. The upper extremity and thorax may be more developed in comparison to lower extremities.
3. Palpation of pulses may reveal **radio-femoral dealy** (symmetrical reduction and delay of femoral pulses in comparison to radial pulses). All the pulses like radial, carotid, brachial, femoral, popliteal and *arteria dorsalis pedis should be examined in details.*
4. Prominent suprasternal and carotid pulsation.
5. Collateral pulsation are present (seen as well as felt) in axilla, trunk and infrascapular area (Suzman's sign). Suzman's sign (dilated, tortuous and pulsatile arteries) is best elicited when the patient stands and bends forward with arms hanging down at sides.
6. **Systemic hypertension** (upper extremity high BP with low or normal BP in lower extremity).
7. Bruit over the collaterals. 'Cork-screw' appearance of retinal arteries (fundoscopy).
8. Left ventricular type of cardiac enlargement (heaving apical impulse); a systolic murmur may be heard over the anterior chest and back. Continuous murmur may be present over collaterals.
9. Clinical associations : Bicuspid aortic ralve, PDA. VSD, berry aneurysm, polycystic kidneys, Turner's syndrome.
10. [Rib notching from 3rd to 8th rib in chest X-ray — known as Dock's sign].
11. [Barium swallow of oesophagns shows double indentations due to pre- and post-coarctation dilatation—'3 sign' or 'reverse E sign'.]

* Post-subclavian type is the commonest variety of coarctaion of aorta.

Examination of other peripheral pulses :

1. Ulnar artery : At the wrist on medial side where it crosses the distal end of radius.
2. Brachial artery : Palpated by the thumb (left thumb for left arm and vice-versa for right arm) at or just above the elbow (just medial to the tendon of biceps muscle).
3. Subclavian artery : Ask the patient to shrug his shoulders. The artery is felt from behind by pressing the index finger downwards, from above the middle of the clavicle.
4. Carotid artery : Palpated with the thumb (left thumb for right carotid and vice-versa), medial to sternomastoid and at or just below the level of thyroid cartilage. Pressure over the carotid sinus may sometime induce syncope and this is why carotid artery should always be palpated one by one with the patient lying in bed. Dancing carotids in AI, slow upstroke in AS and jerky carotids are characteristic of HOCM.
5. Femoral artery : Lies midway between anterior superior iliac spine and pubic tubercle, at the level of the groin or inguinal ligament.
6. Popliteal artery : The patient lies supine with semiflexed knee. The fingertips of both hands are pressed in the middle of the popliteal fossa while both thumbs rest on tibial tuberosity. It may be palpated in prone position with knee partly flexed.
7. Posterior tibial artery : Lies approximately in the midway between the medial malleolus and heel; better palpated after inversion of the foot as it causes relaxation of the flexor retinaculum.
8. Arteria dorsalis pedis : Palpated lateral to the extensor hallucis longus tendon on the proximal part of dorsum of the foot; it may be absent in about 10% people. Before palpation, make the extensor hallucis longus tendon prominent by asking the patient to extend his great toe against resistance.

Describe the normal arterial pulse (adult) :

The rate is 72 per minute. The beats are regular in rhythm, and normal as well as equal in volume. There is no inequality between the two upper limbs, and the upper and the lower limbs. The condition of the arterial wall is normal (neither thickened nor tortuous) and the pulses are of normal **character (catacrotic pulse).** All the peripheral pulses are symmetrically palpable.

* Character of pulse is described in the section on 'Water-hammer pulse'.

** Throbbing carotids in aortic incompetence is known as 'Corrigan's pulse'.

*** Examination of the pulse is one of the most ancient and time-honoured practice of the medical profession. Try to comment on pulse deficit while describing the pulse of atrial fibrillation.

**** Pulse becomes faster (rapid) after a meal, after smoking, during menstruation and in the evening.

Case 40

WATER-HAMMER PULSE

Define 'character' of pulse :

The volume, waveform and some special features (e.g., collapsing nature) altogether give rise to character of the pulse, which is often helpful to clinical diagnosis of specific diseases or disorders.

Different 'characters' of pulse :

1. Anacrotic pulse.
2. Dicrotic pulse.
3. Water-hammer pulse.
4. Pulsus bisferiens.
5. Pulsus alternans.
6. Pulsus bigeminus.
7. Pulsus paradoxus.
8. Thready pulse, jerky pulse, bounding pulse.

What is catacrotic pulse ?

The normal arterial pulse is known as catacrotic pulse which is described in the section on 'Pulse'.

It has following waves :

- Percussion wave (P, the rapid upstroke in pulse, and is produced by ejected blood in arterial system).
- Tidal wave (T, and is generated along the arterial wall).
- Dicrotic notch and dicrotic wave (in downstroke of pulse; due to elastic recoil of the vessel).

The wavy patttern is not felt in health since it is obliterated by normal vascular tone.

What is pulse pressure and mean pressure ?

Pulse pressure is the difference between systolic and diastolic BP (roughly reflects the volume of the pulse). Mean pressure is approximately the arithmatic mean of diastolic and systolic pressure, and is calculated by diastolic pressure plus 1/3rd of pulse pressure.

What is a bounding pulse ?

It is commonly seen in hyperkinetic 'circulatory states where the pulse volume is high (due to high pulse pressure) with increased blood flow.

What is water-hammer pulse (or high volume collapsing pulse) ?

This is characterised by :

1. High volume pulse,
2. Sharp rise,
3. Ill-sustained, and
4. Sharp fall.

A high volume pulse gives the water-hammer character when the pulse pressure is at least above 60 mm of Hg. A **collapsing pulse** usually occurs where there is rapid run-off of blood from the aorta or the arterial system. The collapsing nature is often reliably detected by palpation of the carotid artery.

* All collapsing pulses are of high volume but all high volume pulses are not necessarily collapsing.

Demonstration of water-hammer pulse :

Palpate the wrist in such a way that your webs fall on the radial artery and rest of the palm lies over the ulnar artery. Examine the volume of the pulse (summation of both radial and ulnar artery) for few seconds. Now elevate the whole upper limb suddenly above the level of the heart (may give a support in the elbow to prevent its flexion) and try to recognise any changes in the volume of the pulse. In water-hammer pulse, the volume increases from the basal level (i.e., volume at the beginning of the examination) after elevation of the upper limb, and the pulse strikes the palpating palm with a rapid and forceful jerk. Abrupt downstroke of the pulse produces the collapsing feel.

For examination of the pulse in this way, one should stand within the 'angle' formed between the patient's body and the said upper extremity. The right-sided pulse should be examined by the right hand while standing on the right side, and vice-versa for the left. Observe the increase in pulse volume, sharp rise and the sharp fall.

Why the name 'water-hammer' ?

It is termed after a 19th century Victorian toy called 'water-hammer'. This is a peculiar toy where a sealed glass cylinder is half filled with water and half with vacuum (two ends being closed). If the toy is suddenly placed upside down, the column of water strikes the other end of the cylinder with a blowing

sound. This is why the term water-hammer has been coined in a high volume collapsing pulse where the pulse strikes the fingers like the thud of a hammer.

Causes of water-hammer pulse :

The causes are mentioned in 'high volume pulse' in the section on 'Pulse'. One should remember **aortic incompetence** (AI) as the first cause of water-hammer pulse and then the others.

Why this type of pulse is seen in AI ?

(A) In AI, the left ventricular stroke volume is high (so the systolic pressure is high) and this is responsible for 'sharp rise' or rapid upstroke in the pulse.

(B) The collapsing character is due to,

1. Diastolic leak back into the left ventricle from aorta.
2. Rapid run-off to the periphery as a result of *low systemic vascular resistance* (the increased cardiac output stimulates the baroreceptors in the aortic arch and the result is reflex vasodilatation of the peripheral vessels into which the blood flows rapidly).

N.B. : 1 and 2 of (B) are responsible for low diastolic pressure and thus in AI, there is a high pulse pressure. These factors are responsible for 'sharp fall' too.

Why do you elevate the arm ?

Mechanisms of action :

1. Aided by the gravity, there is fall of blood column (resulting in vasodilatation) and thus, it helps to reduce the diastolic pressure more. So the pulse pressure widens, or
2. It may be so that the artery palpated becomes more in the line of aorta after elevation of the arm, and thus allows direct systolic ejection and diastolic backward flow.

Other parts to be examined in a patient with water-hammer pulse :

1. Count the rate (bradycardia in complete heart block; tachycardia in thyrotoxicosis).
2. Examine the condition of the arterial wall (for atherosclerosis).
3. See the facies for exophthalmos or examine for tremor (thyrotoxicosis).
4. Record the surface temperature (pyrexia).
5. Examine for anaemia (severe anaemia).
6. Examine for jaundice (cirrhosis with hepato-cellular failure).
7. Examine the chest for emphysema (chronic cor pulmonale).
8. One should not forget to auscultate the aortic and neoaortic area for an early diastolic murmur (AI).

* Lastly, one should examine the patient for capillary pulsation, digital pulsation, carotid dance, pistol shot sound which are usually associated features of water-hammer pulse.

Anacrotic pulse :

It is a low volume pulse with an upstroke felt in the ascending limb. Anacrotic pulse is found in severe valvular aortic stenosis (AS). Typically the pulse in aortic stenosis is known as pulsus **'parvus et tardus'** (slow rising low volume pulse)— 'parvus' means low volume and 'tardus' means slow or late. One may feel carotid shudder in the presence of anacrotic pulse. Pulse of AS is also known as 'plateau pulse'.

Dicrotic pulse :

When an upstroke is felt in the descending limb of the pulse wave, it is known as dicrotic pulse. The dicrotic wave is felt due to hypotonia of the vessel wall. This is also a *low volume* pulse due to very low stroke volume with decreased peripheral resistance, and is found in :

a) Second week of typhoid fever (possibly related to circulating vasculotoxins).
b) Endotoxic shock.
c) Hypovolaemic shock.
d) Diffuse myocardial disease.

What is pulsus bisferiens ?

1. *It is a high volume double-beating pulse* (single pulse wave with two peaks in systole).
2. Method of palpation : best palpated in big arteries like brachial and carotid arteries. Try to press and occulde the brachial artery. Now, slowly release the pressure and feel the double-beating nature of the pulse.
3. The first lift is due to 'percussion wave' (P) and the second lift is due to 'tidal wave' (T). It is said that if P>T, then AI>AS; and ifT>P, usually AS>AI. Thus, we can determine the dominant lesion.

4. It is commonly found in,
   a) Combined AS and AI (commonest),
   b) Isolated AI, and
   c) Hypertrophic obstructive cardiomyopathy (HOCM).
5. Pathophysiology—
   a) Due to 'ventury effect' within the left ventricle.
   b) Another view explains that the 'dip' in the pulse is felt due to energy dissipation in the production of a loud systolic murmur of AS (Bernoulli effect).
   c) The first component is due to large volume of blood ejected in systole and the second component is due to elastic recoil in the arteries (best reasoning).

* Three different causes of **double-beating pulse** are (i) bisferiens, (ii) anacrotic , and (iii) dicrotic pulse.

Pulsus alternans :

This is rare. When the alternate pulse waves are weak i.e., of low volume *(the rhythm remains regular in contrast to ectopics)* in a patient with acute left ventricular failure, pulsus alternans is said to be present. **It is better demonstrated in radial arteries**. In a patient with LVF (severe myocardial failure), some ventricular muscle fibres are healthy and some are degenerated and thus, produces normal and weak beat respectively (defective electromechanical coupling). One should search for gallop rhythm and basal crepitations when pulsus alternans is felt. It is due to prolonged recovery time of damaged myocardium and indicates a poor prognosis.

The compensatory pause of ectopics are absent here.

Pulsus bigeminus :

Clinically, two beats and a pause thereafter recur repeatedly in a regular fashion (bigeminy means twins). The second beat is an ectopic and thus, there is a pause after it. It is commonly found in digitalis toxicity and 3 : 2 heart block. In pulsus trigeminus, three beats and a pause recur in a regular fashion.

Pulsus paradoxus :

Here, the pulse volume decreases with inspiration and increases with expiration (not truely the opposite of sinus arrhythmia which denotes the changes in pulse rate only). The **'paradox'** is that the heart sounds may still be audible on auscultation over the apex at a time when no pulse (pulse wave may totally disappear in inspiration) is palpable at the radial artery. It is commonly seen in,

1. Acute severe asthma.
2. Cardiac tamponade (rapidly developing pericardial effusion).
3. Chronic constrictive pericarditis.
4. Chronic obstructive pulmonary disease (COPD).
5. Sometimes, SVC syndrome.
6. Restrictive cardiomyopathy.

The probable mechanisms are :

1. Intrapericardial pressure rises more during inspiration (as a result of traction on the pericardium) which in turn diminishes cardiac output by causing obstruction in venous return (in cardiac tamponade). Increased intrapericardial pressure in cardiac tamponade also impedes diastolic filling.
2. Anti-Bernheim effect—During inspiration, more blood comes in the right ventricle which pushes the interventricular septum to the left side and thereby diminishing the left ventricular cavity, and resulting in low cardiac output. During acute severe asthma and other causes mentioned above, the degree of negative pressure generated during inspiration is exaggerated. So, more blood is sucked in the right heart, resulting in pulsus paradoxus.

* Pulsus paradoxus is a misnomer and is actually an exaggeration of normal physiological phenomenon. In health, there is a fall in systolic BP in inspiration which is < 10 mm of Hg (so, not detectable normally) but in pulsus paradoxus, there is an exaggerated inspiratory fall in systolic BP > 10 mm of Hg.

Pulses confirmed by sphygmomanometer :

1. Pulsus paradoxus—Systolic BP is more in expiration than in inspiration by > 10 mm of Hg.
2. Water-hammer pulse—Pulse pressure is usually greater than at least 60 mm of Hg.
3. Pulsus alternans—When the strong beats are heard during measurement of systolic BP (initial part of measurement), the pulse rate remains half of the actual rate (as weak beats do not reach

the radial artery). With gradual lowering of the mercury column, the weak beats are also heard and thus, the pulse rate doubles i.e., returns to the actual pulse rate (Gallavardin sign).

Other uses of sphygmomanometer :

1. To measure the blood pressure (principal use of the instrument).
2. Hess' capillary fragility test—See the section on 'Haemorrhagic spots'.
3. Latent tetany—When the pressure is raised above the systolic BP for 3 minutes, typical carpal spasm appears (main d' accoucheur) and is known as Trousseau s sign.
4. To assess the respiratory reserve—Blow the mercury column (by placing the mouth to the inlet tube) upto 40-50 **mm** of Hg and try **to** hold it at this level.
5. Diagnosis from recording of BP of lower limb : Lower limb systolic BP > upper limb systolic B and if the difference is above 20 mm of Hg, it is known as Hill's sign, which is diagnostic of AI. Lower limb systolic BP < upper limb systolic BP happens to occur in coarctation of aorta.
6. To draw venous blood.
7. Previously used as a rotating tourniquet in a patient of LVF (for reduction oi venous return) Keep the cuff inflated in all the limbs at 80 mm of Hg (i.e., at diastolic pressure) for 15 minutes.
8. To draw blood during blood donation.

Describe the pulse in complete heart block (CHB) :

1. Rate—36 to 40 per minute (bradycardia).
2. Rhythm—Regular.
3. Volume—High.
4. Condition of the arterial wall—May be thickened (as the patients are of advanced age).
5. Neither radio-radial nor any radio-femoral delay.
6. Character—May have water-hammer character.
7. All the peripheral pulses are palpable.
8. Special character—It is a 'fixed' pulse i.e., no alteration in pulse rate after exercise, pyrexia or injection of atropine.

In CHB carotid artery shows carotid dance at the rate of 36-40 per minute (ventricular rate), and internaHugular veins reflect atrial pulsation at the rate of 72 per minute with cannon waves appeanng from hme to time. There is beat to beat variation in the BP. BP is of high systolic and normal diastol c pressure. There is varying intensity of S, (cannon sound); rarely a mid-diastolic murmur may be aud (Rytand's murmur).

Case 41

ABNORMAL TEMPERATURE

Normal body temperature and its variations :

Fever is only a symptom of disease which alerts the physician to the underlying abnormality.

1. **Normal-** 98°F-99°F (with a diurnal variation of 1 -5°F; the temperature is lowest in the morning and is highest in between 4-6 PM).
2. **Subnormal-** below 98°F.
3. **Pyrexia or febrile-** above 99°F.
4. **Hypothermia-** below 95°F.
5. Hyperpyrexia-above 106.7°F.

* Though varies from person to person, recent studies reveal that oral AM temperature of > 98.9°F or a oral PM temperature of > 99.9°F would define a fever or pyrexia.

Methods of taking body temperature :

1. **Oral-** The thermometer is placed under the tongue and the patient breathes through the nose with lips firmly closed. It reflects the body-core temperature.
2. **Axillary** or groin- Placed in the armpit or folded groin; generally 0-5-1 °F lower than oral temperature. Axilla, groin and natal cleft should preferably be avoided in adults.
3. **Rectal-** Most reliable as well as accurate, and it is 0-5-1 °F higher than the oral temperature.

N.B. : Thermometer is kept at least for 2 minutes in all the sites and the rectal > oral > axillary temperature

* Recently, a tympanic membrane thermometer (i.e.. electronic thermometer used in the ear) is used for fast and accurate reading of core temperature.

Which site will you prefer in infants ?

The axilla, or groin with thigh flexed over the abdomen (also convenient in an unconscious patient).

If not mentioned, which site is preferred for recording of temperature ?

Oral; if the oral temperature crosses 99°F, the patient is febrile. In axilla, when the temperature is above 98-6°F or 37°C (the arrow is marked here in the clinical thermometer), it is said that the patient is running temperature. Oral temperature does not change with sweating or vasoconstriction (axillary temperature may change). Majority of common people are well conversant with Fahrenheit scale.

Contraindications of taking oral temperature :

1. Infants and children.
2. Mentally dull persons, e.g., Down's syndrome.
3. During convulsions or H/O recurrent fits.
4. After taking hot tea, hot coffee or chewing tobacco; smoking.
5. Inflammation within the oral cavity, e.g., stomatitis, ulcer in the mouth, impacted wisdom teeth.
6. During severe dyspnoea.
7. Unconscious or restless patients.
8. Trismus (tetanus, tetany).
9. Paralysis of the tongue; Bell's palsy.
10. In mouth breathers.

Causes of hypothermia :

1. Myxoedema coma.
2. Prolonged exposure to cold (in street beggars, accidental in elderly, or in mountaineering).
3. Peripheral circulatory failure due to any cause.
4. Enteric fever if associated with haemorrhage or perforation : commonly occurs in the 3rd week.
5. Hypoglycaemia.
6. Panhypopituitarism; adrenal insufficiency.
7. Artificial hypothermia induced in open heart surgery.
8. Near-drowning.
9. Alcohol intoxication; sedatives and hypnotics overdose.
10. Autonomic dysfunction.

* Always confirm hypothermia with rectal temperature.

Causes of hyperpyrexia :

1. Malaria.
2. Septicaemia.
3. Encephalitis.
4. Pontine haemorrhage.
5. Lobar pneumonia.
6. Heat stroke.
7. Malignant hyperthermia (halothane-induced).

g Thyroid storm.

9. Neuroleptic malignant syndrome (haloperidol-induced).
10. Dhatura poisoning.
11. Rabies.
12. Serotonin syndrome (SSRI or MAO inhibitors-induced).

Causes of 'aseptic fever' :

1. Heat stroke.
2. Lymphoma, leukaemias or disseminated malignancy.
3. Collagen vascular disease e.g., SLE.
4. Pontine haemorrhage.
5. Drug fever e.g., rifampicin or sulphonamides.

6. Thyroid storm.
7. Acute myocardial infarction,
8. Gout.
9. Porphyria.
10. Crush injury.
11. Radiation sickness,
12. Over-atropinisation.

Fever with disturbed consciousness :

1. Encephalitis.
2. Cerebral malaria.
3. Meningitis.
4. Pyrexia complicated by metabolic disorders e.g., hypoglycaemia.
5. Typhoid state.
6. Brain abscess.
7. CVA with fever (e.g., chest infection)
8. Rarely in dhatura poisoning.

What is 'hectic' temperature ?

There is a big swing in the temperature which rises with chill and rigor, persists for few hours and suddenly falls with profuse sweating. The common causes are :

1. Pent-up pus anywhere in the body (lung abscess, liver abscess, empyema thoracis, empyema of gall bladder, subdiaphragmatic abscess).
2. Septicaemia or pyaemia.
3. Rarely in advanced tuberculosis.

Causes of fever with chill and rigor :

1. Malaria.
2. Urinary tract infection.
3. Pent-up pus anywhere in the body (e.g., lung abscess).
4. Septicaemia or pyaemia.
5. Cholangitis.
6. Subacute bacterial endocarditis.
7. Thrombophlebitis.
8. Acute pyelitis or acute pyelonephritis.
9. Acute lobar pneumonia (e.g., pneumococcal).
10. Agranulocytosis.
11. Pyrogen reaction after fluid infusion or blood transfusion.
12. Filariasis.

Pathogenesis of chill and rigor :

It should be looked upon in the setting of 'thermostat'. When the temperature is rising to a higher level, heat is being conserved, the cutaneous vessels are constricted (so the patient feels cold) and the patient may even shiver violently. The shivering is known as 'rigor .

When the higher temperature is reached, heat loss starts and the cutaneous vessels dilate for dissipation of heat. The patient feels hot and sweating starts.

Normal temperature is maintained in health by regulating a balance between heat gain and heat loss, governed by the hypothalamus.

What is meant by 'fall by crisis or lysis' ?

Fall of temperature is also known as defervescence. They are :

I **Crisis**—When the raised temperature falls to normal or subnormal level very quickly within 6-12 hours and is associated with severe sweating, it is known as fall by crisis. This is usually seen in,

1. Acute lobar pneumonia.
2. Enteric fever complicated by intestinal haemorrhage or perforation.
3. Adrenal crisis (seen in meningococcal meningitis).
4. Septicaemic shock.
5. Dengue.

II. **Lysis**—When the temperature falls gradually in steps over several days, it is known as fall by lysis. It is usually seen in,

1. Uncomplicated enteric fever.
2. Rheumatic fever.
3. Acute bronchopneumonia.

N.B. : Most of the raised temperature falls by lysis. Use of antipyretics may precipitate fall by crisis.

What do you mean by 'periodic fever' ?

It is the periodic attacks of pyrexia alternating with a period of apyrexia, and is commonly seen in :

1. Hodgkin's disease (Pel-Ebstein fever).
2. Brucellosis.
3. Relapsing fever.
4. Malaria.
5. Rat bite fever.
6. Dengue.

Diagnostic clues in fever :

- Toxic look—Typhoid, septicaemia, miliary tuberculosis, typhus.
- Marked perspiration—Septicaemia, rheumatic fever, amoebic liver abscess, brucellosis.
- Severe myalgia—Influenza, dengne, chikungunya, leptospirosis.
- Purpura—Acute leukaemias, septicaemia.
- Convulsions—Febrile (in children), meningitis, cerebral abscess, tuberculoma.
- Lymphadenopathy Tuberculosis, lymphoma, leukaemia, secondary syphilis, SLE, AIDS.

What is pyrexia of unknown origin (PUO) ?

It is also known as fever of unknown origin (FUO).

Definition (by Petersdorf and Beeson. 1961) :

1. Fever higher than 101°F on several occasions.
2. A duration of fever for more than 3 weeks.
3. Failure to reach a provisional diagnosis after one week of inpatient investigations.

Diseases which may initially present as PUO :

1. Lymphomas, leukaemias, multiple myeloma and carcinoma (specially of lung, liver and kidney).
2. Collagen vascular diseases, e.g., SLE, rheumatoid arthritis. Still's disease, polyarteritis nodosa.
3. Tuberculosis, SBE, subphrenic abscess, liver abscess, brucellosis, fungal infection. AIDS.
4. Factitious fever, drug fever, habitual hyperthermia, use of immunosuppressive drugs.

Recently PUO has been classified into 4 different types (Durack and Street, 1991) •

1. Classic PUO (as previous one except the time frame which is 3 outpatient visits or 3 days in hospital without determining the cause, or one week of intelligent and invasive ambulatory investigations)—e.g., hidden infection, obscure malignancy, collagen vascular diseases.
2. Nosocomial PUO (hospital-acquired)—e.g., septic thrombophlebitis.
3. Neutropenic PUO (when neutrophil count is < 500/mnr')-e.g., perianal infection, candidiasis.
4. HIV-associated PUO (e.g., tuberculosis, NHL, drug fever).

N.B. : Diagnosis of PUO requires 'repeated' physical examination, intelligent interviewing the patient and specific investigations.

* Fever persisting for > 2 weeks in loosely termed as 'prolonged fever'.

When the rectal temperature is preferred ?

1. Possible hypothermia.
2. In collapsed, comatosed or elderly patients.
3. Invalid patients.
4. Cholera patients (surface temperature is subnormal but rectal temperature is raised), and
5. In algid malaria.

N.B. : The rectal temperature is recorded with a special 'low-reading' thermometer. It is stouter than the clinical thermometer, with a rounded bulb (to reduce the risk of injury) and is graduated upto 90°F.

Relative bradycardia and relative tachycardia :

It is known that with per degree (°F) rise of temperature in an adult, the pulse rate is increased by 10 beats/minute. In children, the rise may be upto 12-15 beats/minute.

(A) **Relative bradycardia** In this condition, the increase in pulse rate is less than 10 beats/ minute with per degree (°F) rise of temperature. For example, the pulse rate in relative bradycardia will be about 80/minute, when the temperature is increased by 2°F (actually it should be 92/minute) It is seen in :

(i) Any viral fever (e.g., in yellow fever - known as Faget's sign; dengue).
(ii) First week of enteric fever.
(iii) Sometimes in pyogenic meningitis.
(iv) Brucellosis, psittacosis, Weil's disease.

(B) **Relative tachycardia—** Here, the increase in pulse rate is more than 10 beats/minute with per degree (°F) rise of temperature. For example, the pulse rate will be about 120/minute, when the temperature is increased by 3°F (actually it should be 102/minute). It is seen in :

(i) Actute rheumatic carditis.

(ii) Tuberculosis.
(iii) Diphtheritic myocarditis.
(iv) Polyarteritis nodosa.

Types of fever :

There are three classical types of fever :

I. **Intermittent-** Fever is present only for several hours and **always touches the baseline** sometime during the day. It has three subdivisions :
   (i) Quotidian-The paroxysm of fever occurs daily (i.e., daily rise and daily fall). Examples are,
      a) Double infection of P. vivax.
      b) Pent-up pus anywhere in the body.
      c) Tuberculosis.
      d) Urinary tract infection.
      e) Septicaemia.
   (ii) Tertian- The paroxysm occurs on alternate days, which is found in,
      a) Benign tertian malaria (commonly by P. vivax and rarely by P. ovale).
      b) Malignant tertian malaria (P. falciparum).
   (iii) Quartan- When two days intervene between consecutive paroxysmal atacks, it is quartan pyrexia and is found in quartan malaria (P. malariae) which is rare in India.

II. **Continued-** Fever does not fluctuate more than 1°C (1 -5°F) during the twenty four hours period and **never touches the baseline.** The examples are,
   a) Lobar pneumonia.
   b) Second week of enteric fever.
   c) Miliary tuberculosis.
   d) Meningococcal meningitis.
   e) Rheumatic fever.

III. **Remittent-** Daily fluctuation of fever is more than 2°C (3°F) during the twenty four hours period and it **never touches the baseline.** I he common examples are,
   a) Amoebic liver abscess.
   b) Sometimes in urinary tract infection.
   c) Third week of enteric fever.
   d) Acute bronchopneumonia.
   e) Acute tonsillitis.
   fj Bacteraemia, septicaemia, pyaemia.

What is double quotidian fever (camel hump fever) ?

It is the double fever spike in a single day and is seen in :

1. Kala-azar (classical example).
2. Gonococcal perihepatitis or endocarditis.
3. Sometimes in acute bacterial endocarditis.

Appearance of rash in a febrile patient :

Remember the mnemonics : 'very sick person must take double tea' for appearance of rash in exanthematous fever.

1st day — Varicella, i.e., chickenpox (mainly in trunk; all forms seen at a time; no umbilication o vesicle).
2nd day — Scarlet fever (over chest, neck, scapula; mainly macular).
3rd day — Pox (smallpox); not seen now-a-days (peripheral distribution; rashes come in a sequence; umbilication of vescicle).
4th day — Measles (maculo-papular; over forehead, hairline near ears, face and trunk).
5th day — Typhus (macular; over shoulders, chest, extremities, palms and soles).
6th day — Dengue (morbilliform; over dorsum of hands and feet, trunk).
7th day — Typhoid or enteric fever (rose spots over abdomen, flanks and back; pale-pink; fades on pressure).

* Never forget 'drug rash' which may appear any time or any day during fever.

Features of enteric fever in its first week :

1. Step-ladder pattern of pyrexia.
2. Frontal headache.
3. Constipation (diarrhoea, vomiting and ***pafh*** abdomen may be seen in children).
4. Anorexia, nausea, cough and epistaxis.
5. Flushed face with toxic look.
6. Angry looking tongue—Central coating with red tip and margins.
7. Caecal gurgling (due to presence of fluid faeces and air).
8. Relative bradycardia and rarely dicrotic pulse.
9. Rose spots appearing on the 7th day (usually appears on 7th-10th day).
10. There may be just palpable, soft and tender spleen at the end of first week.

What is typhoid state ?

Usually the untreated enteric fever patient enters into this toxaemic stage at the onset of 3rd week of illness and is manifested by some neurological (encephalitis-like) features like :

a) Semiconsciousness or unconsciousness.
b) Low muttering delirium.
c) Coma vigil — Patient lies with half-open eyes but ignorant of his surroundings (staring stupor).
d) Subsultus tendinum — Involuntary movements of fingers and wrists due to muscular twitching.
e) Carphology — Agitated plucking of the bed sheets, and
f) Convulsions rarely.

What is pulse-respiration ratio ?

It is seen that with per degree (°F) rise of temperature, there is an increase in respiratory rate by 2 to 3/minute. The pulse-respiration ratio goes like this :

a) Normal pulse : respiration = 4:1 (72 : 18)
b) Increased pulse : respiration e.g., 12 : 1 (72 : 6) is seen in narcotic poisoning.
c) Decreased pulse : respiration e.g., 2 : 1 (1 1 2 : 56) is seen in acute lobar pneumonia.

Herpes labialis (fever blisters' or 'cold sore') with pyrexia :

These are painful and tender vesicles on the outer surface of lips, and is commonly observed in :

1. Acute lobar pneumonia (often gives clue to the side affected and stages of pneumonia).
2. Influenza.
3. Malaria.
4. Meningococcal meningitis.
5. Weil's disease.
6. Mycoplasma pneumoniae infection.
7. AIDS.
8. Physiological : sunlight, menstruation.

N.B. : Herpes labialis is due to herpes simplex virus, type 1 infection.

Fever with patch or membrane seen in the throat :

1. Acute follicular tonsillitis.
2. Faucal diphtheria.
3. Infectious mononucleosis.
4. Candidiasis.
5- Agranulocytosis.
6- Vincent s angina.
7. Acute lymphoblastic leukaemia.

What ***are the 'benefits' of fever*** ?

There is release of endogenous pyrogen with rise of temperature and this leads to activation of T-lymphocytes and thus, it enhances the host defence mechanism. Fever is sometimes beneficial in,

1. Neurosyphilis.
2. Chronic arthritis (rheumatoid arthritis).
3. Widespread carcinomatosis.
4. Uveitis.

Physiologic events on body temperature :

(A) Diminished : on rising in the morning (lowest), old age.
(B) Increased : exercise, ovulation and smoking.

Agents causing 'drug fever' :

1. **Sulphonamides.**
2. **Iodides, bromides.**
3. **acils.**
4. Barbiturates.
5. **Penicillin.**
6. **Salicylates.**
7. **Rifampicin ('flu syndrome').**
8. **g Phenolpthalein (used in laxatives).**
9. Quinldine'
10. **Phenytoin.**

The underlying mechanism is hypersensitivity and 50% patients have eosinophilia (remember the usual response in fever is eosinopenia). uemem$_D$er. me

What is factitious fever ?

rin °CThl°nallf- patients Purposefully show false elevations of temperature which are often self-in-fhem ***J*** k f 3re usually youn S women- often attached to health professionals. They may infect themselves with bacteria, ingest thyroxine or falsely register higher temperature (after immersL the thermometer in hot water). The diagnosis is done by,

1. Dissociation between pulse and temperature.
2. Excessively high temperature (106°F).
3. Absence of chills, sweats, tachycardia, tachypnoea.
4. Absence of normal diurnal variation in temperature.

What is febrile convulsions ?

Young children often develop seizures with febrile illness and these are short, generalised tonic-clonic convulsions. The characteristics are :

1. Affects 2-5% of the population of young children.
2. *Age range is from 6 months to 5 years.*
3. Often there is a positive family history.
4. Convulsions are not related to the degree of elevation of temperature as they may occur even with moderate fever.
5. Seizures last for less than 5 minutes and is generalised.
6. There is no recurrence in majority.
7. It is not associated with interictal EEG abnormalities or any neurodeficit.

Management is done by tepid sponge bathing, antipyretics and inj. diazepam (0.2-0.5 me/ke ner dose slow push I.V). Predictive factors for recurrence are : young age of onset, low fever, family H/O lebnle convulsions and short duration of fever before convulsions.

Epilepsy may develop in less than 3% of all children with febrile convulsions. Predictive factors for future development of epilepsy are : partial onset, prolonged seizure (>10 min), more than one seizure in ***2***,4 hours and family H/O epilepsy.

why there is a kink in the clinical thermometer ?

It prevents the return of the mercury column when the thermometer is taken out of the body.

Why the thermometer is triangular in cross-section ?

It magnifies the mercury-line into a wider strip to help in easy reading.

N.B.: One should always try to record oral temperature in the long and short cases.

Case 42

OEDEMA

What is oedema ?

Accumulation of excessive amount of tissue fluid in the subcutaneous tissue (or serous sacs) due to increase in extravascular (interstitial) component of the extracellular fluid volume resulting in swelling of tissue. A weight gain of several kilograms commonly precedes overt manifestation of oedema.

N B. : Total body water (60% of body weight in kg) is distributed as 2/3 ICF and 1 /3 ECF; of the ECF, the distribution is 3 / 4 IF and 1 / 4 plasma. So in a person weighing 70 kg, intracellular fluid is 28 litre, while 9.5 litre is interstitial fluid, and 4.5 litre is the blood volume.

ICF = Intracellular fluid, ECF = Extracellular fluid, IF = Interstitial fluid.

How to demonstrate oedema clinically ?

1 First inspect the legs for any swelling.

2' Apply firm pressure for few seconds (at least 15 seconds to maximally upto 30 seconds sequen- ' tially over the medial malleolus, above the medial malleolus, lower end of tibia (media surface) and the upper part of shin bone by the tip of right thumb, i.e.. press over a bony background. Now inspect and palpate the area for any dimple or pitting. If it is seen that the dorsum of the foot is swollen, now one should press there. Do the same manoeuvre on the opposite side.

In oedema-forming states, **ambulatory patients** develop oedema on the dependent parts i.e., the ankle. 'Pitting' (i.e., the skin is indented) is the cardinal sign of subcutaneous oedema, which gradually fills in by redistribution of the displaced fluid.

3 Now examine the 'BACK', i.e., turn the patient into prone position and press the tip of rig ' thumb over sacrum. Sacral oedema is found in **patients confined to bed** for prolonged period. Sacrum *must be examined in all patients with oedema.*

4 Then examine for 'parietal oedema' - Press the chest piece of stethoscope or the tip of the five fingers of right hand, over the abdominal parietis or thigh for few seconds. Look for pitting oedema there. Oedema of the parietis (e.g., abdominal wall) may also be assessed by pinching the skin with thumb and index finger for few seconds (at least 5 seconds).

N B • Observe carefully for puffy face, puffy lower eyelids and scrotal oedema. It is said that oedema is also recognised by pallid and glossy appearance of the skin with less prominent superficial vem and at times by its doughy feel. Oedema* may be seen in the upper extremity, over sternum, vertebra and **forehead in a case of anasarca.** ***A***

* If *upper part of body is involved* press over wrist, lateral epicondyle at elbow, sternum and forehead for demonstration of oedema.

How to cltissify oedema clinically ?

(A) **Whether it pits on pressure or not** :

I. PITTING OEDEMA—commonly seen in :

a) Congestive cardiac failure.
b) Cirrhosis of liver.
c) Nephrotic syndrome.
d) Hypoproteinaemia with severe anaemia e.g., in protein-losing enteropathy, starvation, kwashiorkor (nutritional oedema).
e) Pericardial effusion.
f) Constrictive pericarditis.
g) Drugs - Amlodipine (i.e., vasodilators), liquorice, corticosteroid, oestrogens.
h) Venous obstruction.
i) Beriberi, epidemic dropsy.

II. NON-PITTING OEDEMA or'SOLID OEDEMA'—commonly seen in :

a) Myxoedema (usually it is infiltrative oedema due to deposition of mucinous material^
b) Lymphatic oedema (late stage) e.g., filariasis (due to organisation of protein-rich fluid).
c) Angioneurotic oedema.
d) Scleredema (post-streptococcal, self limited, painless oedematous induration) or initial stage of scleroderma.

(FU According to distribution of oedema :

I GENERALISED— it is known as **'anasarca'** (previously known as 'dropsy') and the causes a ' the same as a) b) c) and d) of pitting oedema. Points e) and f) too may develop into anas .

II LOCALISED— the common causes are,

' al Venous obstruction- Pregnancy, SVC syndrome, IVC syndrome, varicose veins in legs, prolonged recumbency, deep venous thrombosis (DVT), immobilised or paralysed limb.

b) Lymphatic obstruction (lymphoedema)- Filariasis, tuberculosis, carcinoma of the breast following radical mastectomy, radiation injury, Milroy's disease (congenital hypoplasia of lymph vessels).

c) Allergic cause— Angioneurotic oedema, acute anaphylaxis.

d) lnn*mTMa\or y- Caused by insect bite, snake bite, trauma, ischaemia or infections, and is probably due to liberation of histamine and other factors (increases capillary permeability) Miscellaneous— Bruises, sprains, cellulitis, fracture, gout.

Localised causes may present as **unilateral oedema;** cyclical oedema may be unilateral.

*** °edema "lay be restricted to limited region like pedal/sacral/facial or generalised (anasarca).

In the early stage, lymphatic oedema is soft and pits easily on pressure

SPeC,a"y *he 'OWer ,lmbS - P-'o-SeC busjoum.y, and ,s due to

What is angioneurotic oedema ?

This is the swelling of dermis and subcutaneous tissue, and is of two types ; hereditary and acquired.

- It is a specific form of allergic oedema which results from hypersensitivity.

2. It is a solid oedema; involves deeper layer of skin; usually lasts for a few hours
3. Commonly localised in tongue, lips, face, eyelids etc.
4. The swelling develops rapidly and is pale or faintly pink in colour.
5. Associated with itching; may be ACE-inhibitor induced (acquired).
6. **Congenital (hereditary) variety is due to C, esterase inhibitor deficiency.**
7. May threaten life by suffocation, if larynx or tongue is affected.

How much body weight is to be increased for development of pitting oedema *

also ^rnThafnilrn^"' ^ * necessary ^ demonstration of pitting oedema. It is so seen that pitting oedema occurs when the circumference of the limb is increased by 10%.

Why lymphatic oedema is intractable ?

s.itJiS„fdTZ'"dre"Tf0n °f ,J,Tha"C "°W r"UltS Protein concentration in the Inter- of retained M " "pUlartes,. , situation which severely impedes remova.

Most reliable index of progress to treatment in a case of oedema :

Day to day alteration in body weight.

How cardiac oedema differs from renal oedema ?

(A) **Congestive cardiac failure** :

1. Patients will be dyspnoeic.
2. Engorged and pulsatile neck vein with soft, tender, mild hepatomegaly.
3. Sometimes associated with right ventricular gallop rhythm.
4. Evidence of heart disease, i.e., cardiomegaly may be present.
5. Oedema **starts in the dependent part (around the ankles and pretibial region)** and en ascends progressively; pitting oedema; it is also present over the sacrum in a patient

co™ UehTerl 'te eveM„g?ed'ma " ^ 'nCl °f day'S "rk |sl"" b'_

(B) **Nephrotic syndrome** :

1. A history of previous renal disease may or may not be elicited.
2. **Oedema starts in the face (mainly periorbital), arms and then descends Oedema is** t f ^ ^ Carly m0ming_ Swellln g of scrotal sacs and lower eyelids (due to low tissue tension, are classical; pitting oedema; sacral oedema in non-ambulatory patients

Periorbital andnsCcrSot ,TaSS1Ve SCVere hyP°Proteinaemia and hypercholesterolaemia.

In C^F oeriem H T SUbCUtaneous tlssue fa— accumulation of oedema fluid there,
n CRF, oedema may be either due to renal insufficiency or cardiac failure secondary to hypertension.

Evolution of oedema in different systemic diseases :

1■ Congestive cardiac failure : Legs ^ face -4 ascites.

3 CirPrbr°tiC nndrOl'T : (peri°rbital Puffiness) _ legs ascites (with scrotal swelling)

3. Cirrhosis of liver : Ascites ^ legs -> face.

4. Nutritional oedema : Oedema feet with puffiness of face -> ascites.

Common causes of pedal oedema :

1. Congestive cardiac failure.
2. Nutritional oedema, protein-losing enteropathy, hypoalbuminaemia due to any cause.
3. Cirrhosis of liver.
4. Varicose veins, deep vein thrombosis; abdominal mass (tumour, cyst, pregnancy).
5. Filariasis or chronic lymphatic obstruction, Milroy's disease.
6. Nephrotic syndrome.
7. Cyclical oedema (female > male; temporal relationship with menstrual cycle).
8. Drug-induced - Nifedipine or amlodipine, fludrocortisone, NSAIDs, oestrogens, corticosteroids.
9. Miscellaneous— Pericardial effusion, constrictive pericarditis, immobility (e.g., hemiplegia), postural (inactive persons or prolonged immobilisation), cellulitis, over inflammed joint, lipaedema (abnormal fat deposition in the hips, thighs and legs sparing feet; only in women), irradiation.

* Unilateral—deep vein thrombosis, cellulitis, filariasis (early stage), hemiplegic side and trauma; Bilateral—other causes mentioned in the question above.

** In oedema of legs, try to determine its upper level (e.g., oedema to mid-thigh etc).

Common causes of facial puffiness :

1. Familial; facial cellulitis.
2. Hypoproteinaemia (nephrotic syndrome, acute nephritis, severe anaemia, protein-energy malnutrition).
3. Congestive cardiac failure, pericardial effusion, constrictive pericarditis.
4. Myxoedema.
5. SVC syndrome.
6. Cushing's syndrome.
7. Angioneurotic oedema.
8. Trichinosis as a result of infected pork ingestion.

* 'Conjunctival oedema' is common in hypoalbuminaemia. Weil's disease, Graves' disease, fluid overload and SVC syndrome.

Different mechanisms of oedema formation :

1. Low plasma oncotic pressure e.g., hypoproteinaemia (in cirrhosis of liver).
2. High capillary hydrostatic pressure e.g., congestive cardiac failure, DVT.
3. Increased capillary permeability e.g., acute inflammation, amlodipine-induced.
4. Obstructed lymphatic drainage e.g., filariasis, radiation.

Why there is oedema in heart failure ?

1. Impairment of renal blood flow results in more salt and water resorption.
2. Increase in venous pressure (thus, in right-sided heart failure there is venous congestion in systemic circulation i.e., there is development of oedema, and in left-sided heart failure there is pulmonary venous congestion).
3. Secondary hyperaldosteronism.
4. Increased level of ADH.
5. Some lymphatic factors may play a role.
6. Chronic passive congestion of liver from heart diseases (produces hypoalbuminaemia).

* In 'lipodermatosclerosis' (the skin is teethered and can not expand to accommodate oedema fluid), ankle may be spared in early oedema. Usually a female patient presents with painful areas of inflammation with induration. It may produce non-pitting oedema.

** Be careful in examining a patient of anasarca as the patient may have bilateral hydrothorax, ascites, hydrocele (with or without scrotal oedema) and rarely, pericardial effusion. Oedema restricted only in the upper half of the body is commonly due to SVC syndrome.

*** **Filariasis** may be given as a spot case.

**** Examination by the **tip** of **the thumb** — Oedema is demonstrated. Examination by the **ball** of **the thumb** — a) Sternal tenderness b) Murphy's kidney punch c) Carotid massage, and d) Air sinus tenderness are demonstrated clinically.

Case 43

Clubbing

What is clubbing ?

This is the bulbous swelling of the terminal part of the fingers and the toes with an increase in the soft tissue mass, and increased antero-posterior as well as transverse diameter of the nails due to proliferation of subungual connective tissue, interstitial oedema, and dilatation of arterioles and capillaries. Clubbing is also known as Hippocratic fingers. It is a window in clinical medicine and usually a valuable clue to an underlying disease.

What is onychodermal angle ?

It is the angle formed between the nail and the nail-bed. It is also known as **Lovibond's angle.** The normal angle is approximately 160°. Clinically it is judged by the angle formed between the nail and the adjacent skin-fold. Thus, the other name for clubbing is Lovibond's sign.

How will you examine for clubbing ?

(A) ***First step*** -

i the Patient s Angers at your eye level and look tangentially. Observe the onychodermal angle. If the angle is 180° or more, it is said that clubbing is present.

(B) ***Second step*** -

Very early clubbing can be detected by increase in fluctuation of the nail-bed (due to softening o t e nail-bed). To elicit 'fluctuation-, the patients finger (say the middle finger) is placed on the pulp of examiner s two thumbs and held in this position by gentle pressure with the tips of examiner's middle fingers applied on the patient's proximal interphalangeal joint. The patient's finger is now palpated over the base of the nail by the tips of examiner's index fingers. There is always some amount of fluctuation present in normal fingers. When fluctuation is obvious (due to clubbing), it gives a spongy feel and palpation of the nail-bed may give the impression that the nail is floating on its bed.

* *For detection of clubbing, first examine the onychodermal angle and then for fluctuation.*

Alternative method for detection of clubbing :

Few clinicians prefer this method. Place the nails of two fingers of two hands (preferably the thumbs or ring fingers of both hands are taken for examination) face to face and look for the diamond-shaped area formed between the two nails and the proximal nail-folds. The normally formed diamond-shaped area is obliterated in the presence of clubbing. This is known as *window sign or Schamroth's sign.*

Digital index :

It is an objective measurement (or numerical assessment) of clubbing. For individual finger, the circumference at nail-bed (i.e., at the site of onychodermal junction) is divided by the circumference at the distal interphalangeal joint. The individual digit ratio of 10 fingers are added. The final value is now divided by 10, and if it is found to be > 1, clubbing is said to be present.

Degree of clubbing :

1° Clubbing - Increased fluctuation of the nail bed with loss of onychodermal angle.

2° Clubbing - 1° + increase in antero-posterior and transverse diameter of the nails as well as nails become smooth and glossy with loss of longitudinal ridges.

3° Clubbing - 2° + increased pulp tissue.

4° Clubbing - 3° + wrist and ankle swelling due to HOA (hypertrophic osteoarthropathy).

N.B. : 1° and 2° are designated as MILD CLUBBING, and 3° and 4° as SEVERE CLUBBING.

What is HPOA ?

It is known as hypertrophic pulmonary osteoarthropathy where there is 'subperiosteal new bone formation at the lower end of radius, ulna, tibia and fibula, and the patient complains of swelling as well as pain in the wrist (most common) and ankle; the elbow and knee joint may be affected The joints ***sZnT-*** and tCnder °n palPation- Ultimately other bones like ribs, clavicle, scapula may be affected. HPOA is commonly seen in bronchogenic carcinoma (usually from squamous cell variety) and that is why the term 'pulmonary' is added. It is diagnosed by X-ray; isotope bone scanning may reveal increased periosteal activity. HOA may be familial (pachydermoperiostitis) or idiopathic.

N.B. : When you examine the patient for clubbing, always look for any swelling and tenderness in the wrist or ankle. If these are present, the clubbing is of 4°.

Causes ***of clubbing :***

(A) Cardiac causes -

1. Cyanotic congenital heart diseases like Fallot's tetralogy.
2. Subacute bacterial endocarditis (SBE).
3. Rarely in cardiac tumours (e.g., atrial myxoma).
4. Eisenmenger's syndrome, primary pulmonary hypertension.

(B) Lung and pleural causes -

1. Bronchietasis.
2. Lung abscess.
3. Bronchogenic carcinoma.
4. Empyema thoracis.
5. Fibrosing alveolitis.
6. Pleural mesothelioma.
7. Pulmonary arteriovenous fistula.
8. Cystic fibrosis.
9. Rarely in long-standing fibrocaseous tuberculosis.

(C) Ulcerative colitis.

(D) Biliary cirrhosis, sometimes in hepato-cellular failure.

(E) Intestinal causes -

1. Malabsorption syndrome.
2. Crohn's disease.
3. Polyposis coli.
4. Coeliac disease.

(F) Normal - Found normally in some people (idiopathic).

(G) Genetic - May be a familial condition.

* Remember the mnemonic 'Clubbing' to remember the causes. Majority of the causes of clubbing remain within the CVS and respiratory system. COPD does not give rise to clubbing.

** Clubbing may be resolved after removal of tumour from lung.

*** The commonest cause in young is bronchiectasis and that in elderly is bronchogenic carcinoma.

Different types of clubbing :

1. **'Drumstick'** type is seen in :
   a) Cyanotic congenital heart diseases, e.g., Fallot's tetralogy.
   b) Bronchiectasis.
2. **'Parrot-beak'** type : Commonly seen in bronchogenic carcinoma.

Painful clubbing :

1. Bronchogenic carcinoma.
2. SBE.
3. Lung abscess.

Reversible clubbing :

1. Lung abscess.
2. Empyema thoracis.

Unilateral clubbing :

1. Presubclavian coarctation of aorta (left-sided clubbing).
2. Bronchogenic carcinoma (commonly apical).
3. Cervical rib.
4. Aneurysm of subclavian or axillary artery.
5. Erythromelalgia.
6. Arteriovenous fistula of brachial vessels.

Unidigital clubbing :

1. Hereditary (if bilateral).
2. Repeated local trauma.
3. Rarely from median nerve injury or deposition of tophi (gout).
4. Sarcoidosis.

Clubbing limited to upper extremity :

Chronic obstructive phlebitis of upper extremity as a result of chronic I.V drug addiction (e.g., heroin).

Clubbing limited to lower extremity (differential clubbing) :

In infected abdominal aortic aneurysm; sometimes in PDA with reversal of shunt (with cyanosis).

What is 'acute' clubbing ?

When the clubbing develops very rapidly e.g., in lung abscess and empyema thoracis, clubbing may develop as early as 10-14 days after the onset of illness, and is known as 'acute' clubbing.

Why the pulp tissue is increased ?

This is due to,

1. Proliferation of subungual connective tissue.
2. Interstitial oedema.
3. Dilatation of arterioles and capillaries, or opening of anastomoting channels at nail-bed.

Most *reliable' early sign of clubbing :

Loss of normal onychodermal angle. One of the earliest sign is increased fluctuation of the nail-bed though not always reliable.

Causes of 'pseudoclubbing' :

This is due to subperiosteal bone resorption of terminal phalanges (there is absence of soft tissue proliferation and increased curvature of nails) and is seen in,

1. Scleroderma.
2. Acromegaly. ■
3. Hyperparathyroidism.
4. Leprosy.
5. People working with vinyl chloride (acrosteolysis).

Which finger is usually affected first in clubbing ?

Usually the index finger.

Points to note when clubbing is detected :

1. Unilateral or bilateral.
2. Painful or not.
3. Presence or absence of central cyanosis.
4. Presence or absence of dyspnoea.
5. The degree of clubbing.
6. Duration of clubbing.

Possible mechanisms of clubbing :

The different hypothesis are—

1. Anoxic (arterial hypoxaemia) - This is the most important theory which leads to opening up of deep arteriovenous anastomotic channels of the terminal phalanges resulting in overgrowth of soft tissues; example - Fallot's tetralogy.
2. Toxic - The example is SBE.
3. Reflex (neurogenic) - Vagotomy often improves the clubbing in bronchogenic carcinoma.
4. Metabolic - The example is thyrotoxicosis.
5. Humoral - Increased growth hormone, parathormone, bradykinin, e.g., in acromegaly.
6. Pressure changes between the radial and the digital arteries.
7. Reduced ferritin (may escape oxidation in lungs and leads to dilatation of arteriovenous anastomosis by entering into systemic circulation) may play an important role (recent view).

Pathogenesis of clubbing :

1. Hereditary predisposition - An autosomal gene of variable penetrance has been detected.
2. Vasodilators, e.g., prostaglandins, bradykinins, 5-HT may be responsible for the development of clubbing. In bronchogenic carcinoma, vasodilator substances normally detoxified by lungs enter into systemic circulation unaltered.
3. *There is trapping of megakaryocytes and platelet clumps with local release of platelet-derived growth factor (PDGF) and other cytokines (TNF-a). which increase the capillary permeability and accentuate proliferation of connective tissue (latest and most acceptable theory).*

Some other uncommon causes of clubbing :

1. Thyrotoxicosis (part of thyroid acropachy).
2. Asbestosis.
3. Occupational i.e., in jackhammer operators.
4. Sarcoidosis.
5. Amoebic liver abscess.
6. Portal cirrhosis.

What is koilonychia ?

It is the 'spoon-shaped deformity' of the nail usually found in chronic iron deficiency anaemia.

Loss of pulp tissue in right middle finger and left great toe in **severe atherosclerosis.** The patient had H/O intermittent claudication

Deep venous thrombosis of calf muscles (with some eczematous changes in lower part of leg)

Oedema of the genitalia (scrotum and penis) in nephrotic syndrome

Muscle haematoma (left thigh) and monoarthritis of left knee joint in **haemophilia**

Necrobiosis lipoidica diabeticorum (NLD) – yellowish plaque-like lesion which has ulcerated with atrophic centre along with surrounding spreading erythema, classically seen over the shins in diabetes mellitus

A **cretin** aged 18 years presented with short stature, coarse facies like depressed bridge of the nose, thick lips, broad flat nose and an idiotic look, and **pot-bellied abdomen with umbilical hernia**

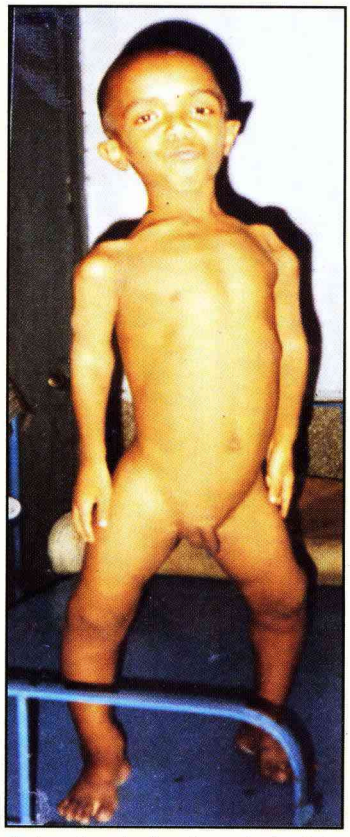

Achondroplasia characterized by dwarfism with short limbs and a relatively large head. Normal development of external genitalia is seen

Pituitary dwarf. Juvenile facies, thick, short and plump (chubby) with normal intelligence

Down's syndrome. A cheerful idiot

Precocious puberty in a boy aged 7 years

Koilonychta develop, as a result of retarded growth of the nail plate. Kollos' means hollow and 'onych' means nail. Toe nails are affected earlier than the finger nails.

Hoiu to ***examine for koilonychia*** ?

Bring the patient's fingers at your eye level and look tangentially (same as clubbing). Observe as wel as palpate the nail plates for any flattening or spooning.

Stages of koilonychia :

There are three stages :

(A) First **stage**- 'Stage of brittleness', where the nail becomes brittle and roug .

(B) Second stage - 'Stage of flattening (platynychia). where the nail is thin, flat and without ongi tudinal ridges.

(C) Third stage - 'Stage of spooning', where the nail becomes concave.

Causes of koilonychia :

1. Long-standing iron deficiency anaemia (commonest).
2. Idiopathic or familial.
3. Onycholysis due to any cause may give rise to spooning of nails.
4. Overuse of solvent (e.g., nail varnish remover) or detergents.

N.B.5 AfJrTxmTl'1C*tend'S,or clubbing. examine the other hand and next examine the toes.

Case 44

MOON FACE

Describe the face :

The face looks bloated and rounded (like the full moon).

Common causes of moon face :

1 Cushing's syndrome (and Cushing's disease)-with hirsutism and facial plethora.

2 Nephrotic syndrome (marked periorbital oedema; with baggy lower eyeli s)

3 Acute glomerulonephritis (periorbita, oedema with narrowing of palpebral fissure,.

4. Prolonged steroid therapy (often with hirsutism and facial plethora).

Mvxoedema (with baggy lower eyelids).

6 Superior mediastinal syndrome (with prominent veins in forehead and temple regio).

7 Angioneurotic oedema of face (lips may be swollen; patchy involvement .

K Subcutaneous emphysema of face, extending from chest (asymmetrical swe g).

« **'Periorbital oedema (or puffiness)-** is characteristic^ **IJScdlu-**

favours accumulation offluid around the eyes.

** Read individual section for description.

'Check list' prior to steroid therapy :

1. H/O diabetes mellitus.
2. Pyogenic infection anywhere in the body.
3. Presence of active tuberculosis.
4. H/O peptic ulcer, gastritis or positive occult blood in stool.
5. Uncontrolled hypertension.
6. Evidence of osteoporosis.
7. Bleeding tendencies.
8. Previous H/O any psychological disorder.

Common indications for steroid therapy :

1. Addison's disease; Sheehan's syndrome.
2. Anaphylactic shock.
3. Acute severe asthma.
4. Circulatory shock.
5. Acute lymphoblastic leukaemia.
6. SLE and other collagen diseases.
7. Rheumatoid arthritis.
8. Nephrotic syndrome.
9. Acute rheumatic carditis.
10. Increased intracranial tension.
11. Interstitial lung disease.
12. In organ transplants to prevent rejection.
13. Lymphoma.
14. Cranial arteritis.
15. Vasculitides.
16. Ulcerative colitis.

How to reduce the side effects of corticosteroid ?

Give only in established indications with lowest possible dose, single dose, alternate days therapy than daily dosing, morning dose with minimal possible duration; curtail sodium and calorie intake, supplement with calcium and/or vitamin D, and bisphosphonates, H_2RA/PPI—may minimize the side effects on prolonged use.

Side effects of prolonged steroid therapy :

(A) Metabolic effects— More or less identical to those seen in Cushing's syndrome e.g., hyperglycaemia, hypokalaemia, hypochloraemia, alkalosis, sodium and fluid retention, osteoporosis etc.

(B) Suppression of hypothalamo–pituitary–adrenal (HPA) axis — In a patient with suppressed HPA axis, it may take months or years to recover fully. The dosage of steroid given only in the morning, or on alternate days, or gradual withdwal will produce less suppression of HPA axis. Treatment for 3 weeks or less with prednisolone < 5 mg/day will not suppress adrenal axis significantly.

(C) Features like Cushing's syndrome— Moon face, truncal obesity, growth retardation, acne, hirsutism, purple striae, easy bruising, osteoporosis, avascular necrosis of bone, peptic ulcer, pancreatitis, hypertension, diabetes mellitus, glaucoma, cataract, CCF, psychosis, myopathy, impotence.

* Morning cortisol level in serum is low in iatrogenic Cushing's syndrome in comparison to true Cushing's syndrome where the level is high.

Differences between ACTH and corticosteroid therapy :

	ACTH	Corticosteroid
1. Administration	Parenteral	Oral and parenteral
2. Sodium retention	More marked	Less marked
3. Adrenal androgen	Increased	No rise
4. Adrenal atrophy	Absent	Present
5. Acne	More	Less than ACTH

Effects of sudden withdrawal of steroid therapy :

The patients should be advised to avoid sudden drug withdrawal as it may produce :

1. Suppression of HPA axis.
2. Acute adrenal insufficiency.
3. Pseudotumour cerebri (specially affecting young and obese women; there is headache, papilloedema, constricted visual field with absent neurological signs, dilated ventricles on CT scan; idiopathic condition; may be treated with steroid or ventriculo-peritoneal shunt).

What is 'facies' ?

It is the 'expressions in the face' of the patient, and very often these facial signs collectively lead to prompt aetiological diagnosis of a disease. The facial appearance may be anxious, sad, calm, happy, cachectic, pyrexial, toxic, dehydrated, puffy or may show some specific characteristic of a particular disease, e.g., parkinsonism, thyrotoxicosis or acromegaly. As face is known to be 'mirror of mind', reading of face is very important in clinical medicine.

Identification points (moon face) :

(A) Rounded and bloated face — Moon face.
(B) With obesity — Cushing's syndrome, prolonged steroid therapy, myxoedema.
(C) With engorged neck veins — SVC syndrome, acute glomerulonephritis.
(D) Expressionless face — Myxoedema.
(E) Malar flush or plethora of face — Myxoedema or Cushing's syndrome.

(F) With hirsutism — Cushing's syndrome or prolonged steroid therapy.

(G) With breathlessness — SVC syndrome or receiving steroid for bronchial asthma.

(H) With anasarca — Nephrotic syndrome.

(I) With pallor — Nephrotic syndrome, myxoedema, SVC syndrome.

* If after careful and meticulous **examination of face** (in any patient), no diagnosis (of any 'specific facies') is reached, always try to look for :

1) Tongue (cyanosis, severe anaemia), 2) Pseudoptosis or partial ptosis, 3) Mild exophthalmos or enophthalmos, 4) Malar flush, 5) Masked facies, 6) goitre (though not a structure within the face), and 7) Ask the patient to show the upper teeth (facial palsy).

Case 45

DWARFISM (CRETINISM)

What is dwarfism ?

Dwarfism or short stature is a condition where the height of a person is much below in relation to chronological age and sex of that person as compared to a normal individual.

Common causes of dwarfism or 'short stature' :

1. Heredofamilial.
2. Constitutional (delayed growth and puberty).
3. Protein-energy malnutrition e.g., marasmus and kwashiorkor **(commonest cause of dwarfism in developing countries).**
4. Rickets.
5. Cretinism.
6. Pituitary dwarf.
7. Achondroplasia; mucopolysaccharidosis; progeria.
8. Cyanotic congenital heart diseases e.g., Fallot's tetralogy.
9. Gross kyphoscoliosis.
10. Down's syndrome, Turner's syndrome, Cushing's syndrome, Noonan's syndrome.
11. Pseudohypoparathyroidism.
12. Cystic fibrosis, bronchiectasis, thalassaemia major, coeliac disease, rheumatoid arthritis from childhood, uncontrolled type 1 diabetes mellitus, intrauterine growth retardation.

What is cretinism ?

Cretinism—hypothyroidism since birth due to partial or complete failure of thyroid gland (commonly due to thyroidal agenesis). Juvenile myxoedema — onset of hypothyroidism since childhood but develops before puberty (commonly due to dyshormonogenesis); myxoedema — onset of hypothyroidism after puberty (probably Hashimoto's thyroiditis is the commonest cause).

Describe the facies in cretinism :

The facies resembles an old man's face :

1. Appearance is dull, expressionless and idiotic; large head with sparse scalp hair.
2. Depressed bridge of the nose, broad flat nose with big nostrils.
3. Hypertelorism (widely set eyes) with wrinkling of eyebrows; narrow palpebral fissures.
4. Sparse, coarse and brittle hair with dry skin.
5. Lips are thick and everted with big, fissured, protruded tongue (macroglossia).
6. Delayed dentition with hoarse voice.

Other morphologic characteristics of cretin :

1. Short stature but maintains the infantile proportion, i.e., upper segment > lower segment.
2. The patient is lethargic and apathetic.
3. Markedly retarded intelligence. Memory is grossly impaired.

4. Skin is dry, scaly, rough and cold; skin looks pale yellow (i.e., carotenaemia).
5. Thick and short neck with presence of supraclavicular pad of fat.
6. Pot-bellied abdomen with umbilical hernia.
7. Flaccid muscles with marked hypotonia.

Features of hypothyroidism in neonatal period :

1. Prolonged physiological jaundice,
2. Hoarse cry,
3. Somnolence,
4. Feeding problem (difficulty in sucking),
5. Constipation, and
6. Delayed milestones of development (in later months).

How to differentiate between cretin and pituitary dwarf ?

The characteristics of cretin (thyroid dwarf) are :

a) Depressed bridge of the nose; coarse facies.
b) Lack of intelligence, and
c) More or less, normal genital development.

The characteristics of pituitary dwarf are :

a) 'Juvenile' facies; characteristically 'chubby'.
b) Normal intelligence, and
c) Sexual infantilism.

Laboratory diagnosis of cretinism :

A) BLOOD -

a) High serum cholesterol.
b) Low radioactive I^{131} uptake.
c) T_4 level is low with high TSH level.

* In neonates, heel-prick blood sample is used.

B) ECG - Low voltage.

C) SKELETAL X-RAY (OF LONG BONES AND PELVIS) -

a) Delayed closure of epiphysis (i.e., bone age is less than that of chronological age).
b) Delayed dentition.
c) Epiphyseal dysgenesis - Instead of one epiphysis, there are multiple epiphysis (DIAGNOSTIC).

Treatment of cretin :

1. Very small dosage of L-thyroxine is needed. Initial dose is 10 mg to 25 ng, and the dose is adjusted according to clinical improvement and biochemical findings.
2. Rehabilitation.

Differentiation of dwarfism by body ratio :

(A) Upper segment = Lower segment is seen in :

a) Heredofamilial,
b) Constitutional, and
c) Pituitary dwarf.

(B) Upper segment > Lower segment is seen in :

a) Achondroplasia,
b) Cretinism.
c) Juvenile myxoedema.

(C) Upper segment < Lower segment is seen in :

— Spinal deformities.

* Remember, short stature may be associated with features of delayed puberty.

Characteristics of Turner's syndrome (gonadal dysgenesis) :

The genetic constitution is 45, XO; usually recognised at puberty in girls ; short stature, webbed neck, low hair line, 'shield-like' chest, widely spaced nipples, cubitus valgus and mild mental retardation. Primary amenorrhoea, failure of development of secondary sexual character, streak gonads, sterility, peripheral lymphoedema, short 4th metacarpals and coarctation of aorta are associated features.

What is achondroplasia (achondrodysplasia) ?

Dwarfism in achondroplasia results from decrease in the proliferation of cartilage present in growth plate. It is an autosomal dominant disease and is usually recognised at birth. The dwarf jokers we see in the circus are usually achondroplasia patients. The characteristics are,

a) Dwarfism.
b) Normal mental (intelligence), dental, endocrine and sexual development; normal trunk.
c) Short limbs.
d) Large head with saddle nose.
e) Lumbar lordosis; kyphoscoliosis.

What is pseudohypoparathyroidism ?

In this condition, the secretion of parathormone (PTH) is increased but due to end organ resistance, there is no response to PTH hormone and thereby, resulting in clinical features of hypoparathyroidism. It is a hereditary disorder with distinctive skeletal and developmental defects. These patients have elevated levels of serum PTH. The common features are :

a) Short height with stocky built.
b) Round face with short neck.
c) Mental retardation.
d) Epileptic convulsions.
e) Short 4th and 5th metacarpals and metatarsals.
f) Basal ganglia calcification.

What is progeria ?

It is the 'premature aging' mimicking senile appearance of a person. It is manifested by accelerated atherosclerosis, atrophy of subcutaneous fat, alopecia, dwarfism, mild mental retardation and skeletal hypoplasia, and is followed by angina, myocardial infarction and systemic hypertension. Death usually occurs before the age 20.

Basic investigations performed in dwarfism :

[1. History—natal (prenatal, intranatal and postnatal) history, family and personal history].
2. Thyroid function tests.
3. Growth hormone assay.
4. Assessment of bone age (non-dominant hand and wrist are used for radiology).
5. Chromosomal karyotyping in females (e.g., Turner's syndrome).

Identification points :

Cretins are diagnosed by typical 'coarse facies' and other morphological features (there is marked physical and mental retardation; sometimes, its D/D is mucopolysaccharidosis, i.e, Hurler or Hunter syndrome). Cretins look younger to their chronological age.

If the height of an adult is < 4 feet, he/she may be called a dwarf.

Case 46

TALL STATURE

Common causes of tall stature :

1. Constitutional (idiopathic)—the commonest cause.
2. Racial, or familial.
3. Marfan's syndrome.
4. Gigantism (cerebral) and acromegaly.
5. Hypogonadism.
6. Klinefelter's syndrome.
7. Homocystinuria (inherited disorder of amino acid metabolism)
8. Supermales (XYY) and superfemales (XXX).

What is 'build' or 'built' ?

It is the 'skeletal framework' of a person in relation to his/her age and sex as compared to a normal person. Build is classified into two groups ;

1. Short stature, and
2. Tall stature (less common than short stature).

* Short stature : Below 3rd percentile for height of normal population of same age and sex.

Tall stature : Above 97th percentile for height of normal population of same age and sex.

** ***Stature*** is the total height measured from crown to heel. 'Build' is important in clinical practice due to the fact that some diseases are prevalent in tall stature while some are in short stature.

*** Body constitution (somatotypes) differs from person to person. They are divided into :

a) Normosthenic—with normal body build.

b) Asthenic—lean bodies, narrow shoulders, thin limbs and flat chest. They are prone to visceroptosis and neurasthenia.

c) Sthenic—thick trunk, short neck, broad shoulders, and thick and short limbs. They are more likely to develop hypertension and ischaemic heart disease.

Differentiate tall stature by body ratio :

The skeletal height of a person is measured from crown to heel when he/she stands erect against the wall to which a vertical scale is attached.

Upper segment (crown to pubis) : lower segment (pubis to heel) ratio of our body is approximately 1.8 : 1 at birth; by the age of 10 years the ratio becomes 1 : 1 and, it is approximately 0.9 : 1 in adults because the legs grow more rapidly than the trunk. Hence,

(A) Upper segment = Lower segment is seen in :

a) Constitutional, and

b) Pituitary causes (i.e., hyperpituitarism).

(B) Upper segment < Lower segment is seen in :

a) Marfan's syndrome,

b) Klinefelter's syndrome,

c) Hypogonadism (e.g., eunuchoidism), and

d) Homocystinuria.

(C) **Upper segment > Lower segment is seen in :**

a) Precocious puberty.

b) Adrenal cortical tumour.

Clinical features of Marfan's syndrome :

Marfan's syndrome is characterised by triad of symptoms (A, B and C described below)

(A) Skeletal abnormalities like,

1. Crown to heel height is above average (i.e., tall stature) with thin built (asthenic).
2. Lower segment > Upper segment of body.
3. Arm-span > height.
4. Hyperextensible joints (Steinberg's sign or thumb sign — in which the thumb, when opposed across the palm inside the clenched hand, extends beyond the ulnar border of the palm).
5. Kyphoscoliosis, straight back syndrome.
6. Anterior chest wall deformity (pectus excavatum and pectus carinatum).
7. High arched palate.
8. Long slender fingers and toes (arachnodactyly).
9. Metacarpal index > 8.4 (the length of each of the last four metacarpal bones is divided by the width at its midpoint, and the values are averaged).
10. Wrist sign — in which the patient can enclose his wrist with the thumb and little finger of other hand, and the digits overlap each other by at least 1 cm.
11. Loose jointedness, pes planus or pes cavus.
12. Long and narrow facies (dolicocephalus).

(B) Subluxation or dislocation of lens downwards commonly (look for iridodonesis). Myopia, retinal detachment and blue sclera may be seen.

(C) CVS (CVS abnormalities are major cause of morbidity and mortality) -

1. Aortic incompetence.
2. Dissecting aneurysm of ascending aorta.
3. Mitral valve prolapse.

(D) Others—Spontaneous pneumothorax, cystic bronchiectasis, striae over shoulders.

* Intelligence and sexual development are normal in Marfan's syndrome.

** Bernard Jean Antonin Marfan (1858-1942) was Physician in Paris, France.

*** Lean and thin persons with long, slender fingers—loosely termed as 'marfanoid habitus'.

Where lies the deffect in marfan's syndrome ?

Not truely known but defective collagen cross-linking may be responsible for the abnormalities in the supporting tissue. Recently it is said that mutation of fibrillin-1 and fibrillin-2 genes may be responsible for Marfan's syndrome. It is an autosomal dominant disease.

Arm-span versus height :

Normally, the arm-span (i.e., distance between fingertips when hands are stretched parallel to the ground) is equal to the height of a person. Arm-span becomes greater than height in conditions where lower segment > upper segment of the body (see above). Height is greater than arm span in hyperpituitarism, precocious puberty and adrenal cortical tumour.

Diagnostic points in Klinefelter's syndrome :

1. Tall stature (due to hypogonadism) with eunuchoid body proportions in a male; obese.
2. Lower segment > upper segment of the body. Crown to pubis length < pubis to heel.
3. Gynaecomastia with loss of secondary sexual characters.
4. Phenotypically male with small, firm testis; small penis; male psychosexual orientation.
5. Mental subnormality (mild).
6. Azoospermia (sterility) with elevated levels of plasma and urinary gonadotropins.
7. Chromation (Barr) body is usually present (chromosomal pattern is 47, XXY) in buccal smear preparation.

* Eunuchoidism, gynaecomastia and hypogonadism are triad for Klinefelter's syndrome.

Features of homocystinuria :

1. It is due to reduced activity of the enzyme cystathionine (3-synthase.
2. Mental retardation; autosomal recessive inheritance.
3. Displacement of lens downwards.
4. Life-threatening thrombotic episodes may occur.
5. Elevated plasma methionine and homocysteine levels.

What is menat by eunuchoidism ?

In a general sense, androgen loss reflects eunuchoidism. If testicular failure occurs before puberty it results in hypogonadism, lack of sexual maturation and tall stature—collectively known as eunuchoidism.

Why there is tall stature in hypogonadism ?

Testosterone accelerates epiphyseal ossification and fusion. When there is lack of testosterone in human body, there is uninhibited longitudinal growth.

Clinical associations in 'tall stature' :

Accident-proneness, isolated signs of virilism, signs of early puberty and rarely, symptoms of hyperthyroidism.

Conclusion :

One should always examine the testes, palate (high arched), spine and CVS (for AI) in tall patients.

Case 47

EMACIATION

What is ***emaciation*** ?

Generalised undernutrition, i.e., loss of total body fat and diminution of muscle bulk.

How do you assess nutrition at the bedside ?

Nutrition is the 'nourishment' of the body. It is clinically assessed by (semi-quantitatively) :

1. SUBCUTANEOUS FAT—assessed by picking up skinfold between the index finger and thumb. Actually, it should be measured by a special calliper (Harpenden or Schofield's calliper).
2. BULK OF MUSCLE MASS—measure the mid-arm circumference or mid-thigh circumference by a tape from the elbow joint or knee joint respectively (i.e., from a fixed point).

3. SIGNS OF VITAMINS, MINERALS AND NUTRIENTS DEFICIENCY—assessed by the presence of glossitis, cheilosis, angular stomatitis, xerophthalmia, Bitot's spot, koilonychia etc.

Remember, even the presence of mild oedema (as a result of hypoproteinaemia), anaemia, or koilonychia indicates malnutrition. For the assessment of subcutaneous fat and muscle bulk, always compare with the other side of body to diagnose localised or generalised nature of the disease process.

* In the presence of anasarca, nutrition can not be properly assessed. Skinfold thickness in the mid-triceps region (midway between acromion and olecranon process, when the arms are hanging by the side of the body) is the most commonly used site; other sites assessed are biceps, infrascapular and supra-iliac region.

** To assess the nutritional state, clinical history including dietary history and physical exmination including anthropometric measurement are necessary.

*** Average adult triceps skinfold thickness : Males 12.5 mm, females 16.5 mm.

Average adult left mid-arm circumferance ; Males 25.5 cm, females 23 cm.

How the 'nourishment' of the body is divided ?

- Normal
- Underweight (e.g., malnutrition, emaciation and cachexia)
- Overweight
- Obesity

How emaciated patients look like ?

All skin and bone'. All the bony prominences become more prominent.

What is malnutrition ?

Undemutrition with signs of vitamin, mineral and essential amino acid deficiency is known as malnutrition. Malnutrition may be due to starvation, maldigestion and malabsorption. Remember, over-nutrition is also malnutrition. So, a complete dietary history is important.

What is cachexia ?

It is combined manifestations of anorexia, anaemia plus emaciation, i.e., a profound state of general ill-health. Decrease in muscle mass is known as 'sarcopenia'.

Common causes of emaciation :

1. Pulmonary tuberculosis (commonly encountered in India).
2. Diabetes mellitus (in spite of increased appetite; specially in type 1 DM).
3. Thyrotoxicosis (in spite of increased appetite).
4. Disseminated malignancy (commonly colon, lung, pancreas, stomach).
5. Acquired immune deficiency syndrome (slim disease).
6. Anorexia nervosa (psychogenic) - Rare.

* Other causes of 'wasting' or 'weight loss' are malabsorption, malnutrition, cirrhosis of liver, Addison's disease, motor neurone disease, Sheehan's syndrome. Unexplained and unintentional weight loss of > 3 Kg in the previous 6 months is known as 'significant' weight loss.

Localised muscle wasting is characteristic of disuse atrophy, poliomyelitis, motor neurone disease, muscular dystrophy, peripheral neuropathy, cord lesions and local nerve injuries.

Table 27 : Indicators of nutritional depletion

Anthropometric	Chemical	Others
1. % of weight loss (>10%) (sub- or undemutrition)	1. Serum albumin (< 35 g/L)	1. Skin anergy
2. Mid-arm circumference (< 23 cm in male < 22 cm in female)	2. Serum transferrin (< 2 g/L)	2. Lymphocytopenia
3. Triceps skinfold thickness (<10 mm in male <13 mm in female)		

Hb/6, serum haematinics (iron, TIBC, ferritin, B_{12} and red cell folate) and prothrombin time are also indices of nutrition.

How to diagnose obesity clinically ?

Overweight — When the body weight is 10% excess over the upper limit of standard weight in relation to age and sex of that individual.

Obesity — When the body weight is 20% more than the upper limit of standard weight in relation to age and sex of that individual. 'Morbid obesity' is 100% more overweight than the upper limit of standard weight.

Clinical assessment —

1. Body weight > 20% above the ideal body weight or BMI > 30 (see below).
2. When measured by a special calliper, a fatfold thickness of greater than one inch in the inferior angle of scapula (male) or the mid-triceps region (female) is known as obesity.
3. Ponderal index <12

$$\text{Ponderal index} = \frac{\text{Height in inches}}{\text{Weight in pounds}}$$

* Obesity can be quantified by anthropometry (i.e., skinfold thickness), densitometry (underwater weight), CT or MRI scan (measures mesenteric fat).

How do you classify obesity clinically ?

1. Android—excessive fat deposition at waist.
2. Gynoid—excessive deposition of fat at hip or thigh.
3. Truncal—excessive fat deposition on face, neck and trunk (abdomen).

How can you assess obesity by body mass index (BMI) or Quetelet index :

BMI (a measure of generalised obesity) is obtained by calculating a person's weight in kilograms and dividing it by the person's height in metres squared (kg/m^2). For example, an adult male weighing 60 kg with a height of 1.70 metres has a BMI of $60/1.70^2 = 20.7$; BMI is height-dependent and thus short and tall persons of similar proportions have a similar BMI. BMI in children is less reliable than adults as an indicator of excess body fat. WHO classification of obesity is :

Category	**BMI range**
Underweight	< 18.5
Healthy weight	18.5 - 24.9
Overweight	25.0 - 29.9
Moderately obese	30.0 - 34.9
Severely obese	35.0 - 39.9
Morbidly obese	> 40

Abdominal or truncal obesity can be clinically measured by **'waist-hip ratio'** at the bedside. The ratio is measured by dividing the waist circumference in centimetres by the hip circumference in centimetres. The waist is usually measured at its narrowest point whereas the hips are measured at the fullest point around the buttocks. Truncal obesity is important (specially the mesenteric fat) because it is more atherogenic than peripheral fat, and is strongly correlated with insulin resistance. In a true sense, waist circumferance is a strong predictor of truncal obesity.

Waist circumference : It is measured mid-way between the superior iliac crest and the lower costal margin in the midaxillary line. Substantially increased waist measurement in males > 102 cm and in females > 88 cm indicate high-risk abdominal obesity associated with metabolic complications.

Hip circumference : It is measured at 1/3rd the distance between anterior superior iliac spine and the patella, or from greater trochanter of one side to greater trochanter of other.

Systemic hypertension, diabetes mellitus, ischaemic heart disease, hyperlipidaemia and insulin resistance may be associated with abdominal (truncal) obesity, and the morbidity and mortality risks are increased if the ratio is found to be > 1.0 in males or > 0.9 in females.

The BMI is useful in the assessment of both obesity and malnutrition.

Common causes of obesity :

1. Idiopathic (simple obesity).
2. Physical inactivity (sedentary habit).
3. Cushing's syndrome.
4. Hypothyroidism (primary).
5. Hypothalamic disorders (Froehlich's syndrome or injury).
6. Insulinoma.

7. Laurence-Moon-Biedl syndrome, Prader-Willi syndrome.
8. Iatrogenic — Prolonged therapy with corticosteroid or oestrogen.

* Causes of **'weight gain'** are,

1. Different causes of obesity, and
2. Increased fluid retention due to nephrotic syndrome, CCF. cirrhosis of liver, pregnancy.

Essential amino acids :

(A) Essential (can not be synthesised in humans but are indispensable for synthesis of some important proteins) :

- Tryptophan
- Histidine
- Methionine
- Threonine
- Isoleucine
- Phenylalanine
- Valine
- Lysine
- Leucine

(B) Conditionally essential (if there is adequate dietary supply, they can be synthesised from other essential amino acids) :

- Cysteine
- Tyrosine
- Arginine
- Proline
- Glycine

Features of hypoalbuminaemia :

(A) Causes : PEM, chronic liver disease (e.g., cirrhosis of liver), protein-losing enteropathy, nephrotic syndrome, burns, trauma with sepsis (hypercatabolic states).

(B) Normal serum level : 3.5-5.5 g/dl (usually < 2.5 g/dl have serious hypoalbuminaemic features).

(C) Features : Weakness, dependent oedema, anasarca, conjunctival oedema with oedema of eyelids, polyserositis, ascites, leuconychia and increased susceptibility to infection.

Signs of vitamin A deficiency :

1. Toad's skin - Follicular hyperkeratosis (phrenoderma).
2. Xerosis of the conjunctiva, Bitot's spot, xerophthalmia and keratomalacia.
3. Recurrent respiratory and gastrointestinal infection.

N.B. : Most important symptom is night blindness (other causes of night blindness or ***nyctalopia*** are retinitis pigmentosa, peripheral chorioretinitis, retinal detachment, zinc-deficiency and malingering). **Bitot's spot** is whitish, raised, foamy and triangular spot with its base towards limbus; it is present on the bulbar conjunctiva, a little away from the limbus.

* ***Essential fatty acid*** (linoleic acid, linolenic acid and arachidonic acid) deficiency also cause phrenoderma.

** Other causes of xerophthalmia in clinical practice are Sjogren's syndrome, chronic conjunctivitis, anaesthetic cornea, Stevens-Johnson syndrome, burns and pemphigoid.

Signs of riboflavin (vitamin BJ deficiency :

1. Magenta-coloured tongue (glossitis).
2. Cheilosis (cracks and fissures at mucocutaneous junction of the lip), angular stomatitis.
3. Keratitis, vascularisation of cornea, corneal opacity, angular blepharitis.
4. Seborrhoeic dermatitis (face, scrotum) with loss of hair; fissures in the nasal orifice.
5. Anaemia.

Signs of nicotinic acid deficiency :

1. Cheilosis, angular stomatitis.
2. Raw-beefy tongue—Red, swollen and painful tongue.
3. Dermatitis (pellagra)—Specially seen on the exposed part of the body with erythema, cracking, desquamation and exudation in acute cases. There may be roughening and pigmentation of skin. Dermatitis in the neck (Casal's collar) is pathognomonic.
4. Dementia and delirium (acute form).
5. Diarrhoea.

* Common causes of **cheilosis** are,

a) Iron deficiency anaemia.
b) Deficiency of riboflavin, folic acid and vitamin B_{12}.
c) Exposure to cold weather (cracked lip—in the middle of lower lip).
d) Nicotinic acid deficiency.

Signs of pyridoxine (vitamin BJ deficiency :

Though vitamin $B_{(}$. deficiency is rare, it may produce :

1. Polyneuropathy, 2. Mild depression (in women taking oral contraceptive pills), 3. Hypochromic anaemia, 4. Convulsions, and 5. Cheilosis, glossitis, seborrhoea.

* Uses of pyridoxine in clinical practice are :

a) Along with INH (to prevent peripheral neuropathy), penicillamine, L-dopa and cycloserine therepy (these drugs are pyridoxine-antagonist and may produce convulsions).
b) Sideroblastic anaemia.
c) Neonatal convulsions.
d) Vomiting of pregnancy.
e) Rare diseases like xanthurenic aciduria, cystathioninuria, oxaluria.
f) High doses of vitamin B_6 is beneficial in carpal tunnel syndrome, diabetic neuropathy, autism, schizophrenia and premenstrual syndrome.

** Increased homocysteine level in plasma is associated with acute myocardial infarction and stroke. Folate (low dose), vitamin B_{12} and B_g supplementation reduce the homocysteine level in plasma efficiently.

Signs of dehydration :

1. Face is drawn (facies Hippocraticus).
2. Shrunken eyes.
3. Pinched-up nose.
4. Parched lips.
5. Hollowness of temporal fossa.
6. Depressed anterior fontanelle (infants).
7. Tongue is dry and coated.
8. Skin is dry and wrinkled; subcutaneous tissue feels lax.
9. The sign of ridge' - If the skin is pinched up by index finger and thumb, and then released, a ridge is formed which subsides slowly (in severe dehydration) instead of it springing back with normal elasticity, i.e.. there is loss of elasticity of skin (i.e., loss of skin turgor).
10. The eyeballs are soft due to lowering of intraocular tension.
11. Hypotension with weak pulse.
12. Scanty, dark, concentrated urine of high specific gravity.

* Assess hydration by skin elasticity, intraocular tension and recording of BP (specially, postural hypotension).

Case 48

EXAMINATION OF NECK VEINS

Internal or external jugular vein ?

Always examine the internal jugular vein; external jugular vein is less reliable because it is:

1. Superficial and prone to kinking.
2. Does not directly drain into SVC,
3. May have valves, may pierce fascia,
4. Engorged, if patient wears a tight collar,
5. Not a direct reflector of central venous pressure (CVP).

* Internal jugular vein is in direct continuity with the right atrium and reflects the pressure changes in the right atrium as well as CVP. As it is deeply situated, the internal jugular vein is difficult to visualise.

N.B. : Recent view is that both external and Internal jugular veins have valves and as internal jugular vein is difficult to visualise, the external jugular vein is gaining importance.

Prerequisites for accurate assessment of neck veins :

1. The patient should be reclining supine at 45° (angle formed by trunk and the level of the bed at waist is 45°). .
2. Neck muscles should be 'relaxed' properly (examination should always be done with a 'back-rest' or properly adjusted pillows; if'back-rest' is not available, patient's body can be lifted and supported on your arm to make an angle of 45° but proper relaxation of neck muscles is not achieved by this method).

3. Good light is necessary for visualisation of neck veins. A light source e.g., a torch illuminated from behind (tangential application) helps to visulaise the waves in a better way.
4. It is better to observe the right internal jugular vein (the innominate vein may be compressed by the aortic knob which damps and elevates the venous pressure in the left jugular vein).
5. It is better to stand on the right side with patient's face slightly turned to the left for observation of right-sided neck vein.
6. One should look in between the two heads of sternomastoid muscle and if it seems full, observe the uppermost point of distension (one may identify the internal jugular pulsation with the help of hepato-jugular reflux, or by occluding it with gentle digital pressure above the clavicle).

N.B. : If in the sitting position neck veins are fully engorged, it is not necessary to examine the patient at 45°, and in that situation measure venous pressure in sitting position. Similarly, the patient may have to lie flat if the JVP is very low.

Table 28 : Bedside differentiation between venous and arterial pulsation in neck

Venous pulsation	Arterial pulsation
1. Wavy or undulating	1. Jerky or abrupt
2. Better seen than felt	2. Better felt than seen
3. Becomes prominent on expiration	3. No change
4. Becomes prominent on lying down	4. No change
5. Becomes prominent on application of abdominal pressure (hepato-jugular reflux)	5. No change
6. Prominent movement is inward	6. Prominent movement is outward
7. Can be abolished by gentle digital pressure applied above the clavicle (important point of differentiation in the examination hall)	7. Does not affect arterial pulsation
8. Two positive waves are seen (when in sinus rhythm)	8. One positive wave is seen (when in sinus rhythm)
9. It has a definite upper level	9. No such level is seen
10. Pulsatile displacement of the ear lobes in high CVP	10. Absent in arterial pulsation

Causes of increased jugular venous pressure (JVP) :

(A) ENGORGED AND PULSATILE NECK VEIN :

1. **Congestive cardiac failure (commonest cause of raised JVP).**
2. Chronic constrictive pericarditis.
3. Cardiac tamponade.
4. Tricuspid valve disease (TI and TS).
5. Restrictive cardiomyopathy.
6. Chronic cor pulmonale.
7. Pulmonary thromboembolism.
8. After massive fluid infusion or blood transfusion, pregnancy, acute nephritis (i.e., salt and water retention).
9. Complete heart block (from time to time cannon waves are seen).

* T JVP is the first sign to appear and last sign to disappear in CCF or right heart failure.

(B) ENGORGED AND NON-PULSATILE NECK VEIN :

1. **Superior mediastinal syndrome (commonest).**
2. Rarely in chronic constrictive pericarditis.
3. Valsalva manoeuvre.

Low jugular venous pressure (JVP) :

1. Dehydration (commonest).
2. After haemorrhage (hypovolaemia) or patient in hypovolaemic shock.
3. After massive diuretic therapy.

* JVP is increased in cardiogenic shock.

Points observed in neck vein at the bedside :

(A) Engorged or not.

(B) If engorged :

a) Pressure,

b) Pulsation (waveforms), and

c) Hepato-jugular reflux.

Importance of hepato-jugular reflux :

When firm pressure is applied on any part of the abdomen for 10 seconds, specially over the right hypochondrium, there is transient rise in JVP as the hepatic venous reservoir is compressed (the patient reclining at 45°). This is hepato-jugular reflux (often called abdomino-jugular reflux).

In health, significant alteration of JVP does not occur by this manoeuvre. A positive hepato-jugular reflux is defined by increase in JVP on 10 seconds firm abdominal compression, which shows rapid fall back of venous column by 4 cm on release of compression. The commonest cause of a positive reflux is right-sided heart failure. Its importance lies in :

1. To diagnose incipient (early stage) or overt right heart failure (CCF),
2. To differentiate between arterial and venous pulsation, and
3. To differentiate between obstructive and non-obstructive causes of engorged neck vein (negative hepato-jugular reflux is seen in SVC syndrome and Budd-Chiari syndrome).

Waves seen in neck vein :

Positive waves—a, c and v; actually, there are two positive waves (a and v) seen clinically as c-wave is small and rarely appreciated at the bedside. Negative troughs (waves)—x and y.

a-wave is absent in atrial fibrillation and v-wave (so called 'systolic wave') becomes very prominent in TI. Small x-descent in TI, and pominent x-descent in cardiac tamponade; slow y-descent in TS, and sharp y-descent is found in constrictive pericarditis.

Mechanism for production of different waves in neck vein :

'a' wave	—	Right atrial contraction. It is the most dominant wave in JVP.
'c' wave	—	Closure and bulging of tricuspid valve (according to few clinicians, it is due to transmitted carotid impulse).
'x' descent	—	Atrial relaxation with downward descent of tricuspid valve.
'v' wave	—	Passive right atrial filling during ventricular systole.
'y' descent	—	Right ventricular filling with atrial emptying.

* *a-wave coincides with S_r v-wave with S_2.*
x-descent follows S_r y-descent follows S_2.

What is giant a-wave (venous Corrigan) ?

When the right atrium contracts against outflow tract obstruction, giant a-wave is produced, e.g.,

1. Tricuspid stenosis,
2. Pulmonary hypertension, and
3. Pulmonary stenosis.

* Exaggerated a-waves are the hallmark of right atrial hypertrophy.

Cannon wave :

Huge pathological (i.e., very large) a-wave is known as cannon wave. It is seen when the right atrium contracts against closed A-V valve (i.e., tricuspid valve). It is commonly found in.

1. Regular— Nodal tachycardia, junctional rhythm.
2. Irregular— Complete heart block, classic AV dissociation with ventricular tachycardia.

Kussmaul's sign :

In normal healthy persons, the neck venous pressure falls (so, the height lessens) on deep inspiration due to sucking of blood into the right atrium. Reverse happens after deep expiration.

But in patients with constrictive pericarditis, cardiac tamponade (less common), severe right-sided heart failure, right ventricular infarction (produces decreased right ventricular compliance) and restrictive cardiomyopathy, there is paradoxical rise in JVP after deep inspiration due to non-accommodation of increased venous return to right side of the heart. This is Kussmaul's sign and is also known as venous pulsus paradoxus.

Why the neck vein is examined at 45° ?

Regardless of body position, the centre of the right atrium lies 5 cm below the sternal angle (the 'reference point'). When a person is lying flat, the jugular veins are seen distended in the neck. If he/she

is at 90° (sitting), the upper level of vein is never seen normally. But if the person reclines at 45 , the upper level of vein is just visible above the clavicle or invisible. So, if we see the pulsating venous column far above the clavicle at 45°, the JVP is said to be raised. It is why the neck veins are always examined at 45°. In the other way, **the patient should lie at 45° in order to standardise reading.**

At 45°, the vertical distance between the top of the oscillating venous column and the sternal angle is the jugular venous pressure (JVP) and is normally 3-4 cm. Thus, 3 cm + 5 cm = **8 cm of blood or H_2O is the normal venous pressure, right atrial pressure, JVP or CVP.**

How venous pressure is measured, at bedside ?

It is measured by the vertical height of internal jugular vein above the sternal angle. Clinically it is done with the help of two postcards (or scales); one postcard is placed vertically over the sternal angle and the other is placed horizontally from the top of the oscillating venous column upto the first postcard when the patient is reclined at 45°. The junctional point between the two postcards is marked and the vertical distance from this point to the sternal angle is measured, e.g., if it is seen to be 6 cm in a patient of CCF, the JVP of that patient will be 5 cm + 6 cm =11 cm of blood, i.e., JVP is raised.

Describe the neck vein in CCF :

a) Engorged and pulsalite.
b) JVP is raised (measure, if possible).
c) Waves are seen.
d) Hepato-jugular reflux is present.

* During elicitation of hepato-jugular reflux in a suspected patient of CCF, patient will C/O pain (as the liver is tender on palpation due to congestive hepatomegaly). Also look for bipedal oedema. These are indirect evidences in the examination hall.

What is Friedreich's sign ?

It is the rapid y-descent in the venous pulse seen in constrictive pericarditis and is due to rapid inflow of blood into the right ventricle as soon as the tricuspid valve opens.

Bedside diagnosis of constrictive pericarditis :

When acute fibrinous or serofibrinous pericarditis (i.e., from tuberculosis, bacterial infection or haemopericardium) heals and leads to obliteration of pericardial sac by granulation tissue, thick and fibrous pericardium encase the heart and the disorder is known as chronic constrictive pericarditis. It is diagnosed by :

1. Fatigue, dyspnoea on exertion, orthopnoea, loss of weight (symptoms).
2. Protuberant abdomen (ascites).
3. Peripheral oedema and systemic venous congestion.
4. Rapid, low volume pulse and pulsus paradoxus.
5. Elevated CVP with Friedreich's sign (sharp y-descent).
6. Kussmaul's sign.
7. Invisible or feeble apex beat with normal-sized heart; distant (or quiet) heart sounds.
8. Pericardial knock heard at lower left sternal border.
9. Congestive hepatomegaly with ascites; ascites > peripheral oedema.
10. Splenomegaly.

* The pathophysiology of clinical features in constrictive pericarditis are :

- 4, Ventricular filling (just like cardiac tamponade)—Kussmaul's sign, Friedreich's sign, pulsus paradoxus.
- Systemic venous congestion—T JVP, oedema, ascites and hepatomegaly.
- Pulmonary venous congestion—dyspnoea, orthopnoea (rare).
- 4. Cardiac output—fatigue, low volume pulse.

** One of the common D/D of constrictive pericarditis at the bedside is cirrhosis of liver.

*** **Pericardial knock** — This is an extra sound in early diastole and is probably due to restrictive effect of adherent pericardium on diastolic expansion of the ventricle.

Conclusion :

During examination of the neck veins in the examination hall, allways ask for 'back-rest'. If not supplied, support the patient's trunk on your left arm to make an angle of 45°.

Although the neck veins are engorged and pulsatile in biventricular failure, it is primarily a sign of right ventricular failure.

Case 49

SPIDER NAEVI

What are these ?

These are telangiectases that consist of a centrally dilated arteriole from which numerous small vessels radiate resembling the legs of a spider. Usually it is a sign of hepato-cellular failure.

Common sites :

In the upper half of thorax (necklace area) and back of upper chest commonly; face, forearms and dorsum of hands. Rarely, they are seen in mucous membrane of oral cavity and nose.

Method of demonstration :

The central arteriole (central prominence) is occluded by giving pressure with a pinhead or glass slide, and the response is immediate blanching of the whole naevus. If the pressure is released, the naevus goes back to its original shape and colour, which shows filling from the centre to the periphery.

Size of spiders :

From a pinhead to 0.5 cm in diameter. When it attains large size, it may be seen or felt to pulsate.

Other names of spider naevi :

Arterial spider, spider telangiectasis, spider angioma, vascular spider.

Clinical associations :

1. **Cirrhosis of liver, specially in alcoholics.**
2. Viral hepatitis (transient).
3. **During third trimester of pregnancy.**
4. **Occasionally, in children.**
5. **Sometimes, in thyrotoxicosis.**
6. In some healthy persons **(2%)—< 3** in **number, F > M.**
7. **Oestrogen therapy.**

Aetiopathogenesis :

Spiders are formed due to hyperoestrogenaemia (diminished hepatic clearance of precursor androstenedione results in increased peripheral conversion to oestrogen). It is known that oestrogen has a dilating effect on spiral arteries of endometrium and such a mechanism may be responsible for the development of cutaneous spiders. Now-a~days, it is said that the ratio of (high) oestrogen and (low) testosterone level is the main factor for production of spiders.

Differential diagnosis :

1. **Mosquito bite—The 'fresh' mosquito bite marks blanch like spiders. H/O using mosquito nets at night should be taken. Mosquito bite marks may be present anywhere in the body.**
2. **Hereditary haemorrhagic telangiectasis (HHT)—** *'Telangiectasia'* **are small dilated blood vessels which may be visible on the skin surface, particularly on the lips and** *usually blanch on pressure.* **Common sites of HHT are mucosal surfaces like tongue, lips, nose, palate, pharynx, oesophagus and stomach. It is generally connected with a single vessel. Telangiectasis may be seen in CREST syndrome.**
3. **Haemorrhagic spots—Petechiae and purpura never blanch on pressure.**
4. **Venous star—It is seen in persons with high venous pressure and never blanches on pressure. Common sites are back, legs, lower part of anterior chest wall and dorsum of foot. Here, the blood flows from the periphery to the central part in contrast to vascular spiders where blood flows from the centre to the periphery.**
5. **Campbell de Morgan's spots (cherry angioma)—These spots are very common in aged persons (size -1 to 2 mm in diameter), and are commonly seen in anterior abdominal wall and front of the chest. They do not blanch on pressure and are usually elevated from the skin surface.**

6) Rose spots—Seen in enteric fever, specially over abdominal skin; blanch on pressure.

Why the spiders are mostly seen in necklace area ?

It is said that spiders are seen in the area drained by superior vena cava (above the line joining both nipples). Actually, the basic cause is not known but it is expected that exposure of the necklace area to sunlight may damage the skin in such a way that appropriate internal stimulus may provoke the development of spiders in the said area. Experiment shows that people in the nudist colony having cirrhosis of liver show spiders distributed all over the body.

Draw inference if a previously seen spider disappears :

1. The hepato-cellular failure is corrected (good prognosis), or
2. The fall of blood pressure in a case of hepato-cellular failure (commonly due to fresh haematemesis or melaena) may be responsible for the disappearance of spiders (bad prognosis).

Conclusion :

One should search spiders meticulously in its specified area of distribution. Spiders are very often missed, if not careful. Confirm it by 'blanching response' after application of pressure by a pinhead.

Case 50

PALMAR ERYTHEMA

What is this ?

It is commonly seen that in a setting of hepato-cellular failure, the palms become bright red in colour (and also warm). Thus, other name of palmar erythema is 'liver palms'. The soles of the feet may be similarly affected.

Sites affected within the palm :

1. Thenar eminence,
2. Hypothenar eminence,
3. Pulp of the fingers, and
4. Bases of the fingers.

Method of demonstration :

Like the spider naevi, **palmar erythema blanches on pressure.** Here, a glass slide is used for application of pressure and the redness of palm reappears after release of pressure. In the absence of glass slide, press the patient's palm with your thumb.

* At times, the palm flushes synchronously with the pulse rate after being pressed by a glass slide.

Clinical associations :

1. Cirrhosis of liver.
2. In alcoholics.
3. Long-continued rheumatoid arthritis.
4. Pregnancy.
5. Thyrotoxicosis.
6. Chronic leukaemias.
7. Rarely, in some normal persons (familial).
8. Hyperdynamic circulation e.g., high fever.

* Remember, *polycythemia* causes redness of the palm and sole; so, search for plethoric face, dusky-red oral mucous membrane and suffused conjunctiva.

Aetiopathogenesis :

Same as spider naevi, or a non-specific change indicative of hyperdynamic circulation.

S ***kin and appendicular changes in hepato-cellular failure :***

1. Spider naevi.
2. Palmar erythema.
3. Bleeding manifestations— Due to coagulation disorder (hypoprothrombinaemia) and defects in the platelet (number and functional abnormalities) petechiae, purpura, ecchymosis may be seen.
4. 'Paper money skin'— It is usually seen in upper arms and also observed in the common sites for spider naevi. These are nothing but small blood vessels and resemble silk threads in United States' dollar bills.
5. White spots — Seen in arms and buttocks (demonstrated after cooling the skin). These are forerunners of a spider.
6. White nails (leuconychia) — This is due to opacity of the nail-bed. All the fingers may be affected but thumb and index fingers are specially involved. Hypoalbuminaemia is thought to be responsible for production of white nails (thus, sometimes seen in nephrotic syndrome).
7. Gynaecomastia— May be unilateral and is developed as a result of hyperoestrogenaemia. It is said that spironolactone therapy is the commonest cause of gynaecomastia in a patient of cirrhosis of liver.

8. Clubbing— Specially seen in biliary cirrhosis.
9. Jaundice—In case of severe jaundice, skin may become yellow. Jaundice gives some guide to the severity of hepato-cellular failure.
10. Diffuse pigmentation of the body, particularly over the face.
11. Dupuytren's contracture, specially in alcoholics.
12. Scanty pubic and axillary hair.
13. Xanthoma (in palmar creases) or xanthelasma (around eyes) are seen in primary biliary cirrhosis.

Case 51

EXAMINATION OF THE HANDS

Points to note in hands :

(A) Shake hands with the patient (to assess surface temperature, skin and the grip strength) may reveal :

a) Warm and moist hand—thyrotoxicosis, type II respiratory failure, pyrexia (only warm).
b) Cold and moist hand—anxiety neurosis; moist and doughy handshake—acromegaly; cold and clammy hand with peripheral cyanosis—shock.
c) Cold and dry hand—myxoedema: only cold hand—low cardiac output (e.g., heart failure), hypothermia, Raynaud's phenomenon.
d) Patient may not relax his hand after handshake—myotonia.
e) Weak grip strength—weakness of the small muscles of hand or weakness of flexor muscles.
f) Rough, thick palm—phrenoderma (vitamin A or essential fatty acid deficiency), arsenic poisoning, tylosis (hyperkeratosis of palm often associated with oesophageal carcinoma), psoriasis, verruca vulgaris, multiple corn or callosities.
g) Shake hand producing pain — rheumatoid arthritis.

(B) Colour changes :

a) Anaemia or pallor (the palmar creases become pale when the Hb level is < 7 g/dl).
b) Jaundice—mainly the palms, dorsum rarely.
c) Cyanosis—tips of fingers, nail-beds and palm.
d) Palmar erythema.
e) Janeway's lesion (non-tender maculopapular lesion present in thenar eminence in SBE).
f) Carotenaemia (orange-yellow or lemon-yellow colour of palm).

(C) Finger deformities :

a) Arachnodactyly (long slender, spider-like fingers)—Marfan's syndrome, hypogonadism.
b) Polydactyly (extra finger)—Laurence-Moon-Biedl syndrome, associated with VSD.
c) Syndactyly (joined fingers)—Poland's syndrome, underlying congenital heart disease.
d) Clinodactyly (incurved finger)—commonly affects the little finger in Down's syndrome.
e) Sclerodactyly (tight skin over the phalanges)—scleroderma.
f) Broad hand with thick, large, square-tip fingers (spade-shaped hand)—acromegaly.
g) Bradydactyly (short fingers)—Down's syndrome. Turner's syndrome, mucopolysaccharidosis.

(D) Clubbing :

(E) Wasting of the small muscles of hand : leprosy, MND, syringomyelia, rheumatoid arthritis etc.

(F) Pulsation :

a) Capillary pulsation (see the section on 'Aortic incompetence').
b) Digital artery pulsation (see the section on Aortic incompetence).
c) Pulse—give the classical description (some clinicians may not like to include 'examination of pulse' under examination of the hand).

(G) Tremor:

a) Static tremor.
b) Action tremor.
c) Intention tremor, and
d) Flapping tremor

} read the section on 'Tremor'

(H) Swellings :

a) Osier's node (tender papule mainly In the pulp of fingers)—seen in SBE.

b) Heberden s node—hard bony nodules seen at the dorsal aspect of distal interphalangeal (DIP) joints in osteoarthritis.

c) Bouchard s node hard bony nodules seen at the dorsal aspect of proximal interphalangeal (PIP) joints in osteoarthritis.

d) Rarely, rheumatoid nodules or nodule formation in leprosy.

e) Gouty tophi—over dorsal aspect of PIP and DIP joints.

f) Calcinosis—scleroderma.

g) Oedema over dorsum of the hand. Ganglion, neurofibroma, lipoma are of surgical interest.

(I) Hand deformities :

a) Spindle-shaped fingers (due to swelling of PIP joints)—rheumatoid arthritis, scleroderma.

b) Swan neck deformity (hyperextended PIP joints and flexed DIP joints)—rheumatoid arthritis.

c) 'Boutonniere' or button-hole deformity (flexed PIP joints and hyperextended DIP joints) — rheumatoid arthritis, and is just reverse of swan neck deformity.

d) Volar subluxation with radial deviation at wrist and ulnar deviation of digits—rheumatoid arthritis.

e) Z-deformity of thumb (hitch-hiker's thumb)—rheumatoid arthritis.

f) Swelling of DIP joints only—osteoarthritis, psoriatic arthropathy or scleroderma. In psoriasis, telescoped phalanges may produce shortening of fingers with gross impairment of function.

g) Dupuytren's contracture (flexion contracture of ring and little fingers due to thickening, fibrosis and shortening of ulnar side of palmar fascia). The causes are :

a) Repeated trauma to palm.
b) Alcoholic cirrhosis.
c) Phenytoin sodium therapy[7] in epileptics.
d) Working with vibrating tools.
e) Manual workers (gardener).
f) Diabetes mellitus.
g) Peyronie's disease.
h) Idiopathic.

h) Surgical deformities like club hand, Madelung's deformity, mallet finger etc.

i) Claw hand—read the section on 'Claw hand'.

j) Main d' accoucheur—metacarpophalangeal (MCP) joints are flexed, the PIP and DIP joints are extended with opposition of the thumb. It is commonly seen in tetany and also known as carpal spasm. The method of demonstration of carpal spasm by sphygmomanometer is known as Trousseau's sign. [There is another Trousseau's sign in internal medicine which is characterised by migratory thrombophlebitis in a patient with carcinoma of the pancreas.]

k) Jaccoud s arthritis rheumatic arthritis usually heals without deformity; very rarely, minor deformity of hand (marked ulnar deviation of MCP joints due to subluxation) may persist. Rarely, SLE and Sjogren's syndrome may develop into this type of defomity.

1) Short 4th and 5th metacarpals in pseudohypoparathyroidism ('dimpling sign'),

m) Wrist drop—Radial nerve palsy.

* Armand Trousseau (1801-1867) was Physician, Hotel Dieu, Paris, France who actually died from pancreatic carcinoma.

(J) Nail changes :

a) Pitting (thimble) nails—psoriasis, atopic eczema, alopecia areata etc.

b) Beau's line transverse ridges develop after recovery from any febrile illness, in zinc deficiency.

c) Horder s line or splinter haemorrhage (linear longitudinal haemorrhage underneath the nails)—SBE, trauma, trichinosis, systemic vasculitis etc.

d) Mees line transverse white stria of 1-2 mm width appears above lunula (the white part at base of nail) in arsenic poisoning.

e) Koilonychia 'spoon-shaped nail' is seen in chronic iron deficiency anaemia.

f) Onycholysis—candidiasis, ringworm infection, psoriasis, lichen planus, trauma etc.

g) Missing nail in nail-patella syndrome — presents with (hereditary) nephrotic syndrome.

h) Nail-fold thrombi— scleroderma and other collagen vascular diseases (vasculitis).

i) Green nail— severe pseudomonas infection.

j) Blue lunula (azure arcs) CuS04 poisoning, Wilson's disease, zidovudine therapy, cyanosis and ochronosis.

k) Red lunula—seen in CCF.

1) Black nail—hair dyes, Peutz-Jeghers syndrome.

m) Brown nail—hydroquinone-induced.
n) Grey-black nail—melanoma.
0) Bitten nails—persons with anxious personality.
p) Fungal infection of nails (onychomycosis)—candidiasis, ringworm (tinea unguium),
q) Shiny nails— indirect evidence of pruritus.
r) Leuconychia (white nails)— seen in hypoalbuminaemic conditions like cirrhosis of liver, nephrotic syndrome, severe malnutrition, kwashiorkor and protein-losing enteropathy; also known as Terry's nail.
s) Yellow nails in 'yellow nail syndrome'; other components of the syndrome are lymphoedema of the extremities and pleural effusion,
t) Half-and-half nail (proximal half is white and distal half is pink) — seen in uraemia; also known as Lindsay nail.
u) Platynychia (flat nails) — Hereditary, iron deficiency anaemia,
v) Pterygium unguis (loss of skin fold around nail) - seen in lichen planus.
w) Paronychia or whitlow (i.e., swollen and inflamed nail-bad)—working in wet conditions, diabetes, repeated trauma,
x) Hypertrophy of nails—chronic fungal infection.
y) Absence or atrophy—nail-patella syndrome, congenital ectodermal defect,
z) Subungual fibroma—observed in tuberous sclerosis.
a) Brittle nail—fungal infection, iron deficiency anaemia, psoriasis, peripheral vascular disease.

(K) **Skin changes** (mainly dorsum of the hand) :

a) Hyperpigmentation.
b) Hypopigmentation.
c) Ichthyosis (fish skin).
d) Palmar xanthoma—seen in familial hyperlipidaemia.
e) Lilac-coloured knuckles in dermatomyositis (Gottron's sign).
f) Petechiae, purpura, ecchymosia.
g) Rash (from diseases or drugs).

(L) Miscellaneous :

a) Nicotine staining in right index and middle fingers in chronic smoker.
b) Single palmar crease (simian crease) in Down's syndrome.
c) Involuntary movements like chorea, athetosis, minipolymyoclonus etc.
d) Power of individual small muscles should be tested; sensory loss, if any, should be detected.
e) Trophic ulcers—vasculitis, Raynaud's disease, neurological disorders (e.g., syringomyelia).
f) Movement at different joints— to find out any restriction of movement.
g) Loose-jointedness—tested by passive hyperextension of fingers, and even the hyperextended fingers may touch the forearm. It is commonly seen in osteogenesis imperfecta, Marfan's syndrome, Ehlers-Danlos syndrome and in some normal persons.
h) Pulp atrophy, telangiectasia, digital infarction, digital ulceration, digital gangrene, triphasic colour response of Raynaud's phenomenon—in scleroderma or SLE (features of vasculitis).
1) Test for finger-flexion jerk and Hoffman's sign (see the sections on 'Jerks and clonus'), grasp reflex, and test for myotonia (tapping the thenar eminence).

Examination of the hand in SLE and scleroderma :

Read the individual sections.

Examination of the hand in leprosy :

1. Read the skin changes in TT and LL varieties from the section on 'Leprosy'.
2. Claw hand with wasting of the small muscles of hand (commonly ulnar clawing affecting fourth and fifth fingers), and
3. Trophic changes — Dry and rough skin, brittle nails, loss of hair, digital ulceration and gangrene, tapering and conical fingertips with trophic ulcers, and loss of distal digits.

Examination ***of the hand in rheumatoid arthritis :***

1. Spindle-shaped fingers (swelling of PIP joints, DIP joints unaffected).
2. Swelling of the wrist and different joints (MCP and PIP) in the hand— No swelling at DIP joints.

3. Swan neck deformity (described earlier)— Due to disruption of the volar plate of PIP joints, often with associated rupture of the insertion of flexor sublimis.
4. 'Boutonniere' or button-hole deformity (described earlier)— Chronic synovitis of PIP joints lead to rupture of central slip of extensor tendon (looks like gap of button hole) allowing protrusion of joint between two lateral slips of extensor tendon.
5. Volar subluxation with radial deviation at wrist and ulnar deviation of digits— Due to bowstring action of displaced extensor tendons.
6. Z-deformity of thumb— Due to muscle wasting, rupture of tendon and weakened joint capsule.
7. Opera glass hand appearance—Mutilating arthropathy.
8. Palmar erythema (seen in long-continued rheumatoid arthritis).
9. Joint movements are painful and restricted.
10. Grip-strength is poor.
11. Wasting of the small muscles of hand— Chiefly due to disuse atrophy; carpal tunnel syndrome, vasculitis, mononeuritis multiplex or rarely prolonged use of corticosteroids may be attributed.
12. Digital infarction, digital gangrene, splinter haemorrhage.
13. Nail-fold thrombi.
14. Carpal tunnel syndrome (with evidance of wasting of thenar muscles).
15. Rheumatoid nodule (rare in hands).
16. Trigger finger (flexion deformity from which the finger can be extended only by force).
17. Rupture of the extensor tendons of ring and little fingers resulting in 'dropped finger' (rare).
18. Purpuric rash (thrombocytopenia due to Felty's syndrome).
19. Raynaud's phenomenon.
20. Pallor (anaemia) in severe active deforming disease.

'Vasculitis' and its characteristic skin changes :

Vasculitis is the necrotising inflammation of blood vessels. Endothelial oedema and proliferation with haemorrhage contribute to the occlusion of the vascular lumen and subsequent ischaemic changes along with organ damage. Vasculitis is commonly due to infections, drugs (e.g., allopurinol), immunological disorders (e.g., SLE) and malignant diseases. It is classified according to the size of vessel involved (Chapel Hill Consensus Conference Classification).

Classification :

(A) Large-vessel vasculitis : Giant cell arteritis (temporal arteritis) and Takayasu's arteritis (aortic arch syndrome or pulseless disease).

(B) Medium-sized vessel vasculitis : Polyarteritis nodosa and Kawasaki disease (mucocutaneous lymph node syndrome).

(C) Small-vessel vasculitis of arterioles, capillaries and venules : Wegener's granulomatosis, microscopic polyangiitis, Churg-Strauss syndrome, leucocytoclastic vasculitis (hypersensitivity vasculitis), Henoch-Schonlein purpura and essential mixed cryoglobulinaemia.

* SLE, Behcet's disease, scleroderma, polymyositis or dermatomyositis, SBE, rheumatoid arthritis and paraneoplastic syndromes are also associated with vasculitis.

** ANCA-associated vasculitis are Wegener's granulomatosis, Chmrg-Strauss syndrome and microscopic polyangiitis. ANCA stands for antineutrophil cytoplasmic antibody.

Dermatological manifestations ;

1. Large arteries - Digital gangrene.
2. Small arteries -
   a) Palpable purpura.
   b) Urticarial rashes (tender).
   c) Morbilliform eruptions (look like measles rashes).
   d) Maculopapular eruptions.
3. Arterioles and very small arteries -
   a) Digital infarction.
   b) Digital ulceration.
   c) Nail-fold thrombi.
   d) Vesicular or bullous lesion.
   e) Splinter haemorrhage.
   f) Raynaud's phenomenon.
   g) Pulp atrophy.
   h) Necrotic ulcer.

*** Vasculitis in collagen vascular diseases is responsible for these characteristic skin lesions in hands.

Case 52

WASTING OF THE SMALL MUSCLES OF HANDS

What are the smalll muscles of hand ?

(A) Thenar muscles -

1. Abductor pollicis brevis,
2. Flexor pollicis brevis, and
3. Opponens pollicis.

(B) Hypothenar muscles -

1. Abductor digiti minimi,
2. Flexor digiti minimi, and
3. Opponens digiti minimi.

(C) Adductor pollicis.

(D) Palmaris brevis (superficial muscle of hand).

(E) Palmar and dorsal interossei.

(F) Lumbricals.

Nerve supply of these muscles :

I. Median nerve supplies,
   1. Thenar muscles.
   2. Two lateral lumbricals.
   3. Sometimes, 1st dorsal interosseous muscle.

II. Ulnar nerve supplies,
   1. Hypothenar muscles.
   2. All palmar and dorsal interossei.
   3. Two medial lumbricals.
   4. Two heads of adductor pollicis.
   5. Medial head of flexor pollicis brevis (thenar muscle).
   6. Palmaris brevis.

N.B. : Ulnar nerve supplies all the small muscles of hands excepting the thenar muscles and the two lateral lumbricals.

How to diagnose wasting of the small muscles of hands ?

1. Flattening of palm due to wasting of thenar and hypothenar muscles.
2. Prominent knuckles and bony prominences.
3. Flexor-extensor tendons will stand out.
4. The interosseous space in the dorsum of hand will be hollowed or depressed due to wasting of interossei and lumbricals.

Test of interossei and lumbricals :

Test the patient's ability to flex all of his MCP joints and to extend all the DIP joints of hand. Remember, the palmar interossei are also adductors and dorsal interossei are abductors of fingers.

Test of 1st dorsal interosseous — Place the flat of the hand with seperated fingers over a table and ask the patient to abduct his index finger against your resistance. The muscle can be seen and felt to contract.

How to test these small muscles ?

I. Abductor pollicis brevis— The patient is asked to abduct his thumb in a plane at right angles to the palmar aspect of index finger, against resistance offered by your thumb. The muscle can be felt to contract. This muscle is affected first in carpal tunnel syndrome.

II. Adductor pollicis— Give the patient a book ('book test') and ask him to grasp it firmly between the thumb and other fingers of both hands. In a normal subject the thumbs remain straight whereas in lesions of the ulnar nerve, the terminal phalanx of the thumb of the affected hand will be flexed (Froment's sign).

III. Opponens pollicis— Ask the patient to touch the tip of all the fingers with his thumb. You can oppose the movement with your thumb or index finger, or you can ask the patient to swing the thumb across the palm.

Common causes of wasting of the small muscles of hand :

THE SMALL MUSCLES OF THE HAND ARE SUPPLIED BY C_8 AND T, SEGMENTS OF THE SPINAL CORD. The causes of wasting, therefore, include lesions in the lower motor neurones at any point between these spinal segments and the muscles, together with certain other conditions in which primary muscle degeneration or reflex muscular wasting occurs.

a) Lesion in the anterior horn cells—

1. Acute anterior poliomyelitis.
2. Motor neurone disease (amyotrophic lateral sclerosis).
3. Syringomyelia.
4. Intramedullary tumours like glioma, ependymoma.

b) Lesion in the nerve roots (anterior roots) or radiculopathy—

1. Extramedullary lesion, e.g., patchy arachnoiditis.
2. Cervical spondylosis.
3. Neuralgic amyotrophy.
4. Leptomeningitis (syphilitic) - Rare.

c) Lesion in the spinal nerve — Klumpke's paralysis from birth injury.

d) Lesion in the brachial plexus —

1. Cervical rib.
2. Thoracic inlet syndrome.
3. Trauma.
4. Metastasis.

e) Lesion in the median and ulnar nerve —

1. Injury or trauma.
2. Peripheral neuropathy from leprosy, lead neuritis etc.
3. Peroneal muscular atrophy (usually follows wasting of legs and feet).
4. Carpal tunnel syndrome.

f) Muscle disease and others —

1. Distal myopathy of Gower's.
2. Myotonia dystrophica, rarely.
3. Volkmann's ischaemic contracture.
4. Peripheral vascular disease.

g) Reflex wasting (due to disuse atrophy] — Rheumatoid arthritis, post-paralytic, post-fracture.

h) Systemic wasting — Malignancy, tuberculosis, diabetes mellitus, thyrotoxicosis, AIDS.

N.B. : Five common causes of wasting of the small muscles of hands are,

1. Leprosy.
2. Motor neurone disease.
3. Rheumatoid arthritis.
4. Poliomyelitis.
5. Syringomyelia.

Wasting of small muscles of both upper and lower extremities :

1. Charcot-Marie-Tooth disease and other motor peripheral neuropathies.
2. Distal myopathy of Gower's.
3. Distal spinal muscular atrophy.
4. Post-G.B. syndrome.
5. Myotonia dystrophica.
6. Rheumatoid arthritis.

How to diagnose cervical rib clinically ?

The patient may complain of pain along the ulnar border of forearm and hand. Horner's syndrome may be evident. Adson's test confirms the presence of cervical rib.

Adson's test — This test is also positive in thoracic inlet syndrome. The examiner feels the radial pulse from the back of the sitting patient. Now the patient is asked to take a deep breath and to turn the face (not flexion) towards the affected side. In the presence of cervical rib, there will be obliteration or diminution of pulse.

Identification points for an aetiological diagnosis :

1. History from childhood -
   a) Poliomyelitis.
   b) Klumpke's paralysis.
2. If complains of neck pain -
   a) Cervical spondylosis.
   b) Intra- or extramedullary tumour.
   c) Cervical rib (may be associated with bony lump).

3. If associated with fasciculation and brisk tendon reflexes in upper extremities — Amyotrophic lateral sclerosis.
4. Associated with painful swelling of joints - Rheumatoid arthritis.
5. If there are **trophic changes** in hand-
   a) Leprosy.
   b) Syringomyelia.
   c) Cervical rib.
6. Examine the elbow for signs of old injuries like excessive callus, cubitus valgus deformity (for nerve injury) or for **thickened ulnar nerve** (leprosy).
7. If there is :
   a) Absence of sensory loss - MND.
   b) Dissociation of sensory loss - Syringomyelia.

N.B. : Wasting of the small muscles of hands may be associated with claw hand.

Case 53

Claw Hand

Describe the claw hand deformity ;

Claw hand or 'main-en-griffe' is a condition where the metacarpophalangeal (MCP) joints are hyper-extended. and the PIP and DIP joints are flexed.

We know that the lumbricals are the main flexors of the first phalanx and the interossei are the sole extensors of the middle and distal phalanges. When the lumbricals are paralysed, there is hyperextension at MCP joints (by unopposed action of extensor digitorum) and when the interossei are paralysed, the PIP and DIP joints are flexed. So **claw hand is produced by the paralysis of interossei and lumbricals.**

Enumerate the common causes of claw hand :

The interossei and lumbricals are supplied by the T_t segment of the spinal cord through the ulnar and median nerves. So any lesion of T_t segment or of the nerves will produce the claw hand deformity.

1. **True claw hand :**
   a) Combined lesion of ulnar and median nerves by injury or leprosy (tuberculoid variety) will produce claw hand. It is obvious that only ulnar nerve affection will produce ulnar claw hand.
   b) Cervical rib (by friction against the lowest trunk of the brachial plexus) or thoracic inlet syndrome.
   c) Klumpke's paralysis.
   d) Motor neurone disease (progressive muscular atrophy, amyotrophic lateral sclerosis), syringomyelia, intramedullary tumours etc.

N.B. : Actually the diseases which produce wasting of the small muscles of hands may show some degree of claw deformity.

2. **Mimicking (pseudo) claw hand :**
   These are basically surgical conditions like :
   a) Dupuytren's contracture.
   b) Volkmann's ischaemic contracture.
   c) Post-burn contracture.

Aetiological differentiation by sensory functions :

1. Motor neurone disease, either amyotrophic lateral sclerosis or progressive muscular atrophy — No sensory loss.
2. Injury to the ulnar and median nerve -
   a) Practically, all modalities of sensation in the palm and the dorsum of hand are lost.
   b) In the dorsum of hand, a small area escapes sensory loss (over the base of thumb and the first interosseous space) as it is supplied by radial nerve.
3. Leprosy — Patchy and distal sensory involvement (peripheral neuropathy).
4. Syringomyelia — Dissociated sensory loss, i.e., loss of pain and temperature sensation with preservation of fine touch sensation.

Hand feels very cold : what will you think ?

It is the vasomotor insufficiency produced by the presence of cervical rib. thoracic inlet syndrome or due to severe form of vasculitis. The affected hand feels colder than the normal side, and becomes pale when elevated and blue when dependent for some time.

What is wrist drop ?

(A) Definition . Paralysis of the extensors of wrist. There will be difficulties in extension of wrist and fingers (finger drop). In an attempted extension of fingers, there will be flexion of MCP joints and extension of interphalangeal joints due to unopposed action of lumbricals and interossei.

(B) Method of testing : Ask the patient to make a fist and try to flex the wrist forcibly against patient s eflort to maintain the posture. Normally, it is almost impossible to flex the wrist overcoming the patient's wrist extensors. But in wrist drop, patient's wrist will be very easily flexed by the examiner.

(C) Aetiology :

1. Radial nerve palsy (trauma, Saturday night palsy or compression at axilla),
2. Chronic lead poisoning, and
3. Other peripheral neuropathies (including mononeuritis multiplex).

Identification points for an aetiological diagnosis :

Same as described in the section on 'Wasting of the small muscles of hands'.

*** Never forget to palpate the ulnar nerve in the elbow (e.g., leprosy) and to examine for trophic changes in the fingers in a patient with claw hand or wasting of the small muscles of hands.**

Case 54

GYNAECOMASTIA (GYNAECOMAZIA)

What is gynaecomastia ?

This is a condition where the male breast looks like that of a female. On inspection, even the nipple and areola assume a feminine appearance. Early gynaecomastia is characterised by proliferation of both the fibroblastic stroma and the duct system. Eventually the number of ducts decrease. It is usually painless but elderly person with gynaecomastia may have little pain. Gynaecomastia results from an increase in the oestrogen/androgen ratio.

What is lipomastia ?

Lipomastia or 'false' enlargement of breast (found in obestity) is best palpated with flat of the palm while gynaecomastia is best appreciated with fingers. In lipomastia, no breast tissue is there but only mammary fat is present. One should remember that no breast tissue is palpable in normal man.

* Pseudogynaecomastia is found in lipomastia, neurofibromatosis, cold abscess or malignancy.

** Painful gynaecomastia : Puberty or adolescence, drug-induced (e.g., spironolactone) and cirrhosis of liver.

Examination of the patient :

1. Examine the breast tissue first with flat of the palm, then with fingers to confirm the glandular tissue. Tenderness indicates rapid growth.
2. Age of the patient.
3. Unilateral or bilateral.
4. **Stature** of the patient and signs of eunuchoidism.
5. H/O taking drugs (produce gynaecomastia) or alcoholism.
6. H/O mumps or castration.
7. Examine both the **testes.**
8. Examine the **liver, spleen,** and search for any hepato-celullar failure.
9. Look for the signs of carcinoma of the lung in the form of SVC obstruction, collapse of the lung.
10. Examine the spine for any tenderness or gibbus (caries spine).
11. Signs of leprosy nodules, hypopigmented spots in skin or thickened peripheral nerves etc.
12. P/R examination to exclude carcinoma of the prostrate for which stilboestrol is advised.

Drugs ***producing gynaecomastia :***

1. Oestrogens.
2. Digitalis (due to oestrogen-like effect).
3. Spironolactone (reduces serum testosterone level)— Often the breasts are tender.
4. Cimetidine (anti-androgenic).
5. INH (cause not known).
6. Methyldopa (cause not known).
7. Marijuana, cannabis or heroin abuse (associated with high oestrogen and low testosterone).
8. Busulphan, phenothiazines, tricyclic antidepressants, ketoconazole, diazepam, phenytoin.

Explanation of your method of examination :

1. Age of the patient— Newborn, adolescence and old age may have physiological gynaecomastia.
2. Stature of the patient— Klinefelter's syndrome and hypogonadism may have tall stature.
3. Drugs, mumps orchitis, castration— all produce gynaecomastia.
4. Examination of testes :

" a) Testicular tumour— Asymmetry of testes, smooth or lobulated (e.g., Leydig cell tumour).

b) Klinefelter's syndrome— Small and firm testes.

c) Cirrhosis of liver with hepato-cellular failure— Small and soft testes.

d) Lepromatous leprosy— Atrophied small and soft testes.

* By Prader orchidometer, testicular size < 3 cm indicates atrophy (normal adult size is 3.5-5.5 cm). Pre-pubertal males have small and rubbery testes.

5. Examination for hepatosplenornegaly :

a) Cirrhosis of liver.

b) Leprosy.

c) Acute leukaemia (leukaemic deposits in breast may mimic gynaecomastia).

6. Facies :

a) Puffy, bloated and congested— SVC obstruction due to carcinoma of the lung.

b) Leonine facies— Lepromatous leprosy.

c) Hepatic facies— Cirrhosis of liver with hepato-cellular failure.

d) Rarely true hermaphroditism.

7. Spine— Cold abscess may form behind the breast tissue in a patient suffering from caries spine (abscess coming in front through muscle plane). It is not true gynaecomastia and usually produces unilateral painless swelling of the breast.
8. Examination of the skin is done for hypopigmented anaesthetic spots, fall of body hairs and eyebrows, and subcutaneous nodules for lepromatous leprosy which causes gynaecomastia. Sparse pubic hair is common in hypogonadism.
9. P/R examination — If the patient gives history of taking stilboestrol (probably suffering from carcinoma of the prostrate).
10. Unilateral or bilateral— Gynaecomastia may be unilateral to start with. Klinefelter s syndrome and physiological gynaecomastia are bilateral.

Common causes of gynaecomastia :

1. Physiological— Newborn, adolescence and old age.
2. Klinefelter's syndrome (47, XXY).
3. Hepato-cellular failure commonly from alcoholic cirrhosis.
4. Drug-induced.
5. Bronchogenic carcinoma.
6. Lepromatous leprosy.
7. Leukaemic deposits in breasts (not true gynaecomastia).
8. Starvation; recovery from wasting diseases.
9. Hypogonadism due to any cause (secondary testicular failure from orchitis or castration).
10. Obesity.
11. Oestrogen-secreting testicular (Sertoli cell tumour) or adrenal tumours.
12. Hyperthyroidism, renal diseases, hyperprolactinaemia, local trauma.

How to proceed for diagnostic evaluation ?

After proper clinical evaluation :

1. A careful drug history is taken.
2. Measurement and examination of testis (if both are small and firm, a karyotype is indicated; if testes are asymmetric, an evaluation for testicular tumour is warranted).
3. Liver function tests.
4. Blood for testosterone, LH, FSH. oestradiol, prolactin and HCG estimation.
5. 24-hours urinary 17-ketosteroid estimation.

Explanation : If there is,

- LH T and tesosterone 4- = testicular failure.
- LH J. and testosterone i = most likely there is increased primary oestrogen production (e g Sertoli cell tumour of the testis). &
- LH T and testosterone T = androgen resistance or gonadotropin-secreting tumour.
- T Urinary 17-ketosteroid = feminising adrenal tumour.

Work up is necessary where,

a) Drug history is negative.
b) Breast is tender with rapid growth.
c) Breast mass > 4 cm in diameter.

How do you like to treat your patient :

1. Reassurance for pubertal gynaecomastia (may presist for 2-3 years).
2. Treatment of the cause like leprosy, hepato-cellular failure, withdrawing the offending drug etc.
3. Painful gynaecomastia who are not candidates for other therapy — Treatment with antioestrogens, e.g.. tamoxifen (20 mg/day) should be tried. Aromatase inhibitors (testolactone can be effective). Patients with testicular insufficiency may be benefited by androgen replacement therapy.
4. Indication for surgery (simple mastectomy or liposuction) —
   (i) Severe psychological problem.
   (ii) Cosmetic problem.
   (iii) Continued growth.
   (iv) Suspicion of malignancy.

* In gynaecomastia, the risk of developing carcinoma of the breast is very very rare.

Case 55

Hypo- or Hyperpigmentation

Common causes of hyperpigmentation

1. Familial, racial.
2. Sunburn.
3. Addison's disease.
4. Haemochromatosis.
5. Peutz-Jeghers syndrome.
6. Chronic kala-azar.
7. Cirrhosis of liver.
8. * Drug-induced.
9. Pellagra.
10. Chronic arsenical poisoning.
11. Facial pigmentation in chloasma, SLE.
12. Porphyria (cutanea tarda).
13. Freckles, lentigos (post-sunexposure).
14. Urticaria pigmentosa.
15. Acanthosis nigricans.
16. Melanoma.
17. Scleroderma.
18. Paraneoplastic syndrome.

* Clofazimine (reddish-brown), busulphan, oral contraceptive pills, bleomycin, phenothiazines, heavy metals (arsenic, gold), tetracycline, amiodarone, minocycline, psoralens.

** Abnormal increased pigmentation is known as hyperpigmentation which may be localised (commonly due to dermatological disorders) or generalised (commonly due to systemic diseases).

Causes of hypopigmentation :

Read the section on 'Pityriasis versicolor'.

Sites examined for increased pigmentation :

1. Face.

2. Inside the oral cavity, specially buccal mucosa (commonly seen in Addison's disease, malabsorption syndrome, chronic cachexia, Peutz-Jeghers syndrome and haemochromatosis), palate and tongue.
3. Palmar creases.
4. General skin surface (pressure points; normally pigmented areas like areola, genitatia, sun-exposed areas; recent scars); palms and soles.

Pigmentation in chronic kala-azar :

Due to increased black pigmentation, the disease is known as kala-azar (the Hindi version of 'black' is 'kala'). Hyperpigmentation occurs as a result of disturbance in melanin metabolism. Pigmentation is commonly seen **around the mouth, on the temple and forehead.**

Pigmentation in Addison's disease :

Pigmentation in Addison's disease is due to increased pituitary MSH and ACTH secretions. At first, there is tanning noticed following sun exposure. Afterwards, there is increased pigmentation **at pressure points** (elbow), in the **areas normally pigmented** (areola, genitals, knuckles, palmar creases, old and new scars) and also in the **mucous membranes** (mouth and genitals). Rarely, there may be areas of vitiligo.

Features of addison's disease :

Commonly the patient is female and suffers from :

1. Asthenia (glucocorticoid 4)
2. Hypotension (mineralocorticoid 4)
3. Hyperpigmentation (ACTH t)
4. Anorexia, malaise, weight loss.
5. Decreased body hairs.
6. Hyperkalaemia.
7. Hypoglycaemia.

I V cardinal manifestations J

8. Nausea, vomiting.
9. Chronic fatigue syndrome
10. Acute adrenal crisis.

* Thomas Addison (1793-1860) was a physician in Guy's Hospital, London, UK.

Differentiation between primary and secondary adrenocortical hypofunction :

Glucocorticoids, mineralocorticoids and androgens are low in both the conditions.

In primary (Addison's disease) cases, there are features of,

1. Pigmentation,
2. Absence of hypothyroidism and hypogonadism, and
3. High plasma ACTH level.

In secondary hypofunction (in involvement of pituitary or hypothalamus), there are :

1. Absence of pigmentation.
2. Presence of hypothyroidism and hypogonadism, and
3. Low plasma ACTH level.

What is haemochromatosis ?

It is an iron-storage disorder with inappropriate increase in intestinal iron absorption. There is deposition of iron in parenchymal cells with eventual tissue damage. The disease is clinically manifested by,

1. Excessive generalised skin pigmentation (due to increased melanin and iron deposition; melanin gives the typical bronzing or slaty grey hue of the skin).
2. Diabetes mellitus (bronze-diabetes).
3. Arthropathy.
4. Cardiac involvement — CCF, cardiomyopathy.
5. Hepatic involvement (cirrhosis or hepato-cellular carcinoma) with hepato-cellular failure.
6. Loss of libido and testicular atrophy.

* The **pigmentation is more pronounced** on face, neck, lower forearms, dorsa of hands, lower legs, genitals and in scars.

Treatment of haemochromatosis :

1. Phlebotomy. "
2. Iron chelation by desferrioxamine.
3. Treatment of CCF, hepato-cellular failure, diabetes mellitus etc.

How a haemochromatosis patient dies ?

1. CCF.
2. Hepato-cellular failure.
3. Hepato-cellular carcinoma (in treated cases).

What is Peutz-Jeghers syndrome ?

In this syndrome, there are numerous polyps seen in small and large intestine. The polyps show leatures of hamartoma on histological section. Chance of malignant transformation is very rare. The syndrome is associated with mucocutaneous pigmentation and rarely, germinal cell tumour of ovary. Commonly it gives rise to **perioral pigmentation.**

What is chloasma or melasma ?

A common hypermelanosis of young females (very rare in males) frequently precipitated by pregnancy (chloasma gravidarum) or by prolonged use of oral contraceptive pills (also known as 'mask of pregnancy). The pigmentation is generally seen on malar prominences and bridge of the nose (bilateral and frequently symmetrical); also seen in forehead and moustache area. It is a benign condition.

What is acanthosis nigricans ?

It is a thickened, velvety hyperpigmentation predominantly of the flexures (e.g., sides of neck, axilla). In majority, it is associated with obesity who is also having underlying insulin resistance. It can be a reflection of internal malignancy (e.g., G. I. tract), or endocrinopathy such as acromegaly, Cushing's syndrome or insulin-resistant diabetes mellitus.

Causes of 'plethoric face' ?

1. Chronic alcoholism.
2. Cushing's syndrome.
3. Polycythemia.
4. SVC syndrome.
5. Chronic cor pulmonale.
6. Carcinoid syndrome.

* See the section on 'Mitral stenosis' for causes of 'malar flush'.

Case 56

SCABIES

Aetiology and transmission :

This contagious disease is caused by the mite Sarcoptes scabiei contracted through close personal contact or contaminated clothings. After copulation the fertilised female mite excavates a burrow in the stratum corneum. From egg — nymphs hatch out — mature into adult males and females on the surface of the skin — mate, and reinvade the skin of same or other person.

Doctors, paramedicals and inmates of mental hospials are at particular risk to have scabies.

Characteristic distribution :

1. Webs of fingers, wrist, ULNAR BORDER OF FOREARM and ARM, anterior axillary folds.
2. Front of chest, areola in female breast, UMBILICAL and PERIUMBILICAL REGION, belt line and lower abdomen.
3. SHAFT OF PENIS, SCROTUM, vulva, folds of buttock, GROIN, MEDIAL ASPECT OF THIGH, knee, front of ankle, webs of toes.

Spread is by prolonged close contact, sharing of clothings and beddings, and by sexual exposure.

An imaginary circle intersecting the main sites of involvement—axilla, elbow flexures, wrist, hand and groins has long been called the 'circle of Hebra'.

Which part of body is usually spared ?

Face and scalp (face and scalp may be affected in infants).

How to diagnose scabies ?

1. Specific lesion with typical distribution.
2. Burrow.

3. Nocturnal pruritus (intractable).
4. H/O affection of several members of the family at a time (as scabies is highly contagious).
5. Demonstration of mite Sarcoptes scabiei from the burrow (confirmation of diagnosis).

* Itching from scabies also increases after a hot bath.

Most pathognomonic lesion of scabies :

Burrow or Tunnel (linear or curved) is the most pathognomonic and characteristic lesion.

This is an irregular or linear skin-coloured ridge caused by tunneling of the mite in the stratum corneum layer of skin. It is seen in areas mentioned under distribution of lesion. The burrow can be identified by 'ink method' (touched with a drop of ink) when the burrow absorbs the ink and is high-lighted as a dark line.

Commonest lesion in scabies :

Papulo-vesicles.

Describe the different lesions :

1. Papules (itchy and red).
2. Vesicles,
3. Pustules,
4. Impetigo,
5. Burrow, and
6. Indurated nodules.

Mode of spread :

1. Very close and intimate contact with scabies patient (e.g., sharing the bed)
2. Overcrowding.
3. Poverty.
4. Poor hygiene.
5. Sexual promiscuity.

Why there is nocturnal itch ?

When the patient retires in warm bed, the mites start moving within the burrow.

Non-itchy scabies :

1. Norwegian scabies, or
2. Scabies with psychiatric illness.

What ***is Norwegian (crusted) scabies ?***

Widespread hyperkeratotic and crusted lesions of scabies (extremely infectious) resulting from infestation with thousands or millions of mites, and are present in :

1. Mentally retarded patients (e.g., schizophrenia, Down's syndrome),
2. Patients with poor cell-mediated immunity (e.g., lepromatous leprosy, AIDS),
3. Severely debilitated patient (e.g., severe malnutrition), and
4. Immunocompromised states e.g., diabetes mellitus, glucocorticoid therapy, organ transplantation.

Lesions ***present in face :***

1. Neonates, or
2. Norwegian scabies.

D/D of scabies :

1. Pediculosis corporis.
2. Atopic dermatitis.
3. Papular urticaria.
4. Dermatitis herpeteformis.

Mention some itchy lesions in skin :

1. Scabies.
2. Dermatitis herpetiformis.
3. Urticaria.
4. Lichen planus.
5. Insect bite.
6. Psoriasis.
7. Eczematous and atopic dermatitis.
8. Pediculosis.
9. Ringworm.
10. Seborrhoeie dermatitis.
11. Drug eruption.
12. Xerosis (dry skin).

Medical causes of generalised pruritus :

1. Obstructive jaundice (medical or surgical).
2. Diabetes mellitus.
3. Chronic renal failure.
4. Polycythemia vera (specially after a hot bath).

5. Systemic mastocytosis.
6. Lymphoma (Hodgkin's disease commonly) and leukaemias; multiple myeloma.
7. Carcinoid syndrome.
8. Thryotoxicosis.
9. Drugs like cocaine, morphine.
10. Psychogenic.
11. Drug reaction, pregnancy (last trimester).
12. HIV infection.
13. Neurosis.
14. Old age, specially in winter; dry skin.
15. Malignancy.

Complications of scabies :

1. Pyoderma, specially impetigo and ecthyma.
2. Acute glomerulonephritis— Due to sensitisation by nephritogenic strains of streptococci (most dangerous).
3. Eczema— Sensitization from parasites or from prolonged itching.
4. Rarely, sulphur dermatitis after initiation of treatment.
5. Secondary lymphadenitis.

* Always search for signs of scabies infection in a patient with acute glomerulonephritis.

Management :

1. At first, the treatment of secondary infection is done by antibiotics. Patient should cut his nails short and his daily used articles (towel, pillow, bed-sheet) should be kept separate and laundered properly. Antihistaminics and calamine lotion may be necessary to control itching. Asymptomatic family members should be treated simultaneously.
2. Instructions to the patient— Start with a bath and dry thoroughly afterwards. Apply the medicine thinly but thoroughly over the whole body from chin downwards (both involved and uninvolved areas). It is better to rub the medicine into the skin. Treatment is best done at night before going to bed. Avoid touching mouth or eyes with hands. Change the undergarments and sheets on the next day and launder them. The patient may take a bath in the morning with soap and water.

   A single overnight application with permethrin is sufficient. In pregnant women and infants, sulphur ointment, permethrin and crotamiton are preferred. Benzyl benzoate needs 3 applications at 12-hourly interval without intervening bath. Sulphur ointment is used once daily for consecutive 3 days. Do not repeat the drugs unless instructed.
3. Medicines used :
   a) Benzyl benzoate lotion (25%) or emulsion (child 12.5%)
   b) Unguentum sulphur (adult 10%, child 5%)

   } apply for consecutive 2 nights

   c) Gamma benzene hexachloride (1%) as lotion or cream.
   d) Crotamiton (10%) as lotion or cream.
   e) Mitigal - 10% solution in liquid paraffin.
   f) Monosulfiram (25%; tetmosol)— used as soap or lotion.
   g) Topical thiabendazole.
   h) Permethrin (5%) — used as cream; single application, may be repeated after 1 week.
   i) Malathion (0.5%) lotion.
   j) Ivermectin (200 (ig/kg, orally in single dose; adult dose in 12 mg) effectively treat scabies.
   Two or more doses at 1 week apart are required for crusted scabies.

* *Itching in scabies* is due to development of sensitization to some of the products (e.g., saliva-scabin) of the mite.

How to diagnose (confirm) scabies under the microscope :

A selected lesion is scraped by sterile needle or scalpel 6-7 times and the scrapings are transferred to a glass slide on which 10% KOH solution has already been kept. The slide is then examined with low power magnification for mites, eggs or faecal pellets.

Case 57

PSORIASIS

Describe the lesion :

1. Red, scaly papules or plaques.
2. Sharply defined.
3. Covered with varying amount of loosely adherent silvery-white scales.
4. Present over knees, elbows, hands, lumbosacral region, scalp, rarely in palms and soles (i.e., MAINLY OVER THE EXTENSOR SURFACES).
5. The lesions are pruritic.
6. Localised lesion to sites of trauma **(Koebner's phenomenon).**
7. Scraping the scales leaves behind punctate bleeding spots **(Auspitz's sign)** - DIAGNOSTIC.

* Usually in young adults, both sexes with genetic predisposition; unpredictable course with relapses and remissions; worse in winter season; no available test to predict outcome.

What is psoriatic arthropathy ?

Arthritis occurs in 5-10% patients of psoriasis. The five distinct clinical forms of arthritis are :

1. Asymmetrical oligoarthritis (35%).
2. Symmetrical seronegative arthritis (30%)—'rheumatoid arthritis pattern'.
3. Arthritis of **distal interphalangeal joint** (15%)—most characteristic.
4. Sacroiliitis and/or spondylitis (15%).
5. Arthritis mutilans — Severe destructive arthritis with deformities of hands and feet (5%).

There may be associated nail changes; rheumatoid factor is negative. Arthritis is commonly associated with HLA-B27 allele. Arthropathy may progress to deformity of fingers (arthritis mutilans may lead to 'telescoped' phalanges).

Clinical forms of psoriasis :

1. Plaque psoriasis— Commonest lesion; coin shaped (numular);
2. Guttate—Raindrop-like, small-sized.
3. Palmo-plantar— Often with sterile pus in palms and soles.
4. Erythrodermic form— Exfoliative dermatitis; may be fatal.
5. Genital— Penis and vulva affected.
6. Flexural (intertriginous)— Instead of extensor surfaces, the flexural sites are involved.
7. Rupioid— Hyperkeratotic, cone-shaped.
8. Scalp psoriasis— Fairly common; not associated with alopecia.
9. Generalised pustular— Known as 'Von Zumbusch' psoriasis; rare but very serious.

* *Exfoliative dermatitis (erythroderma)* is common in psoriasis, contact dermatitis, atopic dermatitis, pityriasis rubra pilaris, drug-induced (e.g., suphonamides, dapsone) and systemic diseases (lymphoma/carcinoma/mutiple myeloma/HIV infection).

Describe the nail changes in psoriasis :

Nail changes are often associated with arthropathy and may reflect the severity of the disease.

1. Pitting (thimble pitting),
2. Subungual hyperkeratosis,
3. Destruction of nail plates,
4. Discolouration (yellow-brown) of nail plates, and
5. Onycholysis (separation of nail from nail-bed) and horizontal ridging.

* Onycholysis is the most characteristic nail lesion in psoriasis.

Causes of pitting nail :

1. Psoriasis.
2. ***Eczema.***
3. Alopecia areata.

Diseases with positive Koebner's phenomenon :

1. Psoriasis.
2. Lichen planus.
3. Viral ***wart.***

Describe macule and papule ?

(A) Macule - Localised area of change of colour in skin, neither raised nor depressed (non-palpable lesion). A big macule is known as 'patch'.

(B) Papule - Raised from skin surface and generally < 5 mm in size; big papule is known as 'plaque'.

* Vesicle is small (< 5 mm), usually clear fluid-containing elevated lesion whereas bulla are large vesicle (> 5 mm). Nodules are solid elevation in skin of > 5 mm in diameter.

Histology of skin lesion in psoriasis :

1. Parakeratosis (immature cells in stratum comeum) } reflecting increase in skin turnover
2. Acanthosis (hyperplasia of stratum malpighii).
3. Loss of granular cell layer.
4. Dilated and tortuous blood vessels in dermal papillae.
5. Rarely, neutrophilic abscesses (microabscesses of Munro) in the homy layer.

Investigations you like to perform : ■

1. Blood for TC, DC to exclude superadded infections.
2. Skin scrapings and nail clippings may be examined for tinea (for differential diagnosis from fungal infection).
3. Rheumatoid factor - Negative (for differential diagnosis of arthropathy).
4. X-ray of affected joints may show 'pencil-in-cup' deformity.
5. Skin biopsy may be done (seldom necessary because the clinical picture is very characteristic).

Management :

The treatment is concerned with control rather than cure and is divided into four categories :

- Topical agents (emollients)—'weak' tar, corticosteroids, vitamin D., agonists or dithranol preparations.

e PUVA or PUVB therapy.

- Systemic agent—retinoids (tazarotene), immunosuppresive drugs (cyclosporin A) or newer biological agents (infliximab).

e Intensive treatment with topical agents and UV-rays under medical supervision (No. 6 below).

1. Coal-tar preparations with keratolytics (salicylic acid 3-5%) as an ointment.
2. Dithranol (0 1 %) cream— used locally; it inhibits DNA synthesis.
3. Corticosteroid ointment may be used locally (systemic corticosteroid is strictly contraindicated).
4. PUVA therapy (photochemotherapy) — 'P' stands for Psoralen taken orally and UVA stands for ultra violet light-A, i.e., of long-wavelength (320 - 400 nm). Oral psoralen is followed 2 hours later by UVA therapy; 2-4 sittings / week are necessary (total 10-20 sittings). UVB is helpful in winter season.
5. Topical preparations of retinoic acid derivatives (01 %) may be tried in localised plaques.
6. Tropical therapy with ultraviolet rays :
   a) Goeckerman regimen—tar plus UVB.
   b) Ingram regiment—dithranol plus UVB.
7. Methotrexate— Used in severe erythrodermic form, arthropathy or resistant cases. Methotrexate is used once weekly in a dose of 5 mg BDPC (used over 24 hours), and is supplemented by folic acid therapy (5 mg, once weekly except the day of methotrexate).
8. Calcipotriol (vitamin D_3 analogue)— Applied twice daily, not exceeding 100 g/week.
9. NSAID for arthropathy.
10. Nail dystrophy is resistant to treatment.

* Oral corticosteroid may be used judiciously in refractory psoriasis, psoriatic arthropathy and erythrodermic form. Flexural psoriasis is treated with calcitriol (vitamin D , analogue) and 0.1 % tacrolimus ointment. Resistant cases may be treated with cyclosporin A, acitretin or hydroxyurea. TNF-a blockers or biologies (infliximab, etanercept, efaluzumab) are now being tried with success.

** UVC : Wavelength 10-290 nm (does not reach earth), UVB : 290-320 nm. UVA : 320-400 nm, visible white light we see : 400-700 nm, infrared rays (primarily evoke heat) > 700 nm.

Conclusion :

Always examine the nails and joints in a patient of psoriasis. Psoriasis does not affect the mucous membrane. One should not forget to examine the elbows, knees, back of the trunk and scalp.

Arachnodactyly – long and slender fingers, compared with a normal-sized hand

Rheumatoid nodule on extensor surface of upper part of forearm

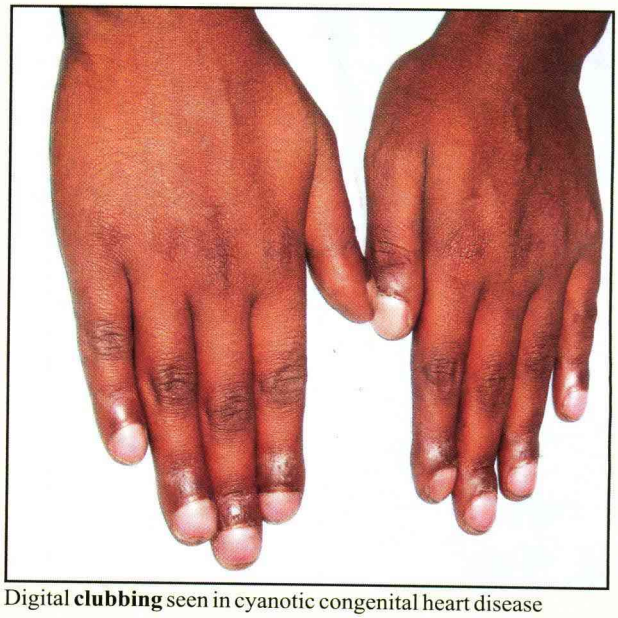

Digital **clubbing** seen in cyanotic congenital heart disease

Rheumatoid arthritis hand characterized by synovial swelling at the wrist, swelling of MCP and PIP joints, Z-deformity of thumb, and swan neck deformity of fingers with mild ulnar deviation of hand

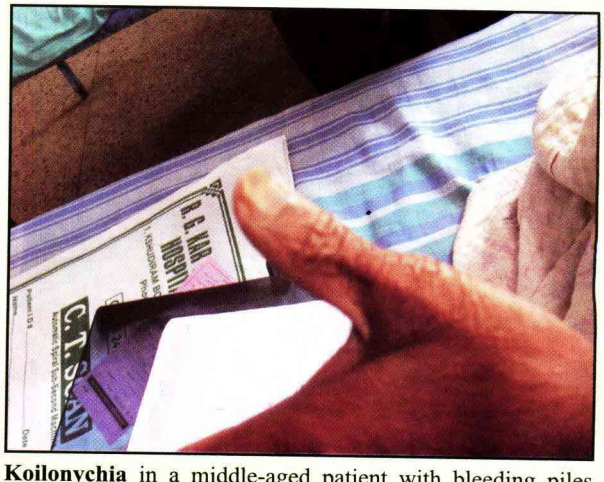

Koilonychia in a middle-aged patient with bleeding piles (resulting in chronic iron deficiency anaemia)

A case of **meningitis** on the day of admission with **discharging right ear**

Bilateral partial ptosis (right > left) in **myasthenia gravis**

Squint developed as a result of left-sided **VIth nerve palsy.** Here, it is a false localizing sign due to raised intracranial tension

Gowers' sign in Duchenne type of muscular dystrophy

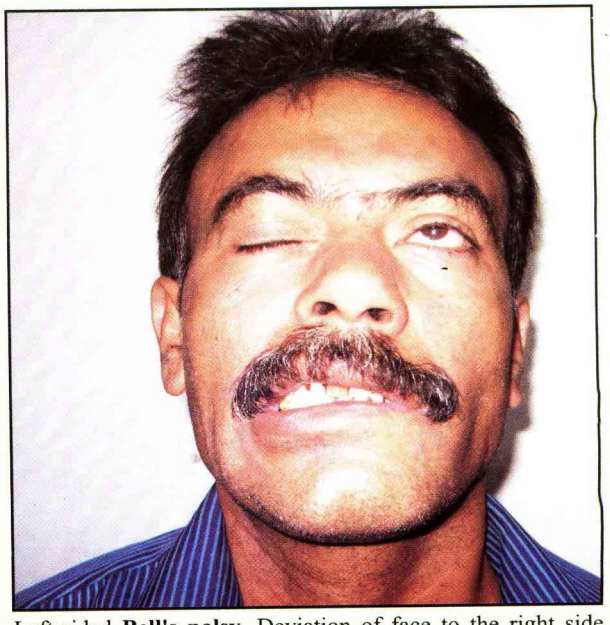

Left-sided **Bell's palsy**. Deviation of face to the right side occurs on showing the teeth as well as Bell's phenomenon is noted on forced closure of eyes

Case 58

PITYRIASIS VERSICOLOR (TINEA VERSICOLOR)

Characteristics :

1. Caused by Malassezia furfur (M. furfur is possibly the parasitic form of a common saprophytic yeast, often called Pityrosporum orbiculare).
2. Occurs in warm and humid climates; a relatively common condition affecting young adults.
3. Well-defined, hypopigmented small macules with fine branny scales (the lesion is of various size, shape and colour).
4. Generally non-itchy.
5. Many small spots may coalesce and form a large depigmented spot.
6. Classical sites are front of the chest, back of the chest, sides of neck, upper arm and face.
7. Sweating aggravates the condition; diabetes mellitus and pregnancy may be predisposing factors.
8. Asymptomatic except the cosmetic problem.

* The fungal hyphae and budding yeast may be seen in the scraped scales when treated by 10% KOH solution and seen by light miscroscopy: on inspection under Wood's lamp, it gives yellow fluorescence.

D/D of hypopigmented (hypomelanotic) spots :

1. Tuberculoid leprosy (test for touch sensation and examine for thickened nerve).
2. Vitiligo (may be idiopathic, sometimes associated with autoimmune diseases).
3. Pityriasis alba (found in the face in children; probably infective; asymptomatic, remits spontaneously).
4. Post-burn (past H/O burn) or post-inflammatory.
5. Tuberous sclerosis (H/O convulsions, low intelligence and adenoma sebaceum in face).
6. Prolonged chloroquine therapy (H/O prolonged chloroquine intake, e.g.. rheumatoid arthritis, SLE).

* Others ; pityriasis versicolor, psoriasis, albinism, nevus depigmentosus, piebaldism and idiopathic guttate hypomelanosis.

Common scaly lesions in skin :

1. Psoriasis.
2. Pityriasis rosea.
3. Seborrhoeic dermatitis.
4. Lichen planus.
5. Certain eczema.
6. Exfoliative dermatitis (erythroderma).
7. Ringworm.
8. Ichthyosis.

What is ringworm ?

Skin infection in ringworm is caused by different dermatophytes (fungi) like Trichophyton, Epidermophyton or Microsporum. The lesion may be single or multiple, small or large, usually circular (ring-like, hence known as ringworm) with papulo-vesicular scaly active border, itchy with central clearing, spread peripherally and heals with hyperpigmentation. The prefix tinea (which indicates ringworm) follows the affected region of the body like tinea corporis (body), tinea cruris (thigh and buttocks), tinea capitis (scalp), tinea pedis (feet), tinea manuum (hand), tinea barbae (beard) and tinea unguium (nail).

Diagnosis is done by demonstration of hyphae on examination of skin scrapings, hairs or nail clippings after dissolving in a drop of 10-20% KOH solution for several hours, and examined under light microscope. Treatment is done by local application of antifungal agents (miconazole, econazole, clotrimazole, tolnaftate, Whitfield ointment etc); lotions and powders are preferred for intertriginous and hairy (scalp) areas. Systemic antifungal antibiotic like griseofulvin (10 mg/kg/day, after meals in twice daily dose for several weeks) is used in extensive lesion and in affection of scalp, nail and bearded area. Griseofulvin-resistant cases may be treated by oral ketokonazole (200 mg once or twice daily). Itraconazole (100-200 mg/day), fluconazole (150 mg/week) or terbinafine (250 mg/day) orally may be given for 4-8 weeks.

* Tinea pedis = athlete's foot, and tinea cruris = 'Dhobi' itch.

Treatment of pityriasis versicolor :

1. Maintenance of good personal hygiene.
2. Sodium thiosulphate (25% aqueous solution) once daily for 3 weeks used locally.

3. Selenium sulphide (2-5%) Apply at night and wash-off in the following morning; for 4 weeks.
4. Topical tolnaftate (1%), clotrimazole, miconazole (2%), econazole, ketoconazole (2%) may be tried — Apply twice daily for 10 days.
5. Retinoic acid (0 025%) cream may be of some help.
6. Azoles Oral ketoconazole 200 mg OD/BD, or oral itraconazole 100 mg, BD is used for 1 week in resistant cases. Ketoconazole shampoo may be tried.

Conclusion :

Mention the finding of pityriasis versicolor in long/short case, if present.

Case 59

HAEMORRHAGIC SPOTS

What are these ?

These are red, blue or black spots in the skin deep to the epidermis. As they contain extravasated blood, they do not disappear on application of pressure by a pinhead, glass slide (diascopy) or on stretching the skin of the affected areas.

How to classify haemorrhagic spots ?

The arbitrary classification goes like :

1. **Petechiae** - 1-2 mm in diameter (i.e., pinhead-size, punctate or tiny).
2. **Purpura** - a bit larger, 2-5 mm in diameter.
3. **Ecchymosis (bruise)** - large confluent (> 5 mm) purpuric lesions.
4. **Haematoma** - large haemorrhages in the skin with surface elevation (fluctuant collection).

Petechiae and purpura are collectively known as ***'purpuric spots'.*** Day by day, there is progressive colour changes in haemorrhagic spots.

Differential diagnosis :

1. Telangiectasia - small, dilated blood vessels visible on skin surface, specially on the lips.
2. Mosquito bite marks.
3. Spider naevi.
4. Cherry angioma or Campbell de Morgan's spot.
5. Drug rash (H/O offending drug intake, often blanches, may be itchy).

How to differentiate haemorrhagic spots from others ?

Telangiectasia, spiders, fresh mosquito bite marks blanch on application of pressure given by a pinhead or glass slide, and the colour returns on releasing the pressure. **Haemorrhagic spots never blanch on compression (identification point).**

Significance of haemorrhagic spots :

Haemorrhagic spots may be due to (A) and/or (B) and/or (C) mentioned below :

(A) Thrombocytopenia (quantitative defect)— Either due to diminished production or increased destruction of platelet (e.g., idiopathic thrombocytopenic purpura or immune thrombocytopenic purpura [ITP]).

(B) Vessel wall abnormalities, vasculitis or increased capillary fragility— Seen in Henoch-Schonlein purpura (HSP), scurvy, uraemia, ageing etc.

(C) Platelet functional (qualitative) defect—Thrombasthenia or Glanzmann's disease (defect in platelet aggregation), after use of drugs like aspirin or phenylbutazone.

Causes of non-thrombocytopenic purpura :

(A) Vessel wall abnormalities, e.g.,

1. Infection— Meningococcus, viral infection, septicaemia.
2. Henoch-Schonlein purpura (HSP) or allergic purpura.
3. Hereditary haemorrhagic telangiectasis (HHT).
4. Drugs— Penicillin, sulphonamides, corticosteroids.

5. Senile purpura.
6. Purpura simplex (devil's pinches).
7. Cushing's syndrome.
8. Scurvy.
9. Paraproteinaemias.
10. Vasculitis.
11. Uraemia.
12. Purpura fulminans.
13. 'Easy bruising syndrome' (benign disorder)

(B) Platelet functional defects (defects in platelet adhesion, aggregation or granule release).

* In (A) : BT — Normal or increased; platelet count — Normal.
In (B) : BT — Increased; platelet count — Normal.

Diagnosis of thrombocytopenia from history :

Apart from easy bruisability and haemorrhagic spots in the skin (petechiae, purpura or ecchymosis), the patient gives H/O spontaneous bleeding from nose (epistaxis) and gums (mucous membrane), haematuria, melaena or menorrhagia.

Importance of splenomegaly with purpuric spots :

1. Acute leukaemias.
2. SLE, SBE.
3. Lymphomas.
4. Blast crisis of CML and CLL.
5. ITP (10% cases only)—splenomegaly does not favour the diagnosis of ITP.
6. Myelofibrosis.
7. Hypersplenism due to any cause.

Laboratory tests of ITP :

1. Low total platelet count (normal platelet count is 1.5 lacs-4 lacs/ mm^3). Peripheral blood smear may show large platelets.
2. *Prolonged bleeding time (BT) with normal coagulation time (CT).*
3. Antiplatelet antibodies may be found in blood.
4. To evaluate the secondary causes of ITP—serology for hepatitis C, HIV infection and ANF for SLE are done.
5. Bone marrow examination reveals megakaryocytes in normal or increased numbers with normal morphology in a hypercellular marrow. Sometimes, there are increased vacuolisation and diminished number of granules in the megakaryocytes.

* Normal BT is 2.5-10 minutes (Ivy) and normal CT is 9-15 minutes (glass tubes).

** Bleeding time (BT) is a sensitive measure of platelet number as well as function.

Characteristics of HSP (anaphylactoid purpura) :

1. A self-limiting vasculitis which often occurs after upper respiratory tract infection. It usually affects children and young adults.
2. The purpuric rashes are urticarial (palpable and itchy) and at times bilaterally symmetrical.
3. The rashes are usually present in buttocks, extensor surfaces of arms and lower legs; face and trunk spared—some purpuric rash coalesce and become necrotic.
4. HSP is often associated with heamaturia and proteinuria (focal segmental protiferative glomerulonephritis), arthralgia or arthritis, and colicky abdominal pain.
5. The coagulation profile (BT and CT) remains normal.

* Thrombocytopenia = flat purpura, and vasculitis = raised purpura.

Probable causes of palpable purpura :

(A) Vasculitis due to any cause—HSP, polyarteritis nodosa, leucocytoclastic vasculitis etc.
(B) Infective emboli—meningococcaemia, disseminated gonococcal infection, measles, septicaemia.

* Palpable purpura are raised from surface, present in buttocks and extensor surfaces, and often pruritic.

Demonstration of Hess' capillary fragility test :

It is a test for diagnosis of increased capillary fragility (e.g., dengue fever) or immune thrombocytopenic purpura (ITP).

The procedure goes like this -

1. Blood pressure cuff is wrapped in upper arm and pressure is raised. The pressure is maintained halfway between systolic and diastolic BP for 5 minutes.
2. ^be^°W the elbow J°int a circle of 1" diameter is drawn on the anterior aspect of upper forearm. The haemorrhagic spots already present within the circle are noted.
3. Normally after application of pressure by BP cuff, upto 10 new haemorrhagic spots may appear. But m pathological states (mentioned above), more than 20 new spots (diagnostic) may appear within the circle after deflation of BP cuff.

This test may be negative in mild to moderate thrombocytopenia but is positive in severe thrombocytopenia (ITP). This test is also known as TOURNIQUET TEST.

Cause ***of sudden death in thrombocytopenia :***

Sudden massive haemorrhage in any vital organ like intracerebral haemorrhage may be fatal in a patient of thrombocytopenia.

Thrombocytosis and thrombocythemia :

(A) Thrombocytosis — Platelet > 4 lacs/ mm^3 which is a temporary elevation e.g., splenectomy, severe bleeding etc. Thrombocytosis is regarded as part of acute phase reaction.

(B) Thrombocythemia — Platelet > 8 lacs / mm^3 which is a sustained elevation. It is regarded as a myeloproliferative disorder.

* Platelet count < 1 lac / mm^3 is known as thrombocytopenia.

** 1 unit of platelet transfusion raises the count by 10000/mm^3.

Purpura in young and elderly :

(A) Young ITP, HSP, SLE, drug-induced, acute leukaemias, infections (e.g., meningococcus).

(B) Elderly—Senile purpura, leukaemia, drug-induced, scurvy, paraproteinaemias.

Drugs causing thrombocytopenia :

1. Sulphonamides.
2. Penicillin.
3. Cyclophosphamide.
4. Thiazides.
5. Quinine.
6. Carbamazepine.
7. Aspirin.
8. Heparin.

Common medical causes of purpura :

\ ITP
2. Acute leukaemias.
3. Aplastic anaemia (no splenomegaly).
4 Drugs (no splenomegaly).
5 SLE
0 Lymphoma.
7 Hepato-cellular failure.
8 SBE

Causes of gum bleeding :

1. Gingivitis.
2. ITP.
3. Acute leukaemias.
4. Aplastic anaemia.
5. Scurvy.
6. Hemophilia.
7. Anticoagulant therapy.
8. Vincents infection.

Causes of gum hypertrophy :

1. Poor oral hygiene.
2. Phenytoin therapy in epileptics.
3. Pregnancy
4 Scurvy
5 Acute monocytic leukaemia.
6 Idiopathic familial fibromatosis.
7 Nifedipine or amlodipine therapy
8. Histiocytosis X disease.

Medical causes of epistaxis :

1. Systemic hypertension.
2. Bleeding disorders (ITP, haemophilia)/anticoagulant therapy/DIC; acute leukaemias.
3. Vasculitis.
4. High altitude.

5. Rendu-Weber-Osler disease (hereditary haemorrhagic telangiectasis).
6. Uraemia.
7. Kala-azar, malaria, enteric fever, infectious mononucleosis, rheumatic fever, diphtheria.

Purpuric eruption with pyrexia :

1. Dengue.
2. Infective endocarditis.
3. Meningococcaemia.
4. Purpura fulminans.
5. Viral haemorrhagic fever.
6. Gram-negative septicaemia.
7. Rocky Mountain spotted fever.
8. Disseminated gonococcal infection
9. Cutaneous small vessel vasculitis.
10. Rat-bite fever.

Safe analgesics in purpura :

Codeine and paracetamol have no effect on platelet number and function.

Critical platelet count :

It is 20000/ mm^3. Below this level, spontaneous haemorrhage in any vital organ (e.g., intracerebral haemorrhage) or anywhere in the body may endanger the life of the patient. These patients require immediate temporary support with platelet or fresh blood transfusion. Recently, haematologists opined that the level may be near about 10000/mm^3 to have risk of internal bleeding.

Sites and organs to be examined in a case of purpura :

Read the 'Scheme of examination' from 'Lymphoreticular system'.

What do you mean by 'bleeding disorders' ?

Bleeding disorders are usually due to one of the following abnormalities :

a) Coagulation disorders.
b) Platelet disorders (number and / or function defect), and
c) Vessel wall abnormalties.

A detailed history, meticulous physical examination and few initial screening tests are required to evaluate bleeding disorders.

(A) Coagulation disorders (e.g., haemophilia, Christmas disease) : Only in males (haemophilia), family history +ve (due to X-linked inheritance, there is oblique transmission, i.e., uncles and nephews may be the sufferer), life-long history; bleeding into viscera, retroperitoneum. muscles (calf, psoas, tongue) and joints (e.g., knee haemarthrosis) are characteristic; purpura is rare; bleeding from nose, mouth, G. I. tract, urinary tract, wounds or in the subcutaneous tissue may occur. Bleeding starts several hours after trauma or surgery (H/O induced and prolonged bleeding), and is notorious for persistence (not profuseness); local pressure is ineffective; absence of splenomegaly, normal BT with prolonged CT, while platelet count remains normal. Acquired coagulation disorder may result from vitamin K deficiency or oral anticoagulant therapy.

(B) **Platelet disorders** : H/O drug intake (specially, aspirin), and bleeding occurs characteristically from mucous membrane (gum), nose (epistaxis), skin (petechiae, purpura, bruises), buccal mucosa, and per vaginum; bleeding may occur from G. I. tract, CNS or superficial wounds; bleeding happens to occur immediately after trauma or surgery, and local pressure is effective to stop bleeding; may have splenomegaly, increased BT with normal CT, while low platelets in thromocytopenia and normal plalelets in thrombasthenia. Qualitative disorders of platelet are adhesion defect (von Willebrand's disease, Bernard-Soulier syndrome) and aggregation defect (Glanzmann's thrombasthenia, uraemia, aspirin therapy).

(C) **Vessel wall abnormalities** : Consider age of the patient (common in old age), petechiae/purpura, recurrent bleeding at a single site, bleeding occurs immediately after trauma or surgery, and local pressure is effective. There is absence of splenomegaly, normal or elevated BT with normal CT, and normal platelet count. See page 368 for causes of vessel wall abnormalities.

* (B) and (C) are commonly characterised by easy bruising and spontaneous bleeding.

Conclusion :

In the presence of purpuric spots, one should examine the patient for 'blanching reaction' which is always absent here. Always perform the Hess' capillary fragility test in a suspected patient of ITP.

Case 60

LEPROSY

Definition :

This is a chronic granulomatous disease caused by Mycobacterium leprae (a gram positive, acid- and alcohol-fast bacillus) which principally attacks the skin, peripheral nerves and nasal mucosa. It is also known as **Hansen's disease.**

What are the different forms ?

1. Two polar forms are—
   (i) Lepromatous (LL), and
   (ii) Tuberculoid (TT).
2. Borderline or dimorphous leprosy—
   (i) Borderline tuberculoid (BT).
   (ii) Borderline (BB).
   (iii) Borderline lepromatous (BL).
3. Indeterminate leprosy (I)—
   (i) Non-classifiable early lesion.
   (ii) Transforms into any polar form, or
   (iii) May spontaneously remit.

* Principally, there are two main forms : polar forms and borderline leprosy.

What do you mean by LL and TT forms ? ***Multibacillary or paucibacillary*** ?

Lepromatous leprosy (LL) means :
(i) Highly bacillated (multibacillary),
(ii) Low resistance (impaired cell-mediated immunity), and
(iii) Systemic infectious form.

Tuberculoid leprosy (TT) means :
(i) Non-infectious (paucibacillary),
(ii) High resistance (i.e., high cell-mediated immunity), and
(iii) Localised disease.

(A) Multibacillary : BB, BL and LL.
(B) Paucibacillary : I, BT and TT.

* Multibacillary—has 6 or more skin lesions which may have bacilli.

Paucibacillary—has 5 or less skin lesions with no bacilli.

Describe the skin lesion of TT variety :

1. Solitary lesion or a couple of lesions.
2. Macular or raised as plaques, or as rings with flat centre (central healing).
3. Sharply defined or circumscribed.
4. *Hypopigmented.* dry, scaly lesion.
5. *Hypoaesthetic,* hypohydrotic (diminished sweating) and hypotrichotic (loss of hair).
6. Present anywhere in the body specially in arms, buttocks, legs and face.

PLUS

The nerve twig or the peripheral nerve supplying the skin lesion may be thickened, e.g.,

a) Great auricular nerve across the sternomastoid muscle (in the posterior triangle) in neck.
b) Ulnar nerve at elbow.
c) Median nerve at wrist.
d) Radial cutaneous nerve at wrist.
e) Common peroneal nerve at the neck of fibula.
f) Posterior tibial nerve around medial malleolus.
g) Sural nerves at the lateral part of ankle.

N.B. : It is compulsory to test the touch sensation in the skin lesion in all suspected patient of TT variety. Always palpate the nerves proximal to the skin lesion. One should look for the great auricular nerve in the neck (by turning the head to the opposite side, the nerve stands out), the ulnar nerve in the funny bone or the common peroneal nerve at the neck of fibula. Test the nerves for thickening, tenderness, and its motor as well as sensory functions.

Describe the skin lesion of LL variety :

1. Hypopigmented macules, plaques or *nodules* (may be bilaterally symmetrical) widely scattered in the body. *Gradually the skin becomes infiltrated and thickened.*

2. Ill-defined (with margins that merge imperceptibly with normal skin).
3. The surface of the lesion is smooth, shiny but without any central healing (inverted-saucer).
4. If the lesion advances, 'leonine' facies may be seen.
5. Both the loss of cutaneous sensation and nerve involvement are late features.

PLUS

a) Lymphadenopathy (painless).
b) Hepatosplenomegaly.
c) Peripheral neuropathy with trophic changes (watch the sole of the feet for trophic ulcer).
d) Testicular atrophy (with impotence) and gynaecomastia; pedal oedema.
e) Ocular lesions — Keratitis, iridocyclitis etc.
f) Miscellaneous—anaemia, nephrotic syndrome, nasal collapse.

N.B. : In a suspected patient of LL variety, one should examine the eyes (e.g., corneal anaesthesia, corneal ulcer), palpate the liver, spleen and testes, test for peripheral neuropathy, search for lymphadenopathy and examine for gynaecomastia. Look at the face carefully and never forget to test the touch sensation in the skin lesion. Palpate the nerves proximal to the skin lesion (though a late and non-prominent feature).

Different types of nerve involvement in leprosy :

(A) Nerver thickening—Classical description given in TT variety (see above).
(B) Sensory nerve involvement with gloves and stockings anaesthesia is commoner in LL variety (peripheral neuropathy).
(C) Motor nerve involvement may result in muscle weakness, wasting, paralysis and contractures lately. The ulnar nerve (claw hand), median nerve (ape hand), common peroneal nerve (foot drop) or posterior tibial nerve (claw toes) may be affected; common in TT variety.
(D) Cranial nerve involvement ; Facial (often bilateral) or trigeminal nerve (loss of corneal reflex); sometimes, multiple cranial nerves are involved (polyneuritis cranialis multiplex).

* Always consider leprosy as a possible cause of peripheral neuropathy in India. Central nervous system is not affected in leprosy.
** Ulnar nerve abscess with adjacent cellulitis in skin is common in BT variety.

Describe the leonine face :

(A) Description ;
1. Lines on the forehead become deeper as well as the upper central incisor teeth loosen or fall out and there is hoarse voice.
2. Loss of hair in the lateral part of eyebrows (madarosis) and thick eyebrows.
3. Depressed bridge of the nose, broad nose with nasal collapse (saddle nose).
4. Thickened skin of face and forehead, specially the infiltrated earlobes.
5. There may be perforated nasal septum.

(B) Causes ;
1. Leprosy (lepromatous).
2. Albright's disease (fibrous dysplasia of bone).
3. Carcinoid syndrome.
4. Cleidocranial dysostosis.
5. Primary hypertrophic osteoarthropathy (pachydermoperiostitis).
6. Amyloidosis.
7. B-cell lymphoma.
8. Paget's disease.

* Actually 2 to 8 mimic leonine face.
** ***Saddle nose :*** lepromatous leprosy, ectodermal dysplasia and congenital syphilis; ***destruction of nasal structures :*** lepromatous leprosy, Wegener's granulomatosis, midline granuloma and lupus vulgaris.

D/D of multiple nodular lesions in face :

1. Leprosy (lepromatous).
2. Post Kala-azar dermal leishmaniasis (PKDL)
3. Sarcoidosis.
4. Acne rosacea.
5. Non-Hodgkin's lymphoma.
6. Amyloidosis.

Do you know any other variety of leprosy ?

1. Histoid leprosy— Succulent cutaneous nodules and a variant of LL variety.
2. Neuritic leprosy— Peripheral nerves are thickened without any skin lesion, probably of TT type-common in India.

Describe the hand of a leprosy patient :

Read the section on 'Examination of the hands'.

Causes of thickened peripheral nerves :

1. Leprosy.
2. Neurofibromatosis.
3. Acromegaly.
4. Amyloidosis (primary).
5. Charcot-Marie-Tooth disease (juvenile).
6. Sarcoidosis.
7. Chronic Guillain-Barre syndrome.
g Dejerine-Sottas type neuropathy.
9. Refsum's disease.
10. Injury to the nerve.
1]. Idiopathic hypertrophic neuropathy.

Complications of leprosy :

1. Crippling of hands.
2. Blindness (due to corneal anaesthesia).
3. Tuberculosis (one of the major cause of death).
4. Amyloidosis (secondary).
5. Lepra reactions.
6. Social outcast.

Lepromin skin test in all the varieties of leprosy :

It depends on the cellular immunity or resistance of the patient though it has no value in diagnosing leprosy (as it may be positive in normal people). *It helps in classifying the disease.*

TT — Strongly positive.

LL — Negative.

BT — Positive.

BB — Negative or weakly positive.

BL — Negative. *

* In Lepromin test, suspension of dead bacilli (M. leprae) is injected intradermally, and the findings read after 4 weeks.

Reactions (lepra reactions) in leprosy :

(A) Type I (reversal reaction)— Existing skin lesions may develop erythema and swelling, peripheral nerves become tender and painful, with sudden loss of nerve function (e.g., foot drop). Common in BL, BT and BB variety. It is a type IV delayed hypersensitivity reaction and is being treated by aspirin, corticosteroid and chloroquine.

(B) Type II or erythema nodosum leprosum (END— Common in LL or BL variety. It occurs in patients in their second year of treatment. Acute crops of painful, tender nodules develop with pain in the nerves, fever, arthritis, lymphadenopathy, iridocyclitis, bone pain and epididymo-orchitis. ENL is treated by analgesics, antipyretics, chloroquine, thalidomide (never used in pregnancy) or prednisolone, and increasing the dose of clofazimine. ENL develops due to immune complex-mediated vasculitis. Eye care is done by hydrocortisone or atropine drop.

(C) Lucio phenomenon— Rare, occurs in diffuse non-nodular LL variety (develops angular ulcer).

Incubation period of leprosy and portal of entry of M. leprae :

Incubation period — Generally 2-6 years, may be more; 2-5 years for TT and 8-12 years for LL variety (as M. leprae has doubling time of 12 days i.e., very slow multiplication time).

Portal of entry— Through nasal mucosa or by inoculation through skin (needs prolonged close contact) Droplets from the sneezes of a lepromatous patient is highly infectious. Untreated patients (man is the only reservoir) with smear-positive extensive disease are potential source of infection.

What are the differential diagnosis of leprosy ?

(A) Skin lesions -

1. Hypopigmented lesions like vitiligo, psoriasis, pityriasis versicolor
2. SLE.
3. Lupus vulgaris (tuberculosis of skin).
4. Yaws.

5. Dermal leishmaniasis.
6. Sarcoidosis.

(B) Claw hand — Read the section on 'Claw hand'.

(C) Peripheral neuropathy — Read the section on Peripheral neuropathy'.

(D) Peripheral nerve thickening — Read the causes of 'thickened peripheral nerves' discussed above.

How to establish your diagnosis ?

The diagnosis is essentially clinical. The investigations performed are :

(A) By slit-skin smear method — Principally the multibacillary disease (BB, BL and LL) is diagnosed by this method and it is less informative in paucibacillary (I, BT and TT) variety. The pinched skin between thumb and forefinger is incised by a scalpel and the exposed area is scraped. The juice is then stained by Ziehl-Neelsen's method (to find out acid-fast bacilli) and put under the microscope. Now the bacterial index (BI) i.e., the number of bacilli living or dead are calculated and scored on a logarithmic scale. Typical histology after skin biopsy also helps in diagnosis.

Sites of incision — Skin lesions (nodules), earlobes, dorsum of the middle or ring finger, nasal mucous membrane.

(B) Biopsy of lymph nodes, nerves, liver may demonstrate the bacilli (rarely required).

(C) Serology or PCR testing for M. leprae—neither sensitive no specific for diagnosis.

Associated features — Mild anaemia, high ESR and hyperglobulinaemia (may give false-positive serological tests like VDRL, rheumatoid factor and ANF—in LL variety).

How are you going to treat a leprosy patient ?

Recommended treatment regimens in leprosy for adults (modified WHO guidelines)

(A) Paucibacillary disease (I, BT and TT) -

(i) Rifampicin 600 mg — once monthly (single supervised dose).

(ii) Dapsone — 100 mg daily (self-administered dose).

Duration — 6 months.

(B) Multibacillary disease (BB, BL and LL) -

(i) Rifampicin — 600 mg once monthly (single supervised dose).

(ii) Clofazimine — 300 mg once monthly (single supervised dose).

PLUS

(iii) Daily dose of clofazimine (50 mg) and dapsone (100 mg)—both self-administered dose.

Duration—12 months.

(C) Single lesion paucibacillary disease (I, BT and TT)-

(i) Rifampicin 600 mg
(ii) Ofloxacin 400 mg
(iii) Minocycline 100 mg
} as a single dose

* Bacteriostatic—dapsone and clofazimine: bactericidal—rifampicin.

** in pregnancy : clofazimine is not used, rifampicain is used cautiously in first trimester but dapsone is safe in pregnancy.

*** Because of long generation time of the bacillus, low dose rifampicin is sufficient (once monthly use).

**** Management of anaemia, secondary infection and lepra reaction are done accordingly.

Side-ejfects of clofazimine and dapsone :

(A) Clofazimine -

1. Skin pigmentation (red colouration of skin, urine and body secretions).
2. Abdominal pain.
3. Pruritus and ichthyosis.
4. Anorexia, nausea and vomiting.

(B) Dapsone (diaminodiphenyl sulphone / DDS)—

1. Exfoliative dermatitis.
2. Haemolytic anaemia.
3. Agranulocytosis.
4. Methaemoglobinaemia.
5. Avoided in G_6 PD deficiency.
6. Psychosis.
7. Hepatitis.
8. Hypoproteinaemia.

Use of rifampicin in internal medicine :

1. Tuberculosis and in non-tuberculous mycobacteria.

2. Leprosy.
3. Chemoprophylaxis of persons at risk of developing meningococcal meningitis.
4. Legionnaires' disease.
5. Brucellosis (with co-trimoxazole or tetracycline-streptomycin combination).
6. Eradication of chronic carrier state in enteric fever (with co-trimoxazole).
7. Endocarditis as a result of Staphylococcus epidermidis or Corynebacterium Spp. (often with vancomycin).
8. Anthrax.
9. Anaplasmosis.
10. Primary amoebic meningoencephalitis (caused by Naegleria fowleri).
11. Pruritus (may be used in pruritus associated with cholestasis).
12. Bartonellosis (chronic).
13. Cat-scratch disease.
14. Prevention of haemophilus influenzae.

Other drugs used in leprosy :

1. Acedapsone (DADDS).
2. Ethionamide.
3. Thiacetazone.
4. Prothionamide.
5. Thiambutosine.
6. Minocycline.
7. Ofloxacin.
8. Clarithromycin.
9. Streptomycin / kanamycin.
10. Corticosteroid (in lepra reactions)

* Vaccination by BCG with heat-killed M. leprae is being tried for prevention of leprosy.

Other modalities of treatment in leprosy :

1. Paralysis from reactional neuritis— Splinting of the limb.
2. Tarsorrhaphy for corneal anaesthesia.
3. Trophic ulcer in feet— Rest, use of crutches, walking plaster.
4. Infection— Appropriate antibiotic.
5. Special protective footwear for anaesthetic feet.
6. Plastic surgery in face or reconstructive surgery in limbs.
7. Haematinics and multivitamins.
8. Physiotherapy to prevent contracture and muscle atrophy.
9. Rehabilitation.

* 'Hypopigmentation' in leprosy is due to 1. Direct invasion at melanocyte level, 2. Utilisation of dopa by lepra enzyme system, and 3. Vascular changes leading to atrophy of melanocytes.

Case 61

NEUROFIBROMATOSIS

What is neurofibroma ?

These are benign, soft, usually non-tender papules or nodules varying in size from a pea to a cricket ball which develops from the Schwann cells and fibroblasts of the neurilemmal sheath of the peripheral nerve (a form of hamartoma). Majority are symptomless but occasionally there is paraesthesia. **The mass may be moved from side to side only** but is otherwise fixed by the nerve from which it arises.

What is neurofibromatosis ?

It is also known as "von Recklinghausen's disease" and has an autosomal dominant inheritance. Here, multiple neurofibroma are associated with cafe-au-lait spots and axillary freckling.

Cafe-au-lait (colour of white coffee or coffee in milk) spots are round to ovoid, pale yellow-brown macules that vary in diameter from 1 cm to more than 15 cm and is usually present on the trunk.

* Friedrich Daniel von Recklinghausen (1833-1910) was Professor of Pathology, Strasbourg, France.

Conditions associated with cafe-au-lait spots :

1. Neurofibromatosis which is characterised by,
   (i) Six or more spots.
   (ii) Uniformly hypomelanotic, circumscribed.
   (iii) Diameter >1.5 cm with multiple Lisch nodules in iris (1 mm yellow-brown spots in iris, best revealed by slip-lamp examination).
2. Albright's disease (polyostotic fibrous dysplasia)—larger and more irregular than No. 1.
3. Occasionally in normal population.
4. Multiple endocrine adenomatosis-type III.
5. Tuberous sclerosis.
6. Watson's syndrome (neurofibroma with pulmonary stenosis).
7. Ataxia-telangiectasia.
8. Bloom syndrome.

What are the types of neurofibromatosis ?

(A) Type I (von Recklinghausen's disease) — Peripheral form (found in 70% cases) and thus, readily recognized by the cutaneous lesions. It is due to an abnormal gene carried on chromosome 17 which encodes 'neurofibromin'. This type may be associated with scoliosis, plexiform neurofibroma, aqueduct stenosis. Lisch nodules in iris and rarely pheochromocytoma.

(B) Type II — Central form and difficult to diagnose as there are few or no cutaneous lesion. This type may be associated with optic glioma, acoustic neuromas, meningiomas, entrapment of spinal nerve roots, cataract, mental retardation and epilepsy. The gene for this type is located on chromosome 22 which encodes 'Merlin' or Schwannomin. As this type may have no cutaneous stigmata, a family history of cerebral or spinal lesion should be noted very carefully.

Where the neurofibromas are mostly found ?

Mainly they are present by the sides of the neck and in the extremities (cafe-au-lait spots are primarily present on the trunk). The tumours are felt as movable, bead-like nodules. Rarely, they may be painful and tender on pressure.

When ***to investigate neurofibromatosis*** ?

In the presence of :

1. Symptoms of cerebral or spinal involvement (acoustic neuroma may present as cerebello-pontine angle tumour, and spinal involvement may present as paraplegia), and
2. Malignant change (sarcomatous change in very few cases).

What is plexiform neurofibroma ?

This is diffuse neurofibromatosis with an overgrowth of the skin and subcutaneous tissue. In this way large hanging folds of skin may be formed. The commonest sites are temple (in connection with branches of trigeminal nerve), the upper eyelid and the back of the neck. The severe form of this variety is known as 'elephantiasis neuromatosa' (usually involves the lower limb).

What is pachydermatocele ?

It is a very rare variety of neurofibromatosis in which coils of soft tissues hang around the neck.

What is phakomatosis ?

These are a unique group of diseases in which neurological abnormalities are combined with congenital defects in skin, retina and other organs. The causes of phakomatosis are von Recklinghausen's disease, tuberous sclerosis, von Hippel-Lindau syndrome and Sturge-Weber disease. These are also known as 'congenital neurocutaneous syndrome'.

'Phakoma' (collection of abnormal neuroglial tissue) is seen in the retina (greyish circular mass about the size of half the optic disc) by ophthalmoscopy.

Conclusion :

If you see a patient with neurofibroma, always search for —

1. Scoliosis, 2. Cafe-au-lait spots, and 3. Axillary freckles,

* Biopsy is usually contraindicated in neurofibroma as it may change into neurofibrosarcoma.

** Surgery may be considered for cosmetic reason or pressure symptoms.

Case 62

Scleroderma

Describe the face of the patient :

The term scleroderma (henceforth called systemic sclerosis—SSc) refers to thickening or hardening of skin due to abnormal collagen deposition in dermis. The typical 'facies' goes like this—

1. *Mask-like facies* (loss of facial expression).
2. Absence of normal skin wrinkling ('ironed' out skin folds).
3. Pinched-up nose or beaking of the nose.
4. Inability to open the mouth fully — Small mouth *(microstomia)* with radial furrows on closing (tobacco-pouch, fish-mouth or crow-feet appearance).
5. Skin over the face seems taut and shiny.
6. Pigmentation and depigmentation.
7. Telangiectasia over face and lips.

Common causes of masked facies :

Poverty of expression in face (hypomimia) is seen in,

1. Parkinsonism.
2. Scleroderma.
3. Hypothyroidism (myxoedema).
4. Bilateral UMN type of facial nerve palsy.
5. Depression.
6. Sometimes in myasthenia gravis and facial myopathies.
7. Dementia.
8. Sometimes in pseudobulbar palsy.

Types and subtypes :

(A) Systemic sclerosis (SSc) is a multisystem disorder of unknown aetiology affecting skin *(scleroderma),* CVS, G.I. tract, kidneys, musculo-skeletal system, lungs and vasculature. Localised form without systemic involvement is known as *localised scleroderma.*

(B) SSc is divided into two subgroups : *limited cutaneous scleroderma (LcSSc;* ***70%)*** and *diffuse cutaneous scleroderma (DcSSc;* ***30%).*** LcSSc -» skin involvement over sites restricted distal to elbow or knee. Face is always involved. LcSSc is now synonymous with CREST syndrome (see afterwards), and DcSSc -> involvement of skin of fingers rapidly involves the whole body, trunk and face.

(C) Localised scleroderma is again divided into two subgroups : *morphoea* and *linear scleroderma.*

(D) *Scleroderma sine scleroderma* **:** Systemic features without any skin involvement.

Initial suspicion of scleroderma in a patient :

1. While examining the patient for anaemia i.e., when the lower eyelids are retracted downward, it seems very tight and the lower palpebral conjunctiva is not exposed fully.
2. Characteristic facies, specially in a middle-aged female patient (30-50 years).

Stages of scleroderma :

There are three stages —

1. Oedematous stage (non-pitting oedema).
2. Indurated stage.
3. Atrophic stage.

How the patients present themselves ?

Very often the first symptom is Raynaud's phenomenon, or symmetrical swelling or stiffness of the fingers.

Examine the hand of your patient (scleroderma) :

1. Skin is very taut, firm and thick, and the skin of the fingers cannot be pinched-up (sclerodactyly) as it is tightly bound to underlying subcutaneous tissue.
2. Raynaud's phenomenon.

3. Symmetrical swelling (puffiness) of fingers.
4. Limitation of full extension and flexion of fingers (flexion contracture).
5. Pulp atrophy (soft tissue at fingertips is lost).
6. Skin is dry. coarse with loss of hair; skin may appear shiny.
7. Skin may be pigmented and/or depigmented (salt-pepper appearance); telangiectasia may be seen.
8. Nail-fold thrombi, dilated nail-fold capillary loops, digital infarcts, painful digital ulceration and rarely digital gangrene.
9. Pseudoclubbing may be present (due to resorption of bone of terminal phalanx).
10. Calcific deposits (calcinosis cutis) in the subcutaneous tissue (sometimes skin may break down with discharge of calcific material).

* The changes in the nail-fold capillaries are best examined clinically by an ophthalmoscope or capillary microscope.

Causes of deformed/multilated fingers/toes :

1. Leprosy.
2. Scleroderma.
3. Buerger's disease.
4. Congenital defect.
5. Frost bite.
6. Diabetic foot.
7. Syringomyelia.
8. Vasculitis.
9. Atherothrombosis.
10. Antiphospholipid syndrome.
11. Arthritis mutilans (psoriasis)
12. Trauma.
13. Porphyria.
14. Amyloid neuropathy.
15. Lesch-Nyhan syndrome.

Respiratory system involvement in SSc :

Respiratory system involvement is the major cause of morbidity and mortality in SSc.

1. Aspiration pneumonia (due to dysphagia).
2. Interstitial lung disease ('honeycomb lung' in chest X-ray).
3. Pulmonary arterial hypertension (10-15%)—common in long-standing disease.
4. Chronic cor pulmonale.
5. Malignant alveolar or bronchiolar cell neoplasm.
6. Pleurisy, rarely.
7. Restriction of chest movement (due to very tight skin which looks like Roman breast plate)—Hidebound chest.

CVS ***involvement in SSc :***

1. Pericarditis.
2. Heart block.
3. Arrhythmia.
4. Restrictive cardiomyopathy (myocardial fibrosis).
5. Heart failure (right heart failure from cor pulmonale, and left heart failure from cardiomyopathy).
6. Systemic hypertension.

Gastrointestinal tract involvement in SSc :

1. Heartburn, regurgitation of gastric contents due to reflux oesophagitis (symptoms are more when the patient lies flat).
2. Dilatation and atony of distal oesophagus — peptic oesophagitis.
3. Dysphagia, specially to solid foods (manometry shows decreased amplitude or disappearance of peristaltic waves in lower 2/3rd of the oesophagus) due to oesophageal hypomotility; odynophagia may occur.
4. Delayed gastric emptying due to atony and dilatation.
5. Recurrent occult upper G. I. bleeding indicates 'watermelon stomach' i.e., antral vascular ectasia.
6. Malabsorption syndrome (due to bacterial overgrowth).
7. Chronic constipation, distension and sometimes intestinal pseudo-obstruction (due to atony).
8. Pneumatosis cystoldes intestinalis (radiolucent cysts within the wall of small intestine).

* Dysphagia is a very important symptom of SSc.

Musculo skeletal manifestations of SSc :

1. Symmetrical polyarthritis (like rheumatoid arthritis).
2. Restriction of hand movement (mostly due to stiffness of skin).
3. Leathery crepitations can be palpated over tendon sheaths or moving joints (specially knee joints) in an advanced disease.
4. Carpal tunnel syndrome.
5. Resorption of terminal phalanges resulting in pseudoclubbing.
6. Proximal muscle weakness, wasting (due to disuse) and low grade myositis.

Renal involvement in SSc :

1. Hypertension.
2. Non-progressive proteinuria.
3. 'Scleroderma renal crisis'—it is due to obliterative vasculopathy of renal cortical arteries and is one of the common cause of death.

How to assess the severity of scleroderma at the bedside ?

Normally in health, a person's 4 fingers (excluding thumb) easily enter within his oral cavity when placed side by side. In scleroderma, as the mouth becomes smaller, all the four fingers may not enter within the oral cavity. Observe the number of patient's fingers entering within the oral cavity with ease; if it is 3 fingers, it is grade I and if it is 1 finger, it is of grade III (severe).

What are the differential diagnosis ?

1. Causes of Raynaud's phenomenon (see below).
2. CREST syndrome (calcinosis, Raynaud's phenomenon, oesophageal dysmotility, sclerodactyly and telangiectasia). This is synonymous or a subset of limited cutaneous scleroderma.
3. Eosinophilic fascitis.
4. Pseudo-scleroderma (amyloidosis, scleredema, acromegaly and scleromyxoedema).

Drugs or toxins producing scleroderma like lesion :

1. Vinyl chloride.
2. Pentazocine.
3. Bleomycin.
4. Epoxy and aromatic hydrocarbon.

How to confirm your diagnosis ?

Antinuclear factor (ANF) is present in 95% cases. Antinuclear antibodies to anti-topoisomerase I (anti-Scl-70) is found in 30% patients of diffuse cutaneous variety; anticentromere antibodies are found in 75% cases of limited cutaneous variety (e.g., CREST syndrome). Rheumatoid factor is positive in 30%.

Chest X-ray (to see cardiomegaly), X-ray of hands (acrosteolysis or calcinosis), barium swallow (confirms oesophageal hypomotility) and CT scan of thorax (to demonstrate interstitial lung disease) also help in diagnosis. Skin biopsy is not so important in diagnosis.

What is mixed connective tissue disease (MCTD) ?

It is an overlap syndrome characterised by the combination of SLE, scleroderma, polymyositis and rheumatoid arthritis. It is associated with unusually high titres of circulating antibody to a nuclear ribonucleoprotein (Ul-RNP).

What is Raynaud's phenomenon ?

Definition — It is a vasospastic disorder (intense vasospasm of peripheral arteries), manifested clinically by the classical 'triphasic colour response' which is sequential development of digital blanching (pallor due to vasospasm of arteries), cyanosis (blue due to sluggish blood flow and accumulation of deoxygenated blood following ischaemia) and rubor (redness due to vasodilatation and reactive hyperaemia) of the fingers and toes following cold exposure and subsequent rewarming. The changes in the fingers and toes are often diagnosed by nail-fold capillography. The fingers are affected more than toes. Numbness, burning and severe pain in digits are common features.

It is a cold-induced digital ischaemia secondary to reflex sympathetic vasoconstriction. The duration of the attack is variable and may last for hours. Some patients may experience bicolour response (e.g., pallor and cyanosis). In chronic and severe cases, there may be tissue infarction and loss of digits.

Common causes are :

1. Collagen vascular diseases like scleroderma, dermatomyositis, CREST syndrome, SLE etc.
2. Raynaud's disease (women of late teens, bilateral and symmetrical affection of hands).

3. Throacic inlet syndrome (specially in unilateral involvement).
4. Neurological — Syringomyelia, spinal cord tumours.
5. Trauma — Vibration injury, use of pneumatic drills, cold injury, typing.
6. Blood dyscrasias — Myeloproliferative disorders, hyperviscosity syndrome, cryoglobulinaemia.
7. Drugs — Ergot derivatives, (3-blockers, methysergide.
8. Arterial disease— When affected by microemboli e.g., atherosclerosis, Buerger's disease.

N.B. : Now-a-days Raynaud's phenomenon is broadly divided into two categories :

a) The idiopathic variety called Raynaud's disease (No. 2), and
b) The secondary variety described above (No. I to 8 except No. 2).

* D/D of Raynand's phenomenon are acrocyanosis, erythromelagia, chilblain, cold aglutinin disease.

D/D of hardness (or thickening) of skin :

1. Morphoea (localised scleroderma)—presents as solitary or multiple patches of thickened skin.
2. Lymphoedema.
3. Vascular insufficiencies (chronic).
4. Recurrent cellulitis with venous stasis.
5. Lipoid proteinosis.
6. Carcinoid syndrome.
7. Schirrhous carcinoma (hardening of skin of chest).
8. Porphyria cutanea tarda.
9. Chronic graft-versus-host disease.
10. Toxic oil syndrome (linked to consumption of contaminated rapeseed oil).
11. Eosinophilia-myalgia syndrome (due to consumption of L-tryptophan).
12. Nephrogenic systemic fibrosis (in uraemic patients on haemodialysis).

Treatment modalities used in SSc :

Virtually no agent has been shown to arrest skin changes. The drugs used are :

1. D-penicillamine (diminishes collagen cross linkage and reduce skin thickening).
2. Colchicine (diminishes procollagen to collagen conversion).
3. Treatment of reflux oesophagitis (by PP1 and prokinetics), myositis (by glucocorticoids), articular symptoms (by NSAID), respiratory tract infection (by antibiotics), interstitial lung disease (by glucocorticoids and immunosuppressants), CVS involvement (pericarditis by glucocorticoids) and hypertension (ACE inhibitors) due to renal involvement are done accordingly.
4. 'Scleroderma renal crisis' is a medical emergency, and requires intensive control of hypertension and use of ACE inhibitors.
5. IFN-a, IFN-y and human recombinant relaxin are being tried with mixed results.
6. Clinical trials of immunosuppressive drugs (methotrexate, mycophenolate mofetil, cyclosporine, azathioprine) are underway.
7. **Raynaud's phenomenon** : patients should wear gloves and woolen mittens, minimise cold exposure, protect the body with warm clothings and abstain from tobacco smoking. Drugs used are calcium channel blockers (nifedipine or diltiazem), prazocin, losartan, sildenafil, topical nitroglycerine, I.V prostaglandins, aspirin/dipyridamole (to prevent platelet aggregation), endothelin-1 receptor antagonist (bosentan, specially in digital ulcers; costly), calcitonin gene-related peptides and statins (empirical use). One should avoid (3-blockers, ergotamine, sympathomimetics and OC pills. Digital sympathectomy may be effective in some patients.
8. Regular exercise and skin lubricants help in maintaining flexibility of limbs and pliability of skin.

Clinical use of colchicine :

1. Acute gout, pseudogout.
2. Scleroderma.
3. Primary biliary cirrhosis.
4. Amyloidosis.
5. Familial mediterranean fever.
6. Study of chromosomes (colchicine arrests cell division at the metaphase).
7. Psoriasis.
8. Behcet's syndrome,
9. Myelofibrosis.
10. Erythema nodosum.
11. Sarcoid arthritis.
12. Recurrent oral ulcers/pericarditis
13. Osteoarthritis.

Case 63

SYSTEMIC LUPUS ERYTHEMATOSUS (SLE)

Describe the face of the patient :

1. Classical photosensitive 'butterfly' rash over the malar areas and bridge of the nose (never involves the nasolabial folds)—slightly raised erythema, may be scaly.
2. The lesion consists of erythema and oedema during acute phase, atrophy and telangiectasia in chronic phase.
3. Patchy alopecia.
4. 'Lupus hairs'— Short, broken hairs seen above the forehead.
5. Ulcers within the oral cavity (palatal ulcer specially, usually painless and recurrent) and nasal mucous membrane (seen after opening the mouth or careful examination of the nose).

N.B. : The face with the 'butterfly' rash looks like the face of wolves ('Lupine' means, like a wolf). The patient is commonly a female one (F : M = 9 : 1) in her second or third decade of life. Butterfly rash in SLE is due to apoptosis of keratinized layer of skin exposed to sunlight/UV light.

* ***Alopecia*** is loss of hair in the scalp, and is of two types : Cicatrical (DLE) and non-cicatrical (alopecia areata, SLE).

Causes of erythematous butterfly-like lesion in face :

1. SLE.
2. Acne rosacea (due to vasodilatation and telangiectasia, there may be red patches with nose disfigurement or rhinophyma of nose; lesion increases after taking tea, coffee etc).
3. Discoid lupus erythematosus (DLE) or mixed connective tissue disease (MCTD).
4. Lupus vulgaris (commonest form of skin tuberculosis).
5. Photosensitive reaction (after ingestion of drugs like tetracycline or phenothiazines).
6. Chloasma or melasma.
7. Leprosy (lepromatous).
8. Dermatomyositis (heliotrope rash; specially the juvenile variety).
9. Post kala-azar dermal leishmaniasis (PKDL).
10. Pemphigus erythematosus (an uncommon variant of pemphigus).
11. Polymorphous light eruption.
12. Sarcoidosis.

Other skin lesions in SLE :

The skin is affected in 85% patients of SLE :

1. Ill-defined, erythematous macular or maculopapular rash with fine scaling (particularly in sun-exposed areas); photosensitivity.
2. Vasculitic lesions on the fingertips and around the nail folds, purpura.
3. Bullous lesion, hives; recurrent urticaria; lichen planus-like dermatitis.
4. Panniculitis (lupus profundus).
5. Periungual erythema.
6. Digital infarcts (watch the tips and pulps of fingers for any tiny cicatrical depression).
7. Livedo reticularis (cyanotic mottling of skin with fishnet appearance).
8. Raynaud's phenomenon.
9. Angioneurotic oedema (non-pitting oedema with itching).
10. Pigmentation.
11. Alopecia.

* Photosensitive rash occurs in face, ears, chin, anterior part of neck, upper back and extensor surfaces of arms.

** D/D of livido reticularis in skin is erythema ab igne (reticular pattern due to prolonged exposure to heat) and cutis marmorata (physiological reaction to cold).

What is chronic discoid lupus erythematosus (CDLE) ?

Lupus erythematosus (LE) has three clinical variants like.

- Systemic lupus erythematosus (SLE).

- Chronic discoid lupus erythematosus (CDLE).
- Subacute cutaneous lupus erythematosus (SCLE).

CDLE is a chronic skin ailment which is commoner than SLE. The skin lesions heal with scarring, and the other characteristic features are :

1. Photosensitivity and erythema,
2. Scaling with atrophy,
3. Telangiectasia,
4. Hypopigmentation and keratotic plugging.

Sites - Face, arms, neck, scalp, ears.

* Rarely, in 5% patients DLE may turn into SLE, while DLE occurs in approximately 20% of patients with SLE. DLE is associated with positive ANF (30%) and normal complement level.

Causes of telangiectasias :

These are small, dilated blood vessels visible on skin surface; they blanch on application of pressure given by a pinhead.

(A) Systemic diseases : SLE, scleroderma, dermatomyositis, hereditary haemorrhagic telangiectasis, ataxia-telangiectasia, carcinoid syndrome, spider naevi in cirrhosis of liver.

(B) Primary cutaneous disorder : acne rosacea, ionising radiation, actinically damaged skin.

Common clinical features of SLE :

SLE is a multisystem disease. The common features are, .

1. Arthritis and arthralgia (commonest).
2. Fever (presents as PUO).
3. Skin eruptions.
4. Lymphadenopathy.
5. Renal involvement.
6. Anorexia, nausea and vomiting.
7. Myalgia.
8. Pleurisy.
9. CNS abnormalities.

* Splenomegaly occurs in 20-30% and hepatomegaly in 25% patients of SLE.

Neurological manifestations of SLE :

1. Convulsions.
2. Depression.
3. Organic psychosis.
4. Cranial nerve involvement.
5. Transverse myelitis.
6. Organic brain syndrome (psychosis, seizure)
7. Migraine.
8. Chorea.
9. Cerebellar ataxia.
10. Rarely, peripheral neuropathy.
11. Cerebrovascular accidents.
12. Aseptic meningitis.

* Fundoscopy may reveal white, hard exudate called 'cytoid body'.

Cardiopulmonary involvement in SLE :

1. Pericarditis, myocarditis, non-bacterial verrucous endocarditis (Libman-Sacks endocarditis may produce a murmur).
2. Heart block and arrhythmia may occur.
3. Ischaemic heart disease (due to premature narrowing of coronary arteries).
4. Recurrent pleurisy and pleural effusion (exudate).
5. Lupus pneumonitis (pulmonary infection is very common).
6. 'Shrinking lung syndrome' (X-ray shows elevation of diaphragm and liner scars from recurrent pulmonary infarction).
7. Fibrosing alveolitis.
8. Intrapulmonary haemorrhage (from vasculitis).

What is drug-induced SLE :

1. Drugs with positive ANF — INH, phenytoin, phenothiazines, a-methyldopa and levodopa.
2. Drugs associated with exacerbations of SLE— Sulphonamides, penicillin and oral contraceptives.
3. Drugs producing syndrome similar to SLE— Hydralazine and procainamide.

N.B. : Anti-hlstone antibody is positive in drug-induced SLE. Renal and neurological manifestations are uncommon. Complement levels are normal.

Renal manifestations of SLE :

It carries the worst prognosis. Renal biopsy is an important guide to prognosis in SLE.

1. Minimal proteinuria, haematuria, cellular casts.
2. Nephrotic syndrome (minimal change to crescentic glomerulonephritis).
3. Chronic renal failure.
4. Urinary tract infections.

Classification of lupus nephritis :

It is done by International Society of Nephrology and Renal Pathology Society (2004). Clinical renal involvement occurs in approximately 30% cases. There are 6 classes :

Class I : Minimal mesangial lupus nephritis (LN).

Class II : Mesangial proliferative LN.

Class III : focal LN.

Class IV : Diffuse LN.

Class V : Membranous LN.

Class VI : Advanced sclerotic LN.

Causes of pain abdomen in SLE :

1. Peritonitis.
2. Pancreatitis.
3. Perisplenitis.
4. Mesenteric vasculitis.
5. Complication of corticosteroid therapy (peptic ulcer).
6. Gall bladder perforation from necrotising arteritis.

* Death in SLE usually results from infection, cardiac failure or renal failure.

How to establish the diagnosis of SLE ?

1. Blood examination reveals normocytic normochromic anaemia or immune haemolytic anaemia, leucopenia, lymphocytopenia, thrombocytopenia, clotting factor defect (due to antibodies formed against factor VII, IX and X). ESR tends to be high with active disease.
2. Urine analysis - Proteinuria (may be in nephrotic range), haematuria, RBC casts.
3. LE cell phenomenon may be positive (not done now-a-days).
4. Coombs' test and rheumatoid factor (30%) may be positive.
5. False positive serological test for syphilis; positive lupus anticoagulant (LA).
6. Blood urea and creatinine may be high in renal involvement.
7. Antinuclear factor (ANF) are present in 98% cases. *Antibodies against native double-stranded DNA (70%) is specific for SLE. Anti-Sm antibody (Smith; 25%) is highly specific for SLE.*
8. Hypocomplementaemia C_3 (i.e., $C_3 < 5.5$ mg/dl).
9. Skin biopsy taken from uninvolved sun-hidden part (shows deposits of immunoglobulins and complement components at epidermal and dermal junction - called lupus band test' (60%))
10. Renal biopsy.

* It is to be remembered that C-reactive protein (CRP) is normal in SLE unless and otherwise there is superadded infection, pleurisy or arthritis (high CRP). Anticardiolipin antibody should be done to diagnose secondary antiphospholipid antibody syndrome.

Autoantibody associations in different subsets of SLE :

Autoantibodies are immunoglobulins which bind to antigens within autologous (self) tissue. Antinuclear antibody (ANA) or factor (ANF) are antibodies produced against nuclear component of a cell.

1. Anti-ds DNA—Nephritis, serositis.
2. Anti-Sm—Specific for SLE.
3. Anti-Ro/La—Photosensitivity, neonatal lupus.
4. Antiphospholipid antibody/Lupus anticoagulant—Coagulopathy, abortion, thrombocytopenia.
5. Anti-Ul-RNP (nuclear ribonucleoprotein)—Mixed connective tissue disease.
6. Anti-histone Drug-induced lupus (e.g., hydralazine or procainamide-induced).
7. Anti-ribosomal P antibody—CNS lupus (psychosis, depression)

8. C autoantibody—having prognostic significance in lupus nephritis.

* Other autoantibodies in different connective tissue diseases are :

- Anti-centromere—CREST syndrome.
- Anti-SSA (anti-Ro)/SSB (anti-La)—Sjogren's syndrome.
- Anti-topoisomerase I (anti-Scl-70)—diffuse cutaneous scleroderma.
- ANCA :
  - c-ANCA—Wegener's granulomatosis.
  - p-ANCA—Systemic vasculitis.
- Anti Jo-1—Polymyositis, dermatomyositis with lung involvement.

How will you manage this patient ?

There is no cure for SLE. The aim of treatment is to maintain remission and control acute 'flares'.

1. Rest.
2. NSAID - For arthritis, arthralgia, myalgia, pleurisy, fatigue, fever etc.
3. Hydroxychloroquine - 400 mg/ day (ophthalmological examination at least once a year should be done and the patient should avoid ultraviolet light) for treatment of skin lesions and arthritis.
4. Low dose corticosteroid in debilitaling skin lesion. Steroid is also indicated (60 mg/day of prednisolone) in cardiopulmonary, CNS and haematologial involvement. Gradually, the dose is tapered after two weeks and the patient is maintained on 10 mg prednisolone/day.
5. Renal lesions need special mention. Renal biopsy should be done prior to treatment. Focal lupus glomerulonephritis respond well to treatment with prednisolone (40-60 mg/day till symptoms disappear). However, diffuse and membranous lesions do not respond well and they need therapy with 1 gm of I.V methyl prednisolone for 3 consecutive days followed by maintenance daily or alternate-day prednisolone (also used in organ damage in SLE). The widely accepted 'pulse' regimen goes like this : cyclophosphamide 500 mg/m^2, I.V, monthly for 6 months -> then 500 mg/m^2, I.V, 3 monthly for 2 doses -> mycophenolate mofetil (1 g BD/day) or azathioprine (1.5-3 mg/kg of body weight/day) for 2 years. Short-term studies show that mycophenolate is superior to cyclophosphamide in induction as well as maintenance phase. Other immunosuppressive drugs used are methotrexate, tacrolimus, cyclosporin. Rituximab (anti-CD20) is used in refractory cases to reduce the level of antibodies.
6. Infection anywhere in the body is treated by proper antibiotic.
7. Skin rash may be treated by sunscreen cream, retinoids or dapsone.
8. Plasmapheresis may be tried.
9. SLE with pregnancy is treated with lowest dose of prednisolone for the shortest period.
10. Antiphospholipid syndrome needs low dose aspirin and anticoagulant therapy.

What is antiphospholipid antibody syndrome (APS) or Hughes syndrome ?

In APS there is persistently elevated levels of anti-phospholipid/cardiolipin antibody and/or positive test for lupus anticoagulant, and the presence of one of the following i.e., arterial or venous thrombosis, recurrent foetal loss and thrombocytopenia. APS is of two types : primary (no cause found) and secondary (with SLE, rheumatoid arthritis, systemic sclerosis etc.).

Clinical features are recurrent arterial or venous thromboembolism, recurrent foetal loss, thrombocytopenia, livedo reticularis, valvular heart disease, chorea/migraine/epilepsy or catastrophic occusion of blood vessels. APS is being treated with anticoagulants (heparin), antiplatelets (aspirin), IVIG and immunosuppressants.

Tests which are helpful in following the clinical course of SLE :

1) Titre of anti-ds DNA 2) Serum C_3 level 3) Haematocrit 4) ESR 5) WBC count 6) Platelet count 7) Urine analysis 8) Serum creatinine.

Indications for use of chloroquine in internal medicine :

1. Malaria.
2. Hepatic amoebiasis.
3. Rheumatoid arthritis.
4. SLE and DLE.
5. Sjogren's syndrome.
6. MCTD.
7. Lepra reaction (type I).
8. Congenital erythropoietic porphyria.

Case 64

ERYTHEMA NODOSUM

Characteristic lesion :

1 • Single or multiple non-ulcerating, bluish-red or erythematous nodular lesion, usually in children or young adults; F> M.
2. Generally present on the extensor sufaces; shins *re the usual site; thigh, upper arm or forearm rarely.
3. Painful and tender; at times bilateral and symmetrical; non-itchy.
4. May be associated with mild constitutional symptoms like fever, chills, malaise, arthralgia; may be recurrent.
5. Lesion is generally self-limiting (2-6 weeks). They fade through bruishing; usually heal without scarring.

Common causes of erythema nodosum :

1. Tuberculosis (specially primary) —so, a chest radiography is essential.
2. P-haemolytic streptococcal infection (commonly after streptococcal sore throat).
3. Sulphonamide therapy.
4. Leprosy (lepromatous).
5. Sarcoidosis.
6. Ulcerative colitis or Crohn's disease.
7. Other durgs like oral contraceptives, barbiturates, penicillins, iodides and bromides.
8. Histoplasmosis or coccidioidomycosis, Behcet's syndrome.
9. Brucellosis, psittacosis, tularaemia.
10. Rarely in rheumatic fever.
11. Bacterial gastroenteritis (Salmonella, Shigella, Yersinia).
12. Idiopathic.

Basic pathology of the lesion :

Actually, their appearance reflects patchy inflammation of subcutaneous fat (panniculitis) and small blood vessels (vasculitis). This is an example of type III (immune-complex) allergic reaction.

Foreign proteins and bacteria are slowly removed from the 'front of the legs' due to poor lymphatic drainage (as tibia splints the overlying tissue, the massage of the lymphatic channels is reduced)—this is why shins are the usual site.

Erythema nodosum is a septal panniculitis and is not of vasculitic in origin.

Differential diagnosis :

1. Resolving bruises.
2. Thrombophlebitis.
3. Erythema induratum.
4. Erythema chronicum migrans (Lyme disease).
5. Erythema multiforme.
6. Cutaneous vasculitis or metastases.

Different allergic reactions of primary pulmonary tuberculosis :

1. Erythema nodosum,
2. Phlyctenular keratoconjunctivitis,
3. Some cases of pleural effusion (not accepted by all), and
4. Sometimes, pneumonitis from exudative hypersensitivity lesion.

Treatment :

1. Stoppage of the offending drug.
2. Treatment of the primary disease.
3. Analgesics (NSAID).
4. Lotio calamine paint over the lesion.
5. Prednisolone (upto 30 mg/day), potassium iodide, dapsone (100 mg/day) or colchicine (0.6 mg BD) in stubborn cases.

What is erythema nodosum leprosum (ENL) ?

1. 50% of lepromatous leprosy and 25% of borderline lepromatous leprosy patients suffer from this type of skin reaction during the course of their illness.
2. This is a type II lepra reaction.
3. Acute crops of painful, tender nodules appear along with fever, lymphadenopathy, arthritis and iritis. The lesion may necrose and discharge sterile pus. It may appear in any part of the body.
4. Treatment Is done mainly by thalidomide, 100 mg 4 times dally. The dose is gradually reduced over weeks or months. Thalidomide is strictly contraindicated in females of child bearing age due to its teratogenicity. If thalidomide Is contraindicated, prednisolone may be used. NSAIDs (as analgesic-antipyretic) are given, If necessary. The dose of clofazimine is increased to 200-300 mg daily for few weeks during the reaction period. Iritis is managed by local Instillation of 1% atropine sulphate.

Lesions characteristically found over the shin :

1. Erythema nodosum.
2. Pretibial myxoedema.
3. Necrobiosis lipoidica diabeticorum.
4. Lichen amyloidosis.

Identification points :

Single or multiple bluish-red nodular lesion in anterior aspect of one or both legs, specially in younger patients.

Case 65

SUBCUTANEOUS NODULES

Differential diagnosis :

1. Lipoma, fibroma.
2. Neurofibroma.
3. Rheumatoid nodule.
4. Rheumatic nodule.
5. Leprosy.
6. Calcinosis.
7. Cysticercosis.
8. Osier's node.
9. Tophi.
10. Xanthoma.
11. * Metastatic carcinoma
12. Panniculitis.

* Skin deposits from carcinoma, lymphoma and leukaemias.

Common sites for rheumatoid nodule :

These nodules signify underlying vasculitis and active disease. They are situated :

1. Most commonly over the extensor surface of elbows.
2. Back of the head.
3. Over the sacrum in bed-ridden patients.
4. Extensor tendons of fingers and toes
5. Over the scapula.
6. Achilles tendon.
7. Margins of patella.

Common sites for rheumatic nodule :

The distribution is more or less like rheumatoid nodules i.e., situated over the bony prominences or at the site of pressure points while lying in bed.

Table 29 : Differentiation between rheumatoid and rheumatic nodules

	Features	Rheumatoid	Rheumatic
1.	Size	Big	Relatively smaller
2.	Ulceration	Frequently occur	Does not ulcerate
3.	Secondary Infection	May occur	Not common
4.	Tenderness	Non-tender	May be tender
5.	Fixity to skin	Very often fixed	Skin Is free
6.	Incidence	20%	3-5% In India
7.	Association	Indicates active disease with +ve RF	Associated with active carditis

Case 66

DOWN'S SYNDROME (MONGOLISM)

What is Down's syndrome ?

It is the commonest chromosomal disorder (1 in 700 newborns). Chromosome 21 is present in triplicate (i.e., total 47 chromosomes) as a result of non-disjunction during meiosis and is known as 'trisomy-21'.

Describe the facies (mongol facies) :

1. Small, round and flat face, brachycephaly; with downy forehead and short, wide fleshy neck.
2. Upwards-slanting eyes (oblique orbital fissure) with epicanthic folds at inner angles.
3. Low set ears; ears are small and dysplastic.
4. Small nose with depressed bridge of the nose.
5. Hypertelorism (widely set eyes).
6. High arched palate with small teeth. ,
7. Open mouth with protruded and furrowed tongue (macroglossia), with
8. An idiotic look (cheerful idiot).

* There are Brushfield's spot on the iris and typical facial grimace on crying.

** It is often said that the tongue is normal but it protrudes because of small size of the oral cavity.

*** John Langdon Hayden Down (Langdon-Down) was Physician (1828-1896), The London Hospital, London who first described the syndrome in 1866.

**** Epicanthic folds may be seen in Turner's syndrome.

Diagnostic points in hand, foot and eye ;

(A) Hand—

1. Short and broad hands (simian hand); short, stubby spatula-like fingers.
2. Single palmar flexion crease (simian crease).
3. Clinodactyly (hypoplasia of middle phalanx of 5th finger produces 'incurving' little finger).
4. Missing of one crease in little finger (cause—same as point 3).
5. Characteristic dermal markings in fingers (dermatoglyphics)—More than eight ulnar loops on fingers, and the ATD angle (distal axial triradii) becomes obtuse.

(B) Foot—

1. Increased gap between first and second toe (sandal gap).
2. Sub-hallucial pad of fat.
3. Single, deep and longitudinal crease in the sole of feet.

(C) Eye—

1. Brushfield's spot (whitish speckling on the iris).
2. Sometimes, cataract is present.
3. Rarely, squint and high myopia may be observed.

Features in other systems in Down's syndrome :

(A) CVS— Endocardial cushion defects, e.g., VSD, ASD, PDA.

(B) Gastrointestinal system— Duodenal stenosis, biliary atresia, severe periodontal disease.

(C) Haematopoietic— There is many fold higher incidence of acute leukaemia (AML in the new-born and ALL in older children).

(D) Neuromuscular— Hypotonia (poor Moro's reflex), floppiness in neonate.

(E) Skeletal— Short-height, joint hyperextensibility.

(F) Personality— Very pleasant with clean habits, and **fond of music.**

(G) Intelligence— I.Q. is generally low (from mild to severe) and often very much mentally retarded. Speech and social developments are severely affected.

* Patients of Down's syndrome may develop early Alzheimer's disease in the 3rd or 4th decade.

** Coeliac disease may be associated with Down s syndrome.

Cause of death :

1. Recurrent respiratory tract infections,
2. Septal defects in heart, or
3. Acute leukaemia (usually AML).

Management :

There is no definite treatment for Down's syndrome. Management is aimed at treatment of respiratory tract infections, acute leukaemia, VSD or proper rehabilitation. They are usually trainable children but may be educable rarely.

* Down's syndrome and Klinefelter's syndrome are associated with increased maternal age (> 35 years) whereas, Marfan's syndrome and achondroplasia are seen with increased paternal age. Prenatal diagnosis of Down's syndrome may be done by amniocentesis or chorionic villus biopsy.

Identification points :

Typical facies, grimace and behaviour.

Case 67

HYDROCEPHALUS

What is hydrocephalus ?

This is the dilatation of ventricles of brain due to increase in the volume of CSF within the ventricles resulting from a disturbance in the circulation (of CSF). It may be due to obstruction of CSF circulation or there may be failure of CSF absorption by the arachnoid villi.

Diagnosis of a child with hydrocephalus :

1. Abnormal enlargement of head, specially the frontal area.
2. Sutural separation.
3. Bulging of the anterior fontanelle.
4. Setting sun' sign— The eyes appear to be pushed down and thus both the upper bulbar conjunctiva become visible.
5. Scalp veins are dilated, and the skin over the scalp is thin and shiny.
6. Macewen sign— Skull is resonant (cracked-pot) on percussion.
7. High pitched cry.

Circulation of CSF :

Choroid plexus oi lateral ventricles (major source of CSF formation)—Foramen of Monro—Third ventricle—Aqueduct ot Sylvius—Fourth ventricle in the medulla—Foramen of Magendie and Luschka—Cistema magna and cisterna pontis—Subarachnoid space. CSF is absorbed by arachnoid villi.

Types of hydrocephalus :

(A) Compensatory : Due to cerebral atrophy from any cause.

(B) Hypertensive :

a) Obstructive If the circulation of CSF is obstructed within the ventricular system.

b) Non-obstructive or communicating (i.e., obstruction distal to fourth ventricle)—Hydrocephalus resulting from occlusion of the subarachnoid cisterns (due to arachnoiditis) or interference with the CSF absorption.

Features of late onset hydrocephalus :

1. Head size may not enlarge.
2. Sutural separation may not be evident.
3. Mental retardation.
4. Presence of papilloedema.
5. Spastic and ataxic child (legs are more involved).
6. Urinary incontinence.

Aetiology of hydrocephalus :

1. Meningitis (bacterial or tuberculous).
2. Head injury.
3. Subarachnoid haemorrhage.
4. Sagittal sinus thrombosis.
5. Brain tumours (posterior fossa).
6. Cerebral haemorrhage.
7. Congenital e.g.. Arnold-Chiari malformation.
8. 'Normal pressure hydrocephalus.
9- Cerebellar abscess or haemorrhage.
10. 3rd ventricle colloid cyst.

* Obstructive 5, 6, 7. 9 and 10: non-obstructive—1, 2, 3, 4 and 8; 1, 2 and 3 are responsible for majority of cases.

Causes and features of acute hydrocephalus :

Causes are :

1. Head injury with its complications.
2. Subarachnoid haemorrhage.
3. Acute exudative meningitis.

Features are :

1. Severe headache and vomiting.
2. Drowsiness, convulsions or coma.
3. Papilloedema may be evident.
4. 6th cranial nerve palsy (false localising sign).
5. Jerks— Brisk (may be lost).
6. Plantar response Extensor.

What is 'normal pressure' hydrocephalus ?

It is a misnomer. Initially there is increased pressure but ultimately CSF haemodynamics compromise (ventricles dilate) and it becomes normal or low pressure hydrocephalus. Actually, it is a variety of communicating hydrocephalus. This rare condition is predominantly seen in old age with the triad of symptoms such as **dementia, ataxia and urinary incontinence.** Though it may result from head injury, subarachnoid haemorrhage or meningitis, many a time no cause is identiiied.

How to diagnose hydrocephalus very early ?

By serial recording of head circumference of the child. An increase in the head circumference by more than 1 cm in every 2 weeks for the first 3 months of life, makes the pediatrician suspicious.

What is normal intracranial pressure (ICP) ?:

It is 5-10 mm of Hg when measured indirectly. Now-a-days, devices measure ICP directly by implanting into the lateral ventricles. When ICP is > 15 mm of Hg, it is known as raised intracranial pressure.

What is benign intracranial hypertension (BIH) ?

Previously the term BIH was used synonymously with pseudotumour cerebrei, meningeal hydrops or otitic hydrocephalus. It is a benign or idiopathic raised ICP developed as a result of diffuse swelling of brain with dilated ventricular system. The patient characteristically presents with headache, vomiting and papilloedema. BIH commonly develops from corticosteroid withdrawal, tetracycline or nalidixic acid therapy, hypervitamlnosis A, Addison's disease, hypoparathyroidism, or COPD with type II respiratory failure. The CSF is under increased pressure but its analysis remains normal. CT scan is within normal limit except the dilated ventricles. Aeetazolamide or repeated lumbar puncture may be of some help.

Diagnosis of hydrocephalus by investigations :

1. X-ray of skull-
   (i) Enlargement of calvariurn.
   (ii) Sutural diastasis (separation).
   (iii) Thinning of bone.
   (iv) Erosion of clinoid process.
   (v) Deepened sella turcica.
2. Ventriculography or cisternography by a suitable contrast medium (to see the site of obstruction).
3. Pneumoencephalography may be tried to localise the site oi obstruction not done now-a days.
4. CT or MRI scan (to show enlarged ventricles and cortical atrophy).
5. CSF flow studies may be done (CSF analysis is not informative).
6. Measurement of ICP—diagnostic.

Differential diagnosis of hydrocephalus :

1. Megalo encephaly (with severe mental retardation, and absence of IIT).
2. Chronic subdural haematoma (mostly with enlargement of the parietal regions).

Treatment of hydrocephalus :

It is important to treat the child before irreparable damage sets in.

(A) Drug—Acetazolamide (50-75 mg/kg/day) for reduction of CSF production.

(B) Shunt surgery—

(i) Ventriculo-peritoneal (commonly used).

(Ii) Ventriculo-atrial.

(iii) Ventriculo-caval (to jugular vein or superior vena cava).

(iv) Lateral ventricle to clstema magna.

(v) Ventriculo-ureteric.

Different varieties of silastic valves are used and the commonly used one is 'Spitz-Holter' valve.

(C) Miscellaneous Compressive head wrapping, repeated lumbar puncture (in acute hydrocephalus), different diuretics, steroid, isosorbide are tried. Neurosurgical removal of tumour, if necessary.

Complications of 'shunt' :

1. Shunt closure— Displacement, kinking or plugging of the shunt.
2. Ventriculitis (by Staphylococcus albus).
3. Bacterial colonisation of the shunt.
4. Shunt nephritis (acute glomerulonephritis).
5. SVC obstruction.

How the head circumference of a child is measured ?

Ideally by a steel tape. The tape is passed over the most prominent part of the occiput and the forehead above the supraorbital ridges.

* Always measure the head circumference in a child with apparent enlargement of head.

Case 68

RICKETS

Clinical manifestations :

(A) Symptoms :

1. Fretful, irritable, pale child with flabby muscles in the age group of 4 months to 2 years.
2. Delayed development; often late eruption of teeth.
3. Failure to sit, crawl, stand and walk at the normal ages.
4. Recurrent respiratory and G. I. tract infections.
5. Rocking of head in pillows with sweating in forehead (during sleep).
6. Poor dentition with late eruption of teeth.
7. Manifestations of tetany may develop.

(B) Signs :

a) Head :

1. *Craniotabes (thin and deformed skull)—Earliest manifestation of rickets-,* when the occipital or parietal bone is compressed and released, there is feeling like compressing a ping pong ball (egg-shell crackling feeling). It is seen below the age of 1 year and is due to small islands of unossified area in the skull.
2. Frontal and parietal bossing with large head (philosopher's head).
3. Quadrate skull with 'hot-cross bun' appearance; skull is apparently larger than normal.
4. Widening of sutures.
5. Late appearance of temporary teeth.
6. Delayed closure of anterior fontanelle.

* Other causes of *craniotabes* are hydrocephalus, congenital syphilis and osteogenesis imperfecta.

b) Chest:

1. Pigeon chest (pectus carinatum).
2. Rickety rosary (swelling or beaded appearance of the costochondral junction).
3. Harrison's sulcus (linear transverse depression by the side of xiphoid process).
4. Kyphoscoliosis.

c) Abdomen :

Pot-belly— Due to multiple factors like weakness of abdominal muscles, gaseous distension, hepatosplenornegaly, visceroptosis or lumbar lordosis.

d) Extremities :

1. Epiphyseal enlargement at wrists and ankles.
2. 'Knock knee' or 'bow leg' (when the child starts walking and thus, unusual before 1 year of age).
3. Genu valgum, varum or recurvatum (acrobatic rickets).
4. Pelvic deformities (triradiate pelvis—occurs in later childhood and may produce difficulties during childbirth).

* Rickets develops as a result of vitamin D deficiency in growing children before the fusion of epiphyses.

How to diagnose rickets ?

(A) Classical clinical features.

(B) Radiological changes (of upper extremity) :

1. Cupping, widening and fraying (saucer deformity) of lower end of radius and ulna.
2. Diminution of bone density.
3. Widening of wrist (soft issue shadow).
4. Increased distance between the distal end of bones of forearm and metacarpal bones because of non-calcification of the rachitic metaphysis.

(C) Biochemical changes :

1. Plasma alkaline phosphatase is raised (of diagnostic value)—indicates osteoblastic activity.
2. Low phosphorus (due to associated secondary hyperparathyroidism).
3. Plasma calcium tends to fall from its normal value (usually remains normal).
4. Plasma 25-hydroxyvitamin D_3 level is low in majority of patients.

* Clinical rickets may occur with normal level of plasma calcium and phosphorus.

** Normal serum allkaline phosphatase level : a) 2-4.5 Bodansky units, b) 4-13 King-Armstrong units, c) 50-130 International units/per liter.

*** Remember, in health, alkaline phosphatase is elevated during skeletal growth.

What are the early manifestations of rickets ?

1. Irritability and restlessness.
2. Head rolling and sweating in forehead, specially during sleep.
3. Craniotabes.
4. Rickety rosary.
5. Big anterior fontanelle.
6. Swelling of wrists.
7. Delayed dentition.

Radiological evidences of 'healing rickets' :

1. The density of metaphysis is increased and roughness is diminished.
2. Epiphyseal cartilage becomes horizontal.
3. Horizontal 'Harrison's line' are seen in the lower end of diaphysis (initially near the epiphysis).

Management of rickets :

1. Vitamin D — 1000-2000 I.U. orally daily, depending on the age of the child and severity of the disease, for 6 to 12 weeks followed by daily supplement of 400 I.U. of vitamin D (**standard daily requirement of vitamin D is 400 I.U or 10 pig).** Few clinicians prefer larger doses; 500-1000 mg calcium is prescribed daily. Therapeutic dose is continued so long the alkaline phosphatase level remains high (normalisation of alkaline phosphatase is a good indicator of healing).
2. Diet— Must be rich in vitamin D and calcium e.g., milk, cod liver oil, halibut liver oil, fatty fish, egg, liver, fortified margarine should be taken.
3. Calcium may be given in the form of lactate or gluconate.
4. Treatment of **tetany** is done by inj. calcium gluconate (10% solution) 20 ml in normal saline

by I.V route, slowly to run over 4-8 hours (inj. calcium chloride may be given). If tetany is not controlled by calcium, administration of I.V magnesium may be necessary. Correction of alkalosis should also be done.

5. If after administration of vitamin D, no sign of radiological healing is seen within 4 weeks, the dose is increased to several thousand I.U. If no healing is observed even after this larger dose, 'refractory rickets' should be considered.
6. The child should be encouraged to play outdoors for exposure to sunlight.

What is 'refractory rickets' ?

Definition : These patients develop rickets inspite of receiving the preventive daily dose (400 I.U) of vitamin D and do not show signs of healing rickets in X-ray, obtained 2 weeks after the parenteral administration (I.M) of 2 doses of 6 lakhs I.U. of vitamin D given at 15 days interval. The causes are :

1. Renal :
   - (i) Renal tubular acidosis.
   - (ii) Fanconi's syndrome.
   - (iii) Familial hypophosphataemic rickets (X-linked dominant disease with renal tubular loss of phosphate).
2. Malabsorption (e.g., coeiiac disease).
3. Hepatic dysfunction— Impairs 25-hydroxylation of vitamin D.
4. Miscellaneous—
   - (i) Hypophosphatasia (deficiency of alkaline phosphatase).
   - (ii) Children on long term antiepileptic drugs.
   - (iii) Certain tumours may secrete parathormone like substances.

* Alkaline phosphatase is low in one variety of rickets only— Rickets due to hypophosphatasia.

** For 'causes of rickets', read 'Bedside Clinics in Medicine, Part II'.

Treatment of refractory rickets :

(A) Large dose as much as 15 lakhs I.U. of vitamin D, I.M is administered daily and subsequently, 3 lakhs I.U. of vitamin D is used daily as maintenance dose. In the presence of renal disease, i rng of 1 u-hydroxyeholecalciferol may be given daily, orally.

(B) Administration of neutral phosphate salts, and

(C) The treatment of the primary cause.

What is vitamin D_2 and D, ?

Vitamin D_2 is ergocalciferol, and vitamin $D_{:1}$ is cholecalciferol.

Commonest cause of vitamin D deficiency in India :

Malabsorp tion.

What is hypervitaminosis D ?

Chronic oral intake of large dosage of vitamin D (50000-100000 I.U daily) for months may give rise to hypotonia, anorexia, nausea, vomiting, Irritability, constipation, abdominal pain, failure to thrive and pallor. Hypervitaminosis D is associated with high serum calcium level. Hypercalcaemia ultimately leads to renal damage and eventually metastatic calcification develops.

Treatment :

1. Administration of vitamin D is stopped immediately.
2. EDTA, sodium phytate may be used.

Megavitamin question—vitamins responsible :

There may be 'hypervitaminosis' with :

1. Vitamin A— Anorexia, nausea, vomiting, pain abdomen, bone pain, weight loss, cracked lips and benign intracranial hypertension, hyperostosis, hair loss and desquamation of skin. High doses of carotenoids are avoided in smokers due to an increased risk of lung cancer, and iii hypothyroid patients who may develop carotenaemia.
2. Vitamin D— Mentioned above.
3. Vitamin C— Oxalate stone, scurvy in the offspring, increased intestinal absorption of iron.
4. Pyridoxine or vitamin B_e— Sensory polyneuropathy.

5. Vitamin K— Jaundice in newborn if given to pregnant women.
6. Vitamin E— Malaise, headache, G. I. ailments and reduced platelet aggregation.
7. Niacin—Flushing, pruritus, aggravation of asthma, gout and acanthosis nigricans.

When the fontanelles close normally ?

Anterior fontanelle closes by 9-18 months. Posterior fontanelle closes by 3-6 months.

Delayed closure of anterior fontanelle :

1. Malnutrition.
2. Rickets.
3. Congenital syphilis.
4. Cretinism.
5. Hydrocephalus.
6. Down's syndrome.
7. Mucopolysaccharidosis.

Bulged anterior fontanelle :

1. Crying infant.
2. Increased intracranial tension (e.g., meningitis, brain tumour).
3. Hydrocephalus.
4. Benign intracranial hypertension (corticosteroid withdrawal, vitamin A overdose, tetracycline therapy, hypoparathyroidism etc).
5. Galactosaemia.

High arched palate :

1. Down's syndrome.
2. Marfan's syndrome.
3. Cyanotic congenital heart disease.
4. Turner's syndrome.

* Keep the patient's mouth wide open and look for palate keeping the eyes at the level of patient's upper incisor teeth—if the roof of palate is not visible, it is known as high arched palate.

Frontal bossing (prominence) of skull :

1. Thalassaemia major.
2. Rickets.
3. Congenital syphilis.
4. Hydrocephalus.
5. Achondroplasia.
6. Acromegaly.
7. Ectodermal dysplasia.
8. Ehlers-Danlos syndrome.

Depressed bridge of the nose :

1. Racial.
2. Cretinism.
3. Thalassaemia major.
4. Down's syndrome.
5. Lepromatous leprosy.
6. Congenital syphilis.
7. Wegener's granulomatosis.
8. Ectodermal dysplasia.
9. Achondroplasia.
10. Osteopetrosis (marble bone disease).
11. Hurler syndrome.
12. Midline granuloma.

Upwards-slanting (mongoloid) of eyes :

1. Racial.
2. Down's syndrome.
3. Ectodermal dysplasia.
4. Prader-Willi syndrome.

Anti-mongoloid slant of eyes :

1. Noonan's syndrome.
2. Apert's syndrome.
3. Turner's syndrome.
4. Alport syndrome. ,

Hypertelorism (widely set eyes) :

1. Racial.
2. Down's syndrome.
3. Cretinism.
4. Thalassaemia major.
5. Craniostenosis (e.g., Crouzon syndrome).
6. Turner's sydrome.
7. Ehlers-Danlos syndrome.
8. Noonan's syndrome.

* Diagnosed clinically by measuring inter inner-canthal distance between two eyes which is more than half of the inter-pupillary distance, or inter-pupillary distance > 85 mm where the average normal value is 60 mm. Hyperplasia of lesser wing of sphenoid bone is usually responsible for hypertelorism.

Hypotelorism :

It means there is decreased distance between orbits, and is found in ethmocephaly, cebocephalia or Patau's syndrome.

Sabre tibia (anterior tibial bowing) :

1. Congenital syphilis.
2. Paget's disease (osteitis deformans).
3. Rickets.
4. Osteogenesis imperfecta.
5. Osteopetrosis.

* 'Sabre' literally means cavalry sword with curved blade.

Prominent supraorbital ridges :

1. Racial.
2. Acromegaly.
3. Paget's disease.
4. Achondroplasia.
5. Hydrocephalus.
6. Thalassaemia.

Low set ears :

1. Down's syndrome.
2. Elfin facies.
3. Trisomy-13 (Patau's syndrome).
4. Trisomy-18 (Edward's syndrome).

* Normally, */ rd of the length of pinna is seen above an imaginary horizontal line, extending from outer canthus of eye to ipsilateral pinna. If less than $*/_3$rd of length of pinna is seen above that line, low set ears are said to be present.

Deep ear lobe cleft :

Though occasionally congenital, the prominent diagonal crease seen over the ear lobe is now well-recognised as strong and independent risk factor for coronary heart disease.

Quadrate skull :

1. Rickets.
2. Osteopetrosis.

Short neck :

1. Cranio-vertebral anomalies.
2. Cretinism.
3. Down's syndrome.
4. Turner's syndrome.
5. Hurler syndrome.
6. Noonan's syndrome.

Identification points (rickets) :

1. Fretful child.
2. Apparently large head.
3. Swelling of lower end of wris sts and ankles.
4. Hypotonia.
5. Pot-bellied abdomen.
6. 'Knock knee' or 'bow leg'.

Case 69

MYXOEDEMA

What is myxoedema ?

Myxoedema results from failure of the thyroid gland (primary disease of the thyroid) after puberty and is characterised by wide-spread deposition of mucinous material (mucopolysaccharides, hyaluronic acid and chondroitin sulphate) in different parts of the body, and clinically manifested by poverty of physical, mental and metabolic activities.

Describe the facies in myxoedema (hypothyroidism) :

1. Dull expressionless, puffy face (periorbital puffiness with baggy lower eyelids); xanthelasma.
2. Coarse hair; fall of hair in scalp (patchy alopecia) and lateral 1/3rd of eyebrows (madarosis).
3. Dry, rough and coarse skin.
4. Facial pallor (sometimes, rose-purple malar flush is seen); thick lips and macroglossia may be present.
5. Hoarseness of voice with bradylalia.

* Don't forget to look at the swollen neck and fullness of the supraclavicular fossa during inspection of face. It is one of the D/D of moon *face as well as masked face.*

** *'Bags under the eyes'* are often seen in insomnia, senility, chronic alcoholism, prolonged crying and myxoedema. It may not have any clinical significance.

*** *Madarosis* is common in leprosy, myxoedema, amyloidosis and neurodermatitis.

Is there any goitre ?

Usually thyroid tissue is not readily palpable in myxoedema. If palpable, think of :

1. Hashimoto's thyroiditis,
2. Iodine deficiency,
3. Use of antithyroid drugs, and
4. Malignancy of the thyroid gland.

Why do you say myxoedema ?

Myxoedema is common in females and there are presence of the following :

(A) Common symptoms are (if you are allowed to take the history) :

(i) Tiredness, lethargy, somnolence; hoarse voice.
(ii) Weight gain; non-pitting swelling of legs.
(iii) Cold intolerance.
(iv) Constipation.
(v) Menorrhagia or irregular bleeding.
(vi) Effort angina.
(vii) Loss of libido.
(viii) Stiff and aching muscles; arthralgia.
(ix) Deafness.
(x) Repeated abortions in productive age.

(B) The signs are :

(i) Physical sluggishness.
(ii) Dry, cold, rough or coarse skin with lustreless, brittle and scanty hairs. There may be lemon-yellow tint of the skin due to carotenaemia.
(iii) Moderate to severe anaemia.
(iv) Deep and *hoarse voice* (due to myxomatous infiltration of vocal cord); bradylalia; macroglossia.
(v) Sinus bradycardia.
(vi) Obesity with non-pitting oedema or solid oedema of legs (supraclavicular fossa, neck and limbs are swollen more).
(vii) Delayed relaxation of ankle jerk (it is better to demonstrate by 'special method' where the patient has to kneel-down on a chair).

* One must examine all the points.

** *Bradylalia* is also seen in depression and parkinsonism.

*** *Heat intolerance* is seen in hyperthyroidism and menopause.

**** Other common causes of *hoarse voice* are laryngitis, singer's nodule, voice-abuse, excessive use of tobacco, recurrent laryngeal nerve palsy, bulbar palsy.

Why there is anaemia ?

1. Lack of thyroxine— Normocytic normochromic type.
2. Menorrhagia— Iron deficiency anaemia.
3. Sometimes, myxoedema is associated with pernicious anaemia.

Mention causes of 'pallor without anaemia' :

1. Peripheral circulatory failure (e.g., low cardiac output in acute LVF) or shock (ashen-grey pallor), or vasoconstriction due to any cause; syncope.
2. Acute myocardial infarction.
3. Very tight aortic stenosis or mitral stenosis.
4. Myxoedema (pallor > anaemia)— Pallor is due to vasoconstriction plus lemon-yellow tint due to carotenaemia, plus anaemia.
5. Nephrotic syndrome.
6. Sheehan's syndrome or panhypopituitarism.
7. Vasovagal attack, fear, exposure to cold, intense emotion; increased carotenoid pigment.
8. Night workers.
9. Oedematous conditions, e.g., anasarca.
10. Thick skin (e.g., scleroderma).

* ***Pallor*** may be associated with or without anaemia :
  a) Pallor with anaemia— All types of severe anaemia, SBE etc.
  b) Pallor without anaemia— Described above.

Mention causes of constipation in clinical practice :

(A) Acute : Intestinal obstruction; acute abdomen.

(B) Chronic :
  a) Faulty habits, lack of physical activity, less intake of fibre; less access to toilet facility.
  b) Painful anal conditions e.g., anal fissure; proctitis.
  c) Obstructive lesions like carcinoma, stricture.
  d) Disturbed motility : irritable bowel syndrome, systemic sclerosis, pregnancy, myopathy, Chagas' disease, parkinsonism, spinal injury.
  e) Metabolic : Hypothyroidism, hypokalaemia, hypercalcaemia.
  f) Drugs : Antidepressants, codeine, iron and calcium supplements, aluminium containing ant-acid, calcium channel blockers.

* Though difficult to define, constipation is the infrequent passage of hard stools or stool frequency < 3 times/week (highly subjective).

Cardiovascular signs in myxoedema :

1. Pulse— Sinus bradycardia.
2. BP— Systolic pressure may be high due to hypercholesterolaemia and atherosclerosis (with or without xanthelasma). There may be diastolic hypertension.
3. Features of CCF (rare).
4. Cardiomyopathy.
5. Features of pericardial effusion, rarely.

* Patient may complain of anginal pain or exertional shortness of breath.

Why there is cardiomegaly in myxoedema ?

1) Cardiac dilatation, 2) Pericardial effusion, or 3) Cardiomyopathy.

Dermatological manifestations in myxoedema :

Non-pitting oedema of hands and feet, periorbital puffiness, dry and lustreless skin with alopecia, purplish lips, malar flush, xanthelasma, carotenaemia and occasionally erythema ab igne.

Features in nervous system :

1. Higher function—
   (i) Poor memory, delayed cerebration.
   (ii) Psychosis (myxoedema madness).
   (iii) Depression.
   (iv) Myxoedema coma.
   (v) Mental confusion, convulsions due to syndrome of inappropriate ADH secretion (SIADH) - Rare.
2. Speech— Slow (bradylalia), sluggish and hoarse.
3. Cranial nerves— Nerve type of deafness.
4. Cerebellar ataxia.
5. Hypotonia.
6. **Ankle Jerk— Delayed relaxation** (myotonic reflex); at times there is 'hung-up reflex'.
7. Entrapment neuropathy— Carpal tunnel syndrome.
8. Myotonia (Hoffman's syndrome)— Painful cramps in muscles; proximal myopathy
9. Muscle stiffness, and aches and pains in. muscle; percussion myoedema (a small ridge of temporary swelling at the point of stimulation by hammer).
10. Rarely, pseudomyotonia.
11. Peripheral neuropathy rarely.
12. Unmasking of myasthenia gravis.
13. Hypokalaemic periodic paralysis.

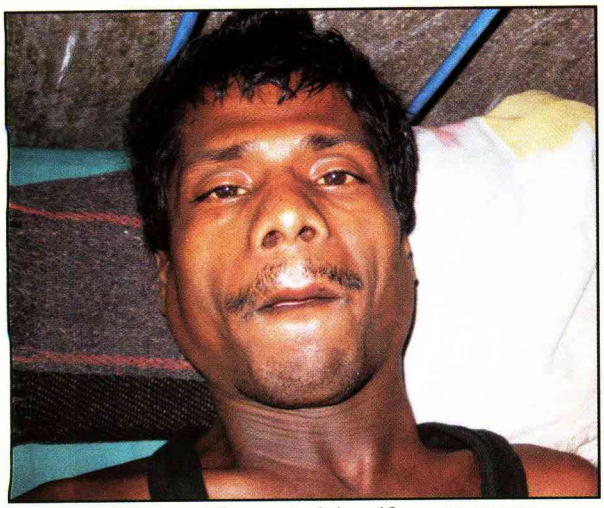

A patient of **chorea** at the onset of choreiform movement

Catatonic patient (hypertonia) holding a rigid posture for hours. It is the admixture of psychic and motor disturbance

Tetanus with a fixed sardonic smile (risus sardonicus or smile of 'Satan') – the smile does not reach the eyes

Multiple neurofibroma

"Main d' accoucheur" or carpal spasm in **tetany**

Gibbus – acute angulation of vertebra; here it is due to metastasis from lung

Pectus excavatum or **funnel chest**

Emaciation evidenced by wasting (eg, supraspinatus), winging of the scapulae (prominent medial border) and vertebral prominence in pulmonary tuberculosis

Pectus carinatum or **pigeon chest.** Rickety rosary and Harrison's sulcus are seen in a patient of **rickets**

Kyphoscoliosis with **winging of the scapula**

What is myxoedema coma ?

It is a rare but dangerous presentation of myxoedema, seen usually in elderly during winter months, due to acute thyroid hormone deficiency and is characterised by,

1. Hypothermia (body is cold and dry without any shivering)—temperature as low as 80°F,
2. Hypotension,
3 Hyponatraemia,
4. Hypoventilation,
5. Hypoxia,
6. Hypoglycaemia,
7- Bradycardia,
8- Convulsions,
9- Unconsciousness.

There is very high mortality (50%) and survival depends upon early recognition and treatment.

What is subclinicat hypothyroidism?

The patient is asymptomatic and clinically euthyroid but biochemically T_3 and T_4 are in the lower limit of normal with high TSH.

Carotenaemia (carotenoderma) and its clinical associations .

Carotenaemia is the presence of increased amount of carotene within the body. It is seen in •.

1. Eating large quantities of carrots, oranges, papaya, mango and other vegetables e.g., squash.
2. Hypothyroid (due to impaired metabolism of carotene in the liver).
3. Diabetes mellitus.
4. Receiving p-carotene for the treatment of erythropoietic porphyria.
5. Anorexia nervosa.
6. Simmond's disease.
7. Castrated male.

It produces an orange-yellow or lemon-yellow colour of skin specially of face, palms and so es. Sclera never turns yellow (D/D of jaundice).

Table 30 : Differentiation between primary and secondary hypothyroidism :

	Features	Primary	Secondary
1.	Skin	Thick and without wrinkles	Thin with fine wrinkles
2.	Hair	Coarse	Fine
3.	Menstrual irregularities	Menorrhagia	Amenorrhoea
4.	Secondary sexual characters	Normal	Poor
5.	Heart size	May be enlarged	Small
6.	Goitre	May be present	Absent
7.	Soft tissue oedema	Marked	Absent
8.	Blood pressure	Normal or high	Low
9.	Cholesterol	Increased	Normal
10.	TSH	High	Low
11.	Plasma cortisol	Normal	Low
12.	TRH stimulation test	Exaggerated response	No response
13.	Thyroid autoantibodies	May be present	Absent

* TO DIAGNOSE PRIMARY AND SECONDARY HYPOTHYROIDISM CLINICALLY, ONE SHOULD EXAMINE THE SKIN, HAIRS, SECONDARY SEXUAL CHARACTERS AND SOFT TISSUE OEDEMA.

What is juvenile myxoedema ?

In this condition, hypothyroidism starts during childhood and adolescence period (before puberty) but the thyroid function is normal at birth or infancy. There is delayed puberty, growth retardation with delayed bone age and galactorrhoea.

How will you investigate the case ?

1. Blood—
   a) Low Hb (usually normocytic normochromic, or macrocytic) and low RBC count.
   b) Cholesterol— High (> 200 mg/dl).
2. Chest X-ray— Cardiac shadow may be enlarged

2 ecg_____

' a) Low voltage (R-waves in limb leads are < 5 mm and that in precordial leads are <10 mm).

b) Sinus bradycardia.
c) Non-specific ST-T changes.

4. Plasma TSH estimation— Elevated in myxoedema (normal value 0-3-5 nU/ml).
5. Plasma T_3 and T_4 estimation— Low in myxoedema.
(normal value of T_3 is 80-150 ng/ 100 ml and that of T_4 is 4-12 jig/100 ml).
6. Radioactive Iodine 131 uptake by the thyroid gland is reduced.

now-amdayf.ram (lnStmmental ^cording of jerks)- Delayed relaxation of ankle jerk; not used

8. Muscle enzymes— Elevated LDH, SGOT (AST) and CK.
9. FNAC and USG of thyroid gland in selective cases may be helpful.

* 1°' ThV°id Peroxldase (TPO) antibodies may be demonstrated in Hashimoto's thyroiditis

, ,,lrun? ^3 d°es not discriminate reliably between euthyroid and hypothyroid patients and ideallv should not be measured in a case of myxoedema. pauenis, ana ideally

D/D of myxoedema :

1. Ageing.
2. Nephrotic syndrome.
3. Angioneurotic oedema.
4. Post menopausal syndrome.

How to treat this case ?

50 ug11^ncremen^al0?6^ 50 mg of L-thyroxine (i.e., T_4) is recommended and can be increased by 25-t>U ng increments at 2-3 weeks interval until an euthyroid state is attained and the dose is "then maintained In majority, usually the maintenance dose is 100-150 ng/day. The drug is given as a

iSnf Sf faT °f ltS l0ng halflifC (? daysS)_ Thera Pv should usually be uninterrupted and e long. Efficacy of replacement therapy is measured by serum TSH level.

If the patient suffers from angina pectoris, start the dose with 25 tig and increase bv 25 ***ue*** at 4 weeks interval with performing serial ECGs. Increased dose may preJpitate anginal pain Dul pregnancy, an increase in T_4 dosage about 25-50 ng is often needed. g P g

How to treat myxoedema coma ?

It is a medical emergency and should be treated promptly.

'■ IJ,1°H0tl?yr,°ni;ne~20 LV b°1US iS followed by 20 Mg every 8 hourly, I.V until there is sustained clinical improvement (thyroxine is usually not available for parenteral use; if available, T_4 is given as I.V bolus in a dose of 400-500 ng). If I.V preparation of T is unavailable T may be given 300 |ig stat orally and followed by 100-300 ng daily. '4

2. Hydrocortisone hemisuccinate—100 mg, I.V, 8 hourly.
3. I.V saline infusion— To combat hypotension; monitor cardiac output.

4' ***room*** °rt hyp0thermla~ Slow swarming of the patient by wrapping with a blanket in a warm

5. High-flow oxygen or assisted ventilation. Correct hypoglycaemia and electrolytes imbalance.
• reatment of arrhythmias and heart failure accordingly, preferably in an ICU.
7. Antibiotics, as infection is very often the precipitating factor

Recovery within 24 hours is usual. Lifelong T_4 replacement is required after recovery.

Identification points :

eyelld.Tnd hoa"edTM,SeCl °b'" pa"enl haVB,g puffy' "Passionless face wtth baggy lower

Lh **Ip16** 'en<*OC$_T$r'ne system' **comprises of** 1. **Hypothalamus and pituitary 2. Thyroid gland 3 Parathv**

Xt«"doSL7cXCreaS ^ Adrena' gla"dS 6_ tissue or mass

Case 70

HYPERTHYROIDISM

Common causes of hyperthyroidism (thyrotoxicosis) :

1. **Graves1 disease (diffuse toxic goitre).**
2. **Solitary toxic nodule (adenoma).**

3. Toxic multinodular goitre.
4. Subacute thyroiditis.
5. TSH producing pituitary adenoma.

* The word goitre comes from Latin 'gutter' means throat.

Confirmation of the neck swelling as goitre :

Ask the patient to swallow and note whether the swelling moves upwards on swallowing (because of its attachment to the larynx). Neck swellings which move upwards on swallowing are thyroid, thyroglossal cyst, subhyoid bursitis, pretracheal and prelaryngeal lymph nodes fixed to trachea and larynx respectively. Thyroglossal cyst also moves upwards with the protrusion of tongue.

* Normal adult thyroid gland weighs 20-25 gm.

Examination of the thyroid gland :

(A) INSPECTION : Note the position, diffuse or localised nature of swelling, extent, shape, size, overlying skin (dilated veins, thyroidectomy scar, local signs of inflammation) of the swelling which is present in the neck; as a thyroid swelling moves upwards on swallowing, look for the inferior border as soon as the gland moves up.

(B) PALPATION **from the behind** :
At first, palpation of the thyroid gland should always be done from the behind on a sitting patient by using both hands (specially, the pulps of the fingers) with slight flexion of the neck (to relax the sternomastoid muscles), and thumbs placed over the nape of the neck. Note the size, shape, consistency, mobility etc.

(C) PALPATION **from the front** :
Expose the neck properly and extend the neck slightly. Often each lobe of the thyroid gland is better palpated from the front by **Lahey's method** e.g., for palpation of the right lobe, the gland is pushed to the right from the left side; the right lobe becomes more prominent and now palpated by the left hand. Henceforth, the following points are noted carefully :

a) Size - Small or large.
b) Shape - Localised or diffuse swelling, nodular or not.
c) Surface - Smooth or irregular.
d) Consistency - The different consitency are : soft (normal gland), firm (simple goitre), hard (carcinoma of thyroid) or woody feel (Reidel's thyroiditis); a cystic swelling may feel solid and a solid one cystic.
e) To get below the swelling - Ask the patient to swallow again (to test the possibility of retrosternal extension).
f) Mobility - Fixed or mobile (the gland is moved horizontally and vertically). Mobility is lost in carcinoma of thyroid with infiltration.
g) Tenderness - Tender (thyroiditis, bleeding within cyst) or non-tender.
h) Relation with the neighbouring structures (pressure effect, fixity etc) ;
   (i) Trachea - Deviated or not.
   (ii) Carotid sheath - Carotid pulsation is increased in Graves' disease whereas the pulsation may not be felt in a patient with thyroid carcinoma.
   (iii) Oesophagus - C/O dysphagia.
   (iv) Recurrent layngeal nerve - May produce hoarseness of voice.
   (v) Sympathetic trunk - Produces Horner's syndrome (pseudoptosis, miosis, anhidrosis of ipsilateral face, and enophthalmos).
   (vi) Sternomastoid muscle.
   (vii) Skin and subcutaneous tissue.
i) Thrill - Present over the thyroid gland (present in Graves' disease due to increased vascularity).

(D) PERCUSSION : Though not very helpful, percussion of the sternum may be done to detect the presence of retrosternal goitre (read the section on 'Percussion of the sternum or base of the heart'). Changing the percussion note from resonant to dull indicates the possibility of retrosternal goitre.

(E) AUSCULTATION : Search for systolic bruit over the thyroid gland (present in Graves' disease). Ask the patient to hold his breath and then auscultate. Presence of systolic bruit in the thyroid gland may be confused with carotid bruit or venous hum.

(F) MEASUREMENT : Measure the circumference of the neck by a tape at the most prominent part.

* The isthmus which lies in front of 2nd, 3rd and 4th tracheal rings, is better palpated from the front.

** **Thyroid bruit**—more prominent in upper part of neck than lower part (as superior thyroid artery arises from external carotid artery); **Carotid bruit**—obviously more prominent in lower part of neck (over common carotid artery) than upper part; **Venous hum**—disappears on gentle pressure applied over base of the neck.

*** *Hyperthyroidism is often associated with goitre (diffuse or nodular).*

**** Cervical lymph nodes should always be palpated to exclude metastasis from thyroid carcinoma.

Pemberton's sign :

Ask the patient to raise both arms above the shoulders until they touch the ears and to keep them in that position for sometime. Facial congestion (plethora), central cyanosis, respiratory distress with stridor, and venous congestion of neck occurs in patient with retrosternal goitre, and is known as Pemberton's sign; it is due to obstruction of great vessels (by pressure effects of retrosternal goitre on arm raising) at thoracic inlet. This test should not be done routinely.

Why do you say that it is Graves' disease ?

As there is presence of exophthalmos and diffuse goitre, it is a patient of Graves' disease.

What is simple diffuse goitre?

It is goitre with no sign of toxicosis, and the causes are iodine deficiency, puberty goitre and use of goitrogens (drugs like amiodarone, lithium, PAS and vegetables like cabbage, cauliflower, turnips).

Features of ophthalmopathy and dermopathy ;

Graves[1] disease is characterised by the classical triad of hyperthyroidism, ophthalmopathy and dermopathy.

I. Ophthalmopathy — Read the section on 'Exophthalmos'.

II. Cutaneous manifestations in Graves' disease :

1. Skin— Warm, hyperhidrotic and moist hand (due to cutaneous vasodilation); palmar erythema, rarely spider naevi, malar flush.
2. Hair— Friable, fine and silky; alopecia.
3. Nails— Separation of the distal margin of the nail from its nail bed (Plummer's nail).
4. Pretibial myxoedema— The affected area (over the shin) is raised, thickened, hyperpigmented and indurated plaque with "peau d'orange" appearance along with growth of coarse hair.
5. Pigmentation— Hyper- and hypopigmentation (vitiligo) may be seen.

6- Thyroid acropachy— Clubbing of the fingers with bony changes resembling hypertrophic osteoarthropathy may accompany the dermal changes in distal extremities.

Physical findings in CVS in Graves' disease :

1. Pulse -
   - (i) Tachycardia (persists even when the patient is sleeping, i.e., high sleeping pulse rate).
   - (ii) High volume collapsing pulse which may be of water-hammer in character (due to wide pulse pressure), capillary pulsation,
   - (iii) Atrial fibrillation (irregularly irregular pulse), ectopics.
   - (iv) Carotid dance and suprasternal pulsation (due to hyperkinetic circulatory state).
   - (v) Other points in pulse — Usually within normal limit.
2. Signs of congestive cardiac failure (high output failure and often refractory) may be present.
3. Heart -
   - (i) Apex— Hyperdynamic and present in normal position.
   - (ii) Sj and P_2 may be loud (due to tachycardia).
   - (iii) Murmur— Systolic murmur at the apex (due to increased blood flow).
   - (iv) Means-Lerman scratch — To-and-fro scratchy sound is heard in the pulmonary area in midsystole (possibly due to rubbing of pleura and pericardium as a result of hyperkinetic circulatory state mimicking pericardial rub). It is rarely found.

* Common symptoms related to CVS are (i) Palpitation with sweating, (ii) Angina pectoris, and (iii) Dyspnoea due to CCF. *Sleeping pulse rate is important to determine the severity of thyrotoxicosis.*

Gastrointestinal manifestations in Graves' disease :

Loss of weight in spite of normal or increased appetite, hyperdefecation as well as diarrhoea and steatorrhoea, vomiting.

Possible causes of increased sleeping pulse rate :

1. **Thyrotoxicosis.**
2. **Rheumatic carditis.**
3. **Atrial fibrillation.**
4. **Pulmonary tuberculosis (active).**
5. **Atropinised patient.**
6. **Myocarditis due to any cause.**
7. **Fever due to any cause.**
8. **Bleeding (internal).**

Three cardinal signs of Graves' disease :

1. **Tachycardia,**
2. **Tremor, and**
3. **Exophthalmos.**

N.B. : *Examine these three signs in all patients with hyperthyroidism.*

*** Robert J. Graves (1796-1853) was a physician, Meath Hospital, Dublin, Republic of Ireland.**

Fades in thyrotoxicosis :

Better known as 'stare'; an anxious startled look due to lid retraction (agitated or terror face). Exophthalmos and other eye changes like Infrequent blinking may be noted. Moist facial skin with a malar flush is sometimes seen and may be associated with a goitre in the neck.

Clinical features regarding involvement of nervous system :

(A) Symptoms-

1. **Insomnia, nervousness, emotional lability or hyperirritability; perspiration.**
2. **Hyperkinesia.**
3. **Depression, mania or psychosis.**
4. **Difficulty in rising from squatting position or climbing upstairs (due to proximal muscle weakness).**
5. **Stupor or coma (thyroid storm).**

(B) Signs-

1. **Fine tremor (most prominent feature) - Tested in outstretched hands and in protruded tongue. In severe cases, the whole body may be shaking and trembling.**
2. **Proximal muscular weakness and wasting - Thyroid myopathy'.**
3. **Myasthenic syndrome and hypokalaemic periodic paralysis may occur.**
4. **Chorea.**
5. **Deep reflexes - Exaggerated.**
6. **Pseudoclonus or ill-sustained clonus.**
7. **Plantar response - Flexor.**

Differential diagnosis of thyrotoxicosis :

(A) Anxiety neurosis is the commonest differential diagnosis (having tremor in both) :

		Anxiety neurosis	Thyrotoxicosis
1.	**Appetite**	1. **Diminished**	1. **Increased (but there is weight loss)**
2.	**Hand**	2. **Cold and moist**	2. **Warm and moist**
3.	**Sleeping pulse rate**	3. **Normal**	3. **Raised**
4.	**Pulse pressure**	4. **Normal**	4. **Increased**
5.	**Goitre**	5. **Not present**	5. **Present**
6.	**Eye signs**	6. Absent	6. **Present**

(B) Other conditions where there is rapid weight loss are :

1. **Diabetes mellitus.**
2. **Pulmonary tuberculosis.**
3. **Malabsorption syndrome.**
4. **Malignancy.**
5. **Pheochromocytoma.**
6. **AIDS.**

(C) Chronic alcoholism — Tremor, tachycardia, sweating, emotional lability in alcoholism often resemble thyrotoxicosis.

Examination of *neck' in clinical medicine :

1. Swelling like branchial cyst, sternomastoid tumour, cystic hygroma, carotid body tumour, Ludwig's angina, dermoid cyst etc. are of surgical interest.
2. Skin—Scar, old tracheostomy mark, signs of inflammation, fistula (branchial), sinus, actinomycosis (rare), pityriasis versicolor, Casal's collar, acanthosis nigricans, acrochordons etc.
3. Enlargement of the thyroid gland (page-401).
4. Lymph nodes (page-223).
5. Salivary glands.
6. Neck vessels (page-345).
7. Examination of trachea (page-75); tracheal tug (page-49).
8. Neck rigidity (page-152).
9. Short neck (associated with low hair line) is found in cranio-vertebral anomaly, e.g., platybasia, Klippel-Feil anomaly (page-169).
10. Great auricular nerve—thickened in tuberculoid leprosy (by turning the head to the opposite side, the nerve stands out).
11. Spasmodic torticollis (page-466) or other abnormal movements (e.g., tics).
12. Suprasternal pulsation, carotid dance (page-39 and 41).
13. Webbing of neck in Turner's syndrome.
14. Swelling of neck in conditions like SVC obstruction, subcutaneous emphysema, bull-neck (malignant diphtheria).
15. Deglutition (to confirm a thyroid swelling).
16. Power testing of neck muscles e.g., sternomastoids (page-471); wasting of sternomastoid muscle in myotonic dystrophy.
17. Restriction of neck movement along with pain (flexion, extension, rotation, side-bending) occurs in cervical spondylosis, ankylosing spondylitis, atlanto-axial dislocation.
18. Ciliospinal reflex (page-448).
19. Auscultation—thyroid bruit, carotid bruit, venous hum (page-402); auscultation over trachea.

* First palpate the back and sides of neck, which are better palpated from the front; then the patient is allowed to sit on a stool and the examination (i.e., palpation) is carried out from behind.

Mention the investigations you like to perform In hyperthyroidism :

1. Serum T_3 and T_4 (free and total both) are increased. TSH is very low (< 0.05 ^xU/ml or may be undetectable).
2. Radioactive Iodine (I^{131} or I^{132}) uptake (RAIU) is increased.
3. Resin T_3 uptake (RT_3U) is increased.
4. Free thyroxine index (FTI) is increased (FTI = serum T_4 x RT_3U).
5. T_3 suppression test - After the administration of T_3, the iodine uptake is not suppressed.
6. Serum TSH level after TRH administration - Blunted response (very helpful test).
7. ECG - Shows sinus tachycardia, ectopics, and / or atrial fibrillation.
8. Thyroid (radionuclide) scan - Done by technetium 99m which shows localised or generalised increased uptake. It is useful in suspected cases of functioning thyroid nodule.
9. Others -
   - (i) Anti-thyroglobulin antibodies—Raised (also elevated in Hashimoto's thyroiditis).
   - (ii) BMR is increased (normal BMR in male is 40 calorie / sq. meter of body surface / hour).
   - (iii) Serum PBI Is increased (normal level is 3.6 - 8.5 (ig/dl) — not used now-a-days.
   - (iv) Low serum cholesterol.
   - (v) Serum LATS (long acting thyroid stimulator) is increased—not routinely used.
   - vi) Antibodies against thyroid peroxidase (TPO) enzyme and thyroglobulin are present in most cases of Graves' disease.
   - (vii) Measurement of TSH receptor antibodies (TRAb) to determine the aetiology.
   - (viii) Needle aspiration of thyroid nodule in selected cases.
   - (ix) High urinary as well as serum calcium and phosphate.
   - (x) Raised SGPT (ALT), alkaline phosphatase, bilirubin; glycosuria ('lag storage').

* In 5% patients of thyrotoxicosis (T_3 toxicosis) serum T_3 is much raised but T_4 remains in the upper limit of normal range.

Table 31 : Clinical differentiation between primary (Graves' disease) and secondary thyrotoxicosis

Features	Graves' disease	Toxic nodular goitre
1. Age	1. < 35 years	1. > 35 years.
2. Goitre	2. Smooth, diffuse enlargement	2. Nodular
3. Onset of symptoms	3. With goitre	3. Goitre first, symptoms later
4. Eye signs	4. Present	4. Absent
5. Cardiac symptoms	5. Slight	5. Severe
6. Neuromuscular symptoms	6. Prominent	6. Slight

Outline of management of thyrotoxicosis :

1. **Antithyroid drugs** - Propylthiouracil (100-200 mg, 6-8 hourly), carbimazole, methimazole, iodide or potassium perchlorate is used. While diminishing the toxicity, these drugs increase the size and vascularity of the thyroid gland. Carbimazole is the commonly used drug.
2. **Radioactive Iodine (I^{131})** —Usually 5-10 mCi of I^{131} is given orally; maybe repeated at 12 weeks.
   Indications -
   a) All patients > 40 years of age.
   b) Toxicity due to drugs or relapse after surgery.
   c) Thyrotoxic heart disease.
   Contraindications -
   a) During pregnancy and lactation (antithyroid drug is the best choice).
   b) In children.
3. Surgery (subtotal or near-total thyroidectomy).
4. General measures -
   (i) Good nutritious diet.
   (ii) **Propranolol** - Dosage upto 160 mg / day may be given. Propranolol antagonises the sympathomimetic manifestations and thus, it alleviates palpitation, tremor, sweating and lid retraction. Propranolol is contraindicated in CCF, heart block, bronchial asthma, peripheral vascular disease and diabetes.
5. For thyroid eye disease -
   (i) Low salt diet and diuretics, with elevation of the head end at night to reduce orbital oedema. Smoking should be stopped.
   (ii) Tinted glass with side frames (to protect the eyes from sun, wind and dust) to reduce lacrimation.
   (iii) 1% methyl cellulose and hypromellose eye drops for lubrication.
   (iv) Prednisolone — 40-80 mg / day with or without cyclosporin in malignant exophthalmos.
   (v) External irradiation or lateral tarsorrhaphy to prevent exposure keratitis.
   (vi) Orbital decompression or corrective eye muscle surgery, rarely.
6. For dermopathy (pretibial myxoedema) -
   (i) Hyaluronidase or triamcinolone (intralesional injection).
   (ii) Topical high potency corticosteroids with occlusive dressing.
   (iii) Ultra-violet radiation.
   (iv) Octreotide is being tried recently.

* Exophthalmos does not necessarily decrease after successful treatment of thyrotoxicosis.

How carbimazole is given ?

The usual dose is 10-20 mg, orally 2-3 times daily till the patient becomes euthyroid. Usually the patient becomes euthyroid in 6-8 weeks and the maintenance dose is then started as 10-15 mg/day *Jor 12-18 months.* The maintenance dose is determined by the measurement of T_4 and TSH.

Side effects — Agranulocytosis (patient complains of sore throat), drug rash, drug sensitivity, hepatitis, drug fever, arthralgia etc.

* Leucopenia or agranulocytosis is the most dangerous complication of antithyroid drugs. If the absolute neutrophil count is <1500 / mm^3 of blood, antithyroid medication should be discontinued.

Use of beta-blockers in internal medicine :

Remember the indications from head to foot as,

1. Anxiety states.
2. Migraine (as prophylaxis).
3. Glaucoma (chronic open-angle).
4. Thyrotoxicosis.
5. Prevention of vartceal haemorrhage (i.e., portal hypertension).
6. Cardiovascular system— Systemic hypertension, angina pectoris (stable and unstable), myocardial infarction, cardiac arrhythmias (specially tachyarrhythmias), hypertrophic obstructive cardiomyopathy (HOCM), mitral valve prolapse syndrome (MVPS), dissection of aorta, cyanotic spells of Fallot's tetralogy.
7. Essential tremor.
8. Pheochromocytoma.
9. Alcohol withdrawal syndrome.

Thyroid storm or thyrotoxic crisis :

It is an extreme degree of hyperthyroid state precipitated by surgery, infection, severe stress, or develops spontaneously in patients with hyperthyroidism. The patients usually suffer from restlessness, delusions, hyperpyrexia, delirium, tachyarrhythmias, hypotension, vomiting, diarrhoea and often coma, and may succumb from heart failure, arrhythmias and hyperpyrexia..

Identification points (thyrotoxicosis) :

1. Goitre with exophthalmos is the first clue—the patient looks anxious, restless and fidgety.
2. Nov/ examine for tremor and tachycardia.
3. Never forget to examine the jerks.

* **If thyrotoxicosis is given as a long case,** examine the patient in the following way :

(A) General survey (specially nutrition, facies, neck glands, pulse, BP, skin and appendages).

(B) Examination of the thyroid gland and eye.

(C) Systemic examination :

a) CVS,

b) Nervous system,

c) G.I. system,

d) Respiratory system, and

e) Reticulo-endothelial system.

' ' **Hyperthyroidism** indicates glandular hypertrophy of thyroid; **thyrotoxicosis** is increased circulating free thyroid hormones along with toxic features.

*** Heat intolerance is a common general symptom of hyperthyroidism.

Lndocrinal emergencies in clinical practice are thyroid storm, myxoedema coma, pituitarv apoplexy, ectopic ACTH syndrome, Nelson's syndrome. Read the section on 'Diabetes mellitus' for diabetic emergencies.

Case 71

EXOPHTHALMOS

What is exophthalmos ?

It is the forward protrusion of the eyeball when a portion of the sclera is visible above and below the cornea. Previously, it was defined as the visibility of the ***lower sclera*** of more than 2 mm when the patient looks straight forward (few clinicians still believe this definition).

In exophthalmos (unilateral), the globes appear asymmetric.

How the exophthalmos is tested at the bedside ?

1. The patient is asked to look straight forward. The examiner stands **in front of the patient** and the visibility of the upper and lower sclera is noted. **The visibility of the lower sclera**

is more important as in thyrotoxicosis, the presence of lid retraction (contraction of Muller's muscle), may give the false impression of exophthalmos.

2. The examiner stands **behind the patient,** tilts the patient's head backwards and looks vertically down the slanting forehead in the plane of superciliary ridges. Thus, one may be sure whether any part of the eyeball (globe) is visible (proptosis) or not. This is known as **Naffziger s sign.**

* *According to Jew clinicians, exophthalmos and proptosis carry the same message.*

****** In health, one-third of the cornea is covered by the upper eyelid.

What are the common causes ***of exophthalmos*** ?

(I) Unilateral :

1. Early thyrotoxicosis.
2. Retrobulbar tumour.
3. Cavernous sinus thrombosis.
4. Chloroma (AML); malignant and lymphomatous deposits.
5. Orbital 'pseudotumour'.
6. Varicosity of orbital vein, carotico-cavernous fistula, aneurysm of orbital vessels, orbital haemorrhage.
7. Orbital cellulitis.

* So. both eyes are not necessarily affected simultaneously in exophthalmos.

(II) Bilateral :

1. Thyrotoxicosis.
2. Bronchial asthma (long standing).
3. SVC syndrome.
4. Cirrhosis of liver (few cases).
5. Cushing's syndrome.
6. Craniostenosis (e.g., oxycephaly).
7. Cavernous sinus thrombosis (bilateral).
8. Hand-Schuller-Christian disease, nasopharyngeal carcinoma affecting both the orbits.

N.B. : Commonest cause of exophthalmos is thyrotoxicosis whether it is unilateral or bilateral; 2, 4 and 5 of (II) produce apparent exophthalmos due to lid retraction.

* Cavernous sinus thrombosis = chemosis of conjunctiva, exophthalmos, ptosis, ophthalmoplegia, papilloedema and reduced sensation in ophthalmic division ol trigeminal nerve.

** Intermittent proptosis : orbital varix, recurrent orbital haemorrhage, periodic orbital oedema.

*** Pseudoproptosis : shallow orbits, pathological myopia and contralateral enophthalmos.

Other eye signs in thyrotoxicosis :

Eye signs in Graves' disease are divided into two parts : 1) Spastic (staring look, lid lag, lid retraction) and 2) Mechanical (proptosis, ophthalmoplegia and congestive oculopathy).

1. Widening of the palpebral fissure.
2. **von Graefe's sign** (lid lag) — When the patient is asked to look downwards suddenly, the upper eyelid lags behind (exposing the sclera between the upper eyelid and cornea).
3. **Joffroy's sign** — Absence of wrinkling on the forehead on looking upwards (head must be fixed).
4. **Moebius's sign** — Lack of convergence of the eyeball (the test for accommodation is done and Moebius's sign is elicited).
5. **Stellwag's sign** (staring look) — Infrequent blinking.
6. **Dalrymple's sign** (lid retraction) — This is equivalent to visibility of the upper sclera when the patient looks forward.
7. **Jendrassik's sign—**Paralysis of extraocular muscles.

* Bilaterally dilated pupil may be found as a result of sympathetic overactivity.

** Swollen extraocular muscles (typical of Graves' disease) and other features of thyroid eye disease are detected by orbital USG or CT scan. The development of unilateral proptosis usually implies a space-occupying lesion and warrants urgent CT scan or MRI of orbit.

Ocular complaints in Graves' disease :

1. Excessive lacrimation.
2. **Grittiness or pain in eyes.**
3. Redness of eye.
4. Photophobia.
5. Diplopia.
6. **Ophthalmoplegia.**
7. Squint.
g Loss of visual acuity.

Table 32 : Classification of ***eye changes in Graves' disease***

This classification was done by American Thyroid Association. Remember the acronym 'No SPECS'.

Class	Mnemonics	Definition
O	(N)	No signs, no symptoms
1	(O)	Only signs (lid retraction, lid lag), no symptoms
2	(S)	Soft tissue involvement (symptoms and signs)
3	(P)	Proptosis > 22 mm (measured by Hertel exophthalmometer)
4	(E)	Extraocular muscle involvement (external ophthalmoplegia e.g., having diplopia)
5	(C)	Corneal involvement (ulceration)
6	(S)	Sight loss (optic nerve involvement)

Extraocular muscles : earliest affection — inferior rectus, least affection—lateral rectus

Causes of pulsating exophthalmos :

Carotico-cavemous fistula and saccular aneurysm of ophthalmic artery.

Physical examination in exophthalmos (from thyrotoxicosis) ;

1. Warm and moist hand.
2. Pulse rate - Whether tachycardia present or not.
3. Tremor - Ask the patient to stretch out the arms and to spread the fingers. Look for the presence of fine tremor. One may examine the protruding tongue for fine tremor.
4. Goitre present or not (also examine for the presence of systolic thrill and / or bruit present over thyroid gland).
5. CVS - See the section on 'Hyperthyroidism'.
6. Jerks - Exaggerated.

* One should examine these 6 points in all patients with exophthalmos. Features like warm and moist hand, tachycardia, tremor, exaggerated jerks and goitre are evident in Graves' disease.

What is exophthalmic ophthalmoplegia ?

It is the presence of exophthalmos, chemosis of conjunctiva (oedema of conjunctiva and injection of sclera) and weakness of extraocular muscles (sparing pupillary and ciliary muscles) leading to diplopia and squint.

Pathophysiology : Proliferation of fibroblasts within the orbit -> secretion of glycosaminoglycans (ydrophilic) -> increase in interstitial fluid volume -> associated infiltration of chronic inflammatory cells swelling of the extraocular muscles increase in retrobulbar pressure.

What is malignant exophthalmos ?

Progressive bulging of the eyeballs, conjunctival oedema, exposure keratitis with corneal ulceration and visual loss are features of malignant exophthalmos.

What is enophthalmos ?

Ir^^hlS condltion' the eyeball is retracted inwards or recessed within the orbit. It is very rarelv seen. The common causes are,

1. Phthisis bulbi (shrinkage of the eyeball from prolonged endophthalmitis) or microphthalmos.
2. Horner's syndrome.
3. Old age (due to atrophy of orbital fat) - physiological; trauma, emaciation.
4. As a consequence of resolved orbital cellulitis.
5. Severe dehydration (facies Hippocraticus).
6. Fracture of the orbital floor.

* Management of ophthalmopathy has been described in the section on 'Hyperthyroidism'.

Case 72

CUSHING'S SYNDROME

What is Cushing's syndrome ?

It Is a syndrome with symptom complexes and signs, produced due to prolonged inappropriate elevation of free corticosteroid in the circulation. Commonly it is due to therapeutic administration of steroids or ACTH (iatrogenic). Non-iatrogenic (i.e., Cushing's disease or adrenal adenoma) Cushing's syndrome is rare.

* Harvey Cushing (1869-i939) was Professor of Surgery, Harvard University, Massachusetts, USA.

Diagnosis of the case by inspection :

The disease is four times more common in women than men.

1. Moon face (dusky and plethoric too; excess hair in face).
2. Obesity (truncal obesity with thin limbs).
3. Buffalo hump.
4. Purple striae.
5. Proximal myopathy.
6. Hirsutism in females.

Describe the clinical features of Cushing's syndrome :

I. Fat deposition -
   a) Obesity - Weight gain is the commonest symptom and thus, obesity is the most frequent sign. There is centripetal (like a lemon on matchstick) deposition of adipose tissue though generalised obesity is not uncommon. Fat deposition in the mesenteric bed produces 'truncal obesity'. The fat deposition spares the extremities.
   b) Moon facies - Due to fat deposition in the upper part of the face (supramalar region).
   c) Buffalo hump - Due to deposition of fat in the interscapular area (upper part).

II. Skin and hair changes -
   a) Plethoric appearance - Due to thinning of the skin and rarely due to associated polycythemia.
   b) *Purple* striae - Commonly seen over abdomen, buttocks, breast, thigh and arms. This is produced due to break-down of collagen fibres in the dermis and thus, the vascularised subcutaneous tissues are exposed. These 'striae distensae' are often painful.

      [***White*** striae (striae albicantes) are usually observed following pregnancy, after paracentesis abdominis in ascites or when an obese person looses weight rapidly; ***pink*** striae are common during pregnancy and in simple obesity with rapid increase in weight].
   c) Easy bruisability and ecchymosis - Due to loss of perivascular supporting tissue (increased capillary faragility).
   d) Hyperpigmentation - This is due to excess MSH secretion found in bilateral adrenal hyperplasia secondary to pituitary tumour or ectopic ACTH secretion from non-endocrine tumours like bronchogenic carcinoma. This is not a very common feature.
   e) Thinning of hair.
   f) Increased incidence of skin infection (e.g., tinea versicolor).

III. Myopathy - Loss of protein in muscle leads to proximal myopathy (difficulty in combing hairs or getting up from squatting position).

IV. Bony changes - Osteoporosis is commonly seen in spine, ribs and femurs (due to loss of protein matrix of the bones); patient may present with backache (vertebral compression fracture).

V. Hypertension - It is due to the increased plasma volume and enhanced vascular response to catecholamines. This appears not to relate to sodium retention as previously believed. There may be ankle oedema or cardiomegaly.

VI. Diabetes mellitus - Due to antagonistic action of cortisol on insulin.

VII. Secondary sexual characters -
   a) Female - Hirsutism, acne, oligomenorrhoea or amenorrhoea, recession of temporal hair, clitoromegaly.
   b) Male - Loss of libido, impotence may be seen.

VIII. Psychiatric abnormality -
   a) Depression.

b) Emotional instability.
c) Irritability.

IX. Growth -
a) Growth retardation is a rule in children.
b) Diminution of height in adult patients may occur due to collapse of the vertebrae (as a result of severe osteoporosis).

X. Miscellaneous -
a) Cataract.
b) Peptic ulcer.
c) Poor wound healing with little inflammatory response.
d) Mild bilateral exophthalmos.
e) Electrolyte disturbance (T Na^+, 4- K+, J, Cl),
f) Avascular necrosis of bone.

Causes of moon face :

Read the section on 'Moon face'.

What is hirsutism, virilisation and defeminisation ?

(A) **Hirsutism** - It is the growth of terminal hair in women in a pattern characteristic of men.

(B) **Virilisation** (i.e., androgen excess in females)- The characteristic features are :
(i) Frontal baldness.
(ii) Increase in size of shoulder girdle muscles.
(iii) Coarsening of voice.
(iv) Acne and seborrhoea.
(v) Hirsutism,
(vi) Clitoromegaly.
(vii) Increased libido.

(C) **Defeminisation -**
(i) Reduction in breast size.
(ii) Loss of female body contours.
(iii) Amenorrhoea.

Causes of hirsutism :

1. Familial.
2. Indiopathic or simple hirsutism.
3. Cushing's syndrome, virilising ovarian tumour (e.g., arrhenoblastoma).
4. Polycystic ovarian disease (PCOD).
5. Adrenal androgen secreting tumour (adenoma, carcinoma), congenital adrenal hyperplasia.
6. Hyperprolactinaemia.
7. Acromegaly.
8. Drug-induced— Phenytoin, OC pills, androgens, diazoxide, cyclosporin, psoralens, minoxidil.
9. Menopause.

* Hirsutism is divided into two groups (i) with virilisation (severe PCOD, congenital adrenal hyperplasia, ovarian neoplasm), and (ii) without virilisation (other causes).

** Therapy is done by bleaching, waxing, electrolysis, laser, anti-androgens and treatment of cause.

What is Cushing's disease ?

It is the hypercortisoiism producing bilateral adrenal hyperplasia due to excess ACTH secretion from the anterior pituitary gland.

Hormones secreted from adrenal gland :

Adrenal glands comprise of an outer cortex and an inner medulla. The cortex is a part of hypothalamic-pituitary-adrenal axis, which scerete cortisol and adrenal andogen after getting signal from above. The cortex is divided into 3 zones.

(A) Cortex —
® Zona glomerulosa—mainly secrets aldosterone (mineralocorticoids)
® Zona fasciculata—predominanly secrets glucocorticoids
• Zona reticularis—mainly secrets sex steroids (androgen, oestrogen and progesterone)

(B) Medulla —
9 Produces catecholamines (adrenaline, nor-adrenaline and dopamine)

How do you like to investigate your case ?

1. Blood examination - Mild neutrophilic leucocytosis, eosinopenia and lymphocytopenia. Haematocrit may be high.

2. Electrolytes - Hypernatraemia, hypokalaemia, hypochloraemia, metabolic alkalosis.
3. Urine - Glucose may be present in urine and there is elevated urinary 17-hydroxycorticoids.
4. Glucose tolerance test - Impaired glucose tolerance. Diabetes is seen in < 20% patients.
5. X-rays :
   a) Spine - Osteoporosis in spine produces cod-fish vertebra or fish-mouth like appearance of intervertebral space. Osteoporosis is also seen in pelvis and skull.
   b) Chest - There may be superior mediastinal widening due to,
      (i) Bronchogenic carcinoma (produces ectopic ACTH) or bronchial carcinoid.
      (ii) Fat accumulation, or
      (iii) Tumour of thymus (may be associated with Cushing's syndrome).
   c) Skull - Enlargement of the pituitary fossa in Cushing's disease only.
6. CT or MRI scan of the abdomen (adrenal adenoma or carcinoma), brain (pituitary tumour) or chest.
7. Selective adrenal arteriography and venography - Not used now-a-days.
8. 19- [13lj] iodocholesterol scanning - Differentiates adrenal tumours from bilateral adrenal hyperplasia.
9. Plasma cortisol level - The normal blood level is 5-25 (ig/dl at 8 A.M. Normally, the cortisol level is lowest at 12 midnight but in Cushing's syndrome the level remains uniformly elevated throughout the 24-hours period (loss of the circadian rhythm).
10. Plasma ACTH level (at 8 A.M.) -
    (i) Very high level (> 300 ng/1) - Ectopic ACTH secretion due to malignancy (from small-cell carcinoma of the bronchus).
    (ii) Moderate level (80-300 ng/1) - Ectopic ACTH secretion from bronchial carcinoid (benign tumour) or pituitary dependent disease.
    (iii) Normal level (10-80 ng/1) or low level - Adrenal disease.
11. 48-hours low dose dexamethasone suppression test - This test is done in two stages. There is failure of complete suppression in Cushing's syndrome. This is a highly sensitive test.
12. Metyrapone test (exaggerated response is seen in Cushing's disease and the test is negative in Cushing's syndrome).
13. Insulin tolerance test — Insulin-induced hypoglycaemia does not stimulate the plasma cortisol level in Cushing's syndrome, which is a feature in normal healthy persons.
14. 24-hours urinary free cortisol excretion > 250 (ig/day is diagnostic (normal value < 90 |ag/day).
15. Demonstration of the adrenal tumour may be done by IVP, aortogram, retroperitoneal air insufflation (not practised now-a-days).

N.B. : i) Adrenal hyperplasia and ectopic ACTH syndrome are ACTH-dependent.
ii) Adrenal adenoma and carcinoma are not ACTH-dependent.

Differentiation of Cushing's syndrome from ectopic ACTH syndrome :

Ectopic ACTH syndrome will have :

1. Sudden onset.
2. Hyperpigmentation.
3. Oedema (more common).
4. Hypertension (more common).
5. Hypokalaemic alkalosis (more common).
6. Markedly elevated ACTH level (> 300 ng/1).

What is 'pseudo-Cushing's syndrome' ?

These patients often physically mimic Cushing's syndrome (Cushingoid appearance) and may have high urinary output of 17-hydroxycorticoids. They are : 1. Primary obesity, 2. Chronic alcoholism, and 3. Severe depression.

Management of your case :

I. Adrenal adenoma :

Surgically removed via a loin approach and suboptimal replacement therapy with 0.5 mg of dexamethasone is started for a variable length of time.

II. Adrenal carcinoma :

Resected as far as possible and the tumour bed is irradiated. Treatment with O, P'-DDD (2-3 g/day) is started immediately.

III. Cushing's disease :

(i) Trans-sphenoidal removal of the adenoma (treatment of choice).
(ii) Radical hypophysectomy - If no tumour is seen.

(Iii) Bilateral adrenalectomy with pituitary irradiation with yttrium-90 implantation to prevent the development of Nelson's syndrome.

IV. Ectopic ACTH secretion :

(i) Surgical removal or therapy of primary tumour (small-cell carcinoma of lung; tumour of the pancreas, thymus, ovary; bronchial carcinoid etc.)

(ii) 'MEDICAL OR CHEMICAL ADRENALECTOMY' is done by—

a) Metyrapone (2-3 g/day).

b) O, P'-DDD or mitotane (2-3 g/day).

c) Aminoglutethimide (1 g/day).

d) Ketoconazole (600-1200 mg/day).

* Mifepristone is a new treatment option for medical adrenalectomy.

V. Supportive therapy is done by :

(i) High protein intake.

(ii) Treatment of hypertension, diabetes mellitus, electrolyte imbalance etc.

(iii) Psychiatric treatment.

* Causes of death are : hypertension, myocardial infarction, heart failure and secondary infections.

What is meant by primary adrenocortical deficiency ?

It is known as Addison's disease (opposite to Cushing's syndrome) and is characterised by,

(i) Asthenia, weakness and weight loss (glucocorticoid deficiency),

(ii) Hyperpigmentation of buccal mucous membrane, face, new scars, palmar creases, pressure points (ACTH excess)—dull, slate-coloured, and

(iii) Hypotension (mineralocorticoid deficiency).

* ***i*** Cortisol ->T ACTH -»T melanin -» pigmentation; vitiligo (10-20%) may occur due to autoimmunity.

What is 'adrenal crisis' or acute hypoadrenalism ?

(A) It is a symptom complex of anorexia, nausea, vomiting, abdominal pain, fever, somnolence, hypovolaemic shock with low pulse volume and low BP, confusion or coma. It is commonly precipitated by,

(i) Infection or septicaemia.

(ii) Surgical stress.

(iii) Fluid loss (diarrhoea).

(iv) Sudden withdrawal of long-term corticosteroid therapy.

(B) It may be due to affection of the adrenal gland by,

(i) Tuberculosis,

(ii) Metastasis,

(iii) Autoimmune destruction, or

(iv) Surgical destruction.

(C) Treatment is done by.

(i) Hydrocortisone hemisuccinate 100 mg, I.V, 6 hourly for a few days.

(ii) Normal saline and 5% glucose drip — Several litres are required within the first few hours.

(iii) Dopamine as a vasoconstrictive agent.

(iv) Treatment of the precipitating cause e.g., antibiotics for infection.

(v) Mineralocorticoid replacemennt by fludrocortisone (0.1 mg, orally) after stoppage of saline.

* Bilateral adrenal haemorrhage from meningococcaemia (Waterhouse-Friderichsen syndrome) is a known aetiology.

What is Nelson's syndrome ?

10-20% patients of Cushing's syndrome undergoing bilateral adrenalectomy develop chromophobe adenomas with hyperpigmentation and erosion of the sella turcica in the subsequent years. The plasma ACTH level in these patients are extremely high. This syndrome does not occur if these patients are immediately treated with pituitary irradiation in addition to bilateral adrenalectomy. This condition is treated by surgery, radiotherapy and drugs (sodium valproate).

Classification of glucocorticoid preparations :

(A) Short-acting (1/2 life is < 12 hours) :

(i) Cortisol (hydrocortisone) (ii) Cortisone.

(B) Intermediate-acting (1/2 life is 12-36 hours) :

(i) Prednisone (ii) Prednisolone (iii) Methylprednisolone (iv) Triamcinolone.

(C) Long-acting (1/2 life is > 48 hours) :

(i) Paramethasone (ii) Betamethasone (iii) Dexamethasone.

N.B. : If the potency of cortisol is taken as 1, the potency of prednisolone will be 4 and that of dexamethasone will be 30-40; so dexamethasone is 8-10 times more potent than prednisolone.

Identification points :

1. Obesity.
2. Face :
   (i) Moon face.
   (ii) Dusky and plethoric.
   (iii) Hirsutism.

Case 73

ACROMEGALY

How to diagnose acromegaly by inspection ?

1. Prognathism (lantern jaw or bull-dog jaw) — Lower incisors (mandible) protrude in front of the upper incisors (maxilla), and widened spaces between upper and lower teeth; heavy chin.
2. Enlargement of the face as a whole with prominent supraorbital ridges as a result of enlargement of maxillary, frontal and ethmoid sinuses; frontal bossing.
3. Macroglossia with thick lips, large ears and fleshy nose (tongue may show indentations from the teeth); wide-spacing of teeth.
4. Thick skin with hypertrichosis (e.g., bushy eyebrows), hyperhidrosis and increased sebum production (greasy skin); exaggerated nasolabial folds.
5. 'Spade-shaped' hand (broad hand with thick, large, square-tip fingers) with warm, sweaty and doughy feeling; broad toes.
6. Deep, husky and resonant voice due to inceased thickness of vocal cord.

* It is a disease of middle age. Common complaints are headache, changes in appearance, visual-field defects, soft tissue swelling and increased sweating.

** Larger ears and nose are due to cartilagenous overgrowth.

*** Females may have a masculinized appearance with mild hirsutism.

**** Other causes of ***prognathism*** are ; Fragile-X syndrome, osteopetrosis (certain variety) and nemaline myopathy. In prognathism, lower teeth overbites the upper teeth.

Cranial nerve involvement in acromegaly :

1. Bitemporal hemianopia (pressure on optic chiasma)— Commonest.
2. Blindness due to optic atrophy (affection of optic nerve).
3. External ophthalmoplegia (paralysis of III, IV and Vlth cranial nerves).
4. Deafness (VUIth nerve palsy).

* So, visual field testing should be done in all cases of acromegaly.

** Other 'pressure effects' by the enlarged pituitary gland may be upward pressure to hypothalamus (polyphagia, polydipsia, thermal dysregulation), on temporal lobe (complex partial seizure), and features of raised intracranial tension.

Metabolic and circulatory changes in ***acromegaly :***

1. Glucose intolerance (25%).
2. Diabetes mellitus (10%), and
3. Hypertension (25%).

Investigations you like to perform :

(A) Hormone assay :

1. Radioimmunoassay shows increased basal level of GH (normal level upto 1 mU/L).
2. GH level fails to be suppressed < 1 mU/L during an oral glucose tolerance test (GTT).
3. Estimation of plasma somatomedin C level (i.e., IGF-1) by radioimmunoassay (almost always raised in acromegaly).

* Due to pulsatile nature of GH secretion, a single random GH level is not useful for diagnosis. In 30% patients, the serum prolactin level is elevated due to co-secretion by the tumour. In acromegaly, insulin-like growth factor 1 (IGF-1) levels are increased and the major biochemical effects of growth

hormone (GH) is mediated by IGF-1. Thus, atheromatous disease, colon polyps and carcinoma of colon may complicate acromegaly in the long run.

(B) Visual field examination—a common defect is bitemporal hemianopia.

(C) Radiological changes :

1. Skull (lateral view) -
   a) Enlargement of the pituitary fossa.
   b) Sometimes, there is double floor of pituitary fossa.
   c) Erosion of clinoid process.
   d) Prominent supraorbital ridges and jaw.
   e) Enlargement of the frontal and maxillary sinuses.
2. Extremities -
   a) Tufting of the terminal phalanges, i.e., 'arrow-head appearance'.
   b) Heel-pad thickness' is increased i.e., > 18 mm in women and >21 mm in men.
3. Spine - There is evidences of kyphoscoliosis and osteoporosis.
4. Chest - Cardiomegaly.
5. Ultrasonography of abdomen—Organomegaly (specially hepatosplenomegaly).
6. CT or MRI scan of brain to visualise pituitary gland—Reveals pituitary (macro-) adenoma.

(D) Biochemical :

1. Oral glucose tolerance test - Impaired.
2. Raised serum phosphorus and alkaline phosphatase level.
3. Elevated urinary calcium and hydroxyproline.

* ***Heli pad, thickness'*** is increased in obesity and oedema-producing states.

Assessment of 'activity' in acromegaly :

1. Increasing size of gloves, rings, hats or shoes.
2. Ill-fitting dentures.
3. Excessive sebum secretion.
4. Excessive sweating.
5. Increasing headache.
6. Increasing visual field defect.
7. Serial photography (gradually progressive macrosomia).
8. Rise in the plasma GH and somatomedin C levels.

What is gigantism ?

Hypersecretion of GH before the fusion of epiphysis is ***gigantism. Acromegaly*** is hypersecretion of GH after the fusion of epiphysis and usually results from a pituitary macroadenoma.

Why the nomenclature 'acromegaly' ?

'Acral' means peripheral (hands and feet), and 'megaly' means enlargement.

What is the opposite terminology of 'prognathism' ?

Micrognathia (receding chin), and is found in Pierre-Robin syndrome and Treacher-Collins syndrome.

Commonest pituitary 'hormone producing' tumour :

Prolactinoma.

Features in respiratory and cardiovascular system in acromegaly :

- Respiratory system—deep and husky voice, increased size of sinuses, obstructive sleep apnoea syndrome.
- CVS—systemic hypertension, cardiomegaly, cardiomyopathy, CCF.

Other features of acromegaly :

1. Arthropathy.
2. Osteoarthritis.
3. Pseudogout.
4. Myopathy (proximal).
5. Peripheral neuropathy.
6. Carpal tunnel syndrome.
7. Visceromegaly (liver, spleen, heart, kidney, tongue).
8. Increased skin pigmentation; fibromata mollusca.
9. Acanthosis nigricans.
10. Galactorrhoea (in females).

Causes of carpal tunnel syndrome (CTS) :

1. Rheumatoid arthritis.

2. Myxoedema.
3. Acromegaly.
4. Compression of median nerve by oedema, tenosynovitis, fracture, fibrosis or fascitis.
5. Primary amyloidosis.
6. Pregnancy in the third trimester (due to oedema) or premenstrual oedema.
7. Osteoarthritis, rarely.
8. Exposure to vibration (drivers of tractor, mobile crane; workers involved in chipping, grinding or using drills), eosinophilic fascitis, systemic sclerosis.
9. Diabetes mellitus.
10. Obesity.
11. Patients on haemodialysis (due to deposition of P_2-microglobulin, an amyloid).
12. Idiopathic (probably the commonest cause)—common in middle aged, obese female.

CTS is due to entrapment of median nerve while it passes through the carpal tunnel at wrist. Nocturnal pain, paraesthesia and numbness of radial three-and-a-half fingers are complained, commonly by a female patient. There may be weakness of the abductor pollicis brevis muscle (at thenar eminence) with or without wasting. Tapping over the median nerve at carpal tunnel produces paraesthesia along the cutaneous distribution of the nerve (Tinel's sign), and the symptoms may be reproduced on passive maximal wrist flexion (Phalen's test); raising the BP above systolic pressure for 2 minutes produces paraesthesia (tourniquet test). Nerve conduction study confirms the diagnosis.

A wrist splint at night, a local corticosteroid injection or surgical decompression of the carpal tunnel are different modes of treatment in CTS.

Different 'entrapment neuropathy' in clinical medicine :

- Median nerve (at wrist)—carpal tunnel syndrome.
- Ulnar nerve (at wrist in Guyton's canal).
- Radial nerve (at spiral groove of humerus after a fracture).
- Lateral femoral cutaneous nerve (at lateral thigh)—meralgia paraesthetica.
- Common peroneal nerve (at the neck of fibula).
- Posterior tibial nerve (at the flexor retinaculum at ankle joint)—tarsal tunnel syndrome.

Outline of management of acromegaly :

1. Medical -

Bromocriptine (long-acting dopamine agonist) — Usual dose is 10-60 mg daily in divided doses. It is started in a low dose of 1.25-2.5 mg/day and the dose is gradually increased. Side effects are nausea, vomiting, dyskinesia, postural hypotension, constipation etc. Bromocriptine is useful along with other modalities of therapy. Another dopamine agonist used is cabergoline (0.5 mg daily) which also shrinks tumours. Now-a-days, somatostation analogues (octreotide or lanreotide) are treatment of choice in resistant cases. The dose of octreotide is 50 ng tds to 1500 ng/day by SC injections, and that of lanreotide is 30 mg I.M depot preparation given daily. Growth hormone receptor antagonists (e.g., pegvisomant; 10-20 mg, SC, daily) are promising drugs.

2. Surgical -
   1. Trans-sphenoidal (for small tumours) and trans-frontal surgery (for large tumours).
   2. Stereotaxic placement of probes (radio-surgery).
   3. Cryosurgery.
3. Radiotherapy -
   a) External gamma irradiation (total 4500 rads).
   b) Accelerated proton beam (total doses upto 10000 rads may be given).
   c) Local implantation of radioactive isotopes of yttrium or gold into the pituitary fossa via a transnasal stereotaxic operation.

* Surgery is usually required in visual field defect. Trans-sphenoidal approach is regarded as first line of treatment; external radiotherapy (gamma knife) is employed as second line of treatment if symptoms persist after surgery. Control of hypertension and diabetes is done accordingly.

** The target of treatment is to achieve a mean GH level < 5 mU/L.

Identification points :

1. Prognathism.
2. Enlargement of the face, and
3. 'Spade-shaped' hand.

Case 74

PALPATION OF BASE OF THE HEART

Method of palpation of base of the heart :

The **patient will sit and lean forward.** Standing on the right side of the patient, put your right palm over the sternum transversely in such a way that your fingers lie over the *pulmonary area,* centre of the palm rests over the sternum, and thenar-hypothenar eminences lie over the aortic area.

* *'Base of the heart' includes aortic and pulmonary area.*

What to palpate ?

1. Pulsation.
2. Palpable heart sounds, and
3. Thrill.

Palpate aortic, pulmonary, mitral and tricuspid areas :

(A) Aortic area—patient will sit and lean forward; put your right palm over right 2nd ICS.

(B) Pulmonary area—patient will sit and lean forward; put your right palm over left 2nd ICS.

(C) Mitral area—read the section on 'Mitral incompetence' (i.e., palpate the apical area).

(D) Tricuspid area—patient will be lying in supine position. Put your right palm over left 4th ICS (close to sternum).

Causes of pulsation over the pulmonary area :

1. Children (physiological),
2. Severe pulmonary hypertension,
3. ASD,
4. PDA,
5. VSD,
6. Idiopathic dilatation of pulmonary artery.

Causes of palpable heart sounds in precordium :

For palpation of heart sounds, use whole flat of the right palm.

(A) Palpable S_1 (mitral area)—produces 'tapping' apex beat in MS.

(B) Palpable S_2 (P_2)—Best palpable in pulmonary area.

It is known as diastolic shock or 'diastolic knock' and is found in pulmonary hypertension of any aetiology. Read the section on Mitral incompetence' for the causes of pulmonary hypertension.

(C) Palpable S_3—In LVF (mitral area) or RVF (lower left parasternum).

(D) Palpable S_4 (mitral area)—responsible for 'double' kicking apex beat in IHSS.

For demonstration of any event (palpation, percussion or auscultation) in aortic or pulmonary area, always ask the patient to sit and lean forward.

Pulsation over the aortic area :

Aneurysm of the arch of aorta.

Causes of thrill in the base :

Read the section on Aortic stenosis'.

Palpation for parasternal (left) heave :

Patient lies supine. Place your thenar and hypothenar eminences (heel of the palm), or the ulnar border of the right hand over the lower left parasternum (i.e., 3rd, 4th and 5th ICS). Standing on the right side of the patient, look for any lifting of the hand. The causes of heave are :

a) RVH due to any cause,
b) Left atrial hypertrophy (rare; e.g., in MI),
c) ASD (left parasternal lift), and
d) Aortic aneurysm.

* Heave means the impulse is forceful and it is well sustained; 'lift' means the impulse is forceful but it is ill sustained.

Case 75

PERCUSSION OF THE STERNUM OR BASE OF THE HEART

Three cardinal rules of percussion :

See page 82.

Why percussion is not done routinely in CVS ?

1. Not much informative (has been replaced by chest X-ray and echocardiography).
2. Dislodgement of vegetations may occur in a case of MS, acute myocardial infarction (AMI) or atrial fibrillation. Thus, it may precipitate systemic embolism.
3. It is a cumbersome method in female patients.

Situations where cardiac percussion is still helpful :

1. Pericardial effusion (cardiac dullness is increased),
2 Emphysema (cardiac dullness is lost),
3. Aneurysm of the arch of aorta (left 2nd ICS will be dull on percussion).
4. Dextrocardia.

* There is loss of cardiac dullness in left-sided pneumothorax too.

Percussion note over sternum :

It is resonant because aerated lungs are present behind the sternum. .

How the sternum is percussed ?

Sternum may be directly percussed by percussing finger (like the percussion of clavicle) Here, the sternum itself acts as pleximeter finger. Actually in clinical practice, the method described below is followed for percussion of the sternum.

How to percuss the base of the heart ?

1. Ask the patient to sit. Percussion is usually done in the 2nd ICS.
2 First place the pleximeter finger in the aortic area parallel to right sternal border.
3. The line of percussion in the *aortic area* will be perpendicular to right sternal border and go on percussing upto the middle of the sternum (i.e., go from right to left).
4 Now place the pleximeter finger in the *pulmonary area* parallel to left sternal border^ The line of percussion in the pulmonary area will be perpendicular to left sternal border and percuss upto the middle of the sternum where you left (i.e., now go from left to right).
5 One may percuss the aortic and pulmonary areas by the above method and may stop the ' percussion after reaching right and left borders of the sternum respectively. Then percussion of the sternum may be done directly (alternative method).
6. Listen the percussion note carefully. Thereafter, percussion may be done in the 3rd ICS.

* **This total method may be used for percussion of base of the heart** or **percussion of the sternum** or **'mediastinal percussion .**

Dullness over pulmonary area :

1. Aneurysm of the aorta,
2. Massive pericardial effusion,
3. Any mediastinal mass.

Dullness over sternum :

Sternum is dull on percussion due to superior and anterior mediastinal mass like,

1. Lymphoma,
2 Bronchogenic carcinoma,
3 Thymoma,
4. Aortic aneurysm,
5- Retrosternal goitre,
6. Teratodermoid,
7- Metastatic carcinoma, and
8. Oesophageal cysts.

N B ■ If a dull note is obtained over the sternum, immediately look for any venous prominence in the neck or swelling of the face and arm, i.e., for the signs of 'SVC syndrome'. SVC syndrome 1S an indirect evidence of the presence of mediastinal mass. Never forget to percuss the sternum in a patient with generalised lymphadenopathy (e.g., mediastinal adenopathy in lymphoma).

How will you percuss the heart ?

Cardiac percussion is not routinely practised now-a-days for reasons mentioned earlier.

1 At first find out the upper border of liver dullness along the right MCL.
2' Now to choose your space of percussion for the delineation of right border of heart, select 'one space higher' the upper border of liver dullness. Keeping the pleximeter finger parallel to the arbitrary right border of heart, lightly percuss from right to left. Actually percussion is done in the 3rd and 4th ICS. As soon as the dull note is obtained (due to heart), mark it an then join the points. This is the **right border of heart.**

3. Now, localise the apex.
4. For the **left border of heart,** percuss along (or parallel to) the 'left acromio-xiphold line' (an imaginary line from left-sided tip of the acromion process to the xiphisternum) in the 2nd 3rd and 4th ICS. Join the points of dullness with the apex.
5. Lastly, percuss the base of the heart to delineate the **upper border** (left 2nd and 3rd ICS). Percussion is done parallel to prasternal line (line in between MCL and lateral sternal line)

Normally right border remains retrosternal; if the dullness is parasternal, think of pericardial effusion, aneurysm of the ascending aorta, dextrocardia, mediastinal mass etc. Left border usually remains along the apex beat; if it is outside the apex beat, think of pericardial effusion. *Remember normally the left 2nd ICS is resonant and the left 3rd ICS is dull on percussion-,* if the 2nd ICS gives dull note, think of pericardial effusion, mediastinal mass, aortic aneurysm, pulmonary hypertension.

Cardiac dullness is also increased in cardiomegaly due to any cause (left border will be corresponding to apex). In pericardial effusion, left border will be outside the apex.

N.B. ; In case of loss of either of liver or cardiac dullness, exclude the presence of right- or left-sided pneumothorax respectively; if both the dullness are lost, think of presence of emphysema.

Case 76

AUSCULTATION OF DIFFERENT AREAS OF HEART

Auscultation of the mitral area :

1. First you have to **localise the apex beat** (i.e.. the mitral area) by proper method of palpation (read the section on 'Mitral incompetence'). Mitral area corresponds to cardiac apex.
2. Now auscultate the mitral area in dorsal decubitus position and then in **left lateral position** and at the height of **expiration.** Conventionally, **first use the diaphragm** of stethoscope and **then the bell.**
3. In case of a faint diastolic murmur, you may allow the patient to do mild exercise (if the present condition of the patient permits to do so, i.e., if there is no dyspnoea, CCF arrhythmia, cyanosis etc). Allow the patient to sit and touch both feet with both of his hands and lie down consecutively for five to six times. The murmur of MS becomes louder and prominent alter mild exercise (before doing the exercise, you may take permission of the examiner).
4. In the presence of mitral systolic (pansystolic) murmur, you may auscult the left axilla and interior angle of left scapula for radiation of MI murmur (alwavs take the permission of the examiner because you are shifting your stethoscope from the mitral area).
5. Comment on murmur, heart sounds (specially, on S,), any split, click, opening snap or pericardial rub.

If the apex beat could not be localised properly, auscultate the area 'below the left nipple'.

Auscultation of the aortic area :

1. The right 2nd ICS (close to the sternum) is the aortic area.
2. Allow the patient to **sit and lean forward.** Now auscultate the aortic area at the height of **expiration** with the **diaphragm** of stethoscope.
3. If you have to confirm the radiation of murmur to carotids (AS) or towards the neoaortic area (AI), you have to take the permission of the examiner.
4. Comment on murmur, heart sounds (specially, on A_2) or any other sounds like split, click etc.

Auscultation of the pulmonary area :

1. The left 2nd ICS (close to the sternum) is the pulmonary area.
2. Patient will **sit and lean forward** and auscultation is done with the **diaphragm** of stethoscope, at the height of **inspiration** (as right-sided events are pronounced in inspiration).

Auscultation of the tricuspid area :

1. The left 4th ICS (close to the sternum) is the tricuspid area.
2. Auscultation is done with the **diaphragm** of sthethoscope, at the height of **inspiration** with the patient **lying** in supine position.

Importance of the neoaortic area :

The left 3rd ICS (close to the sternum) is known as neoaortic area or **Erb's point.** Often the early

diastolic muniur of AI is best audible in the neoaortic area. The area should be auscultated in **sitting and leaning forward position** with the diaphragm of stethoscope, and at the height of **expiration.**

Points ***to note during auscultation of CVS :***

1. Heart sounds,
2. Murmur,
3. Splitting of heart sounds, ejection click, opening snap, and
4. Others : Pericardial rub, pericardial knock, prosthetic valve sounds, tumour plop.

Sequence of auscultation of heart :

Apex -» proceed along the left border of sternum, i.e., tricuspid area -> neoaortic area -> pulmonary area -> then auscultate aortic area auscultate different areas, with auscultatory manoeuvres, if required.

But majority of clinicians prefers to examine or write in the following way : apex -> pulmonary area aortic area -> tricuspid area -» neoaortic area.

Points to note in a murmur :

Murmurs are abnormal cardiac sounds produced by turbulent blood flow (laminar flow is distorted to turbulent flow) through the abnormal valves (MS, MI etc), normal valves (pregnancy, severe anaemia), great vessels (any arterial stenosis will produce bruit) or blood passing through an abnormal channel (VSD, ASD etc). The points noted in a murmur are ;

1. Where best heard or point of maximum intensity (enumerate the area).
2. Timing (systole, diastole or continuous).
3. Character (e.g., blowing, harsh, musical, rumbling) and pitch.
4. Radiation or direction of selective propagation (radiation indicates the direction of blood flow).
5. Intensity (grading; if thrill is present, it is grade 4 or 4+).
6. Change with respiration.
7. Change with posture.
8. Change after exercise.
9. Whether best audible with the diaphragm or the bell of stethoscope.

* Always try to describe a murmur with these NINE POINTS.

** 'Pitch' of a murmur is determined by the flow of blood, i.e., iow-pitch indicates low-velocity flow and high-pitch indicates high-velocity flow.

*** Systolic murmurs coincide with carotid upstroke and diastolic murmurs precede the carotid upstroke.

Explanation of effects of respiration or posture on murmur :

During inspiration the intrapleural pressure becomes more negative and thus, more blood comes in the right atrium. So, during inspiration there is increase in the stroke output of the right heart and reduction in the stroke output of the left heart. Similarly stroke output of the left heart increases on expiration. So the murmurs originating in the right side of the heart become louder and prominent on inspiration, and that of the left side of the heart become more intense on expiration.

In the left lateral position, the apical area (mitral area) comes closer to the chest wall, so does the base of the heart in sitting and leaning forward position. It is why the murmurs in those areas become more intense 011 adopting the sttid postures.

* Low-pitched sound e.g., murmur of MS and TS are best auscultated by the bell of stethoscope. All other murmurs are best heard with the diaphragm of stethoscope.

Case 77

Pericardial RUB

Characteristics :

It is a leathery sound produced by the rubbing of inflammed visceral and parietal pericardium :

1. Superficial, scratchy or leathery, inconstant or evanescent (varies from hour to hour), high-pitched, to-and-fro sound (mimics the sound of husking machine); 'close to the ear' quality.

2. Usually best heard on the left side of lower sternum (may be heard over the entire precordium)—here lies the bare area of heart i.e., part of heart not covered by the lung.
3. Intensity of the sound increases when patient sits and leans forward (thus, always auscultate in sitting position of the patient).
4. Intensifies by pressing the chest piece (diaphragm) of stethoscope.
5. It may have presystolic, systolic and early diastolic components.
6. **Sound continues even after holding the breath.**
7. May be associated with chest pain.
8. Usually there is no transmission (i.e., localised).
9. At times it is paipable—The 'tactile fremitus' (palpable pericardial rub).

What is your case ?

This patient is suffering from acute dry pericarditis and there is presence of pericardial rub (describe the characteristics). *The hallmark of diagnosis of pericarditis is pericardial rub.*

Common causes of acute pericarditis :

1. Idiopathic (without any obvious cause),
2. Viral (H/O fever, cough etc—commonly Coxsackie B virus infection),
3. Tuberculous (H/O haemoptysis, anorexia, night sweats etc),
4. Pyogenic (high rise of temperature with toxic features),
5. Rheumatic fever (arthritis, pancarditis, subcutaneous nodules),
6. Uraemia (oedema, anaemia, oliguria and usually painless pericarditis),
7. Myxoedema (delayed ankle jerk, hoarseness of voice),
8. Acute myocardial infarction (acute chest pain with collapse) during acute attack, or Dressler's syndrome (after few days to weeks, following an attack of myocardial infarction),
9. Trauma (H/O trauma),
10. Collagen vasular diseases like SLE, systemic sclerosis (skin rash, arthralgia),
11. Neoplastic or post-irradiation (H/O radiation, lymphadenopathy) etc.

* 1,2 and 3 are most common causes, specially in India.

Describe the chest pain in pericarditis :

Pain is an important but not invariable symptom in pericarditis. *Pain is absent* in slowly developing tuberculous, hypothyroid, neoplastic, post-irradiation or uraemic pericarditis.

There are three types of pain :

1. Pleuritic (steady and constrictive), i.e., due to associated pleurisy and caused by direct extension of infection and thus, the pain is aggravated by inspiration, coughing, sneezing, jolting, change of posture etc. The rub is known as 'pleuro-pericardial rub'.
2. Steady constricting retrosternal pain which radiates in either of both arms, shoulders and neck like acute myocardial infarction.
3. Often the pain is present characteristically in the centre of the chest or left precordial, referred to the back, arms and shoulder.

* The pain of pericarditis is due to associated pleurisy or inflammation of the lower 1/3rd of the parietal pericardium (visceral pericardium is pain-insensitive) supplied by phrenic nerve. The pain varies with breathing and posture, and is often relieved by sitting up and leaning forward but increased by lying supine.

Investigations you like to perform :

(A) Blood— TC, DC, ESR, cholesterol, urea, creatinine, ASO titre, T_4 and TSH, SCOT (AST).

(B) Mantoux test— For tuberculous aetiology.

(C) ECG—**ST-segment elevation with *concavity* upwards,** and flattening or inversion of T-waves.

(D) Chest X-ray (in upright posture)-

1. To exclude tuberculosis in the lungs.
2. To exclude bronchogenic carcinoma or lymphoma (mediastinal widening).
3. Enlarged cardiac shadow may indicate very early effusion.

(E) Echocardiogram— May be helpful in detecting thickening of pericardium and early effusion.

* ECG changes of acute myocardial infarction is ST-segment elevation with *convexity* upwards.

D/D of pericardial rub :

1 Systolic murmur
2 Early diastolic murmur of aortic incompetence
3. Continuous murmur
4. Artefact.
5. Hamman's sign.

1 consistent in character, audible in all ^positions, soft/musical/machinery ***J*** sound, pain is not associated with

What is Hamman's sign ?

It is a crunching, rhythmical sound heard over the precordium and is synchronous with the heart beat. This sign is found in pneumomediastinum (or mediastinal emphysema). The sound is best audible in left lateral position. Always search for subcutaneous emphysema meticulously.

Changes appearinging if pericardial effusion develops :

(A) Symptoms—Patient will C/O heaviness (retrosternal oppression) in the precordium. dyspnoea, palpitation, swelling of feet or whole body, dry cough etc.

(B) Signs—

1. Orthopnoea (sometimes, patient bends forward in sitting position mimicking the position adopted by Mohammedans during prayer).
2. Face— Puffy.
3 Pulse— Tachycardia, low volume, pulsus paradoxus (specially in acutely developing peri cardial effusion), other points in pulse are within normal limit.
4. Cyanosis— If present, mainly of ***peripheral*** in type.
5. Neck veins— Engorged and may be pulsatile; Kussmaul's sign may be present (rare).
6. BP— Systolic BP is low.
7. Oedema— Pitting in nature.
8. Heart—
   a) Bulging of precordium with intercostal fullness.
   b) Apical impulse— Neither visible nor palpable.
   c) Cardiac dullness is increased on percussion. If apex beat is palpable, it will be feeble and will remain within the outer border of cardiac dullness. Percussion note over the sternum and left 2nd ICS is dull. Tympanicity on Traube's space percussion is retained.
   d) Heart sounds become faint or muffled. Pericardial friction rub is not always abolished.
9. Lungs— No adventitious sound is heard. Presence of Ewart's sign which is,
   a) Dullness on percussion,
   b) Increased vocal resonance, and
   c) Bronchial breath sound (tubular) — All the features are due to compression collapse of the left lung by massive pericardial effusion and is found at the inferior angle of left scapula (i.e., base of left lung).
10. Alimentary system—
    a) Liver— Enlarged, soft and tender (congestive hepatomegaly).
    b) Ascites— May be present.
11. ECG—low voltage QRS complexes, electrical alternans (rare).
12. Chest X-ray (PA view)—enlarged cardiac silhouette, globular or 'pear-shaped heart, oligaemic lung fields and positive Rotch's sign. Echocardiography confirms the diagnosis.

* Pulsus paradoxus and Kussmaul's sign are hallmarks of cardiac tamponade. In cardiac tamponade, there is collection of fluid in the pericardial sac in an amount sufficient to produce serious obstruction to inflow of blood to the ventricles and thus, results in acute heart failure (there is decrease in stroke volume due to impaired cardiac contraction). The amount of fluid may be as small as 250 ml when the fluid collects rapidly or it may be more than 1000 ml in slowly developing effusions. It is a medical emergency and pericardiocentesis is life saving.

Uraemic pericarditis : what to do ?

If pericardial rub is heard in a patient of uraemia, immediately send the patient for dialysis.

Treatment of acute pericarditis :

1. Rest in bed.
2. NSAID—indomethacin (25 mg, thrice daily, orally after meal) may be used.

3. Glucocorticoid—Prednisolone 20-80 mg daily in selected cases; does not accelerate cure; only gives symptomatic relief. If there is no response to corticosteroid, azathioprine or colchicine may be tried.
4. Treatment of the underlying cause (e.g., antibiotics, antituberculosis drugs).

* The patient is observed frequently for the development of pericardial effusion.

Conclusion :

_ ^ In a suspected case with pericardial rub, ask the patient to hold the respiration. One should do his to differentiate pericardial rub from left-sided pleural rub. ***After breath holding, pericardial rub continues but pleural rub stops.*** Occasionally during inspiration, pericardial rub intensifies and this component is known as 'pleuro-pericardial rub'. -

Case 78

SHAPE OF THE CHEST

Mention the common chest deformities :

1. Kyphoscoliosis.
2. Barrel-shaped chest.
3. Pigeon chest (pectus carinatum).
4. Funnel chest (pectus excavatum).
5. Alar chest (pterygoid chest).
6. Unilateral or bilateral, depression or fullness of the chest.
7. Deformity associated with ankylosing spondylitis, straight back syndrome, thoracoplasty operation (in this procedure, some ribs are resected on one side of chest to achieve collapse of the lung), severe chest trauma, or absence of part of chest wall (e.g., ribs, pectoralis muscle or clavicle).

Delects in the chest w'all may be described in a better way like :

- Defects in sternum : Pectus carinatum, pectus excavatum.
- Defects in spine : Kyphosis, scoliosis, straight back syndrome, ankylosing spondylitis.
- Defects in costal cartilage : Rickety rosary, scorbutic rosary, costochondritis.

Kyphosis and scoliosis :

(A) KYPHOSIS means backward bending of the vertebral column with its convexity posteriorly (like the shape of the letter 'K'). 'SCOLIOSIS' means lateral bending of the vertebral column (like the shape of the letter 'S').

These are abnormalities of alignment of the dorsal and lumbar spines. In severe kyphoscoliosis, they may lead to asymmetry of the chest wall resulting in restricted expansion of the chest wall, maldistribution of ventilation and blood flow in the lungs. Ultimately type II respiratory failure, pulmonary hypertension, RVF and chronic cor pulmonale develop.

(B) Common causes are :

1. Congenital.
2. Vertebral diseases like ankylosing spondylitis, senile osteoporosis, osteoarthritis rheumatoid arthritis, rickets etc.
3. Caries spine— With 'gibbus' (acute angulation in the spine) formation.
4. Neurological causes— Neurofibromatosis, Friedreich's ataxia, syringomyelia, poliomyelitis and cerebral palsy.
5. Occupational, traumatic or postural.
6. Miscellaneous—Marfan's syndrome. Turner's syndrome, after thoracoplasty etc

Extensive unilateral fibrosis or collapse of the lung in childhood may give rise to scoliosis.

(C) The common form of scoliosis with convexity to the right side displaces the apex beat towards the concavity, i.e., to the left side. Trachea may be displaced in simple scoliosis. It snould be remembered that *Che commonest cause of displacement of the apex beat is deformity of thoracic cage, usually scoliosis.*

(D) Method of diagnosis :

1. Scoliosis—The patient will stand erect with fully exposed chest and the observer looks for scoliosis from his back. It is observed whether the convexity is present in left or right side. Afterwards, it may be corroborated by palpation of the spine.
2. Kyphosis—The observer inspects the back from the sides in profile, i.e., a tangential view from both sides are necessary. The patient will stand erect with fully exposed chest.

In kyphosis, there is increase in the antero-posterior diameter of the chest.

* [LORDOSIS means forward bending of the vertebral column with its convexity anteriorly. It is commonly seen in pregnancy, obesity, secondary to hip joint disorders, muscular dystrophy, in large abdominal tumours or massive ascites].

Describe the normal chest :

1. Elliptical in cross section, i.e., transverse : antero-posterior diameter = 7:5
2. Bilaterally symmetrical and without undue elevation or depression.
3. Both the sides of the chest move simultaneously and symmetrically.
4. Subcostal angle is 90° or less than 90° (males having a narrower angle than females).

Barrel-shaped chest :

1. Antero-posterior diameter of the chest is increased (AP : TR=1 :1) and it is circular in cross section.
2. The whole chest is relatively fixed in full inspiration.
3. Intercostal spaces are full, ribs are less obliquely set and wide apart.
4. There may be kyphosis of thoracic vertebrae.
5. Fullness of supraclavicular fossae.
6. The chest tends to move upwards in one piece.
7. Wide subcostal angle.
8. Prominence of sternal angle.
9. Rarely encircling prominent veins are seen in the lower part of the chest.

Cause : Severe obstructive airway disease or emphysema.

Pigeon chest (pectus carinatum) :

1. Triangular chest (in cross section) with prominent sternum.
2. Rickety rosary (beaded appearance of the costochondral junction; best demonstiated in the 4th, 5th and 6th ribs).
3. Harrison's sulcus (linear depression or sulcus present transversely from the sides of the xiphoid process to the midaxillary line as a result of repeated strong contractions of diaphragm).

Causes :

a) Childhood bronchia! asthma.
b) Repeated lung infections since childhood.
c) Rickets.
d) Idiopathic.

Funnel chest (pectus excavatum) :

1. Curving backwards (i.e., depression) of the body of the sternum, usually the lower part.
2. Antero-posterior diameter < transverse diameter.
3. Undue prominence of the costochondral junction.

Causes :

a) Repeated lung infections since childhood.
b) In cobblers (also known as cobbler's chest).

* Pectus excavatum may give rise to displaced apex beat to the left and a 'benign systolic murmur due to right ventricular outflow tract obstruction; and the cardiac shadow may be enlarged in X-ray chest (PA view) as a result of sternal compression (Pomfret's heart). There may be restrictive type lung function defect, if very severe.

Alar chest :

1. Drooping of both the shoulders.
2. Winging of both the scapulae (i.e., prominent vertebral borders of scapulae).
3. Chest is narrow and tubular.

Cause : It is found in tall and thin built normal persons; often known as phthnoid chest.

* Shield-like chest Broad chest with widely placed nipples, and is found in Turner's syndrome.

** Flail chest—Found in multiple rib fractures where the affected area moves inwards on inspiration, and outwards on expiration (paradoxical movement of chest).

Cross sectional view in different types of chest deformities :

1. Normal— Elliptical.
2. Barrel-shaped chest— Circular.
3. Pigeon chest — Triangular.

D/D of rickety rosary :

Scorbutic rosary (seen in scurvy)— The costochondral junctions are prominent, painful and appear sharp as well as angular; due to posterior subluxation or pushing in of the sternum.

Rickety rosary—The bead-like prominence at costochondral junctions are dome-shaped and semi-circular.

Fullness or depression of the chest :

(A) Fullness—

1. Massive pleural effusion.
2. Empyema thoracis.
3. Pneumothorax.
4. Hydropneumothorax or pyopneumothorax.
5. Bronchogenic carcinoma.
6. Pericardial effusion.
7. Emphysema produces bilateral fullness.
8. Empyema necessitatis, aortic aneurysm, or encysted pleural effusion produces 'localised[1] fullness.
9. Parietal oedema (e.g., from amoebic liver abscess).

(B) Depression—

1. Fibrosis of the lung
2. Collapse of the lung.
3. Thickened pleura or pleural adhesions.
4. After rib resection in thoracotomy.

Straight back syndrome :

The back becomes straight due to loss of normal throacic kyphosis and thus, the antero-posterior diameter of the chest is reduced. The heart may be compressed between the sternum and the spine.

'Inspection' for shape and movement of the chest :

(A) Inspection of the chest is best done in standing or sitting (if standing is not possible) position, in good daylight with proper exposure (by stripping) of front and back of the chest. The patient should stand absolutely straight. Sitting means the patient will sit on a stool. The chest is inspected from:

1. Front.
2. Back.
3. The sides in profile.
4. Looking from above (standing behind the patient), over the shoulders for the upper part of the

If standing or sitting is not possible for the patient, then inspect the chest in lying down position (patient lies absolutely straight in the bed in supine position) from the :

1. Top (panoramic view).
2. Foot end of the bed.
3. The sides in profile.
4. Head end of the bed.
5. Back (try to turn the patient to any one side).

(B) Points to note :

1. Any deformity, fullness or depression (i.e., shape of the chest), apical impulse etc.
2. Back (winging of the scapula, drooping of the shoulder, kyphoscoliosis, gibbus, skin changes).
3. Whether both the sides of the chest are moving simultaneously and symmetrically.

** RCad the Scheme of examination' of respiratory system under the heading 'Inspection'.

Classical winged scapula is found in paralysis of nerve to serratus anterior (C,), sometimes in facio-scapulo-humeral muscular dystrophy, and severe malnutrition.

fr*n_m K,h Ph°!!S' interco®tal suction and chest deformities (e.g., barrel-shaped chest) are best observed from the sides in profile.

In general survey, how do you examine 'Respiration ?

Respiration should always be described by these 5 points.

(A) Rate- Normal respiratory rate in a relaxed adult is 14-18 breaths/min though a wide variation occurs in health; at birth the rate is about 40/min. The variations are :

a) Increased rate— Tachypnoea (read the section on 'Bronchial asthma').

b) Decreased rate— Bradypnoea (read the section on 'Bronchial asthma).

* RATE OF RESPIRATION is counted surreptitiously (without the knowledge of the patient), by placing the hand in the epigastrium or with the fingers held on the radial pulse to avoid patients attention to breathing while observing the chest movements. The rate is counted for a full minute.

(B) Rhythm— Changes in rhythm are diagnosed by inspecting the movement of the chest. There may be wide variations in health.

a) Irregularly irregular or Blot's breathing— The respiration is sometimes slow, sometimes rapid, sometimes superficial, sometimes deep but without any constant relation of succession between the two types, with pauses at irregular intervals. Actually, there are 3-4 respirations without waxing and waning, followed by a pause. This is most commonly seen in meningitis, specially in children.

b) Regularly irregular or Cheyne-Stokes respiration (read the section on 'Bronchial asthma).

c) Miscellaneous—Kussmaul's breathing, stertorous breathing, prolonged inspiration or prolonged expiration (obstruction of upper or lower respiratory tract respectively).

(C) Type— Diagnosed by inspecting the movement of the chest and abdomen. The variations are :

a) Thoracic— Adult women, anxiety, peritonitis, huge ascites, hysteria, diaphragmatic palsy.

b) Abdominal— Adult men, young children, pleurisy, ankylosing spondylitis, intercostal muscle paralysis.

c) Abdomino-throacic— Young children, sometimes in adult men.

d) Paradoxical respiration— Diaphragmatic palsy.

* In females, intercostal muscles play more (so, thoracic type) and in males, diaphragm plays more (so, abdominal type) in normal respiration.

Females with predominantly abdominal type respiration—any painful condition in chest (e.g., pleurisy, chest trauma), pneumothorax etc.

Males with predominantly thoracic type respiration—any painful condition in abdomen (e.g., acute peritonitis), huge ascites etc.

(D) Depth—Inspect the excursion of chest. The variations are :

a) Shallow— Narcotic poisoning.

b) Deep— Hyperpnoea, hyperventilation e.g., in metabolic acidosis.

(E) Breathing pattern-Wheeze or stridor, shallow breathing, air hunger, sighing, gasping, mouth-breathing or purse-lip respiration.

* While examining the 'Respiration', one may comment on movement of accessory muscles of respiration or intercostal suction, if present.

Case 79

AUSCULTATION OF THE CHEST

What will you do if asked to auscultate the chest ?

If anyone is asked to auscultate the chest, he/she has to auscultate for both the respiratory system and CVS. During auscultation of left side of the chest, one has to be careful for both he systems and during auscultation of right side of the chest, only respiratory system will serve the purpose. Auscultate over front (inflaclavicular area to lower costal margin), sides (axillary an in ra axillary areas) and back (supra-, inter- and infrascapular areas) avoiding auscultation over bones (clavicle, sternum and scapula). Always compare with the other side.

If a particular area of the chest (suppose, the area below the right nipple) is asked to be auscultated one must take the permission of the examiner for auscultation over the identical site on left side of the chest for observations regarding vocal resonance (always say vocal resonance as norm increased or decreased after comparing with the other side).

(A) **For respiratory system,** the description will be in the order of :

1. Breath sounds,
2. Vocal resonance, and
3. Adventitious sounds.

(B) **For CVS,** the description goes like this :

1. Heart sounds S,, S_2, any S_3 or S_4 (quality, intensity, splitting etc.),
2. Murmur,
3. Pericardial rub, ejection click, opening snap, pericardial knock etc.

* In the respiratory system, auscultation over trachea is not at all necessary.

During auscultation of the chest, direction given to the patient :

I he clinician will stand on the right side of the paitent. Before auscultation, the patient is asked to :

a) Turn the face to the left side (so that patient can not breathe on the clinician's face),
b) Breathe through open mouth (to prevent noise from partially closed nose),
c) Breathe regularly and deeply, but without any noise.

* Demonstrate the open mouth respiration to the patient for easy understanding.

How to classify the breath sounds ?

Breath sounds- Sounds produced by the passage of air through the tracheo-bronchial tree upto the alveoli Gas turbulence in the major airways is responsible for inspiratory sound and elastic recoil o e lung for expiratory sound. The breath sounds are divided into three types (mainly two types •, vesicular and bronchial) :

(A) Vesicular breath sound—

a) Definition : It is the sound produced by the passage of air. in and out of the aleveoli (vesicles)

b) Characteristics :

(i) Rustling (sound like dry leaves blown by the wind) in character.
(ii) Intensity of inspiration is more than that of expiration.
(iii) Duration of inspiration is greater than that of expiration.
(iv) No gap in between inspiration and expiration.

* *As the normal lung tissue selectively filters out some higher frequencies, the breath sound becomes quieter, and results in vesicular breath sound (the normal breath sound over the chest).*

c) Classical sites :

lniramammary, infra-axillary and inlrascapular regions.

d) Common variations :

1. Diminished vesicular— Thick chest wall, obesity, thickened pleura, pleural effusion, ^ pneumothorax, hydropneumothorax, empyema thoracis, fibrosis, emphysema etc.
2. Vesicular breath sound with prolonged expiration— Bronchial asthma, chronic bronchitis, emphysema. In this type of respiration, the duration of inspiration and expiration becomes more or less equal.
3. Harsh vesicular—
   (i) Intensities of inspiration and expiration are increased.
   (ii) Usually pathological.
   (iii) Found in compensatory emphysema, forced breathing.
4. Puerile—
   (i) Intensities of inspiration and expiration are increased.
   (ii) Normal pysiological phenomenon.
   (iii) In thin built persons (specially children).
5. Cogwheel or jerky— Patients who are hysterical, very nervous or crying during auscultation,

b. Absent breath sound— Pneumothorax, massive pleural effusion, hydropneumothorax collapse with obstructed bronchus, grossly thickened pleura etc.

The quality ol breathing in harsh and puerile types remain the same.

(B) Bronchial breath sound—

(a) Bronchial T'1 prc\d"fed by the Passage of air through the tracheo-bronchial tree.
I r n n u i S°U? 15 audlble ln situations where sound generated in central airways is
^ HHSSHUn? Td UlrOU8h thC lung substances having undermentioned pathology (e.g., consolidation) with a patent bronchus.

(b) Characteristics :

(i) 'Blowing', hollow' or 'aspirate' in character.

(ii) Intensity of expiration is more than that of inspiration.
(iii) Duration of expiration is usually equal to inspiration.
(iv) Definite gap present in between inspiration and expiration.

(c) Classical site : Over the trachea.

(d) Types :

1. Tubular— This is a high-pitched bronchial breath sound. It is commonly found in,
   (i) Consolidation.
   (ii) Collapse of the lung with patent bronchus.
   (iii) Sometimes, above the level of pleural effusion.
   (iv) Many a time, tubular breath sound is heard if the trachea or large bronchus physically comes near the stethoscope by push-pull effect (e.g., fibrosis of the lung)— loosely termed as 'pulled tracheal syndrome'.
2. Cavernous— It is a low-pitched bronchial breath sound classically heard over a superficial, big, empty cavity connected with a patent bronchus e.g., tuberculous cavity, lung abscess.
3. Amphoric—It is a low-pitched bronchial breath breath sound with tones and overtones, or with a metallic tone. The sound mimics the whistling sound produced by blowing air across the mouth of a small glass bottle. This is classically seen in,
   (i) Bronchopleural fistula (open pneumothorax), and
   (ii) Occasionally in a big cavity connected with a small bronchus.

*** Conditions associated with bronchial breath sound will produce quantitative increase in vocal resonance, i.e., bronchophony and whispering pectoriloquy.**

** In obstructed main bronchus, bronchial breath sound may not be heard over consolidation or collapse.

(C) Bronchovesicular breath sound (going to be obsolete though few old school clinicians still prefer it)—

a) Definition :

This is a mixture of two breath sounds where the expiration is mainly of bronchial and inspiration is predominantly of vesicular in character, and there is no gap in between inspiration and expiration.

(b) Classical sites (in health) :

1. Right infraclavicular area (here, trachea is in direct contact with the lung whereas in the left infraclavicular area the aorta, oesophagus and internal carotid artery seperate the trachea from the lung).
2. Interscapular area at the back (root of the lung).

(c) Clinical associations :

1. Consolidation in the stage of resolution.
2. Partial collapse of the lung.
3. Cavity in the lung.

Caution during auscultation of respiratory system :

1. *Always try to auscultate with the diaphragm of stethoscope* to avoid time consumption and practical difficulty; as most of the normal lung sounds are low-pitched, the bell is preferred over the diaphragm by some clinicians.
2. Ask the patient to cough :
   a) To clear the throat (if throat sounds appear).
   b) To note the changes in crepitations (often helps in differentiation with pleural rub).
   c) For auscultating post-tussive crepitations (specially in tuberculous cavity).
3. Press the diaphragm of stethoscope in patients with pleural rub to note the local tenderness and enhancement of the intensity of pleural rub.

What is Valsalva manoeuvre ?

This is an attempted **forced expiration** in closed glottis when the mouth is shut and the nose is held closed. This manoeuvre increases the intrathoracic pressure and thus obstructs the venous return in the right atrium. Classical example is the straining exerted during defecation.

Clinical applications ;

1. To make the abdominal wall veins prominent with the help of Valsalva manoeuvre while the patient sits in his bed.

2. During the Valsalva manoeurve— Tachycardia, overshoot of BP and bradycardia occur sequentially in health. This phenomenon is found to be absent in CCF, ASD and autonomic neuropathy.
3. Murmur of mitral valve prolapse syndrome (MVPS) and HOCM increases during Valsalva manoeuvre.
4. As a vagotonic procedure to abolish ectopic beats.
5. To terminate bouts of hiccough as a simple househould remedy.

What is Muller's manoeuvre ?

It is just the opposite of the Valsalva manoeurve. This manoeuvre is an attempted forced inspiration in closed glottis when the mouth is shut and the nose is held closed. This manoeuvre decreases the intrathoracic pressure. Classical example is a drowning man.

Case 80

PLEURAL RUB

Characteristics :

It is a leathery or creaking sound produced by the rubbing of inflammed and roughened, visceral and parietal pleura. The pleural rub is, .

1. Superficial (the sound seems to be very close to the ear), scratchy or grating in quality.
2. Biphasic (heard during inspiration and expiration both).
3. Better heard on pressing the chest piece of stethoscope over the chest wall.
4. Localised— Generally heard over the anterio-inferior part of lateral chest wall or in the lower part of back as the movement of lung is maximum in these regions.
5. Neither any alteration after coughing nor any variation with change of .posture,
6. Patient may complain of pain in the chest and local tenderness may be elicited.
7. Disappears when breath is held.
8. At times it is palpable— The 'friction fremitus'.

Differential diagnosis :

(A) It should be differentiated from coarse crepitations (which is also biphasic) by the following points. Crepitations are :
   (i) Not intensified on pressing the stethoscope,
   (ii) Modified or diminished after coughing,
   (iii) May be auscultated over a widespread area, and
   (iv) Discontinuous; not superficial, not associated with pain or tenderness.

(B) Pericardial rub (pericardial rub continues after holding the breath).

(C) Hepatic or splenic rub—often very difficult to differentiate, and is audible over enlarged liver and spleen respectively. Hepatic and splenic rub are inaudible if the patient holds his breath.

* Occasionally, after pressing the stethoscope in an uneven chest (with prominent ribs), pleural rub-like sound is produced due to friction of moist, sweaty chest wall with the diaphragm of stethoscope. Put the chest piece in a new place near the previous one after wiping off the sweat.

** In a hairy chest wall, avoid friction of hair by moistening the chest wall with sprinkled water and henceforth apply the chest piece tightly over the chest.

What is your diagnosis ?

Acute dry pleurisy.

Causes of acute dry pleurisy :

1. Pulmonary tuberculosis.
2. Pneumonic consolidation.
3. Bronchogenic carcinoma.
4. Pulmonary infarction.
5. Bornholm disease (epidemic pleurodynia).
6. Amoebic liver abscess.
7. Collagen vascular diseases.
8. Subdiaphragmatic abscess.
9. Bronchiectasis.
10. Injury to the chest wall.
11. Pleural metastases.
12. Mesothelioma of pleura (rare)

1, 2, 3 and 4 are most common and important causes.

Classical chest pain of acute dry pleurisy (pleuritic pain) :

1. Sharp, stabbing or tearing localised pain.
2. It increases on coughing, sneezing, deep inspiration, pressure from outside, jolting or bending.
3. Localised pain (usually non-radiating).
4. The pain is usually non-exertional but may increase after exercise (due to tachypnoea).
5. When the diaphragmatic pleura is involved, the pain may be referred to the tip of shoulder (central part of the diaphragm is supplied by C_{345}) or to the epigastrium (domes of the diaphragm are supplied by intercostal nerves).
6. The pain is diminished by holding the chest or holding the respiration (i.e., by taking shallow respiration).
7. Associated with pleural rub.

* Pleuritic chest pain is often associated with pyrexia and dry cough. See also page 69.

** Parietal pleura is pain sensitive (supplied by intercostal and phrenic nerve), while visceral pleura is pain insensitive (supplied by autonomic nervous system).

Decubitus in different diseases of pleura :

(A) Pneumothorax— Patient prefers to lie on the affected side. It allows maximum expansion of the normal lung.

(B) Pleural effusion— Patient prefers to lie on the side of effusion as it allows maximum expansion of the unaffected lung. Pleural fluid may compress the mediastinum and produce discomfort, if the patient lies on the normal side.

(C) Acute dry pleurisy—

1. Majority of patients lie on the affected side (if there is absence of overlying sensitive skin). In this way they splint their chest wall with the surface of the bed.
2. Few patients lie on the opposite side because the overlying skin is very sensitive and the patient cannot keep contact with the bed.

Describe different types of 'decubitus' in clinical medicine :

Decubitus means posture or attitude of the patient in bed assumed by him/her in most of the time of day and night. The different variations are :

1. Of choice—The patient is comfortable in any position in bed (also known as 'dorsal decubitus' or 'supine' position').
2. Propped-up— Propped-up position with a back-rest is found in patients suffering from dyspnoea. The back-rest can be adjusted according to the requirement of the patient e.g.,

   Mild dyspnoea— adopts 45°

   Moderate dyspnoea— adopts 60°

   Severe dyspnoea or orthopnoea— adopts 90° (i.e.. patient sits in bed).

Dyspnoea is basically due to respiratory and cardiovascular ailments (cardio-respiratory embarrassment). Gastrointestinal cause like massive ascites, and neurological causes like diaphragmatic palsy, respiratory muscles palsy, myasthenia gravis may also produce dyspnoea. Propped-up decubitus relieves dyspnoea because,

a) The excursion of diaphragm occurs better in erect posture.

b) Erect posture diminishes the venous return and thus dyspnoea of cardiac origin becomes less.

c) While in recumbency, the increase in intrathoracic blood volume elevates pulmonary venous and capillary pressure which ultimately increase the pulmonary closing volume and diminishes vital capacity. This is corrected on assuming erect posture.

3. Stooping forward position (Mohammedan's prayer position) on a cardiac table— Seen in severe dyspnoea of pericardial effusion, acute severe asthma, cardiac asthma and COPD. It is also observed in acute pericarditis or acute pancreatitis to get relief of pain. Patients with acute pancreatitis is partly relieved by lying down with knees drawn towards the chest.
4. Squatting—Fallot's tetralogy is the commonest cyanotic congenital heart disease where squatting is observed. As soon as the patient becomes dyspnoeic, he adopts squatting posture to relieve from dyspnoea. Squatting increases the peripheral resistance (i.e.. pressure in aorta increases) and thus reduces the right-to-left shunting through VSD.
5. Trepopnoea—See page 98.
6. Platypnoea—See page 98.

7. Lateral decubitus—See above (decubitus adopted in diseases of pleura); patient of liver abscess prefers to lie on the left side.
8. Listless attitude or where the patient lies still in bed. This attitude is usually seen in peritonitis (abdominal wall movement causes intense pain), anginal pain, coma and hysteria.
9. Curled-up—Observed in renal colic and biliary colic; restless, tossing—In colics, AMI.
10. Head end down (usually adjusted by placing bricks or wooden blocks in the foot end of bed)—In the treatment of bulbar palsy, after lumbar puncture, after spinal anaesthesia, balanced traction in orthopedics, in treatment of sinus bradycardia developed from acute myocardial infarction, deep venous thrombosis in legs, and in postural drainage of bronchiectasis and lung abscess (lower lobes).
11. Decubitus of hemiplegia—The affected arm remains flexed, adducted and semipronated, and the affected lower limb adopts extended, adducted and plantiflexed attitude. As a whole, the affected side shows less movement while the patient is in bed.
12. Opisthotonus, pleurothotonus and emprosthotonus—Respectively, they are bending of the body like an arc in forward direction, laterally to one side, and backward direction. These bending postures are seen in tetanus and strychnine poisoning.
13. Dorsal decubitus position with a pillow placed below the legs (pedal oedema, cellulitis of foot) or below the popliteal fossa (acute inflammation of knee joint, e.g., in rheumatic and rheumatoid arthritis, haemophilia).
14. Decerebrate posture—Extended elbows and wrists, with arms pronated; there is tonic extension and plantiflexion of the lower extremity, associated with head retraction and jaw clenching. The lesion lies at upper brainstem level, disconnecting cerebral hemispheres from brainstem.
15. Decorticate posture Flexed elbows and wrists, with arms supinated; lower extremities show tonic extension. It is seen in bilateral hemispherical lesion above midbrain.
16. Prone position—Colics, abdominal aortic aneurysm (eroding vertebra and producing back pain).
17. Knee-elbow position—Pain of chronic pancreatitis is reduced on assuming this posture.

Medical (non-surgical) causes of pain abdomen :

1. Basal pneumonia (basal pleurisy).
2. Acute myocardial infarction (inferior wall infarction commonly).
3. Diabetic ketoacidosis (may be due to acute gastric dilatation and/or pancreatitis).
4. Henoch-Schonlein purpura (vasculitis).
5. Sickle cell anaemia (vaso-occlusive crisis).
6. Acute intermittent porphyria (autonomic neuropathy).
7. Intercostal herpes zoster (pre-herpetic eruption produces radicular pain).
8. Caries spine or cord compression (radicular pain); collapse of vertebra.
9. Tabetic crisis (probably due to autonomic neuropathy; not seen now-a-days).
10. Polyarteritis nodosa (vasculitis).
11. Allergic pain (C_t esterase inhibitor deficiency).
12. Hyperlipidaemia (familial).
13. Lead poisoning (colic).
14. Localised tetanus of anterior abdominal wall muscle.
15. Functional gastrointestinal disorders.

* Peptic ulcer, acute pyelonephritis and acute pancreatitis may also be considered.

** Endocrine causes of pain abdomen are : (i) Diabetic ketoacidosis, (ii) Adrenal crisis, (iii) Hyperparathyroidism, and (iv) Cushing's syndrome.

Pain abdomen associated with shock :

1. Acute pancreatitis.
2. Peptic ulcer complicated by bleeding or perforation.
3. Acute myocardial infarction (inferior wall infarction).
4. Diabetic ketoacidosis.
5. Acute mesenteric ischaemia.
6. Dissection of abdominal aorta.
7. Rupture of amoebic liver abscess
8. Adrenal crisis.
9. Acute intermittent porphyria.
10. Strangulation of hernia.
11. Ruptured ectopic pregnancy.
12. Septic abortion.

Absent pleural rub after few days—reasoning behind :

Either the patient is cured, or developed pleural effusion.

Exfoliative dermatitis (erythroderma) from internal malignancy (lymphoma)

Extensive skin lesions in **Stevens-Johnson syndrome** with signs of healing

Multiple **erythema nodosum** (panniculitis) in sarcoidosis

Erythema multiforme with bullous (Stevens-Johnson syndrome) and iris / target (red periphery with a cyanotic hue) lesions

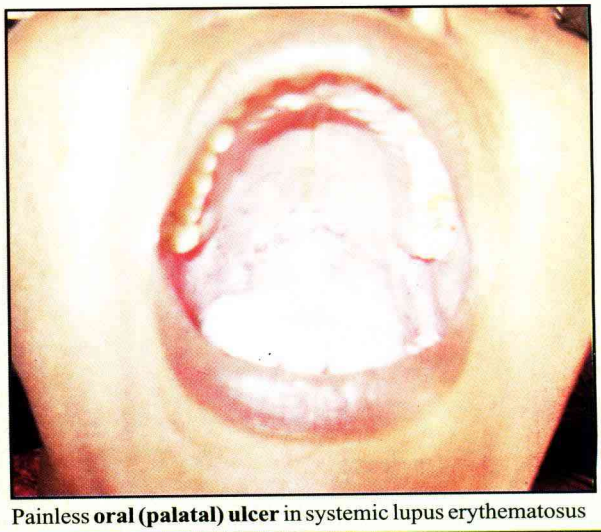

Painless **oral (palatal) ulcer** in systemic lupus erythematosus

Pytiriasis versicolor – manifested by hypopigmented macules in right side of the face

Salt-pepper appearance in skin [depigmentation (white-like salt) and pigmentation (black-like pepper)] in **scleroderma**

Acanthosis nigricans – brown to black, poorly defined, velvety hyperpigmentation of the skin of neck in type 2 diabetes mellitus (indicating insulin resistance) with skin tags (acrochordons)

Viperidae **snake bite** with cellulitis, oedema and haemorrhagic blister formation in and around the site of bite

Elephantiasis of legs from **filariasis**

Management :

1. Rest in bed.
2. Relief of chest pain by,
   at Hot fomentation.
   b) Splinting of the chest wall with leukoplast.
   c) Analgesics (NSAIDs).
   d) Sedatives.
3. Treatment of the underlying aetiology.

Identification points :

1. Sometimes, it may be confused with pericardial rub (in left-sided pleurisy). Pleural rub stops after holding the breath but pericardial rub continues.
2. It should be differentiated from coarse crepitations by the points discussed above.

Conclusion :

To diagnose pleural rub, remember these 3 points :

1. Hold the breath (pleural rub disappears while pericardial rub continues).
2. Ask the patient to cough (D/D with crepitations; pleural rub does not alter with cough).
3. Press the chest piece of stethoscope (pleural rub intensifies or patient may C/O pain).

Case 81

EXAMINATION OF THE TONGUE

How examination of the tongue helps in the diagnosis in clinical practice ?

(A) Ask the patient to SHOW THE TONGUE by protruding it outside the oral cavity—the patient is unable to protrude the tongue in case of short frenum (known as 'tongue tie' or ankyloglossia), malignancy of the tongue and also in bilateral paralysis of the tongue (Xllth nerve palsy). Sluggish and slow protrusion is seen in mental retardation.

(B) MOVEMENT OF THE TONGUE :

1. **'Trombone tongue'** — rapid forward and backward movement of the tongue is characteristic of general paralysis of insane (GP1); may be seen in Parkinson's disease.
2. Ask the patient to protrude the tongue — the patient protrudes it momentarily and takes it back within the oral cavity instantaneously (lizard tongue)—seen in rheumatic chorea (Jack-in-the-box tongue).
3. 'Chewing tongue' — seen in athetosis, as if the patient is chewing something.
4. Irregular and continual rotatory movements of the tongue may be seen in extrapyramidal syndromes (dyskinesia) induced by drugs like phenothiazines, metoclopramide. levodopa.
5. Rolling movements of tongue are found in cretins, mongols and as part of tics.
6. Ask the patient to protrude the tongue out of the oral cavity and look for fine **tremor—** characteristically found in anxiety neurosis, thyrotoxicosis, chronic alcoholism etc.
7. Ask the patient to keep the tongue relaxed in the floor of the mouth and look for **fasciculation;** it is seen in MND, bulbar palsy or LMN palsy of Xllth cranial nerve.
8. Observe for lingual myoclonus (with palatal myoclonus), forced deviation of tongue (as part of focal seizure), and tics and habit spasm.

(C) SIZE OF THE TONGUE :

1. Large tongue or **macroglossia** (with impression of teeth in sides) is seen in,
   (i) Acromegaly.
   (ii) Myxoedema.
   (iii) Cretinism.
   (iv) Down's syndrome.
   (v) Primafy amyloidosis.
   (vi) Mucopolysaccharidosis e.g., Hurler syndrome.
   (vii) Haemangioma or lymphangioma of tongue.
   (viii)von Gierke's disease (glycogen storage disease).
   (ix) Angioneurotic oedema.
2. Small tongue or **microglossia** is seen in,
   (i) Cerebral diplegia.
   (ii) Bulbar and pseudobulbar palsy.
   (iii) Motor neurone disease (MND).
   (iv) Wasting of the tongue (LMN lesion of Xllth cranial nerve).

* Acute swelling of tongue is found in bite, infection, angioneurotic oedema, haemophilia, pemphigus.

(D) COLOUR AND MORPHOLOGICAL CHANGES :

1. Dry tongue — dehydration, mouth breathing, xerostomia, after administration of atropine.
2. Moist tongue — sialorrhoea in post-encephalitic parkinsonism, heavy metal poisoning.
3. Pale tongue — anaemia (severe).
4. Blue tongue — central cyanosis, meth- or sulphaemoglobinaemia (mainly the sides of the tongue), intake of blue coloured food material.
5. Yellow tongue — jaundice (the undersurface), intake of yellow coloured sweets.
6. Bluish-red tongue — polycythemia.
7. **Magenta-coloured tongue** (a bit pinkish) — riboflavin deficiency.
8. Black tongue — after ingestion of bismuth, liquorice, charcoal; Addison's disease.
9. Blotting paper like pallor (with black pigmentation in the margin) — often seen in hook-worm infestation.
10. White or greyish coating or 'furred' tongue — smoking, chronic debility, acute tonsillitis, sore throat etc. 'Fur' is common in heavy smokers.
11. **'Bald tongue'** — there is total loss or atrophy of papillae, and is classically seen in pellagra, pernicious anaemia, iron deficiency anaemia, tropical sprue and syphilis.
12. **'Raw-beefy tongue'** — red, swollen and painful tongue. Found in pellagra and vitamin B_{12} deficiency.
13. **'Angry-looking' tongue** — central coating with red tip and margins (enteric fever).
14. 'Black hairy' tongue — produced due to failure of keratin layer of the filiform papillae to desquamate normally. It is found in staining by tobacco, food, chromogenic organism, fungal infection, after use of penicillins and tetracyclines.
15. 'Geographic' tongue — denuded red patches 'wandering' or migrating (look like boundaries of a country map) across the surface of the tongue due to rapid loss and regrowth of filiform papillae. It is an asymptomatic inflammatory condition and though looks odd, it has no clinical significance.
16. 'Strawberry' and 'raspberry' tongue — hypertrophy of fungiform papillae with changes in filiform papillae, and is seen in scarlet fever. The tongue looks red with papillae standing out as white dots.
17. 'Scrotal' tongue — deep horizontal fissures in the tongue where debris may collect; of no clinical significance.
18. Median rhomboid glossitis — a lozenge-shaped denuded area in the middle of the tongue posteriorly. It is a congenital abnormality and should be differentiated from carcinoma of the tongue as it feels nodular.
19. White patches on the tongue — due to thrush (i.e., moniliasis due to immunosuppressive theraphy, diabetes and AIDS), other fungal infection, leucoplakia, chronic superficial glossitis etc.
20. Ulcers in the tongue — aphthous ulcer, frenal ulcer (in frenum), tuberculous ulcer (in dorsum), malignant ulcer (anywhere in the tongue), snail-track ulcer (in dorsum) in secondary syphilis, ulcers at the margins (by ill-fitted dentures) or ulcers from Behcet's disease (mimicking aphthous ulcer) may be present.
21. Bite mark in the tongue — accidental bite during eating or after convulsions.
22. **Spastic tongue** with pointed tip (without any fasciculation) — in pseudobulbar palsy.
23. **Flaccid tongue** with rounded tip and the tongue sits on the floor of the mouth like a mushroom (grossly wasted), often with fasciculation — in bulbar palsy.
24. Growth in the tongue (with halitosis)* — in squamous cell carcinoma of the tongue.
25. Mushroom like tongue — sore tongue with white slough, seen in corrosive poisoning.
26. Horny tongue (crocodile tongue) — tongue with cornification of the mucosa.
27. Dry, red tongue with atrophy of the papillae and fissures (parchment-like tongue)—seen in Sjogren's syndrome.
28. Hairy leucoplakia—painless white corrugated lesion on sides are due to Epstein-Barr virus infection, specially in AIDS.

(E) DEVIATION OF THE TONGUE :

Ask the patient to protrude his tongue,

1. In UMN lesion of Xllth cranial nerve — deviated to the opposite side.
2. In LMN lesion of Xllth cranial nerve — deviated to the same side.

(F) POWER OF THE TONGUE ;
Ask the patient to move the tongue inside the oral cavity at random and to press the cheeks with the tongue when resistance is applied in the cheeks from outside.

(G) TASTE SENSATION :
Taste sensation of anterior 2/3rd of the tongue is carried by the facial nerve and that of posterior 1/3rd is carried by the glossopharyngeal nerve. Sugar or saccharin, common salt, vinegar and quinine are used to test the sweet, salt, sour and bitter taste sensations respectively. Sensations perceived by the tongue are sweet at the tip, sour at the margins, bitter at the back and salt by any part of the tongue. Loss of taste sensation is ageusia and may result from lesions in any part of the peripheral and central pathways of taste fibres.

Directly ask the patient for recent loss of taste or any abnormal taste sensation. Now to test the taste sensation, ask the patient to close his eyes, hold the tongue with a swab and put the substance on the anterior 2/3rd of the protruded tongue on each side in turn. Ask him to identify the substance. Each time mouth is washed and a new substance is applied. Bitter sensation is tested last.

* **Halitosis** (malodorous breath)—the common causes are bad oral hygiene, smoking, decomposed food debris collected in between teeth, stomatitis, gingivitis, caries tooth, sinusitis, atrophic rhinitis, any tumour of nasal passage, carcinoma of the tongue, bronchiectasis, lung abscess, diabetes, hepatic and renal failure, gastro-colic fistula and intestinal obstruction.

** **Sialorrhoea** or ptyalism (hypersalivation) occurs during pregnancy, carcinoma of the tongue or mouth, stomatitis, caries tooth, Wilson's disease (drooling), acid or alkali poisoning, post-encephalitic parkinsonism, bulbar palsy, schizophrenia, hydrophobia; in arsenic, mercury or lead poisoning.

*** **Xerostomia** (dry mouth) is common in fear, anxiety, dehydration, high fever, drug-induced (diuretics, antipsychotics), Sjogren's syndrome, as a complication of polyuria, irradiation for head and neck carcinoma and psychogenic.

**** pigmented lesions within the oral cavity are seen in Addison's disease, Peutz-Jegher s syndrome, haemochromatosis, melanoma and lead poisoning (blue line or Burtonian line in the gum).

***** Tongue may be regarded as mirror of dysfunction of all the systems; previously tongue was known as the mirror of G. I. tract only.

Case 82

VISIBLE PERISTALSIS

Significance :

Usually no peristaltic wave is seen in health. Visible peristalsis signifies mechanical obstruction of intestine (pathological). As a normal finding, it is occasionally seen in children with thin abdominal wall or in adults where the abdominal musculature has been thinned out by repeated pregnancy, long-continued ascites or in elderly patients with lax abdominal wall (physiological).

Localisation of obstruction :

Obstruction is generally seen in one of these three places like stomach, small gut or large gut, and the site of obstruction is determined by analysing the peristaltic waves.

a) STOMACH — Usually visible peristalsis is seen due to obstruction at pylorus [Children - congenital hypertrophic pyloric stenosis (CHPS), adult - pyloric stenosis from chronic duodenal ulcer, old age - pyloric growth may produce gastric outlet obstruction] and the wave moves in the upper "abdomen from left to right hypochondrium, occasionally through the umbilical region. These waves are golf-ball like and generally not more than 2-3 waves are seen at a time. _

- b) SMALL GUT — The peristaltic waves are seen as 'ladder pattern' (zigzag fashion) in the peri-umbilical region and there may be 10-12 waves formation per minute,

c) LARGE GUT — If the obstruction is located in transverse colon, the waves are seen moving from right to left hypochondrium (opposite to pyloric obstruction). These are larger in size, i.e., cricket-ball like. The waves are seen in the flanks in case of obstruction of ascending or descending colon.

How to evoke peristalsis at the bedside ?

In a suspected case, peristalsis can be Induced by,

1. Flicking or gentle massage of the anterior abdominal wall, or
2. Drinking water (1-2 glasses), or
3. Pouring few drops of ether or alcohol over the abdomen.

Regarding inspection of waves, a tangential view is always better for slow waves. Small intestinal peristalsis may be occasionally seen normally through divarication of recti or in incisional hernia through abdominal scar.

Common causes of gut obstruction :

(A) Stomach - Pyloric stenosis, carcinoma of the stomach.

(B) Small gut - Adhesions and external hernias.

(C) Large gut - Colonic carcinoma, sigmoid diverticulitis and volvulus.

Common causes of gut obstruction in India :

Round worm infestation in children and intestinal tuberculosis in any age group.

Clinical confirmation, if peristalsis is seen in upper abdomen :

Give the patient a quick shake and carefully listen for succussion splash (e.g., pyloric stenosis).

Confirmation of diagnosis of intestinal obstruction :

After careful history taking and meticulous clinical examination, the physician should do a straight X-ray of the abdomen **in erect posture,** where observation of multiple fluid levels will confirm the diagnosis (normally there may be fluid levels in i) stomach ii) lower duodenal flexure, and at iii) ileo-caecal junction). *More than three fluid, levels clinch the diagnosis of intestinal obstruction.*

Importance of auscultation over abdomen :

1. Peristalsis Normal sound (vide page 111); increased in intestinal obstruction; absent in paralytic ileus.
2. Bruit—Specially in renal artery stenosis (best heard just above the umbilicus, about 2 cm on either side of midline), coarctation of aorta and aortoarteritis of abdominal aorta (systolic bruit); hepatic bruit (vide page 283). Bruit is also heard over aortic aneurysm.
3. Succussion splash—Vide page 110 (pyloric stenosis).
4. Venous hum—Vide page 434.
5. Hepatic and splenic rub—Vide page 283 and 287 respectively.
6. Ausculto-percussion—Vide page 110.
7. Uterine souffle (pregnancy).
8. Foetal heart sounds (auscultate with the bell of stethoscope).

Conclusion :

In a patient with visible peristalsis, always localise the 'site of obstruction' and look for :

1) Incision mark in the abdomen (adhesion from past abdominal operation), 2) Succussion splash, and 3) Borborygmi (intestinal obstruction).

Case 83

PROMINENT VEINS WITH VENOUS HUM

What is venous hum :

It is synonymous with murmur heard in arteries. One may call it venous murmur. It is produced as & result of enormous blood flow through the veins.

Common sites for venous hum :

Commonly heard as a continuous humming sound over prominent veins (i.e., collaterals) seen in the epigastrium or dilated veins seen around the umbilicus in cirrhosis of liver (pathological). Some-

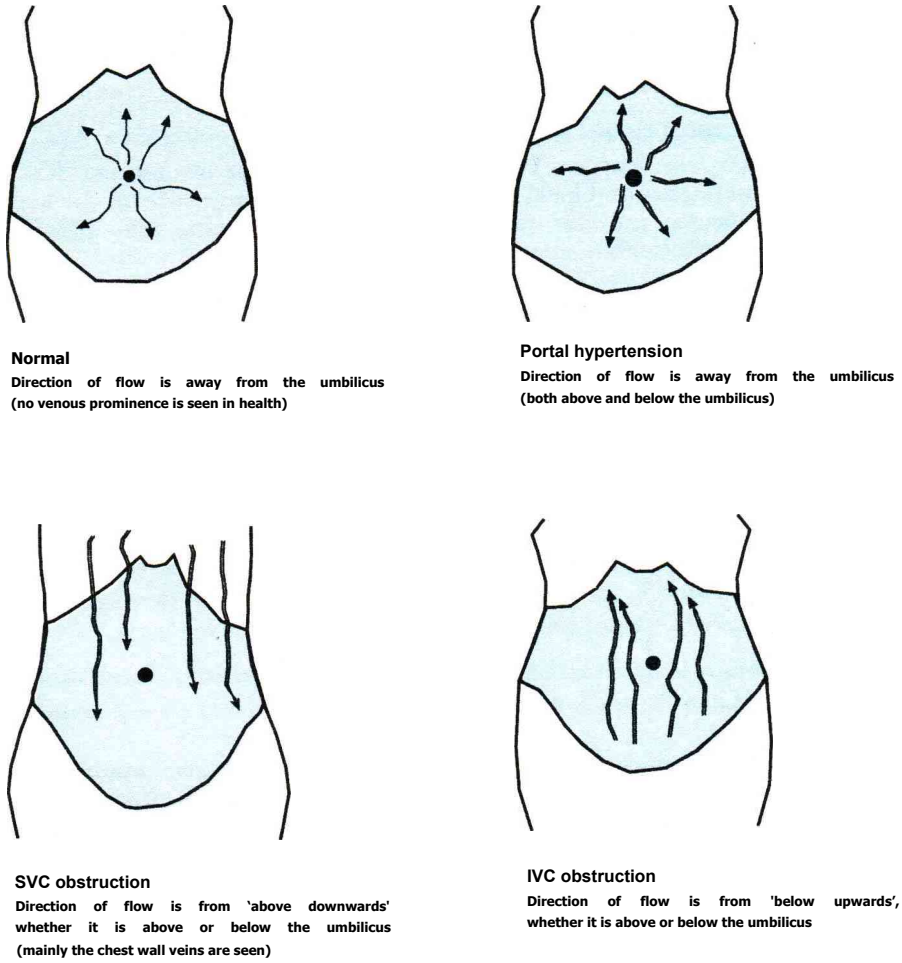

Fig. 2 : Abdominal wall veins

times it is heard above either clavicle in a child and during pregnancy (physiological). The cervical venous hum (Devil's murmur) in adults (pathological) is often audible in hyperkinetic circulatory states e.g., severe anaemia, thyrotoxicosis etc.

Characteristics of venous hum :

1. Soft and low-pitched.
2. Often continuous with early diastolic accentuation.
3. Best heard in sitting or erect position with the bell of stethoscope.
4. Best audible in inspiration.
5. Disappears on pressing the bell of stethoscope (so, place the bell lightly over a prominent vein), and after Valsalva manoeuvre. It is accentuated by exercise.
6. Thrill may be associated with and detected by application of light pressure.

In which situation should we search for abdominal venous hum ?

In the presence of dilated abdominal veins, we search for venous hum. The combination of dilated abdominal wall veins (caput medusae) and a loud venous hum at the umbilicus with normal liver is called Cruveilhier-Baumgarten syndrome. This syndrome may originate due to congenital patency o umbilical vein but more usually to a well-compensated cirrhosis.

Direction of blood flow in these prominent abdominal veins (see question above) :

Blood flow is always away from the umbilicus as it is dealing with a case of 'portal hypertension.

D/D of venous hum ***:***

(A) In the epigastrium : Hepatic bruit (over liver) or continuous murmur (e.g., coarctation of aorta).

(B) In the upper chest or supraclavicular area (left side) : Patent ductus arteriosus.

How these abdominal wall veins are formed in portal hypertension ?

Dilated and tortuous veins suggest venous obstruction. These are formed due to blood passing through a large umbilical or paraumbilical vein in the falciform ligament **from** the left branch of portal vein **to** the superior epigastric, internal mammary or inferior epigastric veins present in the abdominal wall (i.e., opening of anastomotic channels between portal and systemic veins).

How these abdominal wall veins are formed in IVC obstruction ?

These are dilated anastomotic channels formed between the superficial epigastric and circumflex iiiac vein **below,** and the lateral thoracic veins **above,** carrying blood from long saphenous vein to axillary vein. This is why the direction of blood flow is from below upwards.

Conditions associated with dilated chest wall veins

1. SVC obstruction (commonest).
2. Severe congestive cardiac failuure.
3. IVC obstruction (not uncommon).
4. Localised venous prominence : underlying pleural malignancy or empyema thoracis.
5. Extreme cachexia (due to loss of subcutaneous fat), and sometimes in lean and thin persons.

6- Thrombophlebitis of anterior thoracic vein (Mondor's disease)—rare.

How to know the presence of dilated and tortuous abdominal / chest wall veins ?

1. The patient is asked to sit with legs hanging from the bed (never examine in lying down position).
2. Then the patient is asked to **cough** or to perform the **Valsalva manoeuvre.** Cough makes the veins prominent transiently while the Valsalva retains the prominence of veins so long the manoeuvre is continued.
3. Proper light is necessary (patient facing the window) for demonstration.

Detection of direction of venous blood flow :

Method :

1. Make the veins prominent by adopting the above mentioned method. A tributoiy-free, long segment of vein (preferably one inch or more) is selected for examination.
2. Stand on the right side of the patient and place the index finger of both hands side by side over the vein—the left above the right one. Now start milking the. vein by movement of two index fingers in opposite direction.
3. The two ends ol the bloodless vein is blocked with the pressure given by two index fingers
   The left index finger is now removed and the rapidity of venous filling from above is noted.
   I he same procedure is repeated after removal of the right index finger and the rapidity of venous filling from below is observed now. The rapidity of venous filling indicates the direction of blood flow.

Venous flow in different conditions (Fig. 2 in page 435) :

(A) **Normally** — Away from the umbilicus (but one can not see any venous prominence in health).

(B) **Portal hypertension** — Away from the umbilicus (both above and below the umbilicus).

(C) FVC **obstruction** As a whole, the flow is below upwards, i.e.,

(i) Above the umbilicus - Upwards and away from the umbilicus.

(ii) Below the umbilicus - Towards the umbilicus.

(D) SVC **obstruction** — From above downwards as a whole.

Diagnosis of these pathological conditions at bedside :

The classical direction of venous flow helps in the diagnosis and the added features are •

1. Portal hypertension - Pedal oedema follows **ascites; splenomegaly; prominent veins** are mainly present in the epigastrium and umbilical area.
2. IVC obstruction - Ascites with bipedal oedema may be present **but ascites follows oedema**
   Prominent veins are seen over the abdomen, flanks and back; absence of splenomegaly.

3. SVC obstruction - Tortuous and prominent veins are present in the chest, upper arm with **facial puffiness,** chemosis of conjunctiva, and engorged and non-pulsatile neck veins; of en the patient is in respiratory distress.

Table 33 : Differentiation between portal hypertension and JVC obstruction

	Features	Portal hypertension	IVC obstruction
1.	H/O haematemesis or melaena	May be present	Absent
2.	Sites of venous prominence	Epigastrium and periumbilical	Abdomen, flanks, back; lower limbs
3.	Direction of flow	Away from the umbilicus	From below upwards
4.	Ascites	Precedes oedema; ascites is commonly seen	Follows oedema; ascites is uncommon
5.	Splenomegaly	Commonly present	Usually absent
6.	Venous hum	May be present	Absent
7.	Aetiology	Commonly cirrhosis of liver	Commonly abdominal or pelvic tumour, hypercoagulable states

•Visible vein' versus 'engorged vein' :

Sometimes, veins are visible normally in thin built persons (often in fair-skinned individuals) and is usually present at the skin level, i.e., flushed with the skin. But the engorged vein s a bit raised from the skin surface, which may be confirmed by tangenital application of light. Palpate the vei lightly by index finger and draw your inference. Visibility of a vein does not mean that it is pathological__engorgement and moreover, *tortuosity indicates its pathological nature.*

Conclusion :

For obvious reason, it is preferable to choose a vein below the umbilicus for demonstration of venous flow in abdominal wall veins. Engorged and tortuous veins always indicate some underlying pathology.

Case 84

KAYSER-FLEISCHER (K-F) RING

What is this ?

The K-F ring is formed by the deposition of golden-brown pigment of copper in the Descemets membrane of cornea in a patient suffering from Wilson's disease (hepato-lenticular degeneration).

Classical description :

The golden-brown pigment characteristically accumulate in the outer rim of cornea and the ring is broader superiorly and inferiorly than it is laterally and medially. The superior pole is first affected.

How the ring is detected ?

Many a time the ring can be seen in naked-eye examination. Examine the patient in sunlight, near a window or put a lighted torch in the eyes but slit-lamp examination by an ophthalmologist is usually necessary for confirmation. K-F *ring is the clinical hallmark of Wilson s disease* though their absence does not rule out the disease.

* Samuel A. K. Wilson (1878-1937) was an English neurologist.

Does it hamper vision ?

Never. It disappears after successful treatment.

Inference drawn, if K-F ring is detected :

The presence of K-F ring indicates that hepatic copper has been released in the circulation and

started damaging the brain. So, a patient of Wilson's disease with neurologic or psychiatric manifestations must have K-F ring in eyes. The commonest D/D at the bedside is arcus senilis.

Any other eye finding in Wilson's disease ?

There may be presence of sunflower cataract (15-20%).

Other conditions associated with K-F ring :

'K-F-like' ring may be seen in :

1. Cryptogenic cirrhosis,
2. Prolonged cholestasis due to any cause (e.g., primary biliary cirrhosis), and
3. Chronic biliary cirrhosis.

Types of hepatic involvement in Wilson's disease ;

In children, the liver is chiefly involved **(hepatic form)** though the clinical manifestations of excess of copper are rerely seen before the age of 6 years. The hepatic manifestations are in the form

1. Acute hepatitis,
2. Fulminant hepatitis (with haemolytic anaemia due to release of copper),
3. Chronic persistent and chronic active hepatitis,
4. Cirrhosis of liver, and
5. Asymptomatic hepatosplenornegaly.

* So, always search for jaundice and signs of hepato-cellular failure. Hepato-cellular carcinoma is very rare in Wilson's disease.

Neurological manifestations of Wilson's disease :

Patients presenting themselves after the age of 20 years usually suffer from neurological abnormalities (neurologic form). Neither there is any sign of sensory loss nor there are evidences of pyramidal tract involvement. The neurologic features (mainly of basal ganglia involvement) are :

1. Resting and intention tremor,
2. Chorea, athetosis,
3. Rigidity, parkinsonism,
4. Dysphagia,
5. Slurred speech, silly smile,
6. Difficulty in writing,
7. Grimacing,
8. Cognitive decline,
9. Drooling, and
10. Dementia.

* Three common movement disorders present are—dystonia, incoordination and tremor.

Psychiatric manifestations of Wilson's disease :

These are due to toxic effect of copper in the brain. Manifestations are in the form of :

1. Manic-depressive psychosis,
2. Schizophrenia,
3. Classic neurosis, and
4. Bizzare behaviours.

* Loss of emotional control (e.g., temper tantrums), hyperactivity and depression are common.

Investigations performed in Wilson's disease :

1. Low serum copper and ceruloplasmin (but can be normal).
2. 24-hours urinary copper is increased in the range of 100-1000 (xg.
3. Liver biopsy—affected patients have copper values > 200 |ig/g of dry weight of liver ('gold standard for diagnosis).
4. Haemolysis as well as anaemia.
5. Genetic analysis (due to mutation in ATP7B gene localised to chromosome 13).

Normal values of plasma and urinary copper :

Serum copper : 70-140 mg/dl.

Serum ceruloplasmin : 18-35 mg/dl.

Urinary copper excretion : 20-50 Mg/day.

Plasma (free) copper is low but urinary copper is increased in Wilson's disease. It is an autosorecessive disease with low plasma ceruloplasmin, and high levels of copper in liver and brain.

* 10% patients may have normal ceruloplasmin level.

** Other rare manifestations of Wilson's disease are amenorrhoea, spontaneous abortions, osteoarthritis, haematuria, proteinuria and renal tubular acidosis.

*** Low serum ceruloplasmin level is also seen in fulminant hepatic failure, protein losing enteropathy and malabsorption. High level is found in pregnancy and biliary obstruction.

Management of Wilson's disease :

1. D-penicillamine (with pyridoxine)—Life-long therapy is needed with 1-1.5 g of penicillamine daily, orally in divided doses. Penicillamine is usually available as 250 mg capsule. Pyridoxine supplementation (25 mg/day) is beneficial. As it is a toxic drug and may worsen existing neurologic disease, it is not preferred as a first line drug.
2. Elemental zinc as acetate (inhibits gastro-intestinal absorption of copper) — 50 mg, thrice daily. Zinc is the therapy of choice by many clinician.
3. Trientine hydrochloride (1.2-1.8 g/day in 2 or 4 divided doses)—as a chelator.
4. Low-copper diet, or avoidance of high-copper diet i.e., peanut, chocolate, mushrooms, liver, coffee, shellfish, legumes, nuts, dried beans should be avoided.
5. Liver transplantation.
6. Physiotherapy.

* Potassium iodide (20 mg, four times daily), cobalt chloride and tetrathiomolybdate are other drugs used in Wilson's disease. Wilson's disease is potentially treatable.

** Siblings of the patient are screened for Wilson's disease and treated even if asymptomatic.

Side effects of penicillamine :

1. Hypersensitivity reaction (rash, fever).
2. Nausea, vomiting, mouth ulcers.
3. Agranulocytosis.
4. Thrombocytopenia.
5. Nephrotic syndrome.
6. SLE.
7. Severe arthralgia.
8. Myasthenia gravis.
9- Pemphigus.
10. Goodpasture's syndrome, rarely.

It is mandatory to check routine blood count and urinary protein regularly when on penicillamine.

Use of penicillamine in clinical practice :

1. Wilson's disease.
2. Rheumatoid arthritis.
3. Chelating agent for copper, mercury, lead poisoning.
4. Scleroderma.
5. Primary biliary cirrhosis.
6. Cystinuria.

D/D of K-F ring :

(A) To an inexperienced eye, K-F ring may be confused with **'arcus senilis'.** Arcus is present in the periphery of cornea and is white in colour (usually starts in the lower pole of cornea). It is generally present above the age of 50 years, and represents deposition of phospholipid and cholesterol in corneal tissue (no significance in elderly people). If arcus is present before the age of 50 years, there is a possibility of underlying hyperlipidaemia **(arcus juvenilis).** It is not unduly associated with atherosclerosis, hypertension, myocardial infarction, diabetes mellitus or stroke. It does not affect vision.

(B) Rarely, corneal calcification (band keratopathy) which occurs at the lateral and medial margins of cornea in long-standing hypercalcaemia, e.g., in hyperparathyroidism, may be confused with K-F ring.

Conclusion :

Ability to incorporate radioactive copper (^{64}Cu) into ceruloplasmin differentiates Wilson s disease (little or no incorporation) from other copper-storage disorders (e.g., primary biliary cirrhosis).

It is a dictum that young patients with chronic liver disease showing mental abnormality, chorea, early ascites or haemolysis should always be screened for Wilson's disease, and the clinician should enquire for positive family history and search for K-F ring in that setting.

Case 85

PES CAVUS

Definition :

This is a fixed deformity of foot where both feet are more or less symmetrically high-arched i.e., there is gross exaggerbation of the medial longitudinal arch of the feet. It may result from weakness of intrinsic muscles (lumbricals and interossei) which in turn may be due to poliomyelitis, spina bifida etc. Pes cavus may be associated with clawing of the toes. It is just opposite to pes planus (flat foot) defromity.

Method of demonstration at the bedside :

1. Ask the patient to stand on the floor and observe that only toes, webs and heel touch the floor surface, or
2. Take a foot-print on a white paper after painting the foot by lac-dye or any colouring agent, or
3. After immersing the feet in water, ask the patient to walk barefooted and watch the foot-prints on the floor.

Diseases associated with pes cavus (claw foot) :

Claw feet results from wasting of small muscles of feet due to any cause. The causes are :

1. Friedreich's ataxia.
2. Peroneal muscular atrophy.
3. Syringomyelia.
4. Poliomyelitis.
5. Spina bifida.
6. Cerebral palsy.
7. Familial neuropathies e.g.. Refsum's disease.
8. Idiopathic.

What is Charcot-Marie-Tooth disease ?

It is synonymous with peroneal muscular atrophy (a variety of hereditary senori-motor neuropathy).

Situations where "Charcot's" name has been coined ?

1. Charcot-Marie-Tooth disease (hereditary polyneuropathy).
2. Charcot's biliary triad — Recurrent pain abdomen or biliary colic, fluctuating jaundice and intermittent fever with rigor in patients suffering from stone in CBD.
3. Charcot's intermittent hepatic fever— Fever due to cholangitis principally in the affection of intrahepatic biliary radicles.
4. Charcot joint or neuropathic joint (see page 484).
5. Charcot-Leyden crystals — Found in sputum of patients suffering from bronchial asthma or stool of patients suffering from acute amoebic dysentery.
6. Charcot's artery of cerebral haemorrhage (lenticulostriate branch of middle cerebral artery) — Usually associated with hypertensive cerebral haemorrhage.
7. Charcot's (cerebral) triad — Intention tremor, scanning speech and nystagmus seen in multiple sclerosis.
8. Charcot's vertigo — It is synonymous with 'cough syncope'.
9. Charcot zones — Hysterogenic zones in the human body.
10. Charcot-Neumann crystals — It is the phosphate crystals present in semen.

* Jean-Martin Charcot (1825-1893) was a physician in Hospital Salpetriere, Paris, France.

What is Friedreich's ataxia ?

It is an autosomal recessive form of spinocerebellar degeneration. The patient usually presents between the ages of 5 to 15 years, with clumsiness in walking and trunk ataxia. Gradually there is loss of proprioception and vibration sense with development of muscular atrophy, and loss of tone in the lower limbs. **Tendon reflexes are lost but plantar response remains extensor.** The degenerative process ascends upwards, and affects speech (dysarthria) and movements of the eyes (nystagmus). Optic atrophy (30%) may be seen. Kyphoscoliosis and pes cavus may be evident. It may be associated with diabetes mellitus and cardiomyopathy. The patient is wheel-chairbound by the age of 20. Diagnosis is made by positive family history and clinical findings.

(i) Calculation—Serial 7-subtraction test (i.e., 100, 93, 86, 79, 72 ....) i;e., the arithmatic ability.
(ii) Judgement — Ask the patient 'what will you do if you see a house set on fire, or a stamped and addressed envelope lying in the road in front of your house' ?
(iii) Insight — Observe his awareness about the illness for which he has been admitted.
(iv) Reasoning — Can he tell the difference between 'poverty and dishonesty', 'child and dwarf etc ?
(v) Abstract thinking — Ask him the meaning of proverbs like 'all that glitters is not gold'.
(vi) Attention — It is tested by. tapping the finger with repetition of a particular number.
(vii) Concentration—Ask the patient to count backwards from 20 to 1.

$$* \quad \text{Intelligence quotient (IQ)} = \frac{\text{Mental age}}{\text{Chronological age}} \times 100.$$

** Mental retardation (assessed by IQ) : Mild (50-70), moderate (35-49), severe (20-34), and profound (< 20). Normal IQ is 90-109, whereas > 140 is regarded as near genius.

Mini-mental state examination (MMSE) :

This is a 'simple bedside test' to assess derrangements in the higher functions (i.e., mental or intellectual functions), and is performed by Mental Status Questionnaire (MSQ). The results are scored numerically (the test takes 5-10 minutes and is scored out of 30). The functions tested are 1. Orientation 2. Registration 3. Attention and calculation 4. Recall, and 5. Language.

How do you classify the level of consciousness clinically ?

(A) **Conscious** - Relates to the person who is alert, attentive and co-operative. Actually, it is a state of awareness of one's self and environment.
(B) **Confused** - It denotes incapacity of the patient to think with customary speed and clarity. The patient is conscious but often talks irrelevantly.
(C) **Drowsy** - The patient is sleepy but can be aroused easily by external stimulus.
(D) **Stupor** - The patient who appears to be asleep can be aroused only by painful stimulus (pinching or supraorbital pressure).
(E) Semicoma - When the patient responds only to internal stimulus (e.g., the patient may shake his body with fullness of urinary bladder) but not to external painful stimulus.
(F) **Coma** - No response by internal or external stimuli, and the patient is deeply unconscious.

* The degree of coma or the level of consciousness is assessed now-a-days (as the terminology like drowsy, stuporose, semicoma are ill-defined) by **Glasgow coma scale (GCS)** but GCS can never be a substitute for thorough neurological examination. Circle the best scores from eye opening, motor response and verbal response, and compute the total.

Table 34 : Glasgow Coma Scale (clinical grading of coma)

EYE OPENING (E)	
Spontaneous	4
To speech	3
To pain	2
None	1
BEST MOTOR RESPONSE (M)	
Obeys commands	6
Localises pain	5
Flexion withdrawal	4
Abnormal flexion (decorticate posture)	3
Abnormal extension (decerebrate posture)	2
None (flaccid)	1
VERBAL RESPONSE (V)	
Oriented and converses	5
Confused and disoriented	4
Inappropriate words	3
Incomprehensible sounds	2
No response	1

N.B. : Coma scores = E+M+V : fully conscious =15, and deeply comatose = 3; scores >11 having 5-10% likehood of death, while scoring 3 or 4 have 85% chance of dying

Diagnosis of spina bifida occulta :

Over the lower back, there may be :

1. Tuft of hair,
2. Dimpling of the skin,
3. Dilated vessels,
4. Fibrofatty tumour, or
5. Cicatrical thickening of skin.

Skeletal abnormalities in neurology :

1. Kyphoscoliosis,
2. Gibbus,
3. Pes cavus,
4. High arched palate (rare),
5. Various skull deformities, and
6. Short neck (cranio-vertebral anomaly).

Case 86

TESTS OF MEMORY

Different types of memory :

1. Short term memory, immediate recall or rote memory.
2. Recent memory, and
3. Past memory, long term or remote memory.

What are the different components of memory ?

It may be arbitrarily divided into 4 parts :

1. Registration (defect found in manic states, senile dementia),
2. Retention (defect found in frontal lobe lesion, GPI),
3. Recall (defect found in epilepsy, Korsakoffs psychosis, post-traumatic states), and
4. Reproduction (defect found in CVA).

How to test the memory function at the bedside ?

Clinically 3 forms of memory are tested at the bedside :

(A) **Short term memory** - memory which lasts upto 30 seconds, and is tested by,
- (i) Whether the patient can repeat 'seven digits forwards' or 'five digits backwards' (digit span test).
- (ii) Ask the patient to spell 'India' backwards.
- (iii) Give him a telephone number and ask the number after 30 seconds or so.

(B) **Recent memory** - It is the memory of events occurred within minutes, weeks, months and is an index of the severity of organic brain disease, which is usually tested by,
- (i) Ask the morning news what he has read in the newspaper or seen on television.
- (ii) Give him the names of three different objects and ask it after 3-5 minutes.
- (iii) Ask him about the name of the visitors who met him last evening.

(C) **Past memory** - This part of memory (events occurred years back) is relatively resistant to the effects of neurological insults. It is examined by,
- (i) Ask the patient some important events in life e.g., date of birth, date of marriage etc.
- (ii) Ask him the date of 'Independence day of India'.
- (iii) Ask him the name of the first Prime Minister of India.

* In Wernicke-Korsakoff syndrome, the recent memory is lost with intact past memory whereas the past memory is affected in dementia (e.g., in the late stage of Alzheimer's disease).

What is dementia ?

It means loss of reasoning or more particularly, a deterioration of all intellectual and cognitive functions, without clouding of consciousness or disturbance of perception, and is due to chronic progressive degenerative disease of brain. In dementia, the patient is awake and alert but not aware.

* Two most important types of organic brain syndrome are delirium (acute) and dementia (chronic).

Causes of emotional lability or 'emotional incontinence' :

1. Cerebral atherosclerosis.
2. Multi-infarct dementia.
3. Peseudobulbar palsy.
4. Disseminated sclerosis.

Tests of 'intelligence' :

Intelligence is a total assessment of judgement, reasoning, arithmatic ability etc. and is tested by :

'Released reflexes' in dementia :

In infancy, developmental assessment is very often done by the presence (so called, 'primitive reflexes') or absence of these reflexes. It late infancy, these reflexes disappear as cortical control develops. In few pathological conditions in adults, these reflexes are released from the control of higher centres and thus, may be elicited. The examples are,

(i) Dementia,

(ii) Organic confusional states, and

(iii) Sometimes in contralateral frontal lobe lesion.

The reflexes are :

1. Grasp **reflex** - Stroke the palmar surface of the patient's hand on its 'radial' aspect (region between the thumb and the index finger) by a distally moving stimulus. The patient immediately grasps the object and is unable to relax his grasp voluntarily. It is classically seen in contralateral frontal lobe lesion.
2. Forced groping reflex—someties, if the palmar surface ('radial' aspect) of patient's hand is lightly touched (patients' eyes are closed), the fingers close upon the object, and the hand and arm move towards the stimulus.
3. Avoiding reflex - It is the tendency of the patient's hand to move away from palmar stroking when an object is touched on the 'ulnar' side of the hand. It is commonly seen in contralateral parietal lobe disease.
4. **Palmo-mental reflex** - Scratch the thenar eminence with a pin, key or finger, and there will be puckering of the chin due to contraction of the ipsilateral mentalis muscle. It suggests contralateral frontal lobe lesion, pyramidal lesion or diffuse cerebral disease (may be seen normally in some elderly individuals). This reflex usually have no localising value.
5. Sucking reflex - The contact of an object with the lips or corner of the mouth evokes the movements of the lips, tongue and jaw concerned in sucking.
6. Rooting reflex - The lips follow the stimulating object when it is touched on the lips.
7. Snout reflex - A gentle tap of the examiner's knuckle against the centre of patient's closed upper lips will produce pouting of the lips due to reflex puckering of orbicularis oris.
8. **Glabellar tap reflex (Myerson's sign)-** Normally after repeated tapping of the glabella by standing behind the patient, there are only three or four blinks before the response is inhibited. But in parkinsonism and senile dementia, the response goes uninhibited i.e.. a blink follows after each tap.

Common causes of loss of memory (dementia) :

1. Transient — Following concussion, epilepsy.
2. Cerebral arteriosclerosis (multi-infarct dementia).
3. Alzheimer's disease, Pick's disease.
4. Tumour affecting frontal lobe or corpus callosum.
5. Alcoholism.
6. Chronic subdural haematoma.
7. Pellagra, vitamin B_{12} deficiency.
8. Hypothyroidism.
9. Wilson's disease.
10. Wernicke-Korsakoff syndrome.
11. 'Normal pressure' hydrocephalus
12. Huntington's chorea.
13. AIDS.
14. Renal failure, hepatic failure.

Case 87

SPEECH DISORDERS

What is speech ?

It is the symbolic expression of thought process in spoken words or written words.

Types of speech disorders :

1. Aphasia or dysphasia (defect in higher centre with difficulty in language function).
2. Dysarthria (defect in articulation, commonly due to neuromuscular or muscular disorders resulting in impaired coordination of facio-lingual muscles)—slurring, mumbling etc.
3. Dysphonia (disorder of phonation due to abnormality in the vocal cord)—hoarseness, voice loss etc.

* Mutism means inability to speak while aphonia is inability to produce sounds.

Prerequisites before testing speech :

1. Level of consciousness,
2. Handedness (right or left),
3. Mother language,
4. Intelligence level (education etc),
5. Deaf or not, and
6. Vision.

* So, speech disturbance may be due to : 1. Deafness 2. Dementia/depression (severe) 3. Dysphasia (motor os sensory) 4. Dysarthria 5. Dysphonia.

Where the 'speech area' lies in the brain ?

In the right-handed person (90-95% of general population), it is present in the left hemisphere. In a left-handed person, it is present in the left hemisphere in 70% cases. In ambidextrous persons too, the left hemisphere is the dominant one. Dominant hemisphere also controls language and mathematical functions. The speech areas are distributed as follows :

A) Motor or Broca's area (area 44) is situated in the posterior part of inferior frontal gyrus (spoken word) and in the posterior part of middle frontal gyrus (written word).

B) Sensory or Wernicke's area (area 39 and 40) is situated in the posterior end of superior and middle temporal gyri.

Types of dysphasia or aphasia :

1. **Expressive aphasia or nonfluent aphasia -**
   (i) Motor or Broca's aphasia — Commonest variety. The patient is unable to speak although there is no paralysis of tongue or lips.
   (ii) Agraphia — Inability to write although there is no paralysis of hand muscles.
2. **Sensory or Wernicke's aphasia or fluent aphasia -**
   (i) Word deafness — Though the patient can hear the sound, he is unable to analyse its meaning.
   (ii) Word blindness — The patient can see that something is written but he cannot recognise the words. His mother language appears as a foreign language to him.

3. **Global aphasia** - This is the combination of 1 and 2 i.e., there is defective comprehension as well as production of speech.

Speech evaluation at the bedside :

1. Spontaneous speech i.e., listen the articulation, content, comprehension and fluency.
2. Ask for naming simple objects like pen, coin, book etc.
3. Ask the patient to repeat words or phrases.
4. Instruct the patient to read aloud and to write a simple sentence.

How to examine an aphasic patient ?

1. Ask the patient his name. If he keeps mum, then it is the task of the physician to determine the variety of aphasia : motor or sensory type.
2. Now, write 'show me your tongue' on a white paper and show the paper to the patient. If he protrudes his tongue, then it is a case of expressive aphasia (comprehension is perfect and word blindness is not present) and if he does not protrude the tongue, probably you are dealing with a case of sensory aphasia or global aphasia. This test may be done by showing the examiner's protruding tongue to the aphasic patient.

What is ***the commonest cause of aphasia*** ?

Ischaemic cerebrovascular disease (CVA) is the commonest cause of aphasia. Cerebral haemorrhage causes aphasia less often than thrombosis because haemorrhage occurs deep in the white matter of the hemisphere, more often than in the cortex or subcortical regions. The patient with motor aphasia is often hemiplegic (right-sided hemiplegia) as most of the persons are right-handed.

Intracranial tumour is the commonest cause of aphasia during the first half of adult life.

What is nominal aphasia ?

The patient fails to name the common objects like pen, pencil, coin etc (produced in front of him) though he can tell the use of it. If he is told the actual name of the object, he immediately accepts it gladly.

Site of lesion — In between the angular gyrus and the posterior part of superior temporal gyrus.

What are the different dysarthrias ?

The normal requisites for production of syllables are—

- Articulation—labial, lingual and palatal muscles.
- Phonation—larynx.
- Resonance—nasopharynx.
- Along with nomral respiration.

The different types of dysarthria are :

1. Spastic dysarthria — Difficulty in uttering the words but the words pronounced will be distinct. There is difficulty in pronouncing 'b', 'p\ or 't'. It is commonly seen in pseudobulbar palsy.
2. Flaccid dysarthria — There is much difficulty in uttering the words and the uttered words will be slurred and indistinct. Often there is added nasal intonation ('egg' in pronounced as 'eng'). This type is commonly seen is bulbar palsy ('Donald Duck' quality), alcoholism etc.
3. Scanning or staccato speech — Read the section on 'Cerebellar disorder'.
4. Slow, monotonous speech without any fluctuation (i.e., lacking accents) — Seen in parkinsonism.
5. Lalling speech (voice) — Commonly seen in children, cretinism, Down's syndrome and mental retardation.
6. Stammering speech — Usually congenital in nature.

* In a patient of hemiplegia, dysphasia is due to involvement of dominant hemisphere, and dysarthria is usually due to UMN type of affection of Vllth and/or Xllth nerves.

** Ill-fitted dentures are very common cause of dysarthria.

*** Vllth nerve palsy = labial dysarthria; Xllth nerve palsy = lingual dysarthria.

What is dysphonia ?

Dysphonia is commonly due to laryngitis, tumour of the vocal cord or bilateral adductor paralysis (the voice becomes hoarse). In this disorder of vocalisation, the fault lies in the vocal cord.

How to diagnose hysterical aphonia ?

The hysteric aphonic patient (commonly a female) whispers but cannot talk aloud. Ask the patient to cough or give a painful stimulus. These two menoeuvres will definitely produce a sound.

* Echolalia—repetition of examiner's word, palilalia—repetition of terminal words of own speech, jargon aphasia—neologisms (new words) making no sense at all, alexia—inability to read, and perseveration—repeated use of particular words or phrases.

** Flaccid dysarthria, scanning and monotonous speech may be given in the examination.

Case 88

TREMOR

What is tremor ?

These are involuntary, repetitive, oscillatory movements of a part of the body around a fixed point due to alternate contraction and relaxation of groups of muscles with their antagonists.

How do you classify tremor clinically ?

(A) According to relationship with posture :

1. Static tremor,
2. Kinetic, postural or action tremor,
3. Intention tremor, and
4. Flapping tremor.

(B) According to amplitude ;

1. Fine, and
2. Coarse tremor.

How will you examine a patient for tremor ?

At First, look for the presence of any **static tremor** (tremor at rest). This is classically seen in parkinsonism. In the hand, it is described as 'pill-rolling' or 'cigarette making' tremor. This very obvious tremor is characterised by,

1. The wrist and elbows are semiflexed, fingers flexed at MCP joints and extended at interphalangeal joints with abduction of the thumb. The oscillations of the fingers and thumb in two planes produce the 'pill-rolling' effect (flexion-extension at wrist and fingers, pronation-supination in forearm along with abduction-adduction of thumb and complex combinations).
2. It is a static tremor and does not increase at the goal point of action.
3. Coarse in nature (4-6/second).
4. More prominent in hands and can be controlled temporarily by willed movements.
5. Tremor is worse during anxiety or emotion, and is supposed to decrease on activity. It disappears during sleep.
6. If may involve the head, jaw, tongue, legs and even the trunk.

* Other features of parkinsonism like hypokinesia, rigidity, flexed posture and festinant gait will be present. There may by 'drum-beating' or 'bread cutting' tremor present in parkinsonism.

Now, look for the presence of any **kinetic** or **action tremor.** The patient is asked to outstretch his hands with separated fingers (a paper or thin piece of cardboard may be placed over the outstretched fingers) for the appearance of tremor, if present. This type of tremor is seen in anxiety, thyrotoxicosis, chronic alcoholism, by application of drugs (salbutamol, sympathomimetics, tricyclic antidepressants) or in familial tremor. Action tremor is characterised by,

1. Fine in nature (7-10/second).
2. Disappears at rest, and appears in precise and accurate movements.
3. May also be seen in tongue, lips and head.

* Familial tremor is often diminished by intake of alcohol.

Next the patient is examined for the presence of any **intention tremor.** This is classically seen in cerebellar disease, and rarely in severe parkinsonism. It is characterised by,

1. Coarse in nature (4-6/second).
2. Tremor appears at the goal point of an action (i.e., absent at rest and at the beginning of any movement). The patient is asked to hold a glass of water which is kept on the table or to do the 'finger nose test'. The movement becomes clumsy before he reaches the target.
3. Sometimes, there is tremor seen in head (titubation).

* Other signs of cerebellar disease like hypotonia, nystagmus, 'past pointing' etc. will be present.

Lastly, examine the patient for the presence of any **flapping tremor** (asterixis or bat's-wing tremor). This is elicited by three different manoeuvres :

1. By asking the patient to outstretch his arms with the hands extended at wrists and MCP joints, and to keep the limbs in this position for 20 seconds, when jerky forward movements of hand occurs every 2-3 seconds, or
2. By keeping the upper limb in bed with forearm fixed, the wrist is passively extended by holding the fingers. After few seconds, the pressure is released and the patient is instructed to keep the hand in the extended position ***(classical method).*** The respone is described below..
3. Ask the patient to squeeze the physician's extended fingers—Flapping tremor is said to be present as indicated by repeated intensification and relaxation of the intensity of the squeeze ("milkmaid's grip").

Reponse— There is rapid flexion-extension movements at the MCP joints which are often accompanied by lateral movements of the digits and the hand ultimately falls (looks like 'good-bye'). This type of tremor is due to impaired inflow of joint and other afferent informations to the brainstem reticular formation which results in lapses in sustained posture, i.e., there is development of neuromuscular incoordination between flexor and extensor muscles. Flapping tremor is classically seen in,

(i) Hepatic precoma ('liver flap'),
(ii) Renal failure,
(iii) Respiratory failure (carbon dioxide narcosis),
(iv) Severe cardiac failure,
(v) Hypnotic poisoning, and
(vi) Toxic encephalopathies.

* Flapping tremor is absent in hepatic coma.

What are the other sites you will examine next ?

1. THE TONGUE—The patient is asked to protrude the tongue out of the oral cavity for at least 1/2 minute (fasciculation in the tongue is seen when the tongue is relaxed in the floor of the mouth, and not protruded).
2. Head (and neck)—Titubation.
3. Jaw, lips, trunk or lower limbs.

* **One must examine tremor both in hands and tongue.**

Common causes of tremor :

(A) Fine (7-10/second) :

1. Anxiety, nervousness, fatigue.
2. Senile tremor.
3. Thyrotoxicosis.
4. Chronic alcoholism.
5. Drugs like salbutamol or terbutaline.
6. Familial (benign essential tremor).
7. General paralysis of insane (GPI).

(B) Coarse (4-6/second) :

1. Static tremor of parkinsonism.
2. Intention tremor of cerebellar disease or multiple sclerosis.
3. Flapping tremor of hepatic precoma, uraemia.
4. Sometimes, senile tremor.
5. Wilson's disease.

Types of tremor :

1. Static.
2. Action.
3. Intention.
4. Flapping.
5. Senile.
6. Physiological (anxiety).
7. Familial.
8. Hysterical.

Commonest cause of tremor in clinical practice :

Physiological tremor due to anxiety, fear or nervousness.

Identification points (facies) for aetiological diagnosis of tremor :

See the face and observe for :

1. Exophthalmos—Thyrotoxicosis.
2. Flushed face with parotid swelling—Chronic alcoholism.
3. Masked facies—Parkinsonism.
4. Anxious face—Anxiety neurosis.
5. Very old person—Senile tremor or parkinsonism.
6. K-F ring with jaundice—Wilson's disease (asterixis).
7. Alae nasi moving (i.e., the patient is breathless) — Drug-induced (sulbutamol).

Case 89

PTOSIS

Definition :

Drooping of one or both upper eyelid.

What are the types of ptosis ?

1. Complete, and
2. Partial.

* Again, ptosis may be congenital or acquired.

** Recently, ptosis is divided into 5 types : blepharoptosis (eye surgery, old trauma), mechanical (oedema of upper eyelid), aponeurotic (cataract surgery), myogenic (myasthenia gravis, myopathies), and neurogenic (Illrd cranial nerve palsy or Horner's syndroms).

How to recognise partial ptosis ?

By the narrowing of the palpebral fissure, when the clinician stands in front of the patient and the patient looks forward.

Common causes of ptosis :

1. Oculomotor nerve paralysis (usually complete, may be partial).
2. Horner's syndrome (always partial or pseudoptosis).
3. Tabes dorsalis (partial).
4. Myasthenia gravis (worsens as day progresses).
5. Myotonia dystrophica; ocular or oculo-pharyngeal myopathy.
6. Congenital (the upper eyelid is smooth and devoid of any cutaneous folds; and with compensatory head posture i.e., head tilts slightly backwards).

7. Snake bite (Elapidae group).
8. Botulism.
9. Periodic paralysis.
10. Hysterical.
11. Oedema or tumour of upper eyelid, enucleation of eyeball.
12. Temporal arteritis.

* Congenital ptosis may be unilateral or bilateral. Acquired ptosis is usually **unilateral** in Illrd nerve palsy, Horner's syndrome, senility, traumatic and hysterical conversion reaction. It is **bilateral** in tabes dorsalis, myopathy or disorders of myoneural junction.

** Unilateral ptosis is a recognised finding in cluster headache, syringobulbia and cavernous sinus thrombosis.

*** 'Narrow palpebral fissure' results from ptosis and pseudoptosis, enophthalmos and blepharospasm.

What is the opposite phenomenon of ptosis ?

Retraction of the upper eyelid, i.e., spasm of the Muller's muscle in thyrotoxicosis due to sympathetic overactivity.

Nerve supply of the upper eyelid :

There are two muscles in the upper eyelid like,

1. Levator palpebrae superioris (LPS)—Supplied by Illrd cranial nerve.
2. Muller's (tarsal) muscle—Supplied by sympathetic trunk.

Test the power of LPS muscle or upper eyelid, or ***test for ptosis :***

(A) First step Stand in front of the patient face to face, and ask him to look upwards or elevate the upper eyelid voluntarily.

(B) Second step—Now push down the frontal belly of occipitofrontalis muscle of forehead by your left hand (it is done to eliminate its elevating action on the upper eyelid). Again ask the patient to look upwards.

(C) Third step—If the patient can elevate the upper eyelid, now you may apply little resistance by your right index finger over the upper eyelid and ask the patient to look upwards again (obviously with eliminating the action of forehead muscle). Compare with the other side.

* If the patient can not elevate the upper eyelid voluntarily, it is useless to do the next steps.

What is pseudoptosis ?

In a patient of Horner's syndrome, (i.e., damage to the cervical sympathetic fibres) though there is 'partial' drooping of the upper eyelid, the ptosis is often corrected on looking upwards voluntarily (due to intact Illrd nerve) and thus, it is known as pseudoptosis (i.e.. false ptosis).

Features of Illrd cranial nerve palsy :

1. Usually, it is unilateral 'complete ptosis' (as there is complete ptosis in one eye, patients do not complain of diplopia; patients are not able to open the affected eye voluntarily).
2. Lateral or divergent squint (due to unopposed action of lateral rectus). The patient is unable to move the eye upwards, downwards and medially.
3. Fixed (loss of light and accommodation reflex) and dilated pupil.

* Diplopia is complained by the patient as soon as the affected upper eyelid is elevated by fingers.

Components of Horner's syndrome :

Horner's syndrome results from damage to the cervical sympathetic fibres. It is the unilateral—

1. Pseudoptosis (diagnosed by narrowing of palpebral fissure; it is partial ptosis).
2. Miosis (constriction of the pupil, as cervical sympathetic supplies the dilator pupillae)—The pupil shows reaction to light.
3. Anhidrosis (involves ipsilateral half of the face and neck, front and back of upper chest, arm).
4. Enophthalmos (sympathetic supply maintains the tone of the eyeball)—shrunken eye.
5. Loss of ciliospinal reflex (in health, when the skin of the sides of neck is pinched, there is reflex dilatation of pupil and this reflex is abolished in Horner's syndrome).

* Johann F. Horner (1831-1886) was Professor of Ophthalmology, Zurich, Switzerland.

Trace the pathway of ocular sympathetic fibres :

1st order of neurones of sympathetic fibres descend from hypothalamus -> brainstem —> interomediolateral horn of spinal cord at C_g, T, level -> 2nd order of neurones start and go upto superior sympathetic ganglion —> 3rd order of neurones from there carried around carotid artery -» ophthalmic division of Vth nerve nasociliary nerve -> long ciliary nerve -> oculopupillary fibres -> supply dilator pupillae and Muller's muscle of upper eyelid.

Differentiate between Illrd nerve palsy and Horner's syndrome-induced ptosis ?

Illrd nerve palsy :	Horner's syndrome :
1. Usually complete ptosis	1. Partial ptosis
2. Dilated pupil	2. Constricted pupil
3. Squint	3. No squint
4. Extraocular muscle palsy present	4. Extaocular muscles—normal

Can you test the Muller's muscle ?

No. It is an involuntary muscle.

Ptosis and pupil :

1. Ptosis and dilated pupil—Illrd nerve palsy.
2. Ptosis with constricted pupil—Horner's syndrome.
3. Ptosis with normal-sized pupil—myasthenia gravis, myotonia dystrophica, botulism (in majority), snake bite, and rarely in infarction or ischaemia of Illrd nerve (e.g., vasculitis, migraine or diabetes).

What is 'Tabetic fades' ?

This is the classical facies of tabes dorsalis and is characterised by :

1. Bilateral partial ptosis (as a result of paralysis of Muller's muscle),
2. Presence of compensatory wrinkling in the forehead (to overcome the partial ptosis),
3. Elevated eyebrows, and

[4. Associated Argyll Robertson pupil],

* Increased furrowing in the forehead may be seen in any long-standing ptosis.

Speciality of ptosis in myasthenia gravis :

Ptosis may be unilateral or commonly bilateral, and appears towards the end of the day after repeated use of the upper eyelid (fluctuating ptosis with diurnal variation). Ptosis is corrected dramatically by the I.V injection of edrophonium hydrochloride (Tensilon test). There is **no alteration in the pupillary reflex or size of the pupil.** Sustained upward gaze for 2 minutes leads to increased ptosis.

Bedside tests for myasthenia gravis :

1. Maintain sustained upward gaze of eyes—observe the appearance of ptosis.
2. Counting sing—ask the patient to count upto 20 in one breath. The patient starts counting normlly but the voice becomes slurred and unintelligible after counting few numbers due to development of muscle fatigue.
3. Ask the patient to close the eyes tightly and to do it repeatedly—eye closure becomes weaker after repetition.

* Myasthenia means fatiguable weakness which is worse on exercise, itself a neuromuscular junction disorder.

Dilatation (mydriasis) of pupil :

Constrictors of the pupil are supplied by parasympathetics (via oculomotor nerve), while the dilator fibres are controlled by sympathetic nervous system. Changes in the size of the pupil do not affect vision.

(A) Unilateral-

1. 3rd nerve palsy
2. Adie's pupil or myotonic pupil
3. Optic atrophy
4. Acute congestive glaucoma
5. Head injury

(B) Bilateral-

1. Childhood, anxiety, fear
2. Application of mydriatic (atropine)
3. Dhatura poisoning
4. Coma
5. Severe raised intracranial tension
6. Cerebral anoxia, death

Constriction (miosis) of pupil :

(A) Unilateral-
Horner's syndrome

(B) Bilateral-
1. Old age
2. Argyll Robertson pupil
3. Pontine haemorrhage
4. Organophosphorus or alcohol poisoning
5. Application of pilocarpine drops
6. Overdose of neostigmine
7. Iritis

Commonest cause of anisocoria (unequal pupils) is the application of mydriatic to one eye Other causes are idiopathic or physiological (12% population), unilateral Illrd nerve lesion, unilateral lesion in the sympathetic trunk, encephalitis, iritis, HolmesAdie pupil etc.

** Point 3, 4, 5, morphine or barbiturate poisoning, heat stroke may produce **pin-point pupil.**

*** Irregular pupils are due to coloboma, neurosyphilis, following eye operation. Sometimes, it is seen in normal healthy subjects.

How to differentiate between patients with pin-point pupil (point 3 and 4 above) :

(A) Pontine haemorrhage—There is coma, hyperpyrexia and long tract signs (i.e., signs of pyramidal tract lesion).

(B) Organophosphorus poisoning—It is diagnosed by history, absense of long tract signs and signs of respiratory depression. The patient may be unconscious but there is absense of pyrexia.

Causes of Horner's syndrome :

The site of lesion may be in,

1. Cerebral hemisphere—Massive infarction of one hemisphere.
2. Brain stem—Lateral medullary syndrome (vascular), multiple sclerosis (demyelinating), pontine glioma (SOL), syringobulbia, encephalitis.
3. Spinal cord (lower cervical)—Syringomyelia, glioma, ependymoma.
4. Spinal cord (T root lesions)—Cervical rib. trauma, Klumpke's paralysis, aortic aneurysm.
5. Cervical sympathetic chain—Pancoast's tumour, enlarged lymph nodes, mediastinal mass, thoracic surgery, trauma.
6. Carotid artery—Thrombosis, spasm in migraine (temporary Homer's syndrome).
7. Others—Congenital, idiopathic.

* Congenital Horner's syndrome have ipsilateral facial hemiatrophy and light colouration of iris.

What is the size of normal pupil ?

It varies in between 3-5 mm. If < 3mm, it is called miosis and if > 5 mm, it is known as mydriasis. Pupillary size 1 mm or less is known as pin-point pupil. Normally pupils are 'round and regular' in outline, centered in the iris, and equal in size.

Argyll Robertson pupil :

(A) Characteristics :

a) Small, irregular and unequal pupil; often depigmented.
b) Usually bilateral involvement but more marked on one side.
c) Accommodation reflex present but light reflex lost.
d) Dilates slowly to mydriatics.

(B) Site of lesion : Peri-aqueductal grey matter (pretectal region of mesencephalon). Probably there is damage of both colliculo-nuclear and sympathetic fibres.

(C) Clinical associations :

1. Neurosyphilis (classically seen).
2. Diabetes mellitus.
3. Wernicke's encephalopathy.
4. Multiple sclerosis.
5. Brainstem encephalitis.
6. Amyloidosis.
7. Pinealomas.

What is *reversed' Argyll Robertson pupil ?

The pupil reacts to light but not to accommodation reflex. This rare phenomenon may be seen in post-encephalitic parkinsonism and diphtheria.

Myotonic or A die's pupil :

It is characterised by delayed or absent pupillary reaction to light or to accommodation, but once constricted the pupil dilates very very slowly. The lesion is in ciliary ganglion.

* **'Hippus'** is rhythmic constriction and dilatation of pupil, either spontaneously or in response to light. It is not of much clinical importance.

Describe the pathway of light reflex : ■

Light falls on retina----------optic nerve--------optic chiasma-------- optic tract------- superior colliculi at mid-brain (pretectal area)---------- 2nd order of neurone starts from here and goes to the Edinger-Westphal (E.W) nucleus bilaterally---------- preganglionic fibres go to the ciliary ganglion through the oculomotor nerve and its branch to the inferior oblique muscle---------- postganglionic fibres from ciliary ganglion supply the sphincter pupillae and ciliaris muscle through short ciliary nerve.

Describe the pathway of accommodation reflex :

Light falls on retina---------optic nerve------- optic chiasma------- optic tract-------lateral geniculate body--------- optic radiation---------calcarine cortex of the occipital lobe (visual cortex)---------- frontal eyefield area or 'area 8' through superior longitudinal association tract---------- from here cortico-mesencephalie fibres descend to the oculomotor nuclei at midbrain as follows :

1. Nucleus for medial rectus—produces medial convergence of eyeball.
2. E.W nucleus—produces miosis.
3. Nucleus of Perlia—contraction of ciliaris muscle and thus, anterior convexity of lens increases.

* From oculomotor (E.W) nucleus, the pathway for accommodation reflex is the same as light reflex.

Bow to test for light reflex ?

When light falls on one eye, there is constriction of both the pupils. The pupillary reaction on the stimulated side is called 'direct' light reflex, and the pupillary constriction of the other eye is known as 'consensual' light reflex. The method of examination goes like below :

1. Pencil torch is used with good power of illumination.
2. The patient is asked to look straight forward at a distant object and the light is thrown suddenly in one eye ***from sides*** (to avoid the accommodation reflex). The pupil constricts briskly.
3. For direct light reflex, opposite eye should be closed by the hollow of the other palm. Direct light reflex should be tested preferably in a dark room.
4. For consensual light reflex, one hand of the patient is placed over the nose (like a curtain) to prevent the spillage of light to the oilier eye. Both the eyes are kept open. When light falls on one eye, observe the pupillary constriction of the other eye (i.e., consensual light reflex).
5. The afferent pathway—optic nerve, efferent pathway— oculomotor nerve, centre—ciliary ganglion, response—constriction of both the pupils.

* For both direct and consensual light reflexes, each eye is tested separately.

Mechanism of consensual light reflex :

As the fibres leaving one optic tract enter both the E.W nucleus, there is consensual light reflex.

How to test for accommodation reflex or convergence reflex ?

The patient is first allowed to look at a distant object and then to ask him to look at examiner's finger quickly which is placed near his nose (e.g., at 10 cm from the eyes). The responses are,

1. Miosis (bilateral).
2. Medial convergence of the eyeball (bilateral).
3. Increased anterior convexity of iens (not clinically evident).
4. Enophthalmos (not clinically evident).

Afferent pathway—optic nerve, efferent pathway—oculomotor nerve, centre—oculomotor nuclei at midbrain.

How will you test the integrity of intraocular muscles ?

By light (direct and consensual) and accommodation reflex.

Identification points :

In the presence of ptosis :

1. **Miosis indicates Horner's syndrome** and **mydriasis indicates oculomotor palsy.** Ptosis due to Horner's syndrome is partial.
2. Lateral squint with complete ptosis indicates oculomotor palsy.

3. Wrinkling of the forehead points towards long-standing ptosis.
4. Abnormal fatiguability of muscles after repeated use indicates myasthenia gravis.
5. Facies characterised by ptosis, hatchet face' with 'swan-neck', frontal baldness, cataract with atrophy of temporalis and sternomastoid muscles indicate myotonia dystrophica.

Case 90

SQUINT

What is squint ?

In squint, abnormality of ocular movement is such that the visual axes do not meet at the point of fixation or it is a failure of the normal coordination of the ocular axes. 'Manifest squint' is noticeable when both the eyes are kept open while 'latent squint' is detected only by covering one eye.

Types of squint :

Squint or strabismus is of two types :

1. Concomitant (non-paralytic)—There is no paralysis of extraocular muscles.
2. Paralytic—Due to weakness of one or more of the extraocular muscles.
   (i) Divergent squint—Due to paralysis of MR (medial rectus).
   (ii) Convergent squint—Due to paralysis of LR (lateral rectus).

* Upward or downward paralytic squint is rare.

Nerve supply of extraocular (extrinsic) muscles :

a) Lateral rectus (LR)—VIth cranial nerve (abducens).
b) Superior oblique (SO)—IVth cranial nerve (trochlear).
c) Other four muscles (MR, IO, SR, IR)—IIIrd cranial nerve (oculomotor).

* IO—inferior oblique, SR—superior rectus, and IR—inferior rectus.

** **Intraocular (intrinsic) muscles**—(i) Sphincter pupillae and ciliaris—Supplied by IIIrd cranial nerve, (ii) Dilator pupillae— Supplied by sympathetic trunk.

Testing of IIIrd, IVth and VIth cranial nerves :

It is customary to test these three nerves at a time under the following headings :

I. Upper eyelid :
   a) Ptosis, and
   b) Lid retraction (due to sympathetic overactivity).

II. Position of the eyeball at rest :
   a) Squint,
   b) Exophthalmos,
   c) Enophthalmos,
   d) Hypertelorism (may be associated with intracranial congenital abnormalities), and
   e) Conjugate deviation.

III. Movement of the eyeball :
   a) Voluntary, and
   b) Involuntary—Nystagmus.

IV. Pupil :
   a) Size b) Shape, and c) Reaction :
      (i) Light reflex,
      (ii) Consensual light reflex,
      (iii) Accommodation reflex.

N.B. : **To sumarize.** test for 1. LPS muscle and ptosis, 2. Movement of each extraocular muscle, 3. Pupil with reflexes, and 4. Nystagmus.

* Lid retraction, enophthalmos, hypertelorism have no relation with IIIrd, IVth or VIth nerve palsy.

** One should search for arcus senilis (may have atheromatous cerebral vessels) and K-F ring (neurologic form of Wilson's disease) while examining the cornea and iris.

*** Retraction of upper eyelid (thyrotoxicosis, Claude Bernard syndrome, big eye globe, scar of upper eyelid, short tendon of LPS) and retraction of lower eyelid (ectropion, proptosis, early stage of Bell's palsy, ocular myopathy) should be carefully looked for.

How to test for voluntary movements of the eyeball ?

It is important to remember that the recti are elevators and depressors alone when the eye is in abduction, and obliques act similarly (elevation and depression) when the eye is in adduction.

Stand in front of the patient and ask him, not to move his head. He is then instructed to follow your finger which is kept at a distance of 60 cm, and placed sequentially from position 1 to 7 described below. Ask the patient to report for double vision (diplopia).

	Position of examiner's finger		**Muscles working**
1.	Above his head in the midline	1.	SR and IO (both eyes)
2.	Below his head (finger kept at the level of his chest) in the midline	2.	IR and SO (both eyes)
3.	Laterally to the left	3.	LR (left eye) and MR (right eye)
4.	Laterally to the right	4.	MR (left eye) and LR (right eye)
5.	Above his head but placed laterally	5.	SR (same eye) and IO (opposite eye)
6.	Below his head but placed laterally	6.	IR (same eye) and SO (opposite eye)
7.	Straight ahead	7.	All extraocular muscles

No. 5 and 6 are done on both the sides.

According to few clinicians, it is better to test individual muscle of each eye by an H pattern ol movement.

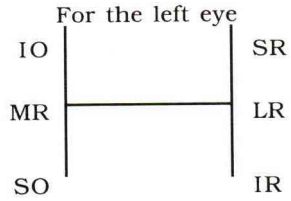

Fig. 3 : Testing for voluntary movements of eye

Function of each muscle :

- LR — abduction
- SR — elevator in abduction
- SO — depressor in adduction
- jy[R — adduction
- IR — depressor in abduction
- IO — elevator in adduction

Different voluntary movements of the eyeball :

The three components of voluntary movements are :

1. PURSUIT (following movements)—The movements of the eyeball described above i.e., slow and smooth eye movements following a target.
2. SACCADIC (searching movements)—These are rapid, programmed, conjugate fixation movements. Ask the patient to focus his eyes rapidly to the ceiling fan, then to the window and next to the switch-board and so on.
3. REFLEX OCULAR MOVEMENTS—To see whether both the eyes are moving simultaneously or not, on examiner's command i.e., the conjugate deviation.

* LMN lesion of Illrd, IVth or Vlth cranial nerve (i.e., nucleus or nerve lesion) produces paralysis of individual or group of eye muscles. UMN lesion leads to paralysis of conjugate gaze rather than individual muscle paralysis.

Table 35 : Clinical differentiation between two types of squint

	Features	**Paralytic**	**Non-paralytic**
1.	Onset	Acquired later in life	Present since childhood
2.	Movements	Restricted	Good in all directions
3.	Diplopia	Present	Absent
4.	Vision	Normal in both eyes	Deviating eye has defective vision

Diplopia results from loss of parallel visual axes, and is commonly due to Illrd, IVth, Vlth nerve palsy, myasthenia gravis and myopathies (e.g., thyrotoxicosis).

Why there is no diplopia in non-paralytic squint ?

In case of paralytic squint, the image on the paralysed side does not fall on the macula and thus diplopia or double vision occurs; whereas in non-paralytic squint, the image formed by the defective eye is either rejected or suppressed by the occipital cortex and thus, there is no diplopia. Diplopia is maximum il the eye is moved in the direction of weak muscle.

Remember, uniocular diplopia' is a rare phenomenon and mostly occurs due to eye disorders like incipient stage of cataract, subluxation of lens, peripheral iridectomy, astigmatism and keratoconus.

Causes of Illrd, IVth and Vlth cranial nerve palsy :

(A) Isolated oculomotor (Illrd cranial nerve) palsy :

1. Intracranial aneurysm arising near circle of Willis.
2. Tuberculous meningitis.
3. Diabetes mellitus.
4. Traumatic.
5. Ophthalmoplegic migraine.
6. Neoplastic diseases (e.g., pituitary SOL).
7. Multiple sclerosis.
8. Vascular disease (e.g., vasculitis).
9. Congenital.

(B) Isolated trochlear (IVth cranial nerve) palsy ;

Isolated lesion is rare e.g., in trauma (head injury), diabetes mellitus etc. It is almost always involved with Illrd or Vlth nerve paralysis in multiple sclerosis, Wernicke's encephalopathy.

(C) Isolated abducens (Vlth cranial nerve) palsy :

1. Increased intracranial tension (it is a 'false localising sign'; Vlth nerve is commonly affected due to its long intracranial course).
2. Diabetes mellitus.
3. Traumatic.
4. Brain tumour (SOL).
5. Basal meningitis or encephalitis.
6. Gradenigo's syndrome (unilateral headache, Vlth nerve palsy with mastoid infection).
7. Lesion in cavernous sinus (aneuryms, meningioma).

* Combined Illrd, IVth and Vlth nerve palsies are common in upper brainstem stroke, cavernous sinus thrombosis, superior orbital lissure syndrome (i.e., Tolosa-Hunt syndrome) and diabetes mellitus.

Symptoms due to isolated IVth nerve palsy :

in superior oblique palsy, the patient feels difficulty in going downstrairs or reading newspapers. The patient overcomes this difficulty by tilting his head (head tilt) slightly to opposite direction.

What is ophthalmoplegia ?

1. Internal ophthalmoplegia Occurs as a result of paralysis of sphincter pupillae and ciliaris muscles due to Illrd nerve palsy. The pupil will be dilated and fixed, i.e., there will be absence o! direct and consensual light reflex as well as accommodation reflex.
2. External ophthalmoplegia — Occurs due to Illrd, IVth or Vlth nerve palsy (e.g., cavernous sinus thrombosis or metastasis at orbital apex); and extraocular muscle paralysis due to myasthenia gravis, ocular myopathy and exophthalmos.
3. Internuclear ophthalmoplegia (INO) — Lesion in the medial longitudinal fasciculus (MLF) anywhere in between the midbrain and the pons will produce difficulty in adduction in one eye and nystagmus in the abducting eye, and the side of lesion is on the side of impaired adduction. It is commonly due to multiple sclerosis.

Points to note during optic nerve examination :

1. Acuity of vision (measures efficacy of the central or macular vision),
2. Held of vision (assess the function of central and peripheral retina),
3. Colour vision (assess the function of retinal cones and optic nerve), and
4. Fundoscopy (to examine optic nerve head and fundus).

According to sorne clinicians, pupillary reflexes' are within optic nerve examination.

Neuroanatomy of optic nerve :

Retina -> optic nerve optic chiasma (here, nasal fibres from each retina, representing the temporal

field, decussate. Temporal fibres from each retina remain 011 the same side) -> optic tract -> lateral geniculate body (some preganglionic fibres project to superior colliculi at midbrain) -> optic radiation projects through posterior limb of the internal capsule —> to calcarine cortex of the occipital lobe. Fibres carrying the upper and lower visual fields pass respectively through the white matter of temporal and parietal lobe; the right half of the visual field is represented in the left calcarine cortex and vice versa.

How to test for visual acuity or acuity of vision ?

It is a test of llnd cranial nerve and it denotes the macular function. The clinical method is .

1. First examine the eye for any local pathology i.e., corneal opacity etc.
2. One eye is tested at a time (other eye is closed by the hollow of (lie palm).
3. Ask the patient to count the beams in the ceiling or blades in the fan (distant object testing).
4. Now ask for finger counting (near object testing).
5. If finger counting is not possible, put a lighted torch in the eye and examine for PL/PR (perception of light / projection of rays). Perception oi light is absent in total blindness.

* Ideally, distant vision is tested by SNELLEN'S TEST TYPE CHART and near vision by JAEGER'S CHART. The patient should wear the spectacles (if any) during the bedside test.

Normal visual acuity by Snellen's chart is $^6/_6$: in clinical practice, loss of visual acuity is commonly due to cataract, refractive error, corneal and vitreous opacities.

How to test for colour vision ?

The primary' colours arc red, green and blue. Roughly, ii can be assessed by asking the patient the colour of his shirt or pant, room-wall. ceiling fan, bed-cover etc. The patient with defective colour vision can not identify the colours correctly.

Ideally it should be assessed by ISHIHARA'S CHART (pseudo-isochromatic plates). The commonest defect in colour vision is red-green anomaly (X-linked recessive), acquired delect may be seen after use of ethambutol or chloroquine. Total colour blindness is rare.

How to test for field of vision ?

'Field of vision' is the field within which all objects are visible when the vision is fixed to a particular object present in that field. This is tested by **'confrontation perimetry'.**

1. First test the acuity of vision.
2. Seat opposite the patient (face to face) at the same level; distance between the patient and the examiner will be one meter. The examiner should have a normal visual fielu.
3. If the left eye is to be tested, ask the patient to cover his right eye with the hollow ot his right palm; ask him to look straight at your right eye and not to take his own eye off yours (the patient should not move his head). Cover your lelt eye with your left palm and look steadily at the patient's left eye (in this way of testing, slight movement of patient's eye can be easily detected).
4. Now place your right hand (the test object is physician's finger or ideally a large red hat-pin) midway between patient's face and your own. It is better to *move the finger during tesiing* und *the finger* is *brought from the periphery to the centre.* Ask the patient whether he can see the movement of the finger,
5. In this way, the hand (finger) is moved in various directions—i.e., upper and lower, nasal and temporal quadrants of the visual field. Bring the test object from the periphery into the fieid of vision in a curved fashion. Use your own field of vision for the purpose of comparison. Lastly, test the field of the right eye of the patient.

* ln a non-cooperative patient, a shiny object is moved from the periphery to the centre and ascertain whether the patient is able to see it, or move your hand quickly towards patient's face and observe the reflex blinking of both eyes (menace reflex), as confrontation method is not possible here (this method can also be applied in a patient who is unable to sit in the bed). Ideally, the held of vision is mapped by using a BJERRUM'S SCREEN PERIMETER (perimetry). One may detect the physiological blind spot by confrontation method. Preferably remove both the examiner's and patient's spectacles (if any) while testing the field by confrontation method.

** Tubular or tunnel vision' (concentric narrowing of the field of vision) is characteristic of terminal glaucoma, advanced retinitis pigmentosa, quinine amblyopia and hysteria,

*** 'Cortical blindness' is a feature of vasospasm of posterior cerebral artery, anoxic encephalopathy, hypertensive encephalopathy, subarachnoid haemorrhage and migraine.

Causes of papilloedema, optic atrophy and optic neuritis :

- ***Papilloedema (oedema or swelling of the papilla, i.e., the optic disc) :***

1. Increased intracranial tension (CVA, SOL, cerebral oedema, meningitis, hydrocephalus).
2. Malignant hypertension.
3. Circulatory block (in CSF).
4. Benign intracranial hypertension (steroid withdrawal, hypervitaminosis A).
5. Cavernous sinus thrombosis.
6. SVC syndrome.
7. Systemic disorders (vasculitis, chronic hypercapnia, COPD, hyperviscosity syndrome).
8. Miscellaneous Guillain Barre syndrome, pseudotumour cerebri, severe anaemia, central retinal vein occlusion, disc infiltration (leukaemia, sarcoidosis).

* Papilloedema is usually bilateral. Unilateral papilloedema is seen in central retinal vein occlusion, Foster-Kennedy syndrome, lymphomatous/leukaemic deposits in one eye, and early stage of bilateral papilloedema.

- ***Optic atrophy :***

1. Multiple sclerosis (Devic's disease).
2. Toxins—Tobacco, methyl alcohol, ethambutol, chloroquine etc.
3. Syphilitic optic neuritis.
4. Glaucoma.
5. Ischaemic optic atrophy.
6. Head injury.
7. Retinitis pigmentosa, chorioretinitis.
8. Leber's optic atrophy (familial).
9. Friedreich's ataxia.

Optic atrophy is of two types. **Primary optic atrophy** is secondary to optic neuritis, and **secondary optic atrophy** develops from papilloedema/papillitis. A third variety of optic atrophy is 'consecutive' optic atrophy resulting from primary retinal diseases (e.g., retinitis pigmentosa, chorioretinitis and central retinal artery occlusion).

- ***Optic neuritis :***

1. Multiple sclerosis, Devic's disease.
2. Vitamin B! or B_{12} deficiency.
3. Meningitis, encephalitis, tuberculosis, syphilis.
4. Toxins : tobacco, alcohol (ethyl or methyl); drugs : INH, ethambutol, quinine.
5. Diabetes mellitus, vasculitis.

* On **fundoscopy** Optic disc (colour, shape, blood vessels, physiological cup, margin), retinal blood vessels, macula and periphery of retina are seen.

The visible part of retina is know as fundus'. Fundoscopy should be routinely done irrespective of patient's complaints.

Fundoscopy in different conditions :

(I) Papilloedema—the disc is pink (hyperaemic), blurring of disc margin (nasal margin first), cessation of normal venous pulsation, obliteration of physiological cup, disc engorgement with dilated vessels, and small haemorrhages surround the disc.

(II) Optic atrophy the disc looks pale (due to loss of nerve fibres); the margin is sharp in primary atrophy while it is blurred in secondary atrophy. The arteries are attenuated in primary variety. No change in retina in primary variety but few exudates and haemorrhages may be seen in retina in secondary variety.

(III) Retrobulbar neuritis—though the patient is blind, the disc is absolutely normal.

Precautions adopted in testing olfactory nerve :

Ideal test objects (non-irritating substances) are—Oil of peppermint, oil of cloves, tincture of asafoetida or oil of lemon. But in the examination, the students should test it by common bedside familiar substances like soap, tooth paste, fruit, scent etc. Irritating substances like ammonia stimulates trigeminal nerve too, and are better to be avoided.

Precautions :

1. Exclude local changes first (i.e., nasal catarrh, patency of the nostrils).
2. Examine each nostril separately after occluding other nostril by digital pressure.
3. Avoid irritating substances like ammonia (they stimulate the trigeminal nerve and may interfere with interpretation of smell).
4. Eyes remain closed during testing. Ask the patient to identify the substance with two sniffs.

5. **The test to usually carried out with two or more substances.**

* *Anosmia* **is usually due to lesion in the olfactory bulb;** *parosmia* **or perverted smell (pleasant odours seem offensive) results from hysteria;** *olfactory hallucination* **(usually of unpleasant nature) is found in temporal lobe epilepsy.** *Cacosmia* **(foul smell) is found in atrophic rhinitis. Commonest cause of bilateral anosmia is coryza. Other causes of anosmia are local disease of cribriform plate, basal meningitis, subarachnoid haemorrhage, zinc deficiency and ageing.**

** **Neuroanatomy : The olfactory and optic nerves actually made up of central nervous tissue rather than peripheral nerves. The olfactory nerve carries the sense of smell. The axons of the bipolar sensory cells in the olfactory epithelium passes through cribriform plate -> to reach the second order of neurones in olfactory bulb -> the olfactory bulb neurones project to the olfactory centres (uncus and parahippocampal gyrus).**

Identification points (squint) :

1. **First determine the type i.e., paralytic or non-paralytic squint by testing the voluntary movement of the eyeball (test all extraocular muscles).**
2. **Ask for diplopia and the duration of squint.**
3. **See the pupil. If there is dilatation of pupil (and ptosis) in the paralysed eye, the squint is due to oculomotor palsy (divergent squint due to unopposed action of lateral rectus).**
4. **If the patient complains of diplopia (obviously paralytic squint), usually the outer image is a false one and it disappears on covering the affected eye.**

Case 91

NYSTAGMUS

What is nystagmus ?

These are rhythmic, involuntary and jerky movements (oscillations) of the eyeball when they are fixed on an object. Nystagmus signifies the disturbance in ocular posture.

How to test for nystagmus ?

1. Examine the patient under good illumination. At first, test the power of extraocular muscles to eliminate their weakness or paralysis (in that situation, nystagmoid movements will appear).
2. Now ask the patient to look forward. Observe for pendular nystagmus.
3. Ask the patient to fix his head or fix the patient's head by one of your hand.
4. Now the patient is asked to fix his vision towards your index finger (held at about 60 cm distance) which is kept at least for 5 seconds laterally to the right side and then to the left side in turn (your finger must be placed within the binocular vision of the patient; do not go for extreme abduction to avoid nystagmoid movement.). It is the examination of nystagmus in the horizontal plane.
5. Next place your finger above and below his head to examine nystagmus in the vertical plane.
6. Observe nystagmus in both eyes.

How will you describe the nystagmus (if present) ?

Nystagmus is usually described under these 6 points.

1. **Pendular** (equal horizontal movement on each side like the swing of a pendulum of wall-clock) or **jerky** (amplitude is more in any one side. i.e.. it has a fast and a slow component).
2. **Direction** of the nystagmus—The direction of the faster component of the oscillations is the 'direction' of the nystagmus.
3. **Plane in which nystagmus is being tested** (i.e., direction of gaze which evoke nystagmus)
   (i) Horizontal, and
   (ii) Vertical.
4. **Plane in which oscillatory movements of nystagmus is occuring**
   (i) Horizontal (to and fro movement of the eyeball in the horizontal plane),
   (ii) Vertical (up and down movement of the eyeball in the vertical plane), and
   (iii) Rotatory (oscillatory movement of the eyeball is rotatory in character).
5. **Amplitude—**
   (i) Fine (< 1mm),

(11) Medium (1-3 mm), and
(iii) Coarse (> 3 mm).

6. **Grading** (discussed below).

Causes of pendular nystagmus :

Pendular nystagmus is almost always binocular and horizontal, any sometimes associated with head-nodding. **Pendular nystagmus appears when the patient looks forward.** The common causes are,

(i) Miners nystagmus (who works in dim light of coal-mines for long duration).
(ii) Errors of refraction—the ocular fixation is defective.
(iii) Amblyopia (if present in early life, impairs fixation of vision) e.g., high infantile myopia.
(iv) Familial nystagmus, albinism, retinitis pigmentosa.

Causes of jerky nystagmus :

Jerky nystagmus is always found on fixation of the gaze laterally.

(i) Cerebellar nystagmus Direction (fast phase) of the nystagmus is towards the side of lesion.
(ii) Labyrinthine nystagmus—Direction (fast phase) of the nystagmus is towards the opposite side of lesion.
(iii) Brainstem lesion—Very often -rotatory' e.g., in brainstem glioma, multiple sclerosis etc.
(iv) Upper spinal cord lesion—Vertical nystagmus e.g.. Arnold-Chiari malformation.
(v) Toxic nystagmus—Induced by drugs like benzodiazepines, phenytoin, phenothiazines, barbiturates and sometimes in alcoholics.

* vertical nystagmus : Downbeat (i.e., fast phase downwards and slow phase upwards) in cranio-vertebral junction abnormality e.g., Arnold-Chiari malformation, and upbeat nystagmus (i.e.. fast phase upwards and slow phase downwards) in lesion of cerebellar vermis.

What is positional nystagmus (Dix-Hallpike's test) ?

Method—The patient is asked to lie in supine position with his shoulders at the end of the coach (with eyes open). The projecting head of the patient is supported by the examiner's hand. The head is now fully extended (30° from horizontal plane) and rotated (30°) to one side. Intense vertigo with nystagmus appears (affected side down) in vestibular dysfunction. It is the rough assessment of the vestibular function of Vlllth cranial nerve. After a short interval, the test is repeated with the head extended and rotted to the other side. Positional nystagmus is also seen in posterior fossa tumour.

What is optokinetic nystagmus ?

i iiis is commonly seen when an individual looks out of the window of a moving train. There is a slow and a fast phase in it. It is a physiological nystagmus and its absence indicates parietal lobe lesion.

What is see-saw nystagmus ?

In this condition, one eye raises up and turns in, while the other eye falls and turns out. It is common in paraseliar tumour.

What are nystagmoid movements ?

These are rhythmic movements of the eyeball when the eyeball is extended laterally beyond the limit of binocular vision. **Brief duration and irregularity** of these movements distinguish them from the true nystagmus. There are usually 4 or less oscillations in the nystagmoid movement. Often this movement is monocular.

What is the grading of nystagmus ?

For example :

Grade 1— Nystagmus with fast component to left, when the patient looks towards the left.

Grade 2— Nystagmus with fast component to left, when the patient looks straight ahead.

Grade 3— Nystagmus with fast component to left, when the patient looks towards the right.

fhis example stands for a ieit-sided cerebellar hemispheric lesion or a right-sided labyrinthine lesion.

What do ***you mean by nystagmus to the left' ?*** -

It does not refer to the direction of gaze in which nystagmus occurs but it indicates the direction oi last component to the left (i.e., 'direction' of the nystagmus).

* Nystagmus is routinely tested during examination of the Illrd, IVth and Vlth cranial nerves. Always fix the head of the patient. Test for nystagmus in different planes.

Few other abnormal involuntary movements of eyes :

1. Oculogyric crisis—involuntary upward conjugate deviation of eyeballs.
2. Skew deviation of eye—one eye is down and medial while the other eye goes up and lateral; seen in acute curebellar lesion.
3. Ocular bobbing—periodic brisk downward movement of both eyes, and is a feature of pontine lesion. Ocular dipping is brisk upward and slow downward movement of both eyes.
4. Opsoclonus—coarse, irregular, disorganised, chaotic, dancing and non-rhythmic oscillations of eyeball occuring in both vertical and horizontal plane, and persisting for a long period. It is often found in cerebellar lesion, encephalitis or brainstem damage.
5. Ocular flutter—pendular horizontal oscillations on fixing gaze on an object; a feature of cerebellar lesion.

Tests of VUlth cranial nerve :

In VUlth nerve lesion, the patient usually complains of dizziness or vertigo, tinnitus (ringing in the ears) or deafness.

(A) Cochlear functions (function of hearing)—first examine the external acoustic canal using a torch and auroscope (wax, tympanic membrane). Hearing should be tested in each ear in turn.

a) Speak loudly from a distance of 20 feet, and gradually come closer to the patient. Normal conversational voice should be heard from 20 feet.

b) Whisper test—In health, a person is able to hear the whisper from a distance of approximately 10 feet. First whisper from a distance and then gradually move closer to the patient, or test either by the ticking sound of a wrist-watch (watch test) or by rubbing fingers; the other ear should be occluded by finger pressure on the tragus.

c) Rinne's test and Weber's test—Read from 'Bedside clinics in Medicine, Part II'.

(B) Vestibular functions—

a) Observe for spontaneous nystagmus—fast phase is away from the side of lesion.

b) Positional nystagmus (see above).

c) Caloric test—Read from any standard ENT text book.

* **Deafness** is of two types ;

I. Conductive deafness—As a result of impacted wax, damage to tympanic membrane, otosclerosis, CSOM etc (i.e., diseases of the external auditory meatus, middle ear and eustachian tube).

II. Sensorineural deafness—Due to damage of cochlear nerve and organ of Corti. Meniere's disease, acoustic neuroma, drugs like aminoglycosides, fracture of petrous part of temporal bone, pontine lesion etc.

** In health and sensorineural deafness, air conduction is greater than bone conduction.

Case 92

BELL'S PALSY

What is your diagnosis ?

This is a case of right-sided LMN type of facial palsy, probably Bell's palsy.

* **Sir Charles Bell** (1774-1842) **was a Scottish surgeon at Middlesex Hospital, London, UK; Professor of Surgery, Edinburgh afterwards.**

Why do you say 'probably' ?

I say 'probably' because I am not allowed to know the history (exposure to cold etc.) and the initial symptoms (pain behind the right ear).

* **Facial paralysis may be supranuclear (UMN type), and nuclear/infranuclear (LMN type).**

Why do you say so ?

Because the right side of face on inspection shows :

1. **Smoothening of furrows in the forehead.**
2. **Wide palpebral fissure [due to loss of tone of the lower eyelid and unopposed action of the levator palpebrae superioris (LPS)]—lagophthalmos or unequal palpebral fissure in comparison to other side.**

3. Asymmetry of blinking.
4. Abnormality in volitional or reflex movement like smiling or crying.
5. Watering from the eye or epiphora (due to loss of capillary action as the punctum is no more in contact with conjunctiva).
6. **Bell's phenomenon** (the eyeball rolls upwards and inwards during attempted forced eye closure. It is a normal as well as protective phenomenon and is preserved in LMN type palsy only).
7. Loss of nasolabial fold or flattening of the fold.
8. Angle of the mouth is drawn to left side when the patient is asked to show his upper teeth.
9. Drooping of the angle of the mouth (right side).
10. Flapping in and out of the cheek on right side during respiration due to the paralysis of buccinator muscle.
11. Saliva dribbles from the right angle of the mouth; difficulty in spitting.
12. Inability to blow or whistle properly (air escapes from the right side of the mouth).

* An important complaint by the patient is collection of food materials in the affected vestibule during eating. Patient may also complain of numbness and stiffness of the cheek on the affected side though the sensory functions of face remain absolutely intact.

** Bell's palsy does not lead to ptosis.

*** The patient may complain of slurred speech for obvious reasons (i.e., weakness of facial muscles).

Test the individual muscle of face :

Test the muscles on both sides of face and observe the weakness on right side (in this patient).

1. Ask the patient to wrinkle his forehead (either the patient will do it on your command or keeping the head fixed, ask him to look at your index finger which is placed above his head)—Frontal belly of occipitofrontalis (muscle for surprize).
2. Ask the patient to frown — Corrugator superciliaris.
3. Ask him to close both eyes forcibly and you try to open the eyelids by your fingers (both eyes must be examined for comparison)—Orbicularis oculi.
4. Ask him to show his upper teeth, or smile—Levator anguli oris, zygomatic major and minor, depressor anguli oris, buccinator and risorius.
5. Ask him to blow or whistle, or inflate the mouth with air—Orbicularis oris and buccinator.
6. Ask the patient to purse his lips shut—Only orbicularis oris.
7. Ask the patient to retract and depress the angle of the mouth with clenching of teeth (or ask the patient to try to touch the chin to the sternum though he will not move the chin at all from its original position)—Folds of platysma (muscle for grinning) may be seen in the neck.

* There may be apparent deviation of the tongue to the healthy side on protrusion.

** No. 1, 2 and 3 are ideal tests for 'upper face' and No. 4 for 'lower face'.

Table 36 : Differentiation between UMN and LMN type of VIIth nerve palsy :

UMN type	LMN type
1. *** 'Upper face' escapes** (forntal belly of occipitofrontalis, corrugator superciliaris and upper part of orbicularis oculi escape paralysis)	1. **Total face is involved** on one side
2. **Bell's phenomenon—Never occurs.**	2. **Bell's phenomenon—Present**
3. Facial muscles are not atrophied	3. There may be fasciculation or muscle atrophy on affected side
4. Taste sensation is preserved	4. Taste sensation may be lost
5. Corneal reflex—Preserved	5. Corneal reflex—Lost
6. Usually associated with same-sided hemiplegia	6. May be an isolated phenomenon (Bell's palsy) and if associated with hemiplegia, it is always crossed
7. Plantar response on the paralysed side of face—Extensor	7. Plantar response on the paralysed side of face—Flexor (may be extensor on the opposite side)

* i.e., forehead wrinkling, frowning, and eye closure and blinking are unaffected.

** In UMN facial palsy—causes weakness of the lower part of face on the opposite side. In LMN facial palsy—casuses unilateral complete weakness which is same-sided.

*** 'Upper face' and 'lower face' are divided by an arbitrary horizontal line passing through outer and inner angles of both the eyes.

What else do you want to examine in your patient of Bell's palsy ?

1. Taste sensation of anterior 2/3rd of the tongue (lost in LMN type).
2. Plantar response (mentioned above).
3. Corneal reflex—Lost in LMN type.
4. Evidence of cerebellar signs—if present on the side of facial palsy, the lesion is probably present at the cerebello-pontine angle (e.g., acoustic neuroma). In cerebello-pontine angle tumour, features of Vth (loss of corneal reflex), Vllth and VUlth cranial nerves lesion as well as cerebellar signs along with pyramidal signs are elicited.
5. Hyperacusis.
6. Examination of VUlth cranial nerve (affected in acoustic neuroma).

Examination within the oral cavity in Bell's palsy :

1. Food materials present within the vestibule of mouth on the affected side, and
2. Loss of taste sensation (if nerve to chorda tympani is affected).

What is mimic facial palsy ?

There are three types of facial palsy :

1. UMN palsy,
2. LMN palsy, and
3. Mimic palsy.

Mimic palsy is a rare phenomenon where the emotional movement of the facial muscles is lost but the voluntary movement is preserved i.e., *in other words, facial palsy or asymmetry is visible only on emotional movements e.g., in laughing or weeping.* This condition is seen in frontal lobe lesion because the UMN fibres concerned with emotion have a different course and is separate from the pyramidal tract.

As LMN is the final common pathway, LMN facial palsy affects the voluntary, emotional as well as associated movements.

In UMN facial palsy (obviously with hemiplegia), the paralysed angle of the mouth will be retracted during laughing (emotional movement) and during forcible closure of the eyes (associated movement).

Summary :

a) UMN facial palsy—No mimic palsy (i.e., emotional movements are preserved).
b) Frontal lobe lesion—Contralateral mimic palsy (commonly seen in multiple sclerosis).
c) LMN facial palsy (e.g., Bell's palsy)—All movements lost.

* So, **UMN palsy** includes the classic UMN type paralysis and rare mimic palsy; **LMN palsy** includes both nuclear and infranuclear lesion.

Why the upper face escapes in UMN palsy ?

The upper part of Vllth nerve nucleus (so the upper facial muscles or upper face) is innervated by corticobulbar fibres from both cerebral hemispheres whereas the lower part of Vllth nerve nucleus (so the lower face) receives fibres from opposite hemisphere only. As the upper facial muscles have dual supply, they escape in UMN palsy but LMN is the final common pathway and thus, total face is affected in LMN palsy.

Causes of unilateral LMN type Vllth cranial nerve palsy :

1. Bell's palsy (commonest and benign).
2. Leprosy.
3. Trauma to parotid gland.
4. Parotid tumour.
5. Herpes zoster infection.
6. Sarcoidosis.
7. Acoustic neuroma.
8. Middle ear disease (e.g.. CSOM).
9. Fracture of base of the skull.
10. Pontine neoplasm.

Causes of bilateral facial palsy of LMN type (facial diplegia) :

1. Acute infective polyneuritis (G.B. syndrome).
2. Leprosy.
3. Sarcoidosis (Heerfordt syndrome).
4. Forceps delivery (trauma).
5. Leukaemia (ALL) or lymphoma.
6. Bilateral Bell's palsy (rare).
7. Bilateral otitis media.
8. Diphtheria.
9. Lyme disease.
10. Seroconversion phase of HIV infection.

* Myasthenia and myopathy produce facial weakness; there is no involvement of facial nerve.

D/D of alteration of facial contour :

1. Hemiatrophy (e.g., localised scleroderma).
2. Hemihypertrophy.
3. Residual Bell's palsy.
4. Lipodystrophy.
5. Unilateral facial oedema (postural).
6. Paget's disease, fibrous dysplasia.
7. Absence of condyle of mandible (congenital)
8. Massive swelling of parotid glands.
9. Acromegaly.
10. Micrognathia.

How do you diagnose bilateral UMN type facial palsy ?

Remember, in bilateral UMN type of lesion, the total face is paralysed (upper 1/2 of face does not escape).

Bilateral UMN type of lesion is diagnosed by (differentiate from bilateral LMN type facial palsy) :

1. Mask like facies.
2. Absence of Bell's phenomenon.
3. Brisk jaw jerk.
4. Presence of glabellar reflex.
5. Spared emotional fibres, and
6. Associated bilateral long tract signs.

* Bilateral UMN type facial palsy is seen in diffuse cerebral atherosclerosis, pseudobulbar palsy and double hemiplegia.

** Isolated unilateral UMN facial palsy is rare but may be seen in CVA and multiple sclerosis.

Definition of Bell's palsy :

It is an acute, idiopathic, unilateral (commonly) LMN type of facial nerve involvement due to non-suppurative inflammation (viral, e.g.. often herpes simplex) of the nerve within the facial canal above the stylomastoid foramen.

Inflammation or oedema strangulates the nerve at the stylomastoid foramen and precipitates the paralysis. Exposure to cold or chill predisposes to Bell's palsy (there may be positive H/O travelling by bus or train, sitting by the side of an open window).

Bell's palsy affects all ages and both sexes. There is sudden unilateral facial weakness, which may be associated with loss of taste sensation and hyperacusis. There is no objective sensory loss in face. It is primarily diagnosed on clinical grounds.

How do you assess the progressing lesion in Bell's palsy ?

1. The inflammation may involve the nerve to chorda tympani — There is loss of taste sensation (hypogeusia) in the anterior 2/3rd of the tongue (chorda tympani arises from the facial nerve about 6 mm above the stylomastoid foramen).
2. Nerve to stapedius may be involved — The patient will complain of hyperacusis due to paralysis of stapedius muscle (sound on the paralysed side seems unusually loud).

* These two features indicate a bad prognosis in Bell's palsy.

Syndromes in nuclear type of facial palsy :

Millard-Gubler syndrome—Paralysis of VIth cranial nerve ± VIIth cranial nerve with contralateral hemiplegia.

Foville's syndrome—Ipsilateral paralysis of conjugate gaze ± VIIth cranial nerve palsy with contralateral hemiplegia.

Clinical features in lesion at the geniculate ganglion :

It is known as **Ramsay Hunt syndrome** which is the affection of geniculate ganglion by herpes zoster (shingles) infection. The clinical features are,

1. Fever with chill and bodyache.
2. LMN type of ipsilateral facial palsy (identical to Bell's palsy).
3. Loss of taste sensation in the anterior 2/3rd of the tongue (on affected side).
4. Hyperacusis (on affected side).

Haemorrhagic bullous lesion in pemphigoid

Vasculitis (Wegener's granulomatosis). Raynaud's phenomenon (colour changes in the tip of the fingers) with destruction of nose and nasal septum is seen. Hands are very cold on palpation

Multiple discharging fistula in lower abdomen in Crohn's disease

Facial haematoma, mild periorbital haematoma (raccoon eyes) and blood collection in forehead in a case of head injury

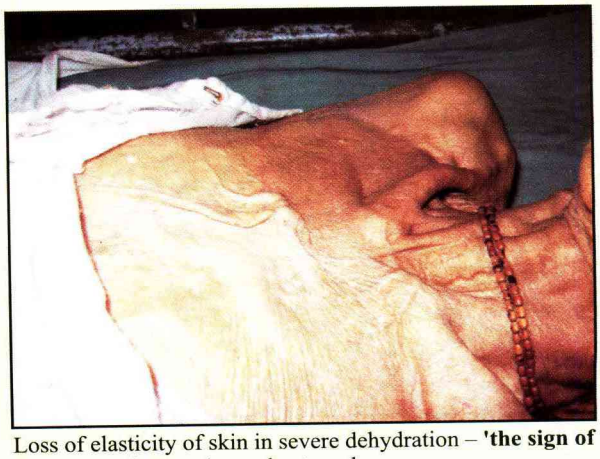

Loss of elasticity of skin in severe dehydration – **'the sign of ridge',** usually tested over the sternal area

Amyloidosis – Clustured waxy papules in the right side of the neck and periorbital ecchymoses ('raccoon eyes'). She also had macroglossia

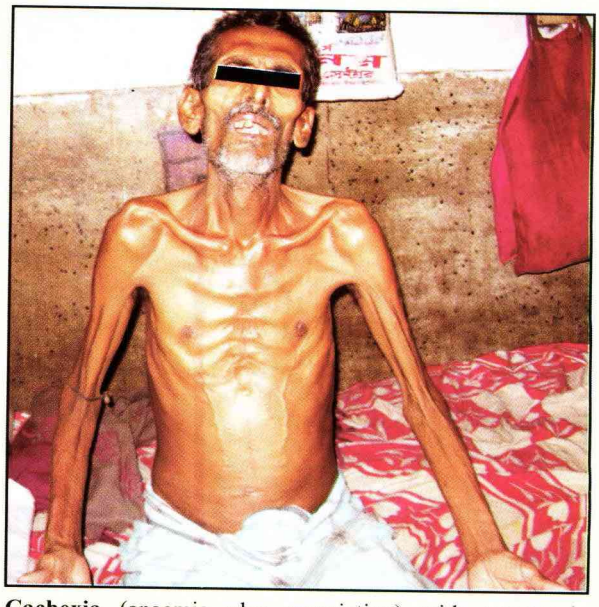

Cachexia (anaemia plus emaciation) with sarcopenia (decrease in muscle mass) – all skin and bone condition

Herpes zoster ophthalmicus of right side. There is risk of corneal scarring and secondary panophthalmitis

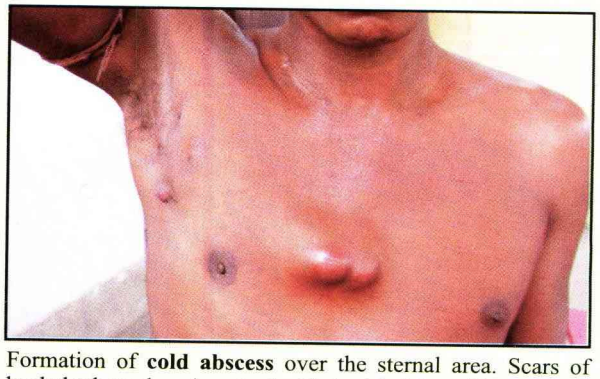

Formation of **cold abscess** over the sternal area. Scars of healed tuberculous lymphadenitis in the right axilla and neck are also noted

Molluscum contagiosum – multiple, glistening pale, poxvirus-induced, umbilicated, dome-shaped, pinhead to 1 cm papules. The child is HIV positive

5. Herpetic rashes on tympanic membrane, external auditory canal, pinna, and occasionally over pharynx, soft palate and tongue.

How do you elicit corneal reflex ?

Method — the patient is asked to see into the distance or at the ceiling. The cornea at its conjunctival margin is touched lightly with a damp cotton wool which is twisted into a fine hair. It the reflex is present, there is simultaneous prompt closure of both the eyes. Both the eyes should be tested one by one. The cornea is stimulated from the side to avoid 'menace reflex' (reflex closure of the eyes, if an object is brought to the patient directly from the front).

Afferent path — Vth cranial nerve (ophthalmic division).

Efferent path — Vllth camial nerve.

Centre — Pons.

Response — Closure of both the eyes.

* Never touch the central part of cornea because corneal ulceration may develop in the presence of corneal anaesthesia. In the absence of cotton, blowing a puff of air into each cornea will serve the purpose. This reflex is also known as *conjunctival reflex.* Loss of corneal reflex is an early sign of sensory involvement of trigeminal nerve in cerebello-pontine angle tumour.

** While eliciting the corneal reflex, prompt closure of ipsilateral eye (eye being examined) is known as direct corneal reflex while closure of contralateral eye Is known as consensual corneal reflex.

Management of Bell's palsy :

1. ***Prednisolone***—A course beginning with 60-80 mg daily, orally during the first 5 days and then tapered over the next 5 days may be of some help; ideally started within 72 hours.
2. Aspirin or other ***NSAID*** (non-steroidal anti-inflammatory drugs) may be given for relief of pain and inflammation.
3. Eye padding is done during sleep and local antibiotic drop is instilled in the eye, if signs of congestion is seen.
4. Proper mouth wash is advised after each meal.
5. Gentle massage over the paralysed muscles is advised.
6. Splint is used to prevent drooping of the lower part of face (by leukoplast).
7. Facial exercise is advised (standing in front of a mirror) or ***consult physiotherapist.***
8. Galvanic current stimulation of the paralysed muscles may be of some help.
9. If not improved at all within 6 weeks — Surgical decompression may be done at the stylomastoid foramen (majority of clinicians say that the indications for operation are still not clear). Suturing upper and lower eyelid (tarsorrhaphy) may be done if eye closure is not at all possible.
10. Parenteral vitamin B_{lt} B_6 and B_{12} may be given; oral or parenteral methylcobalamin may be of some help.
11. Recently, acyclovir (400 mg five times a day for 10 days) or valacyclovir (1000 mg daily for 5-7 days) is tried, although the evidence for giving antivirals is poor.

* Bell's palsy usually recover (70-80%) spontaneously within 2-12 weeks; < 10% may have residual weakness.

Features of incomplete recovery from Vllth nerve palsy :

1. Residual paralysis on the affected side of face.
2. Hemifacial spasm (rregular, painless clonic spasm of facial muscles).
3. Crocodile tears (unilateral lacrimation during chewing foods) — Rare.
4. Unwanted facial movements (e.g., closure of eyes with movement of mouth).

Complications of Bell's Palsy :

1. Exposure keratitis or conjuctivitis.
2. Hemifacial spasm.
3. Crocodile tears.
4. Facial contracture.
5. Jaw winking.
6. Social embarrassment.

Bad prognostic factors :

1. Complete palsy at the beginning.
2. Associated co-morbidities, e.g.. hypertension or diabetes.
4. Hyperacusis or loss of taste sensation.
5. Severe axonal degeneration on electrophy siological study (EMG) after 10 days.

Identification points :

Observe the face for a) asymmetry, b) symmetry of blinking and eye closure, and c) spontaneous

movements of face. Lastly, ask the patient to show his upper teeth when the angle of the mouth is drawn to the healthy side. Try to test the taste sensation, if possible.

* Read the examination of taste sensation from the chapter on 'Examination of the tongue".

** Facial nerve supplies all muscles of the face and scalp, except levator palpebrae superioris. In the parotid region, facial nerve divides into temporofacial (temporal, zygomatic and upper buccal) and cervicofacial (lower buccal, mandibular and cervical) branches to supply muscles of face, scalp and platysma.

*** Recurrent facial palsy may be a feature of multiple sclerosis.

Case 93

CHOREA

What is chorea ?

These are brief, rapid, jerky, explosive, non-repititive, quasi-purposive involuntary movements chiefly involving the face, tongue and limbs. The movements are totally irregular in time, rhythm, character and place of occurence. Chorea literally means 'a dance'.

Types of chorea :

1. Sydenham's chorea or Saint Vitus' dance (rheumatic).
2. Huntington's chorea (autosomal dominant disorder of early middle life with dementia).
3. Chorea gravidarum (during pregnancy).
4. Senile chorea (follow vascular lesion in old age; mainly affects oral-buccal-lingual muscles).
5. Chorea mollis (with hemiplegia).

Other aetiology :

6. OC pills, L-dopa, phenytoin, phenothiazines.
7. Systemic lupus erythematosus and antiphospholipid syndrome.
8. Polycythemia vera.
9. Thyrotoxicosis.
10. Post-encephalitic.
11. Chronic liver disease (e.g., Wilson's disease).
12. Alcohol.
13. Hypernatraemia.
14. Lacunar infarction.
15. Hypoparathyroidism.
16. Carbon monoxide poisoning.

How to demonstrate chorea ?

The diagnosis of chorea is made on clinical grounds. Ask the patient to raise up the hands over his shoulders and to maintain the posture. If chorea is present, patient will start rapid as well as jerky movements of the upper limbs.

* Very often agitation or excitement (e.g., a sudden slap over patient's face) increases chorea; it disappears during sleep.

Six cardinal features in chorea :

1. **Hypotonia** (though an extrapyramidal disorder) **—** Assessed by decreased resistance to passive movement. It is the only extrapyramidal lesion having hypotonia.
2. Patient will tend to pronate the outstretched hands (and sway outward) while extending the arms above the head — The **'pronator sign'.**
3. Ask the patient to grasp or squeeze the examiner's hand or finger tightly. There is waxing and waning of the grip — This is known as **"milkmaid's grip"** or **'milking sign',** and is due to irregular contraction of fingers.
4. The patient is asked to stretch out the hand and spread the fingers — Elbow is hyperextended, forearm is hyperpronated, wrist joint is flexed, metacarpophalangeal joints are extended with the separation of fingers (dinner-fork deformity). This is a manifestation of hypotonia. This phenomenon will be more obvious, if the patient is asked to raise up the hands above his head. This is also known as **'spooning sign'.**
5. Knee jerk — Pendular (due to hypotonia) and often the jerk is called **'hung-up reflex'** (when a choreic movement is superimposed on a tendon reflex).

6. Ask the patient to protrude the tongue — The patient protrudes it momentarily and takes it back within the oral cavity instantaneously **(lizard tongue).** The tongue, when projected, looks like a 'bag of worms'. Typical grimacing of face with protrusion of tongue often clinches the diagnosis.

* Clinical triad of chorea are : hypotonia, choreiform movement and mental instability.

What is athetosis and tics ?

Athetosis — These are slow, sinuous, purposeless, writhing involuntary movements usually involving the distal part of a limb (athetosis means 'instability of posture'). The movements are best seen in fingers, hands, toes, feet and tongue (snake charmer's movement).

Tics — Simple, normal movements which are repeated unnecessarily to become a social embarrassment. These are 'stereotyped' movements like head nodding, eye blinking or grimacing of face. Tics may be seen in anxiety states. They can be briefly suppressed by the patient.

Aetiology of ***athetosis*** are :

1. Post-hemiplegic (infantile).
2. Wilson's disease.
3. Kernicterus.
4. Overdose of L-dopa, phenothiazines.
5. Birth injury.
6. Encephalitis.
7. Cerebral palsy.
8. Degenerative brain disease.

Table 37 : Differentiation between chorea and athetosis

Features	Chorea	Athetosis
1. Lesion	1. Caudate nucleus	1. Putamen
2. Tone	2. Hypotonia	2. Hypertonia (rigidity).
3. Basic pattern	3. Rapid, continually interrupted and never proceeding to completion	3. Slow movements; extension and pronation plus flexion and supination of the arm, with alternating flexion and extension of fingers
4. Effect of agitation or excitement	4. Often increased	4. No effect
5. Parts involved	5. Proximal > distal part	5. Usually distal > proximal
6. Tongue	6. Lizard tongue	6. Chewing tongue
7. Deep reflexes	7. Pendular or hung-up reflex	7. Normal

What is 'pure chorea' ?

Chorea is a delayed manifestation of rheumatic fever (Jones major criteria) and other manifestations may not be present when chorea appears. Arthritis always subsides before the appearance of chorea. Sydenham's chorea appears after a long latent period (upto several months) from the antecedent streptococcal infection. When no previous rheumatic manifestations are observed, the cases are known as 'pure chorea'.

* Hemichorea—choreic movements restricted to one half of the body. Usually chorea is bilateral.

Drugs used in the treatment of chorea :

1. Phenobarbitone.
2. Clonazepam.
3. Chlorpromazine.
4. Haloperidol.
5. Sodium valproate.
6. Tetrabenazine.

What are the differential diagnosis of chorea ?

1. Athetosis.
2. Dyskinesia (m'ainly affects the pharyngeal, perioral and neck muscles, and produces axial tortional movements. This movement disorder is mainly drug-induced e.g.. by metoclopramide, phenothiazines. levodopa etc).
3. Tics.
4. Hemiballismus (violent ballistic and flinging movement of one side of body).
5. Myoclonus (sudden, rapid, irregular, jerky involuntary movements of a limb due to contraction of a single muscle or a group of muscles).

Effect of sleep on chorea :

Choreic movements subside.

What are the other involuntary movements you know ?

Other than, 1. Chorea. 2. Athetosis, and 3. Tics (habit spasm),

There are,

4. Myoclonus,
5. Convulsions,
6. Tremor,
7. Dyskinesia,
8. Dystonia (abnormally. maintained posture).
9. Hemiballismus,
10. Spasmodic torticollis.
11. Myokymia (called 'false or benign fasciculation'),
12. Asterixis,
13. Tetany (see the section on 'Fasciculation'), and
14. Muscle cramp.

* Fasciculation, titubation and opisthotonus are involuntary movements too. Tremor is a very common involuntary movement in clinical practice. Few clinicians do not agree that convulsions and muscle cramp are involuntary movements.

** Akathesia is motor restlessness with inability to sit still. There is always an intense urge to move. It is commonly seen in parkinsonism, chorea, thyrotoxicosis or phenothiazine therapy.

*** Restless leg syndrome (Ekbom syndrome)—intense desire to move the legs due to unpleasant sensation there, specially when the patient attempts to sleep or sits quiet. This is seen in chronic renal failure, peripheral neuropathy and iron deficiency anaemia.

Chorea without hypotonia :

Probably, it is a patient of chorea associated with athetosis (choreo-athetosis).

Conclusion :

1. Classical movements are already described. When choreic movements are superimposed on voluntary movements, there may be a 'grotesque' (strange or ugly) look of the posture.
2. Observe the face and movements of the tongue. At rest, the patient is 'unable to sit still'.
3. Inability to perform a voluntary movement in the absence of paralysis.
4. Bizarre gait.
5. Demonstrate '6 cardinal features'.

* Always examine the heart for any valvular lesion; search for exophthalmos, butterfly rash in face, K-F ring in cornea or polycythemia.

Case 94

FASCICULATION

What is fasciculation ?

These are fine, rapid, irregular and inconstant visible twitching movements of large group of muscle fibres or the whole motor unit. ***It indicates LMN lesion.***

What is fibrillation ?

These are contractions of a single muscle fibre. It is a state of hyperirritability (denervation hypersensitivity) of single muscle fibre and usually can not be detected in naked eye. It can be diagnosed by electromyography (EMG) and usually signifies complete denervation of individual muscle fibre.

Methods of bedside demonstration of fasciculation :

1. They may be seen as ripples underneath the skin overlying muscles at rest or sometimes 'spontaneously' produce clinically visible contractions.
2. If fasciculation is not spontaneous, they may be evoked by mechanical stimulation. In the presence of proper light, sharply tap (by the conical end of a hammer) over the degenerating muscle (never on fully degenerated muscle) for demonstration of fasciculation. Usually the bigger muscles like biceps, triceps, deltoid, calf muscles are chosen (this procedure is controversial because fasciculation should be spontaneous).

3. Fasciculation of the tongue — Keep the tongue relaxed in the floor of the mouth (never protrude the tongue) for demonstration of fasciculation.

Significance of fasciculation :

1. It signifies chronic degeneration of anterior horn cells or their homologue cranial nerve nuclei. It is always seen in a muscle which has undergone wasting. In the absence of wasting, fasciculation has no significance (benign fasciculation). So **fasciculation is seen in muscles undergoing active degeneration, not totally degenerated yet (wasting but not wasted).**
2. If fasciculation disappears from a muscle (which showed fasciculation previously), it signifies that the muscle is totally degenerated i.e., the anterior horn cells are completely destroyed (prognostically worse).
3. The muscular contraction of this special type of involuntary movement (fasciculation) is of fine amplitude and thereby, it is not able to move the adjoining joint.

* Fasciculation is due to spontaneous firing of surviving axons to innervate the denervated muscle fibres.

Can you see fibrillation in naked eye ?

As previously discussed, it is diagnosed by EMG but sometimes it is clinically evident in tongue as tongue has no submucous coat.

Common causes of fasciculation :

1. Chronic motor neurone disease (MND).
2. Cervical spondylosis.
3. Syringomyelia or syringobulbia.
4. Peroneal muscular atrophy.
5. Recovery from facial palsy (Bell's palsy).
6. Intramedullary tumour.
7. Peripheral neuropathy.
8. Acute stage of poliomyelitis.
9. Hypoxia, hypercapnoea, hypoglycaemia.
10. Organophosphorus poisoning.

* MND (amyotrophic lateral sclerosis) is the commonest cause. Fasciculation may be evoked by voluntary muscular contraction, cooling the muscle by ethyl chloride spray or hyperventilation.

What is benign fasciculation ?

When fasciculation is present in the absence of muscular wasting, it is known as 'benign fasciculation'. It is commonly seen in anxiety and fatigue states. It is often evident in thenar eminences, thighs, around the shoulder joint or orbicularis oculi (myokymia) muscles.

How do you classify chronic motor neurone disease (MND) ?

This is a disease of unknown origin which leads to degeneration of anterior horn cells of the spinal cord, motor nuclei of cranial nerves, and the corticospinal and corticobulbar pathways. The disease is characterised by insidious onset with a steadily progressive course, in a middle aged or elderly person. The classification goes like :

(A) Progressive muscular atrophy (predominant LMN type)—Weakness, wasting and fasciculation.
(B) Amyotrophic lateral sclerosis (predominant UMN type in lower limbs, and combined LMN plus UMN type in upper limbs) — Commonest (see below).
(C) Primary lateral sclerosis (predominant UMN type)—Progressive quadriparesis (rare).
(D) Progressive bulbar palsy.
(E) Pseudobulbar palsy.
(F) Mixed type of D and E.

* **MND may** be **given** as **a** long **case.**

Describe the motor functions' in amyotrophic lateral sclerosis (MND) :

(A) Nutrition of muscles :

1. **Wasting of the small muscles of hands (skeleton hand),** prominence of long flexor and extensor tendons of hands; sometimes, there is presence of claw hand. Knuckles are prominent and interosseous spaces are depressed.
2. At first there is wasting of the small muscles of hands which is followed by involvement of forearm muscles. Lastly, there is wasting of deltoid, supraspinatus etc.
3. There is not much wasting of lower limbs.

(B) Tone of muscles :

Upper limb — Tone is usually decreased (hypotonia).

Lower limb — Increased (clasp-knife spasticity).

(C) Power of muscles :

Power Is decreased more In upper limb than in lower limb because of the combined UMN and LMN involvement.

(D) Involuntary movements :

Fasciculation is seen predominantly in the upper limbs. Presence of fasciculation helps in the clinical diagnosis of MND. Never forget to see the tongue for fasciculation.

(E) Coordination of movements : Normal in both limbs (severe wasting may hamper coordination).

* There is early weakness of respiratory muscle. Usually there is no bed sore formation due to preserved sensory function.

** Rationality of nomenclature : LMN involvement—muscle atrophy (i.e., amyotrophy), UMN involvement—loss of fibres of lateral column (fibrilary gliosis i.e., lateral sclerosis).

*** The course of the disease is spastic quadriparesis or paraparesis with wasting.

Reflexes in MND :

(A) Superficial reflex :

(i) Abdominal reflexes are lost. It is seen that abdominal reflex may not be lost for a considerable period in MND though there is bilateral UMN lesion.

(ii) Cremasteric reflex — Lost.

(iii) Plantar response — Bilaterally extensor.

(B) Deep reflexes :

(i) Upper limb Jerks are brisk in the presence of wasting (clinically very characteristic of amyotrophic lateral sclerosis).

(ii) Lower limb — Jerks are brisk, clonus may be seen.

(C) Visceral reflexes : Normal.

N.B. . Small muscles of hands, forearm, deltoid, tongue, facial muscles are involved early. *Higher functions, external ocular muscles, autonomic, cerebellar, extrapyramidal, sensory and sphincterfunctions are normal in MND.* So, the disease presents with spasticity, brisk jerks, Babinski's sign in the lower limb, and fasciculation, weakness, wasting in the upper limb. Electromyography (EMG) is diagnostic (shows chronic partial denervation); nerve conduction velocity (NCV) is usually normal. Progressive and fatal course within 3-5 years. Riluzole (100 mg/day) may slow progression.

UMN Palsy in lower limb and LMN palsy in upper limb :

1. Amyotrophic lateral sclerosis.
2. Cervical spondylosis.
3. Syringomyelia.
4. Friedreich's ataxia.
5. Cervical extramedullary compression.
6. Patchymeningitis hypertrophic cervicalis (spinal syphilis).

What is tetany ?

Tetany is increased neuromuscular irritability due to low ionic calcium in blood. Normal serum calcium level is 9-11 mg/dl and the ionic fraction is 4.5-5.6 mg/dl.

Serum calcium < 8.5 mg/dl is hypocalcaemia while >11 mg/dl is regarded as hypercalcaemia.

Classical physical signs in tetany :

The increased neuromuscular irritability is tested by :

1. ***Trousseau's sign*** - When the pressure is raised above the systolic BP for 3 minutes, typical carpal spasm appears. There is flexion of MCP joints with extension of interphalangeal joints and the flexed thumb takes its position in between the index and the middle fingers (opposition of thumb). This is known as "main d' accoucheur" or obstetrician's hand. 'Pedal spasm is less frequently demonstrated. Latent tetany is best recognised by eliciting this sign.
2. ***Chvostek's sign*** - Tapping the facial nerve (by finger or hammer) in front of the ear will produce twitching of facial muscles.
3. ***Erb's sign*** - Muscular contractions can be produced by application of subthreshold electrical stimulation (0.5-2.0 milli-amps).

4. ***Peroneal sign*** - Tapping the peroneal nerve at the neck of fibula will produce plantiflexion and adduction of the foot with extension of knee (pedal spasm).
5. IECG — Prolonged Q-T interval.]

N.B. : Symptoms of tetany are.

1. Irritability.
2. Muscle cramps (carpopedal spasm).
3. Peripheral (hand and feet) and circumoral paraesthesia.
4. Triad of symptoms are common in children i.e., carpopedal spasm, laryngysmus stridulus (stridor, respiratory distress, cyanosis), and convulsions.
5. Dysphagia, dyspnoea, dysuria, abdominal colic etc.

Common causes of hypocalcaemia :

1. Malabsorption syndrome.
2. Hypoparathyroidism or pseudohypoparathyroidism.
3. Acute pancreatitis.
4. Chronic renal failure (CRF).
5. Rickets and osteomalacia.
6. Hypoalbuminaemia.
7. Alkalosis due to hyperventilation (often hysterical) or persistent vomiting (pyloric stenosis).
8. Citrated blood in massive transfusion.
9. Drugs—Calcitonin, bisphosphonates.

* Low total calcium is not associated with tetany if ionised fraction is normal. Low ionised calcium is associated with tetany irrespective of total calcium level. Transient hypocalcaemia (burn, sepsis) does not develop into tetany.

** Tetany is rare in chronic renal failure because of the presence of metabolic acidosis.

*** Causes of **hypercalcaemia** are : Primary hyperparathyroidism, malignant tumours, prolonged immobilisation, ingestion of excess vitamin A or D, milk-alkali syndrome, Paget's disease, thiazide diuretic, Addison's disease, granulomatous disease (e.g., sarcoidosis).

Causes of lock jaw or trismus :

Trismus develops due to sustained involuntary spasm of masseter and temporalis (masticatory muscles) resulting in inability to open the mouth and mastication, and is found in :

1. Tetanus (spatula test is positive; trismus is by far the most important early symptom)*.
2. Impacted wisdom tooth.
3. Peritonsillar abscess (quinsy), dental abscess, Ludwig's angina.
4. Acute follicular tonsillitis.
5. Temporo-mandibular osteoarthritis (Costen's syndrome) or rheumatoid arthritis.
6. Sometimes in drug-induced dyskinesia (metoclopramide, phenothiazines).
7. Sometimes in tetany, strychnine poisoning, cyanide toxicity.
8. Parotitis, mumps.
9. Hydrophidae group of snake bite.
10. Rabies.
11. Anaesthesia-induced malignant hyperthermia.
12. Hysterical.

N.B. : Painful trismus—2, 3, 4; painless trismus—tetanus and others.

* **Spatula test**—In health, touching the posterior pharyngeal wall by spatula produces reflex opening of mouth. In tetanus, paradoxically mouth closes in such a way that the spatula can not be taken out easily. Thus, spatula test is positive in tetanus and negative in others.

** In scleroderma and submucosal fibrosis of oral cavity, the patient may find difficulty in opening the mouth; but this is not true trismus.

*** **'Facies' in tetanus**—characteristic risus sardonicus (grimace mimicking 'smile of satan) due to contraction of facial muscles, and blepharospasm.

Case 95

MYOTONIA

What is myotonia :

In certain muscle disease like dystrophia myotonica (an autosomal dominant disorder), the relaxation of the muscle is impaired following a strong contraction *(myotonia).* This continued, involuntary muscular contraction after cessation of voluntary effort is known as myotonia. Myotonias are also clasified as -channelopathies' as there is defective skeletal muscles cell chloride ion membrane conductance.

Types of dystrophies of the muscle :

There are two types mainly :

1. Muscular dystrophy (Duchenne type etc.) or myopathy,.and
2. Myotonic dystrophy (or dystrophia myotonica).

* The two most common myotonias are myotonic dystrophy and myotonia congenita.

How do you diagnose myotonia at the bedside ?

The phenomenon (described below} is most evident when the muscles are cold. Myotonic muscle shows sustained contraction on direct percussion. The different bedside methods are :

1. Shake hand with the patient and then let it go suddenly — The patient s grasp is maintained for a moment, then released slowly and gradually i.e., there is poor hand grip relaxation.
2. Percuss the thenar eminence by a hammer — It shows a peculiar movement of the thumb (opponence movement) and a dimple of contraction appears on thenar eminence which fill up very slowly ('percussion myotonia'); this can also be tested over the wrist extensors.
3. Percuss over the tongue — A dimple of contraction appears which relaxes very slowly.
4. Ask the patient to close the eyes forcibly and then to open the eyes. The patient can not open the eyes promptly or opens it very slowly.
5. Ask the patient to smile and then to stop it — Smile remains fixed for a longer duration.

Clinical features of myotonia dystrophica :

Males are affected more than females.

1. Myotonia.
2. Ptosis (partial) with ophthalmoplegia.
3. Proximal muscle wasting with distal limb muscles weakness.
4. Long facial structure ('hatchet faced' and 'swan neck' appearances are due to atrophy of temporalis/masseter/facial muscles, and sternomastoid muscle respectively); a weak and expressioness face.
5. Cataracts.
6. Frontal baldness.
7. Mental retardation (mild).
8. Testicular atrophy.
9. Alopecia.
10. Dysarthria due to weak palatal, pharyngeal and tongue muscles.
11. Caidiac conduction defects, arrhythmias, mitral valve prolapse, glucose intolerance, insulin resistance, decreased oesophageal and colonic motility, low serum IgG, poor tolerance to general anaesthetics.

* Diagnosis is largely clinical. Serum CK level may be normal or mildly elevated, EMG is diagnostic and shows evidence of myotonia (waxing and waning of potentials, known as *dive-Bomber-effect),* while muscle biopsy show's type I fibres with increased number of nuclei, ring fibres and sarcolemmal masses.

Drugs used in the treatment of myotonia :

1. Phenytoin,
2. Mexiletine,
3. Quinine, and
4. Procainamide.

How to test the temporalis muscle ?

First inspect the suprazygomatic region for the muscle bulk of **temporalis.** In weakness oi temporalis, the temporal fossa will be hollow. Now ask the patient to clench his teeth. Inspect (above the zygoma) and palpate the temporalis muscle on both sides. Paralysed muscles will be less prominent and active muscle will stand out.

Masseter, another muscle supplied by the Vth cranial nerve, is tested in the same way. Paralysis of masseter results in flattening of the angle of the jaw. Again ask the patient to clench his teeth. Look for the prominence of masseter and palpate it, which stands out as corrugated hard mass at the angle of the jaw. Masseter, and temporalis to a lesser extent elevate the jaw (jaw closure).

* The other muscles supplied by the Vth cranial nefve are lateral and medial **pterygoids.** Individually, lateral or medial pterygoids help in jaw opening and its side to side movement. When both the pterygoids act, they help in jaw opening and its protrusion. They are tested by asking the patient to depress the jaw and to move it from side to side; then do the test against resistance offered by you by placing your hand under the chin and sides of the chin from time to time. In unilateral pterygoid palsy, on attempted jaw opening, the jaw will deviate (appraised by noting the relation between upper and lower incisor teeth) towards the paralysed side being pushed by the healthy pterygoids (as geniglossus muscle in tongue).

** Jaw opening is done by pterigoids, mylohyoid and anterior belly ot digastric muscle.

How do you test the sternomastoids ?

1. Both sternomastoids - Ask the patient to press the chin downwards against the examiner's resistance. Both sternomastoids will become prominent which can be corroborated both by inspection and palpation of the muscles.
2. Individual stemomastoid - To test the right stemomastoid, ask the patient to turn the chin to left side against resistance by placing your hand on left side of patients iace. The stemomastoid present on the right side becomes prominent on chin movement, il healthy, compare the test with the other side.

* In bilateral stemomastoid weakness, head will drop backwards. l\vo muscles which aie supplied by the XIth cranial nerve are trapezius and stemomastoid. Test the trapezius by asking the patient to shrug his shoulders, against your resistance (first demonstrate the "shrugging to the patient and then press both shoulders downwards simultaneously from BEHIND).

** Accessory nerve (Xlth cranial nerve) has two parts : Cranial (arising from the caudal part oi nucleus ambigiuus) and spinal (arising from upper five cervical segments). While examining accessory nerve, first observe for wasting and fasciculation of stemomastoid and trapezius, and then examine for drooping of the shoulder. Lastly, test the powers of stemomastoid and trapezius.

Neuroanatomy of the trigeminal nerve :

It is the largest cranial nerve.

Sensation of face is provided through three branches of trigeminal nerves, e.g..

(i) Ophthalmic branch (V,)—supplies conjunctiva, cornea, mesial part of the skin of the nose as far as the tip, upper eyelids, forehead and scalp as far as the vertex.

(ii) Maxillary nerve (V_2)—supplies lower eyelids, upper cheek, temple, sides of nose, upper lip, gum/teeth/palate of upper jaw.

(iii) Mandibular division (V_3)—supplies the ear, lower part of face (except the angle of mandible), lower lip, lower teeth and the epithelium of the anterior 2/3rd oi the tongue.

The motor branch supplies the **'muscles of mastication'** i.e., masseter, temporalis, lateral and medial pterygoids. If also supplies anterior belly of digastric, mylohyoid, tensor tympani and tensor veli palati.

The nucleus of trigeminal nerve are arranged like :

(i) Principal nucleus (motor and sensory) at pons—the motor branch conveys through V_3 to innervate muscles of mastication; sensory nucleus is meant for touch, joint-position sense).

(ii) Mesencephalic nucleus—carries unconscious proprioceptive information from palate, temporomandibular joint and muscles of mastication e.g., governs how much pressure is given to break a chicken bone during mastication.

(iii) Nucleus of spinal tract of trigeminal nerve extends from pons to C_2 level of spinal cord, and is meant for pain and temperature sensation ol face.

Tests of Vth cranial nerve :

1. Sensory functions Test for light touch, pain and temperature sensation (compare the right with the left). s
   a) Ophthalmic division :
      (i) On the both sides of root of the nose and forehead.
      (ii) Test for corneal reflex.
   b) Maxillary division :
      On the both malar region and upper lip.
   c) Mandibular division :
      On the both sides of chin (always avoid the angle of mandible which is supplied by C segment of the spinal cord by great auricular nerve). 2
2. Motor functions—Test the power of temporalis, masseter and pterygoids (i e muscles of mastication).
3. Reflex—Demonstrate the jaw jerk.

Clinical pearls in trigeminal nerve :

1. Bruxism involuntary and forceful teeth grinding during sleep.
2. Trismus—sustained involuntary spasm of masseter and temporalis, commonly found in tetanus.
3. Jaw tremor—in parkinsonism.
4. Complex partial seizure—chewing and masticatory movement of lower jaw.
5. Jaw claudication—giant cell arteritis.
6. Jaw fatiguability—myasthania gravis.

Case 96

MYOPATHY

What is muscular dystrophy or myopathy ?

These are genetically determined abnormality characterised by progressive degeneration of group volunta^muSes)1 mv0lvement °f the nervous system (generally, myopathy describes diseases of

Classification of muscular dystrophy (hereditary myopathy) :

I. X-linked :
   a) Severe form of muscular dystrophy (Duchenne type).
   b) Milder or benign form of X-linked disease (Becker type).
II. Autosomal recessive :
   a) Limb-girdle type (usually scapulo-humeral, rarely pelvi-femoral).
   b) Congenital variety.
III. Autosomal dominant :
   a) Facio—scapulo-humeral (Landouzy-Dejerine type).
   b) Distal myopathy (Gower type).
   c) Ocular or oculo-pharyngeal.

Why do you say Duchenne type of myopathy (DMD) ?

1. Male patient (due to X-linked inheritance, females cany the disease and males are the victims) — Starts in infancy and childhood with H/O frequent fall, rare after puberty
2. Positive family history (as it is X-linked disease, oblique transmission is present and maternal uncle, uncle or nephew are affected) - If you are allowed to take the history.
3. Insidious onset with gradually progressive course.
4. Mental retardation (may be present).
5. Positive Gowers' sign.
6. Difficulty in climbing upstairs and getting up from sitting position (due to involvement of

pelvi-femoral muscles i.e., **proximal muscles):** pelvic muscles involvement > shoulder muscles.

7. Pseudohypertrophy in few muscles and atrophy in others.
8. **Sensory system, bladder function, reflexes (superficial and deep) - All are normal.** There is no fasciculation (to differentiate it from MND).
9. Waddling gait.

* Deep reflexes are normal till the late stage.

** At 8-10 years, walking requires use of braces; by the age of 12 years, the patient is wheel chair-bound.

Classification of muscle diseases :

(A) Acquired :

1. Inflammatory myopathies—polymyositis, dermatomyositis, inclusion body myositis.
2. Endocrine and toxic myopathies—Cushing's syndrome, thyroid disease (both hyper- and hypothyroid), hypokalaemia, hypocalcaemia, alcohol abuse, steroids/fibrates.
3. Myasthenic—myasthenia gravis, Lambert-Eaton myasthenic-myopathic syndrome.

(B) Genetic :

1. Dystrophic—see the classification of muscular dystrophy (vide page 472).
2. Myotonic—myotonic dystrophy, myotonia congenita.
3. Channelopathies—hypokalaemic/hyperkalaemic/normokalaemic periodic paralysis.
4. Metabolic myopathies—myophosphorylase deficiency (McArdle's syndrome), mitochondrial diseases, malignant hyperpyrexia.

What are the X-linked disordes ?

1. Haemophilia.
2. G_6PD deficiency.
3. Christmas disease.
4. Duchenne muscular dystrophy.
5. Ocular albinism.
6. Colour blindness.
7. Hunter's syndrome.
8. Hypophosphataemic rickets.
9. Nephrogenic diabetes insipidus
10. Lesch-Nyhan syndrome.

* **Y-linked single gene disorder** is manifested commonly by 'hairy ears' in male. Other Y-linked disorders are XY female with the Y chromosome lacking the SRY (sex-region determining Y factor) gene or XY male having the SRY gene.

Pseudohypertrophy versus true hypertrophy :

(A) Pseudohypertrophy :

These are the large muscles as a result of deposition of fibrofatty tissue. The muscles look bulkier than normal muscles and they are doughy in feel (elastic feel is lost). When asked to contract, they are not hard and globular. The muscles are strikingly weak in spite of their large size. They are hypotonic and the deep reflexes may be dull (reflexes involving the muscles). Muscles affected by pseudohypertrophy in DMD are :

1. Calf muscles. 2. Glutei, 3. Quadriceps. 4. Deltoid, and 5. Infraspinatus.

Atrophy observed in DMD is classically seen in :

1. Pectoralis major (parchment paper-like), 2. Latissimus dorsi, and 3. Biceps.

* Pseudohypertrophy of muscles is seen in DMD, hypothyroidism (percussion myoedema is characteristic), glycogen storage disease and rarely in trichinosis.

IB) True hypertrophy :

Large muscles, elastic in feel; when asked to contract, they are hard and globular. These muscles are stronger then normal-sized muscles.

N.B. : In DMD, usully there is symmetrical involvement of muscles. Ultimately all the muscles in the body become atrophied. Facial muscles and small muscles of the hands are usually spared in DMD.

Causes of true hypertrophy of muscles :

1. Manual labourers.
2. Athletes.
3. Myotonia.
4. Sometimes, in cysticercosis (in muscle).
5. Acromegaly.
6. Benign hypertrophy of limb muscles (hypertrophica musculorum vera of Oppenheim).

What is Gowers' rising test ?

When the patient is asked to stand from lying down position, he adopts a curious manner of rising. He first rolls over his body and then take support successively on the ground, feet, legs, knees and waist, and finally stands up. It seems that the patient is 'climbing up the legs' and is known as Gowers' rising test or Gowers' sign. This sign is not specific for DMD, as it may be found in any condition where the pelvic girdle muscles are weakened and thus, it may be observed in polymyositis, spinal muscular atrophy and other myopathies (e.g., endocrine myopathy).

What is waddling gait ?

It is like the 'gait of a duck'. The body is first tilted backwards, with an increase of lumbar lordosis. The feet are placed wide apart and the body sways from side to side as soon as the patient starts stepping. The hip tilts down when the leg is being lifted. The heel and toes are brought down simultaneously. It is due to weakness of the proximal pelvic muscles and is specially seen in myopathy. Causes of waddling gait are :

1. Duchenne muscular dystrophy.
2. Pregnancy (advanced).
3. Congenital dislocation of hip (bilateral).
4. Sometimes in huge ascites or morbid obesity.

Causes of proximal muscle weakness :

1 Muscular dystrophy.
2. Polymyositis and dermatomyositis.
3. Diabetic amyotrophy.
4. G. B. syndrome.
5. Neuralgic amyotrophy.
6. Radicular lesion, e.g., cervical spondylosis.
7. Sometimes in fulminant myasthenia gravis.
8. Thyrotoxic myopathy or Cushing's syndrome.
9. Metabolic myopathy e.g., hypokalaemia.
10. Drug-induced—Corticosteroid myopathy.
11. Malignancy.
12. Osteomalacia
13. Porphyric neuropathy.

Causes of distal muscle weakness :

1. Wasting of the small muscles of hands (See page 355).
2. Polyneuropathy (familial or acquired).
3. Distal myopathy of Gower.
4. Sometimes in myotonic dystrophy.
5. Charcot-Marie-Tooth disease.
6. Inclusion body myositis.

Causes of wasting of muscles :

1. LMN lesion due to any cause.
2. UMN lesion — There is disuse atrophy only.
3. Muscular dystrophy.
4. Disseminated malignancy.
5. Diabetes mellitus.
6. Thyrotoxicosis.
7. Malnutrition.
8. Disseminated tuberculosis.
9. AIDS (slim disease).
10. Anorexia nervosa.

* Causes of unilateral wasting of leg : old poliomyelitis, diabetic amyotrophy, disuse due to severe arthritis, prolapsed intervertebral disc, cerebral palsy.

Power testing of different muscles involved in DMD :

1. Calf muscles (gastrocnemius and soleus) — Patient lies supine with legs extended. Ask the patient to plantiflex the foot against resistance (keep the ankle fixed by holding it firmly).
2. Quadriceps — Patient lies supine; first bend the knee and then ask the patient to straighten the leg when resistance is applied over the shin.
3. Glutei — Patient lies supine; raise the patient's foot off the bed and ask him to push it down against yout resistance. Knee must be kept extended. Gluteus maximus helps hip extension.
4. Deltoid—First abduct the patient's arm to 30° and tell him to keep his arm in that position. Now ask him to abduct his arm upto 90° against your resistance (supraspinatus abducts the first 30°).
5. Infraspinatus — The examiner stands behind the patient. The patient is asked to tuck his elbow into his side with the forearm placed at right angle. He is now asked to rotate the limb outwards against your resistance (elbow will be placed against the side throughout the test).

6. Latissimus dorsi — Palpate the posterior axillary folds from behind when the patient coughs. Compare the contraction on both sides; or ask the patient to clasp his hands behind his back and you offer resistance to the downward and backward movement (stand behind the patient).
7. Pectoralis major — Standing in front of the patient, ask him to clap his hands together and you attempt to keep them apart. The contraction of pectoralis can be seen.

[N.B. : Hamstrings muscles—The patient lies supine with knee flexed at 90°. Ask the patient to pull the heel towards buttock while you resist it by holding the leg at ankle.]

* **While testing the 'power' of muscles :**

Before testing, always try to demonstrate the movement rather than explaining it verbally.

(i) Expose the muscle fully.
(ii) Ask the patient to contract the muscle against your resistance,
(iii) See the muscles contracting,
(iv) Feel the strength of contraction, and
(v) Compare with your own strength or what you judge to be normal.

** there are two methods of testing muscle power ;

(i) **Isometric testing**— The patient is asked to contract the muscle powerfully and to maintain the contracted position while the examiner tries to keep it in original position. In isometric testing, there is no shortening of muscle.
(ii) **Isotonic testing—** The patient is asked to contract the muscle and the examiner opposes the movement at the initial part of contraction.

*** ***Isometric method is more sensitive and detects minor degree of weakness*** though isotonic testing is commonly practised method in neurology.

D/D you ***will consider in this case :***

1. Different causes of proximal muscle weakness.
2. Peripheral neuropathy - Sensory changes, distal involvement.
3. Motor neurone disease - Adults with asymmetrical wasting and fasciculation.
4. Post-poliomyelitis - Jerks lost with asymmetrical atrophy (characteristics of poliomyelitis—post-febrile, asymmetrical, non-progressive, without any sensory loss and with LMN signs).

How do you like to investigate myopathy ?

1. Enzyme study - Serum aldolase and CK are raised. Normal value of aldolase is 1.5-8.1 units / litre and CK is 55-170 units / litre. Enzymes are often increased by 100-200 times than normal.
2. Electromyography (EMG) shows myopathic pattern.
3. Muscle biopsy - 'Confirms' the diagnosis of myopathy. It shows islands of muscular degeneration as well as regeneration in the ocean of fibrofatty tissue, without any cellular infiltration. There is diminished dystrophin level in muscle tissue, determined by immunochemical staining.
4. CSF study and nerve conduction velocity (NCV) are normal.
5. ECG change — Tachycardia, tall R waves in right precordial leads, deep Q waves in left precordial leads, bundle branch block due to cardiac involvement (cardiomyopathy).

Do ***you know its management ?***

No specific management of muscular dystrophy is available. Active exercise, passive physiotherapy, orthopedic measures are often helpful. Usually death occurs in second decade of life due to pneumonia, respiratory failure, cardiomyopathy or cardiac failure.

Identification points :

1. Male child.
2. Waddling gait and positive Gowers' sign (ask the patient for demonstration).
3. Pseudohypertrophy (principally the calf muscles) plus atrophy of muscles.
4. Proximal muscles weakness (ask the patient to get up from sitting position).

* **Becker type** of dystrophy (X-linked recessive) usually starts between 5-25 years. It is the late onset, 'milder' form of myopathy with slow progression as well as less cardiac involvement. The patients are chair-bound 25 years after the onset and may even survive upto 5th or 6th decade.

** DMD is caused by mutation of the gene responsible for production of the protein dystrophin.

Case 97

JERKS AND CLONUS

What is jerk, deep reflex, stretch reflex or tendon reflex ?

When a tendon is lightly stretched and struck by a single sharp blow with a soft rubber hammer, there is brief contraction of that muscle, which is known as tendon reflex. The tendon reflex is a 'monosynaptic' stretch reflex (note : superficial reflexes are polysynaptic nociceptive reflex). By elicitation of a jerk, the integrity of the afferent and the efferent pathways along with excitability of the anterior horn cells in the spinal segment of the stretched muscle are tested.

Prerequisites before elicitation of a jerk :

1. Use a hammer with firm and flexible shaft.
2. Stand on the right side of the patient (even for elicitation of jerks for the left side).
3. Explain the procedure to the patient. Reassure that it will not hurt him.
4. The patient lies supine in the bed in a comfortable and relaxed position.
5. Tap the tendon, not the muscle belly (specially in triceps jerk).
6. Expose the muscle (being tested) fully—a must for all the reflexes.
7. Observe both the contraction of the muscle and the movement of the limb.
8. Always compare with the other side and observe for the 'symmetry'.
9. Use the hammer by 'swinging movement' of the wrist joint.
10. Sudden, single and sharp blow with sufficient threshold are applied over the tendon.
11. Genitalia should be properly covered in eliciting jerks of lower limbs.
12. Always use same type of hammer in same manner (i.e., maintain the uniformity). Repeat the procedure, if necessary).

* While eliciting different tendon reflexes (see below), the position of the limb is maintained in such a way that the tendon to be tapped is slightly stretched.

Jerks commonly examined in clinical neurology :

Root values and peripheral nerves concerned in different jerks are given below :

1. Ankle jerk ($S_{1\ 2}$)—medial popliteal nerve.
2. Knee jerk ($L_{2\ 3\ 4}$)—femoral nerve.
3. Biceps jerk ($C_{5\ 6}$)—musculocutaneous nerve.
4. Triceps jerk ($C_{6\ 7}$)—radial nerve.
5. Supinator jerk ($C_{5\ 6}$)—radial nerve.
6. Jaw jerk—trigeminal nerve.

Ankle jerk :

1. Conventional method—The patient lies supine with the lower limb (to be examined) flexed at the knee, foot slightly everted (the foot may rest on the opposite leg). Now dorsiflex the foot with the left hand and apply a sharp tap on tendo-Achilles. A quick contraction of calf muscles with plantiflexion of foot occur.
2. Special method The patient takes kneel-down position on a chair with both feet hanging out of the chair. Sharp tap is applied over tendo-Achilles on both sides in turn (do not passively dorsiflex the foot). Calf muscles contract and plantiflexion of foot results. It is done specially in myxoedema to observe the delayed relaxation time (myotonic reflex). Careful observation of delayed relaxation time in ankle jerk (due to 1 muscle metabolism) often clinches the diagnosis of myxoedema at the bedside. Myotonic reflex is classically seen in ankle jerk.

Knee jerk :

1. Conventional method—The patient lies supine with both the knee joints flexed at about 90°. Now place your forearm, dorsum of the wrist or palm under the knee (to be tested) or both the knees, and ask the patient to rest the knee completely on your hand. Be careful so that the legs should not be in contact with each other in bed. Feel the quadriceps tendon and apply a sharp tap there. The quadriceps muscle contracts with extension of the knee.
2. Special method—The patient sits on a chair with the legs hanging free side by side. After tapping the patellar tendon, look for the pendulous movement of the legs. This is classically seen in cerebellar lesion and sometimes in chorea (indicates hypotonia). Hung-up reflex (the knee may be held in extension for few seconds before relaxing) may be seen by this special method (read the section on 'Cerebellar disorder' too).

N.B. : The 'patella' hammer derives its name from knee jerk (because the patellar tendon is tapped) as it was the first tendon reflex which was regularly practised for neurological examination.

Biceps jerk :

The elbow remains semiflexed at right angle with a semipronated position of the forearm. The limb may rest on patient's abdomen or upon your left hand. Place your left thumb or index finger (transmitter for blow from hammer) on the biceps tendon in the antecubital fossa and tap suddenly over your finger. The biceps muscle contracts with flexion of the elbow.

Tricpes jerk :

Place the patient's hand over his chest with the elbow flexed. Support the hand at the wrist by your left hand so that the upper limb does not fall on the bed. Suddenly tap above the olecranon process (strike the triceps tendon, not the belly of the muscle; tap 2" above the elbow) and observe the contraction of triceps with slight extension of the elbow. Muscle contraction after direct hammering is not a stretch reflex.

Supinator jerk :

Forearm is semipronated and the elbow is flexed. Hold the patient's hand at wrist and a sharp tap is applied on the styloid process which results in contraction of brachioradialis, supination of the forearm, and flexion of the elbow with minimal flexion of the fingers. As this muscle was previously called supinator longus, the reflex is known as supinator jerk (also referred as radial jerk).

Inversion of supinator jerk :

When there is a lesion in the spinal cord at $C_{5\ 6}$ segment (commonly due to cervical spondylosis resuting in myeloradiculopathy), there is hyperexcitability of the anterior horn cells below this level. So, ***during elicitation of supinator jerk,*** there is no flexion at elbow but only brisk flexion of the fingers (as C_7 take upperhand) occur; this is inversion of supinator jerk.

Similarly, in INVERSION OF BICEPS JERK (lesion at $C_{5\ 6}$ segment), there is no contraction of biceps during elicitation of biceps jerk but one can see the contraction of triceps (as $C_{6\ 7}$ take upperhand). Inversion of a jerk localises the level of lesion in the spinal cord. Usually, inversion of supinator and biceps jerks are seen in a single patient, and is most commonly found in cervical spondylosis.

Jaw jerk :

Prerequisites :

1. Preferably patient should be seated with mouth partially open.
2. Tongue remains inside the mouth.
3. Left thumb or forefinger is placed over the middle of the patient's chin.
4. Strike the hammer lightly on the thumb in a downward direction.

The normal response is slight and consists of sudden closure of the mouth due to contractions of masseter and temporalis. This reflex is just present or absent in health. The jaw jerk is increased in bilateral UMN lesions above the Vth cranial nerve nucleus e.g., pseudobulbar palsy or multiple sclerosis. Both the afferent and the efferent fibres pass through the trigeminal nerve, and the centre for this reflex lies in the pons. Interpretation regarding mere presence or briskness is often very difficult.

What is finger-flexion jerk ?

Its presence indicates hyperreflexia, and exaggeration or asymmetry suggests UMN lesion on the abnormal 'side. The tips of your middle and index fingers are placed across the palmar surfaces of the proximal phalanges of the patient's relaxed fingers. A sudden tap by a hammer on your fingers produces flexion of patient's fingers, but a very brisk contraction indicates hyperreflexia. The root value of this reflex is $C_{7\ 8}$ and T_r and the peripheral nerves involved are median and ulnar nerve.

Hoffmann's sign :

Flex the DIP joint of patient's middle finger and now flick it down suddenly. The response is brisk flexion and adduction of the thumb as well as flexion of the tip of other fingers. It is also a manifestation of hyperreflexia. This reflex may not be present in all patients with pyramidal tract lesion and moreover, it may be present in a nervous individual without any organic lesion. If the reflex is seen on one side (unilateral) only, it may have some value as a sign of pyramidal tract lesion. The root value of the reflex is C_8, T_r

Wartenberg's sign :

Interlock the flexed fingers of the patient with your flexed fingers and try to pull apart. In health, the thumb remains abducted and extended but in pyramidal tract lesion, the thumb flexes and adducts.

Interpretation of tendon reflexes :

(A) Present — In health.

(B) Lost or diminished — 1. LMN lesion (poliomyelitis, syringomyelia, peripheral neuropathy, tabes dorsalis, peroneal muscular atrophy etc.)
2. UMN lesion in shock stage.

* Isolated loss of a reflex usually suggests radiculopathy. Symmetrical loss of reflex may be found in peripheral neuropathy. Reflexes may be absent if the patient is 'unable to relax'.

(C) Exaggerated — I. Anxiety neurosis, nervousness, hysteria.
2. Thyrotoxicosis.
3. Tetany.
4. Tetanus.

(D) Brisk — 1. UMN lesion.
2. Sometimes in hypoglycaemic coma.

(E) Pendular — 1. Cerebellar lesion.
2. Chorea.

(F) Delayed relaxation (ankle jerk) — Myxoedema.

(G) Hung-up reflex (knee jerk) — Chorea, myxoedema, hypothermia.

(H) Inversion of supinator jerk — Level of lesion in C_{56} spinal segments

** Hyperreflexia means exaggerated or brisk response. For a student it is very difficult to differentiate between the two. In a broader sense, exaggerated reflex means the 'amplitude' of the limb movement is more and brisk reflex means, the reflex is very 'prompt' in its response. We may conclude that hyperreflexia is only of pathological significance when it is asymmetrical (comparing with the other side) or if associated with other signs of UMN lesion (spasticity, Babinski's sign etc.)

*** A reflex seems lost or diminished in defect of technique, relaxation, or observation.

**** Sometimes, lesion in the spinal cord may give rise to 'crossed reflex induction', e.g., while eliciting a knee jerk on right side, it may produce a reflex response on the left knee jerk.

What is Jendrassik's manoeuvre ? .

It is also known as 'reinforcement'. When the deep reflexes or jerks are not elicited by routine manoeuvre, reinforcement is applied for augmentation of response. It is done by distraction of patients' attention. Ask the patient,

1. To make a fist with the contralateral hand, or
2. To interlock the fingers of two hands together and then pull them as hard as possible, or
3. To clench the teeth, or
4. To push the knees hard together.

It is very important to remember that this phenomenon lasts for less than a second. So the patient is asked to do the manoeuvre almost synchronously with the tapping of the tendon (the procedure must be demonstrated to the patient before tapping the tendon). Reinforcement (to make some strong voluntary muscular effort) acts by,

a) Increasing the excitability of the anterior horn cells, and
b) Increasing the recruitment of gamma-fibres, i.e., increasing the sensitivity of the muscle spindle primary sensory endings to stretch (increased gamma fusimotor drive).

* **Always perform the Jendrassik's manoeuvre before declaring a tendon reflex 'absent'.**

** For upper limb reflexes—1, 3, 4; for lower limb reflexes—2, 3.

Causes of loss of knee jerk :

It signifies the lesion at the level of $L_{2\,3\,4}$ spinal segment. The causes are :

1. Non-cooperative patient or faulty technique.
2. Acute anterior poliomyelitis.
3. Peripheral neuropathy.
4. Myelopathy in shock stage.
5. Progressive musclar atrophy (MND).
6. Subacute combined degeneration.
7. Friedreich's ataxia.
8. Tabes dorsalis.
9. Sometimes in diseases of myoneural junction (e.g., myasthenic crisis).
10. Muscular dystrophy in late stages.
11. Ankylosis of the knee joint.

* In case of loss of deep reflex restricted to one limb only, one should not forget acute anterior poliomyelitis, entrapment neuropathy, leprosy and diabetic mononeuropathy.

Chronic tophaceous gout with tophi present over olecranon process, tibial tuberosity, shins, feet, tendo-Achilles and dorsal aspect of fingers

Spider naevi at upper part of back in cirrhosis of liver

Rheumatic nodules – small nodules over olecranon process of a young girl suffering from acute rheumatic fever

Ladder-pattern **visible peristalsis** in acute small intestinal obstruction

Discoid lupus erythematosus (DLE)

Ascites with umbilical hernia. Abdominal paracentesis should be done to avoid strangulation of hernia

Hands in scleroderma showing sclerodactyly (tight skin over fingers), pulp atrophy (acrosteolysis in right index finger), digital infarction, nail changes, salt-pepper skin and H/O Raynaud's phenomenon

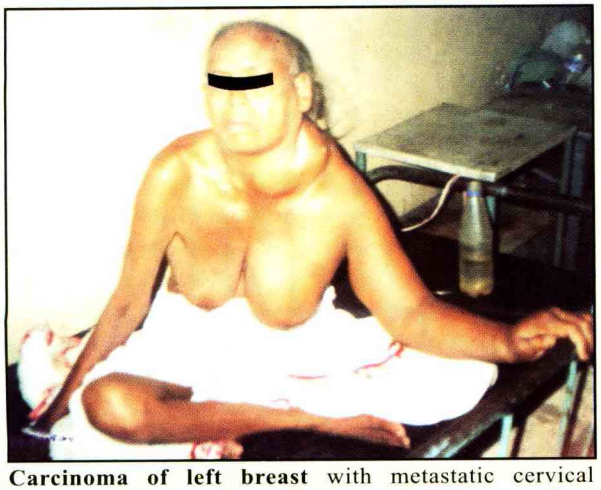

Carcinoma of left breast with metastatic cervical lymphadenopathy and **lymphoedema** of left upper extremity

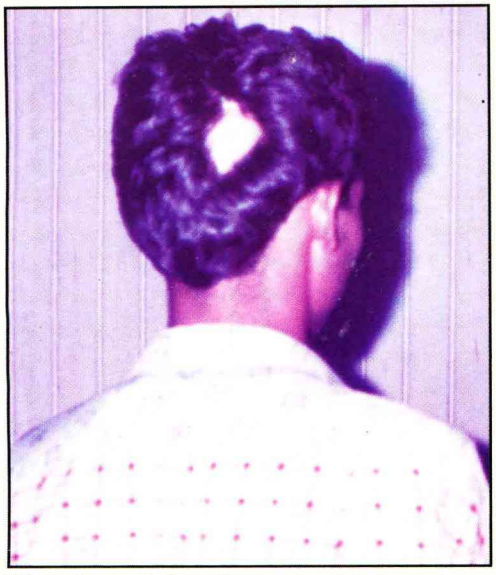

Alopecia areata in scalp

Vitiligo

What are the different responses ?

Usually there are 5 types of responses :

1. Flexor.
2. Extensor (up-going toe).
3. Equivocal.
4. No response.
5. Withdrawal response.

Briefly describe the different responses :

(A) **Flexor**—Normal response; already described.

(B) **Extensor** (extensor plantar response is also known as "Babinski's sign"). The responses are :

1. Dorsiflexion (extension) of the great toe (movement occurs at the metatarsophalangeal joint) which usually precedes all other movements mentioned below.
2. Fanning (spreading out) and extension of outer four toes.
3. Dorsiflexion of the ankle, and flexion of the knee and the hip.
4. Contraction of tensor fascia lata.

* In 1896, Babinski first described this sign. Josef Francois Felix Babinski (1857–1932) was a French physician cum neurologist. This sign is regarded as THE SIGN in clinical neurology.

(C) **Equivocal**—i.e., incomplete response or variable response. When the full components of the extensor response is not manifested e.g., (i) only fanning of outer four toes is seen without any movement of the great toe, or (ii) the hemiplegic side does not show any response and the healthy side shows flexor response (sometimes seen in early cases of CVA), or (iii) asymmetry of 'flexor' response in both sides.

Remember, today's equivocal response may be tomorrow's extensor response.

(D) **No response**—After striking the sole of the foot, there is no movement of any of the toes.

(E) **Withdrawal response**—Often withdrawal response is seen in anxious individuals or in normal persons with hyperaesthetic / sensitive sole. It is seen that the initial normal flexor response is quickly followed by mass extension of toes with withdrawal of the entire leg.

** The afferent nerve of this reflex (plantar response) is tibial nerve; the efferent nerve is tibial nerve for flexor response and peroneal nerve for extensor response.

*** Babinski's sign is the most senstive, delicate and reliable sign of corticospinal tract lesion.

**** In hemiplegia or paraplegia (i.e., UMN lesion), the plantar response remains extensor life-long.

***** 'Crossed' extensor response—on unilateral stimulation of the sole in a case of bilateral cerebral or spinal cord lesion, bilateral extensor response can be evoked (e.g., in severe spastic paraplegia).

Significance of presence of Babinski's sign :

It signifies pyramidal tract lesion with or without anatomical discontinuity. The causes are :

1. **Pyramidal tract lesion** (i.e., UMN lesion above the S_1 level of the spinal cord).
2. Children below 1 year of age (due to lack of myelination of pyramidal tract).
3. Deep coma due to any cause.
4. Deep sleep.
5. Deep anaesthesia; neuroleptics or narcotic overdose; hypnosis; drugs (e.g., barbiturates).
6. Metabolic encephalopathy.
7. Often in hypoglycaemia (even in the absence of coma).
8. Immediately after the attack of generalised convulsions or epilepsy (post-ictal phase).
9. Electroconvulsive therapy.
10. Physical exhaustion (e.g., marathon runner).
11. Apnoea phase of Cheyene-Stokes respiration.

N.B. : Except 1, all are the causes of lesion in pyramidal tract without anatomical discontinuity, and thereby produce transient plantar extensor response. No. 8, 9 and 10 are due to exhaustion of corticospinal tract.

'Reinforcement test' of plantar response, if any :

1. Rotating the patient's head to opposite side.
2. Knee must be extended during the test.
3. Apply warmth to the cold skin of the sole.

Causes of delayed relaxation of ankle jerk :

1. Myxoedema (the contraction phase is delayed too) — Commonest cause 2. Gross pedal oedema 3. Hypothermia 4. Obesity 5. Parkinsonism.

Grading of reflexes :

0	=	Absent		Exaggerated or hyperactive +++
1	=	Present (as normal ankle jerk)		Normal ++
2	=	Brisk (as normal knee jerk)	Or	Diminished +
3	=	Very brisk		Absent –
4	=	Clonus		Only with reinforcement ±

Muscles acting of different joints :

(A) Ankle joint :

a) Dorsiflexion—Tibialis anterior

b) Plantiflexion—Gastrocnemius and soleus (calf muscles)

c) Inversion Tibialis anterior and tibialis posterior

d) Eversion—Peroneii muscles

(B) Knee joint :

a) Extension—Quadricpes femoris (i.e.. three vasti + rectus femoris)

b) Flexion Hamstrings muscles (biceps femoris, semimembranosus and semitendinosus)

(C) Hip joint :

a) Extension—Gluteus maximus mainly

b) Flexion—Ileopsoas

c) Adduction—Adductor muscles

d) Abduction—Gluteus medius and minimus

What is clonus ?

It is the rhythmical contraction of a muscle or group of muscle in response to sudden passive and sustained stretching. Clonus is always associated with brisk tendon reflex, spasticity and Babinski's sign. It is a very reliable sign of pyramidal tract lesion. There are two types of clonus •

1. Sustained clonus (true clonus).
2. Unsustained clonus (pseudoclonus).

Sites for clonus in clinical neurology :

1. Ankle clonus.
2. Patellar clonus (or knee clonus).
3. Jaw clonus (elicit the jaw jerk to see a series of closure and opening of the mouth).
4. Wrist clonus (elicited by sudden passive hyperextension of the wrist which will evoke clonic movement of palm). 1

N.B. : No. 3 and 4 are not routinely practised in clinical neurology.

Ankle clonus :

Patient lies supine. Support the **flexed knee** (both knee and ankle resting in 90° flexion) with your left palm by placing it in popliteal fossa in such a way that heel rests gently on the bed Now suddenly dorsiflex the foot by grasping the forepart of it with your right hand. A series of contraction and relaxation of calf muscles are seen if a steady pressure is maintained on the foot by the right hand.

Patellar clonus :

Patient lies supine with **knee extended.** Patella is pulled upwards by the index finger and the thumb with a fold of skin behind the palm. Now a sharp and sudden displacement of the patella downwards with sustaining the pressure will produce series of quadriceps contraction.

N.B. : Ankle and patellar clonus are produced as a result of loss of upper motor control (i.e., UMN lesion) over $S_{L\,2}$ and $L_{2\,3\,4}$ spinal segments respectively.

Pseudoclonus :

1. The clonus is not sustained inspite of a steady pressure.
2. Irregular in rate (usually less than 6 at a time) and rhythm.
3. It is commonly seen in anxiety, in tense persons, often in hysteria and thyrotoxicosis.

4. Plantar response is always flexor.

* Many a time, the boundary between true and pseudoclonus is not very clear.

Conclusion :

It you are in doubt whether the clonus is true or pseudo, immediately do the following :

1 Plantar response will be extensor in true clonus and flexor in pseudoclonus.
2. Examine the pulse (high volume in thyrotoxicosis, tachycardia in anxiety) and look lor (me tremor (anxiety, thyrotoxicosis) — if present, indicates pseudoclonus.

* **Never forget to examine a patient for clonus if there is presence of brisk tendon reflex.**

Case 98

Plantar Response (Reflex)

Method of elicitation :

One should learn how to elicit this superficial reflex properly. At first, educate the patient about the procedure. The patient lies supine with extended legs and relaxation of the muscles ot the lower limbs. Hold one leg firmly above the ankle joint with your left hand (to prevent withdrawal response) in such a way so that toes of the foot look towards the roof, and the outer border of the sole is scratched gently but firmly (neither too speedy nor too slow) by the tip of a key (preferable stick of the hammer or blunt needle. Starting from the heel, go along the lateral border towards the little toe an then turn medially across the metatarsal pad upto the head of 2nd metatarsus **(never touch the baU of the great toe and the flexor creases of the toes)** in a semicircular lashion. The stimulus should not produce injury but it should be of noxious character (a combination of pressure pain and touc) since this is a 'nociceptive reflex'. Stop stimulating the sole as soon as you get the first movement the great toe. Now do the test on the other side. Plantar response is a spinal reflex arc modified by the pyramidal tract.

It is the most important and most frequently misinterpreted reflex in the body.

What is the normal plantar response ?

The normal response of this age-old sign in neurology is 'flexor' in type and is manifested by :

1. Flexion of all the five toes.
2. Dorsiflexion and inversion of the foot (with a stronger stimulus).
3. Contraction of adductors of the thigh, sartorius and tensor fascia lata (minimal response).

Precautions taken before eliciting plantar response :

1. Assess the thickness of the sole—Thick sole may be responsible for 'no response'.
2. Look for any deformity of great toe—Move the great toe, and confirm that it is moving freely and is not rigid (e.g., hallux rigidus, rheumatoid arthritis).
3. Knee must be extended.
4. Sole should be made warm (e.g., by rubbing with your palm, specially in winter season).
5. Leg should lie straight (don't allow rotation of thigh).
6. One may assess the power of extensor hallucis longus before doing the test (optional).
7. Ask the patient whether sensation in sole is intact or not (by touching the sole with your palm).

What is the root value of this reflex ?

S..

Why the lateral aspect of the sole is stimulated ?

1. Probably the receptors for extensor plantar response are present there in abundance and thus, even in minimal UMN lesion, extensor plantar response is obtained by stimulating the lateral aspect of the sole.
2. If the medial aspect of the sole is stimulated, it may elicit flexion (even in the presence ol UMN lesion) of all the toes as part of the grasp reflex, itself a different phenomenon.

No response' or loss of plantar response :

1. **Faulty technique.**
2. Thick sole
3. Coldness of the feet.
4. **Stage** of'**neural** shock'.
5. Peripheral neuropathy.
6. Myelopathy involving S, segment.
7. Paralysis of dorsiflexors of the foot.
8. **Hallux valgus or** hallux **rigidus.**

What are the 'plantar equivalence' ?

In case of widespread and severe UMN lesion, the reflexogenic zone may be greatly widened and an -extensor" plantar response may be evoked by different techniques. They are :

T LA.u»-. sign—Heaw pressure is applied by the thumb and Index finger from above downwards to anterior surface of tibia (to its medial side>. The extensor response usu y **occurs towards the end of the stimulation.**

2. **Gordon's** reflex—Squeezing or applying deep pressure to calf muscles produce extensor plantar response.
3. **Shefer's** sign-Extensor plantar response is evoked after applying deep pressure to tendo-**Achilles.**
4. **Chaddock's** sign-Extensor response is seen after striking the skin around the lateral mal-leolus in a circular fashion.
5. Bing sign-Pricking the dorsum of foot or the great toe by a pin produces extensor response.
6. Moniz sign—Extensor response is seen after forceful passive plantar flexion of ankle
7. Gonda sign-Extensor resopnse is elicited after forceful stretching or snapping of distal pha-lanx of either of the 2nd or 4th toe.
8. **Brissaud's** reflex-Contraction of tensor fascia lata as a part of extensor response (palpate the upper and lateral part of thigh for appreciation). This is helpful in patients *with amputa e or absent great toe, or complete paralysis of extensors of toes.*

* 12 3 and 4 are commonly practised methods in clinical medicine.

- These reflexes are useful in non-cooperative patients or when the soles are extremely sensitive or the soles are wounded/injured.

What is Rossolimo's sign ?

Method : Either tap the ball of the foot (by percussing the plantar surface of the ball of the great toe with a hammer) or flick the distal phalanges of the toes into extension and then allow them to back into their normal position.

Response : Pyramidal tract lesion, manifested by plantiflexion of all the five toes (only sign with UMN lesion, manifested by plantiflexion of great toe). It is the homologue of Hoffmanns sign of upper limb.

Plantar response is extensor with loss of ankle jerk :

1. Subacute combined degeneration (SCD) of the spinal cord.
2. Taboparesis (GP1 plus tabes dorsalis).
3. Friedreich's ataxia.
4. Cauda-cona lesion (cauda equina lesion with lesion in conus medullaris).
5. Combined cervical and lumbar spondylosis.

Plantar response is flexor with brisk ankle jerk :

1. Sometimes in anxiety and thyrotoxicosis (exaggerated deep reflex).
2. Hepatic pre-coma.

Why the ball of the great toe is not touched while eliciting plantar response ?

During the elicitation of plantar response, one should stop scratching the sole at the head of 2nd metatarsus If the ball of the great toe is scratched, there may be dorsiflexion of the great toe (by direct stimultion) in the absence of any UMN lesion. It is why the root value of the plantar resonse is only the 1st sacral segment of the spinal cord.

N.B. : *The first movement of the great toe is important.* Extension of great toe after a brief initial flexion is not extensor response. Remember, there is nothing called negative or positive Babmski s sign.

Pseudo-Babinski's sign may be seen in plantar hyperaesthesia or chorea.

Case 99

TROPHIC CHANGES (NEUROGENIC)

What are the trophic changes ?

1. Trophic changes in the skin and appendages,
2. Trophic ulcers, and
3. Charcot joint (neuropathic joint).

Changes in the skin and appendages :

1. Dry, rough and cold skin.
2. Pigmentation.
3. Local cyanosis or local oedema.
4. Hypohydrosis (lack of sweating).
5. Hypotrichosis (fall of hairs).
6. Brittle nails.

Sites examined for trophic changes :

Denudation of skin with ulcer (bed sore) formation over the bony prominences is seen :

1. On the lateral malleolus.
2. Back of the heel of foot.
3. Shoulder girdles.
4. Over the sacrum (classical bed sore).

* Bed sore may form in a patient with prolonged recumbency, specially without change of posture.

What is trophic ulcer :

These perforating ulcers are usually present **over the heel** or **ball of the great toe** During walking, heel is touched first in the ground and thus, it is a common site for pressure sore formation The patients with foot drop touches the ground with the ball of the toes (leprosy, diabetes mellitus) and thus, trophic ulcer froms there. In syringomyelia and tabes dorsalis, the ulcer is usually situated in the heel (as no foot drop is there). Trophic ulcer is usually painless.

* Tropical ulcer' (totally different from trophic ulcer) is a chronic form of callous ulcer with its edge raised and undermined. It often refuses to heal.

Common causes for trophic ulcer in feet :

Same as the causes of Charcot joint (see page 484).

* Peripheral nerve injuiy (in legs) and spina bifida may give rise to trophic ulcer in feet.

Aetiopathogenesis of trophic changes :

1. Loss of muscular action upon the circulation,
2. Vasomotor paralysis due to destruction of the vasoconstrictor (sympathetic) fibres, and
3. Partly due to disuse.

* **Search for trophic changes in hemiplegia, paraplegia and peripheral neuropathy.**

** **Autonomic nervous system (ANS)** may be involved in hypothalamic disorders, diabetes mellitus or spinal lesions. The points noted during examination of ANS are :

Sleep disorder (insomnia or somnolence), temperature regulation, genital dysfunction (impotence or amenorrhoea), sweating (diminished or excessive), postural or orthostatic hypotension, trophic changes (e.g., ulcer), Horner's syndrome, bladder and bowel dysfunction (urinaiy incontinence, diarrhoea), pupillary areflexia.

Points to note in examination of cranium and spine in neurology :

(A) Cranium (inspection, palpation, percussion and auscultation) —

1. Microcephaly (cerebral palsy), macrocephaly (hydrocephalus. Paget's disease) or turricephaly (tower-like peaked appearance due to synostosis of sutures), doliehocephaly (long antero-posterior diameter), brachycephaly (short antero-posterior diameter) or oxycephaly (cone-shaped and pointed head).
2. Haematoma, elevation, fracture or depression, scar mark, secondaries in skull, mass in myeloma.
3. Fontanelle (tense fontanelle is seen in hydrocephalus and raised intracranial tension).
4. Sutures (springing of the sutures is seen in hydrocephalus).
5. Cracked-pot sound in hydrocephalus on percussion.
6. Bruit (in angiomatous malformation or stenosis)—Carotid artery bruit in neck at carotid bifurcation, vertebral or subclavian artery bruit at supraclavicular fossa, and bruit in cerebral arteriovenous malformation may be heard over cranium or closed eye.

(B) Spine —

1. Any tenderness.
2. Gibbus (e.g., caries spine, metastasis, trauma).
3. Kyphoscoliosis.
4. Spina bifida occulta (by inspecting the tuft of hair, dimpling of skin, fibrofatty tumour or dilated vessels over the sacrum).
5. Short neck (cranio-vertebral anomaly).
6. Bruit heard over spine in angiomatous malformations.

* **One must examine the spine in all neurological cases, specially in paraplegia.**

Case 100

CHARCOT JOINT

What is Charcot joint ?

This is a chronic, progressive degenerative arthropathy which is also known as **neuropathic joint.** The characteristics are :

1. Huge swelling of knee, hip, ankle or shoulder joint **(most common site is knee joint).**
2. *Painless (most characteristic).*
3. Disorganised, deformed and destroyed joint.
4. Increased mobility (rarely, genu recurvatum may be produced) of the joint and thus, easy dislocation is possible—unstable or subluxed joint.
5. Loose bodies may be palpated in the joint cavity and crepitus may be felt with new bone formation (osteophytes).

What are the common causes of neuropathic joint ?

1. Leprosy (commonly affects the upper extremity).
2. Diabetes mellitus (tarsal and metatarsal joints mostly affected).
3. Syringomyelia (shoulder, elbow and wrist joints mostly involved).
4. Tabes dorsalis (knee, hip and ankle joints commonly affected).
5. Sometimes found in hereditary sensory neuropathy or after repeated intra-articular injection of steroid.

Most important neurological sign tested in a patient of Charcot joint :

Posterior column sensations, i.e., joint, position, muscle, vibration and pressure senses are lost here. Charcot joint is the complication of chronic loss of proprioception.

Pathophysiology of development of Charcot joint :

There are two theories—

1. Loss of proprioception leads to recurrent trauma damage goes unnoticed by the neuropathic patient -> ultimately leads to progressive destruction, degeneration and disorganisation of the joint.
2. Hyperaemia results from neurally mediated vascular reflex -> leads to increased osteoclastic bone resorption.

Basic principles of testing sensory functions :

Sensory evaluation is the most unreliable part of neurological examination as it is subjective and is difficult to quantify. Basic principles of testing are :

1. Explain the patient clearly what is going to be tested; patient's cooperation and alertness are essential. Try to gain confidence by proper understanding.
2. *First test with eyes open and then with eyes closed.*
3. Always compare the sensory function with the opposite side for symmetry.
4. First apply the sensory stimulus to the area of altered sensation and delineate its borders by testing from abnormal to normal area. Ask the patient to say 'yes' if he feels anything.
5. A hairy area may be shaved before testing.

6. Test the spinal segments or dermatomes sequentially (e.g.. In the lower limb, first examine the Lj segment and then proceed downwards for $L_{2\ 5}$ segments and again upwards for S segments present in different places in the said limb).

* Cervical, (CJ has no cutaneous supply, which only supplies meninges.

Superficial sensations (spinothalamic functions) tested are—

(A) TOUCH—fine touch is tested with a small piece of cotton wool which is twisted into fine hair while crude touch may be tested by the wider side of a cotton wool or the tip of index finger. Fine touch sensation may be evaluated over toes, metatarsal heads, heels, and dorsum of feet with a 10 g monofilament (Semmes Weinstein monofilament), specially in a patient of diabetes.

(B) PAIN—usually tested by a pin (avoid heavy pressure); select the pre-stemal area for baseline sharpness before testing a limb; ask whether the quality of sensation becomes sharper or painful (hyperaesthesia). or feels blunter (hypoaesthesia).

(C) TEMPERATURE—actually it is tested by two test tubes containing cold (5°-10°C) and hot (37°-45°C) water touched on face, forearms, hands, trunk and legs in a random sequence; a rough assessment is done by the metal of tuning fork or stethoscope (cold), or by rubbing the palms (hot) as a clinical bedside routine. A normal person can appreciate even a difference of 1°C.

* Deep pain sensation is tested by pressing the calf muscles, tendo-Achilles or testes.

How to test for deep and cortical sensations ?

Deep sensations (posterior column functions) tested are—

(A) VIBRATION SENSE—it is the test of repeated touch sensation in quick succession. First keep the vibrating tuning fork (128 cycles/sec) over the sternum so that the patient can identify the sense of vibration (not the touch sensation). On a particular site, vibration sense should be perceived minimally for 10 seconds. Instruct the patient to close his eyes. For the lower limb, hold the vibrating fork sequentially over the great toe, dorsum of foot, medial malleolus, tibial shaft (shin) and tuberosity, and anterior superior iliac spine. In the upper limb, the fork is kept sequentially over DIP and PIP joints of forefinger, dorsum of hand, wrist joint, olecranon process and over the shoulder. In the trunk, it is tested by placing the fork over ribs, sternum, clavicles and vertebral spines. Always compare with the other side. From time to time, judge the patient by stopping vibrating fork with your hands. The rule goes like this—if the distal vibration sensation persists, it is useless to examine the proximal parts but in case of loss of distal sensation, always move proximally in turn. Vibration sense is commonly lost in posterior column lesion (tabes dorsalis), peripheral neuropathy (specially, diabetes mellitus) and old age (physiological).

(B) MUSCLE SENCE—compress or squeeze big muscle bellies (calf, triceps or biceps) and note whether the patient complains of pain (Abadie's sign) or not. This is the test of PRESSURE SENSE too.

(C) JOINT AND POSITION SENSE—first, explain the patient about the test with movements of joints ('it is up' or 'it is down'). Now, ask the patient to close the eyes. For examination of the lower limb, grasp the proximal phalanx of great toe by your left hand, and hold the ***medial and lateral borders of the distal phalanx*** with the thumb and index finger of your right hand so that pressure above and below does not reveal the direction of movement. Move the distal phalanx up and down at random (15°-30°) and ask the patient whether any movement is perceived by him or not (joint sense), and to identify the direction of movement (position sense). In health, movements of < 10° can be perceived at all normal joints. In the upper limb, this test can be done in the index finger. Perform the test on the other limb too. If there is impaired joint sense in small joints, test the big joints in turn. Caution should be taken during the test so that your fingers should not rub against the patient's other toes. At least four wrong answers should be received before declaring the joint sensation impaired or lost. Position sense can also be tested by instructing the patient to keep one limb in a particular position and then ask him to keep the opposite limb in the similar position.

Cortical sensations (parietal lobe functions) tested are—

(A) ONE POINT LOCALISATION—ask the patient to localise accurately parts of his body touched by a cotton wool (eyes remain closed).

(B) TWO POINT DISCRIMINATION—it is tested by the use of blunt compass or divider. In health, a minimum distance of 2-3 mm on the lips, 3-5 mm on the finger tips, 2-3 cm on the dorsum of hands, or 3-4 cm on the dorsum of the foot can be recognised as two different stimuli.

(C) STEREOGNOSIS—small objects of various size e.g., coins, match box, pencil, key (i.e., familiar objects) are placed in the patient's palm and asked to identify while the eyes remain closed. Recognition of size, shape, weight and form of a common object, and identification of it by touch and manipulation is known as ***stereognosis.*** Patient's failure is known as astereognosis.

(D) GRAPHAESTHESIA—draw letter, number, diagram or circle with a blunt object, or with your index finger over the patient's back, thigh or forearm (eyes remain closed). A normal person can easily identify the letter or number written on the skin surface (graphaesthesia).

(E) SENSORY EXTINCTION (SENSORY INATTENTION, SENSORY NEGLECT, PERCEPTUAL RIVALRY)—homologous points on two sides of the body are pricked with a pin separately (eyes remain closed). If the patient can identify the pin prick in both the situations, the previous points are now pricked 'simultaneously'. In unilateral parietal lobe lesion, the sensation on the opposite side is not perceived by the patient.

* Cortical sensations are carried to contralateral parietal lobe through peripheral nerves via posterior column. If peripheral nerves or primary sensations are at jeopardy, it is useless to test cortical sensations.

** See page 176 for different sensations carried through spinothalamic tract and posterior column.

What are the patterns of different sensory disturbances ?

Sensory modalities should be tested in search of a pattern consistent with spinal cord, spinal root or peripheral nerve abnormalities.

1. Peripheral neuropathy— Symmetrical 'glove and stocking' paraesthesia or anaesthesia, affecting the distal parts more; involves all modalities of sensations.
2. Nerve root lesion— Pain is often felt more than the loss of touch sensation; dermatomal pattern of sensory loss in the distribution of nerve roots.
3. Complete section of the spinal cord— Loss of all modalities of sensations below the level; a narrow zone of hyperaesthesia on the top of anaesthetic zone. 'Sacral sparing' may be present in few cases of high cord compression.
4. Hemisection of the spinal cord (Brown-Sequard syndrome)— Vide page 160.
5. Cauda cona lesion— 'Perianal anaesthesia', i.e., all modalities of sensations are lost involving lower sacral segments. In cauda equina lesion, there is asymmetric sensory loss in lower limbs.
6. Anterior spinal syndrome— e.g., in anterior spinal artery thrombosis there is loss of pain, touch and temperature on both the sides below a level, with preservation of proprioception.
7. Posterior spinal syndrome— It is just the opposite of the anterior spinal syndrome. There is loss of joint, position and vibration sense below a particular level with preservation of touch, pain and temperature. It is commonly seen in tabes dorsalis.
8. Central cord lesion— e.g., in syringomyelia, there is affection of spinothalamic tract due to involvement of fibres crossing the cord from both sides in the anterior commissure though it spares the posterior column. Thus, touch sensation persists but pain and temperature sensations are lost (dissociated anaesthesia). The sensory loss is in shawl-like distribution ('sleeve jacket' anaesthesia).
9. Mid-brainstem lesion— Ipsilateral sensory loss in face with contralateral loss on the body. There is loss of touch, pain and temperature sensations as a result of affection of trigeminal tract or nucleus, and lateral spinothalamic tract.
10. Thalamic lesion— Contralateral loss of all modalities of sensations (position sense is affected more) on one side of face and body. There may be history of spontaneous, disabling type of pain i.e., hyperpathia (thalamic pain).

* **Dissociated sensory loss** (a sign of spinothalamic tract involvement with sparing of posterior column), i.e., loss of pain and temperature with preservation of touch (fine) sensation is found in :

1. Anterior spinal artery thrombosis.
2. Syringomyelia, haematomyelia, hydromyelia, intramedullary tumour.
3. Posterior inferior cerebellar artery syndrome (or lateral medullary syndrome).
4. Brown-Sequard syndrome (hemisection of spinal cord).
5. Leprosy neuropathy (small fibre neuropathy).

What other signs will you search in a patient with Charcot joint ?

Always search for trophic ulcers in the heel or ball of the great toe in a patient with Charcot joint.

Radiological features of Charcot Joint :

1 Osteopenia (bone density is less). 3. Severe disruption and disorganisation of the joint.
2. Sharp cortical margin. 4. Inappropriate new bone formation.

Differential diagnosis of a swollen knee joint :

1. Septic arthritis.
2. Osteoarthritis.
3. Huge joint effusion (e.g., traumatic).
4. Gout or pseudogout.
5. Haemophiliac joint.
6. Rheumatoid arthritis.
7. Tuberculosis of the knee joint.
8. Charcot joint.
9. Reactive arthritis.
10. Rheumatic fever.
11. Seronegative spondarthritides.
12. Psoriatic arthritis.

* Except 8 , all are painful.

Management of Charcot joint :

1. Treatment of the underlying disorder.
2. Stabilisation of the joint is done by braces and splints.
3. In case of diabetes mellitus, prevent weight bearing in the foot for 2 months to prevent severe disease (trophic ulcer etc).
4. Lastly, fusion of a very unstable joint may be done.

Conclusion :

In a suspected patient of Charcot joint,

1. Test the joint for pain sensation (by moving the joint).
2. Test for other posterior column sensations.
3. Always search for trophic ulcers in foot.

Case 101

ABNORMAL GAIT

What is gait ?

It is the posture of the patient during walking (decubitus means posture of the patient in bed).

Precautions taken before examination of gait :

T'ne pattern of gait very often gives a clue to neurological disorder. Normal body posture and locomotion require integration of motor and sensory system, extrapyramidal system visual informa _ tJon, intact labyrinthine function and proprioception-the last one is the most important. One should ascertain the following facts before the examination of gait :

1 Examine the stance. Is the patient able to walk ? Any deviation ? Any tendency to fall
2. Exclude the disease of joints and bone or surgical causes producing disorders in gait (say, osteoarthritis of the hip).
3. Legs should be adequately exposed (i.e., at least upto the knee).
4 Feet should be bare.
5 The patient is asked to walk freely in the room, and then along a straight line (crack or g ' placed in floor-mosaic); and then to turn and walk back in the original position.
6. ^he patient may be asked to walk on toes or on heels. Tandem gait (heel to toe gait) should always be examined.
7 Assure the patient of his safety by your close presence.

* During walking look meticulously for posture (e.g., stooped), arm swinging, as^oc[1]^ mvolunt ry movements, pain complained, fall towards one side, symmetry of steps and width of the bas .

What is stance :

, • Hih.rip r.f Ihr natient on standing'. The bipedal stance is examined by asking the

ZZSZ

Sel to stfTnTofone U at a time, ihen to »ta„d on toe,, and then on beets. The pa,ten, may be

pulled abruptly backwards from the shoulders while noting his balance (i.e., postural reflex). Stance in different disease are :

1. Hemiplegic stance—the patient stands with extended and adducted lower limb with plantiflexed foot on the affected side, keeping the body weight on the healthy side. The affected upper limb is typically flexed, adducted and semipronated; there is flexion of the wrist, MCP and IP joints with slight adduction of the thumb.
2. Wide base stance—the patient stands with legs and feet placed wide apart to keep balance of the body weight, and is classically seen in alcoholics, sensory ataxia and peripheral neuropathy.
3. Stance with unilateral cerebellar disease—The affected-sided shoulder is held at a lower level and the body weight is thrown on the healthy side. 'Head tilt' is observed towards the affected side.
4. Stance in parkinsonism—the patient stands in a general attitude of flexion (typical 'stoop'). The head is slightly flexed on the trunk and there is general flexion of the spine. All the limbs are held in flexion in all the joints and the hands may exhibit static tremor.
5. Lordotic stance—In proximal muscles weakness (e.g., myopathy), the patient can stand erect with an exaggerated lumbar lordosis. In weakness of erector spinae muscles (e.g., spinal muscular atrophy), the patient stands with a lordotic stance.
6. Hysterical stance—The patient starts swaying which starts in hips instead of ankles but never falls on the ground. The effects are same whether the eyes are open or remain closed (false positive Romberg's sign).

Different types of gait :

1. HEMIPLEGIC or SPASTIC GAIT : This is seen in hemiplegic patients (UMN lesion) after recovery. The patient walks on a narrow base, the hemiplegic limb is held stiffly, and does not flex at the knee and hip. While the patient drags his affected foot, the foot is raised from the ground by tilting the pelvis and the leg is swung forward forming a semicircle or an arc—known as 'circumduction' of the leg. The outer side of the sole of the shoe is worn (as there is plantiflexion on the affected side). The affected arm is carried in a flexed position and does not swing naturally. The hemiplegic gait is essentially a spastic gait.
2. SCISSORS or SPASTIC PARAPLEGIC GAIT : The patient stands with crossed legs (often with a stick in one hand). Each leg is advanced slowly and stiffly with restricted motion at the knee and hip. He steps one limb in front of the other in a semicircular fashion ('scissoring' of gait). It is found in patients with spastic paraplegia and cerebral diplegia.
3. STAMPING GAIT : This is the gait of posterior column lesion or sensory ataxia, and is classically seen in tabes dorsalis. The patient stands on a broad base with careful watch on the ground. He raises his foot suddenly to abnormally high level (as he does not know where the foot is), jerks them forward and bring them on the ground with a stamp (the heel touches the ground first and one may find a trophic ulcer in the heel). These patients are severely ataxic with eyes closed. Romberg's sign is present in patients with stamping gait.
4. HIGH-STEPPING GAIT or EQUINE GAIT : This type of gait is found in patients with foot drop and is commonly seen in peripheral neuropathy, acute anterior poliomyelitis or common peroneal nerve palsy. This is just like the gait of sensory ataxia where the patient elevates his legs to a high level and bring them on the ground with a slapping noise. As there is foot drop, toes touch the ground first (trophic ulcer is found in the ball of the great toe) though a high-stepping attitude is adopted by the patient in order to avoid injury to the toes.
5. FESTINANT GAIT : It is the gait of parkinsonism (read the section on 'Parkinsonism'). It is worthwhile to remember that a patient of parkinsonism may run better than walk or walk backwards better than forward.
6. WADDLING GAIT : The walking becomes a 'waddle' i.e., the pelvis being poorly supported by each leg. Read the section on 'Myopathy'.
7. REELING, STAGGERING, DRUNKEN or ATAXIC GAIT : This is observed in cerebellar ataxia and alcoholic intoxication. The patient walks on a broad base, the unsteady feet are planted widely apart and placed irregularly. The patient sways from side to side. The steps are uncertain, some are shorter and some are longer than intended, and the patient tends to fall or deviate to the side of cerebellar lesion. The ataxia is equally severe whether the eyes are open or closed. Tandem walking is virtually impossible. Read the section on 'Cerebellar disorder'.
8. PROSTHETIC GAIT : This is the gait with an artificial limb.

9. LIMPING GAIT : This type of gait is adopted due to joint diseases (tuberculosis of the hip), talipes equinovarus or any painful condition in the lower extremities.
10. HYSTERICAL or FUNCTIONAL GAIT : The patient often walks with bent knees or trunk. This is a bizarre gait with combination of all the varieties (hemiplegic, paraplegic, ataxic etc.) and does not resemble any known pattern of organic disease. The patient drags the affected leg with an exggerated delay, while the typical circumduction is absent; but walks normally in the absence of an observer. He/she never falls during walking. Hysterical hemiplegia patient should be examined for (to differentiate from organic hemiplegia) :
    a) The patient lies supine and is asked to raise one leg against resistance. In a normal person, the back of the heel of the contralateral leg is pressed firmly down in the bed (examiner's hand placed under the heel), and the same is true in a patient with organic hemiplegia when he/she tries to lift the paralysed or weak leg against resistance. The hysteric will contract the good leg more strongly than as a primary' willed action (Hoover s sign).
    b) Babinski's leg flexion test—If a patient with organic hemiplegia is asked to sit (from supine position) against resistance without using his/her arms, the paralysed leg flexes involuntarily owing to lack of stabilisation of joints while in hysteria the normal leg is flexed first.
    c) Astasia-abasia'—Though the hysterical hemiplegic patient is unable to stand or walk without assistance, he/she uses his legs normally while in bed.

* 'Marche a petipa' (after the Russian ballet master)—In bilateral corticospinal lesions (diffuse cerebrovascular disease) short, stamping steps occurs with bilateral spasticity and extensor plantar response. The rapid steps resemble a ballet dancer on her points. It is found in bilateral frontal lobe disease, pseudobulbar palsy, Alzheimer's disease and normal pressure hydrocephalus.

** Jaunting gait is seen in chorea. Patient's knee may give way momentarily resulting in a fall.

*** Arthritis and muscular pain make walking stiff and slow (antalgic gaint).

**** There is another Hoover's sign in internal medicine where the patients with advanced COPD show paradoxical inward movement of rib cage with each inspiration.

Different varieties of gait :

1. Neurogenic - 1, 2, 3, 4, 5 and 7
2. Myogenic - 6
3. Prosthetic - 8
4. Arthrogenic - 9
5 Psychogenic - 10

O

"Now, this is not the end. It is not even the beginning of the end. But it is, perhaps, the end of the beginning."

— Sir Winston Churchill (1874-1965)
British Politician

YOUR EXAMINATION HALL

1. Be smart, gentle, polite and courteous In your gesture. Do not rush, be patient.
2. You should look confident, never overconfident; be professional in attitude.
3. Be precise. Listen the question carefully and then answer 'to the point'. Speak out clearly, slowly and concisely in a confident voice. Be optimistic and get free from any tension.
4. Do not try to be clever but be careful. Do not hesitate to revise the diagnosis.
5. Be methodical. Remember, mostly the errors are made by making cursory and incomplete physical examination than due to lack of knowledge and skill.
6. While examining a patient, you should have a lady's hand (fine and gentle touch) with an eagles eye. Show respect to your patients as well as examiners (try to wish).
7. Nothing succeeds like thorough preparation though you may not know everything—so prepare yourself for the 'unexpected'.
8. Do not argue with your examiner. Do not be biased. Do not agree to anything you are not sure of. Be alert and focused (key of success). .....
9. Always try to answer in the order of frequency, i.e., from more common to less common causes, and avoid rare ones. Perform systematically.
10. Remember, the difference between success and failure is marginal.

PATH OF SUCCESS

1. Sufficient preparations with sincerity.
2. Ability to express.
3. Ability to build up good relationship between the patient and the examinee, and the examiner and the examinee.
4. Strategic planning, creative visualisation and willpower to succed in the face of all odds.
5. To have confidence as well as common sense, and
6. Good-luck.

INSTRUMENTS TO CARRY IN THE EXAMINATION HALL (CHECK LIST)

1. Stethoscope (preferably double-tube).
2. Hammer (preferably with flexible shaft).
3. Pencil torch (battery should be powerful).
4. Sphygmomanometer (mercury or aneroid type); it is better to have your own instrument.
5. Pins (for testing of pain sensation and blanching reaction).
6. Cotton.
7. Measuring tape (for measurement of the abdomen in ascites, neck in thyroid enlargement, expansion of chest, head in hydrocephalus and assessment of nutrition).
8. Skin pencil.
9. Compass (for two point discrimination)—optional.
10. Tuning fork (128 or 256 cycles/sec for vibration sense, and 256 or 512 cycles/sec for cochlear function).
11. Tongue depressor.
12. Two one-rupee coin (for coin percussion in the chest, stereognosis).
13. Clinical thermometer.
14. Cotton wrapped in a broom-stick (for gag reflex).
15. Four small glass containers for taste sensation (containing solutions of sugar, common salt vinegar and quinine)—optional.
16. Cardboard or clipboard (for history writing).
17. ADMIT CARD, APRON, PEN, scale, pencil, eraser, and **CONFIDENCE.**

* ?"r^/3.hSk f°Q a/'?aCIC;reSt' (f°r neck vein examination), gloves (for per rectal examination) or eighing machine. Switch off your mobile phone while in the examination hall.

THE HISTORY SHEET

1. Prefix the patient's name by Sri/Mr/Mrs/Miss.
2. Write sequentially upto differential diagnosis. Relevant investigations are optional.
3. 'All the systems' should be written. Usually the time alloted in a 'long case is 45 minutes.
4. In the history and clinical examination, stress the important points by underlining them.
5. Blood pressure should always be measured because it is part and parcel of general survey (mandatory—supine; optional—standing position i.e., to diagnose 'postural drop').
6. Do not write the facts which you have not enquired or examined; but remember if any test/ fact is not written, it is granted that it is not done.
7. A beautiful handwriting influences the examiner. Spelling mistakes create a bad impression.
8. Try to avoid abbreviations; remember MS means mitral stenosis as well as multiple sclerosis.
9. If anaemia cyanosis or jaundice is present, mention the degree or type whichever is applicable If any system has no abnormality, it is better to write 'within normal limit or no abnormality detected' against the subheadings of the respective system. In case of build or nutrition, the term 'average' is preferred to 'normal'. If the facies is inconclusive, write 'nothing suggestive'.
10. Write the summary meticulously. Many examiners give stress on summary. A good summary will speak for yourself.

MODEL DISTRIBUTION OF MARKS FOLLOWING RECOMMENDATION OF MCI

General Medicine : Full marks 300

Theory ; Paper I + Paper II = 60 + 60

Internal assessment : 60 (theory 30 + practical 30)

Oral (including X-ray and CT, ECG, instruments and specimens, charts, medical emergency) : 20

Clinical (bedside) : 100 (one long case 60 + one short case 30 + two spot cases 10)

* Marks distributed in the long case (60) as follows : History 15 + demonstration of signs 25 + discussion and crossing 20

** Internal assessment ; Distribution of marks (60) will be as follows ; Medicine 40 + dermatology (including STD) 10 + psychiatry 5 + chest and TB 5

*** Criteria to pass in the examination :

Aggregate 50% i.e., 150 marks

Theory and oral (including internal assessment) 50% i.e., 100 marks

Practical (bedside clinics) 50% i.e., 50 marks

N.B. ; One should get 50% in internal assessment to pass in the examination

Theory part ;

Paper I___CVS, respiratory system, haematology, neurology, endocrinology and rheumatology

Paper II___ Tropical diseases, gastro-intestinal, and diseases of liver and biliary system, renal diseases, metabolic and nutritional diseases, poisoning and environmental diseases, psychiatry, dermatology including STD

**** u_{ac}h theory paper usually contains 4 short questions (4 x 10) and short notes (5 short notes x 4). Short questions are short-structured essay type and problem-oriented type. There may be overlap in Paper I & II.

***** Acute cases (e.g., LVF, acute severe asthma) are usually not given in the examination.

Long case comprises of history writing + demonstration of signs + relevant discussion.

Short case means general survey and examination of one particular system (nothing to be written).

Spot case means spotting the diagnosis (with examiner observing) and mentioning its justification.

A

Abadie's sign 174, 180, 241, 485
Abscess
    liver 115
    lung 88, 92
Abdomen
    consistency 276
    examination 276, 280
    inspection 107, 270
    mass 275
    movement 277, 425
    shape 269, 275
Abdominal reflex 163
ABPI 248
Acanthosis nigricans 252, 362, 395, 414
Accessory muscles, respiration 90
Accommodation reflex 451
Achondroplasia 339
Acromegaly 413
Acute phase reactors 35, 370
Acute severe asthma 97
Addison's disease 361, 412
Adie's pupil 451
Adrenal crisis 412
Adson's test 356
Aegophony 57, 87, 93
Ageusia 433
Agnosia 295
Agranulocytosis 222
AIDP 160, 176
AIDS 232
Air hunger 99, 250
Akathesia 466
Alar chest 423
Albumin 342, 344
Aldehyde test 237
Alkaline phosphatase 117, 132, 393
Alopecia 382
(Xj-antitiypsin deficiency 122, 123, 130
Amino acids, essential 344
Amoebic liver abscess 115
Amyloidosis 233, 292, 373, 374, 431
Amyotrophic lateral sclerosis 467
Anaemia 128, 211, 213, 215, 216, 222, 236, 300, 397
Anal reflex 138
Anasarca 265, 329
ANCA 385
Aneurysm of aorta 49, 277
Angina pectoris 36
Angioneurotic oedema 96, 112, 192, 330, 325
Angle of Louis 83
Angular stomatitis 303
Anisocoria 450
Ann Arbor classification 228, 229
Anorexia 113, 235
Anosmia 457
Anterior spinal syndrome 486
Antimony preparation 238, 239
Antituberculosis drugs 78, 79, 375
Anuria 187, 192
Anxiety neurosis 403
Aortic aneurysm 49, 277
Aortic incompetence 39, 47
Aortic sclerosis 29, 48
Apex beat 7, 21, 25, 26, 75, 418
Aphasia 434. 444
Apical impulse 7, 21, 55
APLA 384, 385
Aplastic anaemia 222
Apnoea 98
appetite 235
Apraxia 295
Arachnodactyly 340, 351
Arachnoiditis 158, 169
Arcus senilis 149, 439, 452
ARDS 15, 103, 104
Argyll Robertson pupil 179, 245, 450
Argyria 306
Arm-span 340, 341
Arrhythmia 315, 316
Arsenic toxicity 179
Arterial pulsation (neck) 41, 346
Arthritis
    rheumatic 34, 35
    rheumatoid 34, 202, 353
Asbestosis 61, 260
Ascites 265, 288
ASD 255, 256
Aseptic fever 323
ASO titre 34
Asterixis 104, 446
Asthma
    bronchial 95
    cardiac 14, 102, 103
Ataxia 294, 295
Atelectasis 259
Atherosclerosis 48, 149, 248, 317
Athetosis 465
Atrial fibrillation 12, 316
Atrial septal defect (ASD) 255, 256
Atrophy, muscle 166
Auscultation
    abdomen 111, 434
    chest 425
    cranium 483
    heart 418
Ausculto-percussion 109, 110, 268
Auspitz's sign 365
Austin Flint murmur 14, 40
Australia antigen 113, 114, 118, 119
Autoantibodies 384
Autonomic nervous system 135, 138, 245, 246, 250, 483
Azotaemia 194, 199

B

Babinski's sign 481. 482
Baggy eyelids 397
Bald tongue 432
Ballottement 277, 279, 286
Band keratopathy 439
Band test 384
Banti's syndrome 125, 291
Barrel chest 99, 423
Beau's line 352
Bed sore 161, 483
Beevor's sign 145, 161, 163
Bell's palsy 459
Bell's phenomenon 460, 462
Benign intracranial hypertension 153, 336, 391, 395, 456
Bernheim effect 50
Beta-blockers 406
Bile salts 310
Bimanual palpation 277, 279, 284
Biot's respiration 425
Bitot's spot 344
Black-out 36, 37, 98, 168, 262
Bladder functions 135, 144, 170
Blast crisis 218, 222
Bleeding disorders 371
Blood transfusion 216
Blue bloater 102
Blue nail 352
Body mass index (BMI) 343
Bornholm disease 72
Bouchard's node 352
Bounding pulse 319
Bowel sounds 111
Bradycardia 314, 325
Brady'lalia 182, 397, 398
Bradypnoea 98
Brainstem syndromes 146
Breath sounds 426
Breathing, types 97-99. 425
Broca's area 444
Bronchiectasis 260
Bronchitis, chronic 102
Bronchogenic carcinoma 90. 226, 262, 264
Bronchophony 92
Bronchopleural fistula 70, 72, 77
Bronchopneumonia 88, 103
Bronchopulmonary segments 261
Brown-Sequard syndrome 160, 486
Brudzinski's sign 136, 152
Bruit 25, 283, 483
Bubo 225
Budd-Chiari syndrome 124, 265, 282, 347
Build/built 3, 339
Bulbar palsy 297
Bull-neck 225, 404
Busulphan 222
Butterfly rash 382

C

Cachexia 342
Cafe-au-lait pallor 51
Cafe-au-lait spots 377
Calcinosis 379, 388
Calciphylaxis 388
Calf muscles 473, 474
Cancrum oris 236, 238
Cannon wave 322, 346, 347
Caput medusae 107, 121, 127, 435
Carbimazole 405
Carbon dioxide narcosis 10.4, 105
Carcinoma, stomach 110
Cardiac dullness 417, 418
Cardiac index 27
Cardiac output 27
Cardiac tamponade 321, 346, 347, 421
Carditis 33-35
Carey-Coombs murmur 14, 33
Caries spine 155, 156, 158, 170, 422, 484
Carotenaemia 308, 351, 397-399
Carotenoderma 308, 399
Carotid hemiplegia 141, 149
Carotid shudder 7, 28, 320
Carotid massage 315
Carpal tunnel syndrome 354, 398, 414, 415
Carvallo's sign 25, 45
Castell's method 285
Catacrotic pulse 318
Catatonia 167
Cauda equina lesion 163, 486
Cavernous sinus thrombosis 407, 456
Cavity, pulmonary 76, 92
CCF (RVF) 21, 50, 330, 331
Cerebellar pressure cone syndrome 154
Cerebello-pontine angle tumour 461
Cerebellum, functions 293
Cerebral oedema 153, 154
Ceruloplasmin 438, 439
Cervical rib 356, 358
Chaddock's sign 482
Charcot joint 484
Charcot's triad 440
Cheilosis 302, 344, 345
Chest
    inspection 55, 61, 424
    movement 66, 67, 424
    shape 422
Chest pain 36, 72, 73, 420, 429
Cheyne-Stokes respiration 98, 425
Child's criteria 128
Chloasma 360, 362
Chloroma 221, 407
Chloroquine 385
Cholestasis 309-311
Chorea 167, 464, 478
Choroid tubercle 231
Chvostek's sign 468
CIDP 176
Ciliospinal reflex 263, 448
Cirrhosis of liver 119
Claw hand 357
Claw foot 440
Clinodactyly 351, 389
Clofazimine 375
Clonus 476, 479
Clubbing 332

Coagulation disorders 368, 371
Coarctation of aorta 318
Coin sound 69, 76
Colchicine 381
Collapse, of the lung 60, 258
Coma 145, 154, 246, 399, 400, 442
Complete heart block 314, 322
Confrontation perimetry 455
Conjunctival reflex 463
Consciousness, levels 442
Consensual light reflex 451
Consolidation, of the lung 61, 87
Constipation 398
Continuous murmur 31, 49
Conus medullaris 161, 163
Cooley's anaemia 214, 290
Coordination 165, 293. 296
COPD 97, 99
Copper 438, 439
Cord compression 158, 160, 162, 168, 170
Corneal reflex 463
Cor pulmonale 101
Corrigan's pulse 39, 318
Corrigan's sign 39, 41
Cortical sensation 137, 485
Corticosteroid, therapy 78, 335, 336
Cough 54, 74, 103, 260, 262
Courvoisier's law 310
Crackles 100
Cranial nerves
  I 456
  II 454-456
  III, IV, VI 447-454, 457-459
  V 463, 471, 472, 477
  VII 145, 146, 433, 459-464
  VIII 458, 459
  IX, X, XI, XII 297-299, 432, 433, 471
Craniotabes 392
Cranio-vertebral anomaly 168, 404, 441
Cranium 136, 483
Cremasteric reflex 163
Crepitations 100, 428
CREST syndrome 349, 378, 380, 388
Cretinism 337
Crises (haemolytic) 213
Cryoglobulinaemia 305
CSF 390
CT scan 132, 153, 154, 233
Cullen's sign 107, 271
Cushing's disease 335, 410
Cushing's syndrome 335, 409
Cushing's triad 153
CVA 141, 147-152
Cyanosis 305
Cyanotic spells 254, 255
Cyst
  abdomen 277
  lung 76
Cysticercosis 387, 388

D

Dapsone 375
Dawn phenomenon 251
Deafness 459
Decerebrate rigidity 430, 442
Decorticate rigidity 430, 442
Decubitus 3, 99, 429, 487
Defeminisation 410
Dehydration 345
Dementia 441, 443
de Musset's sign 39
Depressed, bridge of the nose 395
D' Espine's sign 263
Dextrocardia 21, 22, 42, 75, 417, 418
Dextroversion 21, 22, 42, 75
Diabetes mellitus 177, 178, 239
Diaphragmatic palsy 84
Diastolic shock 23, 32, 416
Dieulafoy's lesion 126
Digitalis 26, 27
Digital index (clubbing) 332
Dinner-fork deformity 167, 464
Diplegia 140, 157
Diplopia 448, 453, 457
Dipping method, palpation 284, 285
Dissection of aorta 76
Dissociated sensory loss 486
Divarication, recti 108, 267
Dix-Hallpike's test 458
DLE 382-383
Dock's sign 318
Dorsal (posterior) column 176, 295, 296
DOTS 79
Down's syndrome 389
Drug fever 328
Duchenne muscular dystrophy 472-475
Dupuytren's contracture 122, 247, 352, 357
Duroziez's murmur 39
Dwarfism 337
Dynamic manoeuvres, cardiology 46
Dysarthria 293, 297, 299, 443, 445
Dysdiadochokinesia 294
Dyskinesia 431, 465, 466
Dysmetria 293
Dyspepsia 106
Dysphasia 443, 444
Dysphonia 443, 445
  Dyspnoea 15, 24, 37, 38, 69, 73, 96, 97, 429
Dyssynergia 293
Dystonia 466
Dysuria 187

E

Ear lobe crease 17, 149, 396
Ears, low set 17, 396
Ecchymosis 368, 371
Ectopics 315, 316
Eisenmenger's syndrome 257, 306, 333
Ejection click 28
Ejection fraction 27
Elephantiasis 232
Emaciation 341
Emergency, endocrine 406
Emphysema 99, 423

Empyema
necessitatis 60, 424
thoracis 59, 62. 86
Endocarditis 33, 51, 383
Endocrine system 400
Enophthalmos 408, 448, 451
Enteric fever 291, 327
Entrapment neuropathy 414, 415
Epistaxis 370
Erb's point 418
Erb's sign 468
Erectile dysfunction 246
Erythema nodosum 386
Erythema nodosum leprosum 374, 387
Erythroderma 365
ESR 35
Eunuchoidism 340, 341
Ewart's sign 421
Exophthalmos 406
Extensor plantar 481
Extrahepatic obstruction (EHO) 123, 125
Extrapyramidal system 146, 184
Extrasystoles 315, 316
Exudate 58, 66, 271
Eye, examination 58

F

Facial palsy 459
Facies
acromegaly 413
Bell's palsy 459
cretinism 337
Cushing's syndrome 409
definition 336
dehydration 345
elfin 29
examination 337, 447, 462
hepatic 122
leonine 373
malar flush 10
masked 181, 183, 378, 396, 462
mitral 10
mongol 389
mongoloid 211
moon 335
myotonia 470
myxoedema 396
nephritic 189
nephrotic 195
parkinsonism 181
plethoric 362
polycythemia 304
scleroderma 378
SLE 382
tabetic 449
tetanus 469
thalassaemic 211
thyrotoxic 403, 406
Fainting 37
Fallot's tetralogy 253-255
Family history 5
Fasciculation 431, 466
Fatty acids, essential 344
Febrile convulsion 328
Feil's triad 169
Felty's syndrome 292
Fetor hepaticus 121
Fever, types 223, 235, 326
Fibrillation 466, 467
Fibrosing alveolitis 259
Fibrosis, of the lung 62, 258
Fibroth'orax 62
Filariasis 232, 329, 331
Finger, deformities 351
Finger flexion jerk 477
Finger-nose test 293
Flaccidity 140, 167
Flapping tremor 128, 446
Flexor spasm 157, 158, 162, 166
Fluctuation, clubbing 332
Fluid thrill 266, 267
Fontanelle 390, 395, 483
Foot drop 180
Fractional test meal 110
Fremitus, over chest 74
Friction fremitus 74, 428
Friedreich's ataxia 440
Friedreich's sign 348
Froin's syndrome 171
Froment's sign 355
Frontal bossing of skull 395
Fundoscopy 454, 456
Fundus 456
Funnel chest 423
'Funny turns' 168

G

Gag reflex 297, 299
Gait 183, 294, 474, 487
Gallavardin's phenomenon 28
Gall bladder lump 280
Gallop rhythm 20, 45
Gasping respiration 98
Gastric carcinoma 109, 110
Gastric outlet obstruction 109
G. B. syndrome 160, 180
Gegenhalten phenomenon 167
General survey 3
Gibbus 61. 161, 260, 422, 484
Gigantism 339, 414
Glabellar tap 183, 443
Glasgow coma scale 442
Glossitis 302, 303, 432
Glucocorticoids 412
Goitre 397, 401
Gordon's reflex 482
Gottron's sign 353
Gout 388
Gowers' sign 474
Gradenigo's syndrome 454
Graham Steell murmur 23, 43
Graphaesthesia 486
Grasp reflex 443
Graves' disease 400-406
Grocco's triangle 62

Groping reflex 443
Guaiac test 127
Gum
bleeding 370
hypertrophy 370
Gynaecomastia 120, 350, 358, 373

H

Haematemesis 91, 126-128
Haematinics, serum 342
Haematochezia 106, 127
Haematomyelia 158, 168
Haematuria 187, 191, 192
Haemochromatosis 214, 361, 362
Haemoglobinuria 191
Haemolysis 211, 213, 214. 309, 31 1
Haemophilia 371
Haemoptysis 13, 54, 91
Haemorrhagic spots 368
Haemosiderosis 214
Haemothorax 58
Halitosis 55, 107, 433
Hallpike's test 458
Hamman's sign 70, 421
Hand
acromegaly 413
anaemia 300
general examination 58, 351
diabetes mellitus 248
leprosy 353, 374
rheumatoid arthritis 353
SBE 51
scleroderma 352, 353, 378
SLE 352, 353, 382
Handshake 351
Hansen's disease 372
Harrison's sulcus 393, 423
Head circumference 392
Head tilt 293, 454, 488
Heartburn 106
Heart failure 20, 21, 50, 193, 330, 331
Heart, position 22
Heart sounds 10. 11, 21, 23, 32. 44-47, 416
Heberden's node 352
Heel-knee test 296
Heel-pad thickness 414
Hemiballismus 465, 466
Hemiplegia 138
Henoch-Schonlein purpura 354, 368, 369
Hepatic amoebiasis 115
Hepatic encephalopathy 128, 129, 133
Hepatic pre-coma 128
Hepatitis
acute 112-119
anicteric 115
cholestatic 116
chronic 116
fulminant 129
relapsing 114, 115
Hepato-cellular failure 117, 121. 122, 129, 130, 133, 134, 350
Hepato-jugular reflux 6, 263, 347
Hepato-pulmonary syndrome 131
Hepato-renal syndrome 132, 194
Hepatosplenomegaly 280
Hereditary disorders 209
Herpes labialis 327
Hess' capillary test 370
High arched palate 395. 441
Hill's sign 39, 40
Hippus 451
Hirsutism 409. 410
History taking 4-6
Hoarseness, voice 397
Hodgkin's disease 223, 227-231, 233
Hoffmann's sign 477. 482
Homocystinuria 340. 341
Honeycomb lung 71, 261
Hooking method, palpation 284
Hookworm infestation 303
Hoover's sign 99, 489
Horder's line 51, 352
Horner's syndrome 169, 262. 263. 401. 447-450
Hughes' syndrome 150, 385
Hung-up reflex .398, 464, 478
Hydatid thrill 277
Hydrocephalus 390
Hydropneumothorax 80
Hydrothorax 58
Hyperacusis 461-463
Hypercalcaemia 469
Hypercapnoea 104
Hypercholesterolaemia 199
Hypermetabolic state 219
Hyperoestrogenaemia 122, 349
Hyperpigmented spots 360
Hyperpnoea 98, 99
Hyperpyrexia 322, 323
Hyperreflexia 478
Hypersplenism 287
Hypertelorism 17, 211, 389, 395, 452
Hypertension 50, 149
Hypertensive encephalopathy 50, 141, 149, 193
Hyperthyroidism 400
Hypertonia 167
Hypertrophic osteoarthropathy (HOA) 332
Hyperventilation 98, 99
Hyperviscosity syndrome 124, 305, 381
Hypervitaminosis 394
Hypoalbuminaemia 237, 344, 469
Hypocalcaemia 468, 469
Hypocapnoea 104
Hypoglycaemia 246, 249
Hypomelanosis 367
Hypopigmented spots 360, 367, 376
Hyposplenism 287
Hypotelorism 396
Hypotension, postural 246
Hypothenar muscles 355
Hypothermia 322, 323, 399
Hypothyroidism 396
Hypotonia 166, 167, 293, 464

Hypoventilation 99
Hypoxia 104, 105
Hypoxic spells 254, 255

I
Idioventricular rhythm 314
Immune thrombocytopenic purpura 368, 369
Impotence 246
Incontinence 171
Increased intracranial tension 135. 144, 153, 154
Indian childhood cirrhosis 130
Infectious mononucleosis 232
Inspection
abdomen 107, 270-271
chest 55. 61, 424
heart 7
Insulin resistance 252. 343
Intelligence, assessment 442
Intercostal suction 55, 61, 90, 99
Intermittent claudication 6, 13, 139
Internal capsule 147
Intracranial pressure 391
Intrapleural pressure 60, 70, 71
Involuntary movements 464-466
Intelligence quotient (IQ) 442
Iron deficiency anaemia 302. 303
Iron overload 214
Itch (pruritus) 363
IVC obstruction 264, 436, 437
IVC syndrome 264

J
Jaccoud's arthritis 34, 352
Janeway's spot 51, 351
Jaundice 308
Jaw jerk 298, 299, 472. 477
Jendrassik's manoeuvre 478
Jerks 476
Joffroy's sign 407
Joint-position sense 176, 295, 485
Jones criteria 33
Jugular veins 3 , 6 , 345
JVP 346

K
Kala-azar 234, 290. 361
Kerley's B lines 16
Kernig's sign 136. 152
Ketoacidosis 243, 244, 246, 249, 251
Kidney 279. 286
K-F ring 123, 437
Klinefelter's syndrome 340, 341
Koebner's phenomenon 365
Koilonychia 302, 334. 335, 352
Korotkoff sounds 39
Kronig's isthmus 83, 84
Kussmaul's breathing 98, 99, 193, 250
Kussmaul's sign 347, 348, 421
K-W syndrome 196, 247
Kyphosis 422, 423

L
Lactulose 133
Lacunar infarction 141
LAF (left atrial failure) 50
Lahey's method 401
LAP score 219
Laryngeal oedema 99, 306
Laryngismus stridulus 96. 469
Lasegue's sign 153
Latent jaundice 308
Lateral column 176
Lathyrism 158, 168, 169
Leg ulceration 248
Lepra reactions 374
Lepromin test 374
Leprosy 179, 353, 356, 357, 372
Leriche's syndrome 13, 16
Leuconychia 344, 350, 353
Leucostasis 220
Leukaemias
acute 221, 231. 291
aleukaemic/subleukaemic 219
chronic lymphatic 218, 231, 291
chronic myeloid 217, 291
Leukaemoid reaction 219
Lhermitte's sign 179, 296
Libman-Sacks endocarditis 24. 53, 383
Lid retraction 407, 452
Light reflex 451
Light's criteria 66
Lipaedema 331
Lipid profile 154. 248, 250
Lipomastia 358
Liver 280-285
Liver abscess, amoebic 115
Liver, carcinoma 115, 130, 131, 282, 283
Liver dullness 83, 285
LMN palsy 140
Lock jaw 469
Locomotor brachialis 7, 39, 141, 149, 317
Locomotor system 201
Loose-jointedness 353
Lordosis 423
Lovibond's angle 332
Lumbar canal stenosis 13
Lung abscess 88, 92
Lung injury, acute 15, 104
Lunula, colour changes 352
Lutembacher's syndrome 12
LVF 20, 50. 193
LVH 20, 29
Lymph nodes 223-227, 230. 231
Lymphadenopathy 63, 227, 230, 231, 288
Lymphoedema 329
Lymphoma 222, 291

M
Macewen sign 390
Macroangiopathy 249
Macroglossia 292, 337, 389, 413, 431
Macule 366
Maculopathv 245

Madarosls 373, 396
Main d' accoucheur 468
Malar flush 10
Malaria 290
Malignant hypertension 50
Malnutrition 342
Mammary souffle 49
Marfan's syndrome 340, 341
Mass reflex 157
Mastication, muscles 471
Matting, lymph nodes 225
MCTD 380
Mediastinal shifting 75
Mees' line 352
Megavitamins 394
Meig's syndrome 58, 59, 265, 271
Melaena 125-127
Melasma 362
Memory, testing 441
Menace reflex 183, 455, 463
Meningism 152
Meningitis 152
Mental retardation 442
Mesocardia 22
Metabolic syndrome 252
Microalbuminuria 198, 247
Microaneurysm 245
Microangiopathy 249
Microglossia, 431
Micrognathia 414
Midclavicular line 275
Millard-Gubler syndrome 146, 462
Miller-Fisher syndrome 160
Mimic palsy 461
Mini-mental state examination 442
Miosis 448, 450, 451
Mitral incompetence 19, 44
Mitralisation 16
Mitral stenosis 8, 44
Mitral valve prolapse syndrome (MVPS) 24
Mongolism 389
Mononeuritis multiplex 177
Monoplegia 140, 147, 151
Motor neurone disease 467, 468
Movement disorders 184
Muller's manoeuvre 428
Murmur 14, 25, 30, 31, 48, 49, 419
Murphy's kidney punch 279, 331
Murphy's sign 310
Muscles
    atrophy 166
    coordination 293, 296
    hypertrophy 473
    motor functions 165, 467
    nutrition 165. 166
    power 165, 474
    pseudohypertrophy 473
    sense 180, 485
    tone 165-167, 183
    wasting 355, 474
    weakness 165, 168, 474
Myasthenia gravis 447, 449
Mydriasis 449, 450
Myelodysplastic syndrome 220
Myelofibrosis 287, 292
Myelography 171
Myelopathy 157-162, 170, 178
Myeloproliferative disorders 288
Myelosclerosis 287, 292
Myerson's sign 183, 443
Myocardial infarction 36, 72, 430
Myocarditis 33
Myoclonus 465, 466
Myokymia 84, 466, 467
Myopathy 178, 472
Myotatic irritability 84
Myotonia 470
Myotonic reflex 398, 476
Myxoedema 396
Myxoma, atrial 14, 333

N

Naffziger's sign 407
Nail changes 352, 365
Nasal regurgitation 297, 299
NASH 125
Neck, examination 404
Neck rigidity 136, 152
Neck veins 345
Nelson's syndrome 412
Neoaortic area 40, 418
Neovascularisation 245
Nephritis, acute 189
Nephrotic syndrome 195, 330
Neurofibroma 376
Neuronopathy 167
Neuropathy
    autonomic 178, 245, 246, 250
    entrapment 415
    peripheral 173
Nicotinic acid 344
Night blindness 344
Night sweats 230
Nocturia 187, 192
Nodal rhythm 314
Nodules 366, 372, 387
Non-cirrhotic portal fibrosis (NCPF) 125
Non-Hodgkin's lymphoma 223, 227-231, 234
Nose, saddle 378
Nutrition 341, 342
NYHA classification 24
Nystagmus 457

O

Obesity 343
Obstetric history 5
Obstipation 109
Obstructive airway disease 96, 97, 99
Occult blood test 127
Occupational history 5, 261
Oculogyric crisis 182, 184. 185, 459
Oedema 328, 335
Oliguria 192
Olliver's sign 49

On-off phenomenon 187
Onychodermal angle 332
Onycholysis 352, 365
Opening snap 9, 11. 47
Ophthalmoplegia 454
Opisthotonus 430
Oppenheim's sign 482
Opsoclonus 459
Optic atrophy 170, 456
Optic neuritis 456
Oral contraceptive pills 150
Oral hypoglycaemic agents 251
Orthocyanosis 307
Orthodeoxia 98
Orthopnoea 97, 98
Ortner's syndrome 16
Osier's node 51, 352
Osteogenesis imperfecta 306, 396
Ovarian cyst 268-270, 277
Oxygen, therapy 105

P

Pachydermoperiostitis 332, 373
Pack years 261
Pain
    abdomen 430
    chest 36, 72, 73, 420, 429
Pallor 3, 208, 300, 397
Palmar erythema 350
Palmo-mental reflex 443
Palpation
    abdomen 107, 275, 276, 280, 284
    chest 55
    heart 7, 416
    kidney 279, 286
    liver 280-284
    spleen 284-289
Palpitation 43
Pancarditis 33
Panniculitis 382, 386, 388
Papilloedema 50, 456
Papule 366
Paracentesis
    abdominal 273, 274
    thoracic 64, 65
Paraplegia 155, 212, 230
Parasternal heave 7, 42, 416
Parkinsonism 181
Parkinsonism-plus syndrome 185
Parosmia 457
Parotids, enlarged 122
Past history 4
Patent ductus arteriosus (PDA) 49, 257
Pectus carinatum 422, 423
Pectus excavatum 422, 423
Pedigree chart 5
Pel-Ebstein fever 223, 324
Pellagra 344
Pemberton's sign 402
Penicillamine 439
Peptic ulcer 110
Perceptual rivalry 486
Percussion
    abdomen 83, 108, 267-269, 285
    chest 72, 80-83, 285
    heart 417. 418
    mediastinum 408
    myokymia 84
    skull 390
    sternum 416
Pericardial effusion 62. 421
Pericardial knock 348
Pericarditis
    acute dry 420, 421
    chronic constrictive 346, 347, 348
Periodic fever 324
Periorbital oedema 335
Peristalsis 111, 433, 434
Peritonitis 111, 271, 430
Peroneal sign 469
Personal history 5
Pes cavus 440
Petechiae 288, 368
Peutz-Jeghers syndrome 360, 362
Phakomatosis 377
Phalen's test 415
Phantom tumour 63
Phase reactors 35
Philadelphia chromosome 219, 221
Phlegm 75
Phrenoderma 344, 351
Pica 302, 303
Pigeon chest 393, 422, 423
Pigmentation 360
Pink puffer 102
Pin-point pupil 450
Pitch, murmur 419
Plantar equivalence 482
Plantar response (reflex) 480
Platypnoea 98
Pleural effusion 56. 85
Pleurisy 69. 428. 429
Pleurodesis 68, 77
Plexopathy 167
PND 14
Pneumatocele 93
Pneumaturia 187
Pneumonia 87
Pneumothorax 68
Poliomyelitis 474, 475
Polycythemia 287, 288, 291, 304, 306, 307, 350
Polydipsia 243, 244
Polyphagia 243, 244
Polythelia 7
Polyuria 187, 192, 243
Ponderal index 343
Portal hypertension 121, 123, 124, 127, 131, 132. 133, 134, 436, 437
Portal vein thrombosis 123, 131

Posterior column 176, 295, 296, 484
Posterior spinal syndrome 486
Post-tussive suction 92
Postural hypotension 246
Prayer sign 248
Pre-coma, hepatic 128
Precordial catch 73
Precordium 8, 9, 21
Pre-diabetes 243
Premature beats 315, 316
Pretibial myxoedema 402, 405
Procoagulant states 150
Progeria 3, 337, 339
Prognathism 413, 414
Proprioception 137, 176, 296, 485
Proptosis 406-408
Prosthetic valve 18, 19
Proteinuria 195, 198
Pruritus 227, 309, 310, 363
Pseudobulbar palsy 297-299
Pseudoclonus 479, 480
Pseudoclubbing 334
Pseudohypertrophy 473
Pseudohypoparathyroidism 337, 339
Pseudolymphoma 230
Pseudoptosis 447, 448
Pseudotumour cerebri 336, 391, 456
Psoriasis 365
Ptosis 447
Puddle sign 268
Pulmonary hypertension 9, 23
Pulmonary oedema 14, 15
Pulmonary thromboembolism 72, 73, 76, 91, 101
Pulsatile liver 282
Pulsation
    carotid 39, 41
    epigastric 42
    hepatic 282
    suprasternal 41
Pulse 309, 313, 319, 325, 327, 402, 403
Pulse deficit 315, 316
Pulse pressure 316, 319
Pulsus alternans 20, 319, 321
Pulsus bigeminus 321
Pulsus bisferiens 47, 320
Pulsus paradoxus 319, 321, 348, 421
PUO 325
Pupil 449-452
Purpura 368-371
Purse-lip respiration 99, 101, 102, 425
PUVA therapy 366
Pyloric stenosis 109
Pyopneumothorax 85
Pyramidal tract 146, 147
Pyrexia 322
Pyridoxine 345

9

Quadrate skull 392, 396
Quadriplegia 168
Quantiferon test 65
Queckenstedt's test 171
Quetelet index 343
Quincke's sign 39

R

Radiculopathy 179, 356, 478
Radio-femoral delay 313, 317
Radio-radial delay 317
RAF (right atrial failure) 50
Ramsay Hunt syndrome 462
Rappaport's classification, NHL 228
Rash 326
Raynaud's phenomenon 305, 353, 354, 378, 380, 381
Rebound phenomenon 294
Rebound tenderness 108
Recurrent laryngeal nerve, palsy 262, 263
Reed-Sternberg cell 229, 233
Reflexes, deep 476
Reinforcement 478
Released reflexes 443
Renal angle 108, 188, 279
Renal failure
    acute 190, 193
    chronic 199
Renal lump 279, 280, 286
Renal vein thrombosis 197
Respiration 55, 85, 97-99, 327, 425
Respiratory depression 99, 306
Respiratory failure 103, 104
Respiratory paralysis 299
Reticulocyte index 304
Reticulosis 223
Rheumatic fever 18, 33, 34, 38
Rheumatoid arthritis 34, 202-207, 352, 353
Rhonchi 100, 101
Riboflavin 344
Rickets 392
Rickety rosary 393, 423, 424
Riedel's lobe 284
Rifampicin 375
Rigidity 167, 183, 184, 186
Rigor 324
Ringworm 367
Rising test 161, 276
Romberg's sign 138, 179, 294-296, 488
Root lesion 179
Root of the lung 81
Root pain 155, 160, 162, 170, 179
Rosacea 382
Rose spots 349
Rossolimo's sign 482
Roth spot 17, 51, 52, 53
RPGN 194
Rub
    hepatic 281, 283
    pericardial 419
    pleural 428
    pleuro pericardial 420, 422
    splenic 287
RVF (CCF) 21, 50, 330. 331
RVH 20, 29
Rye classification, HD 228

S

SAAG 273
Sabre tibia 396
Saddle nose 373
Sarcoidosis 225, 226, 232
Sarcopenia 342
SBE 51-54
Scabies 362
Scalene node 224. 226
Schamroth's sign 332
Schober's test 201
Scleredema 329, 380
Sclerodactyly 351, 378, 380
Scleroderma 305, 329, 334, 378
Scoliosis 422, 423
Seagull murmur 24, 51
Sensory extinction 486
Sensory functions 135, 137, 176, 484-486
Sensory loss, dissociated 486
Serum-ascites albumin gradient (SAAG) 273
Shifting dullness
    abdomen 267-269
    chest 80, 85
Short neck 169, 396, 484
Sialorrhoea 432, 433
Sideroblast 215
Simian hand 389
SinuSr abdominal wall 278
Sinus arrhythmia 315
Sinus of Valsalva, rupture 49
Sinus rhythm 314
Situs inversus 22
Skin
    itchy 363
    scaly 367
Skinfold thickness 342, 343
Skodaic resonance 60
Skull 483
SLE 232. 291, 382
Sniff test 85
Somogyi phenomenon 251
Spasticity 140, 167, 183
Spatula test 469
Speech 293, 443
Sphygmomanometer 322
Spider telangiectasia 349
Spina bifida 441, 484
Spine 161. 484
Spinothalamic tract 176, 485
Spleen 284-289
Splenectomy 215, 216, 221, 288
Splenosis 287
Splinter haemorrhage 51, 352
Spondyloarthropathy 205
Sputum 74, 75
Squatting 6, 8, 46, 254, 255, 429
Squint 452
Stance 487
Stature 339. 340
Status asthmaticus 97
Steatorrhoea 247, 309, 402
Steinberg's sign 340
Stereognosis 486
Sternal angle 83, 347
Sternal tenderness 217, 331
Sternomastoid sign 75
Steroid therapy 335, 336
Strabismus 452
Straight back syndrome 422, 424
Straight leg raising test 153
Strangury 187
Striae 107. 271, 409
Stridor 54, 96, 99, 262, 263
Strokes 141, 144, 145. 147-152
Subacute combined degeneration 179
Subarachnoid haemorrhage 141, 149, 150
Subclavian steal syndrome 142
Subcutaneous emphysema 70
Succussion splash
    abdomen 109, 110
    chest 80, 81
Suzman's sign 7, 42, 61, 318
SVC syndrome 261
Sweating 230
Syncope 37, 73
Syndactyly 17, 351
Syndrome X 252
Syphilis 179, 232
Syringomyelia 484, 486
Systemic lupus erythematosus (SLE) 382
S, 10, 11, 416
S_2 23, 32, 416
S_3, S_4 20, 21, 45-47, 416

T

Tabes dorsalis 179, 447, 449, 484, 486
Tabes mesenterica 278
Tachycardia 314, 325
Tachypnoea 98
Target cell 213, 216
Taste sensation 433, 461, 462
Telangiectasia 349, 368, 378, 379, 382, 383
Tenesmus 106
Tensilon test 449
Tetany 393, 468, 469
Tetralogy of Fallot 253-255
Thalassaemia 208, 290
Thenar muscles 355
Thermometer, clinical 322, 323, 325, 328
Thickened pleura 61
Thoracentesis 64, 65
Thready pulse 317
Thrill 30, 42, 416
Thrombasthenia 368, 371
Thrombocythemia 370
Thrombocytopenia 368-371
Thrombocytosis 370
Thrombo-embolism 148, 150
Thyroid gland 401
Thyroid storm 406
Thyrotoxicosis 403, 405, 406
TIA 151
Tics 465

Tidal percussion 63, 84
Tinel sign 415
Titubation 293, 294, 446
Todd's palsy 139
Tone 165, 166, 167, 183
Tongue, examination 303, 431
Tophi 387, 388
Tourniquet test 370
Trachea 60, 75
Tracheal tug 7, 49, 99
Trail's sign 75
Transudate 58, 66, 271
Transverse myelitis, acute 158, 159, 162, 172
Traube's sign 39
Traube's space 62, 63, 83, 110
Treatment history 5
Tremor 128, 182, 293, 403. 445
Tricuspid incompetence 25
Trlopathy 249
Trismus 323, 469
Troisier's sign 110, 226
Trophic ulcer 357, 358, 483
Tropical eosinophilia 102
Tropical spastic paraplegia 158, 169
Tropical splenomegaly syndrome 287, 291
Trousseau's sign 110. 322. 352, 468
Tuberculosis
    abdominal 275, 278
    miliary 231, 292
    pulmonary 78, 79, 260
Tubular vision 455
Turner's syndrome 337, 338
Two fingers' test 277
Tylosis 351
Typhoid state 327

U

Ulnar nerve palsy 356, 357
Ultrasonography 132, 233
Umbilicus 107, 266, 269, 270
UMN palsy 140, 145
Urinary bladder 170, 270, 277, 278
Urine, red 191

V

Vagolytic procedures 315
Vagotonic procedures 315
Valsalva manoeuvre 46, 315, 427, 435, 436
Vasculitis 177, 354, 358, 379, 386
Venous Corrigan 347
Venous flow 436
Venous hum 46, 49, 302, 434
Venous pulsation (neck) 346
Venous star 349
Ventricular septal defect (VSD) 25, 253, 256
Vesicle 363, 366
Vibration sense 248, 485
Viral hepatitis 112
Virchow's gland 110, 224, 226
Virilisation 410
Vision, tubular 455
Visual field 454, 455
Vital signs 313
Vitamins
    A 344, 394
    B_2 344
    B_6 345, 394
    B_{12} 179
    C 369,394
    D 393,394
    E 395
    K 133, 385
    nicotinic acid 344, 395
Vocal fremitus 55, 74
Vocal resonance 92, 93
Voice, hoarse 396, 397
von Graefe's sign 407
von Recklinghausen's disease 376, 377
VSD 256

W

Waist-hip ratio 343
Waldeyer's ring 226, 227, 229
Wartenberg's sign 477
Wasting, small muscles of hand 355
Water-hammer pulse 319
Water-seal drainage 77, 86
Weakness, generalised 168
Weber's syndrome 146
Weight gain 344
Weight loss 223, 235, 342
Wheeze 54, 95, 96
Whisper test 459
Whispering pectoriloquy 92
Wilson's disease 130, 437-439
Winging of the scapula 55, 61, 424
Wrist drop 358
Wrist sign 340

X

Xanthelasma 48, 149, 309, 388, 398
Xanthochromia 171, 172
Xanthoma 388
Xerophthalmia 344
Xerostomia 433
X-linked disorders 473

Y

Y-descent in JVP 347, 348
Yellow nail syndrome 58, 353
Y-linked disorders 473
Young strokes 149

Z

Z-deformity of thumb 352. 354
Zieve's syndrome 125, 128

Key Features of the Book

- An ideal book to recapitulate medicine before examination
- Questions and answers format with oral and practical orientation
- Model long, short and spot cases along with differential diagnosis, relevant investigations and management with stress on core topics
- Expanded coverage on clinical methods in medicine
- A concise, lucid, revised and updated ready-reckoner in medicine
- A uniquely accessible portable guide for ward and clinic

About the Author

Professor Arup Kumar Kundu has been working as an internist for nearly 25 years and is renowned for his sharp clinical acumen, analytical approach and clarity of expression towards solving different problems in internal medicine. He is vibrant and innovative in his field, and has multifaceted personality. Dr. Kundu, an astute clinician and a dedicated teacher, has been teaching medicine to students, both undergraduates and postgraduates, and has been an examiner in different Indian Universities. He is well-known all over the country for his proficiency as an illustrious teacher in medicine. Dr. Kundu, a brilliant academician and an avid medical writer, has authored three other indispensable books entitled 'Bedside Clinics in Medicine, Part II', 'MCQs in Internal Medicine' and 'Pearls in Medicine for Students'. He is a gifted orator and has been invited as speaker / faculty in different State and National conferences. He has taken part in International symposia / seminars, and is credited with more than 80 publications in peer-reviewed journals. Dr. Kundu has contributed constructive articles in National daily / weekly, interviews in AIR / Doordarshan for common people. He has written sections on online appendix of Kumar and Clark's textbook 'Clinical Medicine', both in the 6th and the 7th edition, and is an Indian member, International Advisory Panel of the 7th edition of the book. He has also contributed chapter in API textbook of Medicine, the 8th edition. Dr. Kundu, known all over as 'clinical scientist', has been conferred the fellowship of the Indian College of Physicians (FICP) and the membership of prestigious New York Academy of Sciences (USA)

ISBN : 978-93-80599-12-0

5 th Edition

Bedside Clinics in Medicine

Part II

X-ray ECG Charts Drugs Emergency Specimens Procedures & Instruments

Arup Kumar Kundu



Academic Publishers

“Do not waste the hours of daylight in listening to that which you may read by night. But when you have seen, read. And when you can, read the original descriptions of the masters who, with crude methods of study, saw so clearly.

To study medicine without books is to sail an uncharted sea, while to study medicine only from books is not to go to sea at all.”

Sir William Osier (18491919)
Professor of Medicine, Oxford, UK

QfyooAsby/Jm

Bedside Clinics in Medicine, Part I

Sixth Edition

Highly practical and informative handbook with expanded coverage on 'clinical methods in medicine' in questions and answers for MBBS/MD students with oral and practical orientation, which deals with : Model long, short and spot cases with differential diagnosis, relevant investigations and management with stress on core topics

Published by :

KSP Udyog, 64 College Street, Kolkata-700 073, India
e-mail : kshovanp@yahoo.com

MCQs in Internal Medicine

Third Edition

An indispensable revision tool for mastery in medicine with almost 2200 systematically arranged questions with single-choice answer covering major aspects of internal medicine, specially for UG students. It forms the foundation for success in different PG entrance examinations

Published by :

Paras Medical Publisher, Hyderabad-500 095, India
e-mail : parasmedpub@hotmail.com

Pearls in Medicine for Students

First Edition

A treasure island in medicine for medical students, which consists of short description of facts frequently encountered at the bedside. A quick-reference ready-reckoner handbook to increase the core knowledge during early years of medical training

Published by :

Jaypee Brothers Medical Publishers, New Delhi-110 002, India
e-mail : jaypee@jaypeebrothers.com

Author: Fellow/Member of

- **Indian College of Physicians (Ind)**
- **New York Academy of Sciences (USA)**
- **International Advisory Panel of "Kumar & Clark's" Textbook, 'Clinical Medicine', 7th Edition (Edinburgh)**
- **Association of Physicians of India (API)**
- **Indian Rheumatology Association (IRA)**
- **Indian Medical Association (IMA)**

BEDSIDE CLINICS IN MEDICINE

PART II

FIFTH EDITION

Instruments with Procedures, Specimens, X-ray, ECG, Charts, Drugs & Emergency Medicine

Arup Kumar Kundu MD FICP MNAS
Professor
Department of Medicine
&
In-charge, Division of Rheumatology
R. G. Kar Medical College, Kolkata
West Bengal, India

Author of:

Bedside Clinics in Medicine, Part I
MCQs in Internal Medicine
Pearls in Medicine for Students
Chapter in API Textbook of Medicine, 8th Edition
Chapter in Postgraduate Medicine, 2009
Chapters in 'Rheumatology : Principles and Practice', 2010
Chapter in Medicine Update, 2010
&
Section on Online Appendix of "Kumar & Clark's" Textbook, 'Clinical Medicine', 6th & 7th Edition

ACADEMIC PUBLISHERS
5A, Bhawani Dutta Lane
Kolkata 700 073, India
e-mail : info@acabooks.net
website : www.acabooks.net

Published by :

Kaustuv Paul
For KSP Udyog
64 College Street, Kolkata-700 073
Regd. Office : Flat No. S2W4, Bidhan Nibas
4 Bidhan Sishu Sarani, Kolkata-700 054, India
e-mail : kshovanp@yahoo.com

Distributed by :

Academic Publishers
5A, Bhawani Dutta Lane, Kolkata-700 073, India

BEDSIDE CLINICS IN MEDICINE, PART II

Copyright © 2010, Dr. Arup Kumar Kundu

First Edition : January 1999
Second Edition : September 2000
Third Edition : April 2003
Fourth Edition : August 2006
Fifth Edition : August 2010

ISBN : 978-93-80599-22-9

All rights reserved. This book is protected by Copyright Act. No part of this publication in general may be reproduced or transmitted, in any form or by any means, electronic, mechanical, photocopying, recording or any information storage and retrieval system, without the prior written permission of the author and the publisher. Breach of this condition is liable for legal action. In case of any dispute, all legal matters are to be settled under Kolkata Jurisdiction only

Typesetting, processing and printing done by :

Abhinaba Mudrani, 77/1 Simla Street, Kolkata-700 006, India

Cover design and colour processing done by :

Cosmos Graphics, 71/1A Patuatola Lane, Kolkata-700 009, India

Price : Rs. 325.00

Dedicated to my mother

Smt. GOURI RANI KUNDU

Who showed me the light of this world

A few personal communications with Giants of Medicine

in

From : (Regarding an error in renal clearance test)

Dr. John Macleod
13 Merchiston Avenue
Edinburgh, Scotland, EH 10 4PJ

13/7/83

Dear Dr. Kundu,

. It was good of you to take the trouble to write to me about the 13th edition of Davidson.

Thank you for your kind comments.

You are of course, correct about the typographical error on page 428. It should have been C = U x V / P; the printer omitted the division sign. This is now being adjusted.

Again many thanks for writing.

With best wishes,

Yours sincerely

Sd/ **John Macleod**

(**2**)

From : (Regarding errors in serum-ascites albumin gradient)

Kurt J. Isselbacher, M.D.
Director, Massachusets General Hospital Cancer Center, Boston
Mallinckrodt Professor of Medicine, Harvard Medical School
Editior : Harrison's Principles of Internal Medicine, 13th Edition

February 23, 1998

Dear Dr. Kundu,

I must commend you for your astute and thorough reading of the Harrison's textbook and in addition, thank you for pointing out two obvious typographical errors. In fact, this was already done in the second printing of the 14th edition.....

Again, many thanks for your thoughtfulness in bringing these two typographical errors to our attention.

Sincerely,

Sd/ **Kurt J. Isselbacher**

(3)

From : (Regarding erythema nodosum, & pulmonary stenosis)

Keith A A Fox
Duke of Edinburgh, Professor of Cardiology and Head of Department
Cardiovascular Research Unit, The University of Edinburgh
Hugh Robson Building, George Square, Edinburgh EH8 9XF

5th December 1995

Dear Dr. Kundu,

Re : Davidson's Principles and Practice of Medicine : 17th Edition 1995

On behalf of Editors of this textbook I have been asked to respond to you in view of the fact that this chapter was written by Dr. Boon and myself.

In response to your first question we have obtained source material which indicates erythema nodosum is a manifestation of acute rheumatic fever.

In conjunction with pulmonary stenosis, the only reason why the thrill may be best palpated in expiration is because of the fact that the heart moves closer to the anterior chest wall. We entirely agree that the velocity of blood flow across the pulmonary valve is increased in inspiration and this is demonstrated using echo Doppler techniques. However, for the reasons mentioned above palpation of thrill may be more obvious in held expiration when the heart and vessels are closer to the chest wall. I hope that these comments help to clarify the situation.

Yours sincerely

Sd/ **Keith A A Fox**
Professor of Cardiology

(4)

From: (Regarding contribution in "Kumar & Clark's" textbook on Medicine)

Ellen Green
Senior Commissioning Editor
Elsevier, 1 -3 Baxter's Place
Leith Walk, Edinburgh EH1 3AF

23/6/2005

Dear Dr. Kundu

Firstly, **on behalf of Kumar & Clark,** I would like to thank you for your contributions to the Online Appendix for **Clinical Medicine 6e** ..... I hope you are pleased with the book..... Kind regards.

Sd/ **Ellen Green**

(5)

From: (Regarding some clinical methods & apex beat localisation)

Dr. J G Douglas
Chest Clinic, Clinic C
Aberdeen Royal Infirmary, Foresterhill
Aberdeen AB25 2ZN

2nd November 2005

Dear Dr. Kundu

ReJ: MacLeod's Clinical Examination, 11th Edition

Thank you very much for your recent e-mail..... 1 am an editor of this edition... I am responsible for writing much of the Respiratory Chapter and was most interested in your comments. In response:

Examining for Tracheal Shift..... Clearly this technique could also be performed with the patient standing or sitting.

Technique of Percussion - I entirely agree with your comment that to obtain the loudest percussion note ideally the other fingers, apart from the middle finger, should not touch the skin surface. Figure 4.19 is ambiguous and I will make a note of this for the next (12th) edition.

... **Vocal Resonance**..... However I agree that as written in the first paragraph of page 143 there is some confusion..... Again I will make a note to clarify this for the next (12th) edition.

Aegophony (page 144)..... However I agree that it's position is a little confusing and again I will make a note of this when redrafting the next (12th) edition.

Examination Sequence (page 97..... palpation of apex beat) - I entirely agree with you that the second half of the statement under the 3rd arrow: "If you cannot feel it, ask the patient to roll on to their left side" is incorrect and references the wrong figure! I will make sure this is removed at the next reprint.

We are enormously grateful to you for your attention to detail in pointing out these points.

With best wishes. Yours sincerely,

Sd/ **J G Douglas**

(**6**)

From : (A compliment from Chief Editor of Harrison's book)

Dennis L. Kasper, M.D.
William Ellery Channing Professor of Medicine and
Professor of microbiology and Molecular genetics
Harvard Medical School
Director, Channing Laboratory
Brigham and Women's Hospital, Boton, MA 02115
Editor : Harrison's Principles of Internal Medicine, 16th edition.

7/10/2006

Dear Dr. Kundu,

..... I very much appreciate your interest in contributing to Harrison's. I have looked up your publications on PubMed, and I can see that you are active and productive in your field..... and I wish you all the best in your ongoing studies and clinical practice.

Best regards,

Sd/ Dennis Kasper

(7)

From : (Regarding some queries on clinical medicine)

Laurence Hunter,
Senior Commissioning Editor, Elsevier

11/9/2008

Dear Dr. Kundu,

ReJ: Hutchison's Clinical Methods, 22 Ed

Once again I am most grateful to you for taking the trouble to contact us with queries about the content of this textbook. I shall pass on to the Editors the comments and ask them to take full account of these in the revision of the book.

Thank you once again for your interest in our publishing programme.

With all good wishes.

Sd/ Laurence Hunter

Preface to the First Edition

With the advancement of time, the subject of medicine is expanding astonishingly. It seems difficult for the undergraduate students to cope up with the mammoth subject. This compelled me to write a book dealing with model cases oriented to oral and practical examinations with special stress on elinical methods — the 'Bedside Clinics in Medicine, Part I'.

As radiology, electrocardiography, urine examination, instrumental procedures, emergency medical management and drugs are integral part of diagnosis and treatment, I feel obligated to my students to write a new book which deals with those subjects. I have tried to cover the subjects thoroughly to give a vivid idea on radiology, ECG etc., and to assist the students in economic and selective reading prior to final examination. Though basically meant for the undergraduates, the postgraduates and the practicing physicians will also be benefitted if they pry into it.

Bedside Clinics in Medicine, Part II would not have been completed had it not been for the patient understanding of our family, especially my wife Mrs. Bijoya Kundu who helped me throughout the making of this book, my parents, my daughter Ushasi and son Abhishek, who were deprived of their father's company for long long hours and days.

Finally, I am, really thankful to Mr. Kaustuv Paul of Crest Publishers for keeping me under constant pressure to write this new monograph, Mr. Kajal Saha for laying out the computerized drawings, and to the staff of Abhinaba Mudrani who have helped me in every step to complete the work. I also express my thanks to Dr. Sunetra Mukherjee, PGT in Radiodiagnosis and Dr. Sujoy Ghosh, PGT in General Medicine for providing me with X-ray plates. Healthy suggestions and constructive criticisms regarding the book will be highly appreciated and duly acknowledged.

In conclusion, I can not forget the constant encouragement given by my beloved students. I am greatly indebted to all of them.

Date : 1st January, 1999

Arup Kumar Kundu

"Trimurti"
BG-87, Sector-II, Salt Lake City,
Kolkata-700 091, India.

Preface to the Fifth Edition

I am delighted to write the preface of the fifth edition of Bedside Clinics in Medicine, Part II which has now received a total new-look. The overwhelming responses by eminent clinicians, hardcore academicians and encouraging reviews by different peer-reviewed journals have made me more enthusiastic to rewrite the book with updated clinical materials and data, while maintaining the style of presentation unaltered.

To write a book single-handedly is a challenging task, and I am fully aware of it. As radiology, electrocardiography, instrumental procedures, specimens, data analysis, different drugs and emergency medicine (that is to say the 'Table-works') are integral part of diagnosis and treatment, I felt obligated to my students to rebuild the book with current and comprehensive medicine. I clearly emphasize that this book is a companion to the text book and a reference manual to the undergraduates. I do expect and hope that the combination of clinical information, therapeutics and laboratory medicine is useful not only to undergraduates and postgraduates but residents and practicing physicians will also be highly benefited if they read the book thoroughly.

This monograph is a clear, concise as well as comprehensive reference to a busy clinican in need of immediate medical information.

To develop their practical recognition skills on some must know areas on the subject of medicine, the students are advised to read this manual in between lines. I expect that the book will help the students to face oral and practical examinations in a different way.

I wish to acknowledge Mr. Kaustuv Paul of KSP Udyog for publishing, Mr. Bimal Dhur and Mr. Dipankar Dhur of Academic Publishers for distributing, and Mr. Amar Nandy for printing the book with great personal care. Finally, a very special note of thanks should be delivered to my parents, wife Bijoya, daughter Ushasi and son Abhishek, and my beloved students for being enduring source of light, unfailing support and constant inspiration.

I welcome healthy suggestions, constructive criticisms and critical appraisal of the book from thoughtful readers through e-mail (arup kundu@hotmail.com).

Date : 15th August, 2010

Arup Kumar Kundu
"Trimurti"
BG-87, Sector-II, Salt Lake City,
Kolkata-700 091, India.
e-mail : arup kundu@hotmail.com

In their esteemed opinion about the book.....

- **"Your book is an excellent replicative educational medium for exam-going students. Congratulations.....**

» **"..... I am proud of you as you are a THINKER. May your tribe increase. Many students make you their role model. God will bless you always....." —Prof. B. M. Hegde, Ex-Professor & Dean of Medicine, Kasturba Medical College, Mangalore (Ex-Vice-Chancellor, MAHE University, Manipal).**

"... Dr. Kundu has brought out a book based on bedside clinics on 26 model long cases and 74 short and spot cases oriented to clinical and oral examinations with special stress on clinical methods.....He discusses the history, diagnosis, signs, differential diagnosis and management in the form of questions and answers. The answers are given in detail. ..... There is an exhaustive coverage of the subject and Dr. Kundu has to be congratulated for bringing out such a wealth of knowledge. This is not a text book but it contains a lot of information which the students are expected to know at the end of the clinical training.The book is very helpful to the students of clinical medicine while revising the subject before examination. Dr. Kundu has discussed the various questions which student may encounter during the examination and he has done it admirably". —Book review in Journal of the Association of Physicians of India (JAPI) by Dr. P. S. Shankar, Dean, K. J. Somiya Medical College, Mumbai.

".....Examinees who wish to anticipate routine questions and to avoid long embarrassing silences would do well to read these pages.....important points have received appropriate emphasis.....The text is closely written and the amount of information provided is truely gross. Every line and word has to be remembered....." —Book review (Part I) in Journal of the Indian Medical Association (JIMA).

"The monograph on Bedside Clinics in Medicine is very well written, studded with your long experience as clinical teacher. Such monograph was a long felt neerd. You have really done an excellent job. The monograph will be very well received not only by undergraduate and postgraduate students but by clinical teachers as well." —Dr. A. P. Jain, Professor & Head, Department of Medicine, M. G. Institute of Medical Sciences, Sevagram, Maharashtra.

"I highly appreciate the efforts, hard work and sincerity in bringing up this publication in a beautifully designed manner with rich clinical material inside". —Dr. S. B. Agarwal, Professor & Head, Department of Medicine, B. J. Medical College and Civil Hospital, Ahmedabad, Gujarat.

".....It is a poetry on Clinical Medicine." —Final year MBBS student, N.R.S. Medical College, Kolkata.

"..... I congratulate you for bringing out this book..... " —Dr. P. K. Rathor, P. G. trainee, M. K. C. G. Medical College, Berhampur, Orissa.

"....The book is good and very useful to undergraduates & postgraduates in Medicine ..... I shall continue to recommend your book.....congratulation to the author for his concentrated effort." — Prof. (Capt.) G. Nagaiah, Professor & Head, Department of Medicine, Thanjavur Medical College & Hospitals, Tamilnadu.

"..... I have gone through this book and found it most suitable for the students. 1 will definitely recommend this book to the students....." — Prof. (Dr.) D.K. Hazra, Director, Professor & Head, Department of Medicine, S.N. Medical College, Agra, Uttar Pradesh.

"..... Bedside Clinics in Medicine by Dr. Arup Kumar Kundu is a good book for undergraduate medical students. It is helpful for preparing for final MBBS Examination. Students can guess as what type of questions may be asked in the practicals..... " — Dr. B.T. Tukol, Professor of Medicine, K.M.C, Hubli, Karnataka.

".....is an excellent book for junior students in Medicine. This book, very simply written in a concised and rational manner will greatly help the undergraduate students to establish the foundation of Clinical Medicine with ease and confidence." —**Dr. P. C. Bhattacharyya, Ex-Professor of Medicine, Gauhati Medical College, Assam.**

".....it is just excellent. It is an ideal companion for both undergraduates and postgraduates during exam time....." —**Dr. Neelakantan V. and Dr. N. Parvathi Sulochana, Sundarapuram, Coimbatore, Tamilnadu.**

"The second revised edition of Bedside Clinics in Medicine contains information at one place which postgraduates in Medicine aspire to assimilate in order to learn art and science of Medicine. Really an excellent job by Dr. Arup Kundu". —**Dr. A. P. Jain, Professor** & **Head, Department of Medicine, M. G. Institute of Medical Sciences, Sevagram, Maharashtra.**

".....It is so nice that all clinical problems are completed in so small a volume.....". **—Dr. K. Gandhi, Assistant Professor of Medicine, Thanjavur Medical College, Tamilnadu.**

".....This is not a book but something more than that. This is self-explanative and could be one of the best books in the field of Clinical Medicine required for our students. The book is indispensable for not only undergraduates and postgraduate students but also for teachers and practitioners in Medicine as well. This book is a living Clinical Tutor". —**Dr. Kiranmoy Mitra, Ex-Assoc. Professor & Head, Department of Medicine, Burdwan Medical College and Hospital, West Bengal.**

"Your fascinating presentation of long cases and short cases in Medicine has attended our presence towards your book..... " —**R. Ravishankar and S. Gupta, Final year MBBS students, Thanjavur Medical College, Tamilnadu.**

"In keeping with the expanding horizon of medical sciences and the gallant gallops of a plethora of newly emerging methodologies, Dr. Arup. K. Kundu has very meticulously and ingenuously architectured his master creation Bedside Clinics in Medicine, Parts I and II. A purist pedagogue, a massive mentor, and an exemplary exponent engrossed with an expansive professional expertise and competency, he has probed deeply into several cases along with history, diagnosis and management invariably in an easy-to-understand question-answer form. This lucidity, sometimes in a literary, and mostly in a highly scientific manners, has made this work an invaluable medical contribution-cum-anthology for undergraduate and postgraduate students. Moreover a beginner may find it a crutch to have a naive rendezvous into this area of medicine. The diagnostic procedures and methodologies are nicely delineated. This book will be a constant concise companion for all, students and teachers alike, in different Indian Universities and Medical Colleges as this treasure will elicit the clinical spirit of approach from a modest conventional way to highly sophisticated method." —**Prof. (Dr.) C. R. Maity, Ex-Dean, Faculty of Medicine, Burdwan University; Principal, Burdwan Medical College, Burdwan, West Bengal (Ex-Director of Medical Education, WBMES, Government of West Bengal).**

"I happened to go through your book Bedside Clinics in Medicine ..... It was nice and quite interesting.....I can recommend the book to my students as a ready reckoner....." **—Dr. V. Venugopal, Professor of Medicine, Perundurai Medical College, Tamilnadu.**

"The book Bedside Clinics in Medicine, Part I and II is comprehensive with wide coverage of all systems and attractively produced..... it is informative and beneficial not only to the UGs/PGs, but also to the physicians." —**Col. A. S. Kasthuri, Professor and Head, Department of Medicine, AFMC, Pune, Maharashtra.**

".....I found that there is a wealth of information in the book which is difficult to get from other books.....you must have gone through several journals and the whole of encyclopedia of medicine.....Congratulation?." —**Dr. K. Ramachandran, Visiting Professor of Radiology, MG University School of Medicine, Gandhi Nagar, Kottayam, Kerala.**

"……I have been an ardent reader of both of your textbooks on clinical medicine, since the first day of my ward duty. To be very honest I have learnt more from your books than from…… " —Dr. Saif Omar, Internee, Katihar Medical College, Katihar, Bihar.

"…… many congratulations for writing an ultimate manuscript in medicine……" —Dr. Kamaalchand M, P.G. trainee in Pediatrics, JNMC, Aligarh Muslim University, Aligarh, Uttar Pradesh.

"…… Bedside Clinics in Medicine, Part 1 & Part II is a Treasure Island" for students of Medicine both undergraduates & postgraduates……The book has in fact satisfied the need of a long awaited reference book for examinee being complete by itself in all respects…. recommend this book strongly for students of medicine……" —Prof. (Dr.) P. R. Nath Barbhuiya (Retd.), Professor & Head, Department of Medicine, Silchar Medical College & Hospital, Assam.

"…… Bedside Clinics in Medicine, Part I, which is highly informative, well-written with latest additions …….. " —Dr. N. S. Neki, Associate Professor of Medicine, Government Medical College, Amritsar, Punjab.

"…… the joy of reading the book is so overwhelming that, by far, medicine has never seemed so pleasurable. It definitely provides so much of knowledge and information, that everytime I close the book after reading it, I do so with an extreme sense of happiness and confidence of knowing so much……It is unequivocal opinion that the book is outstanding and entirely removes the need to study multiple books in clinical medicine……For my final year exams …….. the questions that were asked during discussion were entirely based upon the facts given in your book. I just had to quote them to be appreciated by the examiners. I wish to explain my gratitude as a student of medicine for your valuable contribution which is unfathomable ……" —Dr. Keerthana Karumbaiah K, Internee, Bangalore Medical College, Bangalore, Karnataka.

"…… this 'made easy', if assimilated properly by the students, will help to learn many aspects of medicine……The chapters on radiological diagnosis and ECG interpretations will certainly help all concerned. Emergency tackling of different cases also, will help the young professionals……The book is likely to be well accepted and the second edition of the book supports that expectation."—Book review (Part II) in Journal of the Indian Medical Association (JIMA).

"…… its really the eighth wonder in the world. Looking back, recollecting my MD days, I repeat my words…….I owe you my MD."—Dr. Pradeep Kumar Shenoy C, Ex-clinical fellow and registrar. Department of Rheumatology, Manipal Hospital, Bangalore.

"…..I am very happy to inform you that I have got selected for MD……. I owe my success to your book, and your in time valuable suggestion and advice. You have been my behind the scene teacher and educator and inspiration……"—Dr. Bhushan Madke, student of Indira Gandhi Govt. Medical College, Nagpur, Maharashtra.

"….You have donated breath to me……"—Jagroop Singh, student of Guru Gobind Singh Medical College, Faridkot, Punjab.

"……I feel it is a very good book and very informative……"—Dr. George K. Chako (MD, PhD), PDH Hospital Group, Mumbai, Maharashtra.

"I am a final year medical student. I read your book on bedside clinical examination……. The book is really wonderful. Hats of sir……"—J. Mahammad Sadiq, Government Medical College, Salem, Tamilnadu.

"….I am highly impressed with clarity and concept of your book. The book is not only helpful for clinical exams but also for theory. The book is really a wonderful book……"—Ramchandra Chaudhary, student of S.R.T.R Medical College, Ambajogai, Maharashtra.

"Sir, its really great whatever you write, I have read your book in final year to clear exam, that helped very much to pass final prof..... "—Dr. Amit Sharma, (DM cardiology student), and passed MD (medicine) from KGMC, Lucknow, Uttar Pradesh.

"Bedside Clinics in Medicine by Dr. Arup Kundu is really nice to crash all the viva Q-A in your clinical viva.....also it helps to clear basics.....It teaches you how to think medicine" —in http://medcosmosbaroda.blogspot.com/2008_09_01 archive.html

A website in Vietnam, recommended this book as only clinical medicine book from Asia— www.ykhoavn.net/modules.php?name=Forums&file=viewtopic&p=7035-43k

Website in China (Weifang Medical University, Shandong, China) recommends this book for their students— www.xmail.net/wfmustudents/medicalbooks.htm

www.rxpgonline.com

- **"Medicine viva—by kundu; this comes in 2 volumes and is a must read stuff...."**
- **"Kundu is great for Symptomatology and specific exam cases... "**
- **"....go through a good clinical 'exam/cases book like Hutchinson and Kundu...."**
- **"Some important things you should know before entering clinics is given in Mcleods, Kundu clinical medicine. I think you can get these books and start off...."**
- **"....It is wonderful for all category of students whether average or brilliant one. It teaches you the basic medicine...."**

mciforchina. blogspot.com / 2008/ 08/ m-c-i-screening-test-books-syllabus. html-85k....recommended Bedside Clinics in Medicine, Part I & II for MCI screening test books for students passed lyiBBS from aborad.

www.medicalgeek.com (which book for clinical medicine?)

- **"....Arup Kumar Kundu—notes on all major, minor cases for exam...."**
- **"For clinical exam I read everything from Kundu part 1 and 2....never touched...even Dr. Arup Kumar Kundu was our external examiner....."**
- **"I would go for Kundu"**
- **"....for cases, Indian book—By Dr. Kundu....."**
- **"....you must buy Kundu..... "**

".....I m using Kundu.....all case wise clinical study is very fine..... I really like it...." in www.cafemedico.com

"..... also Arup Kundu if you want to dash answers in ward round cases. I would recommend Kundu as a must buy over and above one basic book like Hunter... " — www.aippg.net

"..... Favorite Medical Books: Guyton's Physiology & Kundu's Medicine_____ " in www.doctorshangout.ning.com/profile/DrMansi

"....Favorite medical books: Harrison's principle's of internal medicine, Kundu, de Gruchy, John Patten...." in www.doctorshangout.com/profile/PEUISHSUGATHAN

"I would like to meet : Harrison, Hutchison, Davidson, Kundu_____" in www.doctorshangout.com / profile /RAJESHARAHANT.

"I am a 4th year student at IMTU Dar Es Salaam Tanzania. I have seen one of book titled Bedside clinics in medicine. How can I get my copies....."—hance Mdunye, IMTU, Dar Es Salaam, Tanzania.

"....It is a well known fact among medical professionals, that your book on bedside medicine has proved to be a holy gift to the generations of medical students in this part of the world...."—Apildev Neupane, final year medical student at Institute of Medicine, Kathmandu, Nepal.

..... and many others from every nook and corner of the country.

CONTENTS

CHAPTER I : INSTRUMENTS AND PROCEDURES 1-63

Ryle's tube.....1
Tracheostomy tube..... 4
Simple rubber catheter.....6
Bone marrow aspiration needle.....9
Liver biopsy needle..... 12
Lumbar puncture needle.....15
I.V fluid bottle and infusion set.....22
Syringe (5 ml/50 ml)..... 28
Scalp vein set..... 31
Insulin syringe..... 32
Three-way cannula.....35
Oral rehydration salt.....36
The stethoscope.....39
Sphygmomanometer..... 40
Clinical thermometer.....45
Tuning fork.....46
Hammer.....48
Pin.....48
Cotton..... 49
Measuring tape..... 49
Tongue depressor..... 50
Torch..... 51
Plain glass test tube.....51
Condom.....52
Airway tube..... 53
Intracath..... 53
Metered dose inhaler.....54
Spacehaler..... 55
Proctoscope.....56
Ambu bag..... 57
Endotracheal tube.....57
Renal biopsy.....58
Paracentesis abdominis.....60
Thoracentesis.....61
Pericardiocentesis.....~..... 62

CHAPTER II : PATHOLOGY SPECIMENS 64-74

Lung.....!..... 64
Kidney.....67
Nervous system..... 70
Cardiovascular system.....70
Intestine.....72
Liver.....73

CHAPTER III : RADIOLOGY 75-114

X-RAY CHEST..... 75
Preface..... 75
Consolidation of the lung.....`.....80
Pleural effusion..... 80
Pneumothorax..... 82
Hydropneumothorax.....83
Emphysema.....83
Bronchiectasis.....84
Lung abscess..... 85
Homogeneous opacity of one hemithorax..... 87
Collapse of the lung..... 88
Fibrosis of the lung..... 88
Tuberculous infiltrations..... 89
Miliary mottlings..... 91
Mediastinal widening..... 92
Pulmonary oedema..... 94
Thoracic neoplasm..... 95
X-RAY CHEST-HEART..... 96
Mitral stenosis.....96
Pericardial effusion.....98
Enlarged cardiac shadow..... 99
STRAIGHT X-RAY OF THE ABDOMEN..... 100
Gas under the diaphragm.....100
BARIUM STUDY..... 101
Duodenal ulcer..... 102
Gastric ulcer.....102
Oesophageal carcinoma..... 103
Cardiospasm..... 104
Pyloric stenosis.....105

X-RAY OF SKULL..... 106
Multiple myeloma..... 106
Thalassaemia..... 108
Miscellaneous skull X-rays..... 108
X-RAY OF HANDS..... 109
Scurvy..... 109
Rickets.....HO
Miscellaneous hand X-rays..... Ill
A SYNOPSIS OF CT SCAN.....112

CHAPTER IV : ELECTROCARDIOGRAPHY 115-149

INTRODUCTION AND BASIC PRINCIPLES.....115
DETERMINATION OF AXIS..... 116
ROTATION AND LIE.....118
DIFFERENT WAVES, COMPLEXES AND INTERVALS.....119
HYPERTROPHY PATTERNS..... 126
Atrial hypertrophy.....126
Left ventricular hypertrophy..... 126
Right ventricular hypertrophy..... 126
Chronic cor pulmonale..... 127
Acute cor pulmonale.....128
MYOCARDIAL ISCHAEMIA AND INFARCTION.....128
Angina pectoris.....128
Acute myocardial infarction..... 129
DISORDERS OF RHYTHM..... 130
Sinus arrhythmia..... 131
Sinus tachycardia..... 131
Sinus bradycardia.....131
Supraventricular premature beats.....132
Paroxysmal supraventricular tachycardia.....132
Atrial fibrillation.....133
Atrial flutter..... 134
Ventricular premature beats..... 134
Ventricular tachycardia..... 135
Ventricular fibrillation..... 136
Ventricular flutter.....136
INTRAVENTRICULAR CONDUCTION DEFECTS.....137
Right bundle branch block (RBBB).....138
Left bundle branch block (LBBB)..... 138
Bifascicular block.....139
Trifascicular block.....140

ATRIOVENTRICULAR (AV) CONDUCTION DEFECTS..... 140
First degree heart block.....140
Second degree heart block.....141
Complete heart block..... 142
HEART BLOCK.....143
MISCELLANEOUS..,.....143
W-P-W syndrome.....143
Sick sinus syndrome..... 144
Hypothermia.....144
Electrical alternans.....145
Digitalis toxicity.....145
Quinidine toxicity..... 146
Hyperkalaemia.....146
Hypokalaemia..... 147
Dextrocardia.....147
Pericarditis.....148
Myocarditis..... 148
Myxoedema..... 149
Athlete's heart..... 149
Cerebral diseases..... 149
Pacemaker complex.....149

CHAPTER V : EMERGENCY MEDICINE 150-201

EVALUATION AND MANAGEMENT OF COMA..... 150
HEPATIC PRE-COMA/COMA.....153
COMA IN A DIABETIC..... 154
Hypoglycaemia.....155
Diabetic ketoacidosis..... 155
Hyperosmolar non-ketotic coma.....156
Lactic acidosis..... 157
EVALUATION AND MANAGEMENT OF SUDDEN RESPIRATORY DISTRESS.....157
Acute left ventricular failure..... 158
Acute severe asthma..... 159
Acute pulmonary thromboembolism.....160
Anaphylaxis..... 161
Hysterical hyperventilation..... 161
CONGESTIVE CARDIAC FAILURE..... 161
REFRACTORY HEART FAILURE..... 162

EVALUATION AND MANAGEMENT OF ACUTE CHEST PAIN..... 163
Angina pectoris..... 164
Acute myocardial infarction .... :..... 164
Musculoskeletal disorders..... 167
Acute dry pleurisy.....167
Acute dry pericarditis..... 167
Herpes zoster.....167
Diffuse oesophageal spasm 167
Cardiac neurosis.....167
Unstable angina..... 167
DRUG THERAPY IN HYPERTENSIVE EMERGENCIES..... 168
UNCONSCIOUS PATIENT WITH BRADYCARDIA..... 170
Stokes-Admas syndrome.....170
Sick sinus syndrome..... 171
Myxoedema coma..... 171
Hypothermia..... 172
MANAGEMENT OF A PATIENT OF HYPERPYREXIA..... 172
Benign tertian malaria..... 173
Malignant malaria..... 173
Cerebral malaria..... 174
Heat stroke..... 175
PATIENT WITH FEVER, UNCONSCIOUSNESS AND NECK RIGIDITY..... 175
Pyogenic meningitis..... .....;.....176
Tuberculous meningitis.....177
Viral meningits.....177
Meningoencephalitis..... 177
Typhoid meningism..... 178
RAISED INTRACRANIAL TENSION..... 178
CEREBROVASCULAR ACCIDENTS (CVA)..... 179
Cerebral thrombosis..... 179
Cerebral embolism..... 179
Cerebral haemorrhage.....179
Subarachnoid haemorrhage.....*180*
Hypertensive encephalopathy..... 180
CONVULSIONS.....180
Febrile convulsion..... 180
Status epilepticus..... 180
ACUTE ATTACK OF MIGRAINE..... 181
ACUTE GLOMERULONEPHRITIS..... 182

ACUTE PYELONEPHRITIS (UTI).....182
INTRACTABLE HICCOUGH..... 183
HAEMATEMESIS/MELAENA.....184
DYSENTERY..... 185
Acute amoebic dysentery.....185
Acute bacillary dysentery.....185
AMOEBIC LIVER ABSCESS.....186
ACUTE VIRAL HEPATITIS.....187
ENTERIC FEVER..... 187
ACUTE PANCREATITIS.....188
CHOLERA WITH SEVERE DEHYDRATION..... 189
HAEMOPTYSIS..... 190
SEVERE ANAEMIA..... 191
CARDIAC ARREST (CPR).....*..... 194
PAROXYSMAL ATRIAL TACHYCARDIA (PAT).....195
ACUTE RHEUMATIC FEVER..... 196
TETANUS.....197
ORGANOPHOSPHORUS POISONING..... 198
SNAKE BITE..... .....v.....198
DOG BITE..... 200
SCORPION BITE..... 200

CHAPTER VI : DRUGS 202-228

Drugs on autonomic nervous system 202
Drugs used in bronchial asthma/airways obstruction.....204
Drugs used in systemic hypertension..... 205
Diuretics.....208
Anti-anginal drugs..... 209
Antiarrhythmic drugs.....211
Analgesics, antipyretics and anti-inflammatory drugs..... 213
Antihistaminics and anti-5HT drugs..... 215
Sedatives and antipsychotic drugs.....216
Antiepileptic drugs..... 218
Anti-parkinsonian drugs.....220
Antituberculous drugs..... 221
Antileprosy drugs.....223
Drugs for kala-azar..... 224
Antimalarial drugs.....*..... 225
Lipid lowering agents..... 227

CHAPTER VII : CHARTS 229-306

CHARTS ON HAEMATOLOGY.....229-244

Preface.....229

Iron def iciency anaemia.....231

Megaloblastic anaemia.....232

Acute leukaemia.....234

Chronic myeloid leukaemia.....235

Pancytopenia.....237

Agranulocytosis.....238

Tropical eosinophilia.....240

Thalassaemia.....241

Thrombocytopenia •.....243

CHARTS ON GLUCOSE TOLERANCE TEST (GTT).....245-252

Preface.....245

Normal GTT.....246

Impaired *GTT/IFG*.....247

Ranal glycosuria.....248

Alimentary glycosuria.....249

Diabetic curve.....251

CHARTS ON STOOL/FAECES.....252-258

Preface.....252

Acute amoebic dysentery.....253

Acute bacillary dysentery.....254

Giardiasis.....256

Occult blood in stool.....256

CHARTS ON URINE.....258-270

Preface.....258

Acute glomerulonephritis.....260

Nephrotic syndrome.....262

Chronic glomerulonephritis or chronic kidney disease.....263

Urinary tract infection.....266

Diabetic ketoacidosis.....269

CHARTS ON CSF.....270-280

Preface.....270

Acute pyogenic meningitis.....271

Tuberculous meningitis.....273

Acute viral meningitis.....275

Meningism.....276

Subarachnoid haemorrhage.....277

Xanthochromia.....279

CHARTS ON TEMPERATURE.....281-298
Preface..... 281
Quotidian temperature.....282
Tertian temperature..... 283
Continued temperature.....285
Remittent temperature..... 288
Step-ladder pattern pyrexia.....290
Temperature chart on measles.....292
Temperature chart on varicella infection..... 294
Temperature chart on lobar pneumonia..... 296
Temperature chart on dengue.....297
CHARTS ON LIVER FUNCTION TESTS.....299-306
Preface..... 299
Acute viral hepatitis.....300
Unconjugated hyperbilirubinaemia 301
Cirrhosis of liver..... 302
Cholestasis.....303
Chronic hepatitis..... 305

APPENDIX 307-318

FEW VALUABLE INFORMATIONS..... 307
INCUBATION PERIOD OF SOME IMPORTANT INFECTIONS..... 309
THERAPEUTIC AND TOXIC BLOOD LEVELS OF COMMONLY USED DRUGS.....309
HAEMATOLOGICAL DATA AND APPROXIMATE CONVERSION CHART.....310
SERUM BIOCHEMICAL VALUES.....311
YOUR ORAL TABLE AND DISTRIBUTION OF MARKS..... 312
INDEX.....313

CHAPTER I : INSTRUMENTS AND PROCEDURES

RYLE'S TUBE

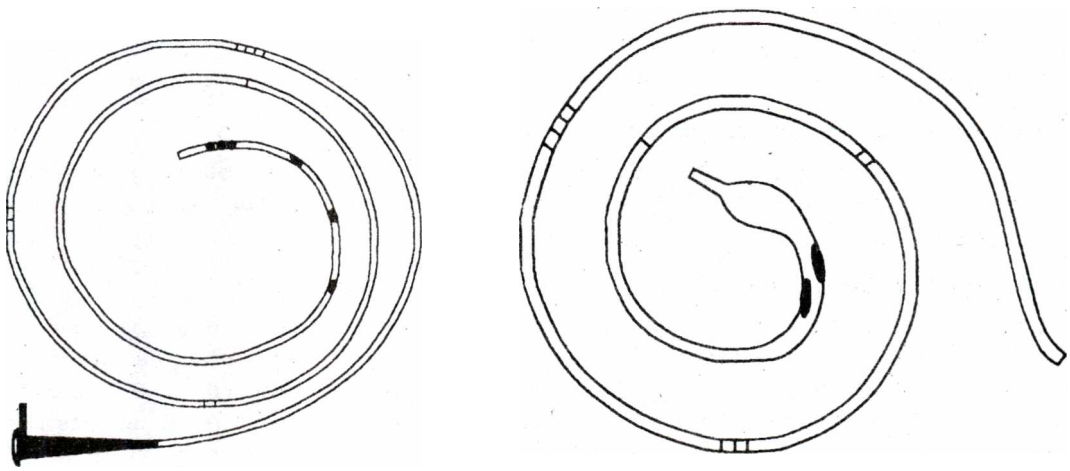

Fig. 1.1 : Ryle's tube (polythene and rubber) showing markings

Description :

It is a fine bore flexible red rubber or polythene (transparent) tube with external circumference of 8 mm and length 90 cm. The blind bulbous tip contains a lead shot inside the tube to facilitate passage of the tube into the oesophagus (it is heavy and thus it is easier for the patient to swallow the tip). The lower end of the tube is perforated by a number of side holes at different levels to allow easy suction of gastro-duodenal contents. There are four circular markings in the body of the tube as mentioned below :

a) First mark (single circular mark)—Placed at a distance of 40 cm from the tip and indicates the distance from upper central incisor teeth to cardiac orifice of stomach.

b) Second mark (two circular marks)—Indicates the distance between upper central incisor teeth and body of stomach (50 cm).

c) Third mark (three circular marks)—Indicates the distance between upper central incisor teeth and pylorus (57 cm).

d) Fourth mark (four circular marks)—Indicates the distance between upper central incisor teeth and first part of duodenum (65 cm). *It means the tube has reached duodenum when the fourth mark is seen at the teeth.*

The base (open end) is usually plugged by a conical plastic cap, and is used to fit with the nozzle of a syringe to push or to draw materials from the stomach. Ryle's tube is usually sterilised by keeping in boiling water for 30 minutes or by gamma ray irradiation.

The tip is made blunt to avoid trauma during introduction. If the perforations near the lower end are placed at same level, the tube may be easily torn during manipulation and if blocked {with openings at same level) by food debris or sticking to the mucosal surface of stomach, it would hamper suction of gastro-duodenal contents. Ryle's tube is available in different sizes (tube with smaller diameter is used in children). Instead of lead shot, polythene tube usually contains 3 radio-opaque metal balls.

How to be sure that the tip has reached the stomach ?

It is confirmed by the following methods—

1. Apply a 50 ml syringe at the open end of Ryle's tube. Inject air into the tube by pushing the

piston with a single rapid thrust and simultaneously auscultate over the epigastrium. A gurgling sound confirms the position of the tube in the stomach.

2. Aspirate the gastric contents; the contents come out freely if the tube is in the stomach. Acidic nature of the gastric contents may be confirmed by litmus paper test.
3. Fluoroscopy or straight X-ray of the abdomen shows the exact position of the tip of the tube as the tip contains lead shot or radio-opaque material.

* If the tube is passed falsely into the respiratory tract,

a) Patient complains of a choking sensation.
b) Violent cough appears and persists for long time.
c) Yield of aspiration becomes nil.

In this situation, take out the tube immediately and try to reintroduce it cautiously.

Why this nasogastric tube is named after 'Ryle' ?

So far too many varieties of nasogastric tubes have been discovered but the tube designed by the physician, John Alfred Ryle (1889-1950) of Guy's Hospital Medical School is the most acceptable and commonly used type.

How the Ryle's tube is introduced ?

The patient is first explained about the procedure in order to obtain maximum co-operation. Ask the patient to lie flat in bed with extended neck. Remove the dentures, if present. In the nose, a more patent nostril is selected and properly cleansed, and lubricated with lignocaine jelly (2%). Lubricate the tip of the sterilised tube with liquid paraffin or glycerine, and introduce the tip through one nostril (manually, mould the lower end of the tube a bit curved for easy passage through nasopharynx). As the tube reaches the oropharynx, the patient may start coughing once or twice and may even try to throw the tube by pulling it with his hands. Reassure the patient and ask him to swallow the tube, and to facilitate swallowing, one or two teaspoonfull of water may be poured into the mouth. With patience, the tube will gradually pass into the stomach. Be sure that the tube is in the stomach and not within the trachea (see above). Take care in case of a comatosed patient, where the protective cough reflex is lost and the tube may be introduced within the trachea without any alarming sign.

Lastly, the base (open end) of the tube is kept adhered with the forehead by a leucoplast and the open end is usually plugged (except in intestinal obstruction where the open end is kept open to allow continuous drainage). In a restless patient, hands should be tied.

Conventionally, the tube should not be kept for more than 48 hours. After 48 hours, the tube should be smeared daily with some antiseptic solution by withdrawing it only for 2 inches (the part lying within the nose), and then reintroducing it.

* Do not force the passage of Ryle's tube, if persistent resistance is felt.

** In repeated failure, try a smaller gauge tube.

Different uses :

(A) Diagnostic—

1. Fractional test meal—Virtually obsolete now-a-days.
2. To confirm upper G. I. haemorrhage.
3. To isolate AFB from gastric juice in a child who is suffering from pulmonary tuberculosis (children usually swallow their sputum), or the patient who can not expectorate sputum; searching for malignant cells in gastric carcinoma.
4. For forensic purpose—Detection of cause of death in a suspected case of poisoning by subsequent chemical analysis of gastric aspiration (barbiturate, organophosphorus, copper sulphate, alcohol etc).
5. To aspirate duodenal secretions for analysis of,
   a) Pancreatic function,
   b) Detection of typhoid carriers, and
   c) Detection of Giardia lamblia infestation.
6. To diagnose gastric outlet obstruction (gastic aspirate will exceed 200 ml after overnight fasting).

(B) Therapeutic—

1. **Nasogastric feeding (see the next question).**
2. **Nasogastric suction in,**
   a) **Acute intestinal obstruction,**
   b) **Bowel rest in acute pancreatitis, Crohn's disease and intestinal fistula,**
   c) **Acute dilatation of stomach,**
   d) **Acute abdomen,**
   e) **Post-operative, and**
   f) **G.I. tract haemorrhage or perforation (paralytic ileus).**
3. **Gastric wash or lavage done in,**
   a) **Pyloric stenosis,**
   b) **Non-corrosive poisoning, drug overdose, and**
   c) **Severe hiccough (by ice-cold water or sodi-bicarbonate solution).**
4. **Medication in comatose patient.**
5. **If can be used as a tourniquet.**

* **Gastric lavage is contraindicated in a) Corrosive poisoning (Ryle's tube may perforate the oesophagus in acid or alkali poisoning), and b) Kerosine oil, paraffin or petrolium poisoning (gastric lavage increases the chance of development of lipoid pneumonia).**

** **The two main indications for use of Ryle's tube are a) aspiration of gastric contents, and b) nutritional supplementation of the patient.**

*** **Left lateral position of the patient facilitates the recovery of gastric juices.**

**** **Insert a cuffed endotracheal tube before performing gastric lavage in unconscious patients.**

Indications for Ryle's tube feeding :

1. **Unconscious patients (CVA, hepatic encephalopathy, diabetic ketoacidosis, cerebral malaria, encephalitis, meningitis, head injury).**
2. **Inability to swallow, e.g., after facio-maxillary injury or surgery, bulbar palsy.**
3. **Patients who are reluctant to take food orally, e.g., severe anorexia, anorexia nervosa etc.**
4. **Neurogenic dysphagia, nasal regurgitation in polymyositis or dermatomyositis.**
5. **In patients with burns.**

N.B. : Previously used intragastric milk drip in acute exacerbation of chronic duodenal ulcer is not practised now as milk may increase gastric acid secretion and release of gastrin, stimulated by direct effect of milk protein and calcium.

Complications of nasogastric intubation :

1. **Rhinitis and pharyngitis; ulceration in oesophagus may develop.**
2. **If the tube enters into trachea, aspiration pneumonia and even death may result.**
3. Blockage of the tube.
4. **If the tube is kept in situ for a prolonged period (e.g., in bulbar palsy), it is often difficult to take out the tube (the Ryle's tube may be coiled spontaneously inside the lumen of stomach).**
5. **Perforation of pharynx or oesophagus (chance increased in presence of oesophageal disease).**
6. **Chance of respiratory tract infection in prolonged intubation (thus, chest physiotherapy is necessary).**

Hypochlorhydria and hyperchlorhydria :

(A) Hypochlorhydria or achlorhydria—

1. **Aged persons > 60 years.**
2. **Pernicious anaemia.**
3. **Gastric malignancy.**
4. **After proton pump inhibitor therapy.**

(B) Hyperchlorhydria—

1. **Zollinger-Ellison syndrome.**
2. **Systemic mastocytosis.**
3. **Hyperparathyroidism.**
4. **G-cell hyperplasia.**

N.B. : Read corrosive poisoning, drug overdose, haematemesis in details.

TRACHEOSTOMY TUBE

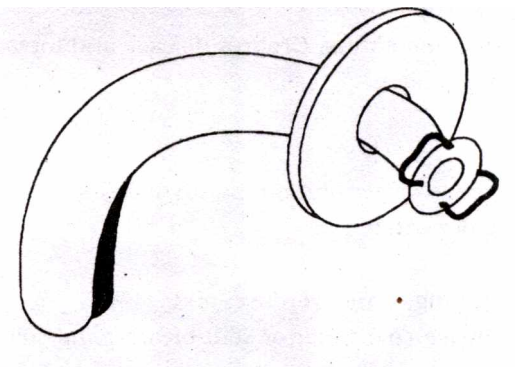

Fig. 1.2 : Fuller's bivalved tracheostomy tube

Available varieties :

(A) Metallic variety—

- **a) Fuller's bivalved tube.**
- **b) Parker's angled tube.**
- **c) Durham's Lobster tail tube.**

(B) Rubber (synthetic) variety—

- **a) Ordinary rubber tube.**
- **b) Portex tube.**
- **c) Morrant Baker cuffed rubber tube.**

Description of Fuller's tracheostomy tube :

It is the commonly used type. It consists of one outer and one inner tube.

Outer tube—The curved tube is split distally into two thin blades which can be easily approximated. As the blades have spring-like action, it acts as a tracheal dilator. Proximally, the outer tube contains a rounded shield bearing an opening on each side through which threads can pass and is fastened to the back of the neck to fix the tube.

Inner tube—It is a tube with an opening and made for air passage. At its proximal end, there are two rings for easy handling.

What is tracheostomy ?

Tracheostomy' is an operation for temporary relief of a patient who is suffering from acute upper airway obstruction. It is aimed at making an opening into the trachea in order to by-pass the upper airway obstruction and introducing a tube into that opening through the incision given in the neck.

Tracheotomy' is a simple incision given temporarily on trachea in an attempt to expose the tracheal lumen for the treatment of tumour or stenosis.

Function of tracheostomy :

The tracheostomy serves the following purposes—

1. **It by-passes the upper respiratory obstruction.**
2. **It reduces the dead space and thus improves efficiency of respiration.**
3. **It diminishes airway resistance, i.e., strain of respiration is reduced.**
4. **It helps in removing the excess bronchial secretions.**
5. **Insertion of a cuffed tracheostomy tube helps in application of positive-pressure ventilation.**

Common indications for 'emergency' tracheostomy :

1. **Laryngeal diphtheria (pseudomembrane obstructs the larynx).**
2. **Impacted foreign body in the larynx.**

3. **Acute laryngeal oedema (oedema glottis resulting from anaphylaxis or inhalation of irritant gases) with cyanosis.**
4. **Tetany (in case of laryngysmus stridulus) or tetanus (laryngeal spasm).**
5. **Acute bulbar palsy (poliomyelitis, G.B. syndrome, rabies, myasthenic crisis).**
6. **Ludwig's angina.**
7. **Spasm of vocal cord (tabetic laryngeal crisis) in tabes dorsalis (not seen now-a-days).**

Common indications for 'planned' or 'elective' tracheostomy :

1. **As a preliminary step in different operations in larynx.**
2. **To relieve obstruction in a case of laryngeal carcinoma.**
3. **In respiratory failure (paralysis of intercostal muscles) i.e., for long-term ventilation, this is aimed to reduce the dead space. Apart from this, intermittent positive-pressure ventilation may be applied through a cuffed endotracheal tube inserted via a tracheostomy, in patients suffering from respiratory paralysis with or without bulbar palsy (particularly when the respiratory paralysis is likely to last for more than 2-3 days).**
4. **Bronchial lavage.**
5. **Incompetent larynx with aspiration.**

Different types of tracheostomy :

It depends on the position of isthmus of the thyroid gland.

A. **High tracheostomy—Opening done above the isthmus (it has the risk of injuring cricoid cartilage, followed by stenosis).**
B. **Median tracheostomy—Opening done at the level of the isthmus (choice in acute emergencies).**
C. **Low tracheostomy—Opening done below the isthmus (some physicians prefer this method).**

Common bedside features of laryngeal obstruction :

The patient presents with,

1. **Restlessness with hyperactive accessory muscles of respiration.**
2. **Dyspnoea and even orthopnoea.**
3. **Cough (croupy cough is seen in diphtheria).**
4. **Stridor.**
5. **Central cyanosis.**
6. **Intercostal suction.**
7. **Signs of exhaustion.**

How the tube is introduced ?

The two tubes are seperated. Press the two cusps (blades) of the outer tube and try to appose them, and now introduce it with its concavity directed downwards. The blades will open up and will act as a tracheal dilator. Tie the outer tube round the neck with a thread. Then introduce the inner tube through the outer one and place a piece of wet sterile gauze over the opening of the tube.

The advantages of double tubing are—

a) **When the inner tube is taken out for cleaning, the outer tube serves the purpose.**
b) **Bivalved outer tube helps to avoid the use of an extra tracheal dilator.**

Precautions taken during the period of intubation :

1. **Metallic tube is kept for a short period, usually not more than 24 hours to avoid necrosis of trachea which may lately give rise to tracheal stenosis. This should be replaced by rubber tracheostomy tube.**
2. **The rubber tube may be kept up to a desired period.**
3. **Precautions are taken so that the tube remains patent. Intermittent suction may serve the purpose.**
4. **Strict asepsis is maintained. A sterile gauze piece soaked in 1 : 1000 acriflavine solution or povidone-iodine solution is commonly used over the opening of the tube.**

5. **Systemic broad-spectrum antibiotic is used to prevent respiratory tract infection, as and when necessary. Good nursing care with strict asepsis is maintained.**

* **The inner tube should be removed every four hours for cleaning purpose. The excess of secretions should be removed (by suction) with a soft rubber catheter. Mucolytic aerosols or humidifiers are often used to liquefy the viscid secretions.**

** **Once the patient can sleep for a night with the tube plugged, it is then possible to remove the tracheostomy tube.**

*** **The tracheostomy tube is sterilised by immersing in concentrated lysol solution.**

Post-operative complications :

1. **Bronchopneumonia.**
2. **Mediastinal emphysema.**
3. **Mediastinitis (i.e., mediastinal infection).**
4. **Pneumothorax.**
5. **Necrosis of anterior tracheal wall.**
6. **Blockage of the tracheostomy tube (in improper toileting).**
7. **Tracheal stenosis or collapse of the tracheal rings.**
8. **Tracheo-oesophageal fistula.**
9. **Erosion of innominate artery.**
10. **Difficulty in decannulation ('decannulation' is the method by which tubes of progressively smaller diameter are introduced in order to adapt the patient to breathe through the normal airway, as the patient often forgets to breathe normally when tracheostomy tube remains for a longer period).**

N.B. : Read steps of tracheostomy operation from standard ENT text book. Read diphtheria and bulbar palsy in details.

SIMPLE RUBBER CATHETER

Fig. 1.3 : Simple rubber catheter

Description :

1. **Simple tube made of India-rubber or latex-rubber.**
2. **There is a channel throughout the whole length of the tube.**
3. **Blunt and rounded tip with perforation (eye); the other end is open.**
4. **Number of size (available in different sizes) is printed on the catheter.**

* **The catheter is sterilised by keeping in boiling water for 30 minutes or by gamma ray irradiation.**

** **Catheters made of 'latex' make it biologically inert as far as possible. 'Silicone' catheters are preferred when required to be kept for a longer time.**

Different uses :

1. **To relieve retention of urine.**
2. **To differentiate retention of urine from anuria.**
3. **As a tourniquet (to produce haemostasis or to make the veins prominent).**
4. **As an oxygen tube, i.e., used as a nasal catheter.**
5. **In infants, it may be used as a feeding tube.**
6. **Used prior to cystography (to introduce dye in the urinary bladder).**
7. **For bladder wash (by acriflavine or silver nitrate solution).**

8. As a drainage tube.
9. To obtain urine specimen in an unconscious patient.
10. To differentiate pelvic lump from bladder swelling.
11. **Before or during delivery (Child birth).**

* Simple rubber cathater is used for catheterisation 'just once' only.

Mention common medical causes of catheterisation :

Temporary catheterisation is done as an emergency measure to relieve pain induced by acute retention of urine. This is usually achieved by using simple rubber catheter or Gibbon's catheter.

A self-retaining catheter (e.g., Foley's catheter) is used with intention to retain the catheter for few days. They are basically used in patients with benign hypertrophy of prostate (BHP) who are unfit for prostatectomy, neurogenic bladder and in patients who are mostly bed-bound (e.g., hemiplegia or paraplegia). A 'haematuria catheter' is a three-way catheter (used in haematuria) with an extra channel for irrigation. The 'medical causes' are :

1. Coma or unconsciousness due to any cause e.g., CVA *(hemiplegia),* diabetic ketoacidosis, encephalitis, hepatic coma, cerebral malaria.
2. Meningitis (tuberculous commonly).
3. Compressive myelopathy (caries spine), acute transverse myelitis, spinal injury, anterior spinal artery thrombosis, i.e., in *paraplegia.*
4. Poisoning—Opium, dhatura, organophosphorus or drug overdose (sedatives).
5. Snake bite (specially Viperidae group).
6. Sometimes, catheterisation is done in acute nephritis, nephrotic syndrome, renal failure and patients in Intensive Therapeutic Unit (ITU) to measure the actual urinary output.

* Common surgical indications are BHP, vesical calculus, bladder injury and carcinoma of prostate.

How to catheterise the urinary bladder ?

Maintenance of strict asepsis is very important.

1. The procedure should be explained to the patient. The catheter is sterilised properly (or already done by manufacturers). The physician should follow strict antiseptic and aseptic measures—hand washing by soap and spirit, and wearing sterile mask, gown and gloves. The local part of the patient is cleaned meticulously by any antiseptic solution.
2. The tip of the catheter is lubricated by liquid paraffin and introduced per urethra; 2% lignocaine jelly may be used to reduce pain during introduction.
3. Oulflow of urine confirms proper introduction while evacuation of the bladder is done gradually.
4. The free end of the catheter should not touch the urine contained in the kidney-tray as contaminated urine from the container may be sucked into the bladder by negative intravesical pressure after evacuation.
5. The catheter is taken out after evacuation is over or may be kept for some time by proper adhesion on the thigh by leucoplast; if repeated or prolonged catheterisation is necessary, a self-retaining catheter (e.g., Foley's catheter) should replace simple rubber catheter.

* For self-retaining catheters in adults, it is better to choose the 'medium size' (neither too large nor too fine). A 14 Charriere catheter is a good first choice in an adult (catheters are sized using the system invented by Charriere).

Risk of rapid evacuation of the bladder :

Rapid evacuation may be dangerous due to development of,

1. Reflex shock.
2. Haematuria as a result of rupture of engorged and dilated sub mucous veins of the bladder.
3. Reflex anuria (rare).

Initial steps to relieve acute retention of urir\e

1. Reassurance.
2. Alternate application of hot and cold over the hypogastrium.

p. Produce the sound of a running tap (to initiate childhood reflex).

4. Apply hot hip bath.
5. Inj. carbachol — 2 ml, I.M may be given to initiate the reflex; parasympathetic stimulation enhances evacuation of urine.
6. Lastly, try catheterisation.

Differentiation between retention of urine and anuria :

(A) Clinically : On inspection hypogastrium looks distended in retendtion of urine. Now percussion of the hypogastrium is done from above downwards where retention will produce a dull note and in anuria, normal tympanitic note of abdomen is elicited. Moreover, application of pressure over hypogastric swelling produces desire for micturition in retention of urine.

(B) By catheterisation : In anuria, no urine comes out after introduction of a simple rubber catheter; urine comes out after catheterisation in a case of retention of urine.

Complications of catheterisation :

1. Urinary tract infection (commonest); catheter fever.
2. Catheter trauma and bleeding.
3. Haematuria after sudden evacuation.
4. Shock (reflex) - rare.
5. False passage (rare).
6. Blockage of the lumen of catheter leading to retention of urine.
7. Long-tern catheterisiation may be associated with urethral ulceration, stricture formation or formation of vesical calculus.

* An indwelling catheter invariably leads to urinary tract infection within days or weeks. This can be minimised by regular bladder wash done by saline or dilute chlorhexidine solution, and changing the catheter after few days.

Common causes of anuria :

(A) Pre-renal:

1. Shock, sepsis (septicaemia), haemorrhage (massive).
2. Dehydration due to any cause (e.g., acute gastroenteritis).
3. Crush syndrome.
4. Burn (extensive).
5. Intravascular haemolysis, mismatched blood transfusion.
6. Congestive cardiac failure.
7. Acute pancreatitis.

(B) Renal:

1. Acute glomerulonephritis, rapidly progressive glomerulonephritis (RPGN).
2. Acute renal failure.
3. Acute papillary necrosis (diabetes, phenacetin-induced, sickle cell disease).
4. Diffuse cortical necrosis.
5. Complete renal arterial and venous obstruction.
6. Chronic renal failure (produces anuria terminally).

(C) Post-renal :

1. Reflex anuria (calculus in one ureter may produce reflex obstruction of the other ureter).
2. Ligation of the ureters (accidental) or bilateral ureteric obstruction by clots, stones or crystals.
3. Ureteric obstruction due to retroperitoneal fibrosis or malignant infiltrations around the ureters.

No urine comes out after catheterisation : reasons behind :

In this situation, one should think of :

1. False passage.
2. Eye of the catheter remaining above the urine level in the bladder — a little withdrawal of the catheter brings out urine.

3. **Catheter Is blocked.**
4. **Dealing with anuria instead of retention of urine.**

*** An oxygen tube may be used as a rubber catheter though it is very thin. Don't confuse a simple rubber catheter with the Ryle's tube (Ryle's tube is longer and has lead shot or metal balls at the tip).**

**** S *elf-retaining catheters* (Foley's, Malecot's) are usually encountered in surgery practical examination.**

BONE MARROW ASPIRATION NEEDLE

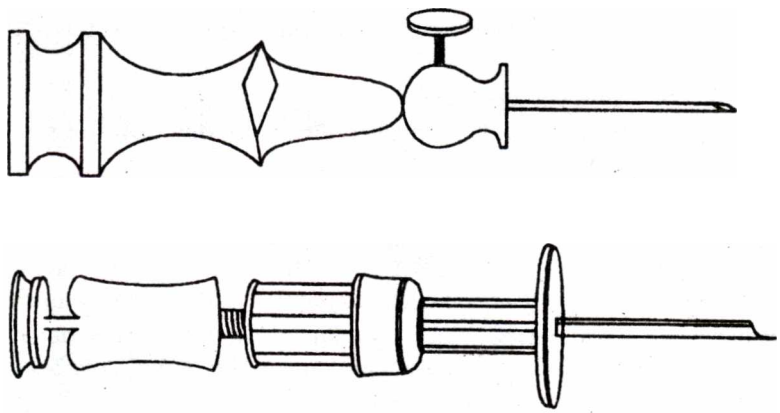

Fig. 1.4 : Sternal puncture needle (Salah and Klima's variety)

Use :

It is used for bone marrow aspiration. Often it is loosely termed as sternal puncture (S.P.) needle.

Description :

The needle consists of three parts—

1. **The needle proper—It is a stout wide bore needle (length is 5 cm); the needle is shortly bevelled at one end, and the base of the stylet or the nozzle of a syringe fits in the other broad end.**
2. **The stylet—It keeps the needle patent during introduction. When kept inside the needle proper, it helps to know whether the tip of the needle has entered into the marrow cavity or not. The base of the stylet contains a small projection for better fixation with the needle proper.**
3. **The adjustable guard—The adjustable screw guard prevents over-penetration of the needle. The plane or flat surface of the guard should look down to the chest wall of the patient.**

The S.P. needle is made of steel. There are two types :

(1) Salah (commonly used) and (2) Klima. The two varieties differ in the design, specially in the type of the guard. Klima's variety contains an adjustable guard on the stem of the needle proper; it has a central screw (not projected from the side like Salah's variety). The needle is sterilised by immersing in concentrated lysol solution.

N.B. : Bone marrow biopsy is of two types :

a) **Aspiration biopsy (by Salah's or Klima's needle), and**
b) **Trephine biopsy (by Jamshidi's needle).**

Sites of puncture :

1. **Body of the sternum—2nd or 3rd piece of body on either side of midline (manubrium stemae is less cellular).**
2. **Posterior iliac crest.**
3. **Upper part of the medial surface of tibia, just below the tibial tuberosity.**
4. **Spinous process of lumbar vertebrae.**
5. **Ribs (rarely used).**
6. **Any site of bone infiltration or tumour (in disease).**

Billious secretion, accumulated in the stomach in acute pancreatitis, is coming out through Ryle's tube and collected in a bag

Blood drawn from right antecubital vein; a glove has been used here as a touriniquet

Orange-yellow coloured urine collected in urosac in a patient of caries spine who is on rifampicin

Heart failure and shock from valvular heart disease are managed in the indoor with dobutamine drip (with the help of **'syringe pump'** kept on drip stand shelf) and multi-channel **monitor** (rests on meat-safe); the patient responded well

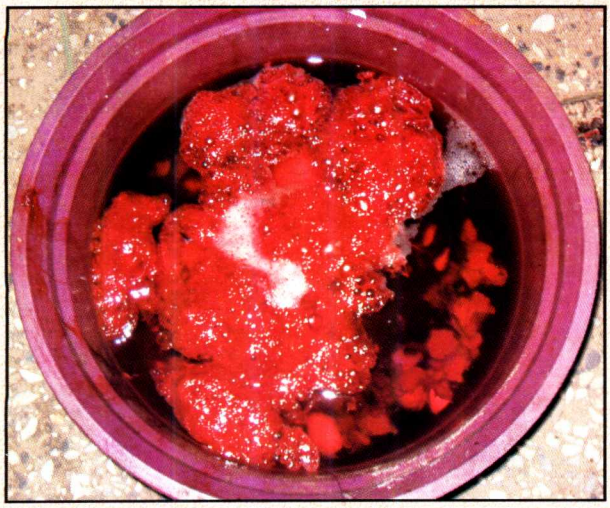

Massive haemoptysis in a patient of bronchogenic carcinoma; air bubbles (froth) are seen mixed with blood

A patient recovering from **lightning injury**

A patient suffering from fibrocalculous pancreatic disease (FCPD) is trying to manage abdominal pain by drawing folded legs over the abdomen - **decubitus** of chronic pancreatitis; she had type 1 diabetes mellitus

Profuse saliva is seen in a sputum-bowl in a patient of suicidal acid ingestion; she had ptyalism or sialorrhoea

Waste disposal in hospitals are done by red (gauze, cotton, IV set, blood bags, saline bottles, catheters), blue (sharp objects like needles, razors, and syringes), and black buckets (common disposals like earthen pots, waste food material, papers); yellow bucket (not in picture) is used for disposal of placenta and other tissues

White slough in tongue with haemorrhagic spots and erythema (sore tongue) are seen in accidental acid ingestion

Cellular debris present in **urine** is collected in the urosac in a patient of severe urinary tract infection (UTI)

A patient of acute leukaemia is undergoing **bone marrow aspiration** from posterior iliac crest

5. The guard is adjusted at a distance which is equal to the depth of the skin and the subcutaneous tissue (varies with the build of the patient) plus 0.5 cm extra length (this is the thickness of cortex of the sternum). The stylet is now put within the needle, and by boring or drilling movement the needle is pushed through the skin vertically down (the needle is held at right angles to the bone) till the medulla is reached.
6. As soon as the bone marrow as reached, the stylet is removed and a metal syringe is attached to the needle. Now as the marrow is aspirated, the patient complains of excruciating suction pain; 0.2 ml of bone marrow is sucked out gently. The needle with the metal syringe is then removed as a whole. The aspirated marrow is dropped immediately over the properly cleaned slides to prepare films.
7. The puncture site is sealed with tincture benzoin and the patient is advised to take rest for at least 30 minutes. Pulse and BP are monitored half hourly for 4 hours, and analgesics may be given to relieve pain.
8. Usually 6 pairs of glass slides are given in the tray. Remove the blood or fluid part from the slide by tilting the slide, or by means of blotting paper or pipette. Marrow films (marrow is granular) are now prepared like blood films (or two slides containing marrow material are apposed and slided over). After drying, the slides are stained (usually with Leishman's stain).

* Aspiration of more than 0.2 ml of material will unnecessarily dilute the marrow (as blood comes) and reduce the concentration of marrow cells.

** If no marrow is obtainable from a site, a different site may be chosen.

(B) Iliac crest puncture—

Safest: the patient lies in prone position on a pillow placed beneath the pelvis.

(C) Lumbar spinous process puncture—

Easy procedure. Patient sits or adopts lateral decubitus position. The needle is introduced perpendicularly and a bit lateral to the midline.

How to recognise that marrow material is present on the slide ?

As the marrow is granular, the surface of the film will appear uneven.

How to be sure that marrow cavity has reached ?

This is diagnosed by,

1. Sudden loss of resistance.
2. The needle remains in vertical position without any support.
3. The tip of the stylet is smeared with red granular marrow material when removed from the needle.
4. Reintroduction of the stylet will produce pain.
5. Suction by the syringe produces severe and intense pain (most reliable proof), and is due to irritation of pain carrying nerve fibres surrounding the marrow cells.

Complications of bone marrow aspiration :

1. Over-penetration (if posterior table of sternum is penetrated, aorta and its branches and other vital mediastinal structures may be damaged)—cardiac tamponade and pneumothorax may develop.
2. Haemorrhage (haematoma) and bone pain.
3. Shock.
4. Infection (osteomyelitis).
5. Sudden death due to accidental injury to vital organs.

Causes of dry tap :

Failure to obtain marrow may be due to,

1. Faulty technique.
2. Myelosclerosis/myelofibrosis (marrow replaced by fibrous tissue).
3. Marrow aplasia or hypoplasia (marrow replaced by fat).
4. Gross marrow hyperplasia—May be seen in leukaemia.
5. Carcinomatous infiltration of the bone marrow (tightly packed with infiltrates).

* These cases actually demand trephine biopsy.

** 'Bloody tap' is the bone marrow which is greatly diluted with blood.

Examination of the bone marrow film :

Following are examined under the microscope—

(A) The cellularity of the marrow.

(B) Type and activity of erythropoiesis.

(C) The number and type of :

a) Developing WBC.

b) Megakaryocytes.

c) Plasma cell.

D) Myeloid-erythroid ratio (M:E).

(E) Presence of :

a) Parasites or any organism.

b) Foreign body; tumour cells or any abnormal cell.

c) Fatty and fibrous tissue.

d) Iron (content).

* Normal M:E = 3:1 or 4:1

Composition of normal bone marrow :

The normal bone marrow is composed of haemopoietic cells (nucleated cells 20000-1 lae/mm^3}, blood vessels, reticulum, fatty tissue and nerves.

Criteria for ideal site in bone marrow puncture :

1. Superficial bone (i.e., easy accessibility).
2. Not close to any vital structure.
3. Thin cortex with more cancellous tissue.

* Trephine biopsy needle is used where aspiration of bone marrow is "unsuccessful (myelofibrosis, myelosclerosis) or unhelpful (malignant infiltration) or in diagnosis and assessment of osteomalacia/ hyperparathyroid bone disease. Jamshicli-Swain biopsy needle has a distal cutting edge. The posterior iliac crest is preferred for performing trephine biopsy.

LIVER **BIOPSY NEEDLE**

edxo=—"

Fig. 1.5 : Liver biopsy needle (the solid stylet; and outer hollow needle with inner split needle within)

Types :

There are three types of needle used for biopsy of liver.

1. Vim-Silverman's biopsy needle (commonly used; it is a cutting needle)—See Fig. 1.5 above.
2. Menghini's aspiration biopsy needle (fragmentation of liver tissue is better, low cost, quicker).
3. Sheathed Trucut' needle (modified Vim-Silverman's needle).

Description :

Vim-Silverman needle has three parts—

1. Outer-hollow needle—It guides the inner split needle.
2. Inner split needle—It brings out the liver tissue.
3. Solid stylet—It keeps the needle patent during introduction.

Indications of liver biopsy :

1. Cirrhosis of liver (commonest).
2. Carcinoma of liver (primary or secondary).

3. Chronic hepatitis.
4. Portal hypertension of any aetiology.
5. Alcoholic liver disease, drug-induced hepatitis or cholestasis of uncertain origin.
6. Storage and metabolic disorders, e.g., glycogen storage disease, haemochromatosis, amyloidosis.
7. Infective or granulomatous diseases e.g., tuberculosis, brucellosis, leptospirosis, amoebiasis, sarcoidosis.
8. Lymphoma (operative liver biopsy for staging), myeloid metaplasia.
9. Unexplained hepatomegaly or elevation of liver enzymes; pyrexia of unknown origin.
10. Post-hepatic transplantation.

Contraindications of liver biopsy :

(A) Absolute contraindications are—

1. Abnormal blood clotting mechanism (thrombocytopenia, haemophilia).
2. Suspected hydatid cyst of liver (may precipitate anaphylactic reaction after puncture of the cyst).
3. Passive venous congestion of liver (i.e., in the presence of congestive cardiac failure).
4. Subphrenic abscess (right).
5. Right-sided empyema thoracis or pleural effusion; septic cholangitis.
6. Haemangioma of liver.
7. Dilated biliary channels (may lead to biliary peritonitis).

(B) Relative contraindications are—

1. Massive ascites.
2. Severe and protracted jaundice.
3. Severe obstructive airway disease.
4. Non-cooperative patient.

N.B. : Liver biopsy should not be performed if the platelet count goes below 80000/mm^3 and bilirubin above 20 mg/dl. In massive and tense ascites, specimen of liver tissue may not be obtained (as liver is displaced medially, it impedes penetration by the biopsy needle, or the biopsy material may be lost in ascitic fluid) or may lead to continuous oozing of fluid.

Prerequisites for liver biopsy :

1. *Prothrombin time should not be more than 3 seconds prolonged over control values (if control prothrombin time is 16 seconds, then patient's value should not be > 19 seconds to have a safe liver biopsy).*
2. Try to rule out hydatid cyst of liver, subphrenic abscess, empyema thoracis or haemangioma of liver by prior ultrasonography. Take the H/O any bleeding tendency before attempting liver biopsy.
3. Rule out protracted deep jaundice.
4. Patient's blood group should be known; arrange for blood transfusion to combat any post-operative bleeding.

If prothrombin time is high, try to normalise it by giving 10 mg of inj. vitamin K daily by I.M route for consecutive 3 days before performing liver biopsy. Sedation before biopsy is not routinely advocated because it may interfere with patient's cooperation.

How the liver biopsy tray is prepared ?

1. Spirit, iodine, sterile gown, mask and gloves for antiseptic purpose.
2. 2% lignocaine solution as local anaesthetic.
3. Sterile liver biopsy needle.
4. 2 ml glass syringe with needle for local anaesthesia.
5. Sterile gauze and cotton.
6. Specimen containers (empty vials) with preservative solution (formol-saline).
7. Benzoin solution.

Procedure of performing liver biopsy :

1. Patient lies flat near the edge of the bed as far as possible. One pillow under the head and one under the patient's lower part of thorax may be placed for the purpose of expansion of thoracic cage.
2. The physician should wear the sterile gown. Standing on the right side of the patient, the physician cleans the local part by antiseptic solution.
3. Idealy, the biopsy site is 2 to 3 ICS below the upper border of liver dullness, which should be assessed beforehand. Local anaesthetic solution is usually infiltrated at the 8th or 9th ICS in the midaxillary line (skin, subcutaneous tissue and parietal pleura are infiltrated).
4. The outer hollow needle with the solid stylet is introduced through the 8th or 9th ICS in the midaxillary line at the end of expiration or with the patient breathing quietly (it is not always possible for the patient to hold the respiration) till is felt to enter the liver. The direction of the needle is slightly posterior and cranial to avoid the injury of gall bladder.
5. Now ask the patient to hold breath for few seconds (ask the patient to practice holding of breath before the procedure is started). Remove the stylet quickly and introduce the inner split needle through the outer needle. The outer hollow needle in advanced completely, and the outer needle plus the inner split needle is rotated as a whole through 360° (as Vim-Silverman's needle is a cutting needle).
6. The whole needle is now withdrawn. The puncture site is sealed with tincture benzoin.
7. The biopsy tissue captured by the inner split needle is kept in the preservative solution of biopsy container for histological examination.
8. After-care—Rest in bed for 24 hours is essential. Observe the pulse, BP and respiratory rate every one hour for next 24 hours. The patient is advised to lie on right lateral position for first 4 hours. Give analgesics, sedatives, antibiotics whenever indicated.

How to be sure that needle has gone within the liver ?

After introduction of the outer needle with the stylet, take off your hand from the needle, and ask the patient to breathe in and out very slowly. If the needle is within the liver, it starts moving with respiration.

'Dry' liver biopsy or causes of failure :

1. Faulty technique.
2. Very tough hepatic tissue (e.g., cirrhosis of liver).
3. Tense ascites.
4. Emphysema.

Complications of liver biopsy :

1. Haemorrhage—Intraperitoneal or intrathoracic (haemothorax). Bleeding is due to perforation of distented portal or hepatic veins, or aberrant intercostal arteries.
2. Biliary peritonitis (due to trauma in gall bladder).
3. Shock or precipitation of hepatic coma.
4. Perihepatitis and/or pleurisy (patient may complain of severe pain in the right hypochondrium and right shoulder, and hepatic/pleural rub may appear).
5. Haemobilia—Bleeding from damaged hepatic vessel into bile duct.
6. Intrahepatic arteriovenous fistula.
7. Intrahepatic haematoma.
8. Transient bacteraemia, septicaemia.
9. Anaphylaxis (if hydatid cyst is punctured).
10. Small pneumothorax (right), puncture of intra-abdominal viscera.

* Now-a-days, USG or CT-guided biopsy reduces the rate of complications. Actually, if the performer is skillful and the patient is carefully selected, the rate of complications are less.

Ideal biopsy tissue :

It is surprising that a small biopsy tissue is the representative of changes in the whole liver. The biopsy tissue should be 1-4 cm long and should weigh 10-50 mg.

What is trans-jugular liver biopsy ?

When the patient suffers from massive ascites, coagulation disorder, small liver (from cirrhosis

commonly) or is really uncooperative, a special Trucut needle is inserted to perform the biopsy through a catheter which is already placed in the hepatic vein, via the jugular vein. The extra advantage of this method is the measurement of the wedged hepatic venous pressure.

* Liver biopsy is done by 4 methods : 1. Percutaneous (by Vim-Silverman's needle) 2. Trans-jugular 3. Laparoscopy 4. Laparotomy (if done for some other reason).

** The modem 'biopty gun' (Biopter) is a modified Trucut needle. If ascites is present, first go for paracentesis abdominis and then do the liver biopsy.

*** 'phe "Trucut' needle is less injurious to Vim-Silverman needle, and is disposable. The Trucut' needle (may be called as **tissue biopsy needle)** may be used for taking biopsy from liver, kidney, pleura. It has a trocar and canula, and the trocar is longer than the canula. It is also a cutting'needle; the cutting needle comprises a 10 cm pointed needle with a 2 cm notch close to the tip, enclosed by a cutting sleeve of 2 mm diameter. Menghini's needle is less injurious than others, so far the complications are concerned; and the success rate is approximately 75%. The success rate of Vim-Silverman's needle is high (approximately 95%).

**** Lj_{ver} biopsy needle may be used in *pleural biopsy* in the absence of Abram's or Cope's pleural biopsy needle. The needle is sterilised by immersing the seperated parts in concentrated lysol solution.

***** **Fine needle aspiration cytology (FNAC)** is less reliable than excisional biopsy. The technique usually obtains only a suspension of cells from within a mass. Cytology from unexplained mass of lymph nodes, thyroid, breast, bone, or pleura/liver/abdomen (USG or CT-guided) is examined by a skilled histopathologist. Though not full-proof, FNAC is very often the investigation of choice in early malignancy where the primary investigations do not yield any result.

LUMBAR PUNCTURE NEEDLE

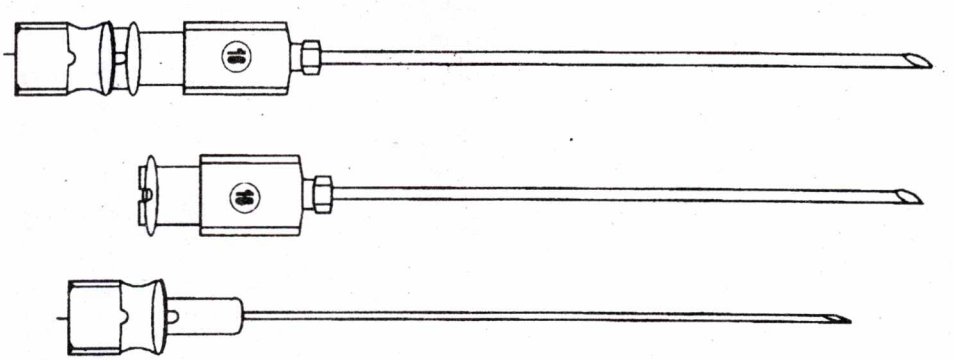

Fig. 1.6 : Lumbar puncture needle (the complete set, the needle proper and the stylet presented sequentially)

Description :

This is a slender malleable narrow-bore needle and consists of two parts like—

1. The needle proper—It is made of platinum-irridium or German alloy, and gives the needle its malleability (now-a-days, malleable steel is being used). The needle is round, slender, cannulated with a shortly bevelled tip and the usual length is 8 cm. The base of the needle fits with the knob (or projection) of the stylet and thus locks the stylet with the needle proper. The hole in the base allows the nozzle of a syringe for intrathecal injection.
2. The stylet—It maintains the patency of the needle i.e., prevents blockage of the needle proper. The knob (or projection) present at its base fits well with the groove present at the base of the needle proper. The length of the stylet should be such that if should not protrude through the bevelled cutting edge of the needle proper.

* The needle is sterilised by immersing the separated parts in concentrated lysol solution or by gamma ray irradiation. The needle is made malleable for finer adjustment during manipulation.

*What is lumbar **puncture** (L.P.) ?*

It is a manoeuvre by which a temporary artificial communication is made with the CSF pathway and *the* exterior (at lumbar region).

Indications of lumbar puncture :

(A) Diagnostic purpose—

a) Meningitis.
b) Subarachnoid haemorrhage.
c) Encephalitis.
d) Meningism.
e) Unexplained coma—Where the diagnosis can not be reached by other investigations.
f) G.B. syndrome (albumino-cytological dissociation) or multiple sclerosis (isolated rise in gamma-globulin).
g) Staging of lymphomas.
h) Miscellaneous : PUO, unexplained dementia, neurosyphilis, sarcoidosis, Behcet's syndrome, or neoplastic involvement of the central nervous system.
i) Queckenstedt's test for diagnosis of spinal subarachnoid block.
j) CT myelography (done in a suspected case of compressive myelopathy to diagnose the level of spinal block), cisternography or pneumoencephalography (done to demonstrate cerebral atrophy; obsolete now.)

N.B. : L.P is done cautiously in a suspected case of spinal subarachnoid block (Froin's syndrome) as it may aggravate the neurodeficit.

(B) Therapeutic purpose—

a) Intrathecal administration of drugs e.g., methotrexate in acute lymphoblastic leukaemia (previously streptomycin was administered in tuberculous meningitis).
b) Spinal anaesthesia, specially in operation of lower adbomen, lower limbs dr in perineal surgery.
c) To relieve intracranial tension in hydrocephalus (risky and not used commonly) or benign intracranial hypertension.

N.B. : While using a drug intrathecally, at first withdraw equal amount of CSF by L.P. needle and then push the drug slowly in strict asepsis.

* L.P. is not done routinely in CVA (cerebrovascular accidents) patients except in case of subarachnoid haemorrhage; L.P. should be avoided in infants, if possible.

Contraindications of lumbar puncture :

1. ***Papilloedema*** *or any otherfeature of high rise of intracranial tension (may precipitate cerebellar pressure cone syndrome*—so, *ophthalmoscopy is a must* before performing lumbar puncture).
2. Local sepsis or bed sore (may lead to meningitis, arachnoiditis).
3. Gross bony deformity in lumbar region or any congenital lesion like meningocele.
4. Restless patient/non-cooperative patient/very low general condition/bleeding diathesis/suspected spinal cord compression, suspected posterior fossa tumour.

What is 'cerebellar pressure cone syndrome' or 'cerebellar coning' ?

It is the tentorial herniation or tonsillar herniation leading to sudden death due to compression of vital centres (i.e., as a result of descent of cerebellar tonsil). The syndrome develops if lumbar puncture is done in the presence of raised intracranial tension (e.g., brain tumour). The patient suddenly becomes drowsy, with positive neck stiffness and dilaled pupil; Cheyne-Stokes respiration/irregular slow respiration -» decorticate posturing -> bilateral Babinski's sign -> apnoea -»bradycardia coma and death may supervene.

How the lumbar puncture tray is prepared ?

1. Spirit, iodine, sterile gown and gloves for antiseptic purpose.
2. 2% lignocaine solution as local anaesthetic.
3. Sterile L.P. needle with stylet.

4. Sterile plain glass test tubes (three).
5. 2 ml glass syringe with needle for local anaesthesia.
6. Sterile gauze and gauze-holding forcep.
7. Benzoin solution with cotton.
8. Leucoplast.

How the lumbar puncture is performed ?

1. The patient is first explained the procedure to obtain full cooperation. Lumbar puncture is best done when the patient is kept in one lateral position (right or left) at the edge of the bed with the knees drawn-up against the abdomen and head flexed (actually an assistant helps in approximating the chin of the patient with his knees). The flexion posture helps in increasing the interspinous space on which the success of L.P depends. L.P may be done in sitting posture of the patient (e.g., in lumbar spondylosis).
2. *The puncture is usually done between L_3 and L_4 interspace,* $^1/_2$" on either side of the midline **(puncture site**—-join the highest points of iliac crests by a line and it will pass through L_4 spine; puncture the space just above this line). The spinal cord ends at the lower border of L_1 vertebra and thus there is no risk of injuring the cord. A space above or below may also be used in a desperate situation.
3. The physician washes his/her hands and wears gloves. Then the puncture site is properly cleansed with spirit-iodine-spirit from centre-outwards and above-downwards. The site is now infiltrated with 2% lignocaine solution.
4. Reconfirm the puncture site. Keeping the bevelled end upwards, the L.P. needle with the stylet in position, it is introduced a bit obliquely in upwards and forwards direction (oblique introduction will not cause any injury to the theca) by cork-screw movement. The ligamentum flavum is pierced and the destination of spinal subarachnoid space is indicated by sudden loss of resistance (penetration of the dura matter), and is actually confirmed by CSF coming out drop by drop when the stylet is withdrawn (the needle passes through the skin, interspinous ligament, ligamentum flavum, the dura and the arachnoid matter). If CSF does not come out. slightly rotate the needle or introduce it inwards slightly. If the CSF still fails to come, withdraw the needle and introduce it again.
5. The rate of flow of CSF is noted and is collected in three sterile test tubes each containing minimally 10 drops to maximally 2 ml.
6. The stylet is reinserted and the L.P. needle is withdrawn. The site is now sealed with tincture benzoin solution and leucoplast.

* Manometric study may be done prior to collection of CSF. The CSF pressure rises and falls with respiration and heart beat, and rises on coughing.

Management of post-lumbar puncture period :

1. The patient is kept in bed for next 8-24 hours under observation.
2. Plenty of water to drink (to prevent post-lumbar puncture headache).
3. *Foot end of the bed is raised* with no pillow below the head (to prevent post-lumbar puncture headache).

Complications of lumbar puncture :

1. Traumatic puncture (trauma to vessel, nerve, intervertebral disc).
2. Post-lumbar puncture headache or low-tension headache.
3. 'Coning' or cerebellar pressure cone syndrome.
4. Breaking of the needle.
5. Introduction of infection (meningitis, arachnoiditis).
6. Bleeding (due to puncture of para-vertebral venous plexus).
7. Low backache.
8. Aggravation of root pain and signs of cord compression (in the presence of spinal cord tumour).

What is post-lumbar puncture headache ?

This usually occurs In patients where L.P Is done with normal intracranial tension. Headache (bifrontal and/or occipital) appears after few hours, stays for few hours to few days, and is enhanced on assuming sitting or standing posture. It is due to low intracranial tension produced as a result of :

a) Withdrawal of CSF, and

b) Continuous leakage of CSF through the puncture site in the theca.

Low tension exerts traction on the meningeal blood vessels (pain-sensitive) and results in headache. The headache (usually a dull-ache) may be avoided by adopting these preventive measures:

1. Using a narrow-bore L.P. needle.
2. Not withdrawing over 10 ml CSF.
3. Oblique introduction of the needle (transverse introduction 'divides' or tears' the fibres of dura and ligamentum flavum but oblique introduction 'seperates' the fibres, and thus chance of CSF leakage is less if the needle is introduced obliquely).
4. Slow withdrawal of CSF.
5. The patient is kept lying in bed for 8-24 hours with foot end of the bed raised. Putting the patient in prone position may relieve headache.

[6. Treatment of headache is done by drinking large amount of water and application of NSAID].

* Prolonged headache is recently being treated by 'autologous intrathecal blood patch' i.e., by injecting 20 ml of the patient's venous blood into the CSF.

How much CSF should be withdrawn at a time ?

1. For diagnostic purpose—Usually 5-8 ml.
2. For therapeutic purpose—Usually 10-20 ml (the amount of drug in volume should be measured first and then the same amount of CSF is withdrawn; now the drug is pushed into the subarachnoid space after fitting a syringe with the L.P. needle).

Thick-bore needle—advantage and disadvantage :

(A) Advantage—Helps in drawing thick purulent material in pyogenic meningitis.

(B) Disadvantage—Post-L.P. headache and cerebellar pressure cone syndrome may develop as large amount of CSF may be withdrawn.

What is a dry tap ?

CSF does not come out through the L.P needle in :

1. Faulty technique (needle not in subarachnoid space), incorrect position of the patient or needle blockage. If the needle is blocked, insert the stylet again to dislodge any dural flap, if present.
2. Spinal subarachnoid block.
3. Presence of very thick pus.
4. Lumbar subarachnoid space filled up with neoplastic tissue or obliterated by adhesive arachnoiditis.
5. Obstruction near foramen magnum as a result of basal meningitis.
6. Lipoma or dermoid (may be present in a case of spina bifida).

What is Queckenstedt's test ?

This test detects the patency of CSF pathway. It is done along with the lumbar puncture. Rise of CSF pressure is noted which is normally > 40 mm of CSF or H_20, after the compression of internal jugular vein *(negative test).* If the rate of flow of CSF is not increased after either jugular venous compression, the test is declared positive (CSF pressure is usually detected by a spinal manometer). *A positive test* is obtained after complete spinal block (partial block gives negative result). Spinal block may result from arachnoiditis, meningioma or neurofibroma.

If CSF pressure rises after compression of one internal jugular vein but not with the other, it is known as positive Tobey-Ayer test and is found in lateral sinus thrombosis.

* Compression of internal jugular vein results in congestion of cerebral veins and the rise in venous pressure leads to increased pressure in CSF.

Other uses of L.P. needle :

1. Cisternal puncture (used during myelography to delineate the upper limit of spinal subarachnoid block).
2. Splenoportal venography (to diagnose portal hypertension).
3. Paracentesis thoracis or paracentesis abdominis.

CSF dynamics and other details :

CSF is formed by the choroid plexus of lateral (major source), 3rd and 4th ventricles. CSF circulation : choroid plexus of lateral ventricles — Foramen of Monro — Third ventricle — Aqueduct of Sylvius — Fourth ventricle in the medulla — Foremen of Magendie and Luschka — Cisterna magna and cistema pontis — Subarachnoid space. CSF is absorbed by arachnoid villi.

Normal CSF values :

(A) Amount or volume : 100-150 ml (approximately 130 ml in adults). Daily formation of CSF is 1500 ml.

(B) Pressure :

a) 60-150 mm of CSF (lying position), and

b) 150-250 mm of CSF (sitting position)

* *Roughly, the CSFJlow (pressure) is equivalent to 1 drop/second on lumbar puncture*

(C) Colour : Crystal clear or colourless

(D) P^H and specific gravity : 7.31-7.34 and 1007 respectively

(E) Biochemical :

(a) Protein : 20-40 mg%

(b) Sugar : 40-80 mg% (usually 1/2 to 2/3rd of the random blood sugar concentration)

(c) Chloride : 720-750 mg%

(F) Cells : 0-5 cells/mm^3 and all are mononuclear cells (70% lymphocytes and 30% monocytes)

(G) Bacteriological : Sterile

(H) Oligoclonal bands: Negative

** The CSF IgG index (normal value is < 0.65) is the ratio of IgG to albumin in the CSF divided by the same ratio in the serum; though the total CSF protein is usually normal or slightly elevated, the CSF IgG index is increased in multiple sclerosis, where the abnormal CSF IgG may be oligoclonal.

*** CSF ammonia (normal : 25-80 Hg/dl) may be increased in hepatic encephalopathy.

Table 1 : Differentiation between traumatic and non-traumatic haemorrhage

Test	Traumatic	Non-traumatic
1. CSF collected serially in 3 test tubes	**1. First tube is bright red and the next two tubes are faintly red**	**1. Uniformly red**
2. Supernatent fluid after centrifugation or on prolonged standing	**2. Clear**	**2. Yellowish or xanthochromic**
3. Shape of the RBC	**3. Normal**	**3. Crenated**
4. Coagulation of blood	**4. Occurs**	**4. Does not occur**

How the examination of CSF is done ?

(A) Physical : Pressure, colour, fibrin clot.

(B) Biochemical : Protein, sugar, chloride concentration.

(C) Cytological : Number and types of cells are analysed (whether polymorphonuclear or lymphocytic pleocytosis present, or not).

(D) Bacteriological including staining and culture.

(E) Serological : VDRL, Kahn test, Wassermann reaction may be helpful in neurosyphilis.

(F) Special : Lange's colloidal gold curve reaction (positive reaction indicates high globulin content of

CSF) Is positive in tabes dorsalis (tabetic curve), GPI (paretic curve) and meningitis (meningitic curve). Polymerase chain reaction (PCR) for detection of DNA sequence of different bacteria or M. tuberculosis is done. Adenosine deaminase activity (ADA) is determined to rule out tuberculous meningitis.

Can an I.V. needle serve the purpose of lumbar puncture ?

Yes (in dire emergency, in the absence of L.P. needle). Now-a-days very slender, highly malleable disposable L.P. needle is available which are used by anaesthetists in spinal anaesthesia.

While performing L.P., how do you identify or suspect different diseases ?

1. Difficulty in flexing the neck of the patient at the beginning (i.e., presence of neck stiffness)—Meningitis, meningism, subarachnoid haemorrhage, cerebral malaria or meningoencephalitis.
2. Unconscious patient—Meningoencephalitis, cerebral malaria, meningitis, meningism, subarachnoid haemorrhage.
3. CSF coming out at a flow rate of > 1 drop/second (opening pressure)—See the causes of increased intracranial tension in the section on 'Charts on CSF'. Low CSF pressure is found in bad needle placement, partial spinal block, severe dehydration and after repeated lumbar puncture.
4. Appearance or colour of CSF—■„
   a) Clear—Normal, tuberculous and viral meningitis, meningism.
   b) Turbid—Pyogenic meningitis (due to high leucocyte count), rarely in carcinomatous meningitis and subarachnoid haemorrhage.
   c) Straw-coloured—Tuberculous meningitis.
   d) Haemorrhagic—Subarachnoid haemorrhage, trauma, extensive cerebral haemorrhage, haemorrhagic encephalitis, bleeding diathesis.
   e) Xanthochromia—See the section dealing with 'charts' on 'Xanthochromia'.
5. Coagulum on standing—
   a) Cobweb coagulum (forms after few hours)—Tuberculous meningitis (most important cause), acute anterior poliomyelitis and neurosyphilis.
   b) Big coagulum (forms immediately or shortly after withdrawal)—Spinal subarachnoid block, G.B. syndrome.
6. Manometry—Queckenstedt's test is positive in complete spinal subarachnoid block.

Examinaton of CSF in different diseases :

(A) Pyogenic meningitis :

Pressure —High (++)
Colour—Turbid
Total cells—Increased +++ (200-5000/mm^3); predominantly polymorphonuclear pleocytosis
Protein—Increased (++)
Sugar—Low (—)
Chloride—A bit reduced
Gram's stain—Gram -ve diplococci, or Gram +ve cocci in pairs

(B) Tuberculous meningitis :

Pressure—High (++)
Colour—Clear
On standing—Formation of cobweb coagulum
Total cells—Increased ++ (200-500/mm^3); predominantly lymphocytic pleocytosis
Protein—Increased (++)
Sugar—Low (-)
Chloride—Low (—) (may be due to prolonged vomiting)
Ordinary culture shows no growth (sterile)

* *Cobweb coagulum* indicates presence of mild to moderate rise of protein along with fibrinogen in CSF

(C) Viral meningitis :

Pressure—High (++)

Colour—Clear

Total cells—Increased + (approximately 150-200/mm^3); predominantly lymphocytic pleocytosis (may be mixed pleocytosis for first 36 hours)

Protein—Increased (+) or normal

Sugar—Normal

Chloride—Normal

Ordinary culture is sterile

(D) Carcinomatous meningitis :

Pressure—High (++)

Colour—Clear or haemorrhagic

Total cells—Plenty (T lymphocytes), malignant cells +

Protein—Increased (+)

Sugar—Normal

Chloride—N ormal

(E) Subarachnoid haemorrhage :

Pressure—High (++)

Colour—Blood-stained, turbid or xanthochromia

Total cells— Plenty; RBC +++, few are crenated

Protein—Raised (protein from blood is added to CSF)

Sugar—Normal

Chloride—Normal •

On centrifugation—Supematent fluid is yellow

Culture—No growth (sterile)

(F) Meningism :

Pressure—High (++)

Colour—Clear

Total cells— 0-5 cells/mm^3 (all mononuclear cells)

Protein, sugar and chloride—Within normal limit

Gram's stain—Nothing could be detected

Culture—Sterile •

(G) Xanthochromia :

Pressure—Very low or nil

Colour—Xanthochromic (yellowish)

On standing—Formation of big coagulum

Total cells— 0-5 cells/mm^3 (all mononuclear cells)

Protein—Increased (++)

Sugar—Normal

Chloride—Normal

Queckenstedt's test—Positive (i.e., no rise in CSF pressure on compression of internal jugular vein).

Culture—sterile

* This is a chart of complete spinal subarachnoid block with albumino-cytological dissociation

N.B. : Lumbar puncture is a very important bedside diagnostic tool though now-a-days radiodiagnosis (e.g., CT scan) is gaining importance over this age-old practice.

I. V. FLUID BOTTLE AND INFUSION SET

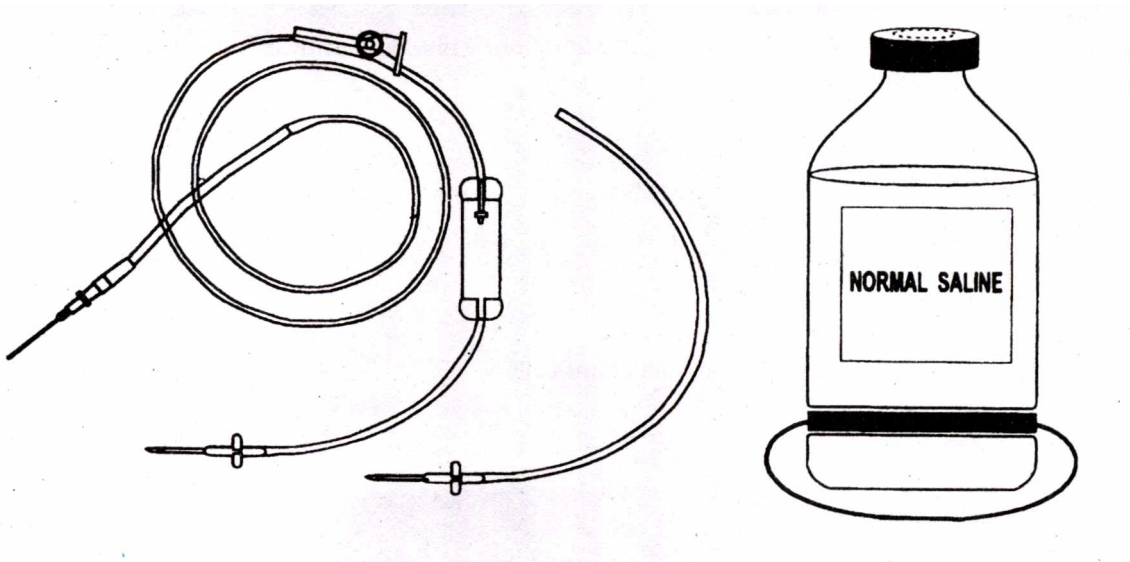

Fig. 1.7 : Drip tube, airway tube and the I.V fluid bottle

Description :

(A) Bottle : 540 ml; made of glass or plastic. The glass bottle has a rubber stopper in the mouth with two openings (one for air entry and the other for fluid outlet). Plastic bottle has now replaced glass bottle.

(B) Infusion set :

a) One long plastic tube (drip tube) with two needles on two sides—One enters into the bottle and the other enters into the patient's vein. A small part of the plastic tube (near the patient's vein) is replaced by a rubber tube to inject drugs by shot-push. In the middle of the tube, there is a small plastic container (Murphy's chamber) to measure the flow of the running fluid. The rate of flow of the fluid is controlled by an adjustable valve attached to the set.

b) A small plastic tube with a needle for air entry in the bottle (airway tube).

* *Blood transfusion* set contains a 'strainer' (to filter clots) in the Murphy's chamber.

What is Murphy's chamber ?

It is a plastic or glass chamber attached to the infusion set to regulate the flow of fluid. It has two ends: through the inlet fluid enters into the chamber (via a glass tube), and through the outlet fluid leaves the chamber. For proper flow of fluid, a fluid level should be maintained in the chamber; if the chamber is fully occupied by fluid, it has to be reset.

What is a micro-drip set ?

It is the same variety of l.V set but contains a small calibered lumen in the Murphy's chamber. In ordinary l.V set, 15 drops of fluid make 1ml but in microdrip set 60 (micro) drops constitute 1ml of fluid. The microdrip set is used when very small and accurate quantity (e.g., microgram dose) of a drug is used in l.V route e.g., dopamine, dobutamine, nitroglycerine etc.

How to set-up a drip ?

Indications :

1. Replacement of fluids (crystalloids, blood products, different electrolyte solutions).
2. To establish an external route for administering l.V medication or nutrition.

* **Crystalloids** i.e., solutions containing solutes that can pass a semipermeable membrane —> rapidly expand both intravascular and extravascular compartments; examples are dextrose, normal saline. Ringer's lactate solution, mannitol. **Colloids** i.e., solutions containing large molecules which do not pass semipermeable membrances -» expand the intravascular space more efficiently; examples are albumin, dextran, haemaccel, blood and hetastarch.

Choice of site :

Most convenient sites for peripheral cannulation are veins over the forearm, wrist or elbow. Selection of left side allows the comfortable mobility as well as different activities of right arm. If veins of the upper extremity is not available, veins of ankle or feet are used. Other sites of cannulation are subclavian or jugular vein.

Precautions :

1. In patients with renal failure, there is a chance of fluid overload.
2. In patients with heart failure, problems may be alleviated by prior administration of a diuretic.
3. Proper asepsis is required to start a drip in patients who are immunocompromised or having valvular heart disease.
4. Always choose a vein with adequate calibre to maintain a smooth flow.

Procedure :

1. All the clothes are removed from the site of puncture and a tourniquet is applied proximally to make the vein distended and prominent. The puncture site is cleared with spirit properly.
2. Keeping the needle parallel to the vein chosen and with the bevelled edge facing upwards, the vein is pierced; by moving the needle, it is continued for a distance within the lumen of the vein. Now, the tourniquet is released and let the fluid from the bottle flow within the vein through the l.V infusion set. The adjustable valve attached with the l.V set controls the rate of flow of the fluid. The needle is fixed to the skin with adhesive tape (leucoplast) and the limb may be splinted with a wooden piece.
3. Follow-up : Look for any sign of inflammation (redness, thrombophlebitis, brawny induration) at the puncture site. A set should not be continued for more than 2-3 days and should be replaced.

N.B. ; If no veins are visible after intensive search for intravenous infusion of fluids, a venesection or **'cut-down'** procedure may be employed in ankle, antecubital fossa or wrist in a desperate situation. Always change the puncture site (i.e., reintroduce in other site) with the appearance of first sign of inflammation (i.e., thrombophlebitis). If continued, pyrexia may complicate the situation. Many a time, inflammation at the venepuncture site of a drip is responsible for unexplained fever.

How to change the bottle / discontinue infusion :

To change the bottle, the adjustable valve attached with the l.V infusion set is locked to prevent entry of air in the tube distal do it. Now, the empty infusion bottle is replaced by a new one.

To discontinue infusion, the adjustable valve is locked; the l.V needle is removed and a sterile dressing is applied over the puncture site.

Content of bottles ;

1. Normal saline or isotonic saline (0.9%).
2. Glucose or dextrose solution (5%, 10%. 20%, 25%, 50%).
3. Dextrose-saline solution.
4. Sodium lactate solution.
5. Hypertonic saline (3% or 5%).
6. Ringer's lactate solution.
7. Darrow's solution.
8. Mannitol (5%, 10%, 20%).
9. Haemaccel.
10. Low molecular weight dextran.

* Now-a-days, multiple electrolyte solutions (e.g., electrolyte R, electrolyte M etc.) are available and contains dextrose, sodium, potassium, calcium etc in varying combination. Some are useful in maintaining daily requirements of water and electrolytes, and others for replacement of fluid loss.

Use of different parenteral fluids :

(I) Normal saline :

Its osmotic pressure is equal to that of plasma and this is why it is known as isotonic saline. The

fluid is also isotonic with the intracellular compartment of RBC and thus, called 'normal' saline; 0.9 gm of NaCl is dissolved in 100 ml of water (0.9%). Now-a-days, it is available in 100 ml, 250 ml, 500 ml, 1000 ml and 2000 ml plastic containers.

Uses :

1. To correct salt-water depletion (e.g., diarrhoea and vomiting).
2. To correct dehydration and hypovolaemia.
3. Acts as a vehicle for l.V. drug administration (e.g., iron-sucrose infusion).
4. To maintain the fluid balance parenterally when oral intake is not possible.
5. In treating alkalosis.

(II) Glucose or dextrose solution :

It is available in different concentration (usually 5%, 10% and 25%).

Uses :

1. Acts as a vehicle for l.V. drug administration.
2. To provide adequate calories to the body; to correct pure H_aO deficit.
3. Hypoglycaemic coma (high concentration is used).
4. As fluid and nutrient replenisher.
5. As a mild osmotic diuretic (10%).
6. 50% solution may reduce cerebral oedema.

(III) Dextrose-normal saline solution (DNS) :

Usually available as 5% glucose plus 0.9% (normal) saline.

Uses :

1. In patients who need additional fluid with minimal sodium intake.
2. As an initial hydrating solution to establish normal renal function.
3. In the presence of metabolic alkalosis (e.g., repeated gastric suction)—Fluid loss with loss of Cl" is compensated.

(IV) Sodium lactate solution :

It is available in two strength,

a) Molar sodium lactate solution, and

b) 1/6th Molar lactate solution.

Sodium ion of sodium lactate combines with HCo" (coming from lactate) and forms $NaHCo_3$, and the blood becomes alkaline.

Uses :

1. Metabolic acidosis e.g., diabetic ketoacidosis.
2. To treat hyperkalaemia (alkalosis reduces the level of serum potassium level).

(V) Hypertonic saline (3% or 5%) :

Prepared by dissolving 3 gm or 5 gm of Nacl in 100 ml of water. The osmotic pressure of hypertonic saline is higher than that of plasma.

Uses :

1. Severe hyponatraemia.
2. Syndrome of inappropriate ADH secretion (SIADH).

(VI) Ringer's lactate solution :

Uses :

1. Fluid of choice in treating cholera.
2. Bums, severe infections, peritonitis, multiple fractures.
3. Replacing deficit of extracellular fluid (ECF) due to decreased water intake or increased excretion of water.
4. Deficiency of Nacl and K^+ with acidosis.

* Electrolytes concentration in Ringer's lactate is almost the same as that of plasma.

(VII) Darrow's solution :

Uses :

1. Treatment of hypokalaemia.
2. In the management of diabetic ketoacidosis.

(VIII) Mannitol (usually 20% solution is used; available in 100, 350 and 500 ml bottle) **:**

Uses :

1. To reduce increased intracranial tension due to any cause.
2. To expedite the urinary excretion of toxic metabolites.
3. Treatment of acute renal failure.
4. To reduce intraocular tension (when other drugs fail).

(IX) Haemaccel (polygeline) :

Uses :

1. Shock or peripheral circulatory failure.
2. To raise the BP in hypotension.
3. Priming of heart-lung machine and artificial kidney.
4. As a plasma expander while performing paracentesis abdominis in cirrhosis of liver.

(X) Low molecular weight (average 40000) dextran :

Uses :

1. Shock.
2. Foetal distress syndrome.
3. Prevention of peritoneal adhesions.
4. As a plasma expander.

Advantages and disadvantages of parenteral (l.V) fluid therapy :

(A) Advantages :

1. Rapid correction of deficit.
2. All types of fluid can be given.

(B) Disadvantages (complications) :

1. Thrombophlebitis.
2. Extravasation with local cellulitis (swelling and oedema); needle blockage.
3. Haematoma formation.
4. Pyrogen reaction with fever.
5. Overloading with injudicious administration, resulting in heart failure (development of pulmonary oedema) and/or renal failure.
6. Chance of transmission of infection, if proper asepsis is not maintained.
7. Air embolism.

Table 2 : Composition of plasma and different l.V. fluids (mmol/L)

Different fluids	Na	K	Cl	Lactate
Plasma	136-145	3.5-5.0	98-106	–
Isotonic saline	153	—	153	—
Ringer's lactate	130	4	110	28
1/$_6$th Molar lactate	167	—	—	167
Darrow's solution	124	36	104	56

* Normal plasma $HC0_3$ level is 22-26 meq/1.

15 drops make 1 ml of fluid.

Normal plasma osmolality is 280-300 mosmol/kg of water.

Approximate **composition of plasma** (mmol/litre) : Na-141, K-4, Ca-2.5, Mg-2, C1-I00, $HC0_3$-25, $P0_4/S0_4$-1, and protein/acid is 25 = 300 (approx); Na and Cl are main ions in extracellular fluid, and K and $P0_4$ are those of the intracellular fluid.

Approximately 50-60% of body weight is 'total body water'. p^H of blood varies between 7.38 and 7.44 (average 7.40).

** l.V infusion set may also be used to remove ascitic and pleural fluid. It may be used temporarily in water-seal drainage to treat a case of spontaneous pneumothorax.

*** For calculation of rate of fluid infusion, read 'Cholera with severe dehydration' in 'Emergency medicine' section. l.V fluid is 'infused' while blood is 'transfused'.

Causes of metabolic acidosis

1. Diabetic ketoacidosis.
2. Renal failure.
3. Severe diarrhoea.
4. Starvation.
5. Lactic acidosis.
6. Poisoning by methyl alcohol, salicylates.
7. Hypoaldosteronism.
8. Renal tubular acidosis.

Causes of metabolic alkalosis :

1. Severe vomiting or vigorous gastric aspiration.
2. Cushing's syndrome.
3. Primary hyperaldosteronism.
4. Severe hypokalaemia.
5. Milk-alkali syndrome.
6. Diuretics (frusemide, thiazides).

Causes of respiratory acidosis :

1. Depression of respiratory centre by disease or drugs.
2. Central sleep apnoea.
3. Sudden failure of ventilation (e.g., myasthenic crisis).
4. Chronic bronchitis, emphysema.

Causes of respiratory alkalosis :

1. Pneumonia, bronchial asthma, acute pulmonary oedema, high altitude (due to hypoxia).
2. Exercise.
3. Anxiety, fever, salicylate overdose (due to stimulation of respiratory centre).
4. Hysterical hyperventilation.

* Disorders	p^H (7.40)	Primary defect	Compensatory effect
Metabolic acidosis	Low	Low HCo_3	Low $PaCo_2$
Metabolic alkalosis	High	High HCO_3	High $PaCo_2$
Respiratory acidosis	Low	High $PaCo_2$	High HCO_3
Respiratory alkalosis	High	Low PaCo.,	Low HCo„

What is anion gap in 'metabolic acidosis' ?

It is the 'unmeasured anions' and are calculated by subtracting the sum of plasma bicarbonate and chloride concentrations (i.e., the measured anions) from plasma concentration of sodium (i.e., the measured cations).

Anion gap = Na^+ - (HCO_g~ + CL)

The normal anion gap is 10-12 mmol/l; most of the anion gap is due to negative charges on plasma proteins (mainly albumin), and phosphate, sulphate and organic acid anions to a lesser degree. When acid anions e.g., acetoacetic acid or lactic acid accumulate in ECF, it results in high-anion gap acidosis.

(A) Increased anion gap :

1. **Diabetic ketoacidosis (or ketoacidosis from alcoholism and starvation).**
2. **Acute and chronic renal failure.**
3. **Lactic acidosis.**
4. **Ingestion of toxins or drugs (salicylate, carbenicillin, ethelene glycol, methanol).**

(B) Normal anion gap (hyperchloraemic acidosis) ;

1. **Diarrhoea.**
2. **Intestinal fistula.**
3. **Ureterosigmoidostomy.**
4. **Renal tubular acidosis.**
5. **Hypoaldosteronism.**
6. **Ingestion of toxins or drugs (ammonium chloride, cholestyramine).**

Causes of hyponatraemia :

1. Severe diarrhoea, vomiting, peritonitis, burns, excess of diuretics, uncontrolled diabetes mellitus, CRF (all producing 'volume depletion', i.e., loss of both Na^+ and water).
2. Congestive cardiac failure, SIADH (syndrome of inappropriate ADH secretion), cirrhosis of liver, nephrotic syndrome, acute and chronic renal failure.
3. Adrenocortical failure, hypothyroidism, hypopituitarism, psychogenic polydipsia.

Causes of hypematraemia :

1. Diabetes insipidus, diabetes mellitus (when water loss is more).
2. Cushing's syndrome.
3. Primary hyperaldosteronism.
4. Infusion of hypertonic saline.

Causes of hypokalaemia:

1. Diaminished dietary intake (e.g., starvation).
2. Vomiting, diarrhoea, intestinal fistula.
3. Diuretics (e.g., loop diuretics).
4. Metabolic alkalosis.
5. Aldosteronism (primary or secondary).
6. After administration of insulin..
7. Diabetic ketoacidosis.
8. Hypokalaemic periodic paralysis.

Cause of hyperkalaemia:

1. Renal failure (acute or chronic).
2. Addison's disease, hypoaldosteronism.
3. Metabolic acidosis.
4. Tissue damage e.g., internal bleeding or muscle crush.
5. Potassium-sparing diuretic e.g., spironolactone, triamterene, amiloride, or use of ACE-inhibitors like enalapril or lisinopril.

Indications of 'blood transfusion' in medical ward :

One unit of whole blood contains approximately 500 ml of blood (i.e., nearly 2 bottles in India).

1. Restoration of volume of circulating blood : Acute haemorrhage e.g., haematemesis, melaena, haemoptysis, epistaxis, haematuria, menorrhagia.
2. Severe anaemia due to any cause : Aplastic anaemia, anaemia of chronic renal failure, thalassaemia, disseminated malignancy, hookworm infestation, severe iron deficiency anaemia. AIDS.
3. Granulocyte transfusion : Severe neutropenia, neonatal sepsis, progressive fungal infection, chronic granulomatous disease.
4. Platelet transfusion : Severe thrombocytopenia or platelet dysfunction.
5. Exchange transfusion : Haemolytic disease of newborn, thrombotic thrombocytopenic purpura, severe falciparum malaria, poisoning (e.g., methaemoglobinaemia or arsine-induced haemolysis).
6. Fresh blood transfusion : In coagulation disorders e.g., haemophilia or thrombocytopenia (e.g., idiopathic or immune thrombocytopenic purpura or ITP); viperidae group of snake bite.

'Total parenteral nutrition (l'PN) **therapy'** through subclavian vein is required in 'specialized nutrition support' (where oral therapy may be harmful or may not be possible) delivered in extensive small bowel disease, intestinal fistula, prolonged hyperemesis gravidarum, severe intra-abdominal sepsis, acute pancreatitis, inflammatory bowel disease, severe cachexia (e.g., cancer, AIDS), in patients on ventilation or any critical illness. This is usually done in an ITU (Intensive Therapeutic Unit) setting. For a central venous TPN regimen, a pre-mixed (contains L-amino acids, lipids, glucose with vitamins, electrolytes and trace elements) 3-litre bag is infused over 24 hours with close monitoring.

SYRINGE (5 ML/50 ML)

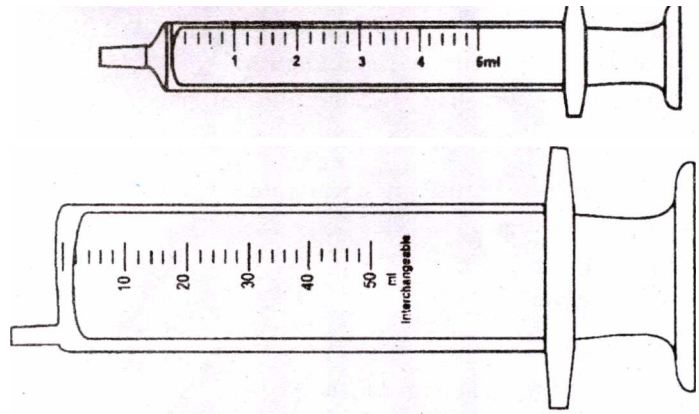

Fig. 1.8 : 5 and 50 ml syringes

Description :

A syringe has two parts,

a) Air-tight piston, and

b) Cylinder with a nozzle at one end for fitting tightly with the base of a needle, scalp vein set or adaptor. The cylinder possesses markings on its outer surface indicating the volume of the drug to be delivered.

The syringe is usually made of glass. Disposable plastic syringe is for single use. This.type of syringes (5ml) are often called 'hypodermic' syringe.

Sterilisation :

1. Keeping (heating) in boiling water minimally for 30 minutes, seperating the piston and cylinder (before putting in water, loosely wrap the piston and cylinder with sterile gauze).
2. Autoclaving.
3. Gamma ray irradiation.
4. Ethelene oxide.

Different uses :

(A) 5 ml syringe—

a) Collection of venous blood samples for laboratory analysis, aspiration from cyst/abscess, for myelography /I VP etc.

b) Parenteral administration of drugs by different routes like I.M (inj. tetanus toxoid), l.V (antibiotics), subcutaneous (terbutaline, adrenaline, erythropoietin), intracutaneous (drug sensitivity, Mantoux test), intra-arterial (arteriogram), intra-articular (corticosteroid), intrathecal (methotrexate in ALL), intrapleural (for pleurodesis) and intraperitoneal (anti-metabolites).

(B) 50 ml syringe—

a) Ryle's tube feeding; gastric aspiration in intestinal obstruction, pyloric stenosis, haematemesis or poisoning.

b) Aspiration of pleural and pericardial fluid, paracentesis abdominis.

c) l.V aminophylline injection.

d) . Aspiration of amoebic liver abscess.

e) Gastric wash by ice-cold saline in intractable hiccough.

* The 'all glass' syringe is known as B.D. syringe (B and D stand for the manufacturer, Beckton and Dickinson). B.D. syringe is available as 2 ml . 5 ml, 10 ml, 20 ml, 50 ml and 100 ml syringes.

** Venous blood collection—After adopting proper aseptic and antiseptic measures, venous blood sample is usually drawn from anticubital fossa after applying a venous tourniquet proximal to the chosen site.

The operator should wear double gloves as a protection against 'high risk' cases e.g., infection with hepatitis B or C, HIV. For femoral vein puncture (lies at the mid-inguinal point medial to femoral artery) *i.e., femoral tap,* insert the needle vertically just medial to femoral artery.

Disadvantages of I.M. injection :

1. Painful.
2. There may be abscess formation.
3. Injury to the nerve may occur.
4. Muscle haematoma in coagulopathy (haemophilia) or prolonged bleeding (ITP).
5. Fibrous nodule formation at the injection site.
6. Anaphylaxis.
7. Transmission of some dreadful infection like hepatitis B rarely (in contamination).

What is record syringe ?

Here, the cylinder (i.e., the body of the syringe) is made of glass while the piston and the long tapering nozzle are built of metal. Various sizes e.g., 2 ml, 5 ml, 10 ml and 20 ml syringes are available. Autoclaving is not possible as it is partly glass and partly metallic (the syringe may be damaged by autoclaving), and thus sterilisation is done by boiling. It can be used for I.M injections and bone marrow aspiration (as the piston can be locked in the body satisfactorily, the suction of the bone marrow can be well maintained).

What is anaphylaxis ?

This is an example of immediate hypersensitivity reaction (IgE-mediated). It is a group of severe reactions which occur in rapid succession in a sensitised person if an antigen is injected e.g., penicillin or sting of an insect, or rarely produced by ingested food in a highly sensitive individual.

Features :

Bronchospasm (wheeze), laryngeal oedema with severe dyspnoea, stridor and cyanosis, and feeling of impending doom; there is fall in BP (anaphylactic shock) and the patient may be unconscious. Swelling of the tongue, anorexia, nausea and vomiting, abdominal pain and diarrhoea may be present. Intense itching, urticaria and angioneurotic oedema (usually around the lips and eyes) may be seen.

Treatment :

It is a potentially fatal condition and if not treated promptly, it possess a threat to life.

1. Patient lies down with head-down position. Prevent further contact with the allergen.
2. Ensure airway patency and start O_a inhalation at the rate of 4-6 litres/min. Maintain an l.V line.
3. *Adrenaline—It remains the cornerstone of therapy;* 0.3-1.0 ml of 1:1000 adrenaline is injected subcutaneously or l.V; may be repeated.
4. Corticosteroids — Hydrocortisone 100-300 mg or dexamethasone 4-8 mg, l.V, to be given immediately and every 4-6 hourly.
5. Antihistaminics — Inj. diphenhydramine 25-50 mg, l.V given for adult and 10-25 mg for children may shorten the duration of anaphylactic reaction. Inj. chlorpeniramine 10-20 mg l.V may be given.
6. Inhaled beta agonist (slabutamol or terbutaline) may be used in bronchospasm; inj. aminophylline may be used as a second line drug.
7. Treatment of shock—Raise the foot end of the bed; start dopamine infusion. Use volume expanders (colloid solutions e.g., dextran is preferable).
8. Assisted ventilation (IPPV) or emergency tracheostomy may be done, if laryngeal oedema is severe.
9. Miscellaneous—Intravenous isoprenaline, salbutamol or terbutaline may be given.

How and where aminophylline injection is given ?

Aminophylline is commonly given in acute exacerbation of bronchial asthma. It may be given in severe bronchospasm due to any cause (e.g., anaphylaxis, acute exacerbation of COPD).

It is also known as theophylline with ethylenediamine. Usually one ampoule of inj. aminophylline contains 250 mg of the drug (in 10 ml). A loading dose of 6 mg/kg is started, followed by an infusion of 1.0 mg/kg/hour for the next 12 hours and thereafter 0.8 mg/kg/hour is maintained. In non-smokers, maintenance dose is less and in patients receiving theophylline, the loading dose will be 0.5 mg /kg. Aminophylline is mixed in the bottle of normal saline or 5% dextrose for infusion. The drug is given slowly in 1 . V route. Common side effects are nausea, vomiting, anorexia, seizures and cardiac arrhythmias.

At present, use of nebuliser has replaced administration of l.V aminophylline in acute severe asthma and COPD.

How do you diagnose amoebic liver abscess at the bedside ?

Pre-disposing factors — young adult males, consumption of alcohol, malnutrition.

Clinical features—

1. H/O amoebic dysentery is present in only 10%) cases. Onset is usualy subacute, rarely acute.
2. The patient looks ill, toxic and prostrated with a peculiar sallowness of the skin. There may be fever with chill, rigor and profuse sweating; temperature rarely exceeds 40°C; presence of emaciation.
3. Dull and aching pain or sensation of heaviness over right hypochondrium is present. Pain increases with deep inspiration and coughing. Patient tends to turn on the left side. Pain may be referred to the right shoulder. Later on, abdominal pain becomes sharp and stabbing.
4. Intercostal tenderness (important bedside clue to diagnosis). Local oedema may be present.
5. Enlarged, soft, tender liver. A bulge may be seen in the epigastrium.
6. Jaundice is unusual.
7. Spleen is not palpable. The lower zone of right lung may show features of consolidation, pleurisy (pleural rub) or pleural effusion.

* The most common site of amoebic liver abscess is in the right lobe of liver, often postero-superiorly and is usually single. The patient may present with PUO.

Indications of expiration in amoebic liver abscess :

The needle aspirates the characteristic 'anchovy-sauce' or 'chocolate' pus, which chiefly consists of liquefied nectrotic liver tissue. The pus is odourless, bacteriologically sterile, may contain few RBCs and occasional WBCs. The trophozoites of E. histolytica are usually absent in freshly aspirated pus but may appear in the escaping pus 4-5 days after initial aspiration. The indications for aspiration are :

1. Lack of response to 3-5-days of metronidazole treatment (i.e., failure to conservative therapy).
2. Very large abscess (> 10 cm in diameter) with or without threat of imminent rupture.
3. Abscess in the left lobe likely to rupture into the pericardium.
4. To rule out pyogenic abscess, specially with multiple lesions.

* Aspiration is usually done under USG or CT guidance.

Needle : description and uses :

The B.D. needle has a bevelled end, body and shoulder. The needles are available in different sizes, e.g., No. 20, i.e., it is 1/20 inch in thickness. The higher the number, the thinner is the needle. Now-a-days, disposable needles are available which are thrown away after single use.

Different uses : For I.M injection (No. 22-24), for collection of blood and l.V infusion (No. 18-20), for collection of blood from a donor (No. 16), and for aspiration of thick fluid from different body cavities (No. 12-14).

Sterilisation is done by boiling the needle for 30 minutes or by autoclaving.

What is venesection ?

When the veins are collapsed and venepuncture is difficult, usually the saphenous vein over the ankle is exposed to the exterior for maintenance of l.V infusion by making a small incision, and is known as venesection or 'cut-down'.

Arterial blood sampling : where and how done ?

It is done to assess the acid-base status in respiratory, renal, cardiac or hepatic failure (e.g., the

blood gas analysis); also done in drug overdose/intoxication (e.g., in aspirin poisoning or diabetic ketoacidosis). Radial artery of non-dominant hand, femoral or brachial artery is chosen for puncture. Prior to sampling, the laboratory should be informed not to delay unnecessarily. Expel the air bubbles from the 'pre-heparinised' syringe. After proper asepsis, draw the arterial blood and place the 'sample' on ice during transit to the laboratory. Haematoma formation (due to inadequate pressure haemostasis) is not uncommon.

SCALP VEIN SET

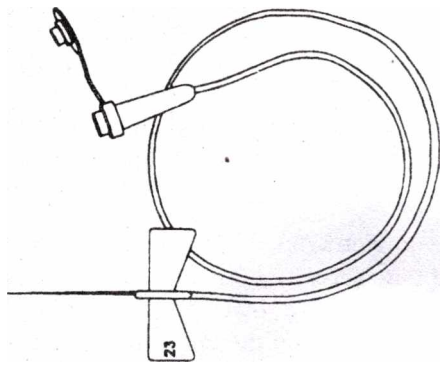

Fig. 1.9 : Scalp vein set (size 23)

Description :

1. A polythene tube—At one end, there is a fine needle (of different size) attached and the other end is open (wider and with a cap) where the nozzle of syringe or l.V set is fitted.
2. Two polythene flaps present on either side of the polythene tube near the needle—for fixation purpose by leucoplast.

* The polythene tube is relatively long to be used as a heparinised channel (see below) and so much so to make the scalp vein set flexible.

Different uses :

1. It is specially used in neonates, infants and small children where the calibre of the vein is small—can be used for parenteral fluid infusion and blood transfusion as well.
2. In adults—For the purpose of fluid infusion or blood transfusion specially when the patient is in shock or collapsed (needle of common l.V infusion set may be large in relation to a collapsed vein and thus, in that situation it may not be possible to place a big needle within the vein).
3. It may be used temporarily (making 'butterfly') for l.V medication administered by shot-push (e.g., in pyogenic meningitis, SBE, septicaemia), by introducing diluted heparin (0.5 ml) within the polythene tube of the scalp vein set with the cap kept closed (i.e., acting as a 'heparinised channel'). The heparinised scalp vein set may be kept in the antecubital vein for few days for the . purpose.of repeated infusion. Intracath has replaced the use of heparinised scalp vein set.

Why the 'scalp vein set' is named so ?

In the pediatrics ward, scalp veins may be used upto the age of 4 or 5 years for l.V infusion. Usually branches of temporal vein, posterior auricular vein and veins of the forehead are commonly used as they are constant in location and large in size. The head of the child is fixed; the local skin is shaved. Putting the bevelled end upwards and maintaining the direction towards the the heart, the needle is fixed at an angle of 30° (from the skin surface) with adhesive plaster. Previously, scalp veins were the preferred site fpr l.V infusion in the pediatrics ward because it would avoid restriction of movement of limbs. Now-a-days, pediatricians do not prefer to use the scalp veins as a recipient channel.

N.B. : Read 'dehydration' with patient's assessment and fluid replacement in details.

INSULIN SYRINGE



Fig. 1.10 : Insulin syringe with needle

Description :

This is a syringe with capacity of 1 ml. The cylinder has markings on its outer surface indicating the amount of insulin in units, present distal to the piston. Insulin syringe resembles tuberculin syringe though the piston is white in colour (not blue).

Insulin is available in India as 40 units/ml or 80 units/ml commonly, or 100 units/ml as available in abroad and thus, 1 ml is graduated into 40, 80 or 100 units.

Different uses :

1. To inject insulin in the subcutaneous (S.C) route in diabetic patients.
2. In neonates, insulin syringe may serve the purpose of a 'hypodermic syringe' for giving injections by I.M or S.C route.
3. Sometimes it is used to give a test-dose on the forearm before administering a drug (e.g., test of hypersensitivity reaction before giving injection penicillin).

* A **'tuberculin syringe'** (1ml syringe with a **blue** pistion; used for Mantoux test) may also be used in neonates for giving injection by I.M or S.C route. *Mantoux test* is a type IV or delayed type of hypersensitivity reaction to tuberculoprotein. 1 tuberculin unit (TU) is equal to 0.00002 mg International Standard PPD (purified protein derivative). Usually 1 TU is injected (0.1 ml PPD) intradermally on volar aspect of the forearm (junction of mid and upper third). The result is read after 72 hours (3rd day). If the skin 'induration' (thickening) across the transverse axis is < 10 mm, the test is negative and if > 10 mm, it is regarded as positive. The amount of erythema (redness) present is not important. A positive test is presumptive evidence of current (active) or prior (old) mycobacterial infection; the larger the diameter of induration (e.g., > 20 mm), the greater the support for a positive diagnosis. A negative test rules out the possibility of tuberculosis for practical purposes. But in a child below 3 years (non BCG-vaccinated), a positive test is commonly associated with active progressive disease. It should also be remembered that the Mantoux test may be negative in fulminant, miliary and meningeal tuberculosis, tuberculosis with low general condition, measles, lymphoma, sarcoidosis, leukaemia and in immunosuppression (steroid therapy, AIDS etc); technical error (S.C. injection instead of intradermal) may give rise to negative result.

The WHO advocates a PPD tuberculin known as PPD-RT-23 with Tween 80. In AIDS, an induration of 5 mm or more signifies a positive Mantoux test.

Different uses of insulin :

1. Diabetes mellitus—
   a) All type 1 DM patients.
   b) Diabetic ketoacidosis.
   c) Diabetes with pregnancy, labour and delivery.
   d) In periods of stress e.g., acute infection, major surgery, acute myocardial infarction, any acute medical illness, stroke, acute injury, or while on glucocorticoid treatment.
   e) In type 2 DM—Secondary failure of oral hypoglycaemic agents; or inadequate control with presence of complications like painful peripheral neuropathy/retinopathy; renal failure, hepatic failure or respiratory failure.
   f) Pre-renal transplantation diabetic patients.
2. Hyperkalaemia.
3. Insulin test or Hollander's test (not used now-a-days)—To know the completeness of vagotomy in a duodenal ulcer patient. Increase in 20 meq/1 of acidity above the basal level after injection of insulin indicates incomplete vagotomy (insulin-induced hypoglycaemia stimulates the neurogenic phase of acid secretion in stomach in the presence of intact vagus nerve).

Who first used insulin ?

On 23rd January 1922, Banting and Best first used pancreatic extract on a severely diabetic patient named Leonard Thompson. Banting received The Nobel Prize along with another physician JJR Macleod in the year 1923 for the discovery of insulin.

Table 3 : Available insulin preparations

Preparations	Time of action		
	Onset	Peak	Duration
Short-acting			
Lispro	5 min	0.5-1.5 h	3-4 h
Aspart	5 min	0.5-1.5 h	3-4 h
Glulisine	5 min	0.5-1.5 h	3-4 h
Regular	30 min	2-3 h	4-6 h
Intermediate-acting			
NPH (isophane insulin)	1-3 h	3-8 h	7-14 h
Lente	1-3 h	3-8 h	7-14 h
Long-acting			
Glargine	1-4 h	None	24 h
Ultralente	4-6 h	10-18 h	16-24 h
Detemir	1-4 h	2-12 h	12-20 h
Mixtures			
70/30, 50/50, 75/25	30 min	7-12 h	10-16 h

* Values (time of action) are highly variable among individuals. Even in an individual, values vary depending on the site and depth of injection, skin temperature and exercise.

** *Insulin combinations :* 70/30 (70% NPH, 30% regular); 50/50 (50% NPH, 50% regular), and 75/25 (75% protamine lispro, 25% lispro), 70/30 (70% protamine aspart, 30% aspart) and 50/50 (50% protamine lispro, 50% lispro) are different combinations used in clinical practice.

Insulin analogues :

These insulin preparations are generated by modifying (i.e., changing the amino acid sequence by recombinant DNA technology) human insulin, and are useful in patients having repeated attacks of hypoglycaemia or show hyperglycaemia during some parts of the day while on regular insulin therapy. Among the five insulin analogues, three are short-acting or rapid-acting (lispro, aspart, and glulisine) and two are long-acting (glargine and detemir) preparations.

Insulin secretagogues and sensitisers :

Insulin secretagogues : sulphonylureas and non-sulphonylureas (repaglinide and nateglinide).

Insulin sensitisers : metformin and glitazones (rosiglitazone, pioglitazone).

Incretin mimetics : a) GLP-1 analogues—exenatide and liraglutide b) DPP-4 inhibitors—sitagliptin and vildagliptin.

* GLP-1 = glucagon like peptide 1, DPP-4 = dipeptidyl peptidase 4

Main types of therapeutic insulins :

1. Species	Bovine Porcine Human
2. Purity	Conventional Single peak Highly purified
3. Duration of action	Short-acting Intermediate-acting Long-acting

* Bovine insulin is more immunogenic, i.e., in relation to immunogenicity (antigenicity), Bovine > Porcine > Human insulin. Animal preparations (bovine or porcine) are no longer used.

Goals of insulin therapy :

1. Alleviation of primary glycosuric symptoms.
   •vention of ketoacidosis and hyperosmolar coma; brings back the lost lean body mass.
3. Improvement in physical performance as well as sense of well being.
4 Diminution in foeto-maternal morbidity, foetal malformations.
5. Reduction in recurrent infections.
6. Delay, prevent or arrestation of micro- and macrovascular complications.

Uses of soluble or regular insulin :

1. *In emergencies, it is the insulin of choice,* i.e., ketoacidosis, infection, surgery, pregnancy, trauma.
2. To supplement depot insulin effects, if necessary.
3. Patients requiring >150 units of insulin/day.
4. Patients not controlled properly with depot insulins.

Different insulin regimens :

1. Conventional insulin therapy.
2. Multiple subcutaneous injections (MSI).
• 3. Continuous subcutaneous insulin infusion (CSII).

How to administer.insulin ?

Patient's education regarding insulin administration is important in treating diabetes mellitus.

1. Preferably, asepsis is maintained. Required dose of insulin is drawn into the syringe through a hypodermic needle.
2. A small, fine-bore hypodermic needle is now attached to the nozzle (or already attached) of the insulin syringe.
3. Preferable sites of injection are : abdomen, arm, thigh, buttock, back. The site is properly cleansed with spirit.
4. Now, a fold of skin and subcutaneous tissue is pinched-up by left thumb and index finger, and the hypodermic needle is introduced in the skinfold by right hand, from the top into the subcutaneous tissue. Insulin is injected and the needle is taken out with care (insulin leakage should be avoided).
5. Injection site is now covered and lightly pressed by a piece of cotton (rubbing should be avoided).

* The rotation of injection site shofild also be taught to the patient. Repeated injections in one site predispose to lipohypertrophy. Insulin injections are to be given deep subcutaneously. The sites have to be rotated so that a second injection does not fall within 1-2 cm of the previous injection site within 1 month of time.

Alternative methods of insulin delivery system :

*

I. Jet injectors,
II. ^ert devices.
III._ Insulin infusion pumps—
. * , a) 'Open' loop — Continuous subcutaneous insulin infusion (CSII).
b) 'Closed' loop (Biostator) — Artificial pancreas.
IV. Nasal, oral, rectal insulin—Not effective in practice at present.
V. Pancreas transplantation—Whole pancreas, segmental pancreas, islet transplant.

* Microprocessor based implantable pumps are now available which are more acceptable than CSII.
** 'Open' loop can be used by S.C, l.V or intraperitoneal route.

Define brittle diabetes and insulin resistance :

(A) Brittle diabetes—*A* small proportion of Type 1 DM patients (1-2 % of diabetic patients in practice) are unstable and difficult to control, and referred to brittle diabetes. Actually, brittle diabetic is a patient

whose life is constantly disrupted by episodes of hypoglycaemia and hyperglycaemia, whatever the cause may be and thus, it is difficult to manage.

(B). Insulin resistance—

a) Old view : when > 200 units of insulin/day are required to control hyperglycaemia and to prevent ketoacidosis, it is said that insulin resistance exists.

b) Modern view : Daily intake of > 1.5 units of insulin /kg of body weight, which is about twice the usual level necessary for full insulin replacement therapy (considering newer insulins).

* Daily insulin production in a normal healthy non-obese adult is 25 units.

Complications of insulin therapy :

1. Hypoglycaemia (commonest).
2. Lipodystrophy—Lipoatrophy and lipohypertrophy (fatty lumps).
3. Insulin resistance.
4. Allergy—Local, and rarely generalised.
5. Insulin oedema (rare but troublesome).
6. Sepsis.

N.B. : Read newer insulins from standard pharmacology or medicine text books.

THREE-WAY CANNULA

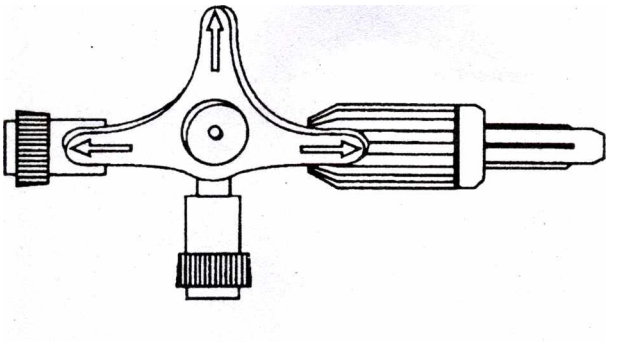

Fig. 1.11 : Three-way cannula (adaptor)

Description:

It is a T-shaped instrument with two inlets and one outlet. By adjustment, the outlet may be connected with either of the inlets.

Different Uses :

1. To aspirate fluid from pleural, peritoneal or pericardial sac (fluid is withdrawn through one inlet by connecting a syringe with the cannula and by adjusting the screw, fluid in the syringe may be pushed into the kidney-tray via the outlet).
2. Through one inlet, I.V fluid may be given (by an I.V set) and the other inlet may be used for medications or monitoring central venous pressure (CVP).

ORAL REHYDRATION SALT (ORS)

Fig. 1.12 : Electrolyte sachet

Presentation :

The ORS is wrapped in an aluminium foil-packet or in a paper-packet.

Indications for use :

To replace the fluid and electrolyte loss commonly as a result of vomiting and/or diarrhoea (i.e., acute gastroenteritis, cholera) — the 'oral rehydration therapy'.

Composition :

As suggested by WHO, the 'universal formula' is :

Ingredients	Composition in g/litre of water
Nacl (table salt)	3.5
$NaHCo_3$ (baking soda)	2.5
or trisodium citrate dehydrate	2.9
Kcl	1.5
Glucose	20.0

Concentration in meq/1 :

Na^+ 90, K^+ 20, Cl" 80, HCo_3~ or citrate 30, glucose 110 and osmolality 310

Method of preparation and application :

The content of the packet is dissolved in one litre of drinking water which is already boiled and then cooled, and should be used within 24 hours. It should be taken frequently as directed by the physician (depends on degree of dehydration).

Approximately, 50 ml /kg of body weight of ORS is given in first 4 hours in mild dehydration and 100 ml/kg of body weight is given similarly in moderate dehydration. Severe dehydration needs l.V fluid therapy.

Advantages of use of ORS :

1. Reduces the cost of treatment (i.e., economical).
2. Easily administered at home (can be used easily by non-trained person).
3. It can be prepared easily at home by simple ingredients like sugar and common salt.
4. Practically, there is very little chance of fluid overload.

Disadvantages of use of ORS :

There are very few disadvantages of oral rehydration therapy like :

1. Unconscious patient (requires l.V access).
2. Severe dehydration (needs l.V fluid therapy).
3. Chance of fluid overload in CCF, chronic renal failure and in infants.

4. The taste may not be accepted by all (few ORS are added with rice flour and used in cholera, are really of very bad taste).
5. Patient may be reluctant to take it in the presence of incessant vomiting.

Principle of action of ORS :

Use of ORS is based on the observation that oral glucose (2%) enhances the intestinal absorption of salt and water (ATP-dependent pump for Na^+ absorption, i.e., glucose-facilitated Na^+ transport), even in the presence of diarrhoea.

Glucose may be replaced by sucrose (40 g of sucrose must be added as sucrose is broken down to equal amount of glucose and fructose). Cereals and other starchy foods (rice flour) may also replace glucose (starch is broken down into glucose and amino acids which facilitate Na^+ absorption).

* Fluids from cooked cereals e.g., rice water may be used in tropics.

Osmolality of blood, urine, stool and CSF :

Blood (plasma)	280-300	mosmol/kg of water
Urine	400-750	mosmol/kg of water
Stool	290	mosmol/kg of water
CSF	292-297	mosmol/kg of water

* *Osmolality of plasma* (mosmol/kg) = 2 [Na^+(mmol/L) + K^+(mmol/L)] + glucose (mmol/L) + BUN (mmol/L). Glucose and BUN are converted to mmol/L by dividing concentration in mg/dl by 18 and 2.8 respectively. Osmolality can also be measured by osmometry.

Diarrhoea and dysentery :

Diarrhoea : It is defined as an increase in daily stool weight over 200 g but in a general sense, frequent passage of liquid or unformed stool is known as diarrhoea. It is divided into *acute* (lasting less than 2 weeks—mainly the infective causes e.g., Rota virus, E.coli, and soon after dietary indiscretions), *persistent* (2-4 weeks) and *chronic* (lasting more than 4 weeks—chronic enteric infections e.g., salmonellosis, giardiasis, hookworm disease, amoebic colitis; pancreatic insufficiency, coeliac disease, pellagra, Addison's disease, malabsorption syndrome, inflammatory bowel disease e.g., ulcerative Colitis and Crohn's disease, intestinal tuberculosis, irritable bowel syndrome, diverticulitis, autonomic neuropathy, lactase deficiency, thyrotoxicosis or laxative abuse) types.

'Hyperdefecation' is characteristic of thyrotoxicosis. Frequent passage of small volume of formed stool is often associated with anorectal disorders (e.g., proctitis) or irritable bowel syndrome is known as 'pseudodiarrhoea'. Involuntary discharge of rectal contents is known as rectal incontinence, and is due to neuromuscular disorders or anorectal sphincteric disturbance.

Dysentery : Characterised by diarrhoea with blood and mucus in the stool as a result of acute inflammation of large gut, and clinically manifested by colicky abdominal pain, pyrexia and tenesmus (basically of two types—amoebic and bacillary).

Table 4 ; Differentiation between small bowel and large bowel diarrhoea

	Features	Small bowel diarrhoea	Large bowel diarrhoea
1.	Volume	Large	Small
2.	Frequency	Less	More
3.	Character	Soup-like, greasy	Mucinous, jelly-like
4.	Colour	Light	Dark
5.	Odour	Very offensive	Offensive
6.	Nature	Watery	Mucoid
7.	Site of pain	Mid-abdomen (colicky and intermittent)	Lower abdomen (gripping and continuous)
8.	Tenesmus	Absent	Present
9.	Blood and WBC within stool	Rare	Common
10.	Common pathogenic organisms	Vibrio cholerae, E. coli. Rota or Norwalk virus, Campylobacter	E. histolytica, Shigella

What are the endocrine causes of diarrhoea ?

1. Diabetes mellitus.
2. Hyperthyroidism.
3. Hypoparathyroidism.
4. Zollinger-Ellison syndrome.
5. Adrenal insufficiency
6. Carcinoid syndrome.
7. Villous adenoma.
8. Non-(5 cell pancreatic tumour.

Common offenders in traveller's diarrhoea ?

(A) Bacterial : enterotoxigenic E. coli, campylobacter jejuni, salmonella, shigella, enteroaggregative E. coli; yersinia enterocolitica, aeromonas spp. and plesiomonas shigelloides are rare causes.

(B) Viral : account for minority of illness.

(C) Parasitic : E.hystolytica, Giardia lamblia and Cryptosporidia spp.

Acute infective diarrhoea in children :

The common causes are—

1. Virus—Rota virus (30-40%), Norwalk virus
2. Bacterial—
   a) E. coli — enterotoxigenic strain (30-40%)
   b) V. cholerae (El Tor biotype)
   c) Salmonella
   d) Shigella
   e) Campylobacter jejuni
   f) Clostridium difficile
3. Parasites—Giardia lamblia, Entamoeba histolytica, Plasmodium falciparum (Algid malaria)
4. Fungi—Candida albicans

N.B. : V. cholerae and E. coli do not invade intestinal mucosa. Diarrhoea is an important determining factor leading to malnutrition in children. Breast feeding should continue along with oral rehydration therapy in infantile diarrhoea.

Chronic diarrhoea in children :

1. Cow's milk allergy.
2. Coeliac disease.
3. Chronic pancreatitis.
4. Cystic fibrosis.
5. Secondary to PEM, or viral/bacterial enteritis, worm infestations.
6. Intestinal stasis.
7. Liver diseases.

How ORS can be prepared at home ?

(A) Two teaspoonfuls of cane sugar + a pinch of table salt + a glass of water, or

(B) 6-8 level teaspoonfuls of cane sugar (i.e., 40 g of sucrose) + one level teaspoonful of common salt (i.e., 5 g of Nacl) ± few drops of lemon + 1 litre of potable water.

* 20 g of glucose is equivalent to 40 g of cane sugar (sucrose), is equivalent to 50 g of rice flour (puffed rice powder).

Can a green coconut (water) replace ORS ?

Previously it was said by some workers in this field that oral administration of 200 ml of green coconut water (GCW) for each litre of fecal loss would serve to maintain K^+-balance in cholera patients with prolonged diarrhoea. It is known that K^+ content of GCW is highland Na^+ and glucose contents are low in comparison to ORS. Though GCW is a readily available, cheap, sterile refreshing drink (an average size GCW contains about 300 ml of fluid) it can never replace ORS because it is not a true replica of ORS.

THE STETHOSCOPE

Fig. 1.13 : The stethoscope

Description:

It has four parts such as 1. Chest piece, 2. Connecting tube, 3. Head piece, and 4. Ear piece.

(A) Chest piece—Usually with a diaphragm and a bell; only one operates at a time. There is a valve that allows switching from diaphragm to bell and vice versa.

a) THE DIAPHRAGM : It should be stiff and smooth to damp out low-frequency sounds, and *unmask high-frequency sounds.* The thin plastic disc (usually having 4 cm diameter) is kept in position tightly by a metallic ring. The cardiac sounds best heard by diaphragm are, 1. All the diastolic and systolic murmurs due to different valvular lesion except mitral and tricuspid stenosis (MS/TS), 2. S_1 and S_2, and 3. Ejection click, pericardial knock, opening snap etc.

b) THE BELL : *Low-frequency sounds are best heard* by the bell. The bell (diameter of 2.5 cm) should be *placed lightly* on the site of auscultation (just enough to prevent room-noise leak) as firm pressure will tighten the underlying skin as a taut diaphragm (in that situation, low-frequency sounds will damp out and only high-frequency sounds are heard). The sounds best heard by the bell are, 1. Low-pitched murmur of MS and TS, 2. S_3or S_4, 3. Foetal heart sounds, and 4. Venous hum.

(B) Connecting tube—A single or double tube connects the head piece with the chest piece via a metallic connector attached to the chest piece. A length of 12 inches (30 cm) is sufficient. A tall physician may add additional 3 or 4 inches.

Long tubing attenuates high-frequency sounds. Very narrow tubes carry low-frequency sounds better, and high-frequency sounds are better carried by wider tubing.

(C) Head piece—The two metal tubes of the head piece are attached together by a metallic U-connector.

(D) Ear piece—The two metal tubes of the head piece end in two plastic ear pieces. Larger ear pieces are ideal as they prevent air leak. The usual stethoscope head piece is designed in such a way that the ear pieces point slightly anteriorly to be in the same line with the external auditory canal.

* One should not replace the torn diaphragm with a small piece of X-ray plate because the X-ray plate is neither thin nor stiff.

Criteria for a good stethoscope :

1. For high-frequency sounds—Smooth, thin and stiff diaphragm.
2. For low-frequency sounds—Shallow bell with a large diameter.
3. Double tubing (more efficient for high-frequencies) with a metal clip which binds the tubes together.
4. Ear pieces should be largest possible one; soft and made of rubbery material.
5. Length and internal circumferential diameter of the connecting tubes should not cross 12 inches and 4-6 mm respectively; the inner lining of the tubes should be made smooth by 'vinyl tubing'.
6. There should be option for rotation of the metal head pieces so that ear pieces can be placed in the most comfortable position.
7. An extra pediatric-sized diaphragm and bell attached.

Who invented the stethoscope ?

The French physician R.T.H. Laennec (1816). He died at the age of 46 years (1781-1826).

Different uses :

Though stethos means 'chest', and skopio means 'to examine', the modern stethoscope is used to auscultate various parts of the body, such as :

1. Cardiovascular system—Heart sounds, murmur, opening snap, ejection click, pericardial knock, pericardial rub etc.
2. Respiratory system—Breath sound, vocal resonance, crepitations, rhonchi, pleural rub, pneumothorax click etc.
3. Abdomen—Normal peristaltic sounds, renal artery bruit, venous hum, succussion splash and ausculto-percussion in pyloric stenosis, hepatic and splenic rub, uterine souffle and foetal heart sounds.
4. Head—Bruit from cerebral arteriovenous malformation may be heard over cranium or closed eyes; bruit of Paget's disease.
5. Neck—Carotid bruit, cervical venous hum, thyroid bruit, conducted murmur of AS.
6. Extremities—Pistol shot sound, Duroziez's murmur, demonstration of Hill's sign.
7. Measurement of blood pressure.
8. Miscellaneous—Subcutaneous emphysema, demonstration of parietal oedema.

* Worldwide, stethoscope symbolises a doctor. Stethoscope manufactured by renowned companies are Littman, Harvey, Sprague, Leatham etc. Besides the conventional variety, electronic and magnetic stethoscopes are also available.

** Except the sounds best heard by the bell, all other sounds mentioned above are best auscultated by the diaphragm of stethoscope.

SPHYGMOMANOMETER

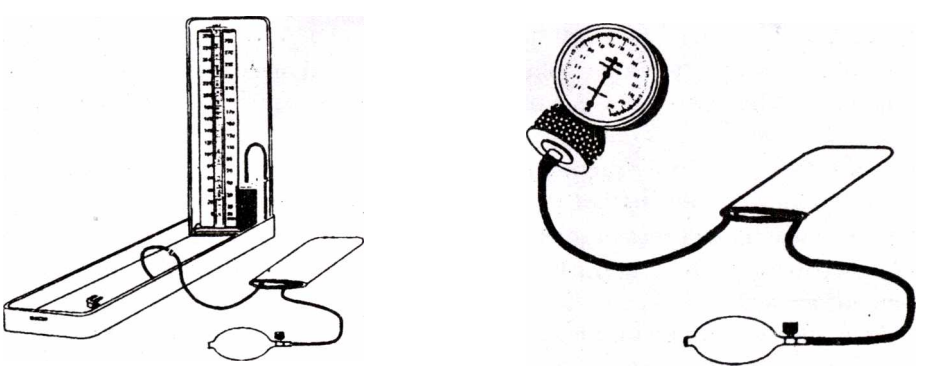

Fig. 1.14 : Sphygmomanometer (mercury column and aneroid type)

Different uses :

They are :

1. To measure the BP.
2. Confirmation of,
   a) Pulsus paradoxus.
   b) Pulsus alternans.
   c) Water-hammer pulse.
3. To demonstrate postural hypotension.
4. To demonstrate Hill's sign in aortic regurgitation.
5. Hess' capillary fragility test.
6. To assess the respiratory reserve (blow through the tube and observe the rise in mercury column).
7. In latent tetany (Trousseau's sign).
8. *To draw* venous blood.

9. As a rotating tourniquet in LVF.
10. To draw blood during blood donation.

* Read 'Bedside Clinics in Medicine, Part I' for further details.

** Sphygmomanometer was discovered by Riva Rocci (Italy) in 1896.

Types :

There are two common types—

a) Mercury column type, and

b) Aneroid type or spring dial type (less accurate).

* Digital (electronic) BP instruments are used by lay people at home.

What is SP, DP, PP and MP ?

Systolic pressure (SP) reflects the cardiac output.

Diastolic pressure (DP) reflects the peripheral resistance.

Pulse pressure (PP) = SP minus DP; normal PP is 30-60 mm of Hg.

Mean pressue (MP) = DP + $^{1}/_{3}$rd of PP; normal MP is approximately 100 mm of Hg.

* Determinants of arterial pressure :

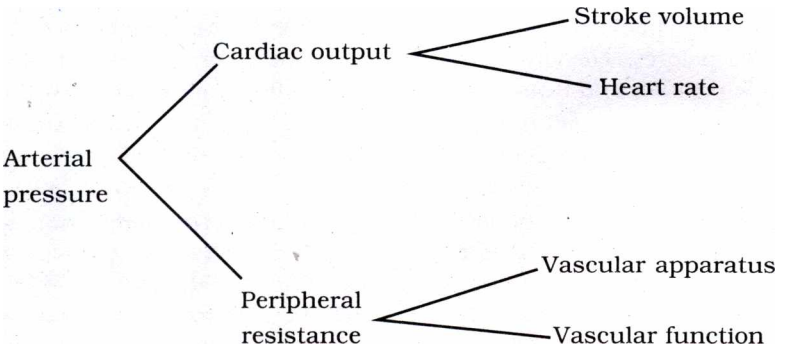

** Diastolic pressure is the most important among all. SP reflects the cardiac activity over and above the peripheral resistance (i.e., indicates the constant load against which heart has to work) and thus, DP is a better guide to assess the haemodynamics in the body.

How to define blood pressure (BP) ?

It is the lateral pressure exerted by the column of blood on the vessel walls while flowing through it.

What is the normal BP ?

It depends on age and sex of the individual, and also on many other parameters like build, exercise, posture, sleep, excitement etc. High BP or **hypertension** is defined arbitrarily by the values which outrange the normal limits of BP as defined by British Hypertension Society or JNC-VII. According to majority of definitions, upper limit of normal BP is 140/90 mm of Hg (lying).

Table 5 : Blood pressure classification

Category	Systolic, mm of Hg	Diastolic, mm of Hg
Normal	< 120	and < 80
Pre-hypertension	120-139	or 80-89
Stage 1 hypertension	140-159	or 90-99
Stage 2 hypertension	> 160	or > 100
Isolated systolic hypertension (ISH)	> 140	and < 90

* Major changes proposed in JNC-VII (2003) guidelines are :

1. In persons > 50 yrs, systolic BP >140 mm of Hg is a much more important cardiovascular risk factor than diastolic BP.

2. A new group called '*pre-hypertension*' with systolic BP of 120-139 mm of Hg and diastolic BP of 80-89 mm of Hg, who needs lifestyle modifications to prevent cardiovascular disease.
3. Most hypertensives should achieve the goal of BP < 140 / 90 mm of Hg, whereas BP <130 /80 mm of Hg should be the target of diabetics and patients with chronic renal disease.
4. Thiazide type diuretics should be used in all unless otherwise contraindicated.

** JNC-VII (2003) stands for American Joint National Committee on high blood pressure. JNC-VIII will come out in the year 2010.

Ideal measurement of sphygmomanometer cuff:

(A) Length : Should not be less than 10 inches.

(B) Width
a) Adults—5 inches.
b) Young children—3 inches.
c) Infants—1 inch.

* Width of 8 inches cuff should be used in legs (thigh) to avoid falsely elevated BP. If an adult-sized cuff is used in a child, it will falsely record low BP and if an infant-sized cuff is used in an adult, it with falsely record high BP. Obese adults require wider cuff for arms (6 inches).

How do you measure the BP ?

Steps :

1. The patient should lie flat on his back (SP may rise after sitting or standing) and should take rest for at least 15 minutes before recording of BP (BP should be recorded with the patient taking rest in a comfortable position and thus, casual recording should always be avoided).
2. Wrap the appropriate cuff firmly and uniformly over the arm in such a way that the lower border of the cuff remains at least 1 inch above the elbow joint. The arm should be kept in extended position at the heart level.
3. Keep the BP instrument (or spring dial) at the level of patient's heart. The midportion of the rubber bag present within the cuff should lie over the brachial artery. Raise the pressure upto 200 mm of Hg or till the radial pulse disappears. Now start deflating, and the point of reappearance of radial pulse indicates SP by 'palpatory method'. Place the diaphragm of sthethoscope over the brachial artery, a little below the cuff ('auscultatory method'). The cuff is inflated again and the mercury column is raised to 20 mm of Hg above the SP which was recorded by palpatory method, and then deflated slowly (2 mm of Hg/second). The BP is usually measured to the nearest 2 mm of Hg.
4. During release of pressure (deflation), following variations of sounds are heard **('Korotkoff sounds',** after their discoverer). Phase I—Sudden appearance of tapping sound (indicates SP); Phase II— Murmur-like sound replaces the tapping sound; Phase III—Gong sound replaces murmur; Phase IV—Loud sound suddenly becomes muffled; Phase V—Absence of all sounds (indicates DP).

N.B. : Previouly DP was recorded by phase IV but now-a-days phase V (just disappearance of sounds) is taken granted for measuring DP (interobserver variations are minimum and more closely corresponds to directly measurred DP while recording phase V). Few countries record the BP as $^{150}/_{96\ 90}$ mm of Hg where the SP is 150, Phase IV-DP is 96 and phase V-DP is recorded as 90 mm of Hg.

5. For recording of BP in legs, wrap the larger cuff in the thigh and place the stethoscope over the popliteal artery in the popliteal fossa while the patient lies in prone position.

N.B. : *Normally the SP in the lower limb is upto 20 mm of Hg higher than the SP in the upper limb, but DP remains the same.* Recording of lower limb BP is important in coarctation of aorta or occlusive disease of aorta (low), and aortic incompetence (high). BP should always be measured in both upper and lower limbs, and in supine and erect posture. In SI units, BP is recorded in Kilopascal (kPa) and 1 kPa = 7.5 mm of Hg (approximately).

* Where Korotkoff sounds remain audible in spite of complete deflation of the cuff (e.g., aortic incompetence, arteriovenous fistula, pregnancy), phase IV should be used for measurement of DP.

Checklists for ideal BP measurement:

1. The patient should be 'relaxed'.
2. Arm placed at heart level. Tight clothing should be removed from the arm.

3. Correct size of bladder cuff without any leak.
4. Sphygmomanometer should be placed upright; aneroid type calibrated at regular interval.
5. Confirm systolic BP by palpation of radial artery; slow deflation.
6. Avoid parallax error (eye should be kept at the same level as sphygmomanometer).
7. Record two measurements at each visit.

Does any variation exist in BP of two upper extremities ?

Normally there may be a difference of 10 mm of Hg observed between right and left upper limb pressure. One must think of few special situations (like thoracic inlet syndrome, aneurysm of the aorta, pre-subclavian coarctation, supravalvular AS, Takayasu's disease, atherosclerosis of aorta) in the presence of significant pressure difference.

What is auscultatory gap or silent gap ?

Sometimes the initial sounds (which record SP) may disappear (after initial appearance) for some period just to reappear at a lower level, and this is auscultatory gap. If a physician is not careful, he may falsely record low SP (if he misses the initial sounds and starts recording after the gap). It is why, the mercury column should be raised upto 200 mm of Hg or more at the initial part of recording to minimise errors.

Clinical importance—Observed in certain patients with systemic hypertension.

Mechanisms — 1. Venous distension.
2. Diminished flow velocity in arteries.

Causes of systolic and diastolic hypertension :

(A) Systolic hypertension—Atherosclerosis, aortic incompetence, complete heart block etc.

(B) Diastolic hypertension—Essential hypertension, parenchymal renal disease, Cushing's syndrome, pheochromocytoma, eclampsia etc.

(C) Divergent BP (high SP and low DP) e.g., 180/30 mm of Hg is seen in atherosclerosis, aortic incompetence.

Causes of secondary hypertension :

Systemic hypertension is of two types : Essential and secondary. The secondary causes are :

I. Vascular :
   a) Coarctation of aorta.
   b) Non-specific aorto-arteritis.

II. Renal :
   a) Acute and chronic glomerulonephritis.
   b) Diabetic nephropathy.
   c) Polycystic kidney disease.
   d) Renal artery stenosis.
   e) Chronic pyelonephritis.
   f) Renal involvement from collagen vascular diseases (e.g., SLE).
   g) Chronic renal failure.

III. Endocrine :
   a) Cushing's syndrome.
   b) Pheochromocytoma.
   c) Conn's syndrome.
   d) Acromegaly.
   e) Hyperparathyroidism.
   f) Myxoedema.
   g) Congenital adrenal hyperplasia.

IV. Drugs ;
   Oral contraceptive pills, corticosteroid, carbenexolone, oestrogens, sympathomimetic amines,

V. Miscellaneous : Eclampsia, obstructive sleep apnoea, alcohol, obesity and porphyria.

N.B. : Essential or idiopathic hypertension comprises 80-90% cases of hypertension and rest are secondary hypertension. Secondary hypertension is a consequence of specific disease or abnormality (so, though severe diastolic hypertension may occur, they are often treatable).

What is postural hypotension ?

Fall of 20 mm of Hg or more in SP, or 10 mm of Hg or more in DP in upright posture is postural hypotension. If the patient complains of symptoms like light-headedness, dizziness, extreme weakness, blurring of vision or syncope, even a lesser degree of fall in BP may be considered as significant. First measure the BP iri lying down position and then record BP **after standing for at least 3 minute.** 'Postural drop' in BP is important bedside clue in syncope, and diabetes mellitus with autonomic neuropathy.

Where the BP instrument may be used as a pneumatic tourniquet ?

1. Emergency control of bleeding where other methods are not available.
2. To produce a bloodless field of operation.

What is 'white coat' hypertension ?

Few patients (20%; especially women) show dramatic elevation of BP when measurements are carried out by a doctor in the chamber, outdoor or indoor. Thus, often it is called as office or clinic hypertension. Contrary to previous beliefs, it may be associated with target organ damage (LVH, carotid atherosclerosis). It is an important well-known cause of refractory hypertension. It has been observed that BP recordings by a senior consultant physician is higher than recording by a junior doctor, which is again higher than the BP recorded by a nursing staff. Accurate diagnosis requires twentyfour hours ambulatory monitoring of BP.

Pseudo hypertension :

In old age, there is false recording of high BP as a result of stiff and non-compliant vessels (Osier's sign). Actually, the true intra-arterial BP is lower than the BP measured by sphygmomanometer.

Labile hypertension :

The patients having high BP for sometimes, but not always, are known as labile hypertensives.

Paroxysmal hypertension :

This (sudden shooting of BP) is classically seen in certain patients of pheochromocytoma, and is also known as episodic hypertension. This is diagnosed by repeated recordings.

Transient hypertension :

In conditions like acute glomerulonephritis, pregnancy, acute myocardial infarction or CVA, systemic hypertension may be seen for a brief period of time and may be due to stress-induced or associated with a disorder having transient phase of hypertension.

Hypertensive urgency and emergency :

Hypertensive urgency : High BP without any target organ damage and thus reduction of BP can be done gradually within 24 hours. *Hypertensive emergency :* Markedly high BP with target organ damage and needs immediate control of BP in order to prevent further target organ damage.

Isolated systolic hypertension (ISH) :

When the SP is > 140 mm of Hg and DP remains < 90 mm of Hg, it is said that ISH is present and is commonly found in old age.

Refractory hypertension :

The patients whose BP, inspite of full compliance, can not be reduced to 140/90 mm of Hg, and who are on triple drug regimen (includes a diuretic in maximal doses) are considered to be refractory or resistant: Think of—

1. Non-compliance with drug therapy (commonest).
2. Inadequate treatment.
3. Failure to recognise secondary hypertension e.g., pheochromocytoma, renal artery stenosis etc.

Target organ damage (complications) in systemic hypertension :

(A) Heart and vessels—Cardiac enlargement, LVF, angina pectoris, acute myocardial infarction, arteriosclerosis, dissecting aneurysm, peripheral vascular disease.

(B) Cerebrovascular—Cerebral haemorrhage, cerebral thrombosis, hypertensive encephalopathy and subarachnoid haemorrhage.

(C) Renal—Impaired renal function, proteinuria, CRF, ARF.

(D) Eye—Hypertensive retinopathy, retinal haemorrhage and exudate, papilloedema (malignant hypertension), central retinal vein thrombosis, sudden blindness.

(E) Nose—Epistaxis.

Classification of 'hypertensive retinopathy' :

It is divided into 4 grades (Keith-Wagener-Barker classification) :

- Grade I: Thickening of arterial wall, increased tortuosity and narrowing of arteriole though red blood column is seen; AV ratio is 1 : 2 (normal AV ratio is 3 : 4).
- Grade II : Grade I plus AV nipping and reduction of arterial calibre in comparison to vein. 'Copper wire'-like arteries seen without any visible red blood column; AV ratio is 1 : 3.
- Grade III : Grade II pluse flame-shaped haemorrhages and cotton-wool exudates. 'Silver wire' arteries seen without any visible blood column; AV ratio is 1 : 4.
- Grade IV : Grade III plus papilloedema. 'Fibrous cord'-like arteries seen without any visible blood column (malignant hypertension).

* From minute to minute, BP varies with emotion, exercise, respiration, tobacco or alcohol consumption, temperature, pain etc.

** In atrial fibrillation, multiple BP recording with averaging is advisable.

*** Blunting of the day-night BP pattern (i.e., nighttime BP is 10-20% lower than daytime BP) is seen in sleep apnoea and autonomic neuropathy.

**** Read malignant and accelerated hypertension from 'Bedside clinics in Medicine, Part I'.

CLINICAL THERMOMETER

Description :

1. A glass tube with markings (graduations); usually 11 cm long.
2. Constricted terminal part containing mercury with the other end sealed.
3. Small lumen inside with constriction at the neck.
4. Cross-section of the body of glass tube is triangular.
5. Indication of normal temperature (98.6°F or 37°C) by an arrow-mark.

* Previously Fahrenheit scale (F) was used in the thermometer. Now-a-days, temperature is recorded in Centigrade scale (C). The formula of conversion of temperature is,

$$\frac{C}{5} = \frac{F - 32}{9}$$

** The kink inside the clinical thermometer prevents the return of mercury column when the thermometer is taken out of body. The triangular cross section (i.e., prism-like) magnifies the thin *mercury* line into a wider strip to help in easy reading.

*** Recently, a tympanic membrane thermometer (i.e., electronic thermometer placed in the ear) is used for fast and accurate recording of core temperature.

**** Lower-oesophageal temperature closely reflect the core temperature.

Temperature range graduated in the thermometer :

It is 94°F to 108°F in Fahrenheit scale, and 35°C to 42°C in Centigrade scale.

Procedure of recording temperature : -

The thermometer should be washed properly with soap-water or any antiseptic solution. In hospitals, it is usually immersed in antiseptic solution. Clean with tap water before using it. Always shake the thermometer before use so that the mercury level comes below the arrow-mark. Before taking oral temperature, the patient should not consume anything hot or cold. Before keeping the thermometer inside the oral cavity, warn the patient not to bite it but to hold it by the lips when the mercury bulb is placed under the tongue.

Clean the axilla of sweat before putting the thermometer there. In infants, the temperature may be taken in groin with thigh flexed over the abdomen. The patient should not bath before recording axillary temperature.

After recording the temperature (thermometer is kept at least for two minutes), shake the thermometer again to send the mercury column beyond normal temperature. Now record the temperature in a white paper with date and time.

Clinical thermometer—which type of thermometer it is ?

It is a *maximum thermometer.* Higher temperature once attained, does not return to normal spontaneously. Clinical thermometer does not reflect the minimum temperature.

Thermometer used for weather report are made of ether or alcohol (instead of mercury) and reflects the minimum temperature. They are minimum thermometer.

What is habitual hyperthermia ?

In some persons, the normal temperature is above 98.6°F and is often in the range of 99°F to 100.5°F. Though rare, these patients run from physician to physician to allay their anxiety. The diagnosis can be made firmly after a certain period of close observation of the pateint.

What is malignant hyperthermia ?

In this inherited disorder, the temperature shoots from 102.2°F to 107.6°F in response to certain anaesthetics like halothane, methoxyflurane, cyclopropane or by muscle relaxants like succinylcholine. The high temperature results from muscular contraction. The situation is tackled by cooled ice, 100% 0_2, fluids and diuretics (to reduce myoglobinuria and hyperkalaemia), $NaHCo_3$ (to combat metabolic acidosis), and dantrolene sodium.

Neuroleptic malignant syndrone (NMS) is probably a variant of malignant hyperthermia and is usually associated with use of neuroleptic drugs e.g., phenothiazines, butyrophenones or haloperidol. NMS is characterised by hyperthermia, altered sensorium, muscular rigidity and autonomic dysfunction (pallor, tachycardia, sweating, labile BP). The mortality rate is high. Similar treatment as adopted in malignant hyperthermia is advocated here.

* Vide the section on Abnormal temperature' in 'Bedside Clinics in Medicine, Part I' for further reading.

TUNING FORK

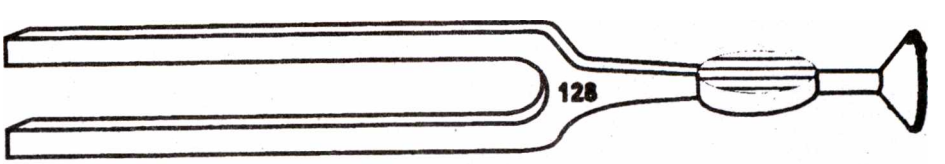

Fig. 1.16 : Tuning fork (frequency 128 cycles/second)

Description :

This Y-shaped instrument has two limbs, a common stem and a disc-like base. Tuning fork produces vibration with constant frequency like 128, 256 or 512 cycles/second. The frequency is written on the instrument where the two limbs join. The tuning fork is made of steel.

Different uses :

Classically the tuning fork' is used for two purposes—

1. Testing of vibration sense (128 or 256 cycles/sec.).
2. Testing of hearing and quality of deafness (256 or 512 cycles/sec.).

Test for vibration sense :

Vide the section on 'Charcot joint' in 'Bedside Clinics in Medicine, Part I'.

Causes of loss of vibration sense :

1. Old age (physiological; even the ankle jerk may be lost in patients over 70 years).
2. Peripheral neuropathy (loss of vibration sense is an early feature in diabetes mellitus) or radiculopathy (prolapse^ intervertebral disc).
3. Lesion in the posterior column (e.g., compressive or non-compressive myelopathy; classically tabes dorsalis).
4. Cortical lesion (e.g., lesion in the parietal lobe).

* Vibration sense is carried through posterior column; in diseases affecting posterior column, patient complains of ataxia (sensory ataxia). In syringomyelia and multiple sclerosis, vibration sense may be affected alone.

Tests for hearing :

There are two 'tuning fork tests' which differentiate the quality of deafness.

(A) Rinne's test :

A vibrating tuning fork is placed by the side of the ear to be tested. Mask hearing in the other ear by giving pressure of tragus on external acoustic meatus. Ask the patient to raise his finger when he can no longer hear any sound. After receiving the signal, the base of the fork is placed on the mastoid process and ask him again whether he can hear any sound. If he says 'no' to your question, the Rinne's test is positive and if says 'yes', the test becomes negative.

Interpretation—In persons with normal hearing, the air conduction (AC) is always greater than bone conduction (BC), i.e., AC > BC, that is to say Rinne's test is positive. If BC > AC, Rinne's test is said to be negative. So Rinne's test is positive in normal persons and in nerve type (sensorineural) deafness, and the test becomes negative in conductive deafness. It is to be remembered that in sensorineural deafness, AC > BC though both are less than normal.

(B) Weber's test :

A vibrating tuning fork is placed on the centre of the vertex in the middle line. A normal individual hears the sound equally on both sides.

In sensorineural deafness, the sound is better heard in the normal or healthy ear, i.e., localisation is on the normal side. But in conductive deafness, the localisation is on the affected or abnormal side.

The explanation goes like this : In sensorineural deafness, both AC and BC are reduced whereas in conductive deafness, only AC is reduced but BC is relatively increased (as ambient noise is excluded).

Interpretation—'Lateralised' or not.

Causes of deafness :

Deafness is of two types :

(A) Conductive deafness — As a result of impacted wax, damage to tympanic membrane, otosclerosis, eustachian tube blockage, CSOM etc.

(B) Sensorineural deafness — Due to damage of cochlear nerve and organ of Corti, Meniere's disease, acoustic neuroma, fracture of petrous part of temporal bone, pontine lesion etc.

* In clinical practice, deafness is further investigated by audiometry (pure-tone) and brainstem evoked potentials in order to come to a definite aetiological diagnosis.

How to differentiate between organic and hysterical loss of vibration sense ?

Place the tuning fork on either side of forehead in turn. As the frontal bone is acting as a single unit, the sensation of vibration is perceived/not perceived on both sides even by the patients having organic lesion. Hysterical patients say that they can not feel the vibration on the side of 'sensory loss'.

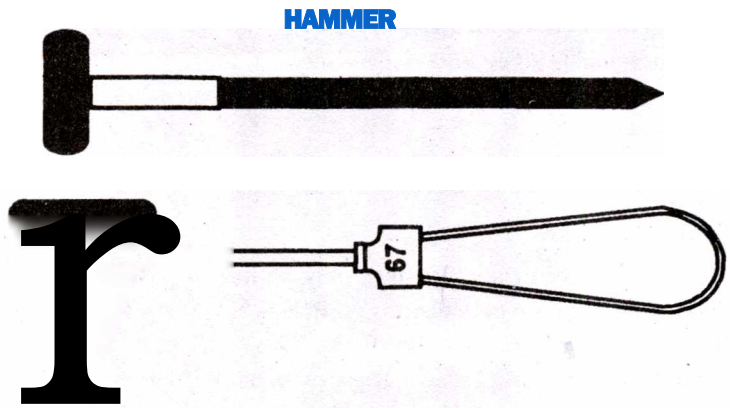

Fig. 1.17 : Hammer (rounded and conical variety)

Synonyms :

Percussion hammer, patellar hammer or tendon hammer.

Why the name patellar hammer ?

Knee jerk was the first tendon reflex to become a regular part of the neurological examination, and this is why it is also known as patellar hammer.

Parts of a hammer :

1. Rounded or conical striking end made of rubber.
2. Shaft (plastic) with a blunt tip for elicitation of different superficial reflexes (abdominal, cremasteric, plantar response). The blunt tip present within the metallic shaft is seen after unscrewing two parts of the shaft.

What is an ideal hammer ?

A hammer with a firm and flexible shaft (made of plastic) is an ideal one.

Different uses :

For elicitation of—

1. Deep reflexes or jerks (percuss the stretched tendon concerned).
2. Chvostek's sign (tap the facial nerve in front of the ear) - twitching of facial muscles are seen in tetany.
3. Fasciculation (strike a big muscle).
4. Myotonia (strike the thenar eminence of palm).
5. Superficial reflexes (use the shaft with blunt tip).
6. While percussing the chest, hammer may be used as 'percussing finger'.

N.B. : Read all superficial (specially plantar response) and deep reflexes in details.

Fig. 1.18 : Pin

Different uses :

1. Testing of pain sensation (e.g., peripheral neuropathy).
2. Testing of crude touch sensation—By the pinhead (specially in leprosy).
3. Blanching reaction in telangiectasia (with special reference to spider naevi) —The pinhead is used.
4. Confrontation perimetry—With special reference to a large pin having red or white-head (hatpin).
5. Elicitation of plantar response may be carried out by a blunt pin (in a desperate situation).

N.B. : Read *leprosy* in details.

COTTON

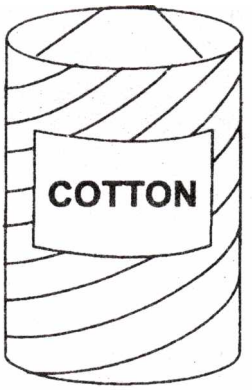

Fig. 1.19 : Cotton packet

Different uses :

1. Haemostasis; wiping secretions; as a dressing material; to cleanse the local part before I.V or I.M injection when soaked in methylated spirit.
2. *Touch sensation*—When a small piece of cotton wool is twisted into a fine hair, it can be used for testing of fine touch sensation and the blunt end may be applied for crude touch sensation (with special reference to leprosy and sensory function testing in clinical neurology).
3. *Corneal reflex.*
4. Test of olfactory nerve—Test objects (e.g., oil of peppermint) are soaked in cotton and presented to the patient.
5. Gag reflex is done by a piece of cotton wrapped in a broom-stick.
6. For preparation of throat swab, conjunctival swab or rectal swab.
7. Cortical sensation—One point localisation and sensory extinction.

N.B. : Read *leprosy* and *comeal reflex* in details.

MEASURING TAPE

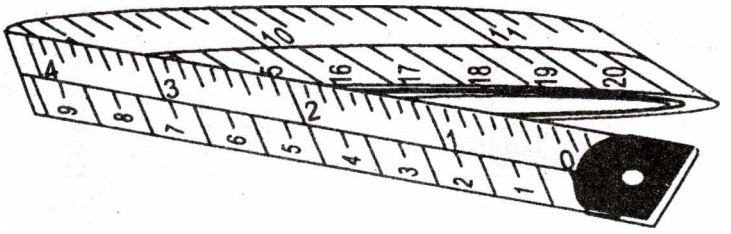

Fig. 1.20 : Measuring tape

Different uses in clinical medicine :

It helps in the measurement of—

1. Abdominal girth in ascites (serial measurement is important).
2. Thyroid enlargement (at the most prominent part of the swelling in neck).
3. Expansion of the chest (specially in emphysema).
4. Head circumference (specially in hydrocephalus).
5. Assessment of nutrition (helpful in obesity and malnutrition).
6. To assess body mass index (BMI) and waist-hip ratio in obesity.
7. Height (e.g., cretinism, Marfan's syndrome).
8. To confirm wasting or hypertrophy of muscles.

TONGUE DEPRESSOR

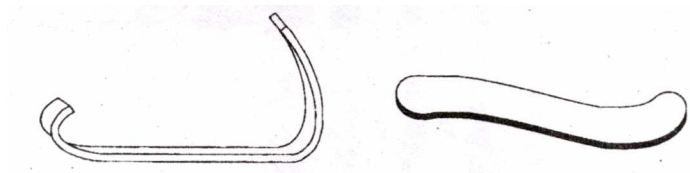

Fig. 1.21 : Tongue depressor (L-shaped and straight variety)

Synonym :

Spatula; spatula is straight but tongue depressor is L-shaped i.e., having an angulation with a holding part (hold by the physician) and a broader depressor part (part that depresses the tongue).

Which part of the tongue is pressed ?

Usually the anterior 2/3rd of the tongue is pressed. Never touch the posterior 1 /3rd (gag reflex may occur) of the tongue.

Different uses :

1. Examination of the throat and oral cavity (teeth, gum, cheek, tongue, fauces and tonsils, palate, oropharynx).
2. 'Spatula test' in tetanus.
3. Detection of posterior nasal bleeding.
4. Removal of foreign body (e.g., fish bone) from the tonsils, throat or posterior part of the tongue.
5. Elicitation of gag reflex.
6. Indirect laryngoscopy.
7. It helps to open the mouth for oral toilet or suction in a comatose patient; oral surgery.

N.B. : Detection of caries teeth, gingivitis, candidial infection in buccal mucosa and tongue, patch tonsil, diphtheritic patch, aphthous ulcer, movement of palate as a part of IXth and Xth cranial nerve examination, spatula test in tetanus, Koplik's spot in measles and palatal ulcer in SLE are subjects of interest in general medicine.

Causes of 'patch tonsil' :

Patch or membrance seen over tonsils in situations like :

1. Acute follicular tonsillitis.
2. Faucal diphtheria.
3. Thrush or candidial infection.
4. Agranulocytosis.
5. Acute lymphoblastic leukaemia.
6. Vincent's angina (spirochaetes and fusiform bacilli).
7. Infectious mononucleosis.
8. Milk curd (in neonates and infants).

Table 6 : Differentiation between acute follicular tonsillitis and faucal diphtheria

	Features	Tonsillitis	Diphtheria
1.	Onset	Sudden	Gradual
2.	Limitation of 'patch'	Only to enlarged tonsils	Tonsils and neighbouring structures like palate, pillars of the fauces may be involved
3.	Toxicity	Little	More toxic than tonsillitis
4.	Membrane or patch	The membrane or patch is yellowish and not adherent, and *can be easily seperated without any bleeding surface*	Greyish and adherent, and *can not be easily seperated. It leaves a bleeding surface after seperation*
5.	Trismus	May be present	Absent
6.	Cervical lymphade-nopathy	+	++
7.	Rise of temperature	100°F-104°F	99°F-100°F

Causes of lock-jaw or trismus :

Trismus develops due to sustained spasm of masseter muscles and is seen in :

1. Tetanus 2. Impacted wisdom teeth 3. Peritonsillar abscess, dental abscess, Ludwig's angina 4. Acute follicular tonsillitis 5. Temporo-mandibular arthritis 6. Drug-induced dyskinesia (metoclopramide, phenothiazines) 7. Tetany, strychnine poisoning 8. Parotitis, mumps 9. Hydrophidae group of snake bite 10. Hysteria.

What is 'spatula test' ?

In health, touching the posterior pharyngeal wall by spatula produces reflex opening of mouth. In tetanus, paradoxically mouth closes in such a way that the spatula can not be taken out easily. Thus, spatula test is positive in tetanus.

N.B. : Read tetanus, diphtheria, measles and bulbar palsy in details.

TORCH



Fig. 1.22 : Pencil torch

Different uses :

1. *Pupillary reaction*—Light reflex (bilateral fixed and dilated pupil often helps in declaring 'deatfy).
2. Test of perception of light (PL) and projection of rays (PR).
3. Examination of pupil, oral cavity and throat, external ear, nose; anus, rectum and vagina.
4. Testing of photophobia (specially in meningitis).
5. Often epigastric pulsation is better seen when a torch is lighted tangentially over the epigastrium; in congenital hypertrophic pyloric stenosis, a torch is focused over the abdomen from right side of the body for better demonstration of slow peristaltic waves while the examiner looks from the baby's left side.
6. Transillumination test in hydrocele.

N.B. : Read pupillary changes in details.

PLAIN GLASS TEST TUBE



Fig. 1.23 : Plain glass test tube

Different uses :

1. For the collection of blood sample for,
   a) Grouping and cross-matching.
   b) Serum electrolytes.

c) Serum urea, creatinine, sugar, uric acid, and

d) Liver function tests.

2. For the collection of urine sample for routine examination (R/E) and culture-sensitivity (C/S) test.
3. For the collection of gastric juice sample for analysis/detection of AFB in a suspected case of pulmonary tuberculosis (specially in children who can not expectorate sputum, and often swallow it).
4. For the collection and analysis of CSF for physical, biochemical, cytological and bacteriological examination.
5. Sputum collection for Gram's staining, detection of AFB and malignant cells, RBC etc.
6. For the collection of pleural fluid, pericardial fluid, ascitic fluid and drained pus from liver abscess for the purpose of physical, biochemical, cytological and bacteriological examination.
7. Two test tubes containing cold (5°- 10°C) and hot (37°-45°C) water for assessment of temperature sensation in clinical neurology.
8. For the collection of throat swab, rectal swab, high vaginal swab, conjunctival swab or wound pus material (a sterile test tube with a'cotton swab stick is used).

* The test tube should be sterilised where it is used for bacteriological examination e.g., in 2, 3, 4, 5, 6 and 8.

** Throat swab examination is necessary in acute tonsillitis, diphtheria and acute rheumatic fever.

CONDOM

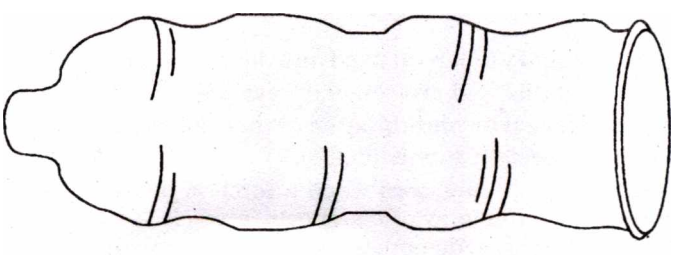

Fig. 1.24 : Condom

Description :

Usually it is of two kinds, i.e., latex (most widely used) and skin-type. The Indian condom is usually 17.5 cm long and 4.4-5.4 cm wide. Latex condoms are preferable as HIV has been shown to leak through natural skin-type condoms.

Different uses :

1. Most widely used barrier contraceptive device for males.
2. Prevents sexually transmitted diseases (STD) with special reference to AIDS, hepatitis B infection, gonorrhoea, syphilis, non-gonococcal urethritis and genital herpes.
3. Often it is used for 'condom catheterisation' (prevents soiling of bed and bed-sore formation, and as the catheter is not introduced per urethra, there is less chance of development of UTI).

* Condoms are easily available, safe, cheap, disposable and having no side effects. Globally, condom is now promoted (specially, in clients of commercial sex-workers) to prevent transmission of HIV infection.

How condom catheterisation is done ?

Make a small nick at the tip of the condom and through it, a Malecot's or Foley's catheter is passed in such a way that the flower of Malecot's catheter rests on the nick. Now the condom is put around the penis with the help of adhesive tapes. Condom catheterisation is valuable in (a) incontinence of urine, and (b) in comatose patients where the urinary output is to be measured.

N.B. : Read AIDS in details.

AIRWAY TUBE

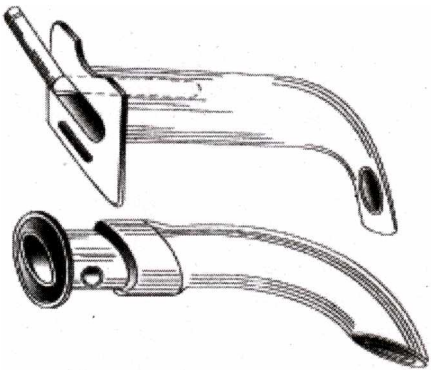

Fig. 1.25 : Airway tube (metal and rubber)

Available varieties :

The slightly curved tube is made either of :

a) Metal, or

b) Rubber.

They help entry of air into the air-passages. This instrument is also known as 'mouth gag'.

Different uses :

1. Unconscious patients.
2. Patients under anaesthesia.
3. During an episode of convulsions (e.g., epilepsy).

It is inserted into the mouth :

a) To prevent the tongue from falling back (the curvature of the tube is so made that it draws the tongue forwards),

b) To assist suction,

c) To prevent the endotracheal tube being bitten by the teeth during anaesthesia, and

d) To prevent the tongue bite (e.g., convulsions).

Multiple openings are present at the inner end, so that some of the openings may remain open when others are blocked by mucus plugs. Keeping the tube in boiling water for 30 minutes or autoclaving sterilises the instrument.

VENFLOW OR INTRACATH

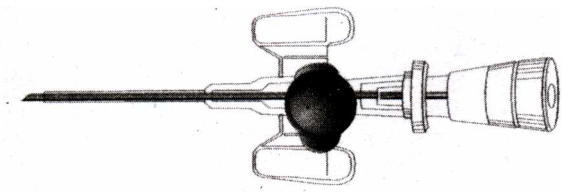

Fig. 1.26 : Intracath

Description :

It has two parts :

1. Inner — metallic stylet or needle (for proper guiding into the vein).
2. Outer — polythene cannula or sheath.

Uses :

This type of indwelling venous catheter (also known as angiocatheter) is required when the intravenous access is needed for a longer period (e.g., 24-72 hrs).

Procedure of introduction :

After puncturing a long vein, the whole of the intracath is gently introduced into the vein. The inner metallic needle is now withdrawn cautiously, keeping the outer polythene cannula within the vein. The polythene cannula is now ready to be connected with a venous line.

Advantages of 'intracath' over scalp vein set:

The intracath,

1. Can be kept within the vein for a longer time in comparison to scalp vein set,
2. Minimum chance of counterpuncture of the vein (scalp vein set often faces this hazard),
3. It produces less thrombophlebitis, and
4. There is no question of heparinisation of the channel.

N.B. : Intravenous line access are preliminary step in the management of dehydration, peripheral circulatory failure, cardiac arrest, shock and unconscious patient. The l.V access is done by (i) simple l.V needle, or (ii) scalp vein set, or (iii) intracath.

METERED DOSE INHALER (MDI)

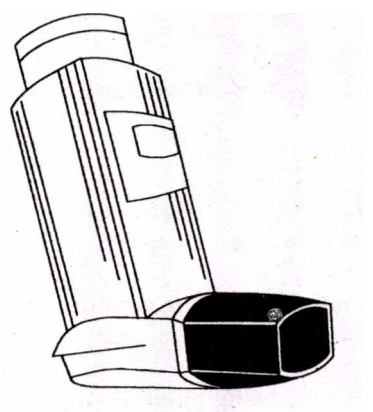

Fig. 1.27 : Metered dose inhaler

What is MDI ?

For the past two to three decades, inhaled medicines are commonly used for bronchial asthma or chronic obstructive pulmonary disease (COPD) patients. These medicines are breathed directly into the lungs, where they are really needed. The devices used to deliver the medicine to the lung are known as 'inhalers'. Inhalers can be of many types e.g.,

a) Spray inhaler (also called metered dose inhaler).
b) Powder inhaler (also called rotahaler).
c) Nebulisers (for giving higher doses).

The inhalers deliver drugs like p_2-agonist (salbutamol, terbutaline, salmeterol, formoterol), corticosteroids (beclomethasone, budesonide, fluticasone), anticholinergics (ipratropium bromide) or mast cell stabiliser (sodium chromoglycate) in *aerosoljorm* which is the preferred mode of treatment for obstructive airway disease.

Description :

This is a L-shaped tube made of plastic and consists of mouth piece, and a tube which holds the canister of medicines to be inhaled. The mouth piece have a cover (cap).

Method of use :

1. Take off the cap of the mouth piece. Shake the canister 5-6 times.
2. Breathe out through the mouth, till the end of normal respiration.

3. Place the aerosol nozzle (mouth piece) between the lips. Start to breathe in, press the canister and keep breathing in steadily and deeply.
4. Remove the inhaler from the mouth. Hold the breathe for 10 seconds cr as long as one find it comfortable. Now breathe out.
5. After 1-2 minutes, get ready to breathe in for the second puff, i*f necessary.
6. Lastly, rinse the mouth with plane water.

* As the device delivers a measured (fixed) dose of medicine, the instrument is called metered dose inhaler. In spite of good technique, only 15% of the contents are inhaled and rest 85% are deposited on the wall of the pharynx, and ultimately swallowed by the patient.

Advantages and disadvantages :

(A) Advantages—
1. Rapid onset of action.
2. Very small dose of the drug is necessary to have desired effect.
3. Very little medicine is allowed to reach other parts of the body, i.e., chances of side effects tend to be minimum.

(B) Disadvantages —
1. The major limitation of the mode of administration is that training and skills are required to coordinate actuation of drug from MDI.
2. Pharyngeal infection (e.g., candidosis with inhaled corticosteroids) if the device in not properly cleaned at a regular interval.

What is a rotahaler ?

Powder inhalers are devices that deliver a measured dose of medicine in a *powdered form.* The transparent rotahaler breaks a capsule (rotacap) in the powdered form and the patient inhales the powder in the aerosol form through the mouth piece of rotahaler.

What is a nebuliser ?

Nebulisers are used for giving higher doses of medication at times when breathing becomes very difficult. This is a machine that transforms the medicine (salbutamol, beclomethasone, ipratropium bromide) into a *Jlne mist,* which can be breathed in by normal breathing, via a facemask or a mouth piece. The nebuliser chamber is connected to the nebuliser and oxygen mask on either side, so that nebulised drug would be inhaled along with oxygen. Nebulisers are used in hospitals or nursing homes, for the management of acute severe asthma or acute exacerbation of COPD patients.

SPACEHALER

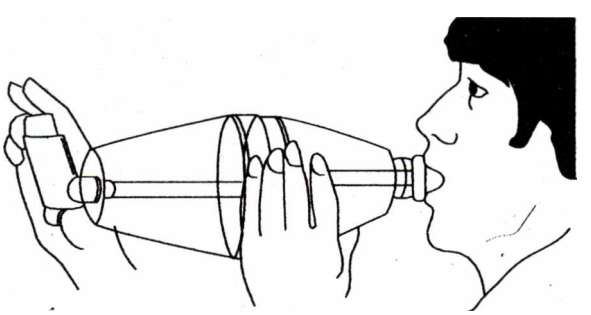

Fig. 1.28 : Spacehaler

Description :

This device consists of two smooth plastic cylinders (one fits into the other producing a 'space'). At one end there is a mouth piece through which the patient inhales the medicine and at the opposite end the metured dose inhaler (MDI) is placed through an inlet. It is also known as 'volumatic' or 'spacer'.

Method of use :

Assemble the spacehaler by pushing the notch of one half into the slot of the other half of cylinder. After shaking the MDI well, fit it into the spacehaler. Rest of the steps are similar to the use of MDI.

* Spacehalers are designed »to reduce velocity of the particles so that less drug is deposited in the mouth.

Advantages and disadvantages :

(A) Advantages —

1. It makes the spray inhaler (MDI) easier to use and added to its effectiveness. The drug delivered from the MDI is not misused or lost because it is kept within a 'space'.
2. Strict coordination of the patient (i.e., aerosol activation and inhalation) is not required as the patient breathes in the cylinder.
3. Chances of development of oral candidosis with inhaled corticosteroid is reduced.
4. Low cost; portable; no electricity required (in comparison to nebuliser).
5. Useful in children and in the elderly.
6. Less drug is deposited in the mouth in comparison to MDI.

(B) Disadvantages —

The device is big to carry in person.

PROCTOSCOPE (ANAL SPECULUM)

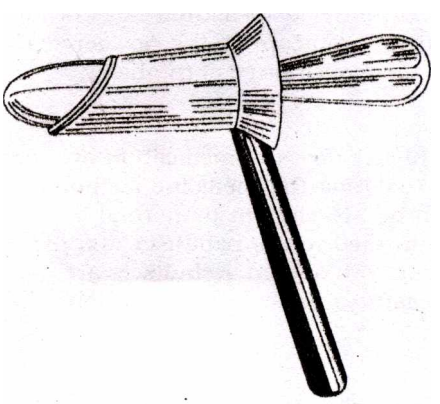

Fig. 1.29 : Proctoscope

Description :

This is a 3-inch long instrument, and has two parts :

a) A cannula — One end is sharp and the other end is wide.

b) Obturator — The blunt end of the obturator (trocar) fits well into the sharp end of the cannula.

Plus

It needs a source of light (i.e., torch)

Different uses :

1. To visualise the anal canal for examination of fissure, internal haemorrhoids (piles), ulcer, growth, polyp etc.
2. For injecting sclerosing agents (5% phenol in almond oil or 3% sodium morrhuate) in the sub-mucous coat of the rectum and the anal canal through the mass of piles.
3. As a primary investigation of ano-rectal discomfort or pain.

Procedure of introduction :

1. The patient is usually placed in the left lateral position (preferred with right leg flexed and left leg extended, or in the 'knee-elbow' position. Inspection outside the anus and digital rectal examination are performed to exclude any painful condition.

2. The lubricated proctoscope is now pushed upwards and forwards towards the umbilicus until the anal canal in passed; the instrument is then directed posteriorly (towards the sacral hollow) to enter into the rectum proper.
3. The obturator is withdrawn and the lower rectum is visulazied with the help of a torch when the light is thrown through the cannula. Now the cannula is gradually withdrawn, and the rectum and the anal canal are visualized for any pathology.

Exciting factors to have internal piles :

1. Straining at defecation (e.g., constipation).
2. Pregnancy, uterine tumours.
3. Portal hypertension e.g., cirrhosis of liver.
4. Persistent straining at urination (e.g., benign hypertrophy of prostate).
5. Carcinoma of the rectum.

Indications of rectal biopsy in clinical practice :

Rectal biopsy is done through sigmoidoscope or colonoscope in—

1. Carcinoma of the rectum.
2. Hirschsprung's disease.
3. Amyloidosis.
4. Schistosomiasis.
5. Ulcerative colitis.
6. Intestinal amoebiasis (rare).

AMBU BAG

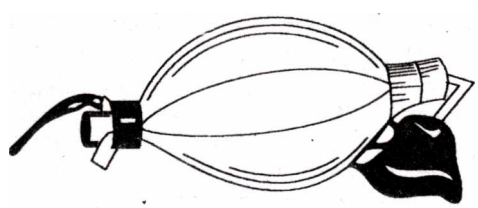

Fig. 1.30 : Ambu bag

Description :

The mnemonic AMBU stands for 'Ambulatory Manual Breathing Unit'.

Air enters into the patient's lungs through a tracheostomy or endotracheal tube after squeezing the bag. When the pressure is released, the bag inflates 'automatically' (the elastic recoil of the chest results air to leave the lungs). This apparatus serves the purpose of mouth to mouth respiration.

ENDOTRACHEAL TUBE

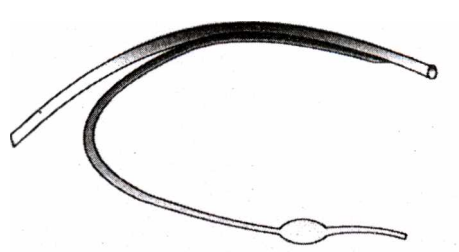

Fig. 1.31 : Endotracheal tube with cuff

Description :

As the name implies, the tube is introduced within the trachea through laryngeal opening via mouth. The tube may be of portex (polyethylene) or rubber-made. Portex variety is less irritant and can be kept for a longer period.

The endotracheal tube may be cuffed or uncuffed. The 'cuffed endotracheal tube' have a small balloon at the upper end and indicates tension in the cuff. A small tubing along the body of the tube helps in inflation of the cuff. The balloon should always be inflated with air (never with water). The size of the tubes indicate their internal diameter and usually it is 7.5 mm for females and 7.5-8 mm for males. Cuffed tubes are preferred as they keep the tube in position.

Procedure of endotracheal intubation :

It is an emergency procedure when an endotracheal tube passes from oral cavity into the trachea for providing adequate ventilation in patients with respiratory failure.

Indications :

1. Respiratory failure as a result of COPD, massive pneumonia or respiratory muscle paralysis, in an attempt to give positive pressure ventilation.
2. To carry out artificial respiration in a patient of cardio-respiratory arrest.
3. Respiratory difficulty in an unconscious patient—clear the airway and prevent aspiration.
4. During general anaesthesia.
5. Severe angio-oedema of larynx in anaphylaxis.
6. Respiratory depression in poisoning like morphine, diazepam.

Procedure:

Pre-anaesthetic medication and anaesthesia are not required. The patient is positioned supine with neck hyperextended and chin in the midline.

a) Oral intubation : First, the oral cavity is cleared of secretions. The oropharynx, nasopharynx and vocal cords are visualised with the help of a laryngoscope; the endotracheal tube of appropriate size is then passed through the vocal cords and positioned in the trachea. Now the chest is auscultated for breath sound (to confirm the air entry on both sides). If breath sounds are equal on both the sides, the cuffed endotracheal tube is then inflated with an aim to keep the tube in position, and to prevent aspiration.

b) Transnasal intubation : Nose as an entry point may be used in a more conscious patient. Presence of nasal polyp and deviated nasal septum make the passage of the tube difficult. Instillation of 1% ephedrine drops in the nostrils helps in easy passage of the tube through the nasal cavity. After entering the oropharynx, the procedure is the same as 'oral intubation' (i.e., a laryngoscope helps in visualisation of vocal cords and the passage of the tube within the trachea). This approach is suitable for long term ventilation.

N.B. : Before introduction, the cuff should be deflated first. Rubber tube is kept for 24 hours whereas the portex tube may be kept upto 7 days.

Contraindications of endotracheal intubation :

1. Trauma/injury/carcinoma present in the upper respiratory tract.
2. Laryngospasm.

Complications :

1. Obstruction — As a result of blockage by secretions, kinking or compression.
2. Intubation of either bronchus may lead to collapse of the lung (corrected by withdrawing the tube above the carina).
3. Tracheal dilatation as a result of overdistension by the cuff — infection — stenosis.
4. Trauma to the upper respiratory tract and vocal cords.
5. Mucosal oedema and ulceration of trachea.
6. Aspiration during attempted intubation.
7. Dislodgement of teeth.
8. Increased intracranial tension.

RENAL BIOPSY

Indications :

1. Nephrotic syndrome (specially in adults).
2. Persistent proteinuria.
3. Persistent haematuria after urological investigations.

4. Acute and chronic renal failure (specially if unexplained).
5. Systemic diseases with renal involvement e.g., diabetes mellitus, SLE, amyloidosis, Henoch-Schonlein purpura.
6. Transplanted kidney for acute allograft rejection.
7. Thin glomerular basement membrane (GBM) disease.
8. Sometimes in rapidly progressive glomerulonephritis (RPGN).

Contraindications :

1. Non-cooperative patient.
2. Severe bleeding diathesis.
3. End-stage renal disease (ESRD).
4. Severe uncontrolled disease.
5. Patients having solitary functioning kidney.
6. Perinephric abscess, hydronephrosis or polycystic kidney disease.
7. Severe uncontrolled hypertension during the procedure.
8. Pre- and post-haemodialysis (as heparin is used during dialysis).

A must before biopsy :

1. Normal coagulation profile.
2. A full explanation of events is given to the patient.
3. Consent.
4. A specialized centre with arrangement for ultrasonic control.
5. Normal or near-normal blood pressure.
6. An IVP or renogram is performed to confirm that both kidneys are functioning.

Procedure of performing renal biopsy (transcutaneous) :

1. Position of the patient : prone with arms abducted, with a hard pillow placed under the abdomen so that the loins are slightly raised.
2. Pre-medication by oral or slow l.V injection of 10 mg diazepam.
3. The kidney is localized by USG and the biopsy site is marked with a pen.
4. Strict asepsis (by sterile mask, gloves, gown and drapes) is maintained; clean the area with antiseptic solution and inject local anaesthetic (2% lignocaine solution) along the biopsy track.
5. A small nick is made over the selected site of puncture. Instruct the patient to hold the breath and the Trucut needle' (refer to the section on 'Liver biopsy needle') is introduced through the small nick. When the needle is within the muscles, its movements are limited but as soon as it enters the kidney, its outer end sways in a wide arc with respiratory movements. Confirm this repeatedly and satisfy that the needle has reached kidney tissue.
6. The stylet is now removed and the prong is introduced through the outer coat into the renal parenchyma. A resistance to further movement is felt at this moment. The needle is advanced further over prongs so that it traps the kidney tissue incised by the prongs (the patient holds his breath during biopsy). The whole assembly is now rotated through 360° and the needle is taken out with prongs very rapidly with the trapped biopsy specimen. The biopsy tissue is sent to experienced pathologist to be examined by conventional staining, electron microscopy, and by immunoperoxidase or immunofluorescence.
7. After-care : A pressure dressing is applied over the biopsy site and the patient is placed on his ba,ck in bed for 24 hours (helps haemostasis). The patient is asked to drink plenty of fluids to prevent clot colic. The pulse, BP and respiration are checked regularly. Ask the patient to report any untoward symptom or haematuria. The patient is discharged on the next day with an advice to avoid heavy lifting or gardening for next 2 weeks.

Complications :

1. Microscopic haematuria (20%).
2. Profuse haematuria.
3. Pain in loins, sometimes referred to shoulder.
4. Perirenal haematoma, retroperitoneal haemorrhage.
5. Bowel perforation, acute pancreatitis.
6. Arteriovenous aneurysm formation.

PARACENTESIS ABDOMINIS
(ASCITIC TAPPING)

Indications :

Actually they are divided into diagnostic and therapeutic indications. As a whole, they are :

1. *Diagnostic* paracentesis (e.g., cirrhosis, tuberculous or malignant ascites).
2. Severe abdominal discomfort or cardio-respiratory embarrassment.
3. Refractory to medical therapy.
4. Danger of strangulation of umbilical hernia, if present.
5. Paracentesis may allow better abdominal examination, needle biopsy of liver, scanning or ultra-sonography.

* 2, 3, 4 and 5 are *therapeutic* indications.

Contraindications :

1. Cirrhosis of liver in hepatic pre-coma.
2. Bleeding diathesis.
3. Acute abdomen.
4. Pregnancy.

Procedure of ascitic tapping :

1. At first, urinary bladder should be emptied. The patient lies supine or semi-reclined with a back-rest. He/she is reassured and explained the procedure.
2. Under strict aseptic precautions, an I.V needle (large bore) is introduced at any one of the sites mentioned below :
   a) Midway between symphysis pubis and umbilicus (bladder must be evacuated), or
   b) Junction of lateral 1 /3rd and medial 2/3rd of the right or left spino-umbilical line.
3. The needle is connected with a rubber tubing which drains the ascitic fluid slowly into a collecting bag or bottle. In one sitting, usually 1-2 litres of fluid may be drained over 4-6 hours. In case of cirrhosis of liver, large volume paracentesis may be done by 3-5 litre of fluid aspirated in single sitting with 6-8 g/litre of salt-free albumin infusion. Diagnostic aspiration requires 20-50 ml ascitic fluid approximately.
4. After the paracentisis, the puncture site is sealed with tincture benzoin.

* Usually pre-anaesthetic medication and local anaesthesia are not required. In a restless patient, the skin and the subcutaneous tissue may be infiltrated with 2% lignocaine.

** In a small collection of peritoneal fluid, paracentesis may be tried in sitting posture of the patient.

*** An abdominal binder may be placed, and fastened slowly and steadily as fluid starts coming out.

**** Protein loss is replaced by salt-free albumin to avoid hazardous reduction in plasma volume.

***** To maintain the homeostasis, specially in cirrhosis of liver, it is better to run albumin, blood, normal saline, 5% dextrose, dextran or haemaccel during paracentesis abdominis.

Causes of dry tap :

Failure to obtain ascitic fluid on attempted aspiration may be due to,

1. Needle blockade by omental patch.
2. Perforation of a viscus.
3. Presence of very little fluid which could not be targeted blindly.

After-care needed :

The patient is monitored for next 24-48 hours for development of any complication.

Complications :

1. Sudden cardio-respiratory distress or shock (if appears during the paracentesis, immediately stop tapping the fluid).
2. Introduction of infection (peritonitis).
3. Precipitation of hepatic coma (the compressed porto-caval shunts open up and nitrogenous materials reach the brain by-passing the liver).

4. Perforation of hollow viseus (bladder or bowel).
5. Protein depletion (5 litre of ascitic fluid may contain 50-100 g of protein).
6. Constant oozing of fluid (specially in tense ascites or malignant ascites).

N.B. : **Peritoneal biopsy** is done with Cope's needle in a suspected case of tuberculous or malignant ascites, or ascites of uncertain origin.

PARACENTESIS THORACIS
(PLEURAL FLUID TAPPING/THORACENTESIS)

Indications :

1. Diagnostic — For physical, biochemical, cytological and bacteriological study of pleural fluid to come to a definitive diagnosis. Approximately, 20-50 ml of fluid should be aspirated.
2. Therapeutic — If there is,
   (i) Respiratory distress,
   (ii) Massive collection,
   (iii) Rapid collection, and
   (iv) Suspected secondary infection of effusion.

* Instillation of drugs (cytotoxics, tetracycline) are done in malignant pleural effusion.

Contraindications :

1. Coagulation disorder, plalelet abnormality.
2. Patient with severe cough or hiccough.

Procedure of thoracentesis :

1. The total procedure is explained to the patient to make him/her comfortable and relaxed.
2. The patient remains semi-reclined with a back-rest, or preferably sitting and leaning forward position with arms folded before him/her and kept over a cardiac table.
3. The site of aspiration may be :
   a) 6th intercostal space (ICS) in the midaxillary line,
   b) 7th ICS in the posterior axillary line, or
   c) 8th ICS in the scapular line.
   d) Loculated or encysted effusion — area of maximum dullness is the site of puncture (may require USG-guidance for actual localisation).
4. The local part is prepared under strict aseptic condition by spirit, iodine or ether. The site of aspiration is infiltrated from the skin upto parietal pleura through subcutaneous tissue with 2% lignocaine solution. The pleural aspiration needle (may be an l.V needle) is inserted right angle to the skin, just above the upper border of the lower rib (nerves and intercostal vessels traverse along the lower border of the rib) to avoid injury to vessels and nerves, till the parietal pleura is punctured with a 'give away' sensation (pleural puncture may be associated with bouts of cough). The needle is then attached to a three-way cannula (adaptor), and the cannula is in turn connected with a 50 ml syringe. Application of suction in the syringe draws pleural fluid into the syringe which is pushed into a kidney-tray via the outlet of three-way cannula by adjusting its screw.
5. Fluid should be aspirated slowly and as much as possible until it is harmful for the patient (therapeutic aspiration). Few clinicians advocate not to aspirate more than 1 litre of pleural fluid on the first occasion because of the risk of the development of acute pulmonary oedema. Repeat aspiration may be done after 3-4 days, after a check X-ray chest to note the amount of fluid remained/collected or amount of expansion of the passively collapsed lung.
6. If the patient complains of cough, respiratory distress, tightness in the chest or becomes severely restless, the aspiration must be abandoned immediately.
7. The puncture site is sealed with tincture benzoin when the paracentesis is over. The patient should be monitored for next 24-28 hours for development of any complication.

Complications :

1. Pleural shock (as a result of vagal inhibition).
2. Empyema thoroacis.
3. Hydropneumothorax (iatrogenic).
4. Acute pulmonary oedema (non-cardiogenic) - if the fluid is aspirated very rapidly; unilateral.
5. Air embolism.
6. Injury to intercostal vessels and nerves.
7. Haemothorax.
8. Cardio-respiratory embarrassment with circulatory collapse.
9. Subcutaneous emphysema.
10. Late complication (rare) - Intercostal artery aneurysm.

Causes of *dry tap* :

Failure to obtain pleural fluid on attempted aspiration may be due to,

1. Empyema thoracis having very thick pus.
2. Encysted pleural effusion (needs USG- or CT-guided aspiration).
3. Interlobar or subpulmonic effusion (needs CT-guided aspiration).
4. A case of thickened pleura, tumour of pleura or massive consolidation of lung rather than pleural effusion (X-ray picture and clinical features may be misleading/simulating).

N.B. : **Pleural biopsy** is done by Abram's or Cope's needle. If planned, it should be done at the first chance of pleural aspiration. Common **indications** are pleural malignancy, lymphoma, tuberculosis and pleural effusion of unknown aetiology. Abram's needle is a punch biopsy needle which is introduced through the skin after making a small incision by a scalpel, while position of the patient remaining the same as thoracentesis. After removing the stylet, let the pleural fluid come out; the parietal pleura is punched and the needle is lastly withdrawn with a slight rotational movement. The small piece of parietal pleura (the biopsy specimen) is collected from the notch of the needle.

PERICARDIOCENTESIS
(PERICARDIAL ASPIRATION)

Indications :

Removal of fluid from pericardial sac is indicated in,

1. Diagnostic aspiration (physical, biochemical, cytological and bacteriological study; culture of the fluid) of unexplained pericardial effusion—about 20-50 ml fluid is removed.
2. Therapeutic aspiration (as much as possible) — If there is,
   (i) Cardio-respiratory embarrassment (in cardiac tamponade),
   (ii) Rapid accumulation of fluid,
   (iii) Massive collection of fluid, and
   (iv) Rarely, in rheumatic effusion — if not cleared within 4 weeks.

Procedure of pericardiocentesis :

1. The patient reclines comfortably at 45° with a back-rest. The total procedure is explained to the patient to get his/her full co-operation, and to make him/her comfortable and relaxed.
2. The site of aspiration may be any one of the four :
   a) Epigastric or xiphisternal,
   b) Apical,
   c) Parasternal, or
   d) Posterior route.

   Pre-requisities :
   (i) At present, blind pericardiocentesis is avoided. It should be performed under ECG and echocardiographic monitoring, if possible.
   (ii) Strict asepsis (sterile mask, gloves, gown and drapes) is maintained.
   (iii) In an anxious and restless patient, pre-anaesthetic medication is done by slow l.V injection of 10 mg diazepam.

(iv) The skin and subcutaneous tissue of the site of aspiration are infiltrated by 2% lignocaine solution.

3. Any of the above mentioned sites may be selected but usually epigastric or xiphisternal route is preferred (usually recommended and safest route).
   a) Epigastric or xiphisternal : The needle (a pleural aspiration needle or an l.V needle) is inserted to the left of the xiphoid process and directed posteriorly towards the left shoulder at an angle of 45° to the skin. After piercing the skin, subcutaneous tissue and diaphragm (a resistance is felt), the needle enters the pericardial cavity. Now the needle is connected with a 50 ml syringe with or without placing a short rubber tube or three-way cannula in between the needle and the syringe. Application of suction in the syringe draws pericardial fluid into the syringe. The needle is further advanced slowly by about 5 cm and the aspiration continued cautiously. If the needle hurts the myocardium (if advanced too far), a crunching sensation is felt; immediately draw back the needle for 2-3 cm to place the tip of the needle again in the pericardial cavity.

      In few centres, an ECG electrode is attached with the needle by a crocodile clip. As soon as the needle touches the heart, the ECG shows a negative deflection while on slight withdrawal of the needle (i.e., needle in the pericardial cavity), ECG reflects a normal tracing. Requisite amount of pericardial fluid is aspirated in this way.
   b) Apical: It carries the risk of injuring the coronary arteries. In the 5th intercostal space, the needle is inserted outside the apex beat but inside the outer edge of cardiac dullness.
   c) Parasternal: This route carries the risk of injuing the internal mammary artery. The needle is inserted in the left 4th or 5th intercostal space just to the left of the sternum. In a massive pericardial effusion, the aspiration may be done in the similar way from the right side of the sternum.
   d) Posterior route : Pericardial fluid is aspirated from the inferior angle of the left scapula posteriorly.
4. After aspiration, the needle is removed and the punctured site is sealed with tincture benzoin.
5. After-care : Rest in bed for 24 hours is essential with nothing per mouth for first 4 hours. Hourly monitoring of pulse, respiration, BP and temperature are done for next 24 hours (clinical and ECG). Analgesics, sedatives or antibiotics are given whenever indicated. In suspected complications (pneumo-/haemothorax or pneumo-/haemopericardium), a chest X-ray may be taken.

N.B. : Prior to aspiration, confirm the presence of pericardial effusion by chest X-ray or echocardiography. Before doing aspiration, facilities of cardio-respiratory resuscitation including arrangement for defibrillation should be available. Repeated and rapid collection of fluid in uraemia, neoplasia and trauma may require 'window' pericardiectomy.

Complications :

1. Vasovagal attack or shock.
2. Arrhythmia (e.g., ventricular tachycardia).
3. Injury to the myocardium or lung.
4. Trauma to coronary/internal mammary arteries.
5. Puncture of right atrium or pulmonary conus is rare but may be life-threatening.
6. Pneumopericardium, haemopericardium or pyopericardium.
7. Contamination of left pleural space (specially when a pyopericardium is drained in the apical route).
8. Pain in the left shoulder.
9. Injury to liver or diaphragm in subcostal approach.

CHAPTER II : PATHOLOGY SPECIMENS

Observe the specimens for the following :

Size (normal/small/enlarged), shape (normal/distorted), surface (smooth/rough), position (relations of adjacent tissues to each other), capsule (present or not; normal or thickened), colour (normal colour of the parenchyma/haemorrhagic/brown/greenish) and cut section (longitudinal, transverse or oblique cut; the normal as well as the abnormal areas. Contents : normally found or not e.g., an abscess cavity with pus).

I. LUNG

The specimen is identified as lung by the presence of pleura, hilum and bronchovascular structures; blackish pigmentation may be distributed throughout the surface.

1. Lobar pneumonia

There is progressive outpouring of inflammatory exudate into the alveoli in response to the irritation produced by pneumococcus, staphylococcus etc. Air in the alveoli is replaced by the exudate and the lung or part of it is converted into a solid and airless organ (just like liver). This is known as consolidation or 'hepatisation'. The *lesion is divided into four stages* and one or more stages may be seen at a time. This is a progressive process starting from hilum and sweeping out to the periphery involving one or more lobes, and sometimes both the lungs.

Macroscopic (gross) :

(A) Stage I or stage of hyperaemia/congestion (1-2 days) —

The lung is voluminous and greyish red in colour; pits on pressure (oedema). Frothy fluid comes out from the cut surface on application of pressure.

(B) Stage II or stage of red hepatisation (2-4 days) —

The cut surface looks red, dry, granular, friable, solid-like liver with sharp margins. The outer surface is covered with a fibrinous exudate and the cut pieces of lung sinks in water.

(C) State III or stage of grey hepatisation (4-7 days) —

The cut surface looks greyish, moist, granular, more friable, airless or solid-like liver with sharp margins. The pleural exudate is thicker and the cut pieces of lung sinks in water. Bronchial lymph nodes are congested.

(D) Stage IV or stage of resolution (7th day onwards) —

Lung is soft and translucent (like jelly). Large amount of creamy fluid may come out on squeezing.

Microscopic :

(A) Stage I — Capillaries are congested, and the alveoli contains eosinophilic fluid with few neutrophils and large number of pneumococci etc; still contains air.

(B) Stage II — The alveolar wall is greatly oedematous and thickened. The alveolar fluid contains fibrin, RBC, and large number of neutrophils and organisms. The air is totally replaced by exudate and this is known as 'mosaic appearance'.

(C) Stage III — The alveolar wall becomes thin; the red cells are mere ghosts, the threads of fibrin become clumped and the organisms disappear. The exudate is collected at the centre (a space left between exudate and wall). In the late stages, polymorphs are replaced by macrophages.

(D) Stage IV — The alveolus becomes free from exudate. The debris and neutrophils are engulfed by macrophages; the fibrin masses shrunken.

Answer type (model) : The specimen of lung is showing solidification and homogeneous grey appearance. It is the grey hepatisation of lobar preumonia.

2. *Bronchopneumonia*

Macroscopic (morbid anatomy) :

Both the lungs show reddish brown patchy areas of consolidation with intervening normal, spongy lung parenchyma. Pleural surfaces may show thin, fibrinous exudate. Bronchial lymph nodes are enlarged.

Microscopic :

1. The bronchiolar wall is inflammed with congested blood vessels. The lumen of the bronchiole is filled with exudate containing pus cells, desquamated epithelium, few RBC, WBC, little fibrin and organism.
2. Peribronchiolar inflammation — Bronchiole is surrounded by a ring of alveoli filled with inflammatory exudate consisting mainly of neutrophils and fibrin.
3. Consolidated areas may alternate with area of congestion, collapse and emphysema.

Answer type (model): This is a specimen of lung from a child (as the specimen seems small) which shows several greyish patches and few bulbous patches over the lung. Both the lungs are involved; it is the specimen of bronchopneumonia.

3. *Lung abscess*

Macroscopic :

The site, size and number of lung abscess vary according to the aetiology.

1. Site, size and number — Not constant in aspiration or inhalation type; the abscess Is usually found in lower part of right upper lobe or the apical region of right lower lobe as a result of vertical disposition of right main bronchus; It is of moderate or big size.

   Abscess following septicaemia are usually small and present anywhere In both lungs. Post-pneumonic abscess Is also found anywhere in the lungs.
2. Gross appearance — Usually the abscess contains yellow, foetid pus. In early stages, the abscess looks yellow with a thin red rim and feels firm. In aspiration or inhalation type, the cavity communicates with bronchus. The wall of the cavity is usually ragged and necrotic but in chronic abscess, it may be smooth due to fibrosis. Multiple small abscesses surrounding the main abscess, bronchiectatic changes, pleural inflammation (pleurisy) may be seen.

Microscopic :

Acute variety shows destruction of lung parenchyma with dense polymorphonuclear and varying number of macrophagic infiltration. The blood vessels are dilated. Alveolar walls are destroyed. The chronic abscess shows a surrounding rim of fibrous tissue.

Embolic abscess shows from inside outwards :

1. Zone of necrosis.
2. Zone of consolidation.
3. Zone of congestion.
4. Zone of fibrosis.

Answer type (model) : It is a specimen of lung showing a big cavity In the middle part; it is lung abscess.

4. *Pulmonary tuberculosis*

Different forms of morbid anatomy are seen in pulmonary tuberculosis which is commonly associated with overlying pleural involvement.

Macroscopic :

(A) Fibroid type — Affected areas of lungs show small, depressed, pigmented and firm (to touch) areas due to extensive fibrosis. Adjacent lung tissue may reveal emphysematous (compensatory) or bronchiectatic changes. The overlying pleura is involved with dense adhesions to the surrounding structures.

On microscopical examination (M/E), extensive proliferation of fibrous tissue infiltrated with giant cells, epitheloid cells and lymphocytes are seen with scanty necrotic areas.

(B) Chronic fibrocaseous type — This is the characteristic lesion of reinfection type. At the apex of

the lung, 'cavity' in formed; the walls of the cavity is smooth due to fibrosis and is traversed by bronchioles and blood vessels. There are features of consolidation, central cavitation and caseation of cheesy material. Surrounding lung tissue may show emphysematous and bronchiectatic changes. The pleura is thickened with adhesion to parietis.

(C) Acute caseous pneumonic type — This type of infection is seen where the virulence of the organism is maximum with least immunity present in the victim. The entire lung is converted into a solid, airless organ (like grey hepatisation of lobar pneumonia). Widespread caseous areas coalesce to form larger areas and the whole lung may appear pneumonic. 'Acute cavities' may be formed which are small, multiple with irregular lining in the walls.

(D) Miliary tuberculosis — The lungs are studded with multiple tubercles which are greyish translucent in appearance and usually of 1 mm in diameter; when caseation starts, they become opaque and yellowish. The tubercles are not surrounded by zone of congestion (in multiple lung abscesses, the small abscesses are surrounded by a congested zone). The pleura may be thickened and adherent to the parenchyma. The tubercles look like millet seeds and hence called miliary tubercle.

(E) Tuberculoma — Usually solitary and is found in upper lobe; consists of a nodular area of caseation necrosis with surrounding fibrosis. The cut surface reveals caseation with foci of calcification.

Microscopic :

The classical **'tubercle'** (the fundamental unit of lesion caused by M. tuberculosis) consists of central area of caseation surrounded by a rim of epitheloid cells, Langhans' giant cells and lymphocytes, and varying degree of fibrosis. Epitheloid cells are the most characteristic cells of a tuberculous lesion.

Answer type (model) : This a specimen of lung of a child where the upper lobe is caseated; it is acute caseous pneumonic tuberculosis. Or, the specimen shows multiple 'sago' grain appearance in the lung — a specimen of miliary tuberculosis.

Table 7 : Differentiation between tuberculous and lung abscess cavity

	Tuberculous cavity		Lung abscess cavity
1.	Usually apical or sub-apical	1.	No constant site. Usualy present in the lower part of right upper lobe or apical region of right lower lobe
2.	Wall — usually smooth	2.	Wall is ragged
3.	Contains caseous material	3.	Contains pus
4.	Adjacent lung tissue shows acinar lesion	4.	Usually normal but may show secondary abscess
5.	Hilar nodes are caseated	5.	Hilar nodes are enlarged and congested.
6.	Caused by M. tuberculosis	6.	Caused usually by pyogenic organisms
7.	Microscopy — structure of tubercle	7.	Microscopy — structure of an abscess seen

5. Bronchiectasis

It is the permanent dilatation of the bronchioles which may be either localised or generalised.

Macroscopic :

The affection may is unilateral or bilateral with involvement of the lower lobes mostly. The dilatation may be cylindrical, saccular, fusiform or beaded. The mucous membrane of the bronchus is hypertrophied and congested with dilated blood vessels. The lumen of the bronchus (known as bronchiectatic cavity) may contain pus. The bronchiectatic cavity may be small or big like an orange. Pneumonitis may be revealed in the surrounding lung tissue.

Microscopic ;

The mucosa may be hypertrophied or atrophied (lately). There is destruction of the musculo-elastic tissue of the bronchial wall (most significant) resulting in dilatation, and replacement by fibrous tissue in

advanced stages. The cavity may contain pus, pus cells and RBC. Adjacent lung alveoli may reveal pneumonitis, collapse or emphysema.

Answer type (model): A cut section of specimen of lung showing multiple cylindrical or fusiform cavities, present in the lower lobe and few of them showing pus within a specimen of bronchiectasis.

6. *Emphysema*

Macroscopic :

The lung looks voluminous and more airy; pale and dry. Large bullae (thin-walled air spaces more than one centemeter In diameter, and are produced by rupture of alveolar walls) may develop which are usually subpleural in location and remain along the sharp margins of the lung.

Microscopic :

Large, distended, airy (clean) alveoli are seen with broken alveolar septae.

Answer type (model) : A voluminous, airy, pale, dry specimen of lung with multiple subpleural bullae : a specimen of emphysema.

7. *Bronchogenic carcinoma*

Macroscopic :

Hilar type Is the commonest. Squamous cell carcinoma usually arise centrally whereas adenocarcinoma arise from peripheral part of the lung. Commonly a 'firm, greyish-white mass' comes out of a bronchus which may produce obstruction of the bronchus by extending within the lumen or giving pressure from outside. Sometimes no growth is seen, instead a white fibrous thickening, roughening and narrowing of the bronchial wall are found. In diffuse variety, the whole of the lung may be filled with malignant deposit.

The bronchial lymph nodes may be enlarged. Secondary changes in other parts of the lung result in collapse, bronchiectasis and abscess formation. The overlying pleura may be thickened and adherent to the parietis.

Microscopic :

(A) Squamous cell carcinoma — Bronchial epithelium changes into squamous type due to metaplasia and the tumour originates from this squamous cell is known as epidermoid carcinoma. From the basement membrane, solid columns of malignant cells go downwards — the distal part of which expands and the whole appearance seems to be 'flask-like'. Large eosinophilic (irregular) cells with intracellular bridges, mitosis, and cell nests (epithelial pearl) are seen.

(B) Adenocarcinoma — Single layered tall columner cells are seen lining the alveolar septa along with small hyperchromatic nuclei. A glandular pattern is formed by the cells which are rich in 'mucin' but sometimes the glandular structure may be distorted. The stroma varies greatly in density and amount.

(C) Anaplastic carcinoma — The cells vary greatly in shape and size. The parent structure can not be identified and thus known as anaplastic type. There is presence of sheets of small or large undifferentiated pleomorphic cells.

Answer type (model): A specimen of lung showing a firm, grehish-white mass within : probably a specimen of bronchogenic carcinoma.

II. KIDNEY

1. *Acute glomerulonephritis*

Macroscopic :

Both the kidneys are involved; slightly enlarged and congested. The capsule Is tense but can be removed easily. The cut surface shows pale cortex and congested medulla.

Microscopic :

Initially, there is dilatation of glomerular capillaries followed by proliferation of endothelial cells. Thus Bowman's capsule is distended and obliterates the Bowman's space. Capsular space contains serum, fibrin, RBC and WBC.

Tubular cells show cloudy swelling and fatty changes. The lumen of the tubule contains inflammatory exudate. Interstitial tissue shows lymphocytic infiltration.

2. *Granular contracted kidney*

Macroscopic :

Both the kidneys look smaller and pale with a granular surface. Pelvic fat and cortex are thinned out. The final stage of chronic renal failure produces granular contracted kidney and the common aetiology are,

1. Chronic glomerulonephritis.
2. Benign nephrosclerosis.
3. Chronic pyelonephritis.
4. Late stage of tuberculosis of kidney.

The differential diagnosis is done by :

(A) Chronic glomerulonephritis — The kidneys are small, pale, hard and finely granular. The capsule is adherent and can not be stripped off easily. The outer surface may have few retention cysts. The cut section shows extreme irregularity and atrophy of cortex. Medulla remains normal. Pelvic fat is increased.

(B) Benign nephrosclerosis — same as chronic glomerulonephritis except,

a) The colour is red,

b) Coarse granularities,

c) Retention cysts are more common, and

d) More contracted.

(C) Chronic pyelonephritis — The surface is coarse and irregularly granular; capsule is adherent. The cut section reveals involvement of both cortex and medulla.

(D) Late stage of tuberculosis of kidney — In the early stage, kidney is enlarged but fibrous tissue develops in the late stage and the kidney becomes small and contracted. The cut section shows presence of tubercle (both in cortex and medulla), tuberculous ulcers, yellow streaks etc.

Microscopic :

(A) Chronic glomerulonephritis — Varying degree, of atrophy, hypertrophy and hyalinisation are seen in glomeruli and tubules.

(B) Benign nephrosclerosis — Smallest vessels show hyaline degeneration (e.g., afferent arterioles). There is sharply defined acidophilic thickening of the sub-intimal tissue (gradually the entire thickness is involved and thus, the lumen is obliterated). The internal elastic lamina splits up into several layers by the process of reduplication. Ultimately, closure of the arterioles ends in hyalinisation of glomeruli.

(C) Chronic pyelonephritis — The most characteristic feature is peri-glomerular fibrosis. There is round cell infiltration in the interstitium. End-arteritis obliterans may be noted.

(D) Late stage of tuberculosis of kidney — Classical picture of a tubercle is seen.

3. *Large white kidney*

Macroscopic :

The kidneys are large in size, smooth, pale (white) and soft. The capsule is tense and thickened but can be stripped off easily.

The different aetiology are,

1. Subacute glomerulonephritis.
2. Amyloidosis.
3. Nephrotic syndrome.
4. Lipoid nephrosis.
5. Diabetic nephrosis (K.W. syndrome).
6. Toxaemia of pregnancy.
7. Leukaemic infiltrations.
8. Early stages of tuberculosis of kidney.

9. Hydronephrosis.
10. Polycystic kidney.

Microscopic :

(A) Subacute glomerulonephritis — There is proliferation of the parietal layer of the capsular epithelium into the capsular space and is known as 'epithelial crescents'. ,

(B) Amyloid nephrosis —- Waxy pale amyloid deposits are characteristically seen in glomeruli between the basement membrane, in the wall of arterioles and around the collecting tubules.

(C) Hydronephrosis — Complete destruction of renal parenchyma is noted. Some glomeruli are normal and some are fibrosed; tubules are atrophied, and the renal parenchyma is replaced by fibrous tissue.

* *Why large ?*

Collection of fluid within the kidney (i.e., interstitium) as well as deposition of lipid makes the kidney large.

** *Why white* ?

Deposition of lipid and collection of fluid within the interstitial space (blood vessels are compressed) make the kidney pale (white).

4. *Flea bitten kidney*

Macroscopic :

The kidney is enlarged and soft; outer surface is smooth with multiple tiny haemorrhagic areas varying from dark red to black in colour, giving the 'flea bitten' appearance. The cut section shows similar haemorrhagic areas on cortex.

The different aetiology are,

1. Subacute bacterial endocarditis.
2. Malignant hypertension.
3. Septicaemia.
4. Disseminated intravascular coagulation (DIC).
5. Microangiopathic haemolytic anaemia e.g., thrombotic throbocytopenic purpura; abruptio placentae or amniotic fluid embolism.

Microscopic :

This depends on the underlying aetiology. There is cellular hyperplasia and arteriolar necrosis in the vessels; focal glomerulitis with presence of small 'focal glomerular thrombi'; tubular hyperplasia (compensatory) may be seen.

5. *Polycystic kidney*

Macroscopic :

This congenital malformation almost always affects both the kidneys. The kidneys are enlarged, sometimes enormously, and one kidney may be more bigger than the other. There are numerous thin-walled cysts of different sizes present in the kidney (irregular outline) giving the appearance of bunch of grapes. Some of the cysts are white in colour, whereas others are brown (due to haemorrhagic fluid). The cut section shows numerous, irregular cysts of different sizes often filled with greenish-yellow gel; the cut surface lacks normal kidney tissue.

Microscopic :

Small cysts lined by tubular epithelium are seen. Surrounding normal kidney tissue is attenuated.

6. *Hypernephroma*

Macroscopic :

The tumour may arise from any one pole of the kidney, commonly the upper one (thus the shape of the kidney is preserved). The mass is usually oval or spherical in shape, and may have lobulations on the surface. The tumour is imperfectly coverd by a capsule made of condensed renal tissue and fibrous tissue; from the capsule, fibrous trabeculae run radially inside the tumour mass, subdividing it into numerous lobules.

The cut section shows characteristic variegated appearance —

1. Healthy parts of the tumour may look golden-yellow in colour (due to deposition of cholesterol and fat), but may be white.
2. The other areas may show fibrosis, necrosis, haemorrhage or cystic changes (containing clear fluid or haemorrhagic fluid; cysts may have red, brown, green or black colour).

Microscopic :

Unlike variegated macroscopic appearance, hypernephroma has a characteristic uniform appearance under the microscope.

1. Cell character — Anaplastic or foamy cells (most characteristic cells; cytoplasm contain glycogen and lipid materials which are washed out by the fat solvents during preparation and fixing, giving the appearance of vacuoles within the cytoplsm), dark cells, clear cells with centrally placed dark nucleus.
2. Cell arrangement — Cord-like, sheet-like, gland-like or tubular pattern.
3. Stroma — Fibrous tissue is scanty.
4. Blood vessels — Numerous, immature and thin-walled (so, haemorrhage occurs commonly).

III. NERVOUS SYSTEM

1. *Meningitis*

Leptomeningitis — Inflammation takes place in the arachnoid and pia matter.

Patchy meningitis — The dura matter is inflammed.

Macroscopic :

(A) Pyogenic meningitis — Purulent exudate extend mainly over the frontal and parietal regions of the brain. Exudate may look green; though thick, it is less thicker than tuberculous meningitis.

(B) Tuberculous meningitis — Abundant, creamy or gelatinous exudate is seen, mainly over the base of the brain. The exudate is thick and may encase all the structures of the brain. Numerous small tubercles may be found scattered over the brain.

Microscopic :

(A) Pyogenic meningitis — The subarachnoid space is filled with inflammatory exudate consisting mainly of polymorphs, scanty fibrin, RBC and bacteria. The blood vessels are congested.

(B) Tuberculous meningitis — The inflammatory exudate mainly comprises of lymphocytes. Tubercles may be seen in various stages of formation.

2. *Brain abscess*

Macroscopic :

Any area of brain may be affected depending on the source of infection. A solitary abscess may be formed or multiple small abscesses may be seen in septicaemia. On the surface, an area of congestion is seen with suppuration. Features of cerebral oedema may be present (obliteration of sulci and flattening of gyri). The cut section shows an abscess with loculation of pus. A chronic abscess may have a tough capsule.

Microscopic :

Area of necrosis with cellular infiltration, mainly polymorphs and macrophages, are seen.

IV. CARDIOVASCULAR SYSTEM

1. *Rheumatic heart disease*

The pathology of rheumatic heart disease is described in three stages, i.e.,

a) Stage of exudation, oedema and fibrinoid degeneration of collagen tissues,

b) Stage of proliferation with Aschoff bodies formation, and

c) Stage of healing by fibrosis.

All the three layers of the heart is inflammed i.e., it is 'pancarditis'.

Macroscopic :

(A) Endocarditis — MacCallum patch i.e., a whitish, rough and thickened patch may be seen, particularly on the posterior wall of the left auricle just above the mitral valve. In the valvular endocardium, mitral and aortic valves are commonly affected. Valve cusps become oedematous, thickened and there is formation of Aschoff bodies in the subendothelial connective tissue. In course of time the surface endothelium becomes raw, and platelet and fibrin are deposited there giving rise to minute pale thrombi; ultimately these rheumatic nodules become organised and covered by adjacent endocardium, and is known as 'rheumatic vegetations'. These are very small (size of a pin'g head), sessile, warty nodules present a few millimeter away from the margin of the cusps knd are arranged in a row. Aschoff bodies are found in chordae tendineae which ultimately becomes thickned, shortened and fibrosed. Valves may be stenosed, specially the mitral and the aortic valve.

(B) Myocarditis — Aschoff bodies are formed in the left side of the heart mainly (due to more strain). They are mostly found in the left ventricle, base of the interventricular septum and base of the mitral valve. Ultimately myocardial fibrosis and myocardial failure may result.

(C) Pericarditis — The pericardium loses its shiny appearance and becomes rough. Acute fibrinous inflammation binds the two layers of pericardium, and when seperated the rough surfaces show 'bread and butter' appearance. There may be exudative collection in the pericardial sac.

Microscopic :

The Aschoff bodies are found around the blood vessels. They are the fundamental units of lesion in rheumatic heart disease, and consist of :

a) Central necrotic area,

b) Surrounded by lymphocytes, plasma cells, occasionally polymorphs,

c) Aschoff cells — large, multinucleated giant cells containing 5-7 nucleoli, and

d) Proliferation of fibroblasts encircling the above elements.

Anitschkow myocytes — large vesicular nucleus containing coarse chromatin, and threads of fibrin from the center to the periphery (cardiac cell with caterpillar nucleus) may also be seen.

2. *Pericarditis*

Macroscopic :

Commonly fibrinous pericarditis is dealt with. The glossy appearance of pericardium is lost, and it becomes rough. Fibrinous exudate binds, organises and produces adhesions between the two layers of pericardium. If the layers are tried to be separated, they give a 'bread and butter' appearance.

Besides this (fbrinous exudate) serous, sero-fibrinous, haemorrhagic or purulent exudate may be collected within the pericardial sac.

3. *Bacterial (infective) endocarditis*

Macroscopic :

Large, friable, polypoid vegetations originate in the line of contact of valve (commonly mitral and aortic) and may spread to involve the whole valve and the mural endocardium. The vegetations get easily detached and produce embolism. The vegetations in subacute bacterial endocarditis are larger than rheumatic vegetations but smaller than that of acute bacterial endocarditis.

Microscopic :

The vegetations consist of network of platelet and fibrin entangling inflammatory cells, chiefly polymorphs, clumps of bacteria and desquamated endothelial cells.

4. *Atherosclerosis of the aorta*

It is a degenerative condition of the arterial wall characterised by deposition of lipid materials in the deepest part of intima of large elastic and muscular arteries.

Macroscopic :

Most commonly the abdominal aorta is involved (as a result of maximum trauma and greater hydrostatic presure). Coronary, cerebral, renal, and other visceral vassels as well as big vessels of the limbs may be affected by the process. Depending of the stage, there may be presence of fatty streaks, wax like drops, atheromatous ulcer, thrombi (fibrin and platelet clump), calcification or haemorrhages in the intima.

Microscopic :

a) Cytoplasm of intimal smooth muscle fibres accumulates lipid and transforms into foamy cells.
b) The foamy cells die and release their contents, extracellular lipid pool appears. This leads to classical slit-like spaces in cholesterol crystals.
c) Connective tissues of intima overlying the cholesterol deposit becomes thickened — the sclerotic part of atherosclerosis.
d) A mature 'fibro-lipid plaque' consists of a core of extracellular lipid surrounded by smooth muscle cells and is seperated from the lumen of the vessel by collagen rich fibrous tissue. There may be vascularisation under the plaque.
e) Haemorrhage, thrombus formation or calcification may be noted.

5. Syphilitic aortitis

Macroscopic :

The lesion starts at the root of the ascending aorta just distal to the aortic valve, and spreads horizontally around the root of aorta and distally as far as the mouths of the great vessels. Ascending aorta, arch of aorta and rarely the descending thoracic aorta are the site of involvement due to their rich lymph supply (organisms are carried through lymphatics). It never affects the coronary artery except its opening; never affects the endocardium except the endocardium covering the aortic valve. The aortic valve may be thickned with shortened cusps and widened commissures.

Affected intima may be raised into patches— at first smooth and pearly, later pitted and scarred. Intervening area is wrinkled. It is the fine transverse wrinkles (as a result of stellate scars) which are highly characteristic of syphilis (tree bark appearance). Atherosclerosis of the aorta often complicates syphilis.

Microscopic :

There is periaortitis and mesoaortitis with secondary changes in the intima.

Intima shows marked fibrous proliferation, hyalinisation and endarteritis obliterans. Media shows ischaemic necrosis with foci of inflammatory cells. Vasa vasorum shows perivascular infiltration of lymphocytes and plasma cells. There is gumma formation, specially around the lymphatic channels and vasa vasorum.

V. INTESTINE

(A) SMALL INTESTINE :

1. Tuberculosis of intestine

Macroscopic :

Classical site is ileocaecal junction but it may extend upto ascending colon or descend upto caecum. Small grey tubercles are seen over the Peyer's patches or lymph follicles opposite the attachment of mesentery. Tubercles undergo caseation necrosis and breaks down into ulcers with ragged and undermined edge. The lie of the ulcer is 'transverse' and thus known as 'girdle ulcer'; when this ulcer heals by fibrosis, it may result in intestinal obstruction (there may be stricture formation). The floor of the ulcer is mammiliated (covered with necrotic tissue). The serosal surface is covered with plastic inflammatory exudate (so, perforation is rare) and sometimes with small tubercles. Mensenteric lymph nodes are caseated.

Microscopic :

Ulceration is present in the mucosa with classical 'tubercle' formation which may extend upto serous layer. Blood vessels may show endarteritis obliterans.

2. *Typhoid lesion (enteric fever)*

Macroscopic :

Classical site of involvement is terminal ileum and ileocaecal region. There is hypertrophy of the Peyer's patches and solitary lymph follicles opposite the mesenteric attachment with occasional ulcer formation. The ulcer is oval or round, and they grow along the longitudinal axis of the gut (vertical ulcer); Crohn's disease also produces longitudinal ulcer. They edge is raised and smooth, but not undermined. The floor is shieve-like (worm-eaten); the floor is formed by submucous and muscle coat but may extend upto serous coat (so, perforation are likely). Mesenteric lymph nodes are enlarged and congested.

Microscopic :

Ulcerated mucosa, hyperplasia of lymph follicles and hypertrophy of Peyer's patches with submucosa infiltrated by mononuclear cells are seen.

(B) LARGE INTESTINE :

1. *Amoebic ulcer*

Macroscopic :

Classically there are two levels of involvement : more commonly the ileocaecal region and less commonly the rectosigmoid region. The shape is oval or round; the margin is undermined and ragged, often formed by the overhanging mucosa (flask-shaped ulcer). The floor is formed by the muscle coat and covered by the necrotic slough (yellow or black). The intervening mucosa seems to be normal. The overlying serous coat may be thickened.

Microscopic :

Flask-shaped ulcer formation with absence of E. histolytica at the centre; the trophozoites are found at the periphery. Proliferation of endothelial Cells of neighbouring blood vessels causing their thrombosis may also be seen.

2. *Bacillary dysentery ulcer*

Macroscopic :

The ulcers are mainly superficial and diffuse. The shape is irregular or snail-track, sometimes communicates with the submucous coat. The floor of the ulcer is very shallow and remain on the mucous coat; the margin is sharp. The intervening mucosa is swollen and oedematous. Overlying peritoneum is usually normal.

Microscopic :

There is absence of mucous membrane; presence of fibrin, RBC, WBC and pus cells over the mucous coat which forms a 'pseudomembrane'. All the layers of intestine are infiltrated with inflammatory cells. The blood vessels are dilated.

VI. LIVER

1. Cirrhosis of liver

Macroscopic :

The size of the liver is variable (i.e., increased or decreased) depending upon hyperplasia and fibrosis; usually shrunken. The outer surface may have fine nodules (micronodular cirrhosis) giving the liver 'Hob-nail appearance', or have large-irregular nodules (macronodular cirrhosis). The colour of the liver in portal cirrhosis is usually brownish (due to deposition of iron pigment) and it is greenish in biliary cirrhosis. The consistency is very firm (due to fibrosis). The liver gives resistance on cutting and the cut section shows nodules and strands of pale yellow bands of fibrous tissue intercepting the hepatic architecture.

Microscopic :

The hepatic lobular architecture is destroyed. Broad bands of fibrous tissue divide and sub-divide a lobule with the result that the position of the central vein is no longer at the center of the lobule. There is

presence of necrosis as well as regeneration of new liver cells (irregular in size and arrangement). Round cell infiltration with proliferation of biliary epithelium are seen in the portal canal.

2. *Amoebic liver abscess*

Macrocopic :

The liver is enlarged and congested. There is presence of a big abscess, commonly at the postero-superior part of the right lobe. Usually a single abscess (big) is seen which may be surrounded by multiple small abscesses. The cut section would show an abscess filled with chocolate coloured pus, better known as anchovy-sauce pus. The content is not true pus but it is an admixture of cytolysed hepatocytes with blood. The wall of the cavity in irregular and ragged.

3. *Pyogenic liver abscess*

Macroscopic :

The whole of the liver is enlarged. There are multiple, small abscesses (necrosed area) seen scattered throughout the liver. Any lobe of the liver may be affected and the right lobe is affected more than the left lobe. The cut section would reveal yellow-coloured pus coming out from the abscess cavity. The wall of the abscess cavity is usually ragged.

4. *Hepato-cellular carcinoma (hepatoma)*

Macroscopic :

In primary carcinoma of the liver, the enlargement usually occurs irregularly. Commonly, one large tumour (nodular or diffuse) may be seen with a few small outlying seedling nodules. The intervening portions of the liver is very firm as hepatomas are commonly seen in cirrhosis of liver. The blood vessels or the bile duct may be involved by extension.

5. *Secondary carcinoma of the liver (metastasis)*

Macroscopic :

The liver is enlarged and studded with multiple big nodules. The irregular nodules show depression at the top and is known as 'umbilication' (due to rapid growth of the tumour there is dimpling as a result of central necrosis). The cut section of a nodule may show area of haemorrhage and necrosis but usually it is greyish-white in colour. There is absence of cirrhotic change in the intervening areas.

'Umbilication' differentiates secondary carcinoma of liver from nodular liver arising out of post-necrotic cirrhosis or hepato-cellular carcinoma.

CHAPTER III : RADIOLOGY

IA] X-RAY CHEST

Preface :

X-rays (electromagnetic rays) were discovered by Sir Wilhelm Conrad Roentgen in November 8, 1895. As on today, the plain radiograph of the chest is still the primary investigation for chest examination.

In the day to day practice, postero-anterior and lateral view of the chest are taken to visualise the lung detail. Depending upon the direction of the rays from the X-ray tube to the X-ray plate, antero-posterior (AP), postero-anterior (PA) and lateral projections are made in roentgenographic examination.

In the PA view, the person should stand erect with the anterior chest closely attached against the X-ray cassette containing the X-ray film, with the hands placed on the waist and the elbows drawn a bit anteriorly. By placing the elbows in a forward direction, the scapulae goes apart and thus they never produce obstruction to the lung fields. The tube-film distance should be about 6 feet or 2 meters, in order to minimise distortion and magnification. *In PA view, the beam of rays falls from behind while in AP view, the beam of raysfalls from the front.* The PA view is preferred because, (a) this view gives a wider lung field as well as a clear picture of bronchovascular shadow (in an AP view, cardiac size is more exaggerated and obstructs part of lung fields), and (b) radiation-risk to eyes is negligible. AP view is often ordered (with the patient supine) in very sick patients who are unable to stand or sit, and in infants. Lateral view (e.g., left lateral film is one which is taken with the left side of the patient's chest placed next to the film), recumbent view (X-ray taken in lying down position, usually supine when the patient is unable to stand due to serious illness), decubitus film (right or left lateral decubitus position) or oblique view (i.e., right anterior, left anterior, right posterior, and left posterior oblique) are taken in special situations. Lateral view of the chest is essential for the identification of lobes and segmental details of lung.

The view of plain films may be :

1. PA, lateral.
2. AP (patient unable to stand/portable X-ray), decubitus (subpulmonary effusion), supine, oblique (for retrocardiac area).
3. Inspiratory-expiratory (air trapping and diaphragmatic movement).
4. Lordotic (e.g., middle lobe collapse), apical (for good visualisation of apex), penetrated (for enlarged left atrium and aorta).
5. Portable/mobile X-ray.

An ideal chest X-ray film should have :

1. Proper exposure (i.e., dose of radiation)—In general, it is desirable that the upper thoracic vertebrae (not all vertebrae) be just barely discernible through the cardiomediastinal shadow. Overexposure makes the lung fields more black with a clear view of vertebral bodies; underexposure makes the lung fields hazy. In overpenetrated films, one may overlook low density lesions. Ideally films should be of medium contrast.
2. Proper labelling by radiology technician—The technician puts 'R' (right) or 'L' (left) in the upper comer of the X-ray plate for side determination. He should label the plate properly with the date of exposure. The physician should read the label at the beginning, otherwise a case of dextrocardia may be missed.
3. Proper centering—The clavicles should be at the same level and the inner ends of the clavicles should be equidistant from the midline i.e., from the spinous process of the vertebral column (or, the gap in the sternoclavicular articulation should be the same on both sides).

The cartilagenous rings of trachea are not visible though the air within trachea may be seen as a dark column (black). Normally, the trachea is slightly deviated to the right.

The scapula should not project over the lung fields. It should be remembered that approximately 75% of the lung fields are seen in routine PA view of the chest (25% lung fields are obstructed by clavicles, ribs, cardiovascular shadow and subdiaphragmatic tissue).

A routine chest X-ray should be always taken in full inspiration except in a case of suspected small pneumothorax. PA view of chest taken in expiration makes the cardiac size enlarged and lung bases hazy. While taking an X-ray, the patient should be unclothed, long hairs should be pinned up, radio-opaque materials e.g., jewelleries should be removed. For lateral view, the patient's arms are folded and extended above the head.

The X-ray plate should be examined in a 'view-box', usually from a distance of 2 feet. The plate should be correctly mounted in the view-box. The side determination (maintaining the anatomical position) is done by the following methods :

1. Label put by the radiology technician (L or R).
2. Apex of the heart should be on the left side.
3. Fundal gas shadow should be on the left side.
4. Right dome of the diaphragm is placed at a higher level than the left.
5. Aortic knuckle should be on the left side.

In a case of rotation of viscera (dextrocardia with or without situs inversus), the above formula does not serve the purpose and one has to depend only on radiographer's labelling.

The normal chest X-ray should be read or described in the following order :

1. View (PA, lateral, oblique).
2. Exposure or penetration.
3. Centralisation.
4. Skeletal structures.
5. Lung fields including blood vessels and pleura.
6. Cardiovascular silhouette.
7. Mediastinum (including position of the trachea and cardiac apex).
8. Costophrenic and cardiophrenic angle.
9. Diaphragm.
10. Soft tissue abnormalities.
11. Final diagnosis or conclusion.

Each part is described below in a nutshell :

1. View
2. Exposure
3. Centralisation

> Described above

4. Skeletal structures — In full inspiration, 10 posterior and 6 anterior ribs should be visible. Actually the thoracic bony cage (rib cage, thoracic spine and bones of the shoulder girdle) is looked for :
   a) Kyphosis, scoliosis, straight back.
   b) Any distortion of size or shape of the chest i.e., symmetrical or not.
   c) Crowding (collapse or fibrosis of the lung) or widely spaced (emphysema) ribs.
   d) Absence of clavicle (cleidocranial dysostosis) or erosion of clavicle (bronchogenic carcinoma or multiple myeloma).
   e) Rib erosion (multiple myeloma, bronchogenic carcinoma, hyperparathyroidism) or rib notching (coarctation of aorta), fracture or healed fracture in ribs.
   f) Presence of cervical rib.
5. Lung fields including blood vessels and pleura— Normally lung fields are translucent and look reticular too (due to bronchovascular markings). The X-ray appearance of the lung fields and. the normal bronchovascular tree depends on the degree of aeration and vascular filling at the time of exposure, the size of the bronchi, and other associated anatomic and physiologic factors..

The *vascular* shadows (looks white linear) in the lung are casted by the branches of pulmonary artery. Pulmonary veins (often seen in upper lobes) produce low-density shadow. Branches of pulmonary

artery (form major bulk of hilar density) and vein are accompanied by a corresponding branch of the bronchus. The alveoli, pleura, interstitium and lymphatics produce a very low-density shadow which are rarely identified in the X-ray film. Increase in the white linear shadows (i.e., bronchovascular markings radiating from the hilar region to the periphery) may be seen in :

a) Accentuated pulmonary arteries—Left-to-right shunt in ASD, VSD and PDA.
b) Distension of pulmonary veins—In the left-sided heart failure (left ventricular or left atrial failure).
c) Accentuation of bronchial pattern—Seen in chronic bronchitis, bronchiectasis.
d) Prominence of lymphatic vessels—Commonly seen in bronchogenic carcinoma.
e) Thickened alveolar septum—Seen in pneumoconiosis, pulmonary fibrosis (interstitial lung disease).

In a normal person, the 'hilar shadows' are made up of pulmonary arteries, pulmonary veins, bronchi, hilar lymph glands, lymphatics and connective tissue components. Left hilum is slightly higher in position than the right. For the purpose of radiological description, *lung fields are divided by two horizontal lines into three zones,* i.e., upper, middle and lower zones. The upper line passes horizontally through the inferior borders of the anterior ends of the second costal cartilages; similarly the lower line passes horizontally through the inferior borders of the anterior ends of the fourth costal cartilages. The upper zone is restricted above the upper horizontal line, the mid-zone lies in between upper and lower horizontal lines, and the lower zone extends from lower horizontal line to the bases of lungs. Zones in the X-ray plate do not correspond with the lobes of the lung. Each zone is examined symmetrically on two sides and an area of abnormality is meticulously compared with the corresponding area on the other side.

The normal pleural structures are seldom visible. The pleura may be visible, if thickened or calcified.

* Bronchovascular markings become less prominent in pulmonary stenosis and pericardial effusion.

6. Cardiovascular silhouette—The cardiothoracic ratio (CTR) is expressed as a percentage of the ratio between the maximum transverse diameter of the heart and the maximum internal diameter of the chest (thorax). In health, the transverse diameter of the heart is usually equal to half the internal diameter of the chest or just less i.e., CTR = 0.5 : 1 or it is just < 0.5 : 1; cardiac enlargement is suspected if the CTR is > 0.57 : 1 or the transverse diameter of the heart is > 16 cm (though often varies with age, sex, build and nutrition). In a PA view of the chest, 2/3rd of the cardiac shadow lies on the left and 1/3rd on the right from the midline.

The CTR is a simple method to estimate cardiac enlargement. The CTR is estimated in a better way by the following measurements. First, draw a vertical line over the spinous process in the midline to divide the heart into two halves. Now, maximum extension of the heart to the right of midline (X) and maximum extension of heart to the left of midline (Y) is measured. Next, maximum internal diameter of the thorax (ID) is measured as the maximum measurement of the thorax to the inside of the ribs, at the lowermost part of the PA view of chest. Finally, the **CTR** is calculated as $X + Y$; X+Y is equivalent to maximum transverse diameter of the heart (Fig. 3.1 A).

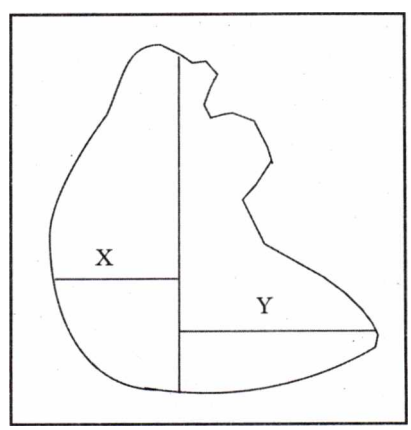

Fig. 3.1 A : Diagramatic representation of maximum transverse diameter of the heart

Borders of cardiac silhouette in PA view of chest :

(A) Right border (from above downwards) :

1. Superior vena cava (sometimes, ascending arch of the aorta takes part)—The upper straight portion.
2. Outer border of the right atrium (sometimes inferior vena cava may be visible just right to the right atrium)—The lower curved portion.

(B) Left border (from above downwards) :

1. Aortic knuckle—A convexity.
2. Pulmonary trunk (conus) or left pulmonary artery—A straight line or a concavity (known as 'pulmonary bay').
3. Left atrial appendages—The short straight portion.
4. Outer border of the left ventricle—The convexity in the lower part, ending at the apex.

Changes in the cardiac size, shape and position :

(A) Prominent aortic knuckle—Old age (unfolding of the aorta and atherosclerosis), aortic aneurysm, post-stenotic dilatation and aortitis.

(B) Concavity of the pulmonary trunk becomes convex—Pulmonary hypertension, left-to-right shunt in the heart, i.e., ASD, VSD, PDA, and idiopathic dilatation of pulmonary artery..

(C) Absent pulmonary artery shadow—Pulmonary stenosis or pulmonary atresia.

(D) Enlargement of cardiac size—Enlarged chambers of heart, pericardial effusion, cardiomyopathy. *Enlargement in transverse diameter indicates RVH, and increase in oblique diameter features LVH.*

(E) Right atrial enlargement— Enlargement of the right border of the heart (a bulge is seen).

(F) Left atrial enlargement :

(i) Straightening of the left border of the heart (the base of the pulmonary bay)

(ii) Prominence of the left atrial appendages in the left border of the heart.

(iii) Double contour of the right border of the heart (the outer and upper border is due to LA, and the inner and lower border is due to RA enlargement).

(iv) Upwards displacement of left main bronchus, and it becomes horizontal; widening of carina.

(v) Posterior displacement of barium-filled oesophagus in right anterior oblique view.

* Atrial enlargement (right or left) is often better seen in the lateral view as a posterior bulge.

(G) Right ventricular enlargement—

(i) PA view—Shifting of the apex to the left (i.e., outward enlargement only) with 'upturned' apex; and increase in the transverse diameter of the heart with 'boot-shaped' configuration.

(ii) Lateral view—Obliteration of retrosternal space from below upwards.

(H) Left ventricular enlargement—

(i) Increase in the oblique diameter of the heart.

(ii) Shifting of the apex outwards (to the left) and downwards.

7. Mediastinum—In a normal chest X-ray, trachea (the black airy tube) remains central or slightly towards the right, and evenly calibred. The thymus, pleural reflections and fibrofatty tissue may or may not be visible. Observe, whether the mediastinum is widened or not. Positions of the cardiac apex (outwards, or out and downwards) and the trachea indirectly indicate shifting of the mediastinum. In there any shadow 'behind' the heart?

8. Costophrenic and cardiophrenic angle—

a) Costophrenic angle (the angle between the diaphragm and the rib)—In a PA view of the chest; costophrenic angles should be clearly visible. Normally, it is sharp and acute in angle. In pleural effusion or empyema thoracis, this angle is obliterated first.

b) Cardiophrenic angle (the angle between the diaphragm and the cardiac broder)—In health, the right-sided angle is acute or near about right angle. In pericardial effusion, the right-sided angle becomes more acute (Rotch's sign). The left-sided angle can not be distinctly seen owing to the presence of epicardial pad of fat (specially in elderly fatty people) and thus it is of no importance radiologically.

9. Diaphragm—The right and left dome of the diaphragm are convex upwards and sharp in outline. The right dome is placed high-up (0.5 to 2.5 cm) than the left dome. In the midclavicular line, the upper limit of the right dome should be between 6th and 7th intercostal space anteriorly and 10th intercostal space posteriorly.
   a) Elevated diaphragm—Collapse or fibrosis of the lung (basal), ascites, pregnancy, diaphragmatic palsy, abdominal mass, amoebic liver abscess (right dome).
   b) Depressed or flattened dome—Emphysema (bilateral), pneumothorax (unilateral).
   c) Localised bulge or 'tenting'—Amoebic liver abscess, subdiaphragmatic abscess, pleural tumour.
10. Soft tissue abnormalities—Soft tissues of the chest wall (wart, angioma, neurofibroma), upper abdomen, neck (calcified lymph nodes) and shoulder may be visible in chest X-ray film. Breast and nipple shadows in female, stemomastoid shadows (specially in male) or gas shadows (subcutaneous emphysema) should be specially looked for. Artefacts (errors in film handling by technician may give rise to white linear shadows or hair balls, buttons may cast rounded shadows, specially in females) should be carefully identified. Check for any foreign body like endotracheal tube, Ryle's tube, chest drain or pacemaker.
11. Conclusion—A normal chest X-ray should be described in the following way (Fig. 3.1) :

    This is a PA view of the chest with normal exposure, proper centering and without any apparent bony abnormality. The trachea is centrally placed and the lung fields are clear with normal bronchovascular markings; cardiovascular silhouette is within normal limit with normal cardiothoracic ratio. The mediastinum, costophrenic and cardiophrenic angles, domes of the diaphragm and soft tissues show no abnormality.

N.B. : For cardiological check-up, following views are necessary :

1. PA 2. Lateral 3. Oblique (right and left anterior oblique views with barium swallow film of oesophagus).

* While describing an X-ray plate, always try to maintain the frame of words described in conclusion, along with the abnormalities seen. While describing individual X-ray plates in the following pages, particularly the abnormalities have been highlighted.

**** Always search for the following, in an apparently normal looking chest X-ray :**

1. Small apical pneumothorax.
2. Very small collection of pleural fluid.
3. Fluid level (e.g., hiatus hernia) or air-fluid level (e.g., achalasia) behind the cardiac shadow.
4. Rib notching, rib erosion, rib fracture, or whiteness of ribs (osteopetrosis).
5. Gas shadow under the diaphragm.
6. Deviation of trachea.
7. Paratracheal lymph node enlargement.
8. Cervical ribs (additional rib/ribs arising from the C_7 vetebra).
9. Mastectomy.
10. Right middle lobe collapse with loss of clear outline of right cardiac border.
11. Soft tissue shadows : subcutaneous emphysema (looks black), axillary lymph node swelling.

*** **Digital chest X-ray** is clean-cut, accurate, more bright and thus revolutionary.

**** **ultrasonography of chest** is indicated in :

1. Small pleural' effusion.
2. To diagnose solid or cystic nature of a superficial lesion.

***** **Q-j. scan 0f chest** is indicated in ;

1. Abnormal or doubtful shadow in chest X-ray.
2. Staging of bronchogenic carcinoma.
3. Widening of mediastinum.
4. Hilar abnormality.
5. Interstitial lung disease, bronchiectasis.
6. Abnormalitis in pleura.
7. Lesions in the chest wall.

CONSOLIDATION OF THE LUNG

(Fig. 3.2)

Description :

This is a PA view of the chest showing a sharply-defined triangular homogeneous opacity involving the right upper and mid-zone; part of the left lower zone also reveals similar opacity. Trachea and apex beat are normal in position. Both the costophrenic angles are clear.

Other points—Within normal limit.

* Air bronchogram is not clearly seen here.

Conclusion :

Consolidation of the right lung with involvement of the left lung too.

Which lobe of right lung is involved ?

It needs a lateral X-ray film to diagnose. It is expected that right upper lobe has been affected.

Differential diagnosis :

1. Collapse of the lung (mediastinum moves to the diseased side; absent air bronchogram).
2. Bronchogenic carcinoma (pleural reaction, i.e., pleural effusion is commonly seen; absence of 'air bronchogram' and there may be presence of rib erosion).
3. Pulmonary tuberculosis (classically sharply-defined consolidation is rare; pleural reaction is more common).
4. Pulmonary infarction (may be a possibility because in pulmonary infarction wedge-shaped, homogeneous, poorly-defined opacity is produced, attached against pleura; thus blunting of costophrenic angle is commonly seen here).

What is air bronchogram ?

Bronchus contains air and the air is not visible seperately in a normal chest X-ray. But in consolidation of the lung (pneumonia), the air within the bronchus casts linear translucency (black) over the background of homogeneous opacity (consolidation). These are commonly seen as scattered linear translucencies rather than continuous branching structures. Air bronchogram reflects that an opacity is intrapulmonary. It is also seen in pulmonary oedema, alveolar cell carcinoma and hyaline membrane disease. It needs a good quality of X-ray film and the observer should have an eagle's eye.

What is 'silhouette sign' ?

When two structures of same radiologic density are in same plane, then the interface between the two is obliterated, and the lack of interface is known as silhouette sign. For example, right heart border is obliterated by right middle lobe lesion (consolidation or collpse), and left heart border is obliterated by lesion in lingular lobe.

Outstanding feature in the X-ray film :

The is no shifting of mediastinum.

N.B. : Bronchopneumonia gives rise to heterogenously scattered patchy opacities without air bronchogram.

PLEURAL EFFUSION

(Fig. 3.3)

Description :

This is a "PA view of the chest showing a triangular homogeneous opacity on the left chest with a curved upper border which is concave medially and upwards, and extends towards the axilla. Left costophrenic angle is obliterated while the right angle is clear. The cardiac shadow and trachea (lower part) have shifted slightly towards the right. Lung fields are apparently normal.

Other points—Within normal limit.

* In pleural effusion, fluid collects in between two layers of pleura, i.e., visceral and parietal pleura.

Conclusion :

Left-sided moderate pleural effusion.

Differential diagnosis :

Actually this type of opacity with concave upper border is classically seen in pleural effusion and ***empyema thoracis. Thickened pleura*** may be a close D/D (usually without any mediastinal shift unless associated with gross thickening when mediastinum is shifted to the same side; ribs may be visible within the opacity, i.e., opacity is not truely dense; upper margin is fading and not concave).

Bronchogenic carcinoma or **consolidation** (with parapneumonic effusion) may be present underneath the effusion. **Fibrosis** or **collapse of the lung** (if considered in the D/D) produces mediastinal shifting to the diseased side.

Hemithorax opacity without any mediastinal shift:

1. Consolidation of the lung.
2. Malignant pleural effusion (due to associated absorption collapse of the lung).
3. Mesothelioma of the pleura.

Blunt costophrenic angle without any fluid collection (spurious) :

1. Breast shadow in females.
2. X-ray taken in expiration.
3. Basal pneumonia in the elderly.
4. Thickened pleura.

Minimal collection for radiological detection :

300 ml fluid is required (earliest clinical detection requires 500 ml fluid).

N.B. : Normally, a small amount of pleural fluid (i.e., 25 ml) is produced from capillaries in parietal pleura at a rate of 0.01 ml/kg/hour which is removed by lymphatics in parietal pleura.

Earliest site of fluid collection in x-ray film (PA view):

Small amount of fluid < 50 ml is not detected on PA view of chest X-ray. However, small effusions (e.g., 100 ml) are diagnosed earlier on lateral film where the fluid is collected in most dependent recess of pleura, the posterior costophrenic angle. A more collection (approximately 300 ml) produces obliteration of lateral costophrenic angle on PA view of chest radiograph.

Why the upper margin of fluid goes towards axilla in chest X-ray ?

Actually it is a radiological illusion. A horizontal section of hemithorax at the level of the upper margin of fluid shows that there is same amount of fluid present anteriorly, posteriorly and laterally. But it is a fact that X-ray beam traverse more fluid laterally than they do centrally because of the peculiar shape of hemithorax. So, we see the curved upper margin going towards axilla in X-ray picture.

Some clinicians opine that it is due to capillary suction between two layers of pleura, which draws the fluid up.

How to diagnose small pleural effusion ?

1. X-ray in lateral decubitus position.
2. USG of the chest.

X-ray picture mimicking pleural effusion but 'dry tap' after needling—why ?

1. Thickened pleura.
2. Empyema thoracis (wide bore needle required).
3. A mass lesion.

How malignant effusion is suspected ?

1. A convex bulge may be seen above the concave fluid level.
2. Collapse (absorption) of the lung may be associated with (in any part of either lung).

3. Trachea may be shifted to the same side (due to associated absorption collapse).
4. Elevated hemidiaphragm may indicate diaphragmatic palsy.
5. Prominence of hilar or parahilar shadow; erosion of ribs may be seen.
6. Recurrent, rapid collection of fluid.

* In this situation, first aspirate the fluid and again take a film.

** USG and CT scan differentiates easily a mass from loculated pleural effusion or pleural thickneing.

PNEUMOTHORAX

(Fig. 3.4)

Description :

This is a PA view of the chest which reveals increased translucency on the right side of the chest with absence of bronchovascular markings. A sharply defined homogeneous opacity is seen lateral to right cardiac border which indicates the collapsed right lung. Right costophrenic angle is a bit blunt but left angle is clear. Cardiac apex and tracheal shadow are not shifted in the X-ray film probably because of improper centering of the patient. Right dome of the diaphragm is a bit flattened. The left lung field is clear and normal.

Other points—Within normal limit.

Conclusion :

Right-sided pneumothorax (probably with a small amount of fluid collection in the right pleural sac).

* *In a suspected case of pneumothorax. X-ray film is taken in erect posture while breath hold in expiration.*

Types of pneumothorax :

(A) Artificial,

(B) Traumatic,

(C) Spontaneous :

(i) Closed (ii) Open, and (iii) Valvular (tension).

* To *diagnose the type of pneumothorax. HI O onset and progress of symptoms are the two most important determinants.*

Why tension pneumothorax is lethal to the patients ?

Marked mediastinal shift -> decreased venous return -> diminished cardiac output

+

Severely compromised ventilation -> arterial hypoxaemia

i

Death, unless tackled immediately. It is a medical emergency to the internist.

Unilateral hypertranslucency in chest X-ray film (D/D) :

1. Pneumothorax.
2. Bullae.
3. Lung cyst.
4. Eventration of the left dome of the diaphragm.
5. Partial bronchial obstruction (unilateral) — obstructive emphysema.
6. Co'mpensatory emphysema.
7. Contralateral thickened pleura (produces apparent increased translucency).
8. Mastectomy, congenital absence or atrophy (e.g., poliomyelitis) of pectoral muscle.
9. Poor technique (e.g., rotation), scoliosis.

* In pneumothorax, .always search for stigmata of tuberculosis in the other lung. Also look for tube drainage and surgical emphysema (i.e., collection of air in the soft tissue).

HYDROPNEUMOTHORAX

(Fig. 3.5)

Description :

This is a PA view of the chest (taken in erect posture) which shows a horizontal fluid level on left chest. There is increased translucency above the horizontal level which is lacking in lung markings ('pneumo' component) and a homogeneous opacity is seen below the horizontal level ('hydro' component). The homogeneous opacity ('hydro' component) is uniform, and medially it has merged with the cardiac silhouette. Trachea and cardiac shadow have shifted towards the right side. The right-sided costophrenic angle and the right lung show no apparent abnormality.

Other points—Within normal limit.

Conclusion :

Left-sided hydropneumothorax.

* The X-ray picture of hydropneumothorax should always be taken in erect posture.

Can you localise the collapsed left lung ?

No. It is usually hidden within the fluid and is not visible in the X-ray.

Cardinal features of hydropneumothorax :

1. Shifting dullness,
2. Succussion splash, and
3. Horizontal fluid level (upper limit of dullness is horizontal).

Differential diagnosis :

1. Haemopneumothorax or pyopneumothorax.
2. Infected lung cyst.
3. Very big lung abscess.

EMPHYSEMA

(Fig. 3.6)

Description :

This is a PA view of the chest which shows hypertranslucency of both the lung fields, wide intercostal spaces, low-flat diaphragm, narrow vertical heart (tear-drop heart), large and prominent hilar shadows with diminished peripheral vascular pattern. Few *'bullae'* are seen as rounded areas of increased translucency with thin hair-line shadow forming the walls. *There is no mediastinal shift.*

Other points—Within normal limit.

Conclusion :

Bullous emphysema.

Bilateral hypertranslucency in chest X-ray film (D/D):

1. Emphysema.
2. Bilateral pneumothorax.
3. Multiple bullae.
4. Bronchial asthma.
5. Overexposed (overpenetrated) film.
6. Fallot's tetralogy with pulmonary atresia, Ebstein's anomaly.

* *Bullae* are thin-walled (<1 mm in thickness) air spaces more than one centemeter in diameter, produced by rupture of alveolar walls. Bullae are usually situated subpleurally, and may be single or multiple, large or small. Rupture of bullae gives rise to pneumothorax.

** *Petit heart (or tear-drop heart)* i.e., long and tubular heart is found in PA view of chest X-ray in emphysema, Addison's disease, panhypopituitarism and constrictive pericarditis.

BRONCHIECTASIS

(Fig. 3.7)

Description :

This is a PA view of the chest which shows multiple ring shadows at both lower zones (left > right). Areas of haziness or fibrosis is seen at places (bases). There is a big bulla seen in the right apex. Right costophrenic angle is blunt. *There is no mediastinal shift.*

Other points—Within normal limit.

* Dilated bronchi give rise to 'tram line shadows' (linear streaks) or 'ring shadows', while dilated air-filled bronchi may produce 'gloved finger shadows'.

Conclusion :

Bronchiectasis (bilateral and basal).

* Commonest site of bronchiectasis is left lower lobe and lingula.

How a bronchiectasis patient presents ?

The common presentation is cough with profuse (and often foetid) expectoration of sputum, usually more marked in the morning after waking from sleep. The patient may have haemoptysis and breathlessness. Features due to secondary infection may be associated with.

What is bronchiectasis sicca (dry bronchiectasis) ?

It is also known as dry bronchiectasis. Here, apices of lungs are affected in contrast to bases and the patient will have minimum or no sputum production (i.e., dry cough as a result of easy drainage). Haemoptysis may be the only symptom.

What is pseudobronchiectasis ?

It is a bronchographic abnormality resulting from atelectasis and tracheobronchitis with ulceration in bronchial mucosa which mimic cylindrical bronchiectasis. Re-expansion of the collapsed lung and healing of bronchial mucosa make the condition reversible and thus it is known as pseudobronchiectasis.

Describe middle lobe bronchiectasis :

When the middle lobe bronchus is obstructed by tuberculous lumph nodes (sequel to primary pulmonary tuberculosis), a post-obstructive bronchiectasis is formed, which is known as middle lobe bronchiectasis or 'middle lobe syndrome'.

What is Kartagener's syndrome ?

This is also known as immotile cilia syndrome. The syndrome is the triad of bronchiectasis, dextrocardia and recurrent sinusitis, associated with infertility. Kartagener's syndrome is a variety of 'primary ciliary dyskinesia' where there is immotility of cilia (with abnormal mucus production) present in respiratory tract epithelium and sperm.

Pathological types of bronchectasis :

1. Cylindrical (fusiform) bronchiectasis—uniform dilatation of bronchi.
2. Varicose bronchiectasis—beaded pattern of dilated bronchi.
3. Saccular bronchiectasis—ballooned or cystic bronchi.

The classification is based on bronchographic appearance.

Outline of management of bronchiectasis :

1. Antibiotics for infection control.
2. Postural drainage—a position is adopted where the lobe to be drained remains uppermost. This is to be continued for 20 minutes, once or twice daily, in empty stomach. Gentle purcussion over the front and back of the chest with cupped hands helps dislodgement of sputum (chest physiotherapy).
3. Bronchodilators, mucolytics as and when necessary.
4. Bronchoscopic aspiration of inspissated sputum is rarely needed.

5. Surgery : lobectomy In localised and unilateral lesion in young adults (< 40 years) who are unresponsive to medical treatment; also in recurrent haemoptysis/pneumonias. Heart-lung transplantation is performed in bilateral extensive disease.
6. General : nutritious diet, correction of anaemia.

How to confirm your diagnosis :

Diagnosis can only be made with certainty by bronchography or high resolution CT scan of thorax (definitive and preferred investigation).

Causes of 'honeycombing' or 'honeycomb lung' (D/D):

X-ray picture shows multiple air containing cyst-like shadows or ring shadows measuring 0.5-2 cm in diameter (mimicking bunch of grapes) in :

1. Bronchiectasis.
2. Fibrosing alveolitis, scleroderma; SLE, rheumatoid arthritis.
3. Cystic fibrosis, tuberous sclerosis, histiocytosis X, pneumoconiosis.
4. Extrinsic allergic alveolitis.
5. After use of drugs like busulphan, nitrofurantoin, bleomycin or melphalan.

Why the right costophrenic angle is blunt ?

It may be due to mild pleural reaction or developed as a result of small collection of fluid.

Three layer sputum test, in bronchiectasis :

When the copious and foetid sputum from a bronchiectatic patient is collected in a conical glass, it seperates into three layers arbitrarily as.

Upper layer — contain's froth,

Middle layer — contain's liquid or thick sputum,

Lower layer — contain's heavier particles, e.g., epithelial debris, masses of bacteria, clumps of pus cells, foul-smelling Dettrich's plugs, blood clots.

Bedside diagnosis of bronchiectasis :

Read 'Bedside Clinics in Medicine, Part I'.

LUNG ABSCESS

(Fig. 3.8)

Description :

This is a PA view of the chest showing a big cavity occupying the left-sided mid and lower zones with thick, rough and shaggy inner wall. The cavity is circular; the lower homogeneous opacity with a horizontal level indicates fluid inside the cavity, and the hypertranslucency (devoid of lung markings) above the fluid level indicates air within the cavity. Rest of the lung fields are clear. Trachea and cardiac apex are in normal position.

Other points—Within normal limit.

* Air-fluid level is the hallmark of lung abscess.

Conclusion :

Left-sided solitary lung abscess.

Differential diagnosis :

Differentiate between the causes of horizontal fluid level seen in the chest X-ray plate. They are,

1. Lung abscess (inflammation associated with necrosis of lung tissue).
2. Hydropneumothorax, haemopneumothorax or pyopneumothorax—loculated variety.
3. Cardiospasm or achalasia cardia.
4. Diaphragmatic hernia (obstructed).

5. Infected lung cyst.
6. Hydropneumopericardium (rare).

Predisposing factors and bedside diagnosis of lung abscess :

(A) Predisposing factors :

1. Alcoholism.
2. Old age.
3. Diabetes mellitus.
4. H/O convulsions.
5. H/O general anaesthesia.
6. Malnutrition or immunocompromised patients (e.g., corticosteroid therapy, AIDS).
7. Oral or pharyngeal sepsis, drowning, following bronchial obstruction, tracheo-oesophageal fistula, bulbar palsy, unconscious patients, achalasia cardia — predisposes aspiration of infected material.
8. Cystic fibrosis (thick, viscid sputum production).
9. Inadequately treated pneumonia, septic emboli, pulmonary infarction, infection of lung cyst.
10. Pulmonary tuberculosis (an important cause of lung abscess).

(B) Specific infection by :

Streptococcus pneumoniae, Staphylococcus aureus, Klebsiella pneumoniae, different fungi etc.

(C) Obstruction by :

Bronchogenic carcinoma, foreign body, bronchial adenoma or enlarged lymph node.

(D) Spread ('local' from liver abscess or subphrenic abscess; 'haematogenous' from septicaemia, pelvic abscess).

(E) Bedside diagnosis (clinical features) :

a) Symptoms :
   - (i) Anorexia, malaise, weakness, loss of weight and symptom of toxaemia; the onset may be insidious, acute or chronic.
   - (ii) Fever—Intermittent, may be hectic.
   - (iii) Cough with profuse, foetid, purulent and often blood-tinged sputum.
   - (iv) Pleuritic chest pain or deep-seated chest discomfort.
   - (v) Haemoptysis.

b) Signs :
   - (i) Fever.
   - (ii) Halitosis.
   - (iii) Clubbing.
   - (iv) Examination of the chest may be normal or may include signs of consolidation, i.e., no shifting of mediastinum, woody dullness on percussion, bronchial breath sound (cavernous or amphoric), pleural rub, coarse crepitations (often post-tussive crepitations) with increased vocal resonance. Sometimes, feature of empyema thoracis may be found.

Frank signs of cavity are rarely found.

*Possible cuases of *multiple' lung abscess :*

1. Aspiration of infected material.
2. Infection by (Staphylococcus aureus, Klebsiella and fungus).
3. Amoebic liver abscess ruptured into lung.

Complications :

1. Massive haemoptysis.
2. Acute dry pleurisy.
3. Empyema thoracis.
4. Pneumothorax or pyopneumothorax.
5. Metastatic cerebral abscess.
6. Pyaemia.

7. Aspergillosis (fungus ball).
8. Amyloidosis (rare)—in chronic cases.

Differential diagnosis of cavity containing air or fluid :

1. Cavity with shaggy walls—Lung abscess, bronchogenic carcinoma, tuberculous cavity (empty).
2. Cavity with thin walls—Tuberculous cavity (caseous), lung cyst, bullae, mycotic cavitation.
3. Very small cavity with much thicker wall—Bronchogenic carcinoma.

Differential diagnosis of intracavitary mass lesion in chest X-ray :

1. Aspergilloma.
2. Cavitating carcinoma of lung.
3. Blood clot.

What is 'pseudocavity'?

Cavity—Liquefaction necrosis within the lung (may remain empty or filled with secretion) surrounded by a wall whose thickness is > 1mm and usually communicating with a patent bronchus.

Pseudocavity—Radiological appearance mimicking pulmonary cavity as a result of summation shadows of ribs, vessels, fibrotic bands, calcification or artefacts.

HOMOGENEOUS OPACITY OF ONE HEMITHORAX

(Fig. 3.9)

Description :

This is a PA view of the chest which shows homogeneous opacity of the whole of the left chest. Left costophrenic angle is obliterated and the mediastinum has shifted to the right side. The right lung apparently shows no abnormality.

Other points—Within normal limit.

Conclusion :

The causes of unilateral dense homogeneous opacity are,

1. Massive pleural effusion.
2. Empyema thoracis.
3. Collapse of the lung.
4. Consolidation (massive).
5. Thickened pleura.
6. Pleural mesothelioma.
7. Agenesis of lung.
8. Pneumonectomy.
9. Destroyed lung (from chronic inflammation and fibrosis).
10. Technical (rotation/scoliosis).

As there is mediastinal shifting towards the opposite side, No 1 and 2 are the most probable possibilities here.

* Causes of bilateral opaque hemithorax are ARDS, bilateral pleural effusion, extensive bilateral consolidation and hyaline membrane disease.

Shifting of trachea and cardiac shadow in others :

1. Collapse of the lung—Same side.
2. Consolidation—No shifting.
3. Thickened pleura—Same side (in gross thickening).
4. Pleural mesothelioma—Usually no shifting.
5. Agenesis of lung, pneumonectomy and destroyed lung—Same side.

COLLAPSE OF THE LUNG

(Fig. 3.10)

Description :

This is a PA view of the chest showing an opacity which is rather homogeneous and involving almost whole of the right lung. The trachea and cardiac apex have shifted towards the right side. Neither elevation of the right dome of diaphragm nor compensatory emphysema of the left lung is noted. Crowding of the ribs are seen on the right side.

Other points—Within normal limit.

Conclusion :

Collapse (absorption) of the right lung.

* To diagnose collapse of the lung, both PA and lateral films are necessary.

What is collapse of the lung ?

This is the reduction in lung volume due to absorption of alveolar air (absorption collapse) or resulting from expulsion of air from the alveoli (compression collapse).

Types of collapse :

1. Absorption or active collapse e.g., mucus plug, foreign body, bronchogenic carcinoma.
2. Compression or passive collapse e.g., pleural effusion, pneumothorax, hydropneumothorax.

[3. Infarction collapse e.g., pulmonary thromboembolism].

Clinical features of collapse :

1. Absorption or active collapse—Read 'Bedside Clinics in Medicine, Part I'.
2. Compression or passive collapse—Features of pleural effusion, pneumothorax or hydropneumothorax are clinically manifested.

Differential diagnosis :

Same as 'Homogeneous opacity of one hemithorax' described earlier.

FIBROSIS OF THE LUNG

(Fig. 3.11)

Description :

This is a PA view of the chest showing haziness in the upper zone of the left lung with shifting of trachea and cardiac apex towards the left side. Crowding of the ribs at the left upper chest are seen. Both the costophrenic angles are clear. Diaphragmatic contours are normal.

Other points—Within normal limit.

* In chest X-ray of fibrosis of the lung one should also search for fibrous bands, pulled-up hilum and tenting of diaphragm which are absent here.

Conclusion :

Fibrosis involving upper zone of the left lung.

Types and clinical features of fibrosis :

Read 'Bedside Clinics in Medicine, Part I'.

Differential diagnosis of such localised haziness :

1. Fibrosis of the lung.
2. Pulmonary tuberculosis (primary).

3. Resolving bacterial pneumonia.
4. Thickened pleura.
5. Localised bronchiectasis (usually basal).
6. Alveolar cell carcinoma.

Causes of fibrosis of the lung of cardiac origin :

1. Mitral stenosis, and
2. Pulmonary infarction (multiple).

Basic clinical differentiation between fibrosis and collapse :

(A) Fibrosis :
- a) Onset is chronic.
- b) Chest wall is retracted on the affected side.
- c) Crowding of the ribs and drooping of the shoulder on the affected side.
- d) Breath sound is diminished but never absent. Crepitations may be heard.

(B) Collapse :
- a) Onset is acute.
- b) Chest wall is flattened on the affected side.
- c) Crowding of the ribs and drooping of the shoulder may be evident, if the collapse is prolonged.
- d) Breath sound is absent if a major bronchus is obstructed; usually no added sound.

* Fibrosis : Opacity is non-homogeneous; collapse ; Opacity is homogeneous.

** Features of collapse are more or less same as fibrosis but is of lesser in degree.

TUBERCULOUS INFILTRATIONS

(Fig. 3.12)

Description :

This is a PA view of the chest which reveals multiple wooly opacities involving both the lung fields, giving the X-ray film a 'moth-eaten appearance'. The costophrenic angles are clear. No mediastinal shift is seen.

Other points—Within normal limit.

Conclusion :

Pulmonary tuberculosis (possibly post-primary type).

Differential diagnosis of such an X-ray picture :

1. Pulmonary tuberculosis.
2. Resolving bacterial pneumonia.
3. Alveolar cell carcinoma.
4. Pulmonary oedema.
5. Fungal disease of the lung.

Different radiological findings in pulmonary tuberculosis :

1. Wooly opacites or soft fluffy shadows (exudative phase).
2. Uni- or bilateral apical infiltrations.
3. Dense nodular shadow (proliferative phase).
4. Miliary mottling.
5. Cavities (bilateral or multiple).
6. Fibrocaseous lesion.
7. Reticulonodular (if interstitium is involved).
8. Calcification (healed disease).
9. Tuberculoma (round or oval solitary shadow).
10. Bronchiectasis, specially affecting the upper zones.

* Involvement of pleura and pericardium is excluded.

Features of tuberculous 'activity' in a patient:

1. Presence of AFB in sputum (i.e., sputum + ve cases), certainly indicates activity.
2. Patients having tuberculous toxaemia, i.e., evening rise of temperature, night sweats, anorexia, malaise, cough or loss of body weight, are in favour of activity.
3. A high ESR may be an indicator of activity.
4. Radiological features of activity are :
   a) Presence of a cavity.
   b) Soft shadows, even if very small.
   c) In case of extensive shadow, activity is likely.
   d) Progression of shadows in spite of treatment (in serial chest X-rays).

* Surest sign of activity—Sputum positivity for AFB in direct smear examination.

N.B. : A strongly +ve Mantoux test (e.g., induration > 30 mm) may be quite compatible with activity.

Types of pulmonary tuberculosis :

(A) Parenchymatous :
   a) Primary
   b) Progressive primary
   c) Post-primary
   d) Miliary
   e) 'Cryptic' miliary

(B) Respiratory tract or airway infection :
   a) Laryngitis
   b) Bronchitis

(C) Pleural :
   a) Pleurisy
   b) Pleural effusion
   c) Pneumothorax
   d) Hydropneumothorax

What is 'primary complex' ?

The subpleural tuberculous focus in the lung, hilar lymphadenopathy and interconnecting lymphatics constitute the primary complex (Ghon's complex).

Enumerate different tuberculous focus in various organs :

1. Pulmonary :
   a) Subpleural — Ghon's focus.
   b) Deep apical — Ashman's focus.
   c) Subpleural focus in the upper lobe — Simon's focus.
2. Cerebral — Rich's focus.
3. Hepatic — Simond's focus.
4. Blood vessels — Wigard's focus (present within tunica intima).
5. Besides these, there are primary lymph node, splenic, renal and intestinal focus.

Common causes of apical shadows in chest X-ray :

1. Tuberculosis.
2. Aspergillosis.
3. Pancoast's tumour.
4. Bullae.
5. Pneumothorax
6. Artefacts (hair balls or stemomastoid shadow).
7. Pleural cap (irregular crescentic, commonly left-sided, may represent old pleural thickening, incidence 7%).

Haemoptysis in post-primary tuberculosis :

Mechanisms responsible :

1. Tuberculous pneumonitis — bronchiolar ulceration and necrosis of adjacent vessels.
2. Rupture of Rasmussen's aneurysm (aneurysmally dilated pulmonary artery in a cavity).
3. Invasion of blood vessels by active tuberculous granulation tissue.
4. Oozing from the wall of an active cavitary lesion.

* Haemoptysis may result from aspergillosis in tuberculous cavity; lately, post-tuberculous bronchiectasis or scar carcinoma may lead to haemoptysis.

How do you like to investigate a suspected case of pulmonary tuberculosis ?

(A) Routine blood examination—Hb, TC, DC, ESR (anaemia, mild elevation of lymphocytes and high ESR may be found).

(B) X-ray chest-PA view; apical lordotic view to visualise the apex in a better way.

(C) Mantoux test—Negative reaction usually rules out tuberculosis but a positive reaction (induration > 10 mm) is observed in the presence of tuberculosis whether it is healed or active. It is often said that a +++ reaction (induration > 30 mm) or a positive reaction below 3 years of age (non-BCG vaccinated) indicates towards active tuberculosis.

(D) Sputum examination for AFB (acid fast bacilli) for consecutive 3 days, or detection of AFB in gastric aspirate in children, or search for AFB from laryngeal swab, broncho-alveolar lavage in selected cases—Confirms the diagnosis.

(E) Biopsy of the cervical lymph nodes in selected cases.

(F) Culture of sputum for M. tuberculosis in Lowenstein-Jensen media; result usually comes within 8-12 weeks.

(G) Newer diagnostic techniques (costly and not routinely practised) ;

a) ELISA (IgG or IgM) — not much useful as the bacilli contains complex antigenic structure; having high specificity (97%) with low sensitivity (65%).

b) Adenosine deaminase activity (ADA).

c) Detection of tuberculostearic acid.

d) Polymerase chain reaction (PCR)—to detect mycobacterial DNA.

e) Radiolabelled DNA and RNA probes, specific for different mycobacterial species, identify organisms in culture.

f) 'Bactec' test—Radioisometric blood culture; result within 7 days.

MILIARY MOTTLINGS

(Fig. 3.13)

Description :

This is a PA view of the chest which shows small discrete nodules or miliary opacities (spotted or mottled appearance) of the size of 1-2 mm diameter, involving all the zones of both the lungs. There is no mediastinal shifting. Both the costophrenic angles are hazy (i.e., may have pleural reactions).

Other points—Within normal limit.

Conclusion :

The probable differential diagnosis of 'miliary mottlings' in chest X-ray are,

1. Acute miliary tuberculosis (generalised, uniform size, smaller shadows, usually hilar lymph nodes are not affected and common in children; upper zones are always involved).
2. Tropical eosinophilia (usually involves the mid and lower zones, non-uniform, larger shadows with hilar lymph nodes involvement, persons of any age are affected).
3. Miliary carcinomatosis (rare, slightly larger shadows of secondary deposits: may be the primary source in breast, bronchus, kidney or thyroid).
4. Pneumoconiosis (size 3-5 mm; coal-miners commonly).

5. Acute lymphangitis carcinomatosa [a form of metastatic carcinoma where the pulmonary lymphatics are invaded and are often blocked by malignant cells; 2-3 mm nodules with thickening of pulmonary septa (Kerley's A and B lines); may be the primary source in bronchus, stomach, breast, colon or prostate].
6. Extrinsic allergic alveolitis (often more pronounced in upper zones).
7. Pulmonary haemosiderosis (smaller but dense shadows).
8. Sarcoidosis (larger shadows, spare apices but hilar lymph nodes may be enlarged).
9. Fungal diseases like histoplasmosis, coccidioidomycosis.
10. Miscellaneous—Collagen vascular diseases, chickenpox pneumonia, mycoplasma pneumonia, mitral stenosis (having pulmonary haemosiderosis from recurrent haemoptysis), aspiration of blood or vomitus, multiple pulmonary infarction, Loeffler's syndrome, alveolar microlithiasis, after lipoidal bronchography, artefacts like multiple skin warts or neurofibromatosis.

* Early lesions of 'miliary mottlings' are often better visualised in over-penetrated PA view of the chest with viewing the X-ray plate by putting a bright light behind. The nodular shadows of miliary mottlings are detected earlier in CT scan than radiograph.

Clinical features of acute miliary tuberculosis :

Read 'Bedside Clinics iri Medicine, Part I'.

* The 1 -2 mm miliary opacities mimic millet seeds and it is why these type of shadows are known as 'miliary mottlings'.

****Calcification' seen in the chest X-ray :***

(A) Parenchymal (lung): Tuberculosis, histoplasmosis, hamartomas (popcorn calcification), silicosis (egg-shell calcification), alveolar microlithiasis, haemosiderosis from recurrent haemoptysis, lung abscess.

(B) Pleural : Tuberculosis, asbestosis, empyema thoracis.

(C) Cardiac : Aortic arch (ring shaped), pericardial (constrictive pericarditis), calcification of heart valves (e.g., mitral and aortic), calcification of coronary arteries, left atrial myxoma with thrombi.

(D) Mediastinal : Lymphadenopathy from tuberculosis or sarcoidosis, teratodermoid.

(E) Chest wall : Costal cartilage calcification, nipple in females, phleboliths, Guinea worm in soft tissue, artefact.

MEDIASTINAL WIDENING

(Fig. 3.14)

Description :

This is a PA view of the chest which shows multiple circumscribed coin-like shadows involving both the lung fields with gross mediastinal widening. Both the costophrenic angles are clear and there is absence of mediastinal shifting. Diaphragms are normal in position with normal contour.

Other points—Within normal limit.

Conclusion :

Apparently it is a case of bronchogenic carcinoma.

Differential diagnosis of 'coin lesion' (or solitary nodule) in the lung :

1. Bronchogenic carcinoma.
2. Bronchial adenoma.
3. Metastatic nodules (secondary infiltrations).
4. Hamartomas.
5. Granuloma (tuberculosis, fungal infection e.g., histoplasmosis, eosinophilic granuloma, Wegener's granulomatosis).
6. Cyst (congenital, hydatid, dermoid, polycystic disease), lipoma, fibroma.
7. Miscellaneous—Arteriovenous fistula, interlobar effusion, mesothelioma of pleura, pulmonary

Infarction, lung abscess, localised pneumonia, rheumatoid nodule, intrapulmonary lymph nodes, bronchopulmonary sequestration.

* **Coin lesion**—Coin-shaped round lesion (usually less than 3 cm) with well-circumscribed margin which is completely surrounded by normal aerated lung, and without associated lung, pleural or mediastinal pathology.

Solitary pulmonary nodule—Spherical, 1-6 cm in diameter, intrapulmonary, roentgenographic density.

Mass lesion — nodules > 6 cm in size, and are often malignant.

Differential diagnosis of mediastinal widening :

1. Lymph node enlargement as a result of bronchogenic carcinoma (primary or secondary), lymphoma, tuberculosis, sarcoidosis, fungal infection of the lung.
2. Mediastinal mass—
   a) Anterior and middle mediastinum—Teratodermoid, lymphoma, metastatic carcinoma, aortic aneurysm, bronchogenic cyst, pericardial cyst.
   b) Superior mediastinum—Thymoma, retrosternal thyroid, metastatic carcinoma, aortic aneurysm, Zenker's diverticulum, tumours of parathyroid.
   c) Posterior mediastinum—Neurogenic tumour (neurofibroma), lymphoma, aortic aneurysm, achalasia cardia, hiatus hernia, paravertebral abscess, pharyngo-oesophageal pouch.

Causes of hilar enlargement :

(A) Bilateral —

1. Sarcoidosis.
2. Lymphoma, bronchogenic carcinoma.
3. Tuberculosis, histoplasmosis.
4. Increased pulmonary flow.
   due to septal defects in heart.
5. Pulmonary hypertension.
6. Silicosis.
7. Lymphangitis carcinomatosa.

(B) Unilateral —

1. Bronchogenic carcinoma.
2. Sarcoidosis.
3. Lymphoma.
4. Tuberculosis.
5. Pulmonary artery aneurysm.

Differential diagnosis of elevation of diaphragm :

(A) Unilateral—Phrenic nerve paralysis, amoebic liver abscess, basal pulmonary infarction, subphrenic abscess, basal collapse or fibrosis, subpulmonic pleural effusion, eventration of the diaphragm, splenic cyst, scoliosis, massive hepatomegaly or splenomegaly.

(B) Bilateral—Poor inspiration, obesity, ascites, pregnancy^ huge mass in the abdomen, hepatosplenomegaly, fibrosing alveolitis, bilateral phrenic nerve paralysis, bilateral basal collapse, pneumoperitoneum.

* **Diaphragmatic hump**—this is a localised elevation on the medial aspect of right dome of diaphragm. The hump is smooth and convex upwards, and is usually a normal finding.

** **Tenting of diaphragm**—the diaphragm may be pulled upwards loosing its smooth upward convex contour by basal pleurisy. Here, the elevation of diaphragm is abrupt and 'tent-like'.

Types of bronchogenic carcinona :

(A) Non-small cell carcinoma (80%) :
   a) Squamous or epidermoid carcinoma.
   b) Adenocarcinoma (including bronchioloalveolar).
   c) Large cell carcinoma (also known as anaplastic carcinoma).'

(B) Small cell carcinoma or oat-cell carcinoma (20%).

* Recent incidence rate of bronchogenic carcinoma is as follows :

Squamous cell carcinoma 35%
Small cell carcinoma 20%
Large cell carcinoma 15%.
Adenocarcinoma 30%

Clinical findings expected in this patient:

Features of superior mediastinal syndrome may be present.

PULMONARY OEDEMA

(Fig. 3.15)

Description :

This is a PA view of the chest which shows "bat's-wing" or "butterfly" appearance of confluent shadows which extends from the hilum to the mid and upper zones. These bilateral pulmonary clouding escapes the peripheral and basal zones. Cardiac silhouette is enlarged. Costophrenic angles are clear and there is no mediastinal shifting.

Other points—Within normal limit.

Conclusion :

Pulmonary oedema.

Differential diagnosis (of widespread alveolar opacities):

1. Pneumonia.
2. Acute lung injury or ARDS.
3. Alveolar cell carcinoma.
4. Uraemic pneumonitis.
5. Intra-alveolar haemorrhage.
6. Fat emboli.
7. Metastasis by haematogenous route.

Different causes of pulmonary oedema :

(A) Cardiogenic—Left-sided heart failure (i.e., left ventricular or left atrial failure), acute myocardial infarction, cardiac dysrrhythmias, pulmonary thromboembolism.

(B) Non-cardiogenic—Drowning, inhalation of toxins, gram-ve septicaemia, fluid overload, insecticide poisoning, narcotic overdose, haemorrhagic pancreatitis, high altitude.

X-ray shows pulmonary oedema without any cardiac enlargement :

1. Mitral stenosis (producing left atrial failure),
2. Constrictive pericarditis, and
3. Causes of non-cardiogenic pulmonary oedema.

Pressure changes in left atrium in evolution in pulmonary oedema :

1) Normal left atrial pressure : 6-10 mm of Hg.
2) Prominence of upper lobar pulmonary veins in X-ray : 12 mm of Hg.
3) Interstitial oedema : > 15 mm of Hg.
4) Kerley's B lines in chest X-ray : > 20 mm of Hg.
5) Pulmonary oedema : > 25 mm of Hg.

Evolution of radiographic features in pulmonary oedema :

(A) Interestitial oedema—As the left atrial pressure rises > 20 mm of Hg (i.e., pulmonary venous pressure increases), normally invisible interstitial septa becomes visible as a result of interstitial oedema (Kerley's B and A lines).

(B) Alveolar oedema—When the left atrial pressure is > 25 mm of Hg, fluid collects within the alveoli giving rise to parahilar "bat's-wing" or "butterfly" shadow in chest X-ray.

THORACIC NEOPLASM

(Fig. 3.16)

Description :

This is a skiagram of the chest, PA view which shows a dense homogeneous opacity (with sharp margin) occupying the left upper and mid-zone. There is absence of 'air bronchogram'. Mediastinal widening, mediastinal shifting, obliteration of the costophrenic angles (though not clearly seen), elevation of diaphragm are absent. There is absence of any rib destruction. Radiographer's signal (L for left) is wrongly given.

Other points—Within normal limit.

Conclusion :

Apparently it is a case of pulmonary neoplasm.

Differential diagnosis of such a lesion in X-ray :

1. Bronchogenic carcinoma.
2. Pneumonia.
3. Lung cyst.
4. Aortic aneurysm.
5. Granuloma.

Common symptoms in bronchogenic carcinoma :

(A) Non-specific systemic symptoms—Anorexia, weakness, loss of weight, nausea and vomiting, pyrexia.

(B) Pulmonary symptoms—Cough, haemoptysis, chest pain, breathlessness.

(C) Metastatic symptoms—Jaundice, neuralgic pain over the extremities, haematuria, convulsions, pathological fracture, SVC syndrome (dysphagia, dyspnoea, hoarseness of voice), lymphoedema with severe breathlessness, spinal cord compression with paraplegia.

(D) *Paraneoplastic syndrome* (not related to metastasis) :

a) Systemic—Anorexia, loss of weight, cachexia, lassitude,

b) Endocrine—Cushing's syndrome, hyperparathyroidism, carcinoid syndrome, syndrome of inappropriate ADH secretion (SIADH), hypoglycaemia.

c) Neuromuscular—Peripheral neuropathy, myasthenic syndrome (Lambert-Eaton syndrome), myopathy, polymyositis, cortical degeneration, subacute cerebellar degeneration, encephalomyelopathy.

d) Haematological—Normoblastic anaemia, granulocytosis, leucoerythroblastosis, polycythemia, haemolytic anaemia, disseminated intravascular coagulation (DIC).

e) Cutaneous—Dermatomyositis, acanthosis nigricans, pruritus, herpes zoster.

f) Bones and connective tissue—Clubbing, hypertrophic pulmonary osteoarthropathy (HPOA) and pachydermoperlostitis.

g) Vascular—Migratory thrombophlebitis, gangrene.

h) Renal—Nephrotic syndrome, glomerulonephritis.

i) Miscellaneous—Gynaecomastia.

* *Paraneoplastic syndrome* is seen when a hormone with biologic activity is secreted by the tumour.

Rib erosion and rib notching :

(A) Rib erosion—There is destruction of ribs; ribs may look moth-eaten. It is found in bronchogenic carcinoma, multiple myeloma, histiocytosis X disease.

(B) Rib notching—Notching of the ribs may be present in the upper border, lower border or randomly. It is found in coarctation of aorta (lower border of 3rd to 8th rib), hyperparathyroidism (random), chronic SVC and IVC obstruction, arteriovenous fistula, neurofibromatosis (upper border), Fallot's tetralogy, pulmonary stenosis, after Blalock-Taussig shunt operation done in Fallot's tetralogy.

* Rib notching in coarctation of aorta in chest X-ray is known as Dock's sign.

Different radiological features of bronchogenic carcinoma in chest X-ray :

1. Solitary, dense, well-circum£ bribed pulmonary opacity; sometimes a cavity within.
2. Dense, irregular hilar opacity with peripheral extension.
3. Localised emphysema (an early feature); atelectasis involving a segment, lobe, or the whole lung.
4. Mediastinal widening, rib erosion, elevated hemidiaphragm (phrenic nerve palsy), pleural effusion may be seen.
5. Linear streaks radiating from hilum, or miliary mottlings developing as a result of lymphangitis carcinomatosa.

* In a suspected X-ray of thoracic neoplasm, always search for rib erosion, pleural effusion and diaphragmatic palsy.

****Pseudotumour' in chest X-ray :***

1. Paravertebral cold abscess.
2. Scoliosis.
3. Aortic aneurysm.
4. Achalasia cardia.
5. Extramedullary haematopoiesis in chronic haemolytic anaemia (e.g., thalassaemia).

[B] X-RAY CHEST—HEART

MITRAL STENOSIS

(Fig. 3.17)

Description :

This is a PA view of the chest which shows **'mitralisation' of heart,** or straightening of the left border of heart and is due to (from above downwards),

a) Small aortic knuckle (due to low cardiac output),
b) Conspicuous convexity due to dilated pulmonary artery (due to pulmonary hypertension),
c) Convexity produced due to prominent left atrial appendages, and
d) Normal left border of left ventricle.

Double contour of the right border of heart (the upper and outer border is due to LA, and the lower and inner border is due to RA enlargement) is present here.

The cardiac size shows enlargement in transverse diameter (RVH). Dilated pulmonary arteries at hilum with peripheral pruning is seen (evidence of pulmonary hypertension). Upper lobar pulmonary veins are dilated.

Kerley's B line, fan-shaped opacity at hilum (pulmonary oedema), mitral valve calcification, features of haemosiderosis are not evident here.

Other points—Within normal limit.

* The apex of the heart in the X-ray plate seems to be outwards as well as downwards (RVH + LVH). As MS does not produce LVH, think of other causes associated with MS (see the question in next page) i.e., this X-ray plate probably does not belong to a case of isolated MS.

** The D/D of this X-ray picture is ASD or left atrial myxoma.

Conclusion :

Mitral stenosis with features of pulmonary hypertension.

What are "Kerley's—A, B and C" lines ?

(A) Kerley's A line : Ragged, unbranched lines which run centripetally towards the hilum; seen near the apex.

(B) Kerley's B line : Fine, dense, non-branching horizontal lines at the base of the lung (near costophrenic angles).

(C) Kerley's C line : Fine, interlacing lines and are seen in the central and parahilar region.

A, B and C lines are also known as septal lines. These white lines represent 'dilated lymphatics and distended interlobular septa'. B line is most commonly seen. They occur most often in pulmonary oedema as a result of chronic pulmonary venous hypertension. Kerley's B line has a relation with left atrial pressure (B-lines are invariably present if LA pressure goes above 20 mm of Hg). These lines are actually found in left-sided heart failure.

* Kerley's **A** line stands for apex, **B** line for base and **C** line for central region.

** Kerley's B lines are found in :

a) Pulmonary venous hypertension e.g., LVF, left atrial failure from MS.

b) Dilated lymphatics due to lymphatic obstruction e.g., lymphangitis carcinomatosa, pneumoconiosis.

Radiological features of raised left atrial pressure :

1. Prominence of hilar pulmonary vascular shadows,
2. Dilated upper lobar pulmonary veins,
3. Kerley's B lines, and
4. Interstitial pattern of pulmonary shadow—either diffuse haziness or "bat's-wing" appearance of acute pulmonary oedema.

Radiological evidences of pulmonary arterial hypertension :

Causes :

1. Left to right shunt (ASD, VSD, PDA).
2. Long standing left-sided heart disease (MS).
3. COPD or other chronic pulmonary diseases (e.g., interstitial lung disease).

Radiological features :

1. Bulging pulmonary arteries at hilum (parahilar prominence).
2. Peripheral 'pruning' (peripherally pulmonary arteries taper sharply).
3. Disappearance of Kerley's B line.

Radiological evidences of pulmonary venous hypertension :

Causes :

1. Left-sided heart failure (LAF/LVF), i.e., mitral or aortic valve disease, IHD, cardiomyopathy, left atrial myxoma.
2. Chronic cor pulmonale.
3. Pulmonary thromboembolism.
4. Pulmonary venous obstruction (veno-occlusive disease).

Radiological features :

Prominent vascular markings as a result of venous congestion in lung (upper lobe vessels become prominent initially followed by parahilar congestion).

X-ray shows 'mitralisation', but the apex is down and out—possibilities :

Always try to determine to position of the cardiac apex by counting intercostal spaces (whether outwards, or downwards as well as outwards) in all chest X-ray (PA view).

Isolated MS with pulmonary hypertension and RVH will have outward apex. As MS (evidenced by mitralisation) does not produce LVH, other causes of LVH should be considered to be associated with MS if the apex goes downwards and outwards. So the likely possibilities are :

MS associated with,

1. MI, AI, AS.
2. Systemic hypertension.
3. Ischaemic heart disease
4. Severe anaemia.
5. Cardiomyopathy.
6. Thyrotoxicosis.

A patient of MS becomes symptomatic suddenly or within few days—possibilities :

Possibilities :

1. Left atrial failure and pulmonary oedema.
2. Development of tachyarrhythmias e.g., atrial fibrillation.
3. Sudden embolic manifestations (e.g., pulmonary embolism).
4. Physical (unaccustomed exercise) and emotional stress.
5. Severe anaemia, intercurrent illness (e.g., infection), development of thyrotoxicosis.
6. Pregnancy.
7. Attacks of active rheumatic carditis.
8. Excess intake of salt, poor compliance with therapy.

* In MS, a chest X-ray done in right anterior oblique (RAO) view with barium-filled oesophagus may reveal the backward curving of oesophagus (sickling of oesophagus) as a result of left atrial enlargement.

** Double contour of the right border of heart may also be found in isolated mitral regurgitation.

PERICARDIAL EFFUSION

(Fig. 3.18)

Description :

This is a PA view of the chest which shows grossly enlarged (globular) cardiac silhouette with a 'water-bottle configuration' or 'pear-shaped heart'. The cardiothoracic ratio is increased. The cardiac land-marks (indentations) on the borders of the heart (ie, ups and downs, or convexity-concavity) are obliterated (stencil-cut outline). Right cardiophrenic angle is more acute (Rotch's sign). The lung fields are oligaemic. Left costophrenic angle is apparently clear but the right costophrenic angle is a bit blunt.

Other points—Within normal limit.

* In pericardial effusion, fluid collects in between visceral and parietal pericardium.

Conclusion :

Pericardial effusion (with right-sided pleural effusion).

Causes of pulmonary oligaemia and plethora :

(A) Pulmonary oligaemia :

a) Radiological features—Bronchovascular markings are less conspicuous and lung vessels are of diminished calibre.

b) Causes—Fallot's tetralogy, truncus arteriosus, severe pulmonary stenosis, pulmonary atresia, pericardial effusion, right-to-left shunt.

(B) Pulmonary plethora :

a) Radiological features—Dilated vessels are seen throughout the lung fields (from hilum to periphery) due to increased pulmonary blood flow. [With the onset of pulmonary hypertension, plethora disappears and the peripheral 1 /3rd of lung will have less arterial markings ('pruning')].

b) Causes—MS, MI, AS, AI, left ventricular failure, left-to-right shunt (ASD, VSD, PDA).

* ASD is an important cause of pulmonary plethora in clinical practice.

How much pericardial fluid is required to show enlarged cardiac silhouette in chest X-ray ?

It is approximately 250 ml.

Minimum amount of fluid required to diagnose pericardial effusion by echocardiography :

Echocardiography can detect pericardial effusion as small as 15 ml.

Common causes and clinical features of pericardial effusion :

Read 'Bedside Clinics in Medicine, Part I'.

* In a patient of pericardial effusion, if the X-ray is taken in Trendelenberg's position, there is widening of superior mediastinal shadow.

ENLARGED CARDIAC SHADOW

(Fig. 3.19)

Description :

This is a PA view of the chest which shows grossly enlarged cardiac shadow with increased cardiothoracic ratio. The indentations on the borders of the heart are retained. Bronchovascular markings and right cardiophrenic angle are within normal limit. The lung fields look normal (i.e., not oligaemic).

Other points—Within normal limit.

Conclusion :

Cardiomegaly apparently due to cardiomyopathy.

Enlarged cardiac shadow (cardiomegaly) in radiology :

1. Cardiomyopathy (indentations at cardiac borders are retained, absence of pulmonary oligaemia, right cardiophrenic angle remains acute i.e., normal.)
2. Pericardial effusion (indentations at cardiac borders are lost, pulmonary oligaemia, more acute right cardiophrenic angle).
3. Enlargement of heart chambers (commonly from multiple valvular heart disease) :
   a) Enlargement in transverse diameter with a boot-shaped configuration—RVH.
   b) Enlargement in oblique diameter—LVH.
   c) Double contour of the right border—LAH.
   d) Extension of the right atrial border with increased convexity—RAH.

* Read the causes of chamber enlargement of heart from 'Bedside Clinics in Medicine, Part I'.

4. Congestive cardiac failure [upper lobar veins are prominent, evidence of Kerley's B line, phantom tumour (interlobar effusion) or even hydrothorax may be present].
5. Atrial septal defect (T CTR, RVH, prominent pulmonary artery with pulmonary plethora).
6. Ebstein's anomaly (T CTR with big right atrium).
7. Left ventricular aneurysm (a distinct bulge is seen from the wall of the left ventricle).
8. Chest X-rays taken in full expiration or lying down position, patients with high diaphragm, or with cardiac pad of fat, or with skeletal deformity (e.g., depressed sternum, scoliosis) may give a false impression of cardiomegaly (spurious).

** In chest X-ray , it is better to say chamber enlargement (e.g., left or right ventricle) while in ECG interpretation, chamber hypertrophy is a better terminology.

N.B. : **In clinical practice, common causes of cardiomegaly are,**

1. Pericardial effusion.
2. Cardiomyopathy.
3. Systemic hypertension.
4. Valvular heart diseases present singly or in combination e.g., AI, MI, MS with MI etc.
5. Ischaemic heart disease.
6. Congenital heart disease (ASD, VSD, Ebstein's anomaly).

What is cardiomyopathy ?

These are diseases primarily involving the myocardium in the absence of congenital, rheumatic, hypertensive, coronary, arterial, or pericardial abnormalities, and is present with cardiac enlargement.

Clinical classification of cardiomyopathy :

(A) Dilated or congestive (commonest)—LVH and/or RVH, CCF, arrhythmias, embolism; systolic dysfunction.

(B) Restrictive (rare)—Restriction of LV and/or RV filling; abnormal diastolic function.

(C) Hypertrophic (rare)—Disproportionate LVH. Massive hypertrophy of interventricular septum. Double kicking apex; diastolic dysfunction.

* Features of restrictive variety mimic constrictive pericarditis.

** The diffuse myocardial fibrosis that accompanies multiple myocardial scars developed as a result of myocardial infarction very often derange LV function, and is termed as 'ischaemic cardiomyopathy'.

Management of cardiomyopathy :

(A) Dilated—Management of heart failure, alcohol withdrawal, cardiac transplantation.

(B) Restrictive—Diuretics, excision of the fibrotic endocardium, cardiac transplantation.

(C) Hypertrophic—Beta blockers, dual chamber pacing.

Possible aetiology of combined pleural plus pericardial effusions :

1. Tuberculosis / viral.
2. Hydrothorax (e.g., CCF, cirrhosis of liver).
3. Lymphoma or acute leukaemias.
4. Collagen vascular diseases (e.g., SLE).
5. Polyserositis.
6. Septicaemia.
7. Neoplastic or post-irradiation.

[C] STRAIGHT X-RAY OF THE ABDOMEN

GAS UNDER THE DIAPHRAGM

(Fig. 3.20)

Description :

This is a striaght X-ray of the abdomen (taken in erect posture) which shows semilunar gas shadow under the right dome of diaphragm. Normal fundal gas shadow is seen under the left dome of diaphragm.

Psoas shadow, feature of bowel obstruction, calculus or any sign of calcification is absent. Lung bases are normal with clear costophrenic angles.

* Never say PA or AP view of the abdomen.

Conclusion :

This X-ray film strongly suggests perforation of hollow viscus, most probably it is acute perforation of a peptic ulcer.

The other possibilities are :

1. Peritonitis by gas forming organism.
2. Subdiaphragmatic abscess (right) by gas forming organism.
3. Following:
   a) Tubal insufflation test.
   b) Abdominal surgery.
   c) Laparoscopy.
   d) Peritoneal dialysis.
4. Chilaiditi's syndrome i.e., interposition of colon between the liver and the diaphragm simulating pneumoperitoneum (colonic haustrations are seen). This is a normal finding as well as a transient phenomenon.

Clinicaly, how to suspect the presence of gas under the diaphragm ?

Percussion of the liver is done from above downwards along right MCL. Loss of liver dullness clinches the above diagnosis in a patient with acute abdomen.

What is Helicobacter pylori ?

These are spiral, curved or comma-shaped, microaerophilic, gram -ve and Giemsa +ve multiflagellated,

highly motile organism measuring 0.5 x 0.3 mm which colonises the stomach in the deep portion of mucous gel layer that coats mucosa and also in the surface epithelial cells. They adhere to gastric epithelium but never invade. H. pylori is responsible for 80% patients developing gastric ulcer, 95-100% cases of duodenal ulcer and 50% cases of non-ulcer dyspepsia.

How to eradicate Helicobacter pylori ?

Eradication of H. pylori is not an easy matter. H. pylori plays a role in the development of gastric adenocarcinoma and mucosa-associated lymphoid tissue (MALT), and thus it should be eradicated at its earliest. There are many drug schedules but the accepted regimens are :

(A) Monotherapy : Colloidal bismuth 120 mg QDAC or lansoprazole 30 mg ODAC for 4 weeks. Cure rate is 10%.

(B) Dual therapy : Omeprazole 20 BDAC, plus amoxycillin 500 gm TDS x 2 weeks. Cure rate is 60%.

(C) Tripple therapy :

(i) Traditional—Colloidal bismuth 120 mg QDAC, plus metronidazole 400 mg TDS, plus amoxycillin 500 mg TDS x 2 weeks. Cure rate is 85-90%.

(ii) Non-bismuth therapy—Omeprazole 20 mg ODAC or BDAC, plus clarithromycin 250 mg BDS, plus metronidazole 400 mg or tinidazole 500 mg TDS x 7 dyas. Cure rate is 90%.

(D) Quadruple therapy : Traditional tripple therapy, plus one antisecretary agent (H_2RA or proton pump inhibitor) x 14 days. Cure rate is 90%.

* A **recently suggested non-bismuth tripple therapy** containing two antibiotics demands very high cure rate and comprises omeprazole 20 mg BDAC, plus clarithromycin 500 mg BDS, plus amoxycillin lg BDS given orally for 7 days only.

** Instead of omeprazole 20 mg, lansoprazole 30 mg/pantoprazole 40 mg may be tried.

*** Important facts : When standard regimens failed ciprofloxacin/levofloxacin, furazolidone and rifabutin are also used in tripple thrapy ('rescue therapy'). A shorter regimen of 7-10 days are not as effective as tripple therapy for 14 days.

**** At present, the accepted :

Regimen 1 : Omeprazole (20 mg BDAC) + clarithromycin (500 mg BDS) + amoxycillin (lg BDS) x 7 days.

Regimen 2 : Same as above except metronidazole (400 BDS) instead of amoxycillin x 7 days.

Regimen 3 : Omeprazole (20 mg BDAC) + colloidal bismuth 240 mg QDAC + tetracycline (500 mg QDS) + metronidozole (400 mg TDS) x 14 days.

N.B. : Regimen 1 and 2 are first line while Regimen 3 is second line choice.

'Calcification' seen in the straight X-ray of abdomen :

1. Faecoliths.
2. Phleboliths.
3. Calcified lymph nodes (e.g., tuberculosis), calcified aorta, calcified dermoid/fibroid/foetus.
4. Calculi in organs like renal, biliary, pancreatic and splenic.
5. Hepatic calcification : haemangioma, tuberculosis, hepatoma, calcified hydatid cyst, brucellosis, histoplasmosis.
6. Chronic pancreatitis, Addison's disease, calcification of abdominal wall (e.g., cysticercosis).

[D] BARIUM STUDY

For barium studies of the G. I. tract, the patient swallows radio-opaque barium sulfate. The radiologist carefully observes the passage of barium on a fluorescent screen/TV monitor with an image intensifier and takes X-ray films for permanent recording. For the study of oesophagus, *barium swallow* X-ray is required (for stricture, varices, achalasia cardia, hiatus hernia); and for stomach, duodenum and small intestine (e.g., narrowing, dilatation, diverticula, floculation of barium in malabsorption, narrow-

ing of ileocaecal valve) barium meal X-ray are taken sequentially after few minutes of swallow *(barium follow-through). Barium enema* (barium suspension introduced per rectum) is used for diagnosis of large intestinal (e.g., ulcerative colitis) and rectal diseases.

For better visualisation in barium enema study, when barium and air both are used it is known as 'double contrast' study.

DUODENAL ULCER

(Fig. 3.21)

Description :

This is a barium meal X-ray of stomach and duodenum which shows deformity of the duodenal cap. The outline of stomach is within normal limit. It is seen that barium has passed into the small intestine.

Conclusion :

Duodenal ulcer.

* Deformity of the duodenal cap is due to an ulcer crater, oedema, muscular spasm, fibrosis or their combination.

Enumerate the deformities of duodenal cap :

One of the deformities is known as clover leaf or trefoil deformity.

How do you diagnose Helicobacter pylori ?

1. Histology by gastric mucosal biopsy (gold-standard for diagnosis; the organism has been discussed in X-ray picture of 'Gas under the diaphragm'. The biopsy tissue is stained by,
   a) Haematoxylin and eosin.
   b) Special stain (modified Giemsa, Warthin-Starry, Gram stain).
   c) Immunohistochemistry (endonuclease analysis).
2. Biopsy culture—most specific but may not be very sensitive.
3. Serology (ELISA)—detects IgG antibody, and are reasonably sensitive (90%) as well as specific. Detection of IgG antibody in saliva may also be done.
4. Rapid urease test—biopsy tissue is put into urea-containing broth (Chlamydia-like organism or CLO test; also known as helicochek test; urea-containing broth is broken down to NH_3 if urease is produced by H. pylori and the colour of the broth is changed to red in a positive test).
5. Carbon-urea (13_c or 14_c) breath test—most consistently accurate test; useful for screening test to detect H. pylori, and also to follow-up after treatment.
6. Stool antigen test for H. pylori (HpSA)—a new promising test, role not fully established.
7. Emerging : Polymerase chain reaction (PCR).

* H. pylori was discovered by Marshall and Warren in 1983, who received Nobel Prize in 2005.

** Invasive tests—1, 2, 4; non-invasive tests—3, 5, 6, 7

GASTRIC ULCER

(Fig. 3.22)

Description :

This is a barium meal X-ray of stomach which shows an ulcer crater on the lesser curvature of the stomach (the small projection) and an indentation or indrawing (incisura) on the greater curvature opposite to the ulcer crater. There is no filling defect seen within the stomach. Duodenal cap is not clearly visualised. Barium has passed into the duodenum and small intestine. Bony and soft tissue structures show no apparent abnormality.

Conclusion ;

Benign gastric ulcer.

Possible aetiology of 'stress ulcers' and erosions in stomach :

1. NSAID (e.g., aspirin) or corticosteroid-induced.
2. Head injury or increased intracranial tension (Cushing's ulcer), bum (Curling's ulcer), severe sepsis, shock and severe trauma.

Table 8 : Differentiation between benign and malignant ulcer in stomach

	Benign ulcer		Malignant ulcer
1.	Projects beyond the margin of lesser curvature	1.	Remains within the margin of curvature
2.	Deep	2.	Shallow
3.	Sharply marginated, round	3.	Irregular in shape
4.	Rugae converge towards ulcer	4.	Rugae are interrupted
5.	Smooth ulcer 'collar'	5.	Absence of ulcer 'collar'
6.	Hampton's line (linear radiolucent line at the base of projection in lesser curvature) is present	6.	Hampton's line is absent
7.	No adjacent nodules or mass	7.	Adjacent wall is rigid or nodular
8.	Heals completely	8.	Complete healing is rare

* Larger ulcers (> 2 cm) are likely to be malignant. Ulcers in lesser curvature are usually benign whereas greater curvature ulcers are likely to be malignant.

OESOPHAGEAL CARCINOMA

(Fig. 3.23)

Description :

This is a barium swallow (oblique view) X-ray of oesophagus showing persistent irregular filling defect or a persistently stenotic segment. Proximal dilated part of oesophagus (usually present) is not seen here.' Either soft tissue growth or clssical 'rat-tail' like deformity is not present. Bony structure shows no apparent abnormality. The dye (radio-opaque barium sulfate) has passed into the stomach.

Conclusion :

Carcinoma of the oesophagus (involving middle and lower third).

How to confirm the diagnosis ?

By endoscopic biopsy.

Irregular filling defect of oesophagus in barium swallow :

1. Carcinoma of the oesophagus (rat-tail deformity).
2. Oesophageal varices.
3. Multiple stricture following strong acid or alkali poisoning.
4. Leiomyoma of the oesophagus.
5. Diffuse oesophageal spasm (corkscrew oesophagus).
6. Candida (monilial) oesophagitis.

Describe the barium swallow picture of oesophageal varices :

Multiple filling defects give a picture of *'moth-eaten'* or *'worm-eaten'* appearance of the oesophagus and the irregularity is maximum near the lower end. The varices formed by anastomosing channels of portal and systemic veins produce those serpigenous filling defects in the regular contour of oesophagus. Oesophageal varices also need endoscopic confirmation and grading.

CARDIOSPASM

(Fig. 3.24)

Description :

This is a barium swallow X-ray of oesophagus which shows smooth and symmetrical beak-like narrowing of the terminal part (of oesophagus) with funnel-like gross dilatation of the proximal part (seen within the cardiac shadow). There is absence of fundal gas shadow. Bony and soft tissue structures show no apparent abnormality.

Conclusion :

Cardiospasm or achalasia cardia.

D/D with carcinoma of the oesophagus :

(A) Cardiospasm : Outline is smooth, central narrowing of lumen, beak-like narrowing and non-rigid affected area (fluoroscopy); absent fundal gas shadow.

(B) Carcinoma of the oesophagus : Outline is irregular, eccentric narrowing of lumen, irregular narrowing and rigid affected area (fluoroscopy); fundal gas shadow is visible.

Symptoms at presentation :

Usually a middle-aged patient presents with,

1. Dysphagia (first with solids, then both with solids and liquids).
2. Retrosternal chest pain (vigorous achalasia).
3. Regurgitation (effortless apperance of gastric content in mouth).
4. Cough due to recurrent pulmonary aspiration.
5. Sense of fullness or a gurgling sound while taking meal.
6. Loss of weight.

Different causes of cardiospasm :

(A) Primary or idiopathic : Congenital defect of smooth muscle innervation [reduction in myenteric neurones which is related to abnormal nitric oxide synthesis within the lower oesophageal sphincter (LES)].

(B) Secondary : Infiltrating gastric carcinoma, lymphoma, irradiation, Chagas' disease, toxins and drugs (chronic narcotic use).

Investigations commonly done :

1. PA view of the chest—Midline opacity with horizontal fluid level may be seen in upright posture; absence of fundal gas shadow.
2. Barium swallow of oesophagus—Described above.
3. Oesophagoscopy—Endoscopy may reveal inflammation and ulceration; oesophagus is dilated. On gentle pressure, the instrument can be pushed into the stomach (may not be possible in oesophageal carcinoma). Endoscopy is very helpful in excluding secondary causes, specially gastric carcinoma (biopsy is taken, if necessary). Proper cleansing of oesophagus is necessary before endoscopy.
4. Oesophageal manometry—Elevated resting lower oesophageal sphincter (LES) pressure; absence of swallow-induced relaxation of LES; simultaneous-onset contractions replace primary peristaltic waves; injection of mecholyl (cholinergic drug) raises the baseline oesophageal pressure instead of lowering it.

Line of management :

1. Calcium channel blockers like nifedipine, or isosorbide dinitrate sublingually; soft foods, sedatives, anticholinergic drugs are not very helpful. Mild cases may not require treatment.

2. Hydrostatic or pneumatic bag dilatation—One or more dilatations may be required.
3. Endoscope-aided injection of botulinum toxin into the LES may induce temporary clinical remission.
4. Heller's cardiomyotomy operation—Risk of development of reflux oesophagitis and peptic stricture of oesophagus are there. In this operation, the circular muscle layer is incised.
5. Colonic interposition may be done.

'Opacity' seen within cardiac opacity in a PA view of chest X-ray :

1. Aortic aneurysm.
2. Paravertebral abscess (e.g., cold abscess).
3. Any soft tissue mass (e.g., mediastinal mass).
4. Extramedullary haematopoiesis (e.g., thalassaemia).
5. Achalasia cardia.

* Achalasia cardia has an increased incidence of developing squamous cell carcinoma of the oesophagus after few years.

PYLORIC STENOSIS

(Fig. 3.25)

Description :

This is a barium meal X-ray (of stomach) which shows grossly distended stomach (with excessive fasting contents). An obstruction is seen near the pylorus though the dye has passed into the duodenum. Bony and soft tissue structures show no apparent abnormality.

Conclusion :

Gastric outlet obstruction, most probably pyloric stenosis.

Confirmation of diagnosis :

a) Failure of the stomach to evacuate the barium meal even after 6 hours.
b) Upper G. I. endoscopy.

Diff erential diagnosis :

(A) Gastric outlet obstruction—Other than pyloric stenosis (resulting from duodenal cicatrisation as a complication of chronic duodenal ulcer) they are carcinoma of the pylorus, oedema of the pylorus, adult hypertrophic pyloric stenosis, hypertrophic gastritis, bezoars (trichobezoars or phytobezoars) and congenital hypertrophic pyloric stenosis (infants).

(B) Non-obstructive gastric dilatation— Gastroparesis diabeticorum (from diabetes mellitus), postpartum and postoperative gastric dilatation, drugs (clonidine, tricyclic antidepressants e.g., amitriptyline), scleroderma, dermatomyositis or polymyositis, myotonia dystrophica. In this category, radioisotopic gastric emptying study often confirms the diagnosis.

Important bedside signs in pyloric stenosis :

1. Diffuse swelling present in the upper abdomen.
2. Visible peristalsis traversing from left to right hypochondrium.
3. Positive succussion splash.
4. Positive ausculto-percussion test.

[E] X-RAY OF SKULL

MULTIPLE MYELOMA

(Fig. 3.26)

Description :

This is a lateral view of the skull which shows multiple small, rounded, 'punched out' areas (radiolucency) of different sizes. The margin of the radiolucent areas are sharply defined and are not surrounded by zone of osteosclerosis.

Orbital fossa, sinuses, pituitary fossa are within normal limit. No intracerebral calcification is noted. Soft tissue shadow of pinna (ear) is present.

Conclusion :

Probably, it is the skull X-ray of multiple myeloma.

Single or multiple osteolytic lesion in skull :

1. Multiple myeloma (classical rounded 'punched out' areas without surrounding osteosclerosis).
- 2. Metastatic carcinoma from bronchus, thyroid, breast or kidney (osteoblastic reaction, i.e., osteosclerosis is seen at the margin of osteolytic lesions).
3. Hyperparathyroidism (spotty decalcification).
4. Paget's disease (moth-eaten appearance).
5. Histiocytosis X disease (big mappy area of radiolucency or 'geographical skull').
6. Leukaemic or lymphomatous deposits (small to large).
7. Burr-hole (iatrogenic).
8. Sarcoidosis (small to large).
9. Miscellaneous—Big diploic foramen, congenital venous lakes, haemangioma of the vault, fibrous dysplasia, arachnoid granulations.

* Mandible may be affected in multiple myeloma, which is usually not a feature of metastatic carcinoma.

Radiographic examination in multiple myeloma :

1. Skull—multiple punched out osteolytic lesions.
2. Spine—collapse of one or more vertebrae, and osteoporosis.
3. Chest—punched out lesions in ribs, clavicle and sternum; pathological fracture in ribs.
4. Pelvis—multiple punched out osteolytic lesions; osteoporosis.
5. Kidney—nephrocalcinosis.

Features noted in any X-ray of skull:

They are viewed as follows,

(A) Calvarium and base (e.g., physiological radiolucencies like sutures, vascular imprints; or fracture; or sinuses, fontanelles).

(B) Sella turcica (shape, size, erosion of clinoid process, mineralisation etc).

(C) Calcification.

Presentation *of multiple myeloma :*

It is a 'plasma cell neoplasm', and other related disorders are Waldenstrom's macroglobulinaemia, benign monoclonal gammopathy, .heavy chain diseases and primary amyloidosis. The patient of multiple myeloma is classically a male one, in between 60-70 years of age and presents with :

1. Bone pain (most common symptom)—specially in the spine.
2. Severe weakness with wasting.
3. Low-grade pyrexia.
4. Pre-syncope, syncope, vertigo, breathlessness as a result of severe anaemia.
5. Paraplegia (with plasmacytoma or localised myeloma).

Radiology

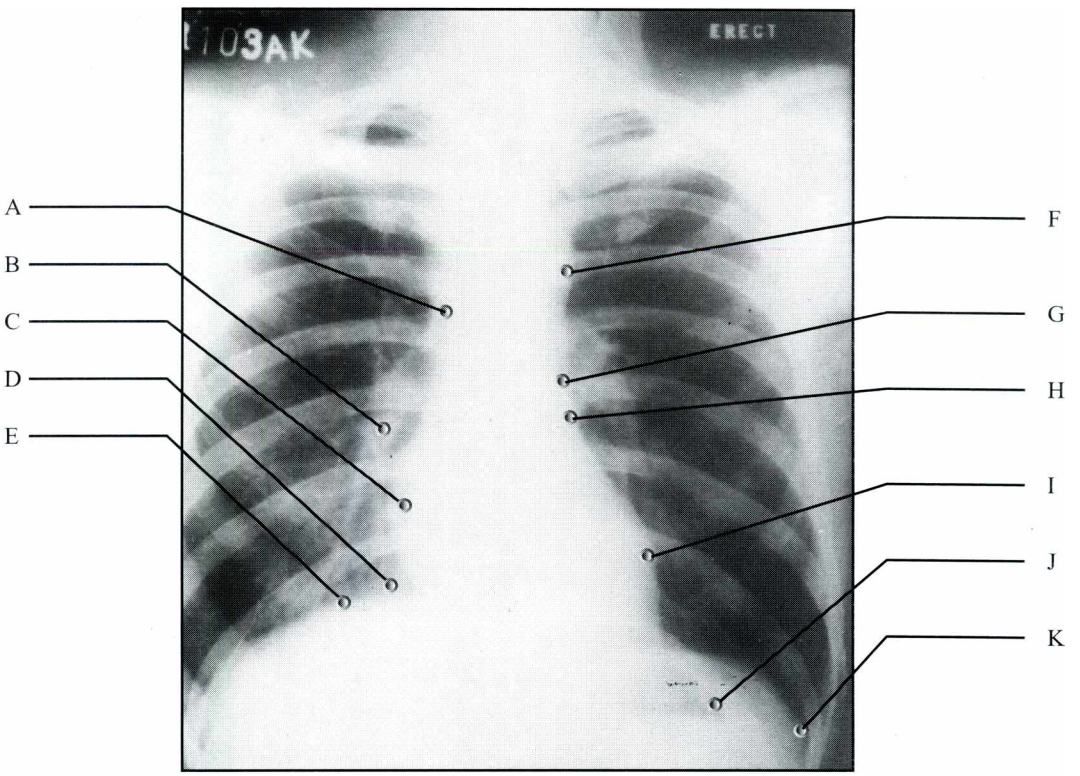

Fig. 3.1 : PA view of the chest in a normal adult

A : Superior vena cava
B : Bronchovascular marking
C : Right atrium
D : Cardiophrenic angle (right)
E : Diaphragm (right)
F : Aortic knuckle
G : Main pulmonary artery
H : Left atrial appendages
I : Left ventricle
J : Fundal gas shadow
K : Costophrenic angle (left)

Radiology

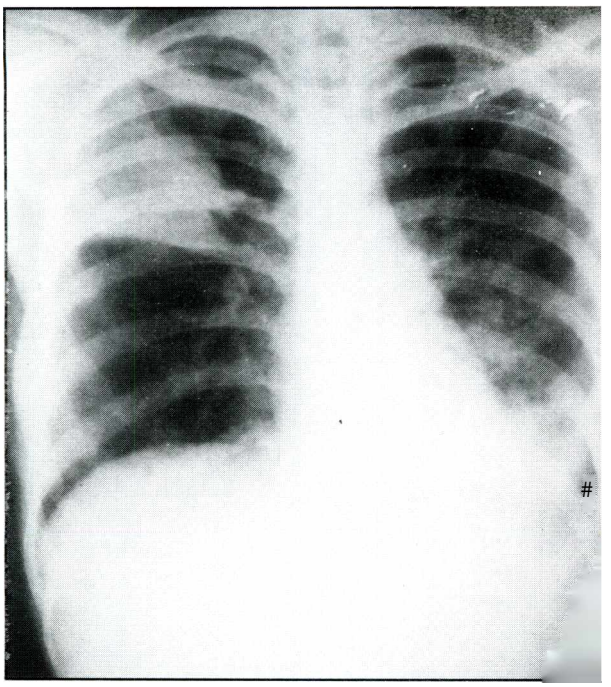

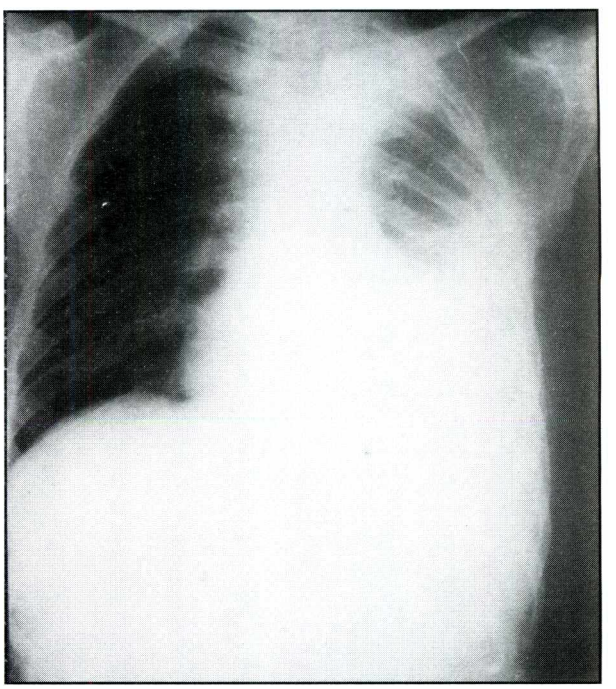

Fig. 3.3 : Left-sided pleural effusion

Fig. 3.2 : Consolidation of the right lung

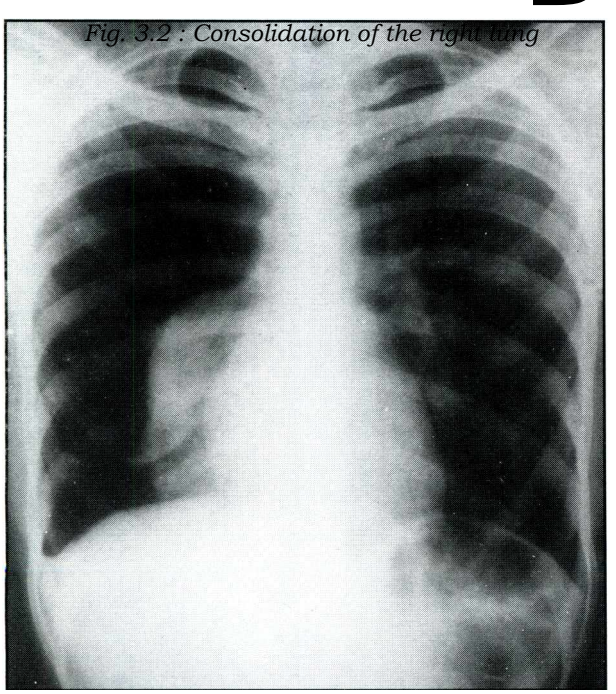

Fig. 3.4 : Pneumothorax of right side

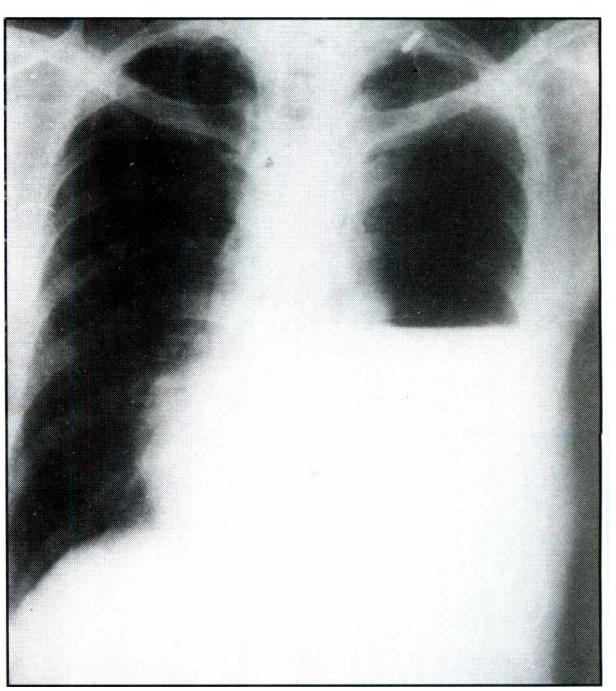

Fig. 3.5 : Hydropneumothorax of left side

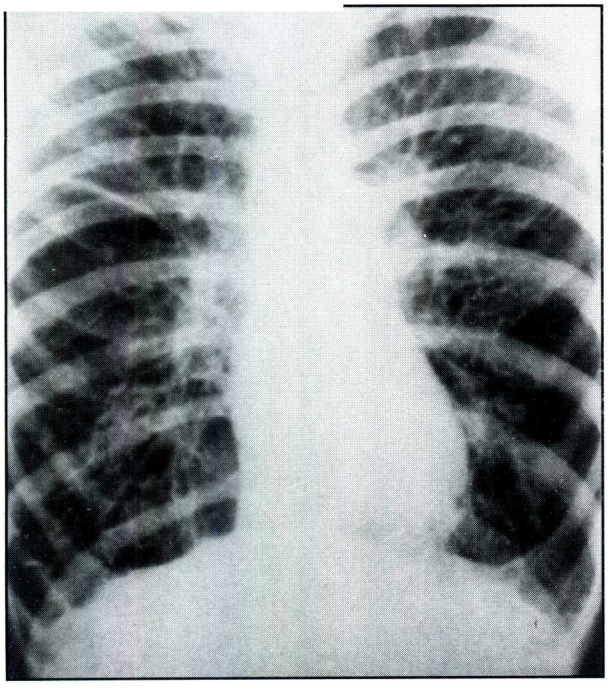

Fig. 3.6 : Emphysema

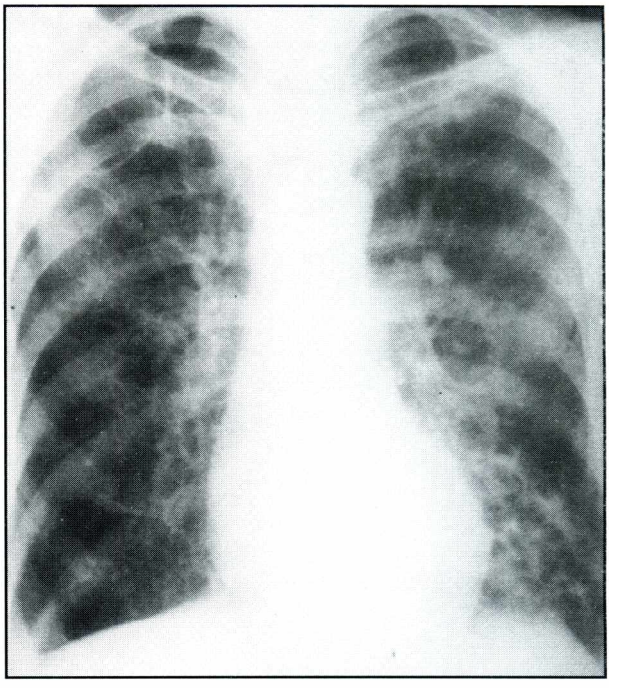

Fig. 3.7 : Bronchiectasis

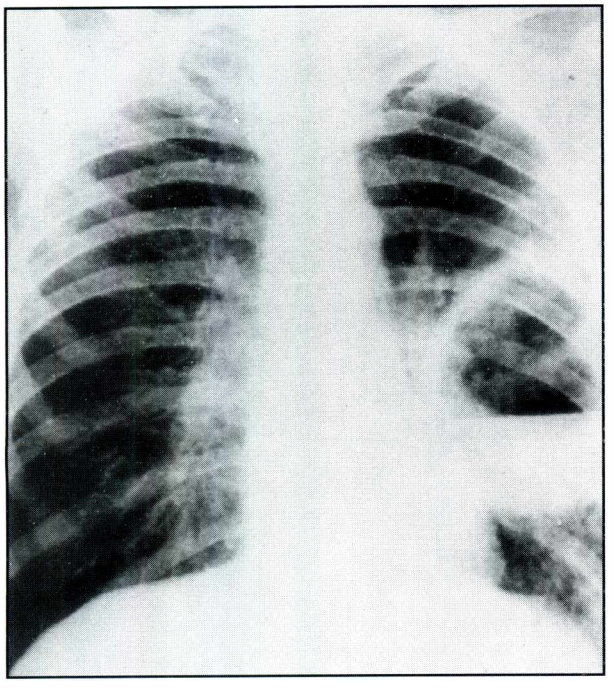

Fig. 3.8 : Left-sided lung abscess

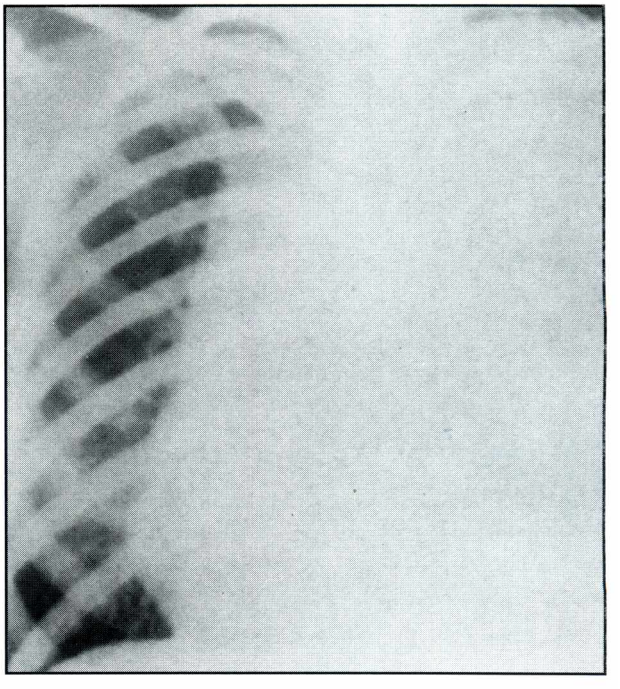

Fig. 3.9 : Homogeneous opacity' of left hemithorax

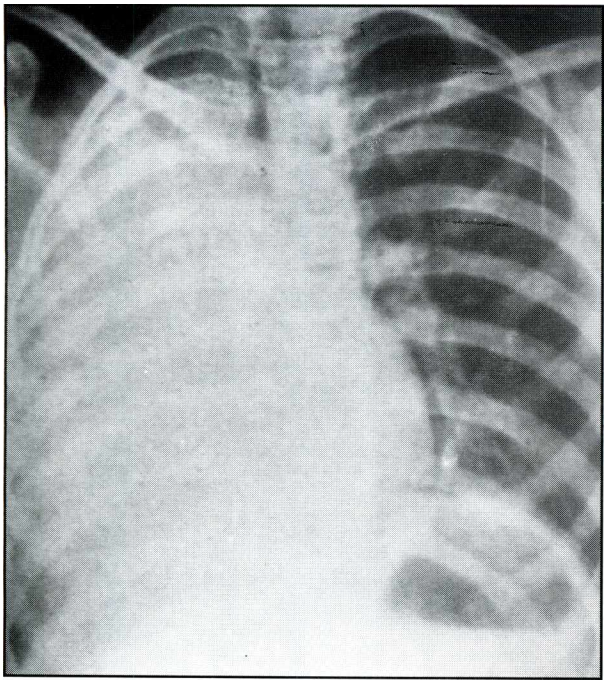

Fig. 3.10 : Collapse of the right lung

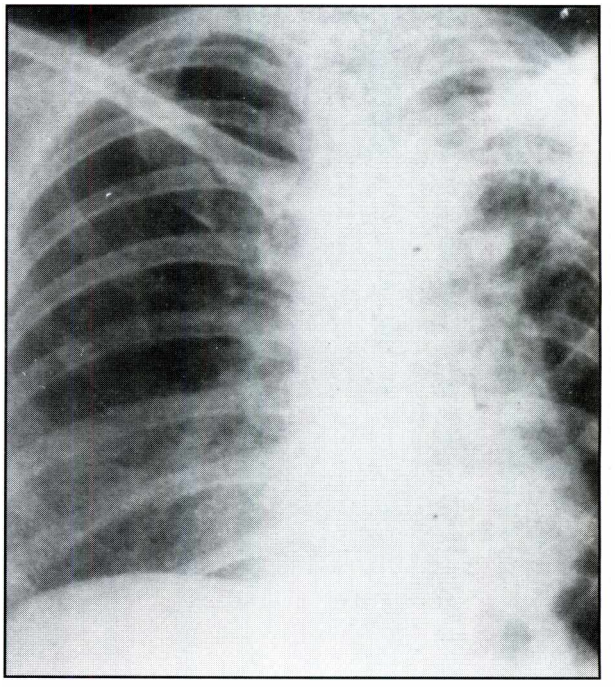

Fig. 3.11 : Fibrosis of the left upper lobe

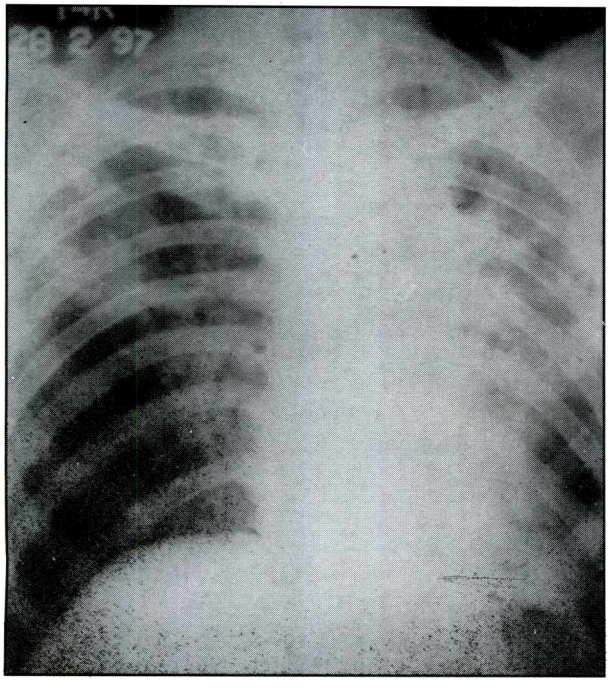

Fig. 3.12 : Tuberculous infiltrations

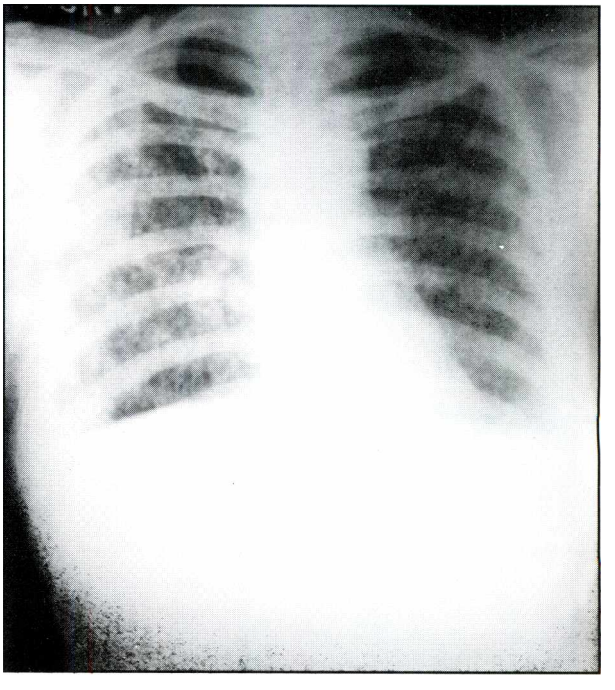

Fig. 3.13 : Miliary mottlings

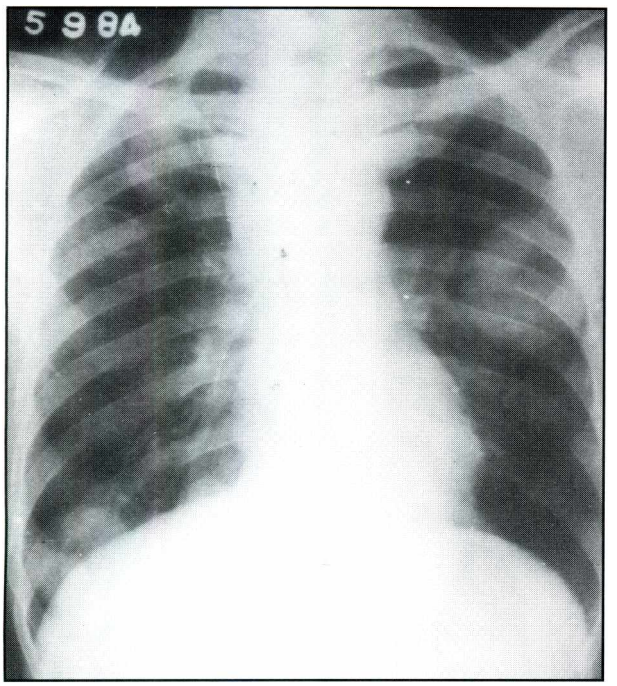

Fig. 3.14 : Mediastinal widening

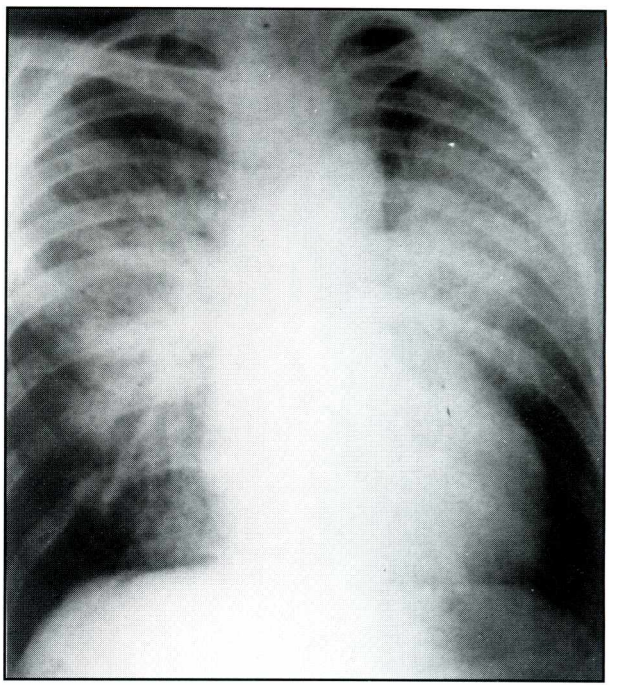

Fig. 3.15 : Pulmonary oedema

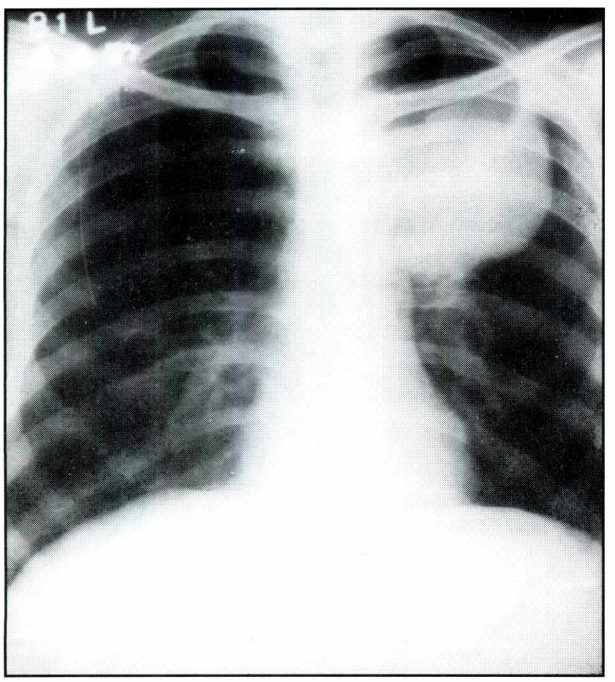

Fig. 3.16 : Left-sided thoracic neoplasm

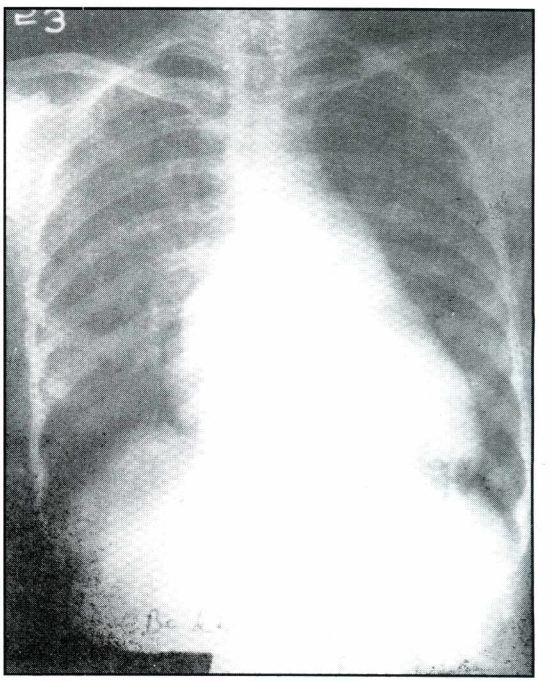

Fig. 3.17 : Mitral stenosis

Radiology

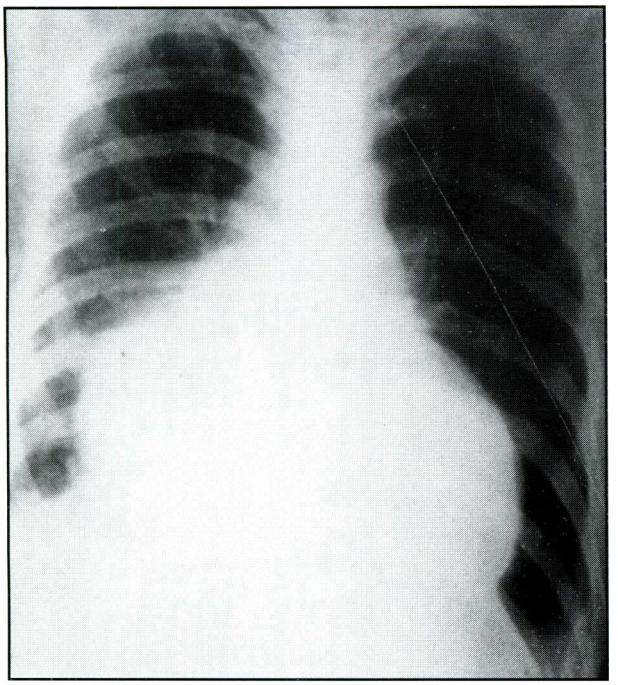

Fig. 3.18 : Pericardial effusion

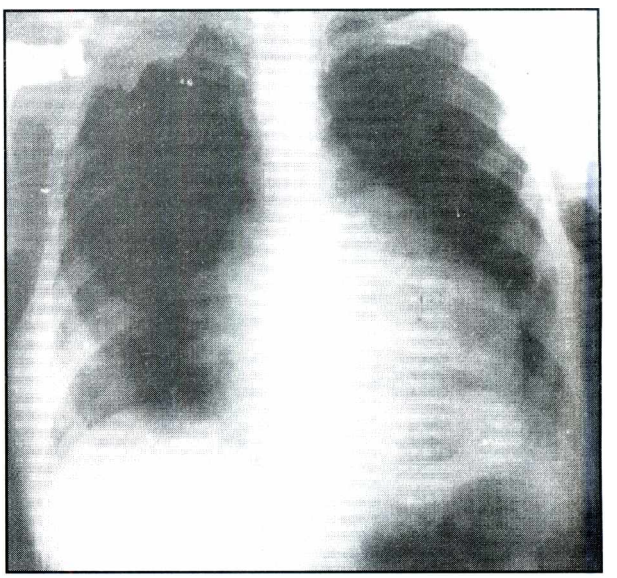

Fig. 3.19 : Enlarged cardiac shadow

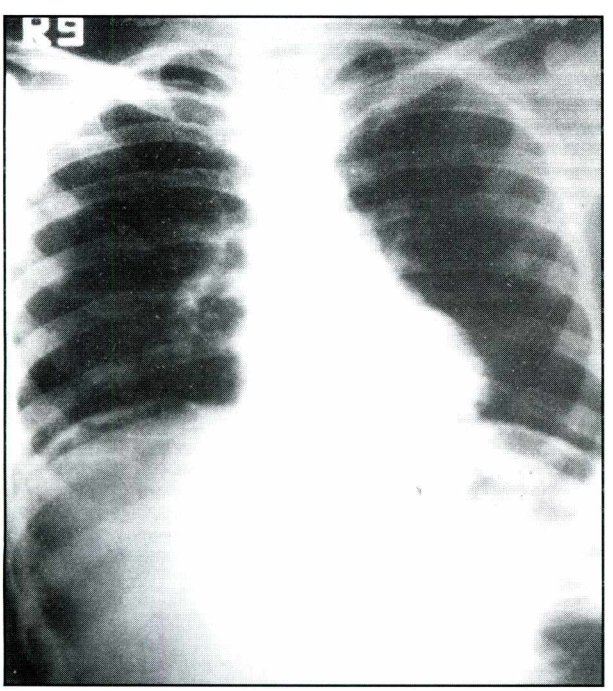

Fig. 3.20 : Gas under the diaphragm

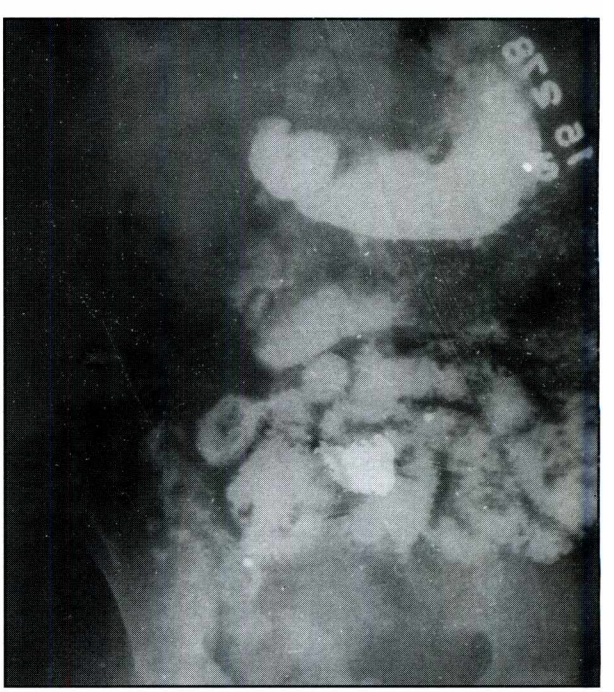

Fig. 3.21 : Duodenal ulcer

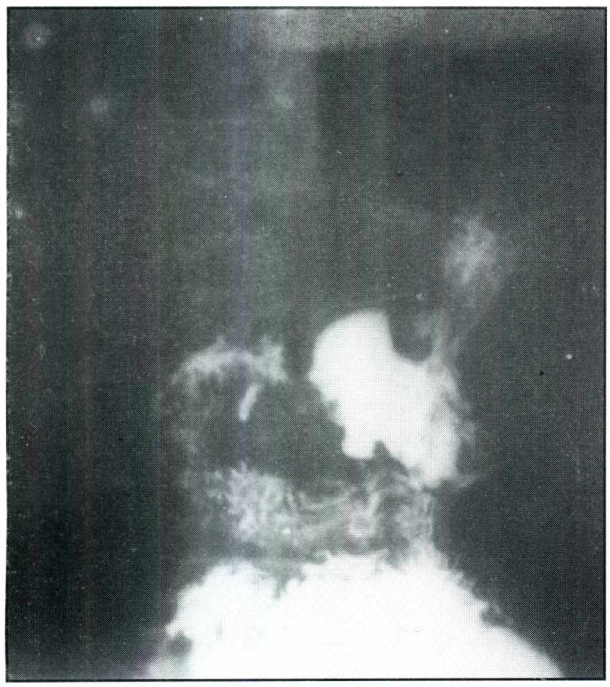

Fig. 3.22 : Gastric ulcer

Fig. 3.23 : Oesophageal carcinoma

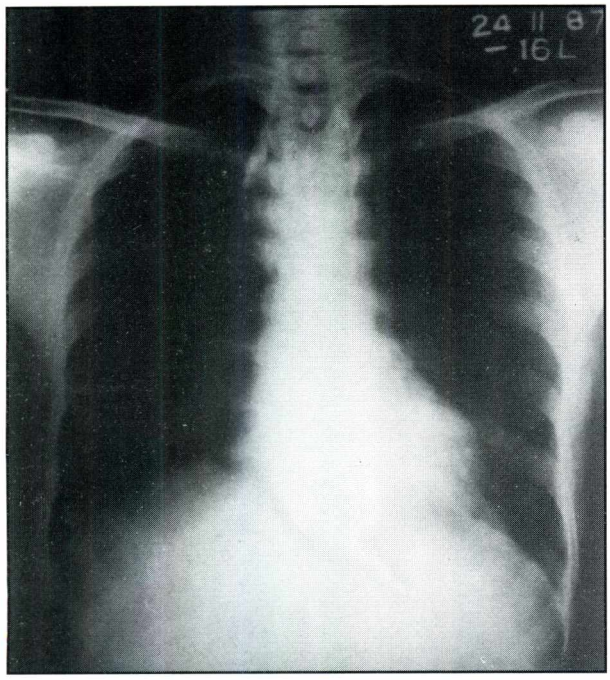

Fig. 3.24 : Cardiospasm (achalasia cardia)

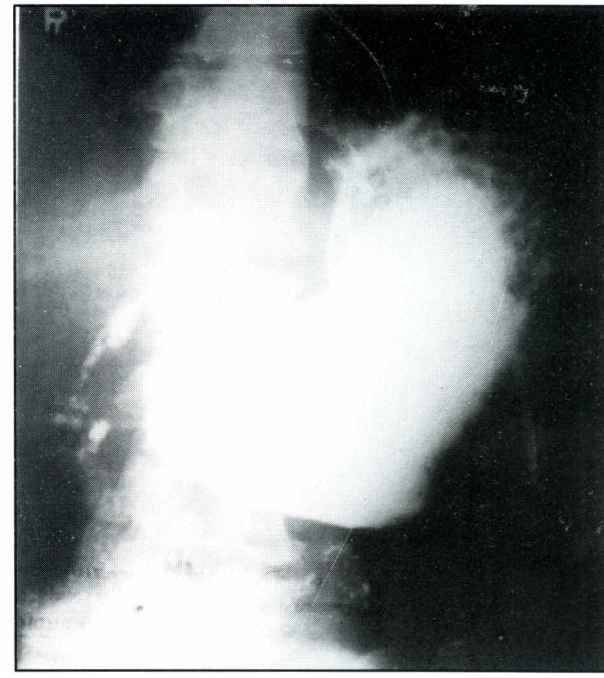

Fig. 3.25 : Pyloric stenosis

Radiology

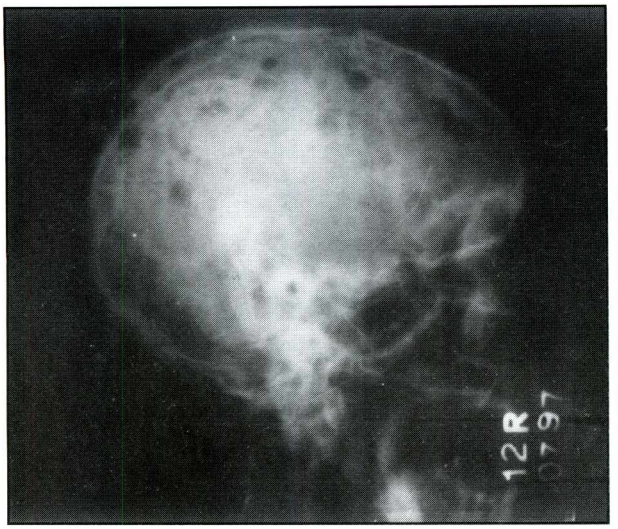

Fig. 3.26 : Multiple myeloma

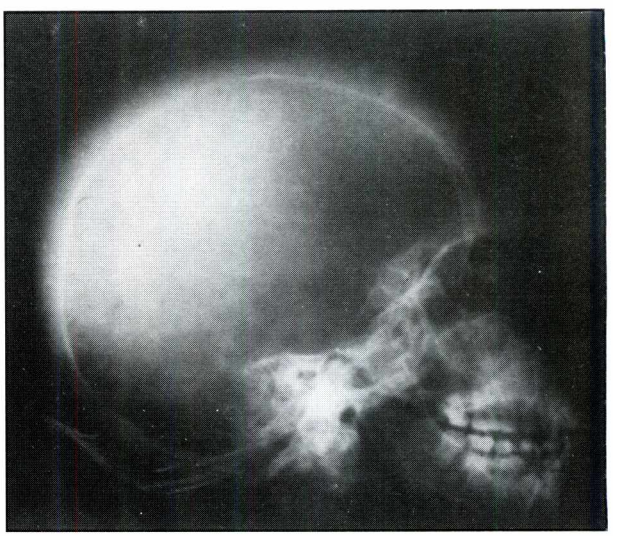

Fig. 3.27 : Thalassaemia

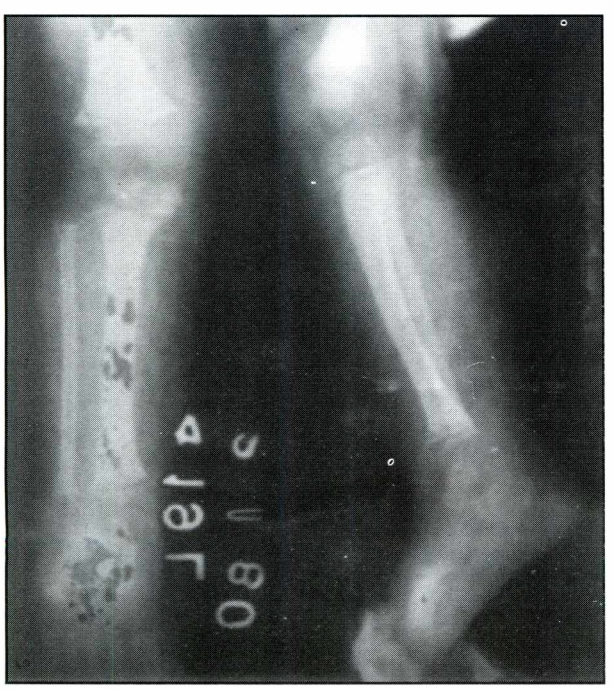

Fig. 3.28 : Scurvy

Fig. 3.29 : Rickets

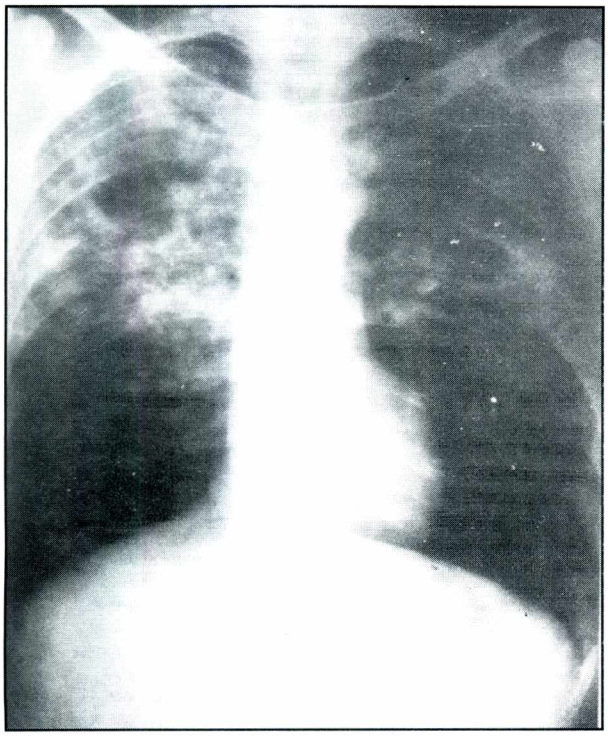

Fig. 3.30 : Bilateral fibro-cavitary lesion

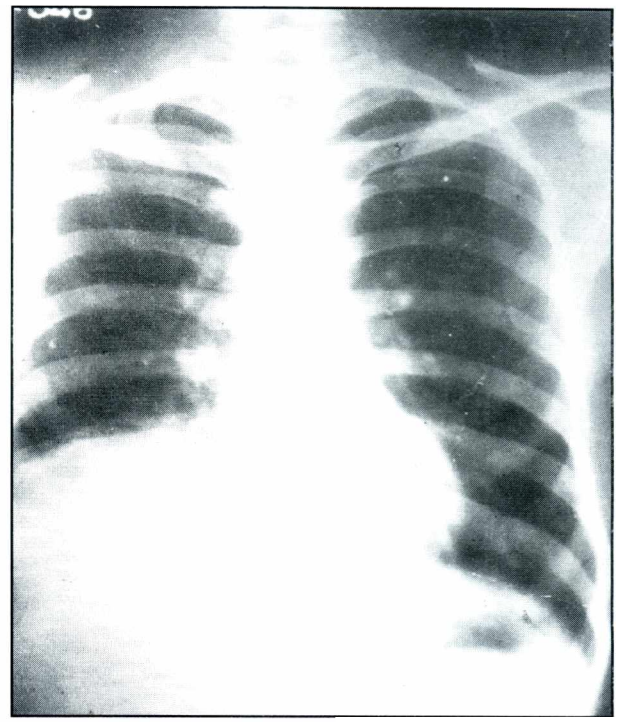

Fig. 3.31 : Elevated right dome of diaphragm

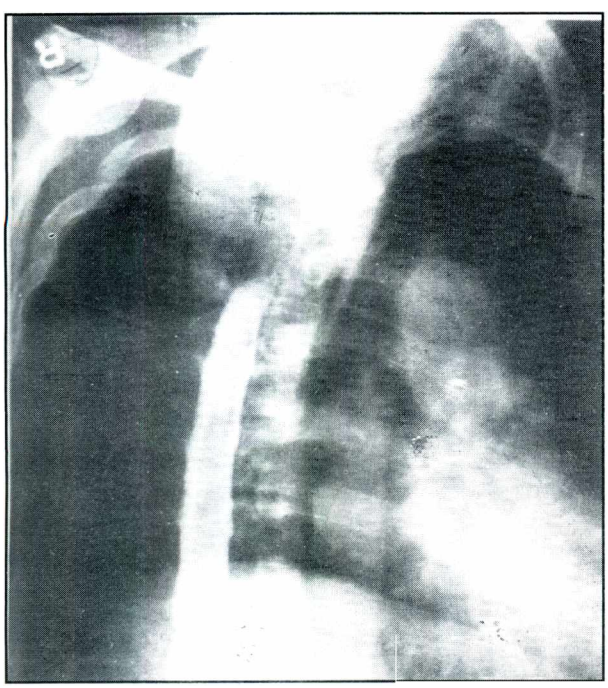

Fig. 3.32 : Myelography with spinal block

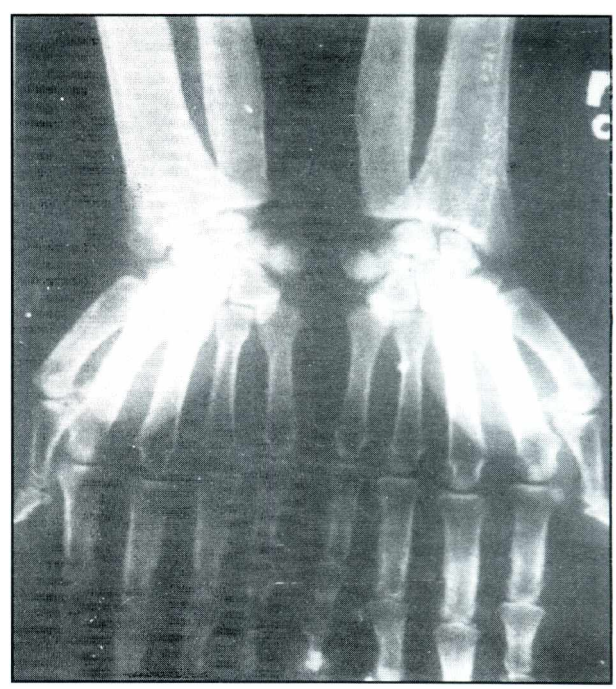

Fig. 3.33 : Hypertrophic osteoarthropathy

CT Scan

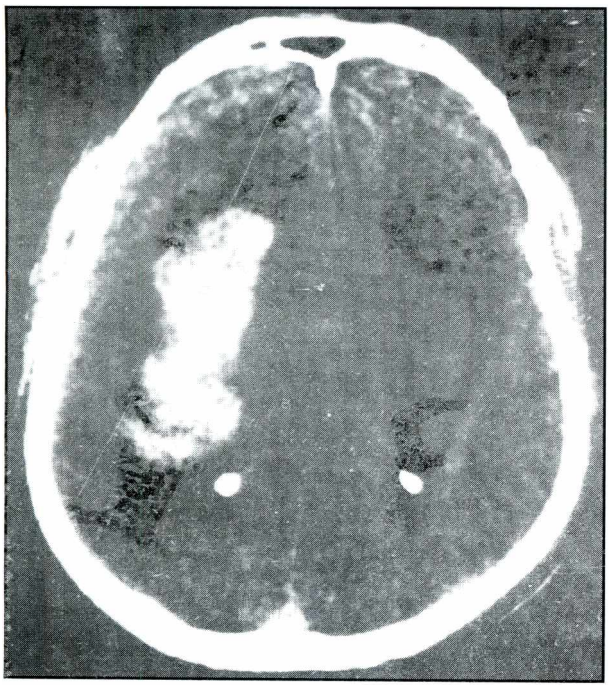

Fig. 3.34 : Intracerebral bleed (haematoma)

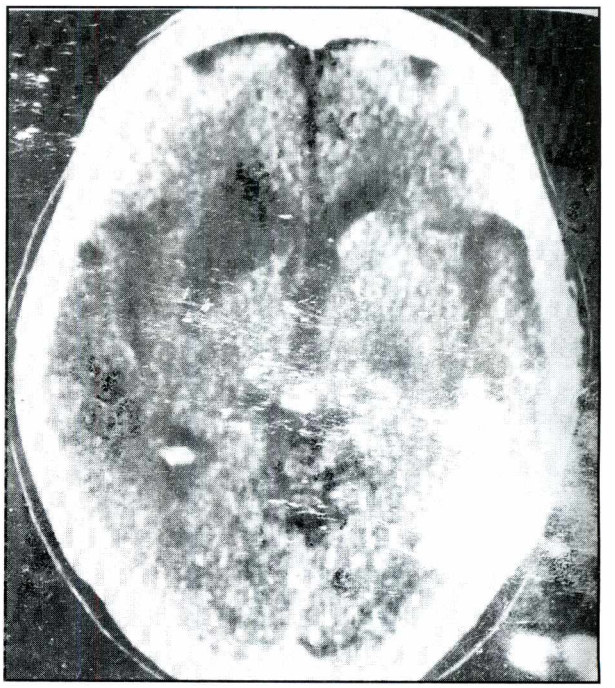

Fig. 3.35 : Cerebral infarction

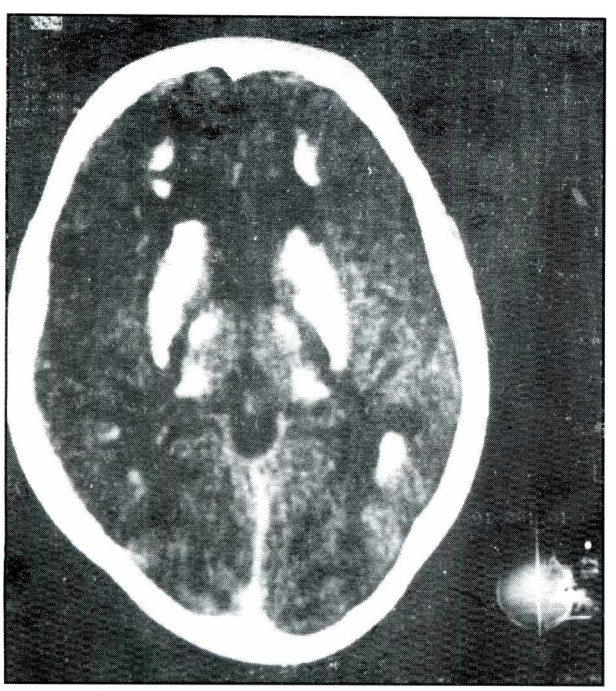

Fig. 3.36 : Basal ganglia calcification

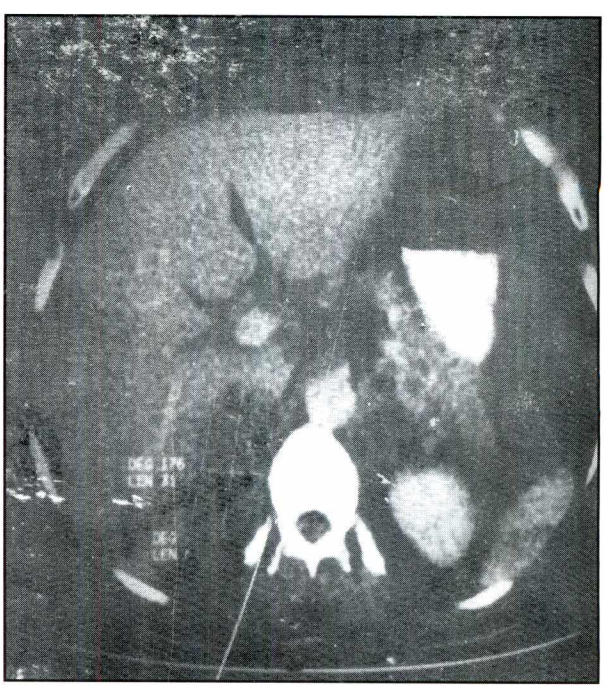

Fig. 3.37 : Bilateral adrenal tumour

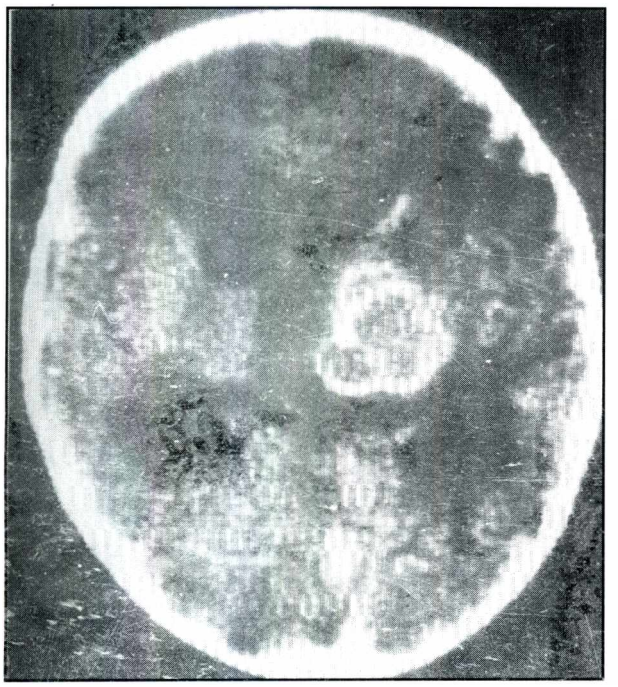

Fig. 3.38 : Tuberculoma

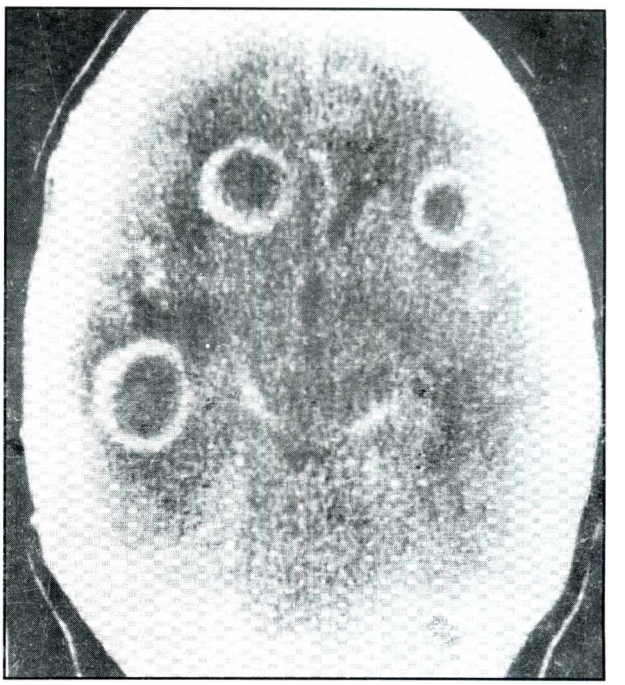

Fig. 3.39 : Multiple cerebral abscesses

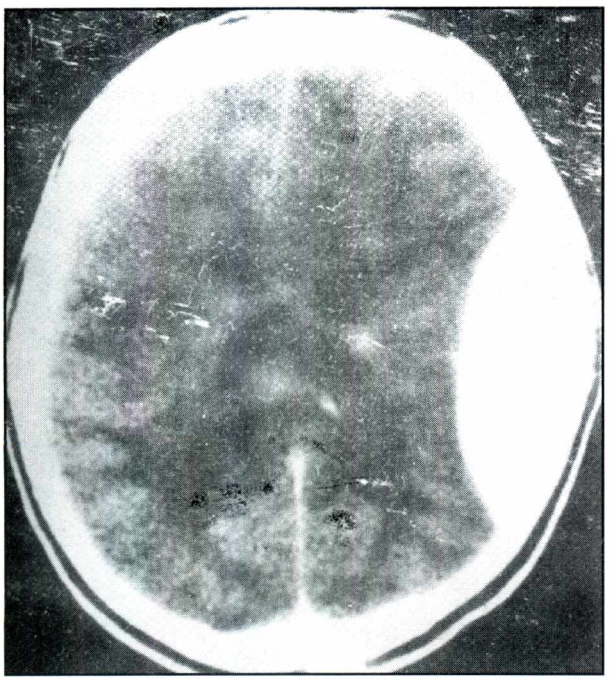

Fig. 3.40 : Epidural haematoma

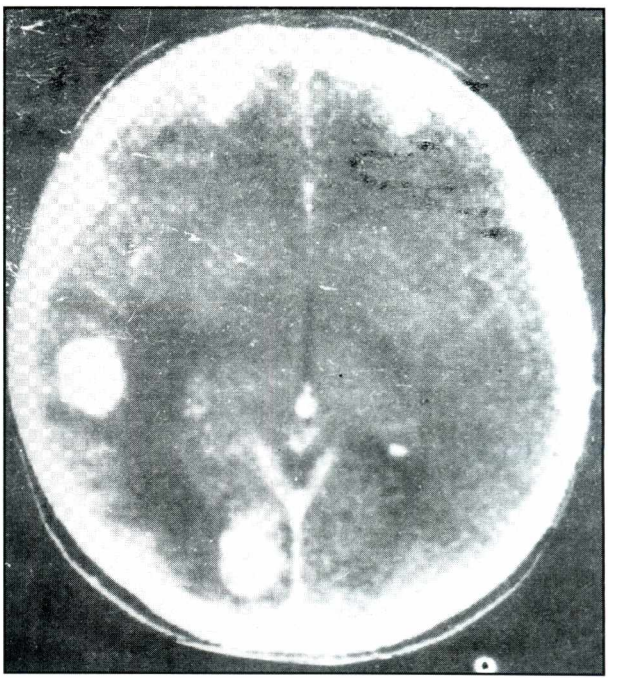

Fig. 3.41 : Cerebral metastases

CT Scan

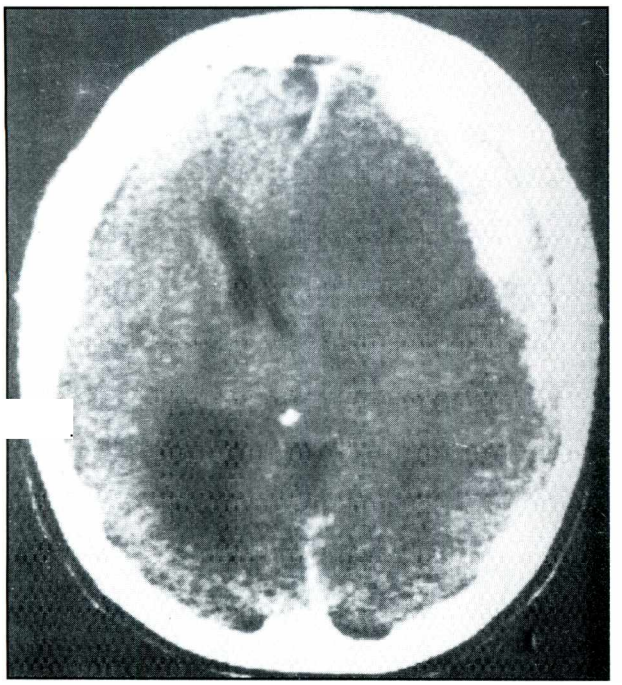

Fig. 3.42 : Acute subdural haematoma

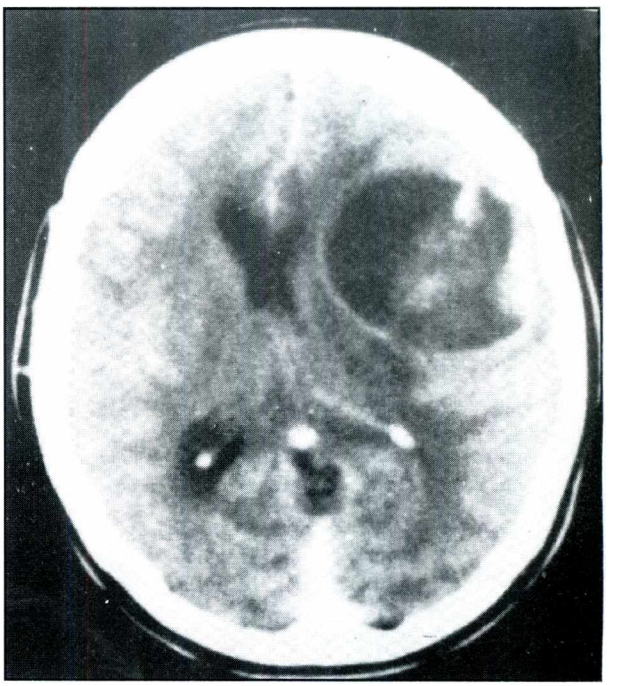

Fig. 3.43 : Intracerebral tumour

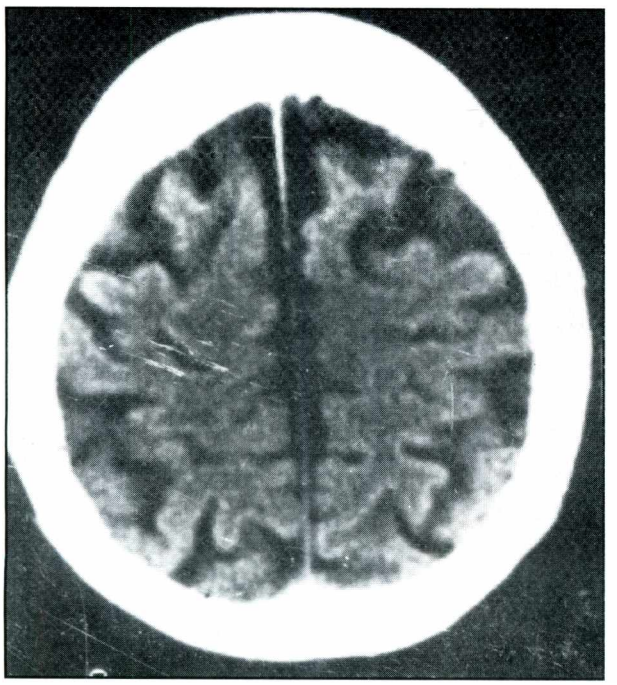

Fig. 3.44 : Cerebral atrophy

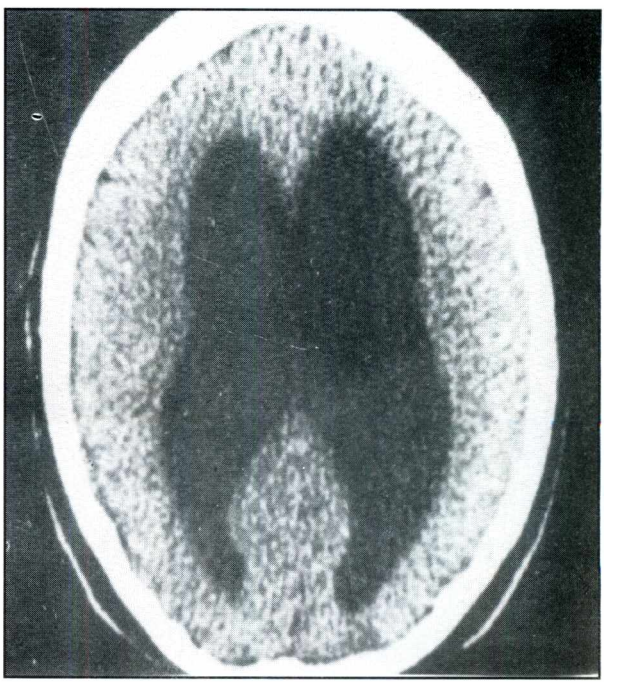

Fig. 3.45 : Hydrocephalus

6. Renal failure [hypercalcaemia, tubular damage due to excretion of light chains (Bence Jones proteinuria), hyperuricaemia, amyloid deposits, recurrent infections and infiltrations of the kidney by myeloma cells are the contributory factors],
7. Joint pain.
8. *Hyperviscosity syndrome* due to aggregation of IgM paraproteins (bleeding from gum or nose, thrombotic episodes, Raynaud's phenomenon, congestive heart failure, neurological manifestations like fatigue, malaise, paraesthesia, headache, fluctuating consciousness, mild impairment to abrupt loss of vision with 'string on sausages' appearance in ophthalmoscopy)—Plasmapheresis (and hydration) may give rapid relief.
9. Recurrent respiratory tract infection.
10. Amyloidosis (secondary).

Low-trauma fractures occur in :

1. Severe osteoporosis.
2. Metastatic bone disease.
4. Multiple myeloma.

M-band or M-component on electrophoretic strip :

1. Plasma cell neoplasms/disorders (mentioned above).
2. CML, CLL, lymphomas, breast carcinoma.
3. Non-neoplastic conditions : cirrhosis of liver, rheumatoid arthritis, sarcoidosis, myasthenia gravis.

What is "paraprotein' ?

Normal immunoglobulins are polyclonal but in multiple myeloma, plasma cells produce immunoglobulin of a single heavy and light chain, a 'monoclonal protein', which is known as paraprotein. These paraproteins are responsible for hyperviscosity, renal damage and amyloidosis (rare).

Confirmation of diagnosis :

Presence of at least two of the following confirms the diagnosis :

1. Monoclonal immunoglobulin, or light chains in blood or urine (by electrophoresis).
2. Bone marrow infiltration with malignant plasma cells (by bone marrow biopsy).
3. Osteolytic bone lesions (by radiology).

* Very high ESR (stormy ESR) and increased rouleaux formation make the pathologist suspicious.

** Plasma alkaline phosphatase level remains normal unless there is a fracture.

What is Bence Jones protein ?

The clone Which produces increased amount of intact monoclonal immunoglobulin, also synthesizes and secretes excess of free light chains that appear in the urine as monoclonal light chains, and is known as Bence Jones protein. Bence Jones proteinuria may also be found in primary amyloidosis, Waldenstrom's macroglobulinaemia and lymphoma.

Possible causes of osteosclerosis (bone turns absolutely whitish):

1. Fluorosis.
2. Secondary deposits from carcinoma of prostate (commonly), and rarely from breast, intestine or bronchus.
3. Hodgkin's disease (ivory vertebra), mastocytosis.
4. Marble bone disease (osteopetrosis or Albers-Schonberg disease).
5. Vitamin A or D toxicity (i.e., hypervitaminosis).
6. Diffuse idiopathic skeletal hyperostosis (Forrestier's disease).
7. Jaw in Paget's disease.
8. Renal osteodystrophy.
9. Osteopoikilosis.
10. Pycnodysostosis.

THALA9SAEMIA

(Fig. 3.27)

Description :

This is a lateral view of the skull which shows widening of diploic space (i.e., seperation of two tables) with faint outer table. The bony trabeculae are arranged perpendicular to the inner table giving rise to 'hair on end' appearance.

Orbital fossa, sinuses, pituitary fossa are within normal limit. No intracerebral calcification is noted.

Conclusion :

Chronic haemolytic anaemia, most probably thalassaemia major (commonest cause).

Radiological features of small bones of hand in thalassaemia :

1. Wide medullary cavity with coarse trabeculae and thinned out cortex (mosaic pattern).
2. Phalanges may loose their biconcave shape and ultimately become rectangular or biconvex.

[3. Long bones may also give rise to mosaic pattern].

Does thalassaemia minor produce these skeletal changes ?

Usually skeletal changes are absent in thalassaemia minor.

What are the other possible radiological changes in skull ?

1. Obliteration of paranasal air sinuses.
2. Slight prominence of frontal and maxillary bones.
3. Dental malposition.

* Very rarely, this type of skull X-ray picture is seen in severe iron deficiency anaemia.

MISCELLANEOUS SKULL X-RAYS

1. Raised intracranial tension—

a) Silver-beaten appearance (in children).
b) Sutural diastasis or seperation (in children).
c) Erosion of clinoid process.
d) Deepened sella turcica.
e) Enlargement of internal auditory meatus.

2. Acromegaly—

a) Thickened skull vault.
b) Enlarged sella turcica (i.e., pituitary fossa).
c) Large frontal and maxillary sinuses.
d) Prognathous mandible.

3. Hyperparathyroidism—spotty decalcification of skull.

4. Paget's disease—

a) Increase in size of the skull.
b) Marked thickening of bone.
c) Hazy opaque mottled appearance (moth-eaten appearance).

5. Intracranial calcification (on plain films)—

a) Primary tumours—glioma, meningioma, craniopharyngioma. Cerebral metastases do not give rise to calcification.

b) Vascular malformations—arteriovenous malformations, Sturge-Weber disease ('railroad track' or curvilinear calcification), cerebral aneurysm.

c) Multiple small discrete calcifications are produced by tuberous sclerosis, congenital toxoplasmosis and cytomegalovirus infection.

d) Old cerebral abscesses.

[F] X-RAY OF HANDS

SCURVY

(Fig. 3.28)

Description :

This is an AP and lateral view of lower part of the thigh, knee joint, leg and foot which reveals,

1. Pencilling of cortex of epiphysis or signet ring appearance of epiphysis (Wimberger's ring sign).
2. Increased density and widening at ends of tibia and fibula seen as white line (white line of Frankl).
3. Transverse band of radiolucency (black line) in the metaphysis, adjacent to white line of Frankl ('scurvy line' or Trummerfeld zone).
4. Ground-glass appearance of the shaft of diaphysis (uniform demineralisation).

* Other radiological features which are not evident in Fig. 3.28 are,

5. Angular lateral bony spurs of marginal fractures in the junction of diaphysis and metaphysis (Pelkan's sign).
6. Elevation of periosteum (as a result of subperiosteal haemorrhage which may rarely calcified).

Conclusion :

Scurvy.

Why the white line and black line are formed ?

a) White line of Frankl reflects impaired growth and continued deposition of calcium phosphate.

b) Scurvy line (black line) reflects failure of primary ossification.

* **Vitamin C deficiency (scurvy)** creates a condition where there is diminished production and maintenance of intracellular ground substance.

Differential diagnosis :

1. Traumatised child syndrome (absence of demineralisation of bone).
2. Heavy metal poisoning e.g., lead poisoning (no osteopenia, and absence of zone of translucency).

Clinical features of infantile scurvy :

Usually It is seen in between 6-18 months of age.

1. Fretful, listless and anorexic child who cries on being handled.
2. Reluctance to move the painful limbs (pseudoparalysis).
3. Symptoms due to haemorrhage :
   a) Subperiosteal—'Frog position' with thighs flexed as well as abducted, and knees flexed.
   b) Bleeding from gum; gum is swollen and spongy too.
   c) Bleeding into skin, mucous membrane; orbit—petechiae or proptosis.
   d) Beading of ribs as a result of posterior displacement of sternum—Scorbutic rosary (angular and sharp in contrast to rickety rosary which in semicircular and dome-shaped).
   e) Haematochezia, haematuria and intracranial haemorrhages are rarely seen.
4. Low grade pyrexia, pallor (anaemia) and extreme weakness.

* **In adults,** there is spongy-swollen-bleeding gums, perifollicular haemorrhages and hyperkeratotic papules, petechiae, ecchymoses, splinter haemorrhages, deformed 'cork-screw' hair projecting from hair follicle, poor wound healing, and muscle and joint haemorrhages.

** Manifestations of scurvy in gums are not seen in edentulous (teethless) persons.

Dose of vitamin C in scurvy :

250 mg of vitamin C should be given 3 times daily.

* Recommended daily intake of ascorbic acid for children and adults are respectively 20 mg and 50 mg.

Dietary sources of vitamin C :

Fresh citrus fruits are good sources. Amla, guava, orange, lemon, tomato, drumstick leaves, amaranth, papaya, cabbage, cauliflower are rich in ascorbic acid. Breast milk contains adequate amount of vitamin C.

RICKETS

(Fig. 3.29)

Description :

This skiagram shows AP view of lower parts of the forearm, wrist joint and part of the hand which reveals cupping, widening and fraying (saucer deformity) of the lower end of radius and ulna. There is generalised demineralisation of bones (osteopenia) present. The epiphysis appears indistinct and lacks a bony cortical margin. Broadening of the wrist (soft tissue shadow) is seen. There is increased distance between the distal end of radius-ulna and metacarpal bones because of non-calcification of rachitic metaphysis.

* Other radiological features not present in Fig. 3.29 are, cortical spurs from metaphysis growing towards displaced epiphysis (produces deformity), and green-stick fracture with bending and deformities.

Conclusion :

Rickets.

Radiological features of x-ray skull in rickets :

1. Delayed closure of anterior fontanelle.
2. Frontal and parietal bossing.
3. Quadrate skull.
4. Widening of sutures.
5. Late appearance of temporary teeth.

Differential diagnosis :

One can not differentiate among different causes of rickets by seeing the X-ray plate only. The X-ray plate of rickets (cupping and fraying) may be confused with metaphyseal dysostosis and hypophosphatasia.

Radiological signs of 'healing' rickets :

1. The radiological density is increased and roughness is diminished.
2. Epiphyseal cartilage becomes horizontal.
3. Horizontal 'Harrison's line' are seen in the lower end of diaphysis (initialy near the epiphysis).

Causes of rickets :

1. Deficiency of Vitamin D—Dietary deficiency, deficient endogenous synthesis (e.g., inadequate exposure to sunlight).
2. Gastrointestinal disturbances—Malabsorpsion (commonest cause in India), gastrectomy, hepatic disorders, chronic pancreatic insufficiency.
3. Disturbances of vitamin D metabolism—Hereditary and acquired (use of anticonvulsants e.g., phenytoin sodium or chronic renal failure).
4. Renal disorders—
   a) Renal tubular acidosis.
   b) Fanconi's syndrome.
   c) Familial hypophosphataemic rickets.
5. Primary defect in mineralisation of bone—
   a) Hypophosphatasia (deficiency of alkaline phosphatase).
   b) Treatment by fluoride.

6. Prolonged lactation and frequent pregnancies.
7. Non-renal acidosis—
   a) Ureterosigmoidostomy.
   b) Chronic acetazolamide or ammonium chloride intake.
8. Conditions with rapid bone formation e.g., osteopetrosis or marble bone disease.

Read 'Bedside Clinics in Medicine, Part I' for further details.

Table 9 : Biochemical features of common bone diseases

Diseases	Calcium	Phosphate	Alkaline phosphatase
Osteoporosis	N	N	N
Osteomalacia or rickets	*I* or N	1 or N	T
Hyperparathyroidism	T	*i*	N
Hypoparathyroidism	1	T	N
Secondary deposits	T	N	T
Multiple myeloma	T	N	N
Paget's disease	N	N	t

* Alkaline phosphatase is increased in hyperparathyroidism with significant bone involvement, and in multiple myeloma with healing fracture of bones (as osteoblastic activity tries to repair fracture).

MISCELLANEOUS HAND X-RAYS

1. Rheumatoid arthritis—

a) Periarticular osteopenia.
b) Loss of articular cartilage (4. of joint space).
c) Periarticular bone erosions.
d) Subluxation of the joints (or ankylosis).
e) Marked osteoporosis may be evident.
f) Varying degree of deformities.

* In the hand, mainly the PIP and MCP joints are affected.

2. Osteoarthritis—

a) Arthritis of the thumb, i.e., involvement of 1st carpometacarpal joint (the joint space is 4.).
b) Hard bony nodules are seen over the dorsal aspect of DIP (Heberden's node) and PIP (Bouchard's node).

3. Chronic haemolytic anaemia—read radiology of 'Thalassaemia'.

4. Acromegaly—

a) The hand is large.
b) Tufting of terminal phalanges, i.e., 'arrow-head appearance'.
c) Widening of MCP joints spaces due to overgrowth of articular cartilage.

5. Resorption of terminal phalanges—

Subperiosteal bone resorption in terminal phalanx is characteristic of :

a) Scleroderma (may have soft tissue calcification)
b) Leprosy.
c) Hyperparathyroidism (rarely may reveal arterial calcification).
d) Acromegoly.

* The fingers may mimick clubbing (known as pseudoclubbing).

6. Gout—

a) Soft tissue swelling (due to underlying arthritis)—periarticular.

b) Typical well-defined punched-out erosion with an overhanging edge over the joints (Martel's sign).

c) Tophi—large soft tissue lumps (due to deposits of monosodium urate crystals) are seen; may show calcification.

Short description of Fig. 3.30 to Fig. 3.33 :

Fig. 3.30 ; This is a skiagram of the chest, PA view which shows bilateral upper and mid-zonal fibrosis (right > left) with cavity formations. Lower zones of the lung reveal evidence of compensatory emphysema. The costophrenic angles are clear.

Impression — Fibro-cavitary lesion of the lung probably resulting from tuberculosis.

Fig. 3.31 : The X-ray plate reveals skiagram of the chest, PA view demonstrating elevated right dome of diaphragm. The pulmonary parenchyma, costophrenic angles, cardiac silhouette and mediastinum are within normal limit.

Inpression — Elevated right dome of diaphragm (the possibilities are mentioned in page 93).

Fig. 3.32 : This is a X-ray picture showing myelogram of a patient with right anterior oblique view of the chest. There is cord compression at upper thoracic level.

Impression — Myelogram demonstrating cord compression (the patient will have paraparesis/ paraplegia).

Fig. 3.33 : This is AP view of lower part of radius and ulna, carpals, metacarpals and phalanges of both hands featuring 'subperiosteal new bone formation' at lower end of both radius.

Impression — Hypertrophic osteoarthropathy (i.e., Grade IV clubbing; differential diagnosis closely resembles thyroid acropachy).

[G] A SYNOPSIS OF COMPUTED TOMOGRAPHY (CT) SCAN

The advent of X-ray computed tomography (CT) in the early 1970s was a major milestone, since it has revolutionized the ability to visualize the inside of a patient's body. In 1979, the Nobel Prize for the invention of CT scan was shared by **Godfrey Hounsfield,** a British engineer and Allen Cormack, a physicist. The CT came in 1970s, magnetic resonance imaging (MRI) in 1980s, and positron emission tomography (PET) and single-photon emission computed tomography (SPECT) thereafter. CT scanning provides a very sensitive method for evaluating suspected lesions in the central nervous system. The parallel and thinly collimated X-ray beam traverse synchronously across a slice of brain tissue between 2 mm and 13 mm thick; the X-irradiation is computer processed and a value (Hounsfield number) is given to its density [e.g., air (black) = - 1000 units, water (less black than air) = 0, and bone (white) = + 1000). The difference in density (i.e., X-ray attenuation) makes it possible to differentiate between extravasated blood, cerebral oedema, space occupying lesion (SOL) or infarction. Contrast enhancement by intravenous iodinated contrast media helps to diagnose lesions with increased blood supply (e.g., angioma, some SOL) and cerebral oedema. The irradiation involved in CT and MRI scan is negligible.

Table 10 : Attenuation values of different tissues

Tissue	Hounsfield units
Air	-1000
Fat	upto-100
Fluid	0-20
Soft tissue	20-100
White matter	30-35
Grey matter	35-45
Acute haemorrhage	55-75
Calcification	90-200
Bone	1000

CT scan of brain and spinal cord demonstrates cerebral haemorrhage, cerebral Infarction, intracranial SOL, subarachnoid haemorrhage, 'mass effect' by lateral shifting of midline structures, hydrocephalus, subdural and epidural haematoma, calcification within a lesion, cerebral atrophy, fracture of skull or vertebra, spinal tumours (CT-myelography) etc.

In MRI scan, protons are imaged with radiofrequency waves, and $T_{1(}$ T_2 and other sequence-weighted images are recorded. One of the advantages of MRI scan is that it involves no ionising radiation, and the other is that it distinguishes between white and grey matter in the brain and spinal cord. The intravenous contrast used in MRI scan contains gadolinium. Following are the situations where MRI is specially useful for evaluation :

1. Demyelinating disease (e.g., plaques of multiple sclerosis).
2. Posterior fossa tumours or vascular lesions.
3. Dementia.
4. Pituitary imaging.
5. Leucodys trophies.
6. MR angiography for arteriovenous malformations.
7. Myelopathy (spinal cord, spinal canal and nerve roots are imaged clearly) e.g., prolapsed intervertebral disc, syringomyelia, vascular malformations.
8. Imaging musculo-skeletal soft tissue diseases or injuries, e.g., shoulder or knee pain.
9. AIDS-associated diseases of brain.
11. Visual disturbances — for imaging beyond retina.

* MRI scan is very helpful in detecting hypothalamic and cranial nerve lesions, white matter lesion and lesion in brainstem.

CT and MRI scan are very safe except the contrast-related systemic reactions experienced by a minority of patients. MRI is costlier than CT.and more time-consuming. The common contraindications of MRI scan are :

1. Patients having pacemaker.
2. Bullet injury (bullets inside the body),
3. Cochlear implant,
4. Along with splint and traction.
5. Tattoed eye-liner, and
6. Any ferro-magnetic clip (e.g., clipping cerebral aneurysm) present within the body. Claustrophobia is a relative contraindication.

CT scan of thorax gives an excellent anatomic details of hilum, pulmonary parenchyma and pleura. Coventionally thick slices (10 mm) are taken. High resolution computed tomography (HRCT) produces thinner slices (1.5 mm). HRCT helps in diagnosis of bronchiectasis, insterstitial lung disease, infiltrative diseases of lung, pulmonary neoplasms, asbestos-related pleural plaques, and planning for radiotherapy.

CT scan of abdomen delineates liver, spleen, gall bladder, kidney, aorta, stomach (barium-filled), pancreas and spine (vertebra). It is helpful in diagnosis of pancreatic diseases, hepatic neoplasms, malignant deposits, ascites, assessment of vascularity of tumour and tumour staging.

In the examination, mount the CT-plate correctly in the view-box (by seeing the patient's name and other write-up) and say : 'it is the CT scan plate of brain showing different cut sections..... and there is a big hyperdense shadow in right parieto-temporal region..... ; the final dignosis is.....'. Try to comment on skull bone (e.g., any fracture), ventricles (e.g., full with blood or 'cupping' seen), midline shift, brain parenchyma etc.

The CT scan plates are described below :

Fig. 3.34 : This is a CT scan of brain which reveals a big intracerebral bleed/haematoma (white) in right cerebral hemisphere with perilesional cerebral oedema (black). Mass effect with midline shift to the left is noted. Choroid plexus calcification is seen bilaterally. The skull bone is intact.

N.B. : The patient will have left-sided complete hemiplegia. It is a patient of cerebral haemorrhage.

Fig. 3.35 : This is a CT scan of brain showing paraventricular triangular hypodense lesion of cerebral infarction on the right hemisphere.

N.B. : the patient will have left-sided complete hemiplegia, and is due to cerebral thrombosis, cerebral embolism and vasculitis (rare).

Fig. 3.36 : This is a CT scan of brain which shows bilateral basal ganglia calcification (white). Calcification in other parts of brain is also seen.

N.B. : common causes of *basal ganglia calcification* are : idiopathic (commonest), familial, hypoparathyroidism, pseudohypoparathyroidism, carbon monoxide poisoning (attempted hanging) and toxoplasmosis (congenital).

Fig. 3.37 : The CT scan of abdomen demonstrates liver, spleen, aorta, stomach (barium-filled) and spine. The left kidney has a mass in its upper pole though the right kidney is not properly visualized; rather a big mass (marked by radiologist) is seen in the right side. Considering the facts, it seems to be a case of bilateral adrenal (suprarenal) tumour.

N.B. : This is a CT scan picture of adrenal tuberculosis. The usual mode of presentation is Addison's disease (i.e., hypofunction of adrenal cortex).

Fig. 3.38 : Contrast-enhanced CT scan of brain (CECT) showing an isodense mass with ring enhancement in the left periventricular region with enlargement of ventricles. This is a patient with tuberculoma in brain.

Fig. 3.39 : CECT scan of brain reveals multiple large 'ring lesions'. This is a case of multiple cerebral abscesses in the white matter.

Fig. 3.40 : The non-contrast-enhanced CT scan of brain showing a peripheral high-density biconvex blood collection. This patient suffers from subacute epidural haematoma.

Fig. 3.41 : CECT scan of brain shows two hyperdense masses in the right posterior temporal and occipital lobes. The lesions enhance homogeneously; perilesional oedema and a slight midline shift to the left is seem. This is a patient of cerebral metastases from carcinoma of colon.

Fig. 3.42 : This is an axial non-contrast-enhanced CT scan of brain showing a peripheral high density extracerebral collection within the subdural space which compresses the left cerebral hemisphere; there is a midline shift. This is a patient of acute subdural haematoma.

Fig. 3.43 : CECT scan of brain demonstrates a well-marginated cyst with central mass in the left cerebral hemisphere; there is midline shift towards right. This is a case of intracerebral tumour (astrocytoma).

Fig. 3.44 ; Axial CT sections of brain shows enlargement of cortical sulci over the convexities. This is the CT scan brain of a 83-years old man having cerebral (cortical) atrophy.

Fig. 3.45 : This is .a CT scan of brain showing symmetrical enlargement (dilatation) of the entire ventricular system. The patient is suffering from communicating hydrocephalus.

* CT scan feature of meningitis is 'diffuse meningeal enhancement'.

** *'Ring lesion'* (single or multiple; outer white ring with inner black shadow) in brain is seen in :

1. Tuberculoma.
2. N eurocysticercosis.
3. Brain abscess.
4. Cerebral metastasis.
5. Venous infarcts.
6. Others—Fungal infection, glioma, demyelinating disorders, toxoplasma, resolving haematoma. CNS lymphoma*etc..

In CT scan, white shadow means hyperdense lesion and black shadow means hypodense lesion.

N.B. : One has to remember that imaging modalities of choice during pregnancy are ultrasound and MRI. In disorders of musculoskeletal system, investigation of choice is MRI.

CHAPTER IV : ELECTROCARDIOGRAPHY

Introduction and basic principles :

The graphic recording of the electrical activity of the heart is known as electrocardiogram or ECG. The ECG is recorded by applying electrodes to different parts of the body and connecting those electrodes to an electrocardiographic apparatus. It is inexpensive, easily accessible, simple to interpret, and provides wealth of information about cardiac status of the patient.

The specially prepared ECG paper (usually pink or blue in colour) is made of small and large squares. Five small squares make one large square. The horizontal and vertical lines are present at 1 mm interval. Heavier lines of large squares are present every 5 mm. Time is measured along the horizontal lines; **one small square is equal to 0.04 second in duration,** and one large square is equal to 0.2 second (i.e., 0.04 x 5). Voltage is measured along the vertical lines and is expressed in mm, and **10 mm is equal to 1 mV** (the usual calibration in ECG is a 1 mV signal that produces a 10 mm deflection). The ECG **paper moves at a speed of 25 mm/second,** i.e., 1500 mm/minute, i.e., 1500 small squares (so called 300 large squares) are covered in 1 minute and thus to calculate the heart rate, one should divide 1500 by the number of small squares present in between two heart beats (R-R interval).

Any deflection above the baseline (isoelectric line) is known as positive deflection and that below the baseline is regarded as negative deflection.

A normal heart has P, Q, R, S, T and U waves (> 5 mm) in ECG. Small waves of < 5 mm in height are designated by small letters (q, r, s).

P wave — Normally upright and signifies atrial depolarisation; precedes the QRS complex.

Q wave — The initial negative deflection that precedes the R wave.

R wave — The first positive deflection of the QRS complex, i.e., ventricular depolarisation.

S wave — The negative deflection of QRS complex that follows R wave.

T wave — Normally upright and signifies ventricular repolarisation; follows S wave.

U wave — Positive deflection that follows T wave and is probably due to slow repolarisation of interventricular (Purkinje) conduction system.

R-R interval — Distance between two successive R waves. It helps in counting the heart rate i.e., R-R interval 15 mm = heart rate 100/minute (1500/15), and R-R interval 25 mm = heart rate 60/minute (1500/25).

P-R interval — It is the time taken for an impulse to traverse from the SA node to the ventricles. This is the period of conduction pause at AV node. It is measured from the beginning of the P wave to the onset of the QRS complex (more accurately P-Q interval) and is normally in the range of 0.12-0.20 second. P-R interval must be correlated with the heart rate.

Q-T interval — It is the time taken for the total ventricular events (i.e., depolarisation as well as repolarisation) and is measured from the beginning of the Q wave to the end of the T wave. The normal Q-T interval is usually 0.35 to 0.44 second.

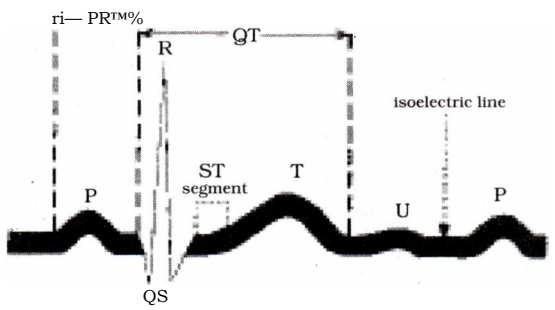

Fig. 4.1 : Diagram of ECG complexes, segments and intervals

Uses of ECG in clinical practice :

1. Hypertrophy of cardiac chambers, myocardial isehaemia or infarction, arrhythmias, different heart blocks, pericardial diseases.
2. Effects of drugs and electrolytes on the heart.
3. Evaluation of efficacy of angioplasty or by-pass surgery.
4. Holter monitoring and stress ECG.

Leads in surface BCG :

Conventionally, 12 leads ECG are used in day to day practice (I, II, III, avR, aVL, aVF, $V_{1(j)}$). The right leg electrode and the lead act as a ground wire.

Bipolar standard limb leads — Lead I, Lead II, Lead III.

Unipolar (augmented) limb leads — aVR, aVL, aVF.

Unipolar precordial or chest leads — V_t, V_2, V , V_4, V_s, V_6.

Lead I, II, III, aVR, aVL, aVF reflect electrical activity of heart in the frontal plane while lead V, to V_6 reflect the same in the horizontal plane. Each standard lead measures the potential differences between two extremity electrodes : lead I = left arm-right arm voltages, lead II = left leg-right arm, and lead III = left leg-left arm.

Besides these leads, oesophageal leads (E) are there to record magnified atrial complexes and to explore the posterior surface of left ventricle (introduced through nasal catheter). Unipolar intracardiac leads (recorded from right atrium or right ventricle) may be used for clarification of different types of arrhythmias.

Though in routine screening of ECG '12-leads' are employed, in following progress of arrhythmia a 'long lead II' or V, is needed, or it is wise to explore higher (e.g., $3Vj_9$) and more lateral areas of precordium (e.g., V_{3R}, V_{4R}) in a doubtful case of acute myocardial infarction. The common precordial positions of the chest leads are as follows :

Vj : 4th intercostal space (ICS) at the right sternal border

V_2 : 4th ICS at the left sternal border

V_3 : Equidistant from V_2 and V_4 leads

V_4 : 5th ICS in the left MCL (midclavicular line). All the subsequent leads ($V_{5\text{–}9}$) are placed in the same horizontal plane (i.e., in left 5th ICS) as. V_4

V_5 : Anterior axillary line

V_6 : Midaxillary line

V_7 : Posterior axillary line

V_8 : Posterior scapular line

V_9 : Left border of the spine

V_3R-$_9R$: Taken on the right chest in the same location as left-sided leads V_{39}; V_{2R} is therefore same as V

$3V,_9$: Taken one intercostal space higher than $V,_9$; these are 3rd interspace leads. Similarly 2nd ICS and 6th ICS leads will be respectively $2V,_9$ and $6V,_9$

VE : Taken over ensiform cartilage

* *Lead aVR* is usually oriented to the cavity of the heart and thus deflections of P-QRST are normally negative in this lead.

Avis *deviation :*

A 'hexaxial reference system' using standard leads and unipolar limb leads, deduced from **'Einthoven triangle'** reflects the mean QRS vector as follows :

Normal axis lies between -30° and +100°

Left axis deviation between -30° and -90°

Right axis deviation between +100° and ±180°

Indeterminate axis (or extreme right axis deviation) between -90° and ± 180°

* Axis lying between 0° to -30° is often known as mild left axis deviation.

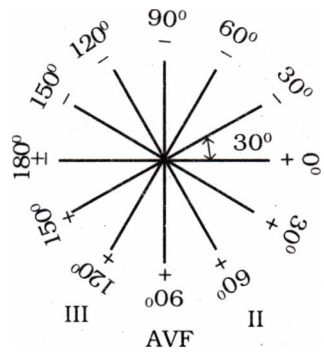

Fig. 4.2 : Hexaxial reference system

Determination of axis :

The positive pole of lead I is considered as 0° and the negative pole of lead I as ±180°; the positive pole of aW is designated as +90° and the negative pole of aVF as -90°. The QRS complexes (positive or negative deflection) is marked or plotted in lead I and aVF accordingly, and the axis is determined accurately (lead I and aVF are perpendicular to each other, and are routinely used to calculate the axis in clinical practice). One may consider lead II and aVL, or lead III and aVR for axis calculation. Actually, the net positive or net negative QRS deflection in lead I and lead aVF is calculated (by subtracting the smaller deflection above or below the isoelectric line, from the larger deflection) and finally plotted for axis determination. One example is given below for better understanding :

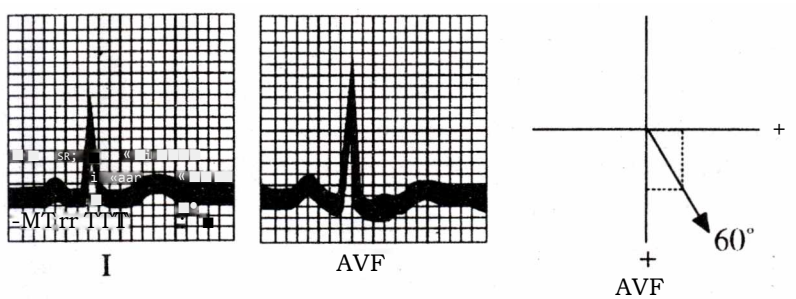

Fig. 4.3 : Diagrammatic illustration of axis determination. The QRS axis is approximately +60°

Causes of left axis deviation —

1. Left ventricular hypertrophy (LVH).
2. Left bundle branch block.
3. Left anterior hemiblock.
4. W-P-W syndrome.
5. Hyperkalaemia.
6. Endocardial cushion defect e.g., ostium primum type ASD.
7. Hypertrophic cardiomyopathy.
8. Mechanical shifts e.g., expiration, obesity, high diaphragm resulting from pregnancy, ascites. abdominal tumours.

Causes of right axis deviation —

1. Right ventricular hypertrophy (RVH), right ventricular strain.
2. Right bundle branch block.
3. Left posterior hemiblock.
4. Normal variation; infants.
5. During inspiration; thin built.
6. Dextrocardia.
7. Emphysema and cor pulmonale.
8. Ostium secundum type ASD, Fallot's tetralogy.

Position of the heart: *

As anatomical rotation is rare, rotation of the heart refers to rotation of the electrical forces. Rotation of the heart may occur on either the antero-posterior axis (i.e., frontal plane) or the oblique axis (i.e., horizontal plane).

Rotation on the antero-posterior axis or **lie of the heart** is diagnosed by axis deviation :

a) Horizontal (-30°)—aVL shows major upward deflection while aVF shows major downward deflection of QRS complex.

b) Semihorizontal (0°)

c) Intermediate (+30°)—both aVL and aVF show major upward deflection (it is the normal position of heart).

d) Semivertical (+60°), and

e) Vertical (+90°)—aVF shows major upward deflection and aVL shows major downward deflection.

Rotation (electrical) on the oblique axis is diagnosed by the precordial leads :

a) Clockwise rotation — Persisting S waves in V_5 and V_6 (i.e., rS complexes in V_5 and V_g).

b) Anti-clockwise rotation — Appearance of left ventricular complexes as early as V_2 (i.e., qR complexes in V_2, V_3).

* Clockwise or anti-clockwise rotation is considered when the heart is viewed through the diaphragm.

Technique of reading or reporting ECG :

1. Standardisation
2. Voltage
3. Heart rate
4. Rhythm
5. Axis
6. Lie and rotation
7. P Wave
8. P-R interval
9. QRS complex
10. ST segment
11. T wave
12. U Wave
13. Q-T duration
14. Final diagnosis or conclusion

* In arrhythmia, study of 'long strip' of lead II is necessary.

** **In the examination,** hold the ECG strip correctly (put your left hand over lead I and right hand over V_6; some small printing from ECG paper manufacturer will help you to select the upper and lower borders of ECG strip) and read the ECG in this way : 'it is the 12-lead strip of electrocardiogram showing normal standardisation..... voltage .....heart rate ..... rhythm ..... axis..... and the final diagnosis is..... '.

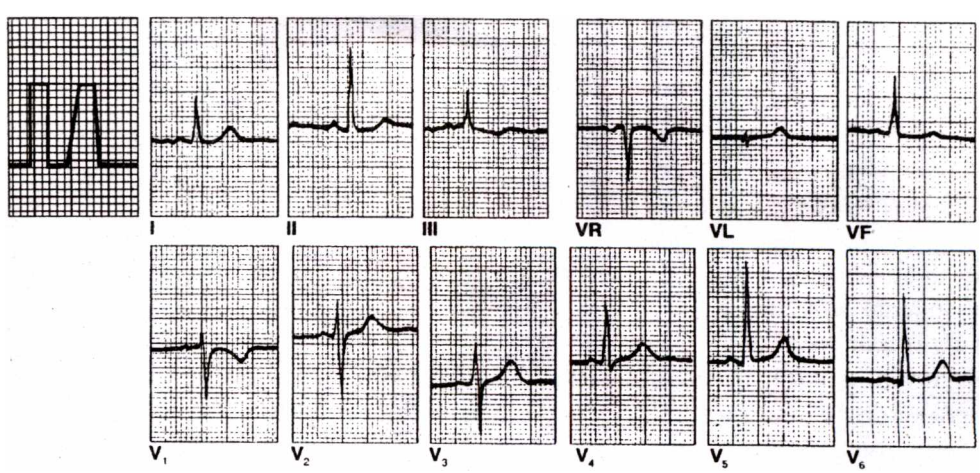

Fig.4.4 : Normal electrocardiogram

DIFFERENT WAVES, COMPLEXES AND INTERVALS :

P WAVE

P wave signifies atrial activity. This is best visualised in lead II and V_r and normally it is upright in lead I, II, aVF and $V_{3\ 6}$. P wave is inverted in aVR and frequently in V_r Normally it does not exceed 2.5 mm in height and 0.12 second in duration (i.e., horizontally).

The abnormalities are :

1. Wide and notched (also known as **P-mitrale;** as mitral valve disease is a common cause of this abnormality)—Indicates left atrial hypertrophy. Notching is considered significant when the distance between two peaks exceeds 0.04 second.

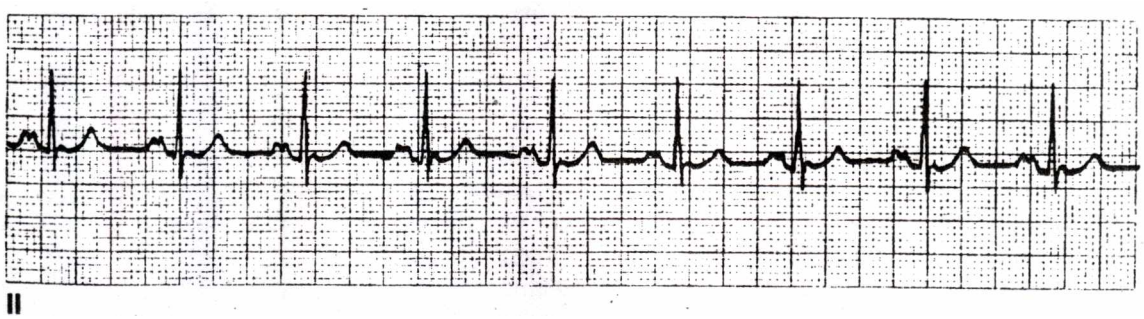

Fig. 4.5 A : P-mitrale

2. Tall and peaked (also known as **P-pulmonale;** as severe pulmonary disease is a common cause of this abnormality)—Indicates right atrial hypertrophy when the height of P wave is greater than 2.5 mm.

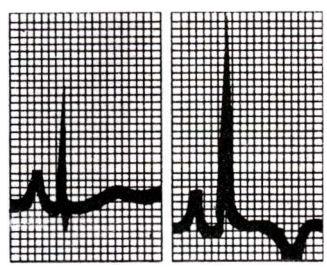

Fig. 4.5 B : P-pulmonale

3. Absent—In atrial fibrillation, nodal rhythm, SA block and sometimes in hyperkalaemia.
4. Inverted (in lead I)—In wrong electrode placement by the technician, dextrocardia or possibly due to retrograde atrial activation (e.g., nodal rhythm).
5. Diphasic or biphasic P wave—The P wave in V, may be normally biphasic with a shallow, terminal negative component. If the terminal negative component is prominent, it indicates left atrial hypertrophy.
6. Deformed—In atrial fibrillation, P waves are replaced by numerous small, rapid, irregular fibrillation (f) waves. In atrial flutter, P waves are replaced by flutter (F) waves which give the baseline a corrugated or saw-toothed appearance.

Summary :

Right atrial enlargement — P-pulmonale in lead II and lead V_l

Left atrial enlargement — P-mitrale in lead II, and/or diphasic P wave with prominent negative terminal component in lead

* Common causes of atrial hypertrophy/enlargement are :

Mitral or tricuspid stenosis, secondary to LVH (develops left atrial enlargement) or RVH (develops right atrial enlargement), secondary to pulmonary hypertension or cor pulmonale, mitral incompetence, left atrial myxoma etc.

QRS COMPLEX

This complex comprises of Q, R and S waves, and is produced as a result of ventricular depolarisation (i.e., septal activation).

(A) Q wave — It signifies depolarisation of the ventricular septum from left to right side.

(B) R wave — It signifies depolarisation of the ventricles. Initially, the anteroseptal portion is depolarised followed by the major muscle mass of ventricles.

(C) S wave — It denotes depolarisation of the posterobasal part of the left ventricle, pulmonary conus and the superiormost part of the ventricular septum.

The height of QRS complex is different in different leads. The height also depends on the position of the heart and the degree of abnormality.

Voltage criteria of QRS complex :

a) Low voltage — When the QRS complex is < 5 mm (i.e., 5 small squares) in limb leads visiting Lead I, II, III, aVR, aVL and aVF, and <10 mm (i.e., 10 small squares) in precordial leads visiting V_1 to V_6, it is designated as low voltage. Common causes are,

1. Incorrect standardisation by the technician.
2. Obesity or thick chest wall.
3. Emphysema.
4. Pericardial effusion or chronic constrictive pericarditis.
5. Myxoedema.
6. Panhypopituitarism.

b) High voltage — Tall QRS complexes usually signifies ventricular hypertrophy (criteria for LVH and RVH are described afterwards).



Fig. 4.6 : Low voltage in a case of myxoedema

T WAVE

It is a dome-shaped wave with two asymmetrical limbs, and is produced as a result of ventricular repolarisation. It is normally upright, except in leads III, aVR, V, and V_2.

The abnormalities are :

1. Tall peaked T wave — In hyperkalaemia, acute subendocardial ischaemia or infarction, often in true posterior wall myocardial infarction.

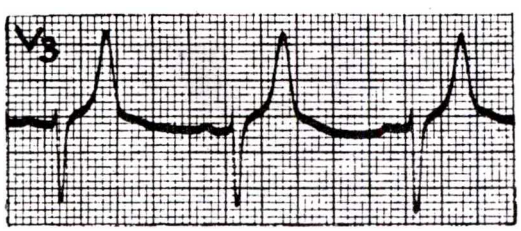

Fig. 4.7 : Tall T wave

2. Low or Inverted T wave — Indicates coronary heart disease or myocardial ischaemia, ventricular 'strain' pattern, constrictive pericarditis, hypokalaemia, CVA (subarachnoid haemorrhage). In myocardial infarction, two limbs of the T wave may be symmetrical.

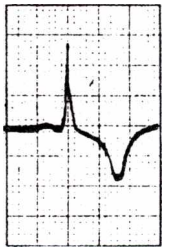

V_5

Fig. 4.8 : Inverted T wave

3. Flat T wave — In thick chest wall, emphysema, myocardial ischaemia, myocarditis, pericardial effusion, myxoedema and hypokalaemia.

* Following the T-wave there is a brief 'isoelectric period' of 0.04 sec.

U WAVE

It is usually a positive deflection which comes after T wave and precedes the P wave of the next cycle. It is possibly produced as a result of slow repolarisation of the Purkinje's fibres, the interventricular septum and the papillary muscles. Many a time, the U wave is not evident in ECG. It is usually best seen in lead V_2 to V_4.

The abnormalities are :

1. Prominent U wave — In hypokalaemia.
2. Inverted U wave (i.e., U wave which is opposite in direction to the T wave) — In coronary heart disease (acute myocardial infarction), hypertensive heart disease, acute pulmonary thromboembolism, intracerebral haemorrhage.

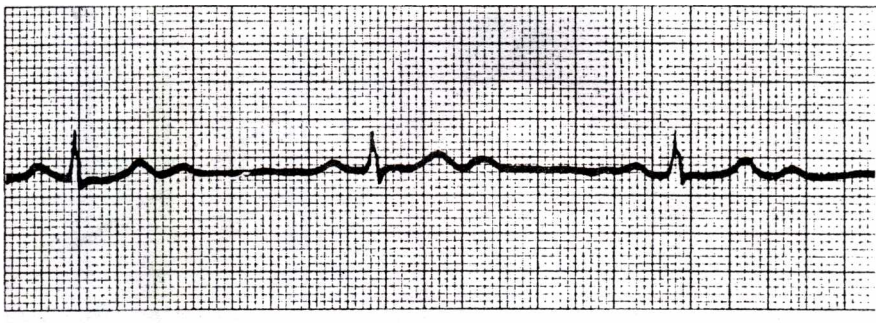

Fig. 4.9 : U wave in hypokalaemia

ST SEGMENT

The ST segment measurement is taken from the end of the QRS complex to the beginning of the T wave. Though usually 'isoelectric', it may vary from -0.5 mm (depressed) to +2 mm (elevated) in precordial leads. The diagnosis of depressed or elevated ST segment is evaluated in comparison to the **T-P segment** (i.e., the base line between the termination of the T wave and the begenning of the P wave of the next cycle). The point where the QRS complex ends and the ST segment begins is known as **'J point',** which is an important point for evaluation of ST segment deviation. ST segment represents the time interval between ventricular depolarisation and repolarisation.

The abnormalities are :

1. Elevated (with convexity upwards) — In acute myocardial infarction, coronary spasm, LV aneurysm.
2. Elevated (with concavity upwards) — In acute pericarditis.
3. Depressed (oblique, plane or sagging) — In coronary artery disease (angina pectoris).
4. Depressed with mirror-image of a 'correction mark'—In digitalis effect.
5. Depressed with upward convexity — In strain pattern of ventricular hypertrophy.

ST Segment deviation :

a) ST elevation—
   1. Acute myocardial infarction.
   2. Prinzmetal's angina.
   3. Pericarditis.
   4. Ventricular aneurysm.

b) ST depression—
   1. Angina pectoris.
   2. Acute subendocardial infarction.
   3. Myocarditis.
   4. Ventricular hypertrophy with strain.
   5. Digitalis effect.
   6. CVA

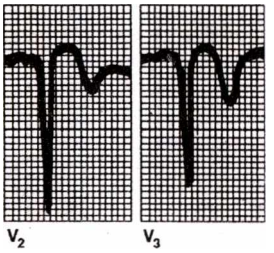

Fig. 4.10 : Acute myocardial infarction with ST elevation (convexity upwards)

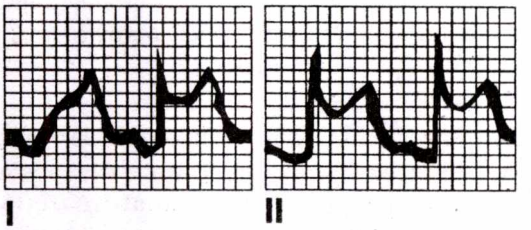

Fig. 4.11 : Acute pericarditis with ST elevation (convexity upwards)

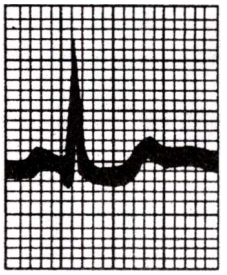

Fig. 4.12 : Sagging depression

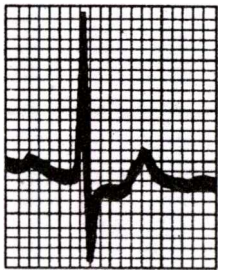

Fig. 4.13 : Plane depression

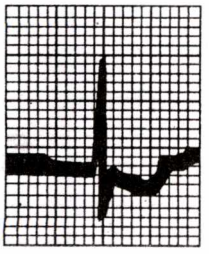

Fig. 4.14 : Digitalis ejfect

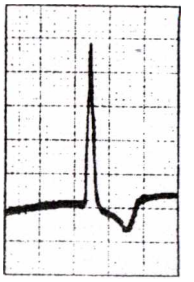

Fig. 4.15 : Strain pattern

P-P AND R-R INTERVAL

The P-P interval is the distance between two successive P waves, and the R-R interval is the distance between two successive R waves. In *sinus rhythm,* the P-P and R-R intervals are same in duration. In heart blocks, some of the P waves are conducted while some are blocked and thus the P-P interval is different from R-R interval. Atrial rate is reflected in P-P interval and so the ventricular rate in R-R interval.

Calculation of heart rate :

If the rhythm is *regular,* count the small squares present between two consecutive P waves or R waves, and then divide 1500 by that number. For example, if the R-R or P-P interval becomes 20 small squares (i.e., 20 mm), the heart rate with be 1500 + 20 = 75 / minute. In a case of complete heart block, the R-R interval (not the P-P interval) will help in calculation of heart rate (i.e., ventricular rate).

If the rhythm is *irregular,* select consecutive 20 large squares (i.e., 0.2 x 20 = 4 second) in long strip of lead II, and count the number of R waves (or QRS complex) present in the time span of 4 second. Multiply the number of R waves by 15 to get the number of beats/minute or heart rate.

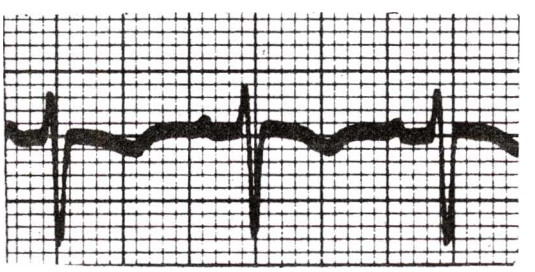

Fig. 4.16 : Patient with heart rate 100 / minute (1500/15)

P-RINTERVAL

It is measured from the beginning of the P wave to the beginning of the QRS complex. The normal P-R interval is 0.12-0.20 second; the duration decreases with increase in heart rate. It is an indirect measurement of the time interval between atrial and ventricular depolarisation, and reflects intra-atrial, AV nodal and His-Purkinje conduction.

The abnormalities are :

1. Increased P-R interval (synonymous with 1° heart block) — In acute rheumatic fever, ischaemic heart disease, after digitalis or (3-blocker therapy, in some cases of hyperthyroidism, ASD and as rare normal variation.

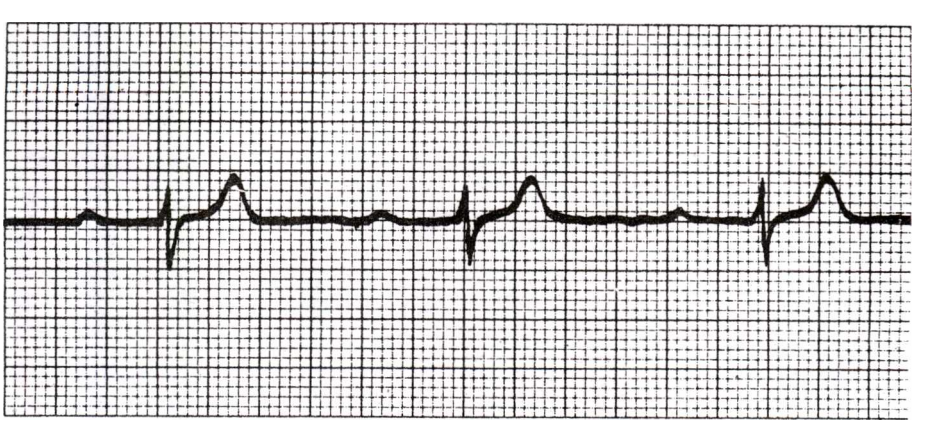

Fig. 4.17 : Increased P-R interval. Heart rate is 50/minute

2. Shortened P-R interval — In Wolff-Parkinson-White syndrome, AV nodal rhythm, low atrial rhythm.

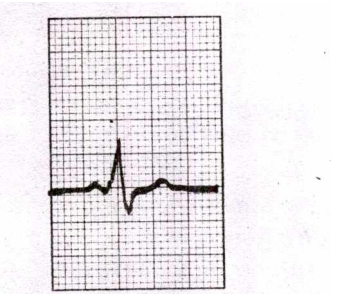

Fig. 4.18 : Shortened P-R interval

3. Progressive prolongation of P-R interval is found in Wenckebach's 2° heart block.
4. Variable P-R intervals are found in wandering atrial pacemaker or multifocal atrial tachycardia.

QRS INTERVAL

It measures the total ventricular depolarisation time. The QRS interval is measured from the beginning of the Q wave (or, consider R wave if no Q wave is visible) to the termination of the S wave. The upper limit of QRS interval is 0.10 second.

If the QRS interval goes above 0.12 second, bundle branch block or intraventricular conduction defect is considered.

Prolongation of the QRS interval >0.12 second = Complete bundle branch block, and if

The QRS interval is < 0.12 second = Incomplete bundle branch block.

* *Intrinsicoid deflection or ventricular activation time (VAT)* is the time taken for an impulse to traverse the myocardium from its endocardial to epicardial surface. Measurement is taken from the beginning of the Q wave to the peak of the R wave. The VAT should not exceed 0.03 second in V_{t2} and 0.05 second in v_M-

Q-T INTERVAL

It is measured from the beginning of the Q wave to the end of the T wave. It measures the total duration of ventricular systole. The Q-T interval should be corrected (Q -Tc) as it changes with the heart rate. Though Q -T interval varies from 0.35 to 0.44 second, the Q -Tc should be :

$$\text{Q-Tc} = \frac{\text{Q-T interval (in second)}}{\text{V R-R interval (in second)}} \simeq$$

This is *Bazett's formula* (rate related) and according to this formula, Q-Tc is < 0.44 second.

The abnormalities are :

1. Prolonged Q-T interval — Hypocalcaemia, hypokalaemia, acute rheumatic carditis, acute myocardial infarction, myocarditis of any aetiology, quinidine or procainamide therapy, CVA, hypothermia and congestive cardiac failure.
2. Shortened Q-T interval — Hypercalcaemia, digitalis therapy, vagal stimulation and hyperthermia.

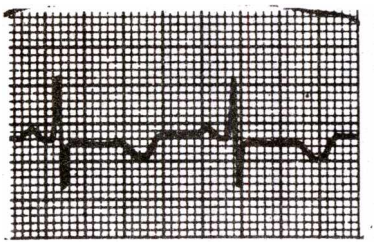

Fig. 4.19 : Prolonged Q-T interval

RHYTHM

Often a glance to the ECG recording is enough to say whether the rhythm is regular or irregular.

1. Regular (sinus rhythm) — Sino-atrial, A-V nodal or idioventricular; the normal rhythm is regular.
2. Irregular (arrhythmia or dysrrhythmia) — Whether any definite pattern is present (i.e., beats grouped in pairs or every fourth beat is dropped) or not (i.e., totally irregular or with erratic irregularity like atrial fibrillation).

Measure the R-R or P-P interval and compare with corresponding two R or P waves.

AVOIDANCE OF TECHNICAL DIFFICULTIES BEFORE RECORDING

To avoid poor technical records, follow these instructions :

1. Patient should be explained the procedure to allay anxiety. Patient should be totally relaxed. A comfortable bed is necessary. Shivering or tremor should be avoided.
2. Good contact between the skin and the electrode is a must. Electrolyte jelly should be rubbed properly in the skin.
3. The patient and the ECG machine should be properly grounded to avoid AC interference.
4. Remove all electronic or magnetic equipments, or metal from the patient's body.
5. Correct standardisaton (see below).

STANDARDISATION

Normal coventional standardisation is 1 mV which will produce a upward deflection of 10 mm. Incorrect standardisation will lead to faulty interpretation as a result of incorrect voltage of the complexes (e.g., overstandardisation will unnecesarily diagnose ventricular hypertrophy and understandardisation will incorrectly diagnose a normal person as hypothyroid). Furthermore, the stylus of the ECG machine should have a correct pressure on the recording edge; otherwise the recording stylus will not move properly. Half standardisation is done in case of very high voltage (e.g., ventricular hypertrophy) and double standardisation is done in very low voltage (e.g., myxoedema).

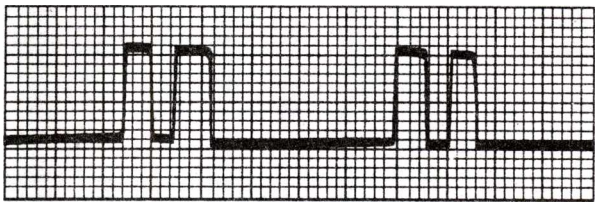

Fig. 4.20 : Correct standardisation

EFFECT OF DEEP RESPIRATION ON ECG

Deep inspiration makes the heart more vertical with clockwise rotation, and in deep expiration heart becomes more horizontal with anti-clockwise rotation. Ofen in lead III, a small q wave appears which disappears on taking deep inspiration (i.e.. lead III R should be a routine procedure in the standard ECG tracing; R stands for respiration).

EXERCISE ELECTROCARDIOGRAPHY

Since the resting ECG is normal in 25-40% of patients with angina, stress (exercise) ECG is used to assess the cardiac response to exercise. The ECG is recorded while the patient walks or runs on a motorized treadmill (TMT or treadmill test) or bicycle ergometer, which follows the 'Bruce protocol'. Exercise can result in relative myocardial ischaemia as it increases myocardial demand on coronary blood supply.

[A] HYPERTROPHY PATTERNS
(CHAMBER ENLARGEMENT)

'Hypertrophy' refers to an increase in muscle mass (pressure overload), commonly resulting from systemic hypertension (T LV) and aortic stenosis (T LV). 'Enlargement' is due to dilatation of heart chamber (volume overload), commonly as a result of valvular heart diseases, e.g., aortic regurgitation (LV enlargement), or mitral stenosis/regurgitation (LA enlargement); hypertrophy and enlargement may co-exist.

Atrial hypertrophy :

Read the P wave in details (described earlier)—P-mitrale and P-pulmonale.

Ventricular hypertrophy :

1. Left ventricular hypertrophy (LVH) :

Criteria for diagnosis —

a) Voltage criteria — There is tall R waves in V_5 and V_6, lead I and aVL; deep S waves in V_t and $V_{\pm}$; R in V_{δ}. or V_{η} is > 27 mm; S in V, or $V_{\uparrow}$,.+ R_{2} in V_{δ} or V_{δ} is > 35 mm, and

b) R in AVL is > 11 mm.

c) Horizontal heart with QRS axis < -30° and anti-clockwise rotation.

c) The intrinsicoid deflection in $V_{_}$ > 0.05 second i.e., VAT is increased.

d) Strain pattern — Depressed and convex upwards ST segment with inverted T wave in lead I, aVL, V_{η} and V_{B}.

* Left axis deviation is not an invariable accompaniment of LVH and if the axis is > -30°, think of associated left anterior hemiblock. Remember, lead V_5 represents the left ventricular forces.

** Now-a-days, *Romhilt and Estes point scoring system* is probably the best formula to diagnose LVH.

*** There may be associated P-mitrale.

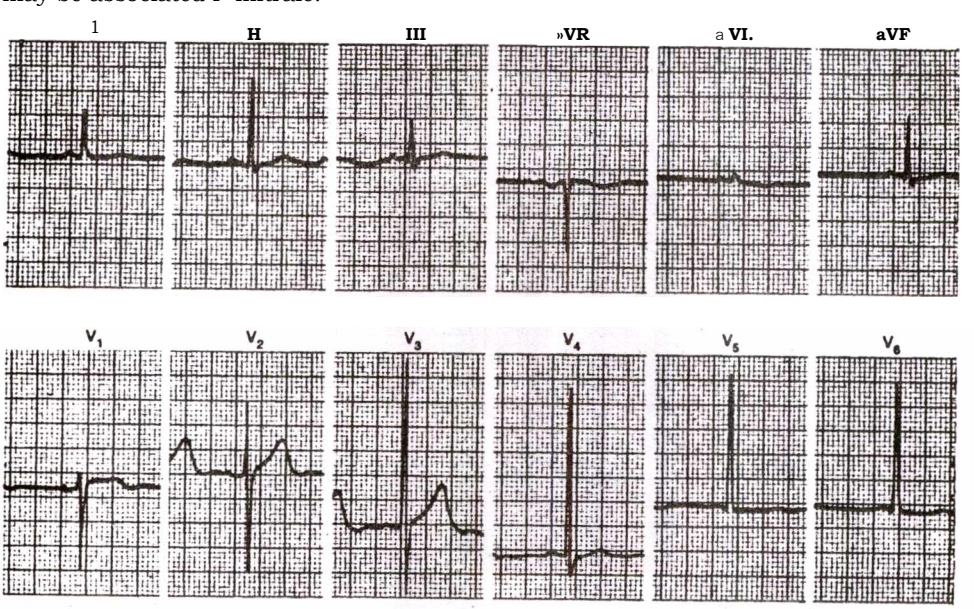

Fig. 4.21 : Left ventricular hypertrophy

Right ventricular hypertrophy (RVH) :

Criteria for diagnosis —

a) Voltage criteria — R wave is greater than S wave in V_1 or V_{3R} i.e., R : S = >1; usually a tall R wave > 5 small squares in V, is suggestive of RVH.

b) Persistent deep S wave in V_5 and V_6.

c) Normal axis or usually with right axis deviation (> +100°).

d) Vertical heart with clockwise rotation.

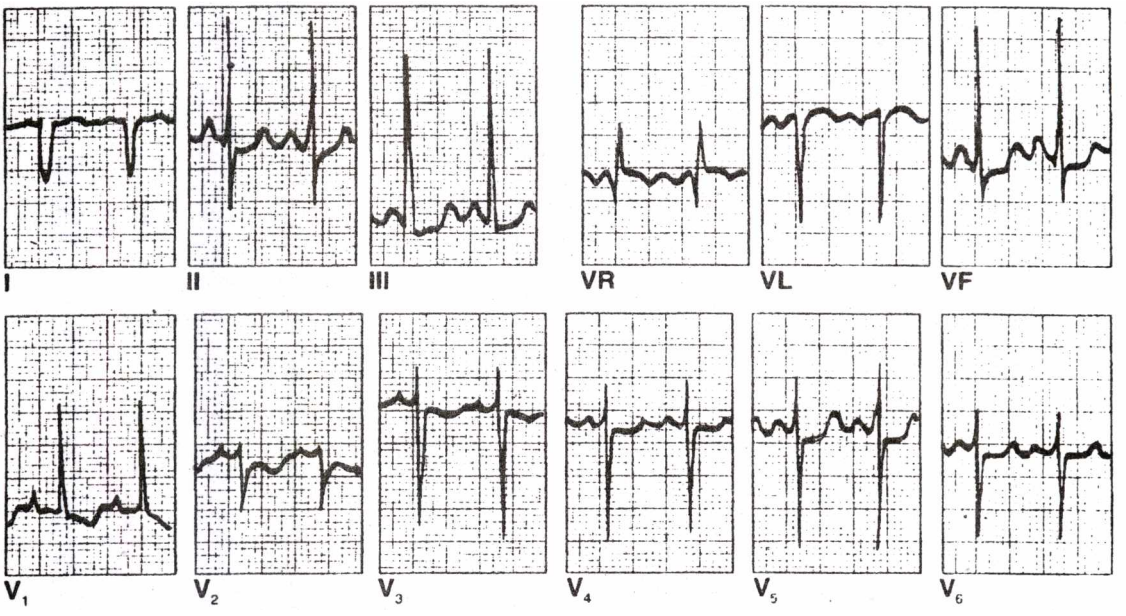

Fig. 4.22 : Right ventricular hypertrophy with strain

e) Intrinsicoid deflection in V_1 or V_{3R} is over 0.03 second i.e., VAT is increased.

f) Strain pattern — Depressed and convex upwards ST segment with inverted T wave in right ventricular leads ($V_;$, aVR, V_{3R}).

* There may be associated P-pulmonale. Remember, lead V_1 represents the right ventricular forces.

3. Combined left and right ventricular hypertrophy :

It is difficult to diagnose because very often the features of RVH are obscured by those of LVH. The most reliable criteria are the features of LVH in precordial leads associated with an axis deviation > +90° (signifies RVH).

* *'Katz-Wachtel phenomenon'*—large amplitude equiphasic RS complexes in mid-precordial leads are seen in biventricular hypertrophy (commonly in VSD).

4. Chronic cor pulmonale :

a) P-pulmonale in lead II, III and aVF.

b) Vertical heart with clockwise rotation; there may be right axis deviation due to RVH.

c) - Features of RVH.

d) Low voltage due to the presence of emphysema.

e) Right bundle branch block (rsR'-pattern in V^.

f) 'Sj, S_2, S_3 syndrome' (producing S wave in standard leads I, II and III) as a result of emphysema.

* The Sj, S_2, S_3 syndrome constitutes supportive evidence of RVH.

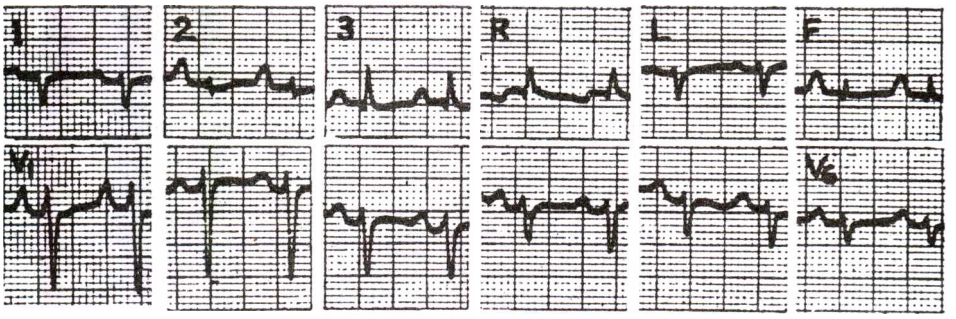

Fig. 4.23 : Chronic cor pulmonale

5. Acute cor pulmonale (acute pulmonary thromboembolism) :

a) Sinus tachycardia.
b) RVH with strain pattern.
c) Right axis deviation.
d) Right bundle branch block.
e) P-pulmonale.
f) 'Sj, Q_3, T_3 pattern', i.e., prominent S wave in lead I, prominent Q wave in lead III and inverted T wave in lead III (a reflection of right heart strain).

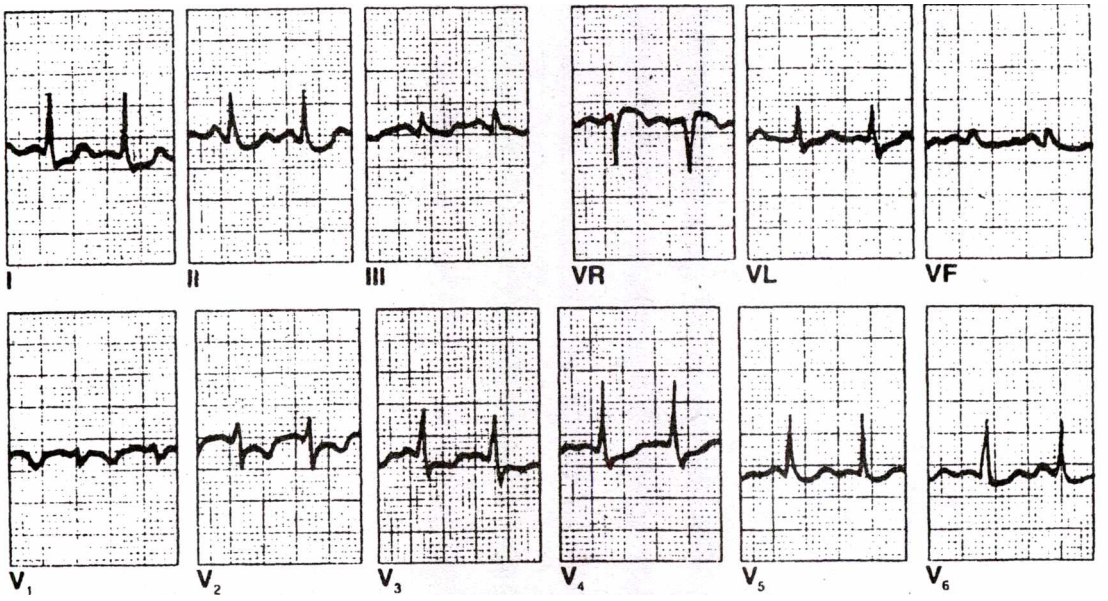

Fig. 4.24 : Acute pulmonary thromboembolism

[B] MYOCARDIAL ISCHAEMIA AND INFARCTION

Ventricular surfaces and leads that reflect ischaemia/infarction :

Surfaces (left ventricle)	Lead orientation
1. Anterior	
2. Anteroseptal	V,_4
3. Anterolateral	I. aVL, V^
4. Extensive anterior wall	I, aVL, V,_g
5. High lateral	I, aVL
6. Apical	
7. Inferior	II, III, aVF
8. Posterior	No direct lead specification. 'Mirror-image' changes (ST depression and tall R) are seen in V_{1-3}

Surfaces (left ventricle)	Lead orientation
Right ventricle	aVR, Vj and right-sided precordial leads, specially V_{4R}

Myocardial ischaemia (angina pectoris) :

Criteria — ST *depression orT wave inversion or both* in standard leads, extremity leads and precordial leads.

The ST depression may be of plane, oblique or sagging depression.

Normal ST segment Oblique depression Plane depression Sagging depression

Fig. 4.25 : Normal and abnormal ST segment

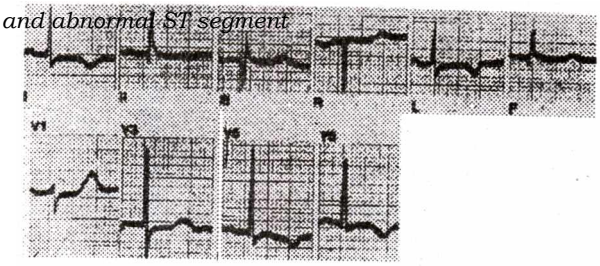

Fig. 4.26 : *Angina pectoris (coronary insufficiency). Antero-lateral ischaemia is present*

* ST depression in angina pectoris usually indicates transient subendocardial ischaemia. In Prinzmetal's angina, there is ST elevation seen as a result of transient subepicardial injury.

Myocardial infarction :

Three zones i.e., ischaemia-injury-necrosis sequence in myocardial infarction is reflected in ECG. The ECG tracing (fully evolved phase) is the summation of,

1. Myocardial injury — ST *elevation with convexity upwards.*
2. Myocardial necrosis — Wide and deep Q wave.
3. Myocardial ischaemia —•' T inversion; T wave is peaked and both the limbs are symmetrical (arrowhead T wave).

* Myocardial infarction is diagnosed on ECG by infarction pattern (Q wave, ST elevation and T wave inversion), seen in more than two consequtive leads; the infarction pattern observed in different leads determines the site (e.g., anterior, lateral, inferior).

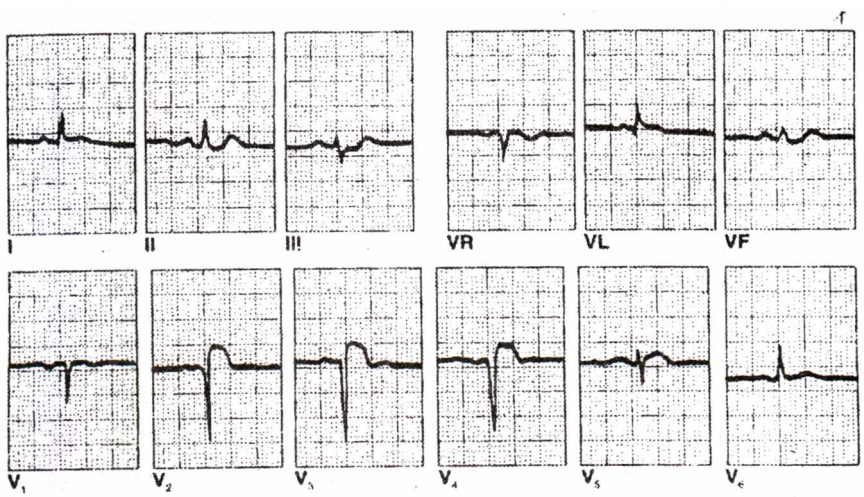

Fig. 4.27 : Acute anterior wall myocardial infarction (extensive) —fully evolved phase

Pathological 9 wave in myocardial infarction :

1. Wide — >0.04 second in duration.
2. Deep — Usually >4 mm in depth.
3. Usually >1/4 th of R wave (in height) and is associated with substantial loss in the height of ensuring R wave.

4. Pathological Q waves are usually present in several leads e.g., in inferior wall infarction, it is present in lead II, III and aVF.

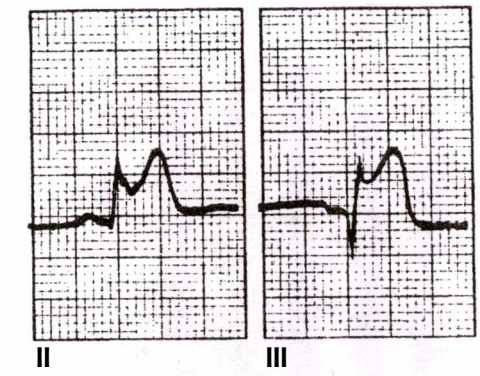

Fig. 4.28 : Hyperacute phase of AMI

The process of infarction progresses through three phases :

(A) Early 'hyperacute' phase (within a Jew hours of the onset) :

1. Slope-elevation of the ST segment with
2. Wide and tall T wave.

(B) Fully evolved phase (usually within 24 hours of the onset) :

1. Pathological Q wave.
2. Coved and elevated ST segment.
3. Symmetrically inverted T wave.

(C) Phase of resolution or old infarction :

1. Pathological Q wave.
2. ST segment and T wave may be normal, equivocal or point towards coronary insufficiency.

N.B. : Pathological Q wave, isoelectric ST segment and symmetrically inverted T wave are found in 'AMI of some duration' (e.g., after 3 to 5 days).

* The reciprocal leads will show ST depression in case of acute myocardial infarction (AMI).

Table 11 : Indicator leads and reciprocal leads in AMI

Indicator leads of AMI	Reciprocal leads
Anterior- I, aVL, V,^	II, III, aVF
Inferior- II, III, aVF	I, aVL and some precordial leads
Lateral- I, aVL, V_{5-0}	$V_{1'}$, V_{3R}

** The above features give an idea of transmural (full thickness) infarction. *Subendocardial (partial thickness)* infarction is a bit different so that ECG shows deep symmetrical T wave inversion and loss of height of R waves facing the infarction (there is neither Q wave nor ST elevation).

*** In high antero-lateral infarction, third intercostal space leads are recorded. Remember, QS complexes may normally be seen in V_{12} (in clockwise rotation) and in AVF (in horizontal- heart). Persistence of ST segment elevation for a period of months or years after AMI indicates development of ventricular aneurysm.

[C] DISORDERS OF RHYTHM

Sinus rhythm :

The rate and rhythm of the normal heart are controlled by the SA node which is again influenced by the vagus nerve. When the impulse is produced by the SA node, it is known as *sinus rhythm* which is the

normal rhythm of the heart. The average heart rate Is 60-100 beats/minute. If vagal tone increases, the heart rate is decreased and in decrease in vagal tone, there is accentuation of the heart rate.

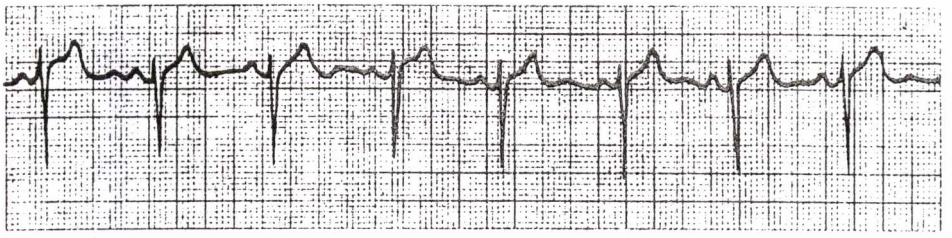

Fig. 4.29 : Sinus rhythm

Sinus arrhythmia :

Heart rate increases with inspiration and decreases with expiration in sinus arrhythmia (i.e., alternate tachycardia and bradycardia associated with phases of normal respiration). This physiological phenomenon is commonly seen in children than in adults and is often associated with sinus bradycardia. Sinus arrhythmia is accentuated by vagotonic produres like carotid sinus massage, and is abolished by vagolytic procedures like exercise. The ECG tracing is diagnosed by gradual lengthening and gradual shortening of R-R interval in a normal ECG with normal P-QRST complexes.

Fig. 4.30 : Sinus arrhythmia

Sinus tachycardia :

It is a *regular sinus rhythm* with SA node discharging in excess of 100 times/minute (usually 100-160 times/minute). Common causes are strenuous exercise, emotion, anxiety, excitement, congestive cardiac failure, severe anaemia, thyrotoxicosis, shock, pain, pyrexia, myocarditis, acute haemorrhage, pregnancy, atropinisation and drugs like nifedipine. The ECG tracing is diagnosed by R-R interval less than 15 small squares with normal P-QRST complexes.

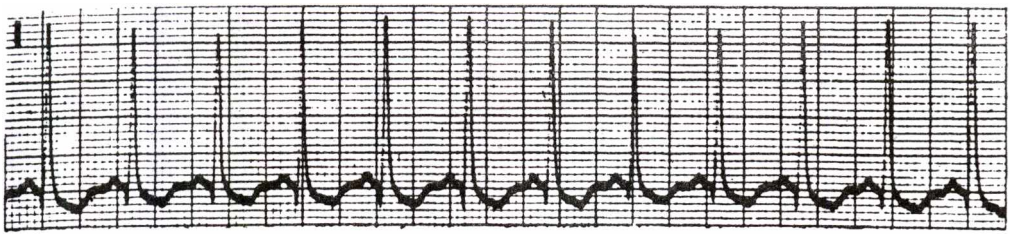

Fig. 4.31 : Sinus tachycardia. Heart rate is 125/minute

Sinus bradycardia :

It is a *regular sinus rhythm* with SA node discharging in less than 60 times/minute. Common causes are athletes, deep sleep, myxoedema, obstructive jaundice, increased intracranial tension, vasovagal attacks, sick sinus syndrome, heart blocks, hypersensitive carotid sinus, hypothermia, administration of drugs like propranolol and digitalis. The ECG tracing is diagnosed by R-R interval more than 25 small squares with normal P-QRST complexes.



Fig. 4.32 : Sinus bradycardia. Heart rate is 42/minute

SUPRAVENTRICULAR RHYTHM DISTURBANCES

Tachyarrhythmias are classified into two groups :

(A) Supraventricular—focus originating from atria or AV node.

(B) Ventricular—focus lies in ventricles.

Supraventricular premature beats (SVPB) or extrasystoles :

The ectopic impulse is due to premature discharge either from the atrium or the AV node.

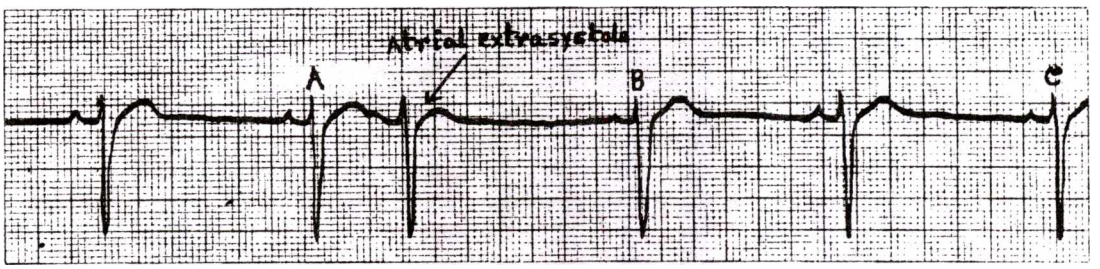

Fig. 4.33 : Atrial extrasystole

Features :

1. As the atrial ectopic beat (P) occurs prematurely, it comes earlier than the anticipated sinus P wave.
2. The P wave may be upright, inverted or diphasic; it may be pointed or notched, i.e., P wave is bizarre.
3. The P wave is usually followed by a normal QRST complex (an ectopic P wave may be blocked and thus it may not be followed by a QRST complex).
4. The 'compensatory pause' is incomplete, i.e., the sum total of the R-R intervals of the normal beat before and after the ectopic beat is less than double of the normal R-R interval, i.e., A-B interval is < B-C interval in Fig. 4.33.

Aetiology :

1. Overindulgence of tea, coffee, cigarettes, alcohol.
2. Anxiety, dyspepsia.
3. Rheumatic, ischaemic, hypertensive, thyrotoxic and cardiomyopathic heart diseases.
4. Drugs — Digitalis, emetine, adrenaline.
5. During cardiac surgery.

* Two to four SVPB may result from smoking, insomnia, overindulgence of coffee or alcohol, and very often regarded as normal.

Symptoms pertaining to extrasystoles :

Symptoms, if present are due to,

a) Extrasystoles or ectopics — Palpitation, extra beat.

b) As a result of compensatory pause — Vertigo, syncope, stoppage of heart, chest pain.

c) As a result of forceful contraction after the pause — Palpitation or thumping sensation.

Paroxysmal supraventricular tachycardia (PSVT) :

PSVT is best thought of as a run of rapidly repeated premature beats of sudden onset, usually three or more consecutive rapidly occuring SVPBs which continue for several hours or days; it may have sudden termination. PSVT is characterised by a regular rhythm at a rate of 160-220/minute.

As PSVT resembles a continuous run of SVPB, each P wave is followed by a ventricular QRS complex. PSVT is principally due to AV nodal re-entry mechanism often exaggerated by using a concealed extranodal pathway.

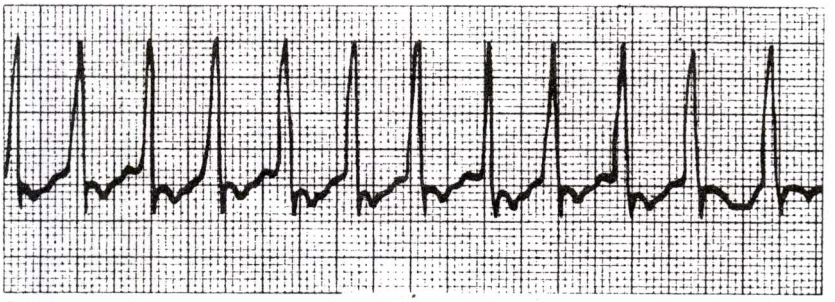

Fig. 4.34 : Paroxysmal supraventricular tachycardia (PSVT)

Features :

1. Abnormal P wave preceding QRS complex.
2. Rapid (160-220/minute), regular and normal QRS *(narrow)* complex.
3. ST segment depression with T wave inversion may be seen.

Usually there is 1 : 1 AV conduction. Sometimes, there is AV block of varying degree, usually 2 : 1 (paroxysmal atrial tachycardia with block). The P -R interval is often prolonged in PSVT and the P wave may be buried in the preceding QRS complex (i.e., no P wave seen), mimicking junctional (nodal) tachycardia.

Significance of PSVT :

Aetiologies are same as SVPB (sometimes PSVT may be seen in association with ASD, Ebstein's anomaly, W-P-W syndrome, sick sinus syndrome or floppy mitral valve syndrome). If PSVT continues for a long time, cardiac failure may be precipitated. *Management* is done by carotid sinus massage or with the help of other vagotonic procedures, and administration of drugs like verapramil, adenosine, beta-blockers; lastly cardioversion with synchronized DC shock (150 J) may be applied.

Atrial fibrillation :

The excitation and recovery of the atria are totally disorganised and chaotic in atrial fibrillation. The atrial rate is usually 350-600/minute and varying degrees of AV block always exist in an untreated patient. The ventricular rate is usually 100-150/minute.

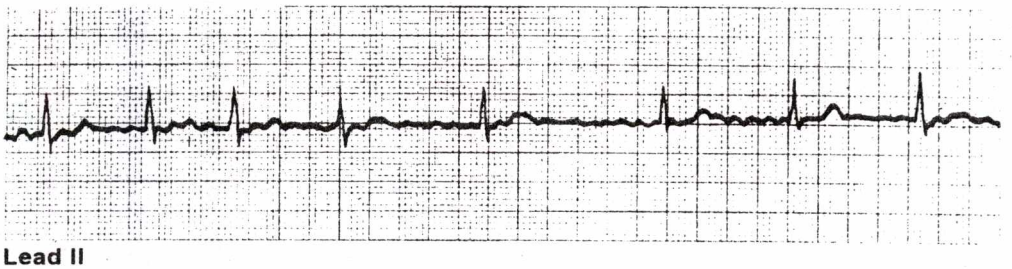

Fig. 4.35 : Atrial fibrillation

Features :

1. Atrial deflections are irregular and chaotic, and thus results in a ragged baseline. The P waves are replaced by fibrillation waves or 'f waves which are rapid, small and irregular waves.
2. *Irregularly irregular ventricular rhythm.*
3. Normal QRS complexes, sometimes varying in amplitude.

Aetiology :

1. Heart diseases — Rheumatic (commonly MS), ischaemic, hypertensive, thyrotoxic and cardiomyopathic.
2. Myocarditis, pericarditis.
3. Drugs — Digitalis, emetine, adrenaline.
4. 'Lone' atrial fibrillation — In elderly persons without any demonstrable organic heart disease.
5. Constrictive pericarditis, ASD, W-P-W syndrome, cor pulmonale, pulmonary thromboembolism.
6. Sinoatrial disease (sick sinus syndrome).

Atrial flutter :

It is the rapid as well as regular contraction of atria at a rate of approximately 220-350/minute. The ventricular rate is usually regular, being 1/2 to 1 /4 th of the atrial rate (as AV block is always associated with). Constantly changing AV block makes the ventricular rate irregular. The P' waves of atrial flutter have a 'saw-toothed' appearance and are known as flutter (F) waves (usually in lead II and III).

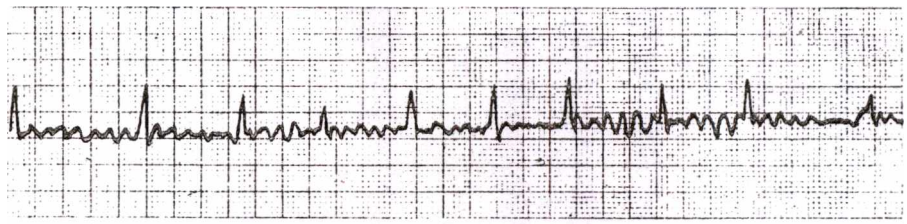

Fig. 4.36 A : Atrial flutter

Features :

1. 'Saw-toothed' or undulating baseline with 'F' waves replacing P waves. Usually atrial rate is 220-350/minute and the ventricular rate is 1/2 to 1/4 th of the atrial rate.
2. *Regular ventricular rhythm* unless associated with changing AV block.
3. Normal QRS complexes in a ratio of 2 : 1 to 8 : 1.

Aetiology :

Same as atrial fibrillation.

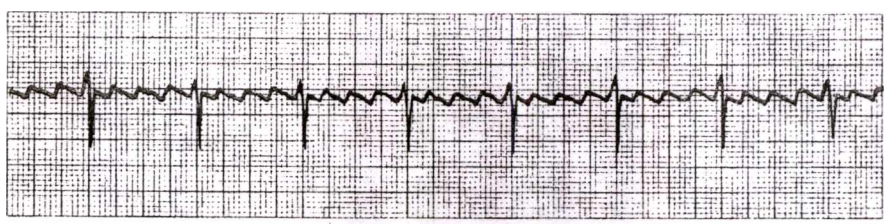

Fig. 4.36 B : Atrial flutter–fibrillation

Flutter-fibrillation :

Sometimes, a mixture of atrial flutter with atrial fibrillation is seen and the precise differentiation between them is often very difficult. This is known as flutter-fibrillation.

* Fibrillation and flutter waves are best seen in lead II and V_r

VENTRICULAR RHYTHM DISTURBANCES

Ventricular premature beats (VPB) or extrasystoles :

The VPB arises from an ectopic focus in any portion of the ventricular myocardium.

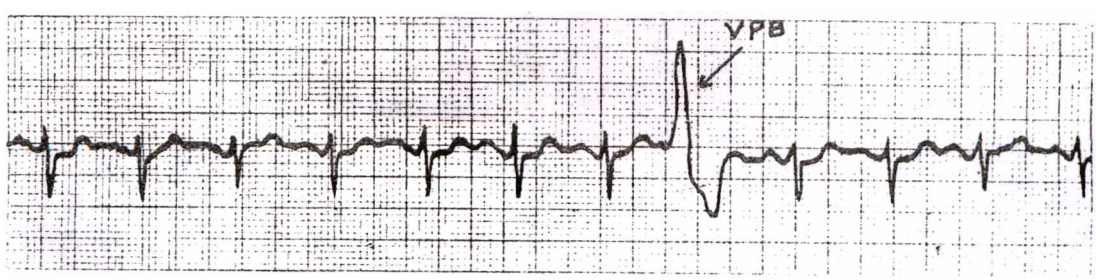

Fig. 4.37 : Ventricular extrasystole

Features :

1. The ectopic beat appears prematurely.
2. P^1 wave is usually hidden in the QRS complex or a retrograde P^1 wave (usually inverted) may follow the QRS complex.

3. Bizarre, wide and tall QRS complexes. The ST segment and T wave are usually displaced in the opposite direction of the major QRS complex.
4. The 'compensatory pause' is complete i.e., the sum total of the R-R intervals of the normal beat preceding and following a VPB is equal to double of the normal R-R interval.

* Ventricular ectopics or VPBs may be monomorphic (same pattern) or polymorphic (different patterns). They may form 'couplet' (a pair of successive VPBs) or 'bigeminal rhythm' (an ectopic beat alternating with a sinus beat).

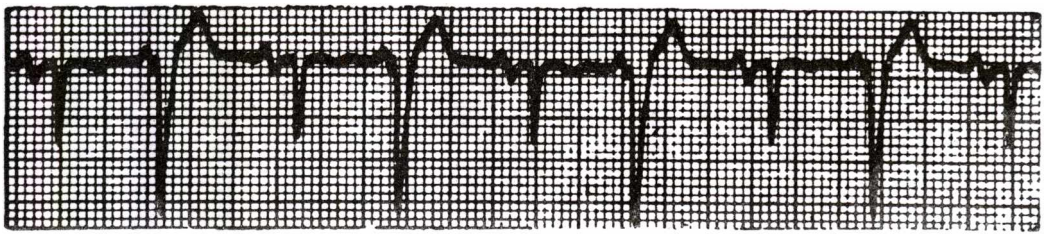

Fig. 4.38 : Bigeminal rhythm produced by alternate VPB

Aetiology :

Same as SVPB.

Significance of VPB :

SVPB frequently occurs in normal individuals. Diagnosis of organic heart disease should not be made solely on the ECG criteria of SVPB. Very often atrial extrasystoles occur secondary to emotional disturbances, after consumtion of tea, coffee, tobacco and alcohol.

Though **VPB** may occasionally be found in normal individuals, it is always significant if associated with,

1. Bigeminal rhythm.
2. In an individual with organic heart disease, specially myocardial disease.
3. If the VPB are multifocal.
4. If the VPB occur frequently, i.e., in 'crops'.
5. If the VPB are present > 5 times/minute.
6. If precipitated by exercise.
7. If occurs in persons > 40 years of age.
8. Presence of 'R on T phenomenon' (such an ectopic beat is prone to initiate repetitive discharge, i.e., ventricular tachycardia or fibrillation may be precipitated).

N.B. : In contrast to SVPB (often found in normal individuals), VPB usually indicates some cardiac disease.

(Paroxysmal) ventricular tachycardia (VT) :

When a series of three or more consecutive VPBs occur for few beats or continue for several hours or days, it is known as VT. Usually VT has a regular rhythm with a heart rate of 140-220/minute.

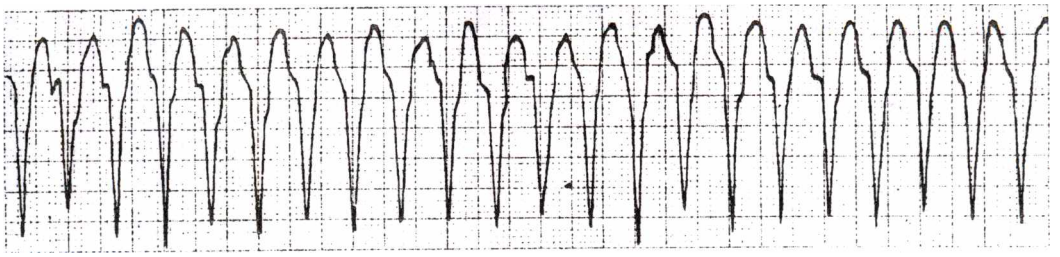

Fig. 4.39 : Ventricular tachycardia

Features :

1. Premature, bizarre, tall and wide QRS complexes recorded in rapid succession.
2. The P wave bears no relationship with the QRS complexes (AV dissociation).

3. Presence of *capture beats* (the normal sinus conducted beat occuring during the run of VT) and *fusion beats* (a blending complex beat which is in between normal sinus beat and ventricular ectopic beat).
4. Concordant precordial leads (i.e., $V_{;\ 6}$)—all the complexes are either upwards or downwards.

Aetiology :

Same as SVPB (commonly due to IHD, cardiomyopathy, valvular heart disease, thyrotoxicosis, floppy mitral valve syndrome, myocarditis, hypoxia, acidosis, digitalis and hypokalaemia). VT is commonly associated with recent myocardial infarction. It is regarded as a very serious arrhythmia. If not treated properly, VT may degenerate into VF.

* *Torsades de pointes* is a form of VT manifested by episodes of alternating electrical polarity with the QRS amplitude twisting around an isoelectric baseline (hence the name); the rhythm usually starts with a VPB and is preceded by prolongation of Q-T inverval. Certain drugs (e.g., quinidine, procainamide) and electrolyte imbalance (iCa^{++}, $4K^{++}$) may precipitate the situation. Usually the attacks are self-limiting but may lead to VF.

Ventricular fibrillation (VF) :

VF is a chaotic and incoordinated activity of the heart, which results in totally irregular, bizarre and deformed deflections of varying height, width and shape. This is a fatal and terminal condition where the peripheral pulses are not palpable and the heart beat is inaudible. Fibrillating ventricles can not effectively pump out blood in the circulation. The treatment is immediate electrical defibrillation.

Aetiology :

1. Ischaemic heart disease, specially acute myocardial infarction.
2. Digitalis, adrenaline or quinidine toxicity, specially if associated with hypokalaemia.
3. Electrical shock (accidental).
4. Hypoxia, specially induced by cardiac surgery.
5. Hypothermia.
6. Myocarditis, cardiomyopathy.
7. Electrolyte imbalance (high or low K^{+}, low Ca^{++} or Mg^{++}).



Fig. 4.40 : Ventricular fibrillation

Significance :

It is considered as the most *serious and catastrophic arrhythmia,* and the prognosis is extremely poor.

Ventricular flutter :

This results from a very rapid and regular ectopic ventricular discharge associated with grossly abnormal intraventricular conduction, and manifested by bizarre and wide configuration of the QRS complex where the QRS complex is fused with T wave mimicking continuous 'hairpin curves' or 'sine-like wave' form.

Aetiology :

Same as VF.

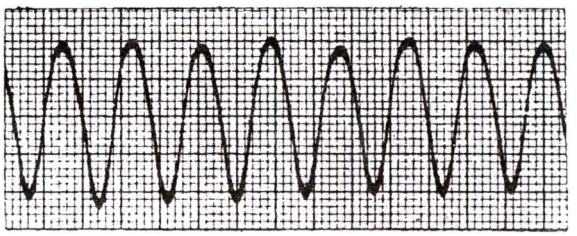

Fig. 4.41 : Ventricular flutter

* Complete absence of electrical activity of heart is called **ventricular asystole** (i.e., cardiac standstill or cardiac arrest) when there is absence of ventricular complexes in ECG (shows flat line) for seconds to minutes. Clinically, this can not be differentiated from ventricular fibrillation unless ECG monitoring is done.

Table 12 : Differentiation between SVT and VT

	Features	SVT with aberrant conduction	VT
1.	P wave	A premature P wave may precede QRS	QRS complex not preceded by P' wave
2.	Duration of QRS complex >0.14 second	Absent	May be present
3.	R-R interval	Perfectly regular and constant	Slightly irregular and not absolutely constant
4.	Carotid sinus massage	May be reverted to normal	No effect
5.	Left axis deviation	Usually absent	Usually presnt
6.	AV dissociation	Not present	Present
7.	Capture and fusion beats	Absent	A characteristic feature

Clinically, VT is associated with varying intensity of and irregular cannon waves in neck vein.

[D] INTRAVENTRICULAR CONDUCTION DEFECTS

Pacemaker tissues and conducting system of the heart :

Certain tissues in the heart responsible for initiation and propagation (i.e., conduction) of the heart beat, are known as 'pacemaker tissues'. They are :

1. Sinoatrial (SA) node—it lies in the right atrium at the junction of superior vena cava and right atrial appendages. SA node originates impulses at a rate of 60-100 beats/min (average 72 beats /min) which traverses through three internodal atrial pathways towards atrioventricular (AV) node. SA node is the natural pacemaker of the heart and generates sinus rhythm.
2. Atrioventricular (AV) node—It is located posteriorly on the right side of the interatrial septum. When SA node fails, AV node may generate impulse at the rate of 40-60 beats/min (nodal rhythm).
3. Bundle of His—It originates from AV node and divides into right (acting as a single fascicle) and left (left anterior and left posterior fascicles) branches. 'Fascicular block' or 'bundle branch block' results from their delay in conduction.
4. Purkinje fibres—they penetrate the ventricular wall after taking origin from terminal divisions of right and left branches of the bundle of His. When SA or AV node fails, the purkinje cells of the ventricular muscle may beat at the rate of 30-40 beats/min (average 36 beats/min), which is known as idioventricular rhythm.

Classification :

1. Unilateral bundle branch block — Right or left; complete or incomplete.
2. Peripheral left ventricular conduction defect—left anterior fascicular/hemiblock (LAHB) or left posterior fascicular/hemiblock (LPHB), septal block.
3. Bilateral bundle branch block or bifascicular block — Right bundle branch block with LAHB or LPHB block, alternating RBBB and LBBB, RBBB or LBBB with prolonged AV conduction.
4. Trifascicular block.

Right bundle branch block (RBBB):

RBBB is a *fairly common ECG finding* and does not necessarily indicate any organic heart disease.
Incomplete — QRS interval <0.12 second.
Complete — QRS interval >0.12 second.

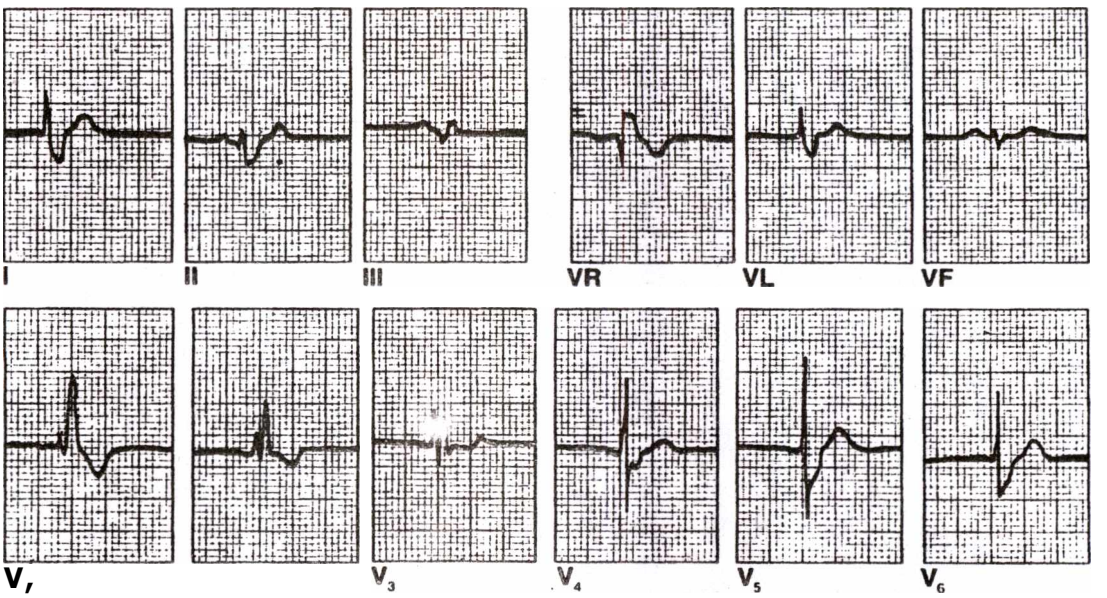

Fig. 4.42 : Right bundle branch block (incomplete)

Features :

1. RSR' or rsR' pattern or 'M-shaped' complexes in V_{12} (also in aVR and V_{3R}); absent q waves in these leads.
2. Wide and slurred S waves in lead 1 and V_c 5-6
3. ST depression and T wave inversion in V .
4. QRS interval is equal, more, or less than 0.12 second (in V_2).
5. Right axis deviation.
6. VAT (intrinsicoid deflection) is prolonged.

Aetiology :

1. Normal variant.
2: Right ventricular hypertrophy.
3. Emphysema of lung.
4. ASD (ostium primum type).
5. Ischaemic heart disease.
6. Myocarditis from any cause.
• 7. Hypertensive heart disease.
8. Acute pulmonary thromboembolism.
9. Cardiomyopathy.
10. Idiopathic.

Left bundle branch block (LBBB) :

Complete LBBB indicates organic heart disease, and is commonly associated with ischaemic and hypertensive heart diseases. Prognostically it is worse then RBBB.

Complete or incomplete — Criteria of duration in timing are same as RBBB.

Features :

1. rsR' or RsR' pattern or 'M-shaped' complexes in leads $V_{4\ 6}$, I and aVL; absent q waves in these leads.
2. ST depression with T wave inversion in lead I and $V_{4\ 6}$.
3. QRS interval is equal, more, or less than 0.12 second (in $V_{5\ 6}$).
4. Usually associated with left axis deviation.
5. VAT (intrinsicoid deflection) is prolonged.

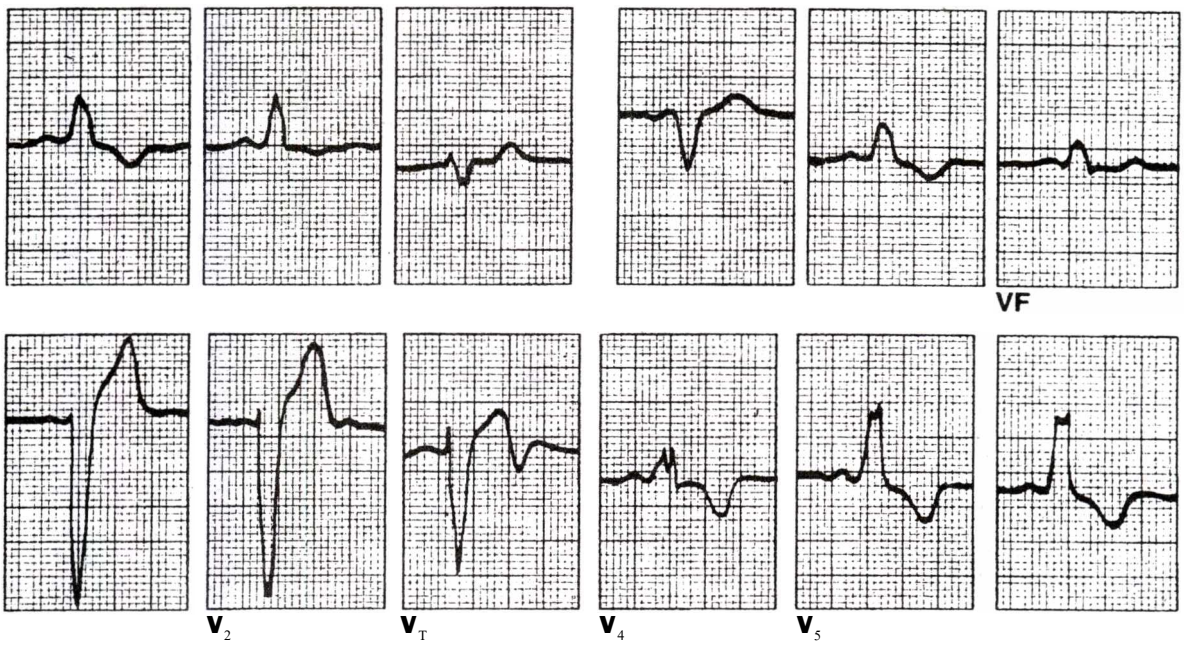

Fig. 4.43 ; *Left bundle branch block (complete)*

Aetiology :

1. Ischaemic heart disease.
2. Left ventricular enlargement due to any cause (specially from systemic hypertension).
3. Cardiomyopathy.
4. Myocarditis due to any case.
5. Drugs like quinidine or procainamide.
6. Aortic valve disease e.g., aortic stenosis.
7. Idiopathic fibrosis.

* The presence of q waves in lead I and $V_{5\ 6}$ always negate the diagnosis of LBBB or indicates associated acute myocardial infarction (AMI).

** In the presence of AMI, LBBB can not be diagnosed properly.

Left anterior fascicular block *(also known as left anterior hemiblock or LAHB)* **;**

Features :

1. Left axis deviation.
2. Narrow QRS complex, qR in lead I, aVL and V_{5-a}; rS in lead II, III, aVF.

Left posterior fascicular block *(also known as left posterior hemiblock or LPHB)**:***

Features :

1. Axis of +100° or greater, i.e., right axis deviation.
2. Narrow QRS complex, and qR in lead II, III, aVF; rS in lead I, aVL and $V_{5\ 6}$.
3. 'Sj, Q_3, T_3 pattern' may be seen.

Left septal block :

Feature :

Absent q wave in $V_{5\ 6}$.

Bilateral bundle branch block or 'bifascicular block':

The possible combinations are :

- RBBB with LAHB — Features of RBBB plus left axis deviation (commonest),
- RBBB with LPHB — Features of RBBB plus right axis deviation, or
- LBBB (both anterior and posterior fasciclcs are blocked).

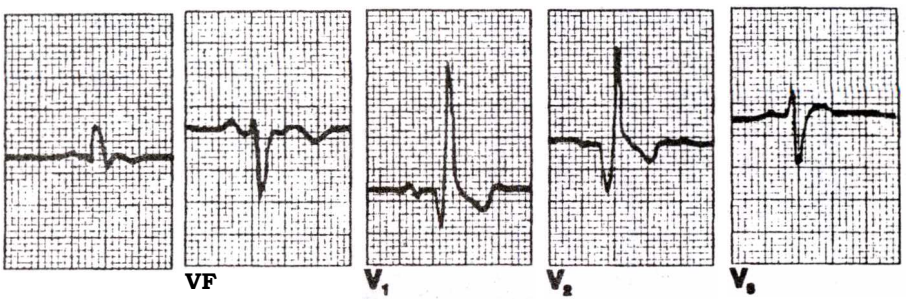

Fig. 4.44 : Bifascicular block (RBBB wih LAHB)

Trifascicular block :

When the three fascicles (right bundle, left anterior fascicle and left posterior fascicle) are blocked, it is known as trifascicular block.

Features :

1. Features of RBBB.
2. Left axis deviation (indicating left anterior fascicular block).
3. Prolonged P-R interval (indicating first degree AV block, or may be represented by left posterior fascicular block).



Fig. 4.45 : Trifascicular block

[E] ATRIOVENTRICULAR (AV) CONDUCTION DEFECTS

AV block is the disturbance in the conduction of normal sinus impulse through the AV node, the bundle of His, or the intraventricular conduction system.

Classification :

(A) Incomplete :

a) First degree (1°)

b) Second degree (2°)

(i) Mobitz type I or Wenckebach type

(ii) Mobitz type II

(B) Complete : i.e., third degree (3°) heart block

1 ° heart block :

There is disturbance in conduction between the SA node and the AV node, and results in the prolongation of the P-R interval above the upper limit of normal (0.20 second). The rhythm is regular with constant P-P and R-R interval. Atrial rate : ventricular rate = 1 : 1 .

Aetiology :

1. Acute rheumatic fever (myocarditis).
2. Any acute infectious disease (mainly viral).
3. Digitalis, quinidine or propranolol-induced.
4. Ischaemic heart disease.

5. ASD or Ebstein's anomaly.
6. Hyperkalaemia.
7. Idiopathic i.e., in the absence of organic heart disease.

Clinical suspicion : If the Sj becomes muffled in the presence of tachycardia, 1° heart block is thought of. There is *no dropped beat* in peripheral pulse.

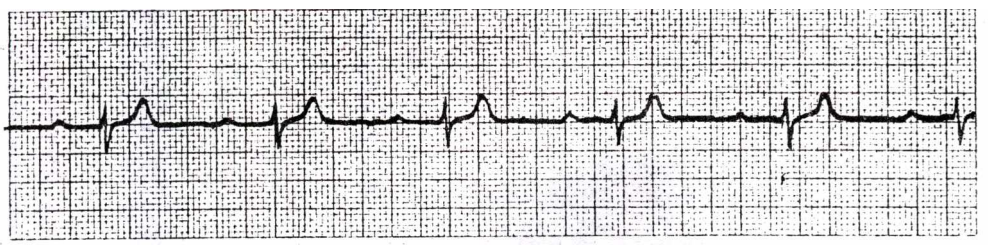

Fig. 4.46 : First degree heart block. P-R interval is 0.32 second

2° heart block :

From time to time, some atrial impulses are allowed to pass and some are not allowed to pass through the AV node. So the atria contracts but as all the contractions do not reach the ventricle, there is missing beats in the pulse. Following are the types of 2° heart block :

a) Mobitz type I or Wenckebach block :

The P-R interval progressively increases till one beat is completely blocked and thus that P wave is not followed by QRS complex. This is more benign and commoner type than Mobitz type II block. This type is commonly associated with acute inferior wall myocardial infarction. Here, the disease lies proximal to the bundle of His.

The basic rhythm is sinus with a constant P-P interval. The conduction ratio varies e.g., 5 : 4, 4 : 3 etc.

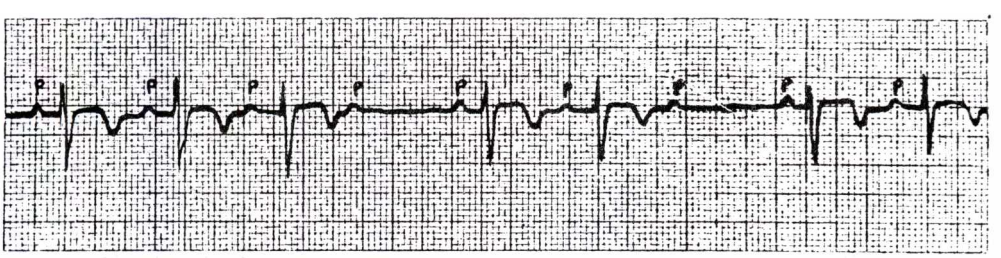

Fig. 4.47 A : Second *degree heart block (Wenckebach type)*

b) Mobitz type II:

The ventricle periodically fails to respond to the atrial contraction in Mobitz type II block. Here, P-R interval remains either normal or prolonged but is always 'fixed'; and ultimately misses one beat (progressive prolongation of P-R interval like Wenckebach phenomenon is absent here). This type is commonly associated with acute anterior wall myocardial infarction. Here, the block lies below the bundle of His and prognostically worse than Mobitz type I block.

The basic rhythm is sinus with constant P-P and P-R intervals. The conduction ratio may be fixed (4 : 3, 2 : 1) or variable. ■

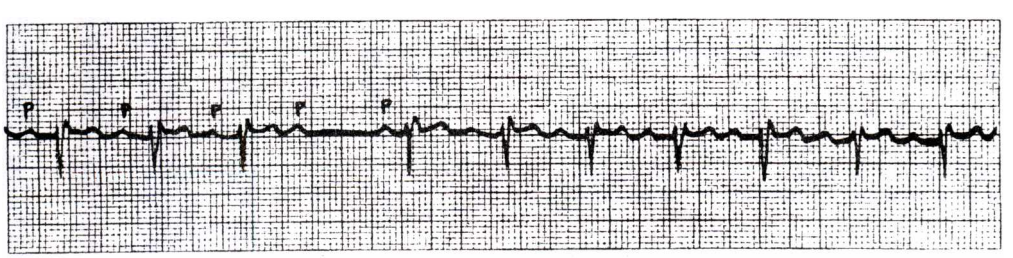

Fig. 4.47 B : Second degree heart block (Mobitz type II)

c) 2° constant (advanced) heart block (2 : 1 or 3 : 1 type):

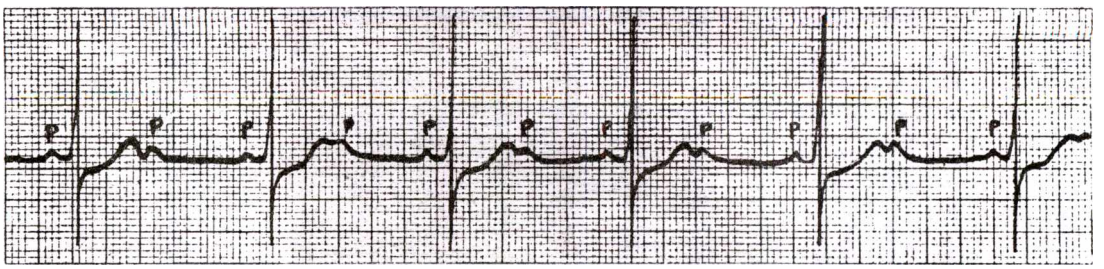

Fig. 4.48 : Second degree fixed heart block (2 : 1 type). Every alternate P wave is not followed by QRS complex

* There is a fixed AV relationship in constant 2° block. In 3 : 2 block, there are 3-P waves and 2-QRS complexes; in 6 : 5 block, 5-QRS complexes follow 6-P waves, i.e., the last P wave does not produce any QRS complex.

Aetiology (of 2° heart block) :

1. Acute rheumatic fever producing carditis.
2. Ischaemic heart disease.
3. Myocarditis following diphtheria.
4. Digitalis toxicity.
5. May be associated with PSVT or atrial flutter as a 'protective mechanism'.

3° *Heart block or complete heart block :*

Here, all the supraventricular impulses are blocked i.e., no SA impulse is allowed to pass through the AV node barrier. Ventricles, therefore, are activated by ectopic pacemaker (idioventricular rhythm) and contract at a regular rate of 30-40/min (idioventricular pacemaker is present in the walls of ventricle close to the AV node). So, there is no relationship between atrial and ventricular pacemaker, and the atrial and ventricular rhythms are asynchronous (there is complete dissociation between P waves and QRS complexes). The atrial rate is that of average regular sinus rhythm. Thus, the P waves and QRS complexes are seen to occur at a different but constant rate (i.e., the P-P and R-R intervals are constant). Usually the rate of the QRS complex is near about half that of the P wave. There is absence of fixed P-R relationship.

If complete heart block develops suddenly and ventricular standstill persists for few seconds, the patient may develop Stokes-Adams syndrome (read the 'Emergency medicine' section).

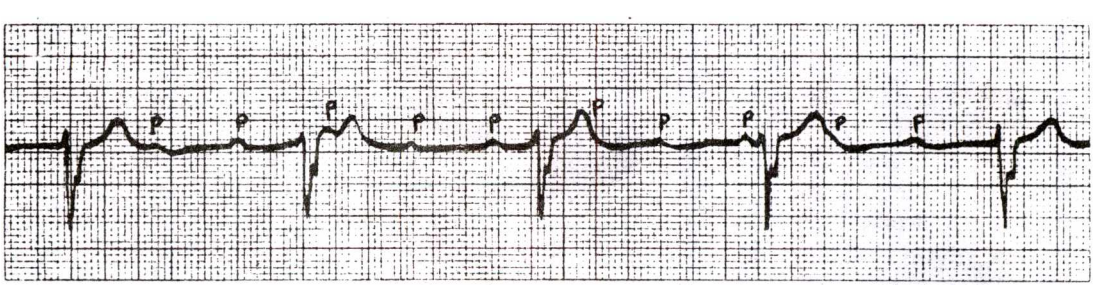

Fig. 4.49 : Complete heart block with ventricular rate 43/minute. Atrial rate is 115/minute

Aetiology :

1. Coronary artery disease, specially acute anterior wall myocardial infarction.
2. 'Congenital' complete heart block.
3. Digitalis, quinidine or procainamide overdose.
4. Myocarditis, pericarditis.
5. Association with ASD (ostium primum type) or VSD.
6. Cardiac surgery (near the conducting system).
7. Lenegre's disease (idiopathic sclerodegenerative disease of the conducting system).

8. Lev's disease (fibrocalcific affection of the conducting system).
9. Cardiac tumour, SBE (aortic root abscess), granulomatous infection (tuberculosis, gumma) or parasitic infestations (Chagas' disease in central and south America).
10. Idiopathic (specially in India).

* Acute rheumatic fever may be associated with first and second degree heart block but not with complete heart block (CHB).

** Clinically, CHB is associated with bradycardia (36-40/min) with regular pulse rate, varying intensity of Sj and irregular cannon waves in neck vein.

[F] HEART BLOCK

Classification of heart block :

1. SA block — The sinus impulse is blocked within the SA junction, i.e., neither atrial nor ventricular activation takes place. So, both the P wave and the QRS complexes are absent, and heart will miss a beat as a whole.

Fig. 4.50 : SA block (every third SA impulse is blocked). Incidentally, there is associated first degree AV block (increased P-R interval)

2. AV block (read section E).
3. Bundle branch block (read section D).
4. Arborisation or Purkinje block — When the bundle branch block is associated with low amplitude complexes, it is known as arborisation block. This term is uncommonly used at the present moment.

* **24-hours ambulatory** or **dynamic ECG** (or **'Holter' ECG.** after its inventor): this technique records transient changes, e.g., an occasional pause in heart beat or a brief paroxysm of tachycardia in the cardiac cycle, complained by the patient. During the recording, the patient remains ambulatory. A1 least 1 lac complexes are recorded in 24-hours and analysed by automatic methods.

[G] MISCELLANEOUS

Wolff-Parkinson-White (W-P-W) syndrome :

Here, the atrial impulse goes to the ventricles via normal as well as anomalous pathway (bundle of Kent). The early activation of the ventricular myocardium is known as *pre-excitation.*

Features :

1. Short P-R interval (< 0.12 sec).
2. Wide QRS complex (> 0.12 sec).
3. Slurred initial upstroke of the QRS complex, known as *'delta wave'.*
4. Secondary ST segment and T wave changes.

* Patients with W-P-W syndrome are prone to attacks of supraventricular tachyarrhythmias.

Fig. 4.51 : W-P-W syndrome with delta wave

Sick sinus syndrome (structural nodal disease) :

It is also known as *bradycardia-tachycardia syndrome.* Patient may present with dizziness, confusion, fatigue, pre-syncope and syncope, palpitation, chest pain, irritability etc. It is diagnosed by,

a) Clinical appraisal (symptoms are due to cerebral hypoperfusion and low cardiac output).

b) ECG monitoring (sinus bradycardia, sinus arrest, sinus pause, SA block with the appearance of escape rhythm, AV block or SVT, atrial fibrillation or flutter).

c) Provocative tests — Sinus node recovery time (a response to overdrive atrial pacing; normal value is < 1500 millisecond) and sino-atrial conduction time. These times are prolonged in structural SA node disease.

Aetiology :

The underlying pathology may involve fibrosis, degenerative changes and/or ischaemia of the SA node.

1. Ischaemic heart disease.
2. Infiltrative or degenerative heart disease.
3. Coronary atherosclerosis with or without systemic hypertension.
4. Cardiomyopathy.
5. Congenital heart disease.
6. Digitalis, quinidine, procainamide-induced.
7. Idiopathic.

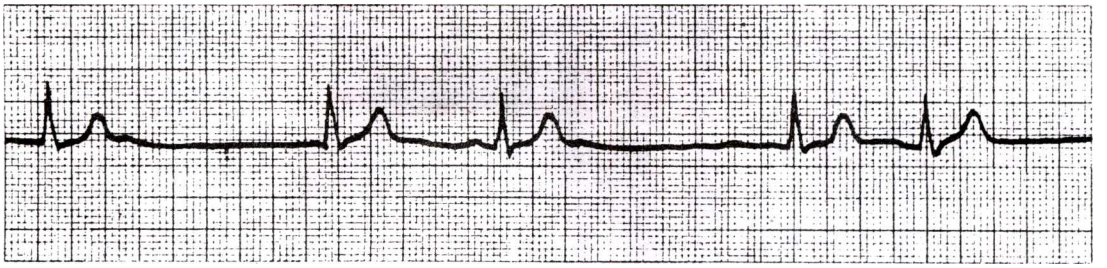

Contd.

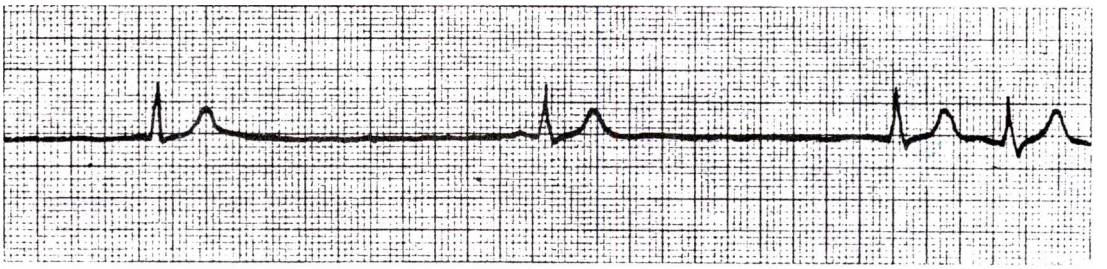

Fig. 4.52 : Sick sinus syndrome

ECG manifestations of sinus node dysfunction are often intermittent and thus it is difficult to prove. Ambulatory ECG (Holter) monitoring remains the mainstay in evaluating sinus node function. Treatment of structural nodal disease is done by artificial demand pacemaker into the right ventricle or permanent pacemaker, as well as using various antiarrhythmic drugs (atropine, isoprenaline).

Hypothermia :

Features :

1. Sinus bradycardia.
2. J wave or 'Osborne wave' — Narrow hump-like wave superimposed on the terminal part of the distal limb of the QRS complex.
3. Q-T interval is prolonged.
4. Muscle tremor (i.e., shivering artefact).
5. Very low temperature, i.e., 30°C or less may produce ventricular fibrillation.

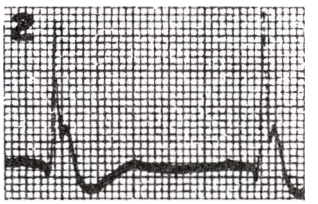

Fig. 4.53 : Hypothermia with J wave

Electrical alternans :

Here, the height of the R wave (i.e., QRS complex) alternates every other beat.

Aetiology :

1. Pericardial effusion, usually with cardiac tamponade (commonest)—heart may rotate freely within the fluid and the electrical axis of the heart may vary with each beat.
2. Paroxysmal atrial tachycardia (rare).
3. Atherosclerotic heart disease (rare).



Fig. 4.54 : Electrical alternans

EFFECT OF DRUGS

Digitalis :

(A) Digitalis effect:

Digitalis effect in ECG does not indicate the need to reduce the dose of the drug. When the patient reaches adequate digitalisation, these changes may be seen in the ECG.

1. ST segment becomes depressed, rounded and with concave (scooped) configuration. It gives the impresion of T wave inversion — the mirror-image of a 'correction mark'.
2. Shortened Q-T interval.

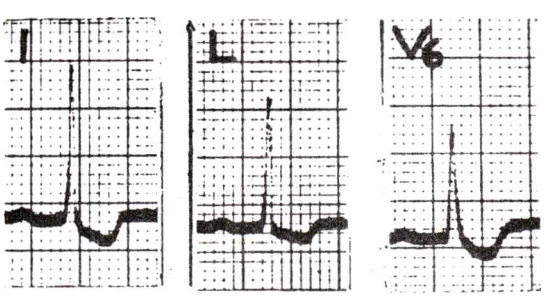

Fig. 4.55 : Digitalis effect

(B) Digitalis toxicity :

Overdigitalisation or toxic effect of the drug may be as follows :

1. Sinus bradycardia.
2. First degree, second degree or third degree AV block; SA block and bundle branch block.
3. Isolated VPB which are unifocal or multifocal, or especially *ventricular bigeminy.*

4. Supraventricular tachyarrhythmias—paroxysmal atrial tachycardia with or without block, atrial flutter, atrial fibrillation.
5. Ventricular arrhythmias — VT, ventricular flutter or fibrillation.

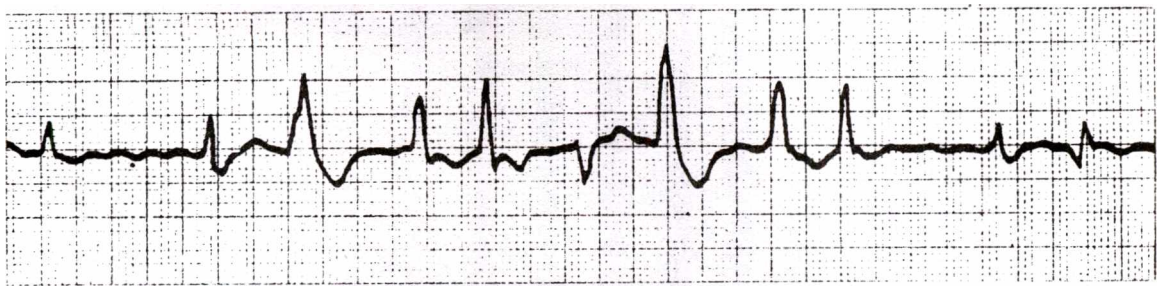

Fig. 4.56 : Digitalis toxicity

* Digitalis may produce any type of arrhythmia except Mobitz type II AV block and parasystole.

N.B. : Digitalis toxicity is increased in the presence of hypokalaemia, renal or hepatic failure and with advanced heart diseases.

Quinidine :

(A) Quinidine effect:

1. ST segment depression with T .wave flattening; wide and notched T wave.
2. Prolonged Q-T interval.

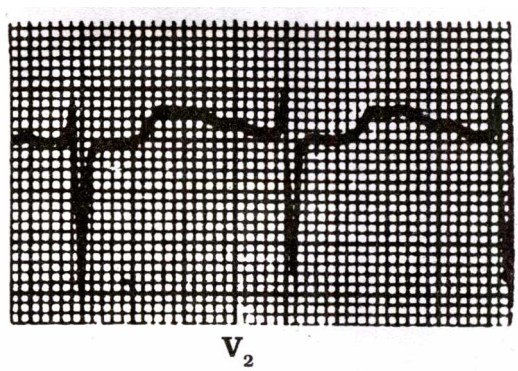

Fig. 4.57 : Quinidine effect with prolonged Q-T interval

(B) Quinidine toxicity :

1. SA block; first, second and third degree AV block; bundle branch block.
2. Ventricular arrhythmias — VPB, VT, idioventricular rhythm, ventricular fibrillation and cardiac standstill.
3. AV junctional rhythm.
4. Widened QRS complex.
5. *Marked prolongation of the Q-T interval.*

EFFECT OF ELECTROLYTES

Potassium :

(A) ***Hyperkalaemia :***

Progressive rise in serum potassium level is associated with the following ECG changes :

1. *Tall, slender and peaked T wave.*

2. Amplitude of the R wave is diminished. QRS complex widens and merges with the T wave in such a way that it is difficult to detect the ST segment, and producing a bizarre, widened and diphasic deflection of T wave.
3. Amplitude of the P wave is diminished and ultimately disappears completely; gradually a 'sine-like wave' is seen.
4. Ventricular arrhythmia may be associated with. Sinus bradycardia may be seen.

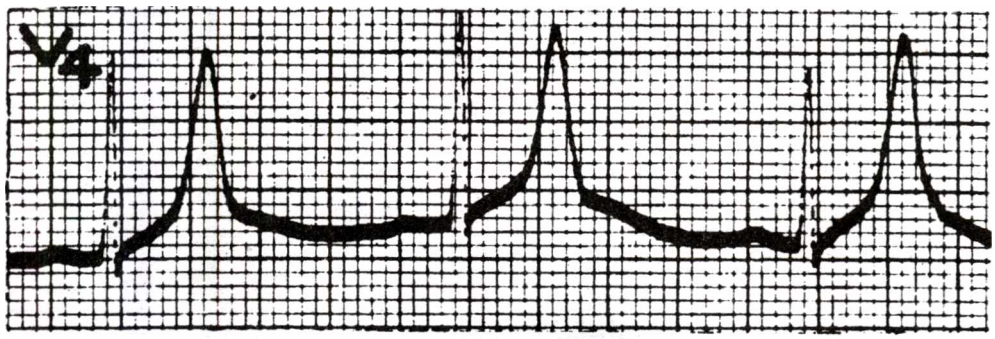

Fig. 4.58 : Hyperkalaemia

(B) Hypokalaemia:

Progressive diminution in serum potassium level is associated with the following ECG changes :

1. ST depression with flattened or inverted T wave.
2. *Prominent U wave.*
3. Prolonged P-R interval.
4. Prolonged Q-T interval.
5. Rarely, SA block.

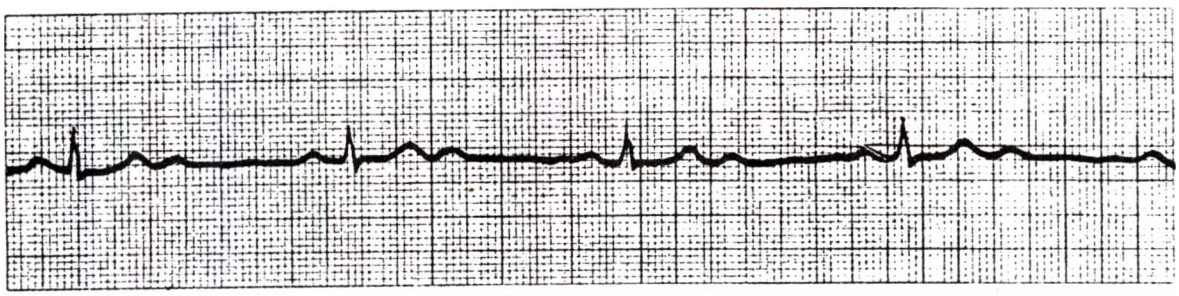

Fig. 4.59 : Hypokalaemia with U wave

* Normal serum potassium level is 3.5-5 meq/L.

Dextrocardia :

Features :

1. P wave is inverted in lead I. QRS complex and T wave are also inverted in lead I. Upright P wave in aVR.
2. Tallest QRS complexes are seen in the right precordial leads, i.e., in V_t and V_2, and progressively diminished to the left. That is to say, there is gradual diminution of height of R waves from V, to V_6.

* In *technical dextrocardia* (faulty interchange of right and left arm electrode by a technician) lead I, II, III, aVR, aVL and aVF will have similar changes like true dextrocardia; but there will be no alteration of normal ECG pattern in precordial leads (i.e., in V,^).

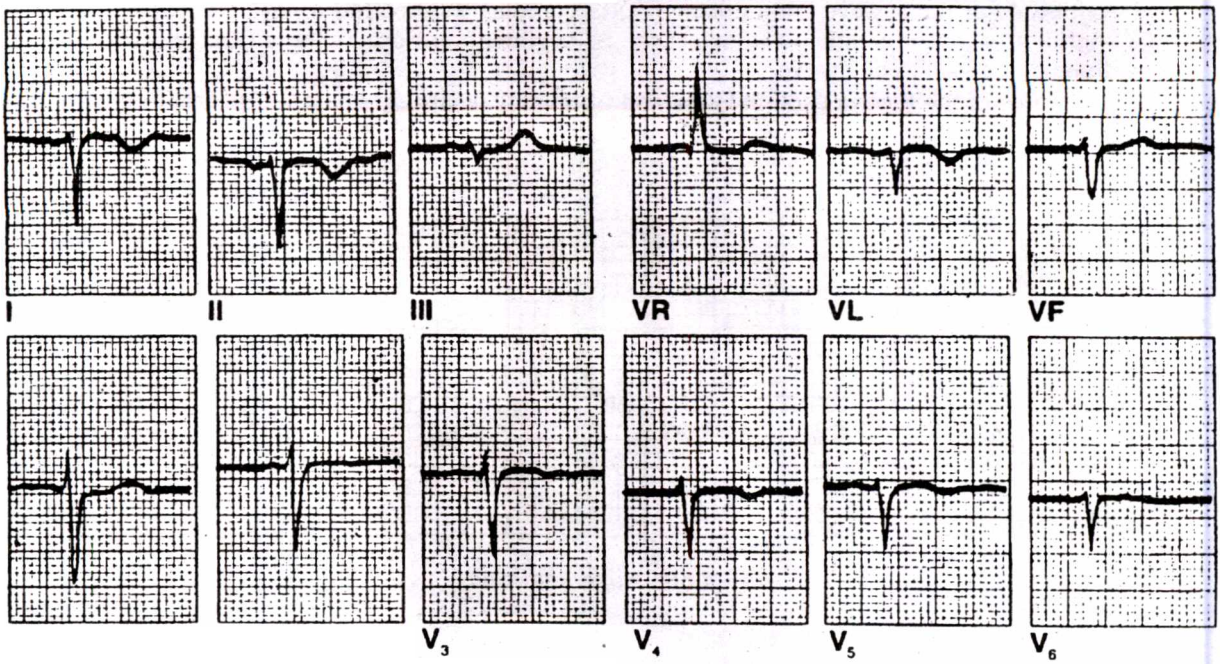

Fig. 4.60: Dextrocardia

Pericarditis :

(A) Acute pericarditis :

1. Normal voltage.
2. *Elevated ST segment with concavity upwards* (in contrast to ST elevation with convexity upwards seen in AMI) — Saddle-back appearance.
3. T wave remains upright (as there is no myocardial ischaemia). After few days, T wave may be inverted.

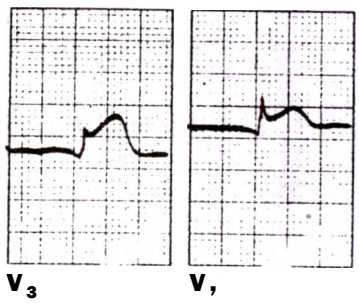

Fig. 4.61 : Pericarditis (acute)

(B) Chronic constrictive pericarditis :

1. Low voltage.
2. Low to inverted T wave.

(C) Pericardial effusion :

1. Low voltage.
2. Low to inverted T wave (sometimes with ST elevation).
3. Electrical alternans may be seen.

Myocarditis :

Myocarditis commonly results from secondary to infections and produces :

1. Varying degree of heart block e.g., first degree AV block, bundle branch block etc.
2. QRS abnormality very often mimics acute myocardial infarction.
3. Various arrhythmias.

Myxoedema :

1. Sinus bradycardia.
2. Low voltage QRS complexes.
3. Prolongation of the P-R interval.
4. Flattened T waves.

Athlete's heart:

1. Sinus bradycardia.
2. Varying degree of AV block (e.g., first degree AV block).
3. Incomplete RBBB is not uncommon.
4. Non-specific ST elevation along with T wave flattening/inversion in precordial leads.

Cerebral diseases on the ECG :

Abnormal ECG is specially found in cerebral and subarachnoid haemorrhage (i.e., CVA), and the changes are :

1. ST depression, and flat to inverted T waves; precordial T waves may be wide and prominent (bizarre ST-T changesl.
2. Prolongation of the Q-T interval.
3. Prominent U waves.
4. Sinus bradycardia.

Pacemaker complex :

The prime indication of electrical pacing of the heart is Stokes-Adams syndrome. The ECG of such a person shows 'pace artefact' or 'pacing spike' (a vertical line) in the tracing. If pace artefact is to be removed, a special magnet should be used while recording the ECG.

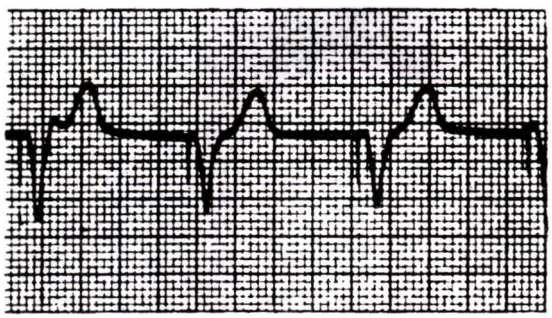

Fig. 4.62 : Right ventricular endocardial pacing. Pace artefact is seen before each QRS complex

ALWAYS REMEMBER THESE GOLDEN LINES

ECG is a simple laboratory test and like all laboratory findings, an abnormal tracing reveals significance if correlated clinically. An abnormal ECG tracing does not necessarily mean an abnormal heart and a normal tracing does not rule out pathology. A patient with a normal tracing may be dead after ten minutes from a coronary attack and another patient with grossly abnormal tracing may survive in this world for many years without having any cardiac symptoms.

CHAPTER V : EMERGENCY MEDICINE

EVALUATION AND MANAGEMENT OF COMA

In coma, the patient is deeply unconscious and there is no response evoked by external or internal stimuli. The Greek word 'kome' means deep sleep.

The common causes of coma are :

1. CVA (e.g., cerebral haemorrhage, massive cerebral infarction with oedema), encephalitis, meningitis, cerebral abscess, subdural or extradural haematoma, intracranial SOL, tentorial herniation, hypertensive encephalopathy, cerebral malaria, head injury, post-epileptic.
2. Diabetic ketoacidosis, hypoglycaemia, renal failure, hepato-cellular failure, respiratory failure, severe anoxia, myxoedema coma, pituitary apoplexy, adrenal crisis, hyponatraemia, eclampsia.
3. Stokes-Adams syndrome, arrhythmias, tight aortic stenosis, cardiogenic shock (e.g., AMI), hypotension, malignant hypertension.
4. Poisoning (barbiturate, organophosphorus, morphine), alcohol overdose, hypothermia, heat stroke, snake bite.
5. Severe sepsis.
6. Psychogenic.

* Structural lesion in the brain (affecting reticular activating system in diencephalon, and brainstem), toxic or metabolic derangements, and cardiac problems are the chief causes of coma.

** Altered consciousness is produced by three basic mechanisms, i.e., diffuse brain dysfunction (metabolic cause), direct effect within brainstem (pontine glioma), and pressure effect on the brainstem (mass lesion within brain) affecting reticular formation, brainstem and cerebral cortex.

Outline of evaluation :

Initial assessment should focus on history (from relatives/associates/eyewitriess) and general physical examination.

(A) History :

Onset, progress, premonitory symptoms, H/O epilepsy, features of increased intracranial tension (IIT), trauma (head injury), alcohol overdose, poisoning, suicidal tendency, high fever, dyspnoea, chest pain, jaundice, haematemesis/melaena, discharge from ear, urinary output, hypertension, diabetes mellitus; circumstances in which the patient was found to be unconscious should be specially asked for.

(B) Physical examination :

Perform a thorough physical examination. General appearance (flushed face with parotid swelling in chronic alcoholism), odour of breath, ears, eyes with special reference to pupil, jaundice, pattern of respiration (frothy sputum coming through nose in organophosphorus poisoning, or Cheyne-Stokes type breathing in metabolic coma), neck rigidity, tongue bite mark, involuntary movements, sweating, soiling of clothes, temperature, pulse (bradycardia in Stokes-Adams syndrome/IIT), BP, motor response (one side of the face may puff off with expiration in CVA with neurodeficit), hepatosplenomegaly (splenomegaly in cerebral malaria/typhoid state), and fundus examination (diabetic retinopathy, papilloedema in IIT) should be performed.

* In coma, plantar response in bilaterally extensor. Often the localisation of side of neurodeficit in CVA is not possible while the patient is in coma.

** Pupil examination :

a) Pin-point but reactive pupil—Pontine haemorrhage, organophosphorus poisoning, narcotic (morphine) overdose. Morphine poisoning also shows features of respiratory depression.
b) Bilaterally dilated and fixed pupil—Severe anoxic encephalopathy, glutethimide or atropine intoxication, dhatura poisoning.
c) Unilateral dilated and fixed pupil (anisocoria)—Oculomotor palsy caused by uncal herniation.
d) Midposition (4-5 mm) but fixed pupil—Midbrain lesion.
e) Hutchinson's pupil-—Head injury.
f) Horner's syndrome (unilateral) — Seen in hypothalamic damage.

*** So, a torch must be in hand while the doctor is in emergency.

**** Corneal reflex is absent in coma.

***** Measure the 'score' by Glasgow Coma Scale (eye opening, best motor response and verbal response).

(C) Investigations :

a) Urine—Specially for sugar, acetone and albumin.

b) Blood—Sugar, urea, creatinine, bilirubin, smear for malaria parasite, Na\ K^+; blood gas analysis. Blood should be sent for metabolic and endocrine studies (cortisol, TSH), and kept for drug screening (salicylates, barbiturates).

c) CSF—Meningitis, subarachnoid haemorrhage.

d) Examination of vomitus or gastric contents (toxicology screening)—Naked eye examination of appearance of undigested tablets, and the odour often clinch the diagnosis of drug overdose or poisoning.

e) ECG—Complete heart block, AMI, tachyarrhythmias.

f) X-ray—Usually not possible in a comatose patient. X-ray in lying down position may be taken for skull/chest (i.e., in injury).

g) CT Scan—May detect structural lesion in brain (if facility is available). Early CT scan is often inconclusive in CVA (e.g., cerebral infarction). EEG, radionuclide brain scan or angiography is dependent on the availability of facilities.

Classify coma on rapidity of evolution :

(A) Abrupt (i.e., within seconds or minutes) :

1. Cerebral haemorrhage.
2. Massive cerebral infarction.
3. Subarachnoid haemorrhage.
4. Cardiac arrest.
5. Epileptic convulsions.
6. Head injury.
7. Psychogenic.

(B) Acute (i.e., within a few hours) :

1. Cerebral haemorrhage or infarction.
2. Acute poisoning or drug-overdose.
3. Hypoglycaemia.

(C) Subacute (i.e., within few hours and a few days) :

1. Metabolic encephalopathy (hyponatraemia, hepatic or uraemic encephalopathy, anoxia or hypercapnoea, heat stroke, diabetic ketoacidosis, dyselectrolytaemias).
2. Encephalitis, meningitis, brain tumour.
3. Toxic encephalopathies resulting from severe infection e.g., cerebral malaria.

Outline of managment:

To maintain life, follow a -> b -> c -> d chronologically.

1. Place the patient on a soft mattress in supine position; bed with railed cot, if available; change of posture in every two hours. Prone in lateral position may prevent aspiration of gastric contents.
2. Maintain *'airway'* by neck extension/chin lift; place oropharyngeal airway tube or endotracheal tube; suck the oropharynx. Always try to prevent the falling back of the tongue.
3. Ensure adequate *'breathing'-,* if necessary, give mouth to mouth ventilation. In a desperate situation give 100% 0_2, ventilate with face mask or Ambu bag.
4. Maintain adequate *'circulation';* if carotid/femoral pulses are palpable, continue ventilation with 0_2. If pulses are not palpable and heart sounds are not audible, deliver a sharp blow to the centre of the chest. If heart does not start immediately, start cardiac massage at a rate of 1/second and ventilate mouth to mouth once/5 massages.
5. After resuscitation by basic life support put a Ryle's tube, insert IV catheter (intracath), apply a Foley's or condom catheter.

6. If necessary (make correction by *'drugs'),*
   a) Maintain circulation—By 5% dextrose, normal saline or plasma.
   b) Acidosis—inj. sodium bicarbonate (7.5%) 1 meq/kg, l.V; may be repeated after 10-15 minutes.
   c) To increase renal perfusion and to treat hypotension—By dopamine infusion at the rate of >5 |ig/kg/min; 200 mg of inj. dopamine is dissolved in 540 ml of normal saline to run at the rate of 10-12 drops/min.
   d) Suspected hypoglycaemia—100 ml of 25% glucose, I.V.
   e) Suspected morpine poisoning—Inj. naloxone 0.4-0.8 mg, l.V.
   f) Convulsions—Inj. diazepam 5-10 mg, slow l.V; may start inj. phenytoin 13-18 mg/kg in normal saline, not faster than 50 mg/min.
   g) Hypothermia—Cover with blankets, continue 0_2, correct acidosis by inj. sodium bicarbonate (7.5%) 1 meq/kg, l.V, to be given over 10 minutes.
      Hyperthermia—Start ice irrigation, ice bag on head, inj chlorpromazine—25 mg, I.M stat.
   h) Organophosphorus poisoning—Inj. atropine, 1-2 mg, l.V. to be repeated till the full dilatation of pupil. Start inj. pralidoxime 1-2 gin infusion of 100 ml of normal saline over 30 minutes. Forced alkaline diuresis is started in barbiturate poisoning.
   i) Copper sulphate poisoning- Start D-penicillamine 250 mg, 1 cap 4-6 hourly through Ryle's tube. In dhatura poisoning, start inj. neostigmine 1 mg, I.M. stat and repeat 4-6 hourly.
   j) Stokes-Adams syndrome—Maintain airway, start inj. atropine 0.6 mg, l.V; repeated, if necessary. Now, start isoprenaline drip by 2 mg dissolved in 540 ml of 5% dextrose, l.V. to maintain the heart rate at 70-80/ min. Permanent pacemaker should be implanted.
   k) Drug poisoning—Start gastric lavage, if not applied yet.
7. Diabetic ketoacidosis, hepato-cellular failure, renal failure, myxoedema coma, hypertensive encephalopathy, snake bite need special line of management (see afterwards).
8. Inj. hydrocortisone hemisuccinate—100 mg, l.V. stat and every 8 hourly. Often helpful in cerebral oedema, Stokes-Adams syndrome and myxoedema coma.
9. General care of the comatosed patient—
   a) Maintain intake-output chart.
   b) Prevention of cutaneous pressure sore (bed sore)—Frequent change of posture in bed, maintain local hygiene (by alcohol/spirit cleansing); bed should be dry and clean; use air cushions to protect pressure points; apply local antibiotic (with or without povidone iodine and metronidazole ointment) from the beginning of a small bed sore, and consult surgeon.
   c) Care of bladder, bowel and mouth—Condom catheter is preferable in male patients as indwelling catheters are common source of UTI. Constipation should.be managed by dioctyl sodium sulphosuccinate tablets (100 mg/tablet), 2 tab at bed time or by enema. Mouth care should be done by swabs soaked in boroglycerine/lotio mercurochrome (1%) or by sucker (prevents parotitis); fungal infection should be tackled by oral clotrimazole lotion.
   d) Maintain Ryle's tube, l.V catheter, condom/indwelling catheter (with an intake-output chart). Check pulse, respiration, BP, temperature **(vital signs)** regularly including pulse oximetry and continuous ECG monitoring. Recheck serum electrolytes.
   e) Start systemic antibiotic in the first chance, if evidenced by UTI, basal pneumonia etc.
   f) Maintain 'nutrition' and hydration by Ryle's tube feeding (3000 calories/day) or I.V alimentation.
   g) Eye care—Gentamycin or chloramphenicol eye ointment is applied (prevents exposure keratitis); taping of eyelids, irrigation as and when necessary.
   h) Start physiotherapy as soon as the patient recovers from coma (in CVA cases).
   i) Inj. ranitidine—50 mg, I.V, 3-4 times daily or sucralfate 1 g, 6 hourly, orally to prevent stress ulcer.
   j) Maintain normal body temperature.
   k) Record improvement by scoring of Glasgow Coma Scale.
   1) Move the legs and arms passively thrice daily to prevent leg vein thrombosis and frozen shoulder respectively.
10. Gastric aspirate and urine should be preserved for possible toxicological screening.

*** Psychogenic or hysterical coma :**

1. Very resistant to firm supraorbital pressure. Often shows forced eye closure in response to painful stimuli.
2. Plantar response—Bilaterally flexor.
3. May be associated with hyperventilation.
4. Absence of H/O spontaneous micturition, defecation or tongue bite.
5. Pupils—Bilaterally normal and reacting equally.
6. The patient is usually a young female under stress or familial dysharmony.
7. Increased tone in skeletal muscles in the presence of coma.
8. Normal caloric test, EEG or CT scan.

**** Doll's-eye movement (oculocephalic reflex) :**

The head of the comatosed patient is quickly rotated from side to side with the eyes kept open, and the positive response observed is conjugate deviation of the eyes to opposite direction to that of the head. For example, in a comatose patient if the head is quickly rotated to the left, the eyes will deviate to the right if the patient has 'intact brainstem' (with release from higher cerebral control). Absence of this reflex indicates severe structural lesion in brainstem or deep metabolic coma. This reflex is not present in normal persons.

***** 'Brainstem functions' are assessed by :**

1. Level of consciousness.
2. Pattern of respiration (e.g., Cheyne-Stokes respiration, apneustic breathing or ataxic type of breathing).
3. Pupillary size and reactivity.
4. Ocular movements (conjugate deviation, doll's-eye movement).
5. Oculovestibular reflex (caloric test).

****** Respiratory patterns in coma (or CNS disorders) :**

1. Post-hyperventilation apnoea (periods of apnoea after 5-10 deep breaths) — indicates bifrontal disease.
2. Cheyne-Stokes respiration—indicates supratentorial lesions (massive cerebral lesions).
3. Central neurogenic hyperpnoea (rather, it is like Kussmaul breathing i.e., deep, regular breathing with increased rate and depth) — indicates midbrain-upper pontine lesion.
4. Apneustic breathing (a pause of 2-3 seconds after full inspiration)

   or

   Biot's breathing (e.g., 3 to 4 respirations without waxing or waning, followed by a pause) - indicates lower pontine-level lesion.
5. Ataxic breathing (rhythm is chaotic, varying in rate and depth) — indicates lesion in medulla.
6. Hyproventilation (regular, rhythmic shallow breathing)—may have lesion in brainstem.

MANAGEMENT OF HEPATIC PRE-COMA/COMA

1. Read the 'general care of the comatosed patient' (see before).
2. In hepatic pre-coma, patient may be restless. Tie him with gauze and cotton, in a railed cot. Oxazepam (15-30 mg) may be given orally through Ryle's tube.
3. Blood is tested for :
   a) Serum bilirubin and other LFTs.
   b) Na\ K^+, HCO_3-; Ca^{++}, Mg+\ Po_4~-.
   c) Serum ammonia.
   d) Urea and creatinine; sugar (random).
   e) Prothrombin time.
4. Identify and remove possible precipitating factors e.g., electrolyte imbalance or drugs consumed with cerebral depressant properties.

5. Protein restricted diet. Recently protein restriction is discouraged to maintain nutrition; replace animal-based protein with vegetable-based protein.
6. Neomycin sulphate (for gut sterilisation)—4g/day or 3 cap (350 mg/capsule) 6 hourly to be given through Ryle's tube till revovery occurs. Metronidazole 200 mg, 6 hourly may be started in the absence of neomycin or where the patient suffers from concomitant renal insufficiency. Recently rifaximin (400 mg tds) has proved to be very effective.
7. Syrup lactulose—10-30 ml, three times daily to continue, orally or so as to cause two to three semisolid stools daily. Lactitol 30 g daily is compatible in efficacy to lactulose.
8. Inj. mannitol (20%)— 100 ml, 8 hourly, I.V (few clinicians prefer to run mannitol 300 ml, I.V rapidly in 30 minutes). It reduces cerebral oedema in hepatic pre-coma. Mannitol should be withheld in hepatic coma.
9. Maintenance of calorie, fluid and electrolytes—
   a) About 1500-2000 calories/day are required of which 1200 calories/day to be given in the form of 10-25% glucose.

   I.V. fluid direction (3 bottles/24 hours) :

   10% dextrose, followed by

   10% dextrose wih normal saline, followed by

   Darrow's solution.

   b) As hypokalaemia is a common complication, 60 meq/day of K^+ should be given in slow I.V route in three divided doses. Half of the dose may be given orally (syrup potassium chloride).
   c) Hypoglycaemia, hypomagnesaemia, hypocalcaemia and hypophosphataemia should be properly dealth with.
10. High bowel wash or enema 8-12 hourly daily for 2-3 days.
11. Inj. vitamin K — 10 mg I.M/I.V twice daily for consecutive 3 days.
12. Inj. ranitidine (50 mg/2 ml)—50 mg, I.V, 3-4 times daily till recovery.
13. Miscellaneous—
    a) Flumazenil, L-dopa (1-4 g/day, orally in divided doses) may be tried "j
    b) I.V. branched-chain amino acid, charcoal haemoperfusion may be beneficial I empirical
    c) Bromocriptine—2.5-15 mg/daily, orally J
    d) Judicious use of diuretics in treating oedema arid ascites.
    e) Manage haematemesis/melaena accordingly.
    f) Inj. ampicillin—500 mg, I.M/I.V, 6 hourly or inj. cefotaxime—lg, I.V, 12 hourly for 5-7 days in systemic infection.
    g) Inj. vitamin B complex- 2 ml, I.M/I.V once daily.
    h) Fresh blood, fresh frozen plasma or platelet transfusion in case of haemorrhage, if any.
    i) L-omithine L-aspartate (LOLA) given orally or parenterally promotes hepatic removal of NH_3 along with detoxication (of NH_3).
    j) Zinc supplementation may be helpful.

* In hepatic coma, clinical jaundice may be mild.

** Flapping tremor is present in hepatic pre-coma, absent in coma.

*** In the management of hepatic encephalopathy (pre-coma/coma), always be careful regarding electrolyte imbalance. It is very often the silent killer (specially, hypokalaemia). Paralytic ileus with diminished peristaltic sound is a bedside clue to hypokalaemia.

COMA IN A DIABETIC

The probable causes of coma in a diabetic are :

1. Hypoglycaemic coma (commonest cause).
2. Diabetic ketoacidosis (DKA).
3. Hyperosmolar hyperglycaemic non-ketotic coma (HHNK or HONK).
4. Lactic acidosis (rare).

5. Other causes of coma like,
   a) CVA,
   b) Renal failure,
   c) Hepatic coma,
   d) Drug-induced coma.

At first, try to differentiate between hypoglycaemic coma and DKA (see below).

Table 13 : Differentiation between DKA and hypoglycaemic coma

	Features	DKA	Hypoglycaemic coma
1.	History	No insulin; infection	Large dose of insulin; no food; heavy exercise
2.	Onset	Gradual	Sudden
3.	Symptoms and signs	Pain abdomen, vomiting	Hunger, drenching sweat, tremor, palpitation
	a) Tongue and skin	Dry	Moist
	b) Pulse	Weak	Bounding
	c) BP	Low	Normal or high
	d) Respiration	Air hunger	Shallow breathing
	e) Reflexes	Diminished	Brisk
4.	Urine examination	Sugar + Acetone +	Sugar - Acetone -
5.	Blood examination	Sugar T hco_3- 1	Sugar 1 $HC0_3$“ : normal

A patient of lactic acidosis may give H/O regular intake of metformin (big'uanides), if associated with severe hepatic or renal disease. HHNK is common in elderly type 2 DM patients.

* DKA patients may have Kussmaul's breathing with smell of acetone in breath.

Management :

(A) Hypoglycaemic coma—

Symptomatic hypoglycaemia occurs when the blood level of glucose is less than 55 mg/dl.

1. Inj. dextrose (25%)-—50 ml, I.V bolus to be followed by 5% dextrose infusion, I.V, rapidly until the patient is able to eat a meal. Blood sugar should be preferably kept above 150 mg/dl.
2. As soon as the patient is able to take food orally, start oral feeding with glucose, sucrose or sugar-containing liquids. Frequent monitoring of blood sugar is necessary.
3. In refractory cases, inj. glucagon 1 mg, S.C or I.M may be given and repeated after 10 minutes, if required.
4. If the patient is on insulin or oral hypoglycaemic agents (OHA). readjust the dosage schedule and reeducate the patient.

(B) Diabetic ketoacidosis—

Management of DKA should preferably be conducted in ITU (Intensive Therapeutic Unit). Success of treatment depends on close monitoring by the physician.

1. In an established case, the patient usually suffers from a fluid deficit of 7-8 litres (sodium loss is 500 mmol). It is better to correct the fluid loss in this way :

Normal saline volume	Time
1 litre	in 30 minutes
1 litre	in next 1 hour
1 litre	in next 2 hours
1 litre	in next 4 hours
4 litres	in next 16 hours

2. Inj. soluble (regular) insulin—Administer soluble insulin (0.1 units/kg as bolus) or I.M (0.3 units/kg), and then 0.1 unit/kg/hour by continuous I.V infusion, as long as normal saline drip continues. When the blood sugar level falls to 250 mg/dl, reduce the rate of insulin infusion to 3 units/hour. If the blood glucose concentration does not fall within 2 hours, the dose of insulin should be doubled.
3. When the blood sugar level reaches 250 mg/dl, the fluid is changed to 5% glucose (as a prophylactic measure to control late cerebral oedema, to prevent dangerous hypoglycaemia and to supply 'free water'). 12 units of soluble insulin is charged in each bottle to neutralise glucose (5%) present in the solution of the bottle. The rate of the fluid is adjusted according to the degree of dehydration and other parameters.
4. Inj. potassium chloride—This therapy is usually required after 4 hours of initial therapy (when acidosis tends to be corrected and the K^+ shifts intracellularly by the action of insulin). If plasma K^+ is <5.5 meq/L, give inj. potassium chloride 10 meq/hr; administer 40-80 meq/hr when plasma K^+ is <3.5 meq/L, or if bicarbonate is given. If oral feeding is possible, give syrup potassium chloride 2 g, 4 hourly for next 48 hours.
5. If P^H goes below 7.0, immediately start 300-500 ml of 1.4% isotonic sodium bicarbonate in place of same volume of normal saline, to run over 30 minutes. Slow correction of bicarbonate is often beneficial.
6. Infection is controlled by inj. cefotaxime or inj. ceftriaxone—1 g, I.V, 12 hourly.
7. 'General care of the comatosed patient' (see before) is followed meticulously. Blood sugar, serum $K^+$and $HC0_3^-$, pH, sugar and acetone in urine should be checked every 2 hourly till the patient regains consciousness.
8. As soon as oral feeding is possible, give fruit juices and frequent small fluid meals. Administer intermediate or long-acting insulin in place of soluble or short-acting insulin.

* Few clinicians prefer 'low-dose insulin' therapy from the beginning by 6-8 units/hour given I.V; as the question of insulin resistance can not be ruled out in few patients, many physicians advocate 25-50 units of soluble insulin/hour until the acidosis is reversed. Persistence of acidosis despite several hours treatment with insulin makes the clinician suspicious about insulin resistance.

** As there is phosphate depletion in DKA, potassium may be administered as phosphate salt in the place of potassium chloride, at least initially.

*** Plasma expander is used, I.V in hypotension. As gastroparesis diabeticorum is common in diabetes, gastric aspiration should be done to minimise the risk of aspiration pneumonia. Central venous pressure (CVP) is monitored in an ideal setting.

**** body temperature remains normal in DKA. If raised, think of infection. Try to find out the underlying cause (e.g., perianal abscess). A chest X-ray, ECG (to exclude AMI), urine and blood culture should be performed.

***** While managing DKA, a *'flow sheet'* containing timing and amount of parenteral fluid and insulin administered as well as recording of vital signs, urinary output and blood biochemistries should be maintained.

****** Inj. magnesium sulphate (50%) in doses of 2.5-5.0 ml (i.e., 10-20 meq magnesium), I.V can be administered in patients with ventricular arrhythmia.

******* DKA is a major medical emergency and remains a serious cause of morbidity and mortality. Other than fluid and electrolytes losses, complications encountered are ARDS, cerebral oedema, DIC, thromboembolism (leg veins and pulmonary) and acute circulatory failure.

(C) Hyperosmolar hyperglycaemic non ketotic coma (HHNK or HONK)—

In HONK, dehydration is profound; plasma osmolality is high.

1. If plasma osmolality is > 350 mosm/kg, start 1 /2 strength i.e., 0.45% saline until the osmolality becomes normal, when (0.9%) normal saline should be given. The rate of fluid infusion will be judged by monitoring CVP and plasma Na^+ concentration (if osmolality of plasma falls rapidly, there is a chance of developing cerebral oedema).
2. As these patients are usually insulin sensitive, half the dose of insulin advised in DKA should be employed here, at least initially.

3. Recognition and correction of the precipitating factors (e.g., infection, heat stroke, peritoneal dialysis, high carbohydrate diet, steroids etc).
4. Others—As done in DKA (inj. potassium chloride, antibiotic, general care etc); sodium bicarbonate requirement is less as it is a non-ketotic coma.

* Usually the fluid deficit is 10 litres or even more in HHNC. The hyperglycaemic hyperosmolar state (HHS; a new terminology for HONK) is diagnosed when plasma glucose is > 600 mg/dl, osmolality > 350 mosm/kg and there is absence of ketoacidosis; the p^H of blood is usually > 7.3 with HCO,, > 18 meq/L. The mortality ranges as high as 20-30%, mainly because of the advanced age. As there is absence of 'ketosis', features like pain abdomen, nausea, vomiting and Kussmaul's respiration are absent.

(D) Lactic acidosis—

Here, the $HC0_{3^-}$ deficit is enormous. The p^H should be kept over 7.2. Treatment is aimed at,

1. I.V sodium bicarbonate—May require 2500 mmol/24 hrs.
2. Soluble insulin—As given in DKA.
3. Often haemodialysis is required (if p^H does not rise above 7.0 on meticulous treatment).
4. Others—As done in DKA.

* Urine may not contain acetone, breath does not smell that of acetone in lactic acidosis. Plasma lactate is high (> 5.6 mmol/1) and diagnostic.

(E) Other causes of coma—

Read respective chapters.

SUDDEN RESPIRATORY DISTRESS

The common causes are :

1. Acute left ventricular failure (LVF) or acute left atrial failure (acute pulmonary oedema).
2. Acute exacerbation of bronchial asthma (acute severe asthma) or COPD.
3. Spontaneous pneumothorax.
4. Acute laryngeal obstruction (e.g., foreign body).
5. Acute pulmonary thromboembolism (PTE).
6. Cardiac tamponade.
7. Anaphylaxis.
8. Hysterical hyperventilation.

Outline of evaluation :

(A) History :

Onset (except bronchial asthma and hysterical hyperventilation, all are acute in onset), progress, H/O chest pain (pneumothorax) or ingestion of foreign body, H/O penicillin administration (anaphylaxis), personality disorder (hysteria), and past history (similar episode may occur in LVF or bronchial asthma) should be taken into account.

(B) Physical examination :

At first, examine the patient for orthopnoea and central cyanosis.

a) Cough ++ —Pneumothorax, LVF, foreign body.
b) Pulse— Pulsus alternans in LVF, pulsus paradoxus in acute severe asthma.
JVP—Raised in cardiac tamponade, LVF; prominent x-trough in tamponade.
c) BP—May be hypertensive in LVF.
d) Urticaria (involving lips, tongue) with itching—Anaphylaxis.
e) Trachea—Deviated to opposite side in pneumothorax.
f) Percussion—Tympanitic resonance on affected side is obtained in pneumothorax. Obliteration of liver and cardiac dullness may be revealed in acute severe asthma and COPD. Cardiac dullness is increased in tamponade.

g) Auscultation—
   (i) LVF—Rhonchi +, crepitations +++, gallop rhythm; vesicular breath sound with prolonged expiration.
   (ii) Acute severe asthma or COPD—Rhonchi +++ , crepitations +, heart sounds muffled; may have silent chest.
   (iii) Anaphylaxis, acute pulmonary thromboembolism—Vesicular breath sound with prolonged expiration, occasional rhonchi and pleural rub (in PTE).
   (iv) Spontaneous pneumothorax—Diminished vesicular or absent breath sound on affected side, no adventitious sound.
   (v) Cardiac tamponade—Muffled heart sounds.

h) Stridor—Anaphylaxis and laryngeal obstruction.
   Wheeze—In other situations.

i) RVH—Acute severe asthma, COPD.
   LVH—LVF.

j) Hysterical hyperventilation—Pause in between inspiration and expiration. No cyanosis; exaggerated in front of relatives. Carpo-pedal spasm may be seen due to tetany.

(C) Investigations :

At least, chest X-ray (PA view) and X-ray of neck (foreign body) should be done. Blood gas analysis may be informative.

* Read the differences between cardiac asthma and bronchial asthma from 'Bedside Clinics in Medicine, Part I'.

Outline of management :

(A) Acute LVF, acute LAF or acute pulmonary oedema (cardiac asthma)—

1. Propped-up position in bed with moist O_z delivered (100%) through face mask or nasal prongs with high flow rates i.e., upto 10 litres/min.
2. Inj. morphine sulphate—Slow I.V injection in a total dose of 5-10 mg, at a rate of 2 mg/minute or inj. pethidine 100 mg, I.M given. Large doses of morphine may produce respiratory depression and it should be aoided if systolic BP is < 90 mm of Hg.
3. Inj. frusemide—40 mg, I.V stat (or bumetanide 1 mg) and maybe repeated after 30 minutes.
4. Inj. aminophylline—It was once commonly used; chance of developing arrhythmia is there; 250-500 mg of the drug should be given I.V slowly, in not less than 20 minutes. It relieves bronchospasm and improves cardiac contractility.
5. Digitalis—Needs judicious use (as diuretics produce hypokalaemia and may precipitate digitalis toxicity in turn).
6. One tab. of nitroglycerine (0.5 mg/tab) is given sublingually, may be repeated after 1/2 hour. Inj. nitroglycerine (5-100 |og/min as infusion) may be given I.V to reduce the preload.
7. Afterload reduction by I.V sodium nitroprusside (20-30 |a.g/min) may be done if systolic BP is > 100 mm of Hg.
8. Dobutamine (2.5-15 |ig/kg/min) may be of some help (I.V) in cardiogenic pulmonary oedema with shock and hypotension.
9. Phlebotomy or venesection (250 ml) may by required in intractable cases. Rotating tourniquets may be applied in the extremities—they reduce the load in the heart by diminishing venous return. Keep the sphygmomanometer cuff inflated at 80 mm of Hg (i.e., at diastolic pressure) for 15 minutes; inefficient and rarely used.
10. The patient may be transferred to ICU for continuous monitoring of pulse, BP, respiration and cardio-respiratory status.

*** This is the treatment schedule of cardiac asthma too.**

**** Few special points in the treatment :**

a) The patient is most comfortable in 'trunk up, legs down' position, i.e., patient will be sitting with the legs dangling along the side of the bed. This reduces venous return and central venous pressure. I.V fluids should be restricted.

b) Morphine relieves anxiety, reduces venous filling pressure to the heart, shifts blood from lesser to the major circulation (pharmacological phlebotomy) and diminishes adrenergic stimuli to arteriolar as well as venous bed.

c) Aminophylline has bronchodilator, vasodilator, diuretic, cardiac inotropic and respiratory muscle inotropic effects.

I amp. of inj. aminophylline (10 ml) contains 250 mg of the drug. Usually it is diluted upto 50 ml with normal saline.

d) If digitalis has not been administered previously, 0.5 mg of the drug may be administered by slow I.V injection. Later, it may be followed by one tab. of digoxin (0.25 mg/tab) daily.

e) Sodium nitroprusside 50 mg is given in 500 ml of 5% dextrose by slow I.V infusion.

f) Correction of precipitating factors e.g., infection or arrhythmia, and underlying cardiac problem.

g) ACE inhibitors or angiotensin receptor blockers diminish both after- and pre-load; specially recommended in hypertensive patients.

h) Amrinone and milrinone may be added in severe left ventricular dysfunction.

*** In clinical practice, most common causes of heart failure are ischaemic heart disease (IHD), hypertensive heart disease and valvular heart disease.

**** **High-altitude pulmonary oedema** can be prevented by dexamethasone, calcium-channel blockers, or long-acting inhaled p_2-adrenergic agonists. The situation is treated by descent from altitude, bed rest, 0_2 therapy, inhaled nitric oxide and nifedipine.

(B) Acute severe asthma—

1. Propped-up position in bed with high concentration 0_2 inhalation through an intranasal rubber catheter at the rate of 4-6 litres/min. An I.V drip should be started with normal saline.
2. Inj. aminophylline—Loading dose is 5.8 mg/kg of body weight in 100 ml normal saline over 20 minutes, followed by maintenance dose as mentioned below :

   Patients with CCF or hepatic disorder—0.45 mg/kg/hour.

   Patients over 50 years of age—0.68 mg/kg/hour.

   Young patients-0.9 mg/kg/hour.

If the patient has used the drug sporadically, loading dose will be half in that situation; I.V drip is to be continued till the acute crisis is over. However, use of I.V aminophylline is not recommended by pulmonologists at present.

* I ampoule of inj. aminophylline contains 10 ml = 250 mg of the drug.

3. Inj. hydrocortisone hemisuccinate—I.V infusion.

   Loading dose—4 mg /kg of body weight for 4 hours.

   Maintenance dose—3 mg/kg/6 hour for next 24 hours.

   Or, inj. hydrocortisone, 200 mg I.V is given 4-hourly for 24 hours from the beginning.
4. The patient is reassessed. Measure 0_2 saturation with a pulse oximeter.
5. Nebulised salbutamol 5 mg or terbutaline 10 mg with 0_2 as the driving gas may be started and repeated 4-hourly.
6. Inj. Ampicillin—500 mg, I.M, 6 hourly or inj. cefotaxime - lg, I.V, 12 hourly for 5-7 days.
7. Antimuscarinic bronchodilators e.g., ipratropium bromide (20-40 (ig. 3-4 times daily) or oxitropium bromide (200 mg twice daily) by aerosol inhalation may be started with p_2-adrenoceptor stimulants. Nebulized solution may also be used.
8. If no improvement is seen, one of the following I.V infusions may be started :
   - Salbutamol 3-20 (xg/min,
   - Terbutaline 1.5-5.0 |ig/min, or
   - Magnesium sulphate 1.2-2 g over 20 minutes.
9. Assisted (mechanical) ventilation is required if :
   a) (i) $Pa0_2$ < 64 mm of Hg and falling

      (ii) $PaCo_2$ > 48 mm of Hg and rising

      (iii) pH < 7.3

   b) Patient goes into coma/respiratory arrest /exhaustion/extreme drowsiness/ totally confused.

10. After the acute attack is over, following drugs will continue :
    a) Tab salbutamol (2 mg) or terbutaline (2.5 mg)—1 tab. thrice daily, orally.
    b) Tab prednisolone (10 mg)—Strafed with 6 tablets in the morning, orally and gradually tapered within 2 weeks.
    c) Sodium'chromoglycate inhalation—20 mg (i.e., 2 puffs), four times daily or nedocromil sodium inhalation (4 mg, 2-4 times daily).
    d) Ketotifen—1-2 mg twice daily, orally.
    e) Leukotriene antagonist, montelukast (10 mg, orally, once daily in the evening) or zafirlukast (20 mg, orally, BD) may be used in mild to moderate persistent asthma.
11. Mucolytics (acetyl-cysteine) may be used during the acute attack.
12. Plenty of fluid with semisolid/liquid diet is given orally when the acute attack is over.

* Inhalation of salbutamol/terbutaline/corticosteroid/ ipratropium bromide may be used in between the attacks. Never sedate the patient during acute attack. Avoid beta-blockers.

** If the patient is not improved in time, check the arterial blood gases and do the chest X-ray (PA view) to exclude pneumothorax developing from acute severe asthma. The patient should be admitted in the hospital for at least 5 days.

(C) Spontaneous pneumothorax—

Read 'Bedside Clinics in Medicine, Part I'.

(D) Acute laryngeal obstruction (foreign body)—

Immediately send the patient to cardio-thoracic surgeon for bronchoscopic removal of the foreign body.

(E) Acute pulmonary thromboembolism (acute PTE or acute cor pulmonale) —

1. Absolute bed rest. Moist 0_2 inhalation at the rate of 4-6 litres/min.
2. Severe chest pain may be relieved by inj. pethidine 100 mg I.M or inj. morphine 15 mg I.M (avoid in severe hypotension).
3. Normal saline drip is started.
4. Inj. heparin sulphate—10000 units, I.V bolus stat; followed by 5000 units I.V, 6 hourly, charged in 200 ml of normal saline (via a side connector) for at least 5 days (may be continued upto 10 days). Low molecular weight heparin (LMWH) given in S.C route has the same effect as unfractionated heparin (e.g., enoxaparin is used in a dose of 1 mg/kg twice daily subcutaneously). LMWH is well tolerated, easier to administer, eliminates the need for frequent monitoring of PTT, and is the treatment of choice in acute PTE. The target INR should be 2.5.
5. Start oral anticoagulation with tablet warfarin sodium (5 mg/tab) from the 2nd day as 1 tab twice daily for at least 3-4 weeks till the patient becomes ambulant, and then tapered gradually (to keep the INR at 2.5-3.0). It may be continued for 6 months. Patients with underlying prothrombotic risk will continue it for life-long.
6. Inj. dopamine infusion in hypotension or shock—200 mg of dopamine (1 ampoule) is dissolved in 540 ml of normal saline. The bottle runs at the rate of 10-12 drops/min (<10 ng/kg/min) and the systemic BP is maintained near about 90-100 mm of Hg.
7. Thrombolytic (fibrinolytic) therapy—In massive embolism with systemic hypotension, sreptokinase or urokinase is injected into the pulmonary artery through a catheter (2.5 lakh units) followed one hourly by 1 lakh unit, I.V for 2-3 days. The treatment is very costly.
8. Digitalis—Digoxin 0-5 mg is given I.V, rapidly to increase the right ventricular output.
9. ACE inhibitors are tried but not much beneficial.
10. Surgical—Pulmonary embolectomy is now rarely performed.

* The dose of heparin is adjusted on the basis of clotting time/aPTT (maintained at 1'/$_2$-2 times of *controlled* value) and that of warfarin is adjusted by the result of prothrombin time (PT). LMWH needs no monitoring of coagulation profile.

** Predisposing factors for PTE :

1. Prolonged immobilisation in bed (predisposes deep venous thrombosis or DVT).
2. Post-surgical, pregnancy, post-partum state.
3. Fracture of long bones of leg.
4. Carcinoma (specially of pancreas).
5. Prolonged use of oral contraceptive pills.
6. Obesity.
7. Chronic deep venous insufficiency in legs.
8. LVF and RVF.
9. Acute myocardial infarction.

*** Ventilation-perfusion (V/Q) lung scans have traditionally been the main test for suspected PTE and a normal V/Q scan virtually excludes PTE; now-a-days contrast-enhanced spiral (helical) CT scan of lung is performed. Whenever the clinical data and non-invasive tests are equivocal or contradictory, pulmonary angiography is performed to diagnose PTE; recently CT pulmonary angiography has largely replaced conventional pulmonary angiography. Assay of plasma D-dimer is also helpful (if undetectable, excludes PTE).

In a patient of DVT, colour Doppler ultrasound of the leg veins remains the investigation of choice.

(F) Cardiac tamponade—

Immediate pericardiocentesis is done under echocardiographic monitoring (read 'pericardiocentesis' from 'Instruments and procedures' section).

(G) Anaphylaxis—

Vide 'Syringe (5 ml/50 ml)' in 'Instruments and procedures' section.

(Hj Hysterical hyperventilation—

1. Reassurance to the patient as well as to the relatives.
2. Rebreathing bag—A paper bag is kept over the mouth of the patient. She/he rebreaths for 5 minutes what has expired out, and this would allow $C0_2$ retention and correction of acid-base imbalance. This is helpful if the patient develops tetany (hyperventilation -> respiratory alkalosis -> alkalosis reduces ionic calcium) and syncopal attack after hyperventilation.
3. Often inj. diazepam 5-10 mg, I.M is helpful.
4. Psychological counselling.

CONGESTIVE CARDIAC FAILURE

Heart failure is a complex syndrome that develops when the heart can not function as a pump and is not able to maintain an adequate cardiac output or can do so only at the expense of an elevated filling pressure. The diagnosis of CCF (basically right ventricular failure) should be suspected from clinical presentation.

(A) Non-pharmacologic measures :

a) Restriction of physical activity helps to reduce myocardial work load and oxygen consumption. Complete bed rest in propped-up position, if dyspnoeic. 0_2 inhalation at the rate of 4-6 litres / minute relieves dyspnoea, reduces the work of breathing, and limits pulmonary vasoconstriction in patients with hypoxaemia. Check pulse and BP regularly. Try to find out the cause of CCF.

b) Salt restricted diet (normal diet contains 10-15 g of Nacl or 4-6 g of Na^+. Salt restricted diet means avoiding table salt or extra salt = 2-4 g of Na^+/day, and salt free diet means avoidance of table plus cooking salt = 1 g of NaVday. Restrict the fluid intake <1.5 litre/day, if found to be hyponatraemic (<130 meq/litre) or presents with volume overload.

(B) Pharmacologic therapy :

a) Diuretics — High potency loop-diuretic may be used; frusemide (40 mg/tab) 1 tablet daily to be taken in the morning (diuretic therapy reduces preload to the heart). Medium potency

thiazide diuretics may be used (hydrochlorthiazide 25-100 mg/day, indapamide 5-10 mg/day, orally), low potency potassium sparing diuretics may be added to loop diuretics (e.g., spironolactone 50-200 mg/day). Recently, it was noted that spironolactone has been shown to lower morbidity and mortality (upto 30% reduction in mortality), improve survival, and decrease hospitalisation in patients with heart failure and severe secondary hyperaldosteronism [spironolactone should not be used with ACE inhibitors, NSAIDs or in renal insufficiency, i.e., serum creatinine > 2.5 mg/dl]. The potassium loss by loop diuretics is adjusted by adding spironolactone to it.

b) Tab digoxin (0.25 mg/tab) *2-a* tablets on the first day, then 1 tab daily to continue. In old age or in the presence of renal insufficiency, 1 tab may be given daily for '5 days in a week'. One should be careful about the appearance of digitalis toxicity as the toxic : therapeutic ratio of the drug is narrow.

c) ACE inhibitors like enalapril (2.5/5/10/20 mg per tablet) — 2.5 - 5 mg tab daily to be taken in the morning or in divided doses. ACE inhibitors improve symptoms and survivals in patients of CCF (reduces preload as well as afterload). The treatment with this drug decreases ventricular filling pressure and thus increases the cardiac output, without little or no change in heart rate or BP. Captopril 6.25 mg, orally, TDS may also be given. Angiotensin II receptor blockers (e.g., losartan) may be useful in patients unable to tolerate ACE inhibitors because of intractable cough or angio-oedema.

d) (3-blockers—The deleterious effects of endogenous catecholamines on the failing heart (e.g., myocyte toxicity) can be antagonised by beta-blockers e.g., carvedilol (initiated at a dose of 3.125-6.250 mg, orally BD and is titrated to 25-50 mg, orally, BD), bisoprolol (initiated by 1.25 mg/day, orally and gradually increased to 10 mg/day), metoprolol (initiated by 12.5-25 mg/day, orally and gradually increased to 100-200 mg/day). A minimum of 2-3 months of therapy is required to observe significant haemodynamic improvement. One must be cautious in using these drugs in heart failure with very low ejection fraction. It is better to avoid p-blockers in patients having bradycardia, severe bronchospasm and heart block.

e) Reduce the dose of digitalis with the appearance of toxicity (may be given V tab daily and to continue as '5 days in a week' with 2 days rest/week). Periodic check up of urea, creatinine, Na*, K* is necessary.

* Arterial vasodilators (hydralazine, prazosin), venodilators (glycerol trinitrate) and inotropic agents (dobutamine) are not beneficial in CCF.

**** Specific treatment of heart failures :**

Forward failure — vasodilators and inotropes

Backward failure — diuretics and venodilators

Systolic dysfunction — diuretics and vasodilators

Diastolic dysfunction — vasodilators

*** Read different types of **shock** (hypovolaemic, cardiogenic, anaphylactic, obstructive [pulmonary thromboembolism] and septic) and **'systemic inflammatory response syndrome' (SIRS)** from any standard texbook.

REFRACTORY HEART FAILURE

Heart failure is considered refractory when the response to therapy becomes inadequate and the patient does not improve in due time. Probable possibilities are :

(A) Overlooked underlying otherwise correctable disease—Silent MS or AS, SBE, systemic hypertension, thyrotoxicosis or constrictive pericarditis.

(B) Precipitating cause of heart failure persists—Recurrent pulmonary thromboembolism, hypoxia, anaemia, arrhythmia, pulmonary infection, myocarditis, pregnancy.

(C) Complication induced by overzealous therapy—Digitalis toxicity, hypokalaemia, hyponatraemia or other electrolyte imbalance.

* *The most common complication results from vigorous therapy with diuretics.*

Management :

1. Carefully look for and correct the overlooked underlying cause or precipitating cause.
2. Search for complications of overzealous therapy e.g., hypovolaemia, dyselectrolytaemia or digitalis toxicity.
3. Easing up of salt restriction and diuretic administration temporarily.
4. Hyponatraemia is corrected by temporary cessation of diuretic therapy and restriction of oral water intake.
5. I.V sodium nitroprusside plus dopamine/dobutamine (raises cardiac output and lowers filling pressure) are started. As the patient feels better, combination of hydralazine/enalapril and amrinone (a phosphodiesterase inhibitor with positive inotropic and vasodilator actions) is used orally.
6. Cardiac transplantation may be considered if all of the above measures fail.

EVALUATION AND MANAGEMENT OF ACUTE CHEST PAIN

The common causes are :

1. IHD i.e., angina pectoris and acute myocardial infarction (AMI).
2. Acute dry pleurisy due to any cause.
3. Pneumothorax.
4. Trauma to the chest wall.
5. Diffuse oesophageal spasm (DES)/oesophagitis.
6. Costochondritis.
7. Malignant deposits on the ribs, rib fracture, intercostal myalgia, herpes zoster on the chest wall, multiple myeloma, acute dry pericarditis.
8. Dissection of ascending aorta.
9. . Hiatal hernia, gall bladder disease, acute pancreatitis.
10. Pulmonary thromboembolism (PTE).
11. Cardiac neurosis (psychogenic):

Outline of evaluation :

(A) History :

Onset, progress, pain with movement, actual site and character of pain, aggravating and relieving factors, duration, relation with food, associated symptoms (e.g., profuse perspiration and vomiting are present in AMI), dyspnoea present or not (AMI, pneumothorax, PTE, dissection of aorta are associated with dyspnoea), shock (AMI, tension pneumothorax, PTE etc), radiation of pain, any personality disorder should be taken into account.

* Retrosternal chest pain — AMI, dissection of aorta, PTE, DES, pericarditis.

** Character :

a) Tenderness—2, 4, 6 and 7 (musculoskeletal disorders).
b) Pleuritic in nature—2, 3, pericarditis and 10.
c) Chest pain with abdominal pain—AMI, basal pleurisy and 9.
d) Retrosternal chest pain with dysphagia—DES.
e) Diffuse chest pain with tenderness all over the chest—Trauma, cardiac neurosis.

(B) Physical examination :

Ashen-grey pallor, pulse, BP, JVP, cyanosis, oedema, decubitus, features of shock, vesicles on the chest wall, tenderness, heart sounds, gallop, pericardial rub, breath sound, rhonchi, crepitations, pleural rub should be meticulously searched/examined.

(C) Investigations :

a) If one investigation to be done, it is the electrocardiogram (ECG).

b) Chest X-ray (PA view).

c) Others : Cardiac injury enzymes (e.g., CK and CK-MB, AST, LDH, troponin T and *troponin I),* USG of abdomen, plasma D-dimer assay (e.g., PTE), barium swallow or upper G. I. endoscopy.

Outline of management :

(A) Angina pectoris (chronic stable angina)—

1. Acute attack :

a) Isosorbide dinitrate (5 mg/tab) or glycerol trinitrate (GTN; 0.5 mg/tab)—1 tab to be placed sublingually (GTN may be used as spray). Usually pain is relieved within 2-5 minutes. If not relieved, any of the drug may be repeated after 10 minutes. If the chest pain continues after use of 2/3 tablets, think of AMI.

b) Acetyl salicylic acid (75-150 mg/tab)—1 tab stat and to be continued indefinitely as 1 tab daily after meal. Clopidogrel (75 mg) - 1 tab daily may be started (instead of aspirin) or added with aspirin.

c) Alprazolam (0.25/0.5 mg per tablet)—1 tab stat and sos to allay anxiety. Diazepam (5 mg)—1 tablet may be given instead.

2. Prevention of further attacks :

a) Restful life. Avoid weight gain, smoking, exertion and psychic stress. Salt restricted, fat free, light diet.

b) Continue isosorbide dinitrate (5 mg/tab)—1 tab 4 times daily (may produce headache). Isosorbide-5 mononitrate (20 mg/tab) may be used instead (1 tab twice daily; 8 A.M. and 3 P.M.—known as eccentric dosage schedule).

* Propranolol—40 mg, twice daily, orally, or atenolol—100 mg, once daily orally, or bisoprolol—5-10 mg, daily, orally may be continued. Calcium channel blockers (CCB) like nifedipine-10 mg, 6 to 8 hourly daily (or sustained-release form), orally or amlodipine (2.5 - 10 mg daily, orally) or verapramil (120 - 240 mg, 8 hourly, orally, daily) or diltiazem (60-120 mg, 8 hourly, orally, daily) may be prescribed. (3-blockers reduce myocardial 0_2 demand by reducing heart rate and myocardial contractility. CCBs reduce myocardial 0_2 demand by relaxing coronary arteries and vasodilatation.

c) Prinzmetal's angina—Add nifedipine 5-20 mg, 8 hourly daily, orally.

d) Regular BP and ECG (resting) check up. Stress ECG (treadmill test) and echocardiography may be performed. The patient is advised to carry isosorbide dinitrate (5 mg/tab) or glycerol trinitrate (0.5 mg/tab) with him, and to be kept under tongue if there is chest pain. In uncontrolled angina pectoris, coronary angiography should be performed.

e) Associated systemic hypertension, diabetes mellitus, hyperlipidaemia (i.e., co-morbidities) should be treated by diet control and drugs. Correct exacerbating factors contributing to angina e.g., obesity, CCF, anaemia or hyperthyroidism.

f) In intractable angina pectoris—Patient may be advised to do coronary angiography with a view to undergo coronary artery bypass grafting (CABG) or percutaneous transluminal coronary angioplasty (PTCA).

** Angina pectoris was first described by Heberden in the year 1772.

*** Internal mammary artery or reversed segments of saphenous vein of patients are used for CABG.

**** Angina without coronary artery occlusion may be seen in severe myocardial hypertrophy, severe AS or AI, severe anaemia, hyperthyroidism or paroxysmal atrial tachycardia with rapid ventricular rate.

(B) Acute myocardial infarction (AMI)—

1. First aid :

a) Bed rest. Give reassurance. Moist 0_2 inhalation at the rate of 4-6 litres/minute.

b) Tab isosorbide dinitrate (5 mg/tab) or tab glycerol trinitrate (0.5 mg/tab)—1 tab to be kept under tongue immediately and to be repeated every 5 minutes till relief of chest pain. Discontinue if hypotension develops.

c) Insert I.V cannula, if possible.

d) Inj. morphine sulphate (to combat excruciating chest pain)—10 mg, I.V stat, may be repeated (5 mg, I.V) if necessary.

e) Acetyl salicylic acid (aspirin; 150-300 mg/tab)—1 tab stat to be chewed or clopidogrel 300 mg given orally as gel.

f) Inj. cyclizine tartrate—50 mg, I.V stat, or inj. metoclopramide 10 mg, I.V stat (as an antiemetic).

g) Start slow I.V drip of 5% dextrose solution as an emergency I.V channel.

h) Carry out 12 lead ECG. Take blood for cardiac enzymes (CK, CK-MB, AST, LDH, troponin T and troponin I), blood count, ESR, electrolytes (Na^*, K^+, Mg^{++}), glucose and lipid profile. Repeat the enzymes study at 12 hrs and 24 hrs. Remember, **CK-MB is elevated in** AMI, myocarditis or after electrical cardioversion.

i) Patient is shifted to ICU at the earliest opportunity.

2. Specific therapy :

If the patient comes within 12 hours (preferably within 6 hours) of the onset of symptoms,

a) Thrombolysis by inj. streptokinase—1.5 million units dissolved in 100 ml of normal saline and infused by I.V route over 1 hour.

Anistreplase (30 units, single I.V injection given over 5 minutes), alteplase or human tissue plasminogen activator (I.V infusion schedule as—15 mg bolus followed by 50 mg in the first 30 minutes and then 35 mg in the next 1 hour), urokinase (1.5 million units bolus plus 1.5 million unit as infusion over $1^1/_2$ hours) may be substitute of streptokinase.

b) I.V atenolol (10 mg) or metoprolol (10 mg) relieves pain, reduces the chance of arrhythmias and also diminishes the size of infarction—if the patient is attended within 12 hours of the onset of symptoms. (3-blockers are helpful to combat ongoing chest pain, tachycardia and hypertension. In hypotension, bradycardia, CCF and heart block, (3-blockers can not be used.

* Inj heparin, S.C, 5000 units twice daily may prevent deep vein thrombosis and left ventricular thrombus formation. After successful thrombolysis, inj. heparin 5000 units, S.C, twice daily may be continued for 7 days (in addition to daily oral aspirin). Enoxaparin, a LMWH may be used 1 mg/kg twice daily, subcutaneously instead. Oral anticoagulation with warfarin sodium may follow inj. heparin.

** ACE inhibitors reduce mortality. Captopril 6.25 mg there times daily (may be increased) should be started early (in patients who are haemodynamically stable) and may be continued (to counteract ventricular remodelling) after discharge from the hospital. Enalapril (5 mg, orally daily) or lisinopril (5 mg, orally daily) may be used instead.

3. Treatment of complications :

a) LVF—See before.

b) CCF—See before.

c) Sinus bradycardia—Elevation of the legs and/or foot end of the bed; inj. atropine 0.6 mg, I.V stat.

d) Sinus tachycardia—Inj. propranolol 2.5 mg, I.V and may be repeated.

e) Hypertension—Inj. diazepam 10 mg, I.V may be given.

f) Atrial fibrillation or flutter—Digoxin 0.25 mg I.V stat; synchronised DC shock in rapid ventricular rate with hypotension or circulatory collapse.

g) Paroxysmal atrial tachycardia—Inj. verapramil 10 mg, I.V.

h) Ventricular fibrillation—DC shock, cardiopulmonary resuscitation (CPR).

i) Cardiac asystole—CPR; if fails, temporary pacemaker.

j) Heart block—Inj. atropine 0.6 mg, I.V stat, repeated if necessary; pacemaker.

k) Ventricular premature beats—Inj. lignocaine 1 mg/kg, I.V, followed by an I.V infusion of 1-4 mg/min. Serum magnesium level maybe measured and repleted if necessary to reduce the risk of ventricular arrhythmia.

1) Cardiogenic shock—0_2 (8-10 litres/min), normal saline drip, dopamine infusion (2-20 *ig/* kg/min), inj. hydrocortisone hemisuccinate (200 mg, I.V stat and repeated 100 mg, 4 hourly, I.V), intra-aortic balloon counterpulsation may be tried. Arrhythmias should be carefully dealt with.

m) Chest pain— Inj. morphine sulphate, 5 mg, I.V. stat given and may be repeated after 10-15 minutes. In recurrent chest pain I.V nitroglycerine at the rate of 0.6-1.2 mg/hr and I.V. heparin (1000 unit/hr) are to be infused.

* Ongoing chest pain, arrhythmias, CCF and shock are common complications in AMI.

** If percutaneous coronary interventions (PCI) are planned (i.e., percutaneous transluminal coronary angioplasty i.e., PTCA, or stent placement in the coronary artery'), start glycoprotein Ilb/IIIa inhibitors (i.e., abciximab, tirofiban, eptifibatide).

4. Symptomatic treatment :
   a) Constipation—Tablet dioctyl sodium sulphosuccinate 200 mg at bed time/Isapgol husk 2-4 tsf in tepid water at bed time.
   b) Restlessness—Diazepam (5mg/tab), 1 tablet twice daily may be given.
5. General treament :
   a) Record vital signs regularly.
   b) Low calorie diet: multiple small feeds from the 2nd day onwards (liquid diet on the 1st day). Diet should contain fibres. Stop smoking.
6. Discharge :
   a) Usually after 7-10 days (depends on complications) with an advice to restrict physical activities for 4-6 weeks.
   b) Advise and liaise with family physician.
   c) Continue,
      (i) Tab aspirin (75-150 mg/tab) or clopidogrel (75 mg-150 mg/tab)—1 tab daily after meal to continue indefinitely until further advice.
      (ii) Tab atenolol (25/50/100 mg/tab)—25-50 mg daily to continue until further advice. Metoprolol 25-50 mg orally, twice daily may be given instead.
      (iii) Tab isosorbide-5 mononitrate (20 mg/tab)—1 tab twice daily (8 A.M. and 3 P.M.; eccentric dosage schedule to prevent nitrate tolerance) to continue until further advice. Tab isosorbide dinitrate (5 mg/tab)—1 tab to be placed sublingually, sos at the onset of chest pain.
      (iv) Tab captopril (25 mg/tab)—1/2 to 1 tab three times daily to continue until further advice. Ramipril (2.5-10 mg) orally daily or lisinopril (5-10 mg) orally daily are other alternatives.
      (v) Statins—Atorvastatin (5-20 mg) or simvastatin (5-20 mg) orally daily given at bedtime to control hyperlipidaemia.
7. Review :
   a) Usually at 1 month.
   b) Carry out exercise test.
   c) Review secondary prevention (avoid smoking, control hypertension and diabetes, taking regular exercise, control weight gain, lower lipid level by diet control and statins) and screening of the family.

* *Relative contraindications of thrombolytic (e.g., streptokinase) therapy :*

1. Recent major surgery (within 1 month).
2. Active internal bleeding (probable active peptic ulcer bleeding, menstruation).
3. Past H/O intracerebral or subarachnoid haemorrhage.
4. A recent head injury, even if minor/recent trauma.
5. Pregnancy.
6. Uncontrolled hypertension.
7. Diabetic retinopathy (proliferative).
8. Acute pericarditis or dissection of aorta.
9. Acute pancreatitis.
10. Recent streptococcal infection.

** *Aim of initial therapy in AMI* is to relieve pain, reduce the size of infarcted tissue, prevent/treat arrhythmias and mechanical complications.

*** Clopidogrel (75 mg) - 1 tablet, orally daily may be an alternative to aspirin (may be added to aspirin). Clopidogrel may be used where aspirin is strictly contraindicated like acute gastritis, H/O chronic duodenal ulcer, H/O recurrent upper G.I. bleeding, acute gout (low dose aspirin is contraindicated) or incipient renal failure.

**** **Right ventricular infarction** is suspected by : T JVP, *I* cardiac output and hypotension, Kussmaul's sign, right ventricular S_3 or S_4, absence of pulmonary congestion, presence of TI murmur and oedema in the background of inferior wall infarction.

***** At present thrombolytic therapy is not recommended for NSTEMI (non-ST-elevation myocardial infarction) and unstable angina.

(C) Musculoskeletal disorders—

1. Hot fomentation followed by local analgesic gel application (e.g., diclofenac gel).
2. NSAID e.g., ibuprofen 400 mg, 8 hourly, orally after meals, plus tab antacid—1 tab, 8 hourly, orally to be taken after meals.
3. Alprazolam—0-25 mg tablet, orally at bed time.

(D) Acute dry pleurisy—

1. Rest in bed.
2. Relief of chest pain by,
   a) Hot fomentation.
   b) Splinting of the chest wall with leucoplast strapping (old practice).
   c) Analgesics e.g., indomethacin 25 mg, 8 hourly, orally after meal along with tablet antacid.
   d) Sedatives.
3. Treatment of the underlying aetiology.

(E) Acute dry pericarditis—

1. Rest in bed.
2. Hot fomentation, analgesic and sedatives are not of much value.
3. If pericardial effusion develops—echocardiography-guided pericardiocentesis is to be done.
4. Treatment of the underlying aetiology (viral, tuberculous, uraemic etc).

* Cardiac tamponade is a medical emergency; so, treat acute dry pericarditis at the earliest.

(Fj Herpes zoster—

1. Calamine lotion or povidone iodine solution—as local application; acyclovir cream may be applied 4 hourly for 7 days.
2. Acyclovir (800 mg/tab)—1 tab 5 times daily for 7 days. Valacyclovir 1 g, 8 hourly may be used.
3. NSAID e.g., indomethacin 25 mg, 8 hourly, orally after meals along with tablet antacid.

[4. Post-herpetic neuralgia is managed by amitriptyline/carbamazepine/gabapentin. Transcutaneous nerve stimulation (TENS) with aggressive analgesia is helpful.)

(G) Diffuse oesophageal spasm—

1. Nifedipine (5 mg)—1 tab stat, orally, twice daily to continue.
2. Glycerol trinitrate (0-5 mg/tab)—1 tab to be used sublingually stat and sos.
3. Tranquilisers e.g., alprazolam 0-25-0-5 mg, orally daily at bed time to continue.
4. Oesophageal dilatation with mercury-filled rubber dilators.
5. Surgery—Longitudinal myotomy of oesophageal circular muscles in intractable cases.

(H) Cardiac neurosis—

1. Reassurance to the patient as well as to the relatives.
2. Inj. diazepam—10 mg, I.M stat.
3. Tab alprazolam—0-25 mg, orally at bed time to continue.
4. Psychological counselling.

N.B. : ***Unstable angina*** is managed by,

1. Absolute bed rest. Continuous ECG monitoring. Rule out AMI by ECG and cardiac enzymes.
2. Aspirin 75-300 mg/day. Clopidogrel (75-150 mg, orally, daily) or ticlopidine (250 mg, BD,.orally) may be used.

3. Atenolol 50-100 mg daily or metoprolol 50-100 mg twice daily, orally. If beta-blockers are contraindicated, it is better to start diltiazem (60 mg thrice daily) or verapramil (40 mg thrice daily).
4. If pain persists, anticoagulation is done by I.V heparin (1000 unit/hour, adjusted by PTT), and
5. I.V nitroglycerine (for refractory pain)—Started at 10 ng/min and maintained at systolic BP > 100 mm of Hg.
6. Identify exacerbating factors e.g., TBP, arrhythmia, acute infection or chronic heart failure, and treat them accordingly.
7. Patients refractory to medical treatment are advised to do coronary angiography with a view to undergo CABG or PTCA.

Definitions :

(A) Unstable angina— it includes a) recent onset of severe angina (< 2 months), b) angina at rest or with minimal activity, c) recent increases in frequency as well as intensity of chronic anginal pain, and d) recurrent angina within several days of AMI without re-elevation of cardiac enzymes.

(B) Angina decubitus— anginal pain while lying flat.

(C) Nocturnal angina— unusual form of anginal pain which occurs at night and may be associated with dyspnoea, palpitations or nightmares; commonly seen in aortic regurgitation.

(D) Prinzmetal's or variant angina— pain occurs as a result of coronary arterial spasm and is accompanied by transient ST segment elevation in ECG without any increase in cardiac enzymes.

* **Acute coronary syndromes (ACS)** include unstable angina, ST-elevation myocardial infarction (STEMI) and non-ST-elevation myocardial infarction (NSTEMI).

DRUG THERAPY IN HYPERTENSIVE EMERGENCIES

Hypertensive crises are life threatening events which demand immediate medical attention. It is an acute perilous state associated with marked increase in peripheral vascular resistance and decrease in tissue perfusion. This syndrome consists of:

1. Malignant hypertension.
2. Hypertensive encephalopathy.
3. Hypertensive acute LVF/acute pulmonary oedema.
4. Dissection of aorta/leaking aneurysm of aorta.
5. Eclampsia.
6. Epistaxis associated with hypertension.
7. CVA (cerebral haemorrhage commonly; also cerebral infarction and subarachnoid haemorrhage).
8. Hypertension related decreasing renal function.
9. Severe hypertension associated with pheochromocytoma.
10. Severe hypertension related peripheral vascular diseases.

* No. 1, 2, 3, 5 and 7 are commonly encountered problems.

Hypertensive 'emergency' : Severe elevation in BP accompanied by acute target organ damage, which must be reduced within minutes, ususally with parenteral medication. Above mentioned 10 points are examples of the situation.

Hypertensive 'urgency' : Severe elevation in BP without any target organ damage, which must be reduced within hours, usually with oral drug therapy. The examples are postoperative hypertension, uncontrolled hypertension in patients requiring surgery, accelerated hypertension or hypertension associated with severe bum/post-organ transplantation.

Outline of management:

1. Complete bed rest; propped-up, if necessary. Hospitalisation is a must.
2. Diet—Salt free diet (avoidance of table salt plus cooking salt), i.e., 1 g of NaVday is allowed; *liquid* diet till the crisis is over. Restrict cholesterol, saturated fat; stop smoking; perform isotonic or aerobic exercise regularly (cycling, swimming, jogging) after recovery and are followed life-long (lifestyle modifications).
3. Take details history to come to a pin-point aetiological diagnosis. Check BP at 10 minutes interval. Perform ophthalmoscopy.

4. a) Insert I.V cannula and send blood for sugar, urea, creatinine, VMA (vanillylmandelic acid for pheochromocytoma).

b) Inj. diazepam—10 mg, I.M stat given.

5. Primary target is to lower the sustained high level of BP by antihypertensives to prevent further target organ damage (majority are administered through I.V route):

a) Sodium nitroprusside—The bottle has to be protected from light because it can decompose into toxic thiocyanates. Dose—initially 0.3 ()ig/kg)/min. I.V; usual 2-4 (|ig/kg)/min; maximum 10 (mg/kg)/min for 10 min.

b) Diazoxide—This is given in the dose of 50-100 mg over 5 minutes in slow I.V bolus and may be repeated. It should not be used with H/O coronary insufficiency and CVA (precipitous fall of BP may occur).

c) Hydralazine—5-10 mg, I.V bolus dose is given at every 15 minutes (maximally 50 mg).

d) Nicardipine—Initially 5 mg/hr; titrate by 2.5 mg/hr at 5-15 intervals; maximum 15 mg/hr. Putting the punctured nifedipine capsule sublingnally for rapid reduction of BP is not practiced now as sudden death may supervene.

e) Frusemide—1 amp (2 ml = 20 mg), I.V stat in shot push and may be repeated after V hour, if necessary. Electrolyte imbalance (especially hypokalaemia) may pose a problem.

f) Reserpine (not a very popular drug at present)—It can be given in the dose of 2-5 mg, every 3 hourly by I.M route. The onset of action is delayed (not prompt like the drugs mentioned above).

g) Enalaprilat (intravenous form of enalapril)—The dose is 0-625-1.25 mg, I.V, over 5 minutes, and is given stat and every 6-8 hours; maximum 5 mg/dose.

h) Labetalol—2 mg/min upto 300 mg, or 20 mg over 2 min, then 40-80 mg at 10 min-intervals upto 300 mg total dose.

i) Esmolol—Initially 80-500 ng/kg over 1 min, then 50-300 (|ug/kg)/min to be maintained,

j) Nitroglycerine—Initially 5 (ig/min, then titrate by 5 ng/min at 3-5 min intervals; if no response occurs at 20 (ig/min, one may incrementally increase the dose by 10-20)ig/min.

k) Phentolamine—5-15 mg bolus dose.

6. Discharge the patient with some advice (mentioned in point No. 2) and antihypertensive medications (ACE inhibitors, calcium channel blocker etc).

* In case of cerebral haemorrhage and infarction (i.e., CVA), immediate reduction of high BP may hamper cerebral autoregulation and exacerbate cerebral damage. So, CVA is an exception among hypertensive emergencies where urgent BP reduction may be injurious to the patient.

Table 14 : Different drugs in hypertensive emergencies

	Hypertensive emergency	Drug (s) of choice	Drugs to be avoided
1.	Hypertensive encephalopathy	Nitroprusside, diazoxide, labetalol	Methyl dopa, reserpine
2.	Hypertension with LVF	Nitroprusside, enalaprilat, loop diuretics	Hydralazine, nifedipine
3.	Hypertension plus renal failure	Nitroprusside, diazoxide, hydralazine, frusemide	Trimethaphan
4.	Malignant hypertension	Nitroprusside, hydralazine, frusemide, enalaprilat	--
5.	Hypertension with pregnancy	Methyl dopa, labetalol, nicardipine, hydralazine, atenolol	Nitroprusside, diazoxide, enalaprilat
6.	Hypertension with subarachnoid haemorrhage	Nitroprusside, nicardipine	Methyl dopa, reserpine
7.	Pheochromocytoma	Phentolamine, nitroprusside	All other drugs
8.	Dissection of aorta	Nitroprusside, esmolol, labetalol	Diazoxide. hydralazine
9.	Hypertension associated with AMI or severe angina	Labetalol, nitroglycerine, nicardipine, esmolol	Nifedipine

* Hypertension in pregnancy is indicated at BP > 140/90 mm of Hg plus proteinuria; severe pre-eclampsia is indicated at BP > 160/110 mm of Hg, proteinuria > 5 g/day, visual disturbances or headache.

Reasons for poor therapeutic response in hypertension ;

(A) Poor patient's compliance, suboptimal dose.

(B) Gain in weight, smoking, insulin resistance, sleep apnoea, ethanol intake (> 30 ml/day).

(C) Volume expansion done by,

a) Excessive intake of salt.

b) Secondary to non-diuretic antihypertensive drugs.

c) Inadequate diuretic therapy.

(D) Secondary hypertension (i.e., not idiopathic).

(E) Using one class of drugs (in that situation, try different classes).

(F) Drug antagonism by,

a) Oral contraceptive pills.

b) Corticosteroids.

c) Sympathomimetics.

d) Carbenexolone.

e) Nasal decongestants, licorice (as may be found in chewing tobacco), erythropoietin, antidepressants.

(G) Pseudo-resistance : 'White coat hypertension', use of regular cuff on very obese arm.

MANAGEMENT OF AN UNCONSCIOUS PATIENT WITH BRADYCARDIA

The common causes of bradycardia encountered in day to day practice are

1. Athletes or during sleep.
2. Myxoedema.
3. Obstructive jaundice.
4. Increased intracranial tension.
5. Drugs like propranolol, digitalis or verapramil.
6. Hypothermia.
7. Complete heart block (CHB).
8. Sick sinus syndrome.
9. Vasovagal attacks.

* Except the CHB, all are established cause of sinus bradycardia. In CHB, there is generation of idioventricular rhythm at the rate of 36-40/minute (obviously it is not sinus bradycardia). Now, while considering bradycardia in an unconscious patient, few of the above causes come in mind, e.g.,

1. Complete heart block (Stokes-Adams syndrome).
2. Increased intracranial tension.
3. Sick sinus syndrome.
4. Myxoedema coma.
5. Hepatic coma form obstructive jaundice (rare).
6. Hypothermia (rare).

D/D among these causes are easy and overt.

(A) Stokes-Adams syndrome—

1. Stoppage of the precipitating agent e.g., digitalis, propranolol etc, if any; A sharp blow over the precordium is often enough to start the cardiac impulse. External cardiac massage as well as mouth to mouth respiration may be initiated. Moist 0_2 inhalation at the rate of 4-6 litres/minute is started.

2. Before inserting temporary pacemaker, following drugs can be given :

a) Inj. isoprenaline sulphate—Direct I.V injection of 01-0-4 mg of the drug, or 2 mg dissolved in 540 ml of 5% dextrose solution to be infused at the rate of 1-10 (xg/min (by drip rate

approximately 15 drops/mlnute) so as to keep the heart rate between 70-80/minute. Afterwards, tablet isoprenaline (20 mg) may be prescribed 1 tab thrice daily to be taken orally, or tablet orciprenaline (10 mg) 1 tab thrice daily to be taken orally.

b) Inj. sodium bicarbonate — 50 ml of 7-5% $NaHC0_3$, I.V is given immediately and may be repeated (to combat acidosis).

c) Inj. hydrocortisone hemisuccinate—100 mg I.V may be given stat to relieve oedema around the AV node, if any (not advocated by all). The drug may be repeated, if necessary.

d) Inj. adrenaline—0-2-0-5 ml of 1 : 1000 solution of the drug may be given I.M, I.V or even in intracardiac route (be sure by ECG that the asystole is not due to ventricular fibrillation). Few clinicians try inj. atropine 0-6 mg, I.V stat.

e) It is better to transfer the patient in ICU for further management.

f) Immediate implantation of permanent pacemaker, if facilities are available.

* **Sequence of events in Stokes-Adams syndrome :**

Vertigo and headache—at 3 seconds; fainting—at 6 seconds; unconsciousness—at 9 seconds; convulsions—at 12 seconds; death—if cardiac asystole persists for > 2 minutes.

Sudden loss of consciousness may occur without any warning and often result in a fall. During the attack, pallor is observed and flushing appears after recovery; in prolonged bradycardia, pallor may change over to cyanosis. Stokes-Adams syndrome is manifested by sudden loss of consciousness (or syncope or black-out due to ventricular asystole) unrelated to posture and may arise from complete heart block, ventricular tachycardia or fibrillation, Mobitz type II block, profound bradycardia or sinoatrial disease.

** Most of the attacks are very brief and may disappear before the physician arives. The future plan should be to prevent such attacks.

(B) Increased intracranial tension—

—See afterwards.

(C) Sick sinus syndrome—

1. Inj. isoprenaline—Direct I.V injection of 0T-0-4 mg of the drug; or Inj. atropine—0-6 mg, I.V stat given. In structural disease of the SA node, both the drugs are unlikely to be successful.
2. Permanent pacemaker (demand type) is the answer of the 'bradycardia-tachycardia syndrome'. As associated disease of the AV conduction system is not infrequent, pacing from the ventricles is commonly indicated; pacing of the atrium may prevent episodes of atrial fibrillation.

(D) Myxoedema coma—

1. Triiodothyronine—20 (xg 1 .V bolus is followed by 20 (ig every 8 hourly until there is sustained clinical improvement. If thyroxine (TJ is available, it is given as I.V bolus in a dose of 200- 300 mg and may be continued in a dose of 100 |ig/day by I.V or orally.
2. Hydrocortisone hemisuccinate—100 mg I.V stat and continued every 8 hourly. It is followed by tapering doses of oral steroids when consciousness is regained.
3. I.V saline infusion to combat hypotension.
4. Combat hypothermia with 'slow rewarming' of the patient by wrapping with a blanket in a warm room.
5. High-flow oxygen or assisted ventilation.
6. Treatment of arrhythmia and heart failure accordingly. Preferably management should be done in an ICU.
7. Inj. ampicillin 500 mg, I.M, 6 hourly, or any broad-spectrum antibiotic since many a time infection in a common precipitating factor.
8. Blood should be sent for T_3, T_4, TSH, Na^+, $Pa0_2$, $PaC0_2$, p^H and R/E (TC/DC).
9. Try to correct hypotension, hypothermia, hypoglycaemia, electrolyte imbalance and respiratory failure.

* As injection of T_3 and T_4 are not always available, attending physician is often compelled to give :

a) Tab triiodothyronine (50 pg/tab)—2 tab stat, then 1 tablet 4 times daily until clinical improvement occurs (pulse, BP, temperature are the guidelines), or

b) Tab levothyroxine (100 |ig/tab)—2 tab stat and then 1 tab daily to continue until clinical improvement occurs.

** It is a life-threatening emergency. As T_3 is biologically more active than T_4, most physicians recommend I.V T_3 over T_4.

(E) Hepatic coma from obstructive jaundice—

—See before.

(F) Hypothermia (temp < 95°F)—

* Mild 95°F-89-6°F, moderate 89-6°F-82-4°F and severe hypothermia < 82-4°F.

** Possible causes are :

a) Accidental exposure to cold weather (specially in alcoholics, elderly, babies, diabetics, street beggars and in mountain climbers).
b) Malnutrition, sepsis.
c) Myxoedema coma, hypothalamic lesions, hepatic coma, Addisonian crisis, hypoglycaemia, CVA.
d) Drug-induced e.g., phenothiazines, ethanol, opiates, lithium, benzodiazepines.
e) Immersion hypothermia.
f) Artificial hypothermia induced in open heart surgery.

Management :

1. Cover the patient with blankets in a warm environment (room). A plastic sack or 'space blanket' may be used (if available) if no shelter is available. Gradual warming is done with an aim to increase core temperature by l°C/hour. Keep the patient horizontal or slightly head down.
2. O_2 inhalation (warm)—4-8 litres/min.
3. 5% dextrose drip (I.V) or warm isotonic saline is started immediately (in an attempt to maintain the blood volume).
4. Internal rewarming technique—Extracorporeal rewarming by haemodialysis and cardiopulmonary by-pass; inhaled humidified air or peritoneal lavage may be done.
5. Inj. sodium bicarbonate—50 ml of 7.5% of the solution may be given I.V, if p^H is < 7-2.
6. Erythromycin 250 mg, 4 times daily, is started orally to prevent pneumonia.
7. Blood should be drawn for serum Na^+, K^+, $HC0_{3^-}$, $Pa0_2$, $PaC0_2$. ECG (arrhythmia) and a chest X-ray (pneumonia) should be done. Always monitor the vital functions with special reference to arrhythmias. Treat in the line of myxoedema coma if found to be hypothyroid.
8. Arrhythmias are treated in ICU. Bretylium tosylate is the drug of choice in ventricular fibrillation. Ventricular tachycardia/fibrillation, or asystole is the usual cause of death. So long the patient is unresponsive to CPR and rewarmed to 89.6°F (32°C), the patient should not be declared dead.

MANAGEMENT OF A PATIENT OF HYPERPYREXIA (>106.7°F)

The probable causes of hyperpyrexia are :

1. Malaria.
2. Septicaemia.
3. Encephalitis.
4. Pontine haemorrhage.
5. Lobar pneumonia.
6. Heat stroke.
7. Malignant hyperthermia (halothane-induced).
8. Thyroid storm.
9. Neuroleptic malignant syndrome (haloperidol-induced).
10. Rabies.

Malaria will be described in 3 parts, i.e., benign tertian malaria (P. vivax), malignant tertian malaria (P. falciparum) and cerebral malaria (P. falciparum).

(A) Benign tertian malaria—

* Usually caused by Plasmodium vivax and rarely by Plasmodium ovale or malariae type.

1. Tab chloroquine phosphate (one tablet contains 250 mg of drug, and 150 mg of base)— One of the two schedules may be followed.
   a) 1st day—4 tab stat (600 mg base), followed by 2 tablets (300 mg base) after 6 hours, 2nd day onwards—1 tab (150 mg base) twice daily for 2 more days.
   b) 10 mg base/kg stat and followed by 10 mg base/kg at 24 hours and 5 mg base/kg at 48 hours (i.e., 4 tab on the 1st day, 4 tab on the 2nd day and 2 tab on the 3rd day).

** Minimally 3 days treatment should be done.

2. Tab primaquine phosphate—Usually each tablet contains 7-5 mg of base. The recommended dose is 1 tab twice daily for 14 days (radical cure). Transfusion-induced malaria need not receive treatment for radical cure. Tab primaquine is started after completion of the course of chloroquine.
3. Treatment is possible at home. Diet should be adequate with plenty of fluids (glucose-drink is preferred). Use blankets during cold stage and tepid sponging in high rise of temperature. Tab paracetamol (500 mg/tab)l tab used sos, if the temperature shoots > 102°F.

Dose in children :

< 5 kg = $^{*}/_{4}$ th of adult dose

5 - 20 kg = $^{1}/_{2}$ of the adult dose

20 - 40 kg = $^{3}/_{4}$ th of the adult dose

> 40 kg = Adult dose

*** Before giving primaquine, the patient should be screened for G_6PD deficiency. *In mild deficiency,* dose of primaquine will be 45 mg once weekly for 6 weeks. Primaquine is absolutely contraindicated in pregnancy and severe G_6PD deficiency.

(B) Malignant tertian malaria (uncomplicated Plasmodium falciparum infection)—

1. Tab chloroquine phosphate—As used in B. T. malaria (see no. 1 of previous prescription). If no response occurs within 3 days, probably it is a case of chloroquine-resistant falciparum malaria (chloroquine resistance is being reported from most of the states of India) and start.

Tab quinine sulphate (300 mg/tab) in the dose of 2 tab 3 times daily for 7 days. This regimen should be followed by,

   a) Combined tablet of sulfadoxine-pyrimethamine (500 mg + 25 mg in a single tablet) to be taken, 3 tablets at a time as single dose therapy, or
   b) Cap. tetracycline 250 mg 4 times daily, orally for 7 days or cap doxycycline 200 mg daily orally for 7 days (used in sulphonamide sensitivity).
2. Alternative to quinine are :
   a) Atovaquone 250 mg + proguanil 100 mg—4 tab once daily for 3 days, or
   b) Artemether 200 mg/day orally for 5 days, followed by mefloquine 500 mg in 2 doses at 2 hours apart.
3. Diet and general treatment are same as done in B. T. malaria. Few clinicians prefer hospital treatment as the patient may be deteriorated at any moment.

* Dose of quinine sulphate in children is 10 mg/kg given three times daily.

** In pregnancy, chloroquine is the safest antimalarial drug; quinine may be used with caution. Tetracycline is contraindicated in pregnancy and children < 8 years of age.

*** Primaquine phosphate may-given 45 mg *as a single dose* for gametocidal therapy of P. falciparum, afterthe remission of fever. P. falciparum has no persistent exo-erythrocytic cycle; recrudescence occurs due to incomplete elimination of parasite from RBC.

**** The terminology of 'malignant' malaria is going to be obsolete now-a-days.

***** As most of the P. falciparum infected patients are resistant to chloroquine, one may start oral quinine from the very beginning.

****** Mefloquine or halofantrine may be used. The dose of mefloquine (250 mg/tab) is 15-25 mg base/kg, single dose (maximum dose 1500 mg); and that of halofantrine is 8 mg base/kg every 6 hours for 3 doses, and may be repeated after 7 days in non-immune subjects.

(C) Cerebral malaria (P. falciparum induced encephalopathy)—

It is ***a medical emergency*** *and needs urgent treatment. Cerebral malaria is* ***defined as*** *diffuse symmetric encephalopathy in a patient with falciparum malaria which is manifested by diminished consciousness, confusion and convulsions, often progressing to unarousable coma and death; and the encephalopathy is not attributable to any other cause e.g., metabolic, dyselectrolytaemic or any other inflammation.*

1. a) Inj. quinine dihydrochloride—600 mg (2 ml) of the drug is dissolved in 300 ml of 5% or 10% dextrose solution for slow I.V infusion (loading dose) to run over a period of 2 hours. The drug is repeated in the same dose (600 mg) every 8 hours till the patient is conscious. The loading dose is avoided if the patient has received quinine, quinidine or mefloquine in previous 24 hours. Quinine hydrochloride may be given by I.M. injection though there is a chance of muscle necrosis. After regaining consciousness, oral medication with quinine sulphate is started as,

   b) Tab quinine sulphate (300 mg/tab)—600 mg (2 tab) to be continued 3 times daily for minimally 7 days; plus,

   c) Sulfadoxine-pyrimethamine combination (500 mg + 25 mg in a single tablet)—3 tablets orally as a single dose, or cap tetracycline 250 mg, 4 times daily orally for 7 days, or cap doxycycline 200 mg daily orally for 7 days may be given.
2. Fluid and electrolyte balance—5% dextrose drip should run alternating with dextrose-normal saline solution. The volume of fluid should be calculated according to urine output and state of dehydration.
3. Control of cerebral oedema—Inj. mannitol (20%) 100 ml, 8 hourly, I.V rapidly over 30 minutes may be tried (not advocated by all). *Dexamethasone (corticosteroid) should not be given.*
4. Control of hypoglycaemia—This is corrected by 5% or 10% dextrose solution (hypoglycaemia results from glucose consumption by malaria parasite and the host, and hyperinsulinaemia as a result of quinine therapy; there is also failure of neoglucogenesis).
5. Control of convulsions—Diazepam is the drug of choice (0.2 mg/kg) and may be repeated every 4 hours. Drip of phenytoin sodium (13-18 mg/kg) at the rate of 50 mg/min, mixed with normal saline solution may be started.
6. Acute pulmonary oedema (acute lung injury)—managed by propped-up position, 0_2 inhalation, inj. frusemide I.V, and stoppage of I.V fluid. In moribund patients, intubation and addition of continuous positive airways pressure (CPAP) / positive end-expiratory pressure (PEEP) are advocated (in life threatening hypoxia).
7. Plasmapheresis is done in elderly with severe malaria, pregnant woman and >30% parasitaemia.
8. Follow the 'general care of the comatosed patient'.
9. Feeding is continued through Ryle's tube or I.V route.
10. Pulse, BP, respiration, temperature, pupil check up are done hourly. Blood should be sent for sugar, urea, creatinine, Na^+ and K\ malaria parasite, lactate and arterial blood gas analysis.
11. Follow 'to combat hyperpyrexia' mentioned in heat stroke (see below).
12. Supportive care is given for severe anaemia, renal failure (haemodialysis is effective in a desperate situation), hypotension, thrombocytopenia, DIC and hyponatraemia.

* As P. falciparum may be chloroquine-resistant, one can not take the risk of giving chloroquine in cerebral malaria. Hence, always quinine is started at the first chance (as the patient is in coma or in a stuporose stage, parenteral route is chosen). It is better to have the cardiac monitoring while the patient is on I.V quinine therapy as the drug is myocardial depressant (at least, ECG should be done; and look for wide QRS and QT-prolongation). Few clinicians advocate I.V loading dose of quinine dihydrochloride by 20 mg/kg in 500 ml of 5% or 10% dextrose solution to run for 4 hours, and then followed by 600 mg 8 hourly, I.V as described in point No. la).

** In uncomplicated P. falciparum infection (without pernicious features), chloroquine is the first drug to be used. In cerebral malaria (chloroquine-sensitive), chloroquine sulphate I.V infusion in a dose of 5 mg/kg may be given (with normal saline) every 12-24 hours and substituted by oral medication afterwards.

*** In a desperate situation, halofantrine/mefloquine/artesunate may be used. Toxicity of mefloquine is neuropsychiatric reactions and convulsions, while halofantrine may give rise to cardiac arrhythmias. Corticosteroids are of no value, rather they increase the chance of infection and G.I. bleeding.

**** This is the treatment of pernicious malaria/severe malaria/complicated malignant malaria.

***** Though passive resistance to head flexion is present in cerebral malaria, signs of meningeal irritation are absent.

****** Vomiting induced by chloroquine or quinine should be treated by inj. ondansetron (lml = 2 mg), 4 mg, I.V as and when necessary. Metoclopramide should better be avoided as extrapyramidal syndrome may develop.

******* Convulsions are managed by I.V inj. diazepam (0.2 mg/kg/dose), and may be repeated every 4 hourly. Inj. phenytoin sodium (13-18 mg/kg) by I.V bolus may be an alternative.

******** Multidrug-resistant (MDR) P. falciparum malaria may be treated by artemether-lumefantrine combination (1.5 mg/9 mg)/kg BD, orally with food for 3 days.

N.B. : Parasitaemia is cleared rapidly by **artemisinin derivatives** e.g., artesunate or artemether. Artemisinin (qinghaosu) is the active component of an herbal medicine, which is being used in China for over 2000 years. They may be used as first-line drug (e.g., cerebral malaria) or after failure of quinine (e.g., severe falciparum infection). The dose of artesunate is 2.4 mg/kg, I.V stat followed by 2.4 mg/kg at 12 and 24 hours, and then daily if necessary. The dose of artemether is 3.2 mg/kg, I.M stat followed by 1.6 mg/kg daily to total dose of 640 mg. Few clinicians prefer artesunate 4 mg/kg daily by I.V route for 3 days along with mefloquine 8 mg/kg daily for 3 days.

(D) Heat stroke—

1. Remove clothings. Take the patient to ITU or in a cool and well-ventilated room (air conditioned room).
2. Vigorous massaging of the body (chiefly the neck and torso) and allow the patient to bath repeatedly in tepid water. For rapid cooling immerse the patient in ice water, or arrange fanning (to increase convection heat loss), or start gastric lavage with iced saline. The goal is to reduce the core temperature to 102.2° F within 30-60 minutes.
3. Application of ice over the lateral aspect of the trunk.
4. 5% dextrose-saline I.V drip (i.e., cold crystallod I.V replacement) should be started immediately and to continue by the guidance of dehydration and central venous pressure.
5. Follow the 'general care of the comatosed patient'.
6. Repeated checking of the rectal temperature (by thermocouple), pulse, BP, respiration and •other vital signs. Send the blood sample for estimation of urea, creatinine, sugar, Na^+, K\ BT and CT, INR, aPTT, platelet count (coagulation profile), Ca", CK, AST and ALT. Record ECG.
7. **To combat hyperpyrexia** :
   a) Ice water enema. Antipyretics are ineffective as the hypothalamic set point remains normal.
   b) Ice-cap application over forehead.
   c) O_2 at a flow rate of 6-8 litres/min.
   d) Lytic cocktail—Pethidine 100 mg, promethazine 50 mg and chlorpromazine 50 mg in I.M route.
   e) Inj. analgin—0.5 g, I.M stat and may be repeated, if necessary.
   f) Convulsions—Inj. diazepam 10 mg, I.V stat and may be repeated, if necessary.
   g) Acidosis—inj. $NaHCo_3$, 50 ml of 7.5% of the drug may be given I.V.

MANAGEMENT OF A PATIENT PRESENTING WITH FEVER, UNCONSCIOUSNESS AND NECK STIFFNESS

The probable possibilities strike in mind are,

1. Meningitis of any aetiology (pyogenic, tuberculous or viral).
2. Cerebral malaria.
3. Meningoencephalitis.
4. Typhoid meningism.
5. Subarachnoid haemorrhage (with some cause of pyrexia).

Note : Palpate for splenomegaly (malaria/typhoid). Plantar response may be extensor in meningoencepalitis and cerebral malaria (even in semicoma stage).

(A) Pyogenic meningitis (meningococcal)—

1. Immediate hospitalisation, preferably in isolation ward. Recording of vital signs with ophthalmoscopic examination is done. If papilloedema is absent, lumbar puncture is performed and the CSF sample is sent for cell count and type, biochemical, bacteriological and serological examinations.
2. Follow the 'general care of the comatosed patient'.
3. Start normal saline drip; Inj. crystalline penicillin is started as follows :

   4 megaunits of the drug is infused I.V every 4 hourly (after proper skin test),

   or

   Inj. cefotaxime 1-2 g, I.V, 4-6 hourly according to severity (maximally 12 g of the drug can be given daily) or inj. ceftriaxone 2 g, I.V, 12 hourly may be started. The drug should be continued minimally for 10 days.

* Inj. cefotaxime/inj. ceftriaxone **plus** vancomycin (2 g/day, 12 hourly, I.V) may be started as empirical therapy in community-acquired suspected bacterial meningitis.

4. Daily monitoring of pulse, BP, respiration, temperature, sensorium, neck rigidity and plantar response should be done. Blood should be sent for TC, DC, electrolytes, urea, creatinine and sugar estimation. CT or MRI scan of brain may be performed, if facilities are there.
5. Management of complications—
   a) High fever—Tepid sponging with 1 tablet of paracetamol (500 mg) through Ryle's tube.
   b) Convulsions—Inj. diazepam 10 mg, slow I.V or injection phenytoin sodium 5 mg/kg/hour in I.V route is given.
   c) Cerebral oedema—Usually 100 ml of inj. mannitol (20%) is given I.V, 8 hourly.
   d) Hypotension and shock (adrenal crisis)—Inj. hydrocortisone hemisuccinate 100 mg, I.V, 8 hourly till hypotension persists.
   e) Respiratory failure—Needs assisted ventilation.
   0 If hydrocephalus develops as a sequelae, consult neurosurgeon for ventriculo-atrial shunt.

Table 15 : Chemotherapy of bacterial meningitis

Organism	Drugs	Dose	Alternative drugs	Duration
Meningococcus	Benzyl penicillin	See the above prescription	Chloramphenicol, Ceftriaxone, Cefotaxime	**10** d
Pneumococcus	Cefotaxime	>-	Ceftriaxone, Chloramphenicol	**10-14** d
H. influenzae	Chloramphenicol	**1** g, I.V, **6-8** hourly	Cefotaxime	**7-10** d
L. monocytogenes	Ampicillin + Gentamicin	**1-2** g, I.V, **4** hrly + **80** mg, I.V, **8** hrly	Rifampicin, Co-trimoxazole	**10** d
S. aureus	Oxacillin	**12-18** g, I.V in divided doses	Nafcillin, Vancomycin	**10** d
Pseudomonas	Ceftizidime	**1-2** g, I.V, **6-8** hrly	Cefoperazone, Gentamicin	**21** d
Unknown cause	Benzyl penicillin + Cefotaxime	See the prescrip-tion above	Chloramphenicol + Gentamycin	**10** d

Dose in children :

a) Ciystalline penicillin—300000 units/kg/day in I.V route.
b) Cefotaxime— 200 mg/kg/day in I.V route.

* '\ Treatment of pyogenic meningitis should be started very promptly. Final drug of choice will be dictated by the culture-sensitivity report of CSF.

** Drugs acting against **Pseudomonas aeruginosa** are ciprofloxacin, aminoglycosides, carbenicillin, third generation (cefoperazone and ceftizidime) and fourth generation (cefepime) cephalosporins, tricarcillin, piperacillin, aztreonam, azlocillin, mezlocillin, imipenem and meropenem.

*** As per available evidence, adjunctive dexamethasone therapy (10 mg, I.V, 6 hourly for 4 days) may have some benefit in meningitis caused by H. influenzae and S. pneumoniae in reducing sensorineural deafness and death.

(B) Tuberculous meningitis—

1. Follow No. 1, 2 and 4 of previous prescription (pyogenic meningitis).
2. In an unconscious patient, all the drugs should be given through Ryle's tube.
   a) Cap rifampicin—450 mg/day if < 50 kg and aged; 600 mg/day if > 50 kg.
   b) Tab INH—5 mg/kg/day (adult).
      10 mg/kg/day (children).
   c) Tab pyrazinamide—20-35 mg/kg/day (maximally 2.5 g).
   d) Inj. streptomycin—1 g/day, I.M if > 45 kg; and 0-75 g/day, I.M if < 45kg.
   e) Tab prednisolone (5 mg/tab)—Initiated by 8 tablets daily for 6 weeks and then tapered off by 5 mg/week, and ultimately stopped at 3 month.

* a + b + c + d for 2 months (initial phase), and a + b for 7 to 10 months more (continuation phase) according to discretion of the physician.

   f) Tab pyridoxine (40 mg/tab)—1/4 of a tablet to be continued along with INH.
3. Management of complications—
   a) Convulsions >
   b) High fever > as done in pyogenic meningitis
   c) Cerebral oedema J
   d) Headache— Paracetamol (500 mg/tab) 1 tab to be given as and when necessary.
   e) Vomiting—Inj. metoclopramide 10 mg, I.M as and when necessary.
   f) If hydrocephalus develops as a sequelae, consult neurosurgeon (not uncommon) for ventriculo-atrial shunt.

(C) Viral meningitis—

1. Specific treatment ;
   a) HSVj and HSV_2—Acyclovir 10 mg/kg, 8 hourly in I.V infusion with normal saline is started immediately and continued for 10 days; may be followed by oral acyclovir (800 mg, 5 times daily). Instead famcyclovir (500 mg tds) or valacyclovir (1000 mg tds) may be given for 7-14 days.
   b) HIV—Zidovudine 200 mg, 6 times daily in I.V infusion with normal saline/orally through Ryle's tube. Actually, the patient should receive highly active anti-retroviral therapy.
2. General and symptomatic treatment—
   As done in pyogenic and tuberculous meningitis.

* SIADH may develop in the course of the disease of meningitis (any type). So physician should be careful for the development of hyponatraemia (water restriction and hypertonic saline are the mainstay of treatment of SIADH).

(D) Cerebral malaria—

Though passive resistance to head flexion is present (not true neck rigidity), signs of miningeal irritation are absent here.

See before for management.

(E) Meningoencephalitis—

Along with the signs of meningitis one may get altered level of consciousness, altered mental state.

H/O seizures (focal or generalised), focal or diffuse neurological signs (cranial nerve palsy, aphasia, hemiplegia, Babinski's sign) and involuntary movements (myoclonic jerks).

For management, follow the regimens given in the management of viral meningitis (see above).

(F) Typhoid meningism—

1. Specific treatment :
   a) Inj. chloramphenicol—50 mg/kg/day in I.V route (in shot push within the plastic tube of the dextrose-normal saline drip) in 4 divided doses for 3-7 days. Then cap chloramphenicol (250 mg/cap) 2 cap. 6 hourly is continued for another 7-11 days, or
   b) Inj. ciprofloxacin—200 mg (200 mg/100 ml) I.V, 12 hourly for 3-7 days and then followed by oral ciprofloxacin tablet (750 mg/tab) as 1 tab twice daily for another 7-11 days, or
   c) Inj. ceftriaxone 2 g, I.V, 12 hourly may be used for 10-14 days (probably, the drug of choice),

   plus

   Inj. hydrocortisone hemisuccinate—100 mg, 8 hourly along with the I.V infusion (charged in the bottle) till the patient regains consciousness.
2. Follow the 'general care of the comatosed patient'.

* I.V ciprofloxacin 200 mg BD for at least 10 days is a good alternative in MDR typhoid fever.

*(G) Subarachnoid haemorrhage —*See afterwards.

RAISED INTRACRANIAL TENSION (ICT)

Treatment of raised intracranial tension should be started immediately in patients with cerebral haemorrhage or massive infarction, producing midline shift.

1. Propped-up position at 30° (improves jugular venous outflow without impairing cerebral perfusion).
2. Mannitol (20%)—100 ml (1-2 g/kg), 8 hourly rapidly over 15 minutes in I.V route, or 300 ml rapidly over 1-2 hours in 24 hours. Rebound cerebral oedema may pose a problem following cessation of the drip. Mannitol should preferably be continued till regaining of consciousness.
3. Inj. dexamethasone—4-6 mg, I.M or I.V, 4-6 hourly. It may aggravate hypertension and diabetes, if there is any. *Corticosteroid is contraindicated in cytotoxic oedema, head injury and CVA* but reduces vasogenic reactive oedema surrounding a tumour, an abscess or brain metastases.
4. Inj. frusemide—40 mg, I.V stat, and as and when necessary.
5. Oral glycerol—1-2 g/kg/day in 3 divided doses. Usually it corresponds to 6 tsf three times daily (given with fruit juice). I.V glycerol may be given in a dose of 1.5 g/kg as a bolus followed by 50 g in 500 ml of normal saline every 4 hourly (may produce haemoglobinuria). Glycerol is not a very good drug for reduction of ICT.
6. Retention enema of magnesium sulphate (not used now-a-days).
7. Hyperventilation, lowering $PaC0_2$ around 25-30 mm of Hg decreases cerebral blood flow by cerebral vasoconstriction and reduces intracranial tension.
8. Treat hypoxia, hypothermia. High-dose barbiturate therapy is adviced for 'refractory' ICT.

* This is the management of **cerebral oedema** too; drugs are used singly or in combination.

** Cerebral oedema is of three types :

a) Vasogenic—e.g., tumour, abscess, CVA, purulent meningitis.
b) Cytotoxic—e.g., hypoxia, Na^+ depletion in SIADH, dialysis disequilibrium syndrome.
c) Interstitial—e.g., increase water content of brain in hydrocephalus.

*** Acetazolamide and/or repeated lumbar puncture may help to lower ICT in idiopathic intracranial hypertension (benign intracranial hypertension or 'pseudotumour cerebri').

**** **Surgical management** is done by treating underlying cause, ventriculo-atrial or ventriculo-peritoneal shunt in hydrocephalus, removal of space occupying lesion or surgical decompression by limited lobectomies in selected cases.

CEREBROVASCULAR ACCIDENTS (CVA)

(.A) Cerebral thrombosis—

1. Complete bed rest. Draw blood for Hb, TC, DC, sugar, urea, creatinine, Na^+, K^+ and lipid profile (cholesterol, LDL, HDL, VLDL and triglyceride). Place the patient in a railed cot. Introduce Ryle's tube and Foley's catheter. About 2000 calories should be provided daily. Start with liquid diet and gradually change over to normal diet, as the patient recovers.
2. Follow the 'general care of the comatosed patient'.
3. Treat 'raised intracranial tension' (see before).
4. Antiplatelet drugs are advised—aspirin (75-300 mg/day orally), dipyridamole (50 mg, 8 hourly, orally daily) or ticlopidine (250 mg, 12 hourly, orally daily) for long term prophylaxis. Tab pentoxifylline (400 mg, 8 hourly), the haemorrheology modifier may be used for few weeks. Clopidogrel (75 mg) - 1 tablet, orally daily is an alternative to aspirin, or may be combined with aspirin.
5. Reduce hypertension by nifedipine (10 mg/cap) 1 cap, 8 or 12 hourly, orally or amlodipine (5 mg/tab) - 1-2 tab, once daily, orally. Diuretics or ACE-inhibifors may be used. BP should be kept at or just below $^{180}/_{115}$ mm of Hg.
6. Control of other co-morbid conditions like diabetes mellitus, hyperlipidaemia, obesity. Oral contraceptives should be discontinued.
7. Arrangement should be made to perform an early CT scan of the brain.

(B) Cerebral embolism—

1. Follow No. 1, 2 and 3 of previous prescription (cerebral thrombosis).
2. Specific treatment—
   a) Inj. heparin sulphate—5000 units, I.V infusion, 6-12 hourly for 5 days along with,
   b) Tab warfarin sodium (5 mg/tab)—usually started from the second day as 2 tab daily for 2 days and then 1 tab daily to be continued for 6 months. Inj. heparin sulphate should be withdrawn after 5 days and let warfarin to be continued alone.
3. Treatment of the underlying cardiac disorder (e.g., tablet digoxin in atrial fibrillation).

* Early CT scan should rule out cerebral haemorrhage or tumour before giving inj. heparin. Heparin and warfarin are specially indicated in an 'evolving stroke' when the patient have atrial fibrillation, paroxysmal arrhythmia or cardiac valve lesions. Anticoagulants have no role in completed stroke.

** *In cerebral infarction (cerebral thrombosis or embolism), maintain the BP at or just below $^{180}/_{115}$ mm of Hg.* **Reduction of BP should be gradual and should be tried when the acute stage is over.**

*** In acute ischaemic strokes, thrombolysis by alteplase (rTPA) is done in few sophisticated centres within first 3 hours of onset.

(C) Cerebral haemorrhage—

1. Follow No. 1, 2 and 3 from the prescription of cerebral thrombosis.
2. Inj. sodium nitroprusside (for reduction of blood pressure)—50 mg dissolved in 500 ml of 5% dextrose (100 fig/ml) and infused in the dose of 20 (ig/min. Usually the I.V infusion dose is 0.25-8.0 (xg/kg/min. Protect the bottle from light (to prevent the production of toxic thiocyanates). Many neurologists do not agree to administer sodium nitroprusside *Maintain the blood pressure just below $^{180}/_{115}$ mm of Hg* to preserve the cerebral autoregulatory mechanism.
3. If CT scan shows > 3 cm haematoma or the patient progressively deteriorates, consult neuro-surgeon for surgical drainage of the haematoma (evacuation of deep cerebral haematoma is rarely beneficial rather surgical consultation is indicated for cerebellar haematoma).

* Early CT scan is advisable in all of the above cases. Physiotherapy should be started in (A), (B) and (C) as soon as the patient recovers from the neural shock stage. Subsequently speech therapy, dysphagia care and occupational therapy are looked for.

** Aspirin and clopidogrel are absolutely contraindicated in cerebral haemorrhage and very big cerebral infarction.

*** In cerebral ischaemia try to avoid hypoxia, dehydration, corticosteroid and 5% dextrose infusion.

(D) Subarachnoid haemorrhage—

1. Follow No. 1, 2 and 3 from the prescription of cerebral thrombosis.
2. Nimodipine—Tablets (30 mg/tab) should be crushed and introduced through Ryle's tube. Recommended dose is 2 tab 4 hourly to be started within 3-4 days of subarachnoid haemorrhage and usually continued for 3 weeks,

   or

   Epsilon amino-caproic acid (EACA)—The drug was previously used. The usual dose is 24-48 g/day by I.V infusion in 5% dextrose-saline infused over 24 hours with the help of a micro-drip apparatus. EACA is a fibrinolytic inhibitor.
3. Hypertension is controlled by diuretics, ACE-inhibitors.
4. MR angiography should be performed in patients 'potentially fit for surgery (< 65 years) and neurosurgeon may be called for surgical treatment (clipping of the neck of aneurysm, embolisation).

* Nimodipine (calcium channel blocker) prevents vasospasm and EACA prevents rebleeding.

** According to few clinicians, anticonvulsants are used for prophylaxis, and inj. dexamethasone for reduction of cerebral oedema as well as for stabilization of blood-brain barrier.

(E) Hypertensive encephalopathy—

1. Follow No. 1, 2 and 3 from the prescription of cerebral thrombosis.
2. Sodium nitroprusside or diazoxide is the drug of choice (see the doses from the section on 'Drug therapy in hypertensive emergencies').
3. Inj. diazepam 10 mg, I.V slowly is used for convulsions and may be repeated, if necessary.

CONVULSIONS

(A) Febrile convulsion—

1. Place the patient in prone or lateral position. Prevent aspiration and guard against tongue bite by a rubber oropharyngeal tube. Start tepid sponging to bring down the raised temperature.
2. Syrup paracetamol (125 mg/ml)— x/„ to 2 ml, orally, according to body weight.
3. Diazepam— Inj. diazepam (0.2-0.5 mg/kg/dose in shot push I.V; maximum of 5 mg/dose) or solution of diazepam may be given per rectally in a dose of 0.2-0.4 mg/kg, or phenobarbitone (60 mg/tab) — 1/2 to 1 tab stat.
4. Antibiotics may be prescribed, if indicated.

* The age limit of febrile convulsion is 6 months to 5 years. Few pediatricians continue phenobarbitone (30 mg at bedtime) till 5 years of age. An EEG should be done afterwards.

(B) Status epilepticus—

When convulsions (seizures) and unconsciousness recur wihout any intervening normal period in between, it is known as status epilepticus. Actually, it is the occurence of prolonged serial seizures (two or more) without the patient regaining consciousness between the attacks over a period of 15-30 minutes (recent definition). Practically, it is a serious conditions where the duration of seizure, which is more than 5 minutes, demands promt use of anticonvulsants. It is a life-threatening medical emergency (cardio-respiratory embarrassment, metabolic derangement, hyperpyrexia) and an ITU is essential for optimal management.

1. Railed cot; mouth gag to prevent tongue bite. Avoid head-pillow. Place in any lateral position with foot end raised (to prevent aspiration pneumonia) and head turned sideways. Try to listen the H/O past illness from patient's relatives.
2. Maintain the airway by repeated suction of mouth, nose and throat. Insert one rubber oropharyngeal tube.
3. Do not try to draw blood samples during convulsions. Blood samples can be taken (sugar, urea, creatinine, glucose, calcium, electrolytes, LFT and for toxicology) afterwards when the patient becomes totally sedated. Take care of BP, acidosis and ventilation.

4. Anticonvulsants—
   a) Start I.V lorazepam (0.1 mg/kg. I.e., 3-6 mg) at the rate of 2 mg/min; may be repeated after 5 minutes,

   or

   I.V diazepam (0.2 mg/kg, i.e., 10 mg) at the rate of 5 mg/min — the short duration of action of lorazepam or diazepam needs concomitant administration of maintenance anticonvulsants, i.e.,

   immediately after the first lorazepam/diazepam dose, start I.V phenytoin drip (always in normal saline; phenytoin precipitates in 5% dextrose solution; fosphenytoin has no such problem which is a pro-drug of phenyton where the risk of hypotension is less in comparison to phenytoin, and 1.5 mg fosphenytoin = 1 mg phenytoin), 13-18 mg /kg to run at the rate of 50 mg/min. Pediatric dose of the drug is 5 mg/kg to run at the rate of 25 mg/min. Monitoring of BP and ECG should be done (EEG, if possible) during infusion of phenytoin.
   b) Consider sodium valproate, I.V, 25 mg/kg if seizures continue in spite of inj. phenytoin.
   c) Inj. chlormethiazole 0.5" 1.2 g/hour, I.V by infusion may be tried in diazepam-failure patients.
   d) Thiopentone sodium 100-250 mg, I.V slowly may be started and followed by 90-120 mg/ hour infusion or phenobarbitone is started 20 mg/kg I.V at 50-75 mg/min. These drugs need assisted ventilation.
   e) Lastly, I.V anaesthesia with propofol or midazolam may be considered.
5. Moist 0_2 inhalation at the rate of 4-6 litres /min.
6. Maintenance drip by normal saline (to act as a route of emergency).
7. 50 ml of 50% inj. glucose, I.V often aborts an attack as hypoglycaemia as this may be an aggravating factor.
8. Discharge the patient from the hospital with tab phenytoin (100 mg/tab)- 1 tab three times daily, orally, regularly till further instruction; follow-up at regular interval.
9. Treatment of acidosis (50 ml of 7.5% sodium bicarbonate) and hyperpyrexia (see before) are done accordingly as these may complicate the course of status epilepticus.

* EEG (mandatory) and CT scan should be done as soon as the acute stage is over.

** *A continuous infusion of diazepam (2-4 mg/hr) is often beneficial* over phenytoin drip in some patients.

*** Lorazepam and diazepam may produce respiratory depression and hypotension.

**** Read different drugs for epilepsy form the section on 'Drugs'.

ACUTE ATTACK OF MIGRAINE

1. Rest. Reassurance.
2. Avoid stress. Chocolate, cheese, alcohol should be prohibited. Avoid oral contraceptive pills (in future). Oral fluid intake is encouraged.
3. Tab ergotamine tartarate (1 mg/tab) —1 tab to be taken orally and may be repeated at $^1/_2$ hour interval, not exceding 3 mg/day (should be taken in the aura stage to abort the attack),

   - or

   Tab'sumatriptan (25/50/100 mg per tablet)—50-100 mg, orally to be taken 'soon after the onset of headache', and may be repeated, not exceeding 300 mg/day, or inj. sumatriptan (6 mg/0.5 ml) 6 mg, S.C, not more than 2 injections in 24 hours may be given. Sumatriptan is a 5-HTj agonist. Zolmitriptan, almotriptan, rizatriptan or naratriptan may be used instead by S.C route for promt relief of headache.
4. *Prevention for future attacks* (any one or combination):
   a) Flunarizine (5/10 mg per tablet)— 10 mg daily, orally in single or divided doses to continue till further advice.
   b) Tab propranolol (40 mg/tab)— 1-2 tab, orally three times daily to continue till further advice. Start initially as $^1/$ tab twice daily and then increase the dose gradually.
   c) Tab amitriptyline (25/50/75 mg per tablet)—25-100 mg, orally at bed time to continue till further advice.

d) Tab sodium valproate—500-1500 mg, orally in 2 divided doses.
e) Pizotifen—0.5-1.5 mg daily at bed time.
f) Methysergide—1-2 mg, thrice daily in resistant cases.
g) SSRI (serotonin-selective reuptake inhibitor), verapramil or topiramate may be used.

* Ergotamine is strictly contraindicated in pregnancy, peripheral vascular disease (e.g., Raynaud's phenomenon) and IHD.

** Sumatriptan is contraindicated in IHD, severe uncontrolled hypertension and with previous H/O myocardial infarction.

*** Acute attack may also be treated by aspirin (325-625 mg), ibuprofen (400-800 mg), naproxen (375-750 mg) or paracetamol (500 mg), orally. Prochlorperazine (12.5 mg) I.M, metoclopramide (10-20 mg) I.V or domperidone 2 mg I.V may be used as antiemetic.

**** **'Triggering factors'** ('anything under the sun including the sun' may be the precipitating factor though it differs from person to person) for migraine are : stress, noise and irritating lights, premenstrual tension, lack of sleep/meals and variations in daily routine, perfumes, caffeine, tobacco, alcohol, chocolate, cheeze, food additives e.g., monosodium glutamate, oral contraceptive pills and a time of relaxation (week-end migraine).

A BOY OF 8 YEARS WITH TWO DAYS H/O PUFFY FACE AND OLIGURIA SUDDENLY BECOMES DYSPNOEIC. HOW TO MANAGE THIS PATIENT ?

Most probably the boy is suffering from acute left ventricular failure developing from **acute glomerulonephritis** (the other acute complications of AGN are hypertensive encephalopathy and acute renal failure). At first, urgent treatment of LVF is done which is followed by treatment of acute poststreptococcal glomerulonephritis.

Management:

1. Treatment of acute LVF—See before.
2. Treatment of AGN :
   a) Complete bed rest until the signs of glomerular inflammation (proteinuria, RBC in urine) and circulatory congestion (oedema, hypertension) subside.
   b) Mild protein restriction in azotaemic patients. Salt free foods are given. The fluid intake is restricted to previous days output plus 500 ml of fluid. Check blood urea, creatinine and electrolytes regularly.
   c) Maintenance of intake-output chart; regular checking of BP and other vital signs.
   d) Tab frusemide (40 mg/tablet)—1 tab daily; the dose may be increased according to necessity (to relieve oedema and hypertension).
   e) Tab nifedipine (5 mg/tab)—1 tab 8-12 hourly according to the height of BP. Other calcium-channel blockers (e.g., amlodipine), hydralazine or diazoxide may be of help.
   f) Inj. crystalline penicillin—5 lakhs, I.M twice daily for 7-10 days (after proper skin test) to eradicate residual infection.
   g) Dialysis, if ARF or fluid overload develops.
   h) Tonsillectomy may be done after recovery.

* The prognosis of AGN in children is usually good. A small number of adults may develop hypertension and renal impairment later in life.

MANAGEMENT OF ACUTE PYELONEPHRITIS (E. COLI)

The treatment of urinary tract infection (UTI) is as follows :

1. Co-trimoxazole (trimethoprim + sulphamethoxazole = 80 mg + 400 mg/tab)—2 tab twice daily orally for 14 days, or cap ampicillin or amoxycillin (500 mg/cap)—1 cap 8 hourly, orally for 10 days, or cap cefuroxime (250 mg/cap)—1 cap 12 hourly for 10 days, or tab norfloxacin (400 mg/tab) or tab ciprofloxacin (500 mg/tab)—1 tab 12 hourly for 10 days, or nitrofurantoin 50 mg 8 hourly for 10 days. In severe infection (high fever, loin pain and tenderness), aminoglycosides e.g., inj. gentamycin I.M/I.V 3-5 mg/kg/day is given in 3 divided doses for 7-10 days, or inj. amikacin I.M/I.V 15 mg/kg/day is administered in 2 divided doses for 7-10 days.

2. Rest in bed. Normal diet. Plenty of fluid (at least two litres/day) to be taken by mouth to initiate water diuresis.
3. Ideally, urine sample should be sent for culture-sensitivity test and colony count, before initiating treatment. As soon as the result of sensitivity test is available, treatment is started (or changed, if already started) according to maximum sensitivity. Severe cases may require intravenous therapy. After recovery, often monthly culture of urine is advised.
4. Factors predisposing to infection e.g., obstruction, neurogenic urinary bladder, calculus, catheterisation, diabetes mellitus etc. should be properly identified and treated, if possible. Regular complete bladder emptying, maintenance of adequate perineal hygiene and application of 0.5% cetrimide cream peri-urethrally before intercourse often reduce the incidence of UTI in females.
5. If Blood urea and creatinine value rise, modification of dose of antibiotics is necessary.
6. In dysuria—
   a) Tab flavoxate (200 mg/tab)—1 tab 8 hourly for 10 days,

   or

   b) Tab phenazopyridine (200 mg/tab)— 1 tab 8 hourly for 10 day (produces red urine).
7. To prevent recurrent infection, suppressive antibiotic therapy by single nightly oral dose of trimethoprim 100 mg, ampicillin/ amoxycillin 250 mg, cephalexin 250 mg or nitrofurantoin 100 mg may be continued for few weeks (upto 6-12 months in recurrence).

* Renal parameters should be normal (i.e., normal urea and creatinine) in patients who are advised aminoglycosides.

INTRACTABLE HICCOUGH

Hiccough in an abrupt, involuntary, synchronous contraction of the diaphragm and the inspiratory intercostal muscles, followed by immediate closure of the glottis. The glottic closure is responsible for the production of characteristic inspiratory sound and associated discomfort. The synonyms of hiccough are hiccup or singultus. Hiccough is now-a-days considered as myoclonus of diaphragm.

Management :

Recurrent hiccough is very distressing and difficult to manage.

1. Reassurance : the patient as well as the relatives should be reassured.
2. Simple household remedies : Divert patient's attention (e.g., by conversation, sudden slapping), intake of ice-cold water, breath holding, Valsalva manoeuvre, lifting uvula with cold spoon, breathing in and out in a paper or plastic bag for 5 minutes, induction of vomiting by stimulation of the pharynx, spraying of ethyl chloride under the costal margins, swallowing rapidly one teaspoon of 'dry' granulated sugar, drinking water without taking any breath, coughing, sneezing (nasopharyngeal stimulation often aborts hiccough of postoperative origin).
3. Local measures : Intake of local anaesthetic viscus e.g., xylocaine, nasogastric suction followed by ice-cold stomach wash or alkaline stomach wash through a Ryle's tube.
4. Antacids/H_2-receptor blocker/proton pump inhibitor : Any liquid antacid (preferably containing local anaesthetic oxethazaine) is given 2-4 tsf, 6-8 hourly daily, orally, or ranitidine 150 mg BDAC or omeprazole 20 mg ODAC, orally. It is often advised to take the tablets with little water, and thus irritation of the pharynx may terminate a bout of hiccough.
5. Drugs : Chlorpromazine (probably best tried first, as an intravenous bolus; 25 mg, orally, tds or 25 mg I.V bolus stat), metoclopramide (10 mg, I.M, tds), baclofen (10 mg, orally, tds), haloperidol (5 mg, I.M stat or 0.25 mg, orally, tds), clonazepam (2 mg, orally, tds), amitriptyline, amantadine, quinidine (200 mg, orally, qds), ondansetron (4 mg, I.V, tds), anticonvulsants like phenytoin sodium, carbamazepine, valproic acid are worth trying in resistant cases. *Baclofen (beta agonist) is an effective drug in the treatment of intractable hiccough.*
6. Surgery ; In stubborn cases, phrenic nerve block by bupivacaine or nerve section is done surgically.
7. Treatment of the underlying cause.

* **Common causes of hiccough in clinical practice are :**

1. Overdistention of stomach.
2. Acute gastritis.
3. Uraemia.
4. Diaphragmatic pleurisy.
5. CVA.
6. Idiopathic.

MANAGEMENT OF HAMATEMESIS AND/OR MELAENA

1. Complete bed rest. Record pulse, BP, respiration, temperature and any sign of shock.
2. Introduce Ryle's tube. 0_2 is given through nasal catheter, if the patient is in shock. Try to assess the amount of blood loss from history and orthostatic haemodynamic changes (see below).
3. Make an I.V channel. Blood is sent for grouping and cross-matching, and for biochemical tests i.e., urea, creatinine, sugar and for LFT.
4. Nothing per mouth should be given if the bleeding continues. Liquid and then semisolid diet of low residue may be given when the bleeding has stopped. Tea, coffee, alcohol and smoking are strictly prohibited.
5. Start Ryle's tube suction intermittently and note the character of the aspirate. Gastric lavage is usually done with isotonic saline (ice cold).
6. I/V fluid therapy goes like this :

   Dextrose solution (10 %_)— 1 bottle

   i T

   Ringer's lactate— 1 bottle

Total 4-5 bottles will run in 24 hours depending upon the amount of blood loss. Rate of fluid infusion will be guided by the patient's vital signs. Type of fluid regimen may be changed according to need (electrolyte imbalance) of the patient. Plasma expanders like low molecular weight dextran is infused to maintain the BP till blood is available for transfusion.

7. Inj. ranitidine (50 mg/2ml)—50 mg, I.V, 3-4 times daily should be given till recovery. As soon as the vital signs improve and active bleeding stops, start tablet ranitidine (150 mg/tab) 1 tab twice daily before meal to continue till further advice. PPI (omeprazole, pantoprazole or rabeprazole) may be used instead.
8. Inj. promethazine—25-50 mg, I.M stat for restless patients; may be repeated, if necessary.
9. Now-a-days upper G. I. endoscopy can be done at the bedside. It yields high 'diagnostic accuracy', therapeutic capability, and low morbidity. When the patient becomes haemodynamically stable after receiving volume resuscitation, upper G. I. endoscopy should be performed early in the clinical course. Though it does not reduce the mortality, therapeutic endoscopy definitely reduces transfusion requirements, need for surgery and length of hospital stay.
10. **a) *For bleeding peptic ulcer :***

    (i) Blood should be transfused as soon as it is available (blood transfusion is required if the nasogastric aspiration shows active bleeding, the patient is in persistent shock, Hb% is <10 g/dl, systolic BP is <100 mm of Hg and the pulse rate is consistently >100 / minute). Maintain the fluid drip after the transfusion is over.

    • (ii) Liquid antacid containing aluminium hydroxide and magnesium trisilicate is given 4-6 tsf every two hourly daily through the Ryle's tube.

    (iii) Upper G.I endoscopy (if not done initially) is done as soon as the patient becomes stable.

    (iv) If the above measures fail, consider surgical intervention.

    b) *For rupture of oesophageal varices :*

    (i) Blood should be transfused as soon as it is available (indications for transfusion are same as in bleeding peptic ulcer). Maintain the fluid drip after the transfusion is over (if blood is transfused in late hours, patient may precipitate hepatic pre-coma).

    (ii) Vasopressin (pitressin)— 20 units to be dissolved in 200 ml of 5% dextrose. This will run as a seperate drip over 20 minutes and will be repeated again (may repeat hourly). It will continue for another 12-24 hours after the bleeding stops (note facial pallor, abdominal colic and bowel evacuation as indicators of active drug molecule; IHD is a contraindication for its use). The therapeutic dose of vasopressin is 0.1-0.5 units/ min. Vasopressin constricts the splanchnic arterioles, and thereby reduces portal pressure and portal blood flow.

* Inj. terlipressin 2 mg, 6 hourly by I.V route, followed by (till bleeding stops) 1 mg, 6 hourly for 24 hours may be used instead of vasopressin. Now-a-days, somatostatin infusion (250 |ig I.V stat followed by 250 (xg/hrly/I.V) is given in few sophisticated centres. Inj. octreotide (somatostatin analogue) 50 |ig, S.C, 8 hourly or infusion at the rate of 50-100 (ig/hour may be tried. Somatostatin and octreotide increase splanchnic arterial resistance.

(iii) If bleeding still continues or recurs, introduce a Sengstaken-Blakemore tube (balloon tamponade). The Minnesota modification is preferred because it contains aspiration facility from stomach and oesophagus.

(iv) If bleeding continues after tamponade, emergency endoscopic sclerotherapy or variceal ligation/banding is tried, if feasible.

(v) If bleeding is still not controlled, surgical assistance e.g., oesophageal transection or TIPSS (transjugular intrahepatic portosystemic stent shunting) is tried, if in a specialised centre.

(vi) Inj. Vit K - 10 mg, I.M/I.V daily for consecutive 3 days. Platelet transfusion may be done.

(vii) All cirrhotics are to be graded on Child's criteria as early as possible. Lactulose and neomycin (see the section on 'Management of hepatic pre-coma/coma') may be started.

11. Follow-up:

a) *Bleeding peptic ulcer—*

Follow the 'Eradication of H. pylori' described in 'Gas under the diaphragm' in 'Radiology' section.

b) *Rupture of oesophageal varices—*

(i) Endoscopic confirmation and grading of varices (if not done initially).

(ii) Endoscopic sclerotherapy, banding/ligation or TIPSS.

(iii) Tab propranolol (40 mg/tab)—1 tab, 8-12 hourly or isosorbide dinitrate (5 mg/tab)—1 tab twice daily, orally may be continued (both are portal hypotensive agents).

(iv) Porto-systemic shunt surgery may be done afterwards.

* Variceal bleeding is a life-threatening medical emergency.

** For other causes of haematemesis/melaena, primarily treat in the line of bleeding peptic ulcer. Do specific management when upper G.I. endoscopy clinches the diagnosis.

** **Orthostatic haemodynamic changes** : Drop in systolic BP of >10 mm of Hg, rise in pulse rate of >15 beats/min are seen with loss of 20% of the circulatory volume.

DYSENTERY

It is characterised by diarrhoea where stool is mixed with blood and mucus as a result of acute inflammation of large gut (colicky pain abdomen and tenesmus are associated with dysentery).

(A) Acute amoebic dysentery—

1. Bed rest. Liquid diet. To consume boiled drinking water.
2. Tab metronidazole (400 mg/tab)— 2 tab 3 times daily for 7 days; or metronidazole (500 mg/100 ml) I.V infusion may be given, as 100 ml 3 times daily till the acute stage subsides; or tab tinidazole (300 mg/600 mg per tablet)— 600 mg 2 times daily for 7 days or 2 g single daily dose for at least 3 days. These drugs are *followed by,*
3. Tab diloxanide furoate (500 mg/tab)— 1 tab 3 times daily for 10 days (to eradicate intestinal cyst), after the treatment with metronidazole or tinidazole is over. Alternative 'luminal agents' are iodoquinol (650 mg tds for 20 days) or paromomycin (500 mg tds for 10 days).
4. Cap tetracycline (250 mg/cap)— 1 cap 4 times daily for 5 days along with any one of the drugs described in No. 2 may be prescribed to eradicate luminal amoebae or to treat secondary bacterial infection.
5. Oral rehydration therapy (see afterwards), if dehydration develops.
6. Tab dicyclomine hydrochloride (10 mg/tab)— 1 tab stat and sos to be used in colicky abdominal pain. Drotaverine hydrochloride (40 mg/tab) may be used instead.
7. Stool examination should be done after 1 month to confirm eradication of Entamoeba histolytica.

* The patient should be warned about the side effects (nausea, vomiting, metallic taste, disulfiram-like reactions, abdominal discomfort) of imidazole compounds.

(B) Acute bacillary dysentery (shigellosis)—

1. Complete bed rest in isolation. Liquid diet till acute stage subsides.
2. Record vital signs at $^1/_2$ hourly interval. Ensure normal urine output.

3. Assess hydration. Oral rehydration therapy (see afterwards), if dehydration develops.
4. Stool should be sent for culture-sensitivity test, but it is not always possible to get the report of stool before initiating specific antimicrobial therapy.
5. Trimethoprim-sulphamethoxazole (80 mg + 400 mg/tab)— 2 tab twice daily for 5 days,

   or

   Tab ciprofloxacin (500 mg/tab)— 1 tab 12 hourly for 5 days,

   or

   Tab norfloxacin (400 mg/tab)— 1 tab 12 hourly for 5 days,

   or

   Tab nalidixic acid (500 mg/tab)— 2 tab 6 hourly for 5 days in adults (specially used in children; in the dose of 55 mg/kg/day in divided doses).
6. Tab dicyclomine hydrochloride (10 mg/tab)— 1 tab stat and sos to be used in colicky abdominal pain. Drotaverine hydrochloride (40 mg/tab) may be used instead.
7. Loperamide (2 mg/tab or cap)— 1 such stat and 1 tab/cap is used sos with each motion (use cautiously in children and aged; it may precipitate paralytic ileus).
8. In high fever, paracetamol (500 mg/tab)— 1 tab stat and sos is used.

Avoid milk and milk products in dysentery.

AMOEBIC LIVER ABSCESS

1. Complete bed rest. High calorie nutritious diet. Advise the patient to consume boiled drinking water. Cysts present in water are disinfected by iodination.
2. I.V metronidazole— 100 ml (containing 500 mg of the drug) to be infused thrice daily till definite clinical improvement occurs; followed by tab metronidazole (400 mg/tab)— 800 mg thrice daily for 7 days,

   or

Inj. dehydroemetine (previously used when metronidazole was not available)— 60 mg, deep I.M daily for consecutive 6 days, gap for 3 days, and again injected I.M for consecutive 3 days. Strict bed rest and ECG monitoring is a must during treatment. Emetine is more cardiotoxic than dehydroemetine. Three days gap is given to avoid drug cumulation within the body. These agents are toxic and thus rarely used at present. Their toxic effects are arrhythmia, chest pain, muscle weakness, myalgia, nausea/vomiting, diarrhoea, hypotension and pain at site of infection.

3. If parenteral therapy is not employed, one may start oral treatment with tab metronidazole (400 mg/tab)— 2 tab 8 hourly for 10 days, or

   Tab tinidazole (300 mg/600 mg per tablet)— 600 mg 8-12 hourly for 10 days or 2 g single daily dose for 3-5 days.
4. Cap tetracycline (250 mg/cap)— 1 cap 4 times daily for 5 days as luminal antiamoebic drug or to control secondary bacterial infection.
5. Tab chloroquine (250 mg/tab)— 2 tab twice daily for 2 days, and 1 tab twice daily for next 19 days.

* No. 4 and No. 5 are used along with No. 2 or 3.

6. To eliminate intestinal luminal cyst, tab diloxanide furoate (500 mg/tab) 1 tab, orally, 8 hourly to be given for 10 days after the treatment with metronidazole is over.
7. Indications of aspiration (under USG or CT guidance)—
   a) Clinical lack of response to 3-5-days metronidazole treatment.
   b) Very large abscess (>10 cm in diameter).
   c) Abscess in the left lobe likely to rupture into the peritoneum or pericardium.
   d) To rule out pyogenic abscess (specially in patients with multiple lesions).
   e) Threat of imminent rupture.
8. Maintain nutrition by I.V normal saline or dextrose-saline infusion.
9. If the abscess ruptures, immediately resuscitate the patient by parenteral fluid therapy, which is *followed* by open surgical drainage.

* Few physicians prefer inj. ciprofloxacin infusion (200 mg/100 ml), 200 mg, 12 hourly infused over 60 minutes to combat secondary pyogenic infection within the abscess. Tablet domperidone (10 mg/tab) 1 tab, 8 hourly, orally in empty stomach for 2-3 days may be advocated in nausea/vomiting.

ACUTE VIRAL HEPATITIS

1. *There is no specific treatmentfor acute viral hepatitis.* Rest in bed till the patient is symptom-free (physical well-being with return of appetite), the liver is no longer tender, and the serum bilirubin becomes less than 1.5 mg/dl; gradual ambulation.
2. A diet containing 2000-3000 Kcal daily is given. Low-fat and high-carbohydrate diet is preferred. The food must be palatable. Plenty of fluid should be taken.
3. Blood should be sent for estimation of serum bilirubin (conjugated and unconjugated fraction), AST, ALT, alkaline phosphatase, serum albumin and prothrombin time. Blood biochemistry e.g., urea, creatinine and glucose should be estimated. Tests of IgM anti-HAV, Australia antigen (HBsAg), anti-HCV, IgM anti-HEV should be advised.
4. During the acute stage, close physical contacts should be avoided. Avoid sharing comb, rajor etc with the patient (specially in type B and C hepatitis). Alcohol, sedatives, oral contraceptive pills are to be totally avoided. Reassurance, as recovery is the rule in majority.
5. Regular surveillance on clinical parameters and close observation regarding development of hepato-cellular failure (abnormality in higher function, pedal oedema, ascites, asterixis etc).
6. Symptomatic treatment (keep the patient on minimum drugs) :
   a) Nausea and vomiting—Domperidone 10 mg, three times daily before meal.
   b) Severe vomiting and fluid loss—Inj. metoclopramide 10 mg, I.M stat; 10% dextrose drip should be started and maintained (4 bottles/day) for 2-3 days. In severe vomiting, ondansetron may be given orally (2 and 4 mg/tab) or preferably parenterally (2 ml inj. containing 2 mg/ml).
   c) Pain in the right hypochondrium—Tab paracetamol (500 mg/tab), 1 tab sos.
   d) Pruritus (in prolonged cholestatic variety)—Read the chart on 'Cholestasis'. Chiefly UDCA, antihistaminics or cholestyramine is advocated.
   e) Weakness—Reassurance; routine vitamins supplement are not necessary. Parenteral injection of vitamin K, 10 mg by I.M route may be given daily for consecutive 3 days if prothrombin time is high.
   f) Hepatic pre-coma/coma (from fulminant hepatitis)—Read the 'Management of hepatic pre-coma/coma' from early part of 'Emergency medicine'.

* Admission to hospital is rarely necessary (except in clinically severe disease and fulminant hepatitis). Corticosteroids have no benefit. There are no controlled data on the efficacy of lamivudine in acute type B hepatitis.

ENTERIC FEVER

1. Bed rest with isolation till fever subsides. Care of the mouth, eyes and skin; high calorie, semisolid, low roughage diet with plenty of fluid by mouth should be taken. Tepid sponging is advised in high rise of temperature. Tab paracetamol (500 mg/tab) 1 tab used sos, if the temperature shoots > 102°F.
2. Tab ciprofloxacin (500 mg/tab)—1 tab twice daily for 10-14 days.

Other drugs (any one may be used)

- Cap chloramphenicol (250 mg/cap)— 3 cap 4 times daily till fever persists; then 2 cap 4 times daily is continued upto 14 days (now-a-days, chloramphenicol-resistant S. typhi is not uncommon; moreover, there is chance of development of aplastic anaemia. So many physicians avoid this drug). Pediatric dose is 30-50 mg/kg of body weight/day.
- Cap amoxycillin (500 mg/cap)—2-3 cap 4 times daily for 14 days. Pediatric dose is 100 mg/kg of body weight/day.

- Co-trimoxazole (160 mg trimethoprim + 800 mg sulphamethoxazole/tab)—2 tab twice daily for 14 days.
- Ofloxacin (200 mg/tab)—2 tab twice daily for 7 days.
- Inj. ceftriaxone—2 g twice daily I.V or 3-4 g once daily I.V for 10-14 days. Pediatric dose is 75 mg/kg of body weight, once daily for 7-10 days.

3. If typhoid state develops, start inj. hydrocortisone hemisuccinate—Read "Typhoid meningism' from early part of 'Emergency medicine'. ,
4. For chronic carrier :
   Tab ciprofloxacin (500 mg/tab)—1 tab twice daily continued for 4 weeks or advise cholecystectomy.

* In **multidrug-resistant (MDR) S. typhi infection,** the bacteria is resistant to chloramphenicol, co-trimoxazole, ampicillin or amoxycillin, streptomycin, sulphonamides and tetracycline. The drugs used in MDR disease are :

(A) MDR S. typhi infection—
   a) Ciprofloxacin — 500 mg BD, orally x 10-14 days
   b) Ceftriaxone — 4 g/d in d/d I.V x 10-14 days
   c) Azithromycin — 1 g/d, orally x 5 days
   d) Cefixime — 400 mg BD, orally x 10-14 days

(B) NARST (Nalidixic acid-resistant S. typhi) strain—
   a) Ceftriaxone — 1-2 g/d, I.V x 10-14 days
   b) Azithromycin — 1 g/d. orally x 5 days
   c) Ciprofloxacin — 750 mg, BD, orally x 10-14 days

MDR infection as well as quinolone resistance are found in India.

ACUTE PANCREATITIS

It is an acute abdominal medical emergency. Though it is a self-limiting disease, support through a) analgesia, b) avoidance of oral alimentation, and c) I.V fluid therapy to maintain intravascular volume are targetted for a fruitful outcome.

1. Urgent hospitalisation with absolute bed rest.
2. No oral intake until the patient is free of pain abdomen and nausea.
3. Intermittent nasogastric suction (prevents abdominal distension and vomitus, and reduces the risk of aspiration pneumonia) through Ryle's tube at 15 minute interval.
4. Catheterisation of urinary bladder by Foley's catheter.
5. Moist 0_2 inhalation by nasal catheter at the rate of 4-6 litres/min.
6. I.V drip to continue with normal saline or plasma expanders as hypovolaemic shock is very common and early fluid loss may be enormous.
7. Inj. pethidine— 100 mg, I.M, 8 or 12 hourly or inj. tramadol 100 mg, I.M, 12 hourly for analgesia (do not use morphine as it causes contraction of sphincter of Oddi; inj pentazocine should also be avoided).
8. Blood sample is drawn and sent for haematocrit, TC, DC, amylase, lipase, sugar, calcium, bilirubin, albumin, lipid profile, arterial blood gases, and grouping and cross-matching. Record the vital signs at regular interval.
9. Inj. ranitidine (50 mg/2 ml)— 50 mg, I.V/I.M, 8 hourly to continue till recovery. Acid suppression should be done in critically ill patients with risk of stress ulcer bleeding.
10. Blood transfusion may be required in haemorrhagic pancreatitis.
11. Antibiotics (prophylactic)— Inj. cefotaxime, 1 g, I.V, 6 hourly or inj. aztreonam 1-2 g, I.V/I.M 6-12 hourly for 7 days to reduce the risk of infective complications. Use of antibiotic in acute pancreatitis still remains controversial.
12. Inj. trasylol— 5 lacs units as I.V bolus may be tried.
13. Inj. glucagon— 1 mg, S.C may be given.
14. Inj. calcium gluconate— 10 ml (10%) by I.V route in shot push and may be repeated.

15. Inj. octreotide—50-200 ng, S.C, 8 hourly may be of some help.
16. Diet— Liquid diet is started on the 3rd to 6th day and a regular diet by the 5th to 7th day.
17. Fulminant and necrotising pancreatitis— Peritoneal lavage / laparotomy with adequate drainage and removal of necrotic tissue are done.

* An urgent USG or CECT scan (preferable) of the abdomen is required to confirm the diagnosis, to exclude other diagnosis (e.g., perforation of viscus) or to see whether phlegmon/abscess has formed or not.

** No. 12, 13, 14, 15 may be given empirically.

*** Inj. insulin is given for hyperglycaemia, I.V calcium for hypocalcaemia and ventilatory support for ARDS. Low molecular weight heparin (LMWH) is given for prophylaxis of deep vein thrombosis (DVT).

N.B : An ITU set up is necessary for porper treatment. In the management of acute pancreatitis APACHE II (acute physiology and chronic health evaluation) or CECT scoring system should be carried out to assess the severity of the attack. Now-a-days, enteral nutrition (by a nasojejunal tube, which crosses stomach and pancreas, and thereby prevents gastric paresis and pancreatic stimulation) is preferred over total parenteral nutrition (associated with a high risk of infection). Lexiplafant, a platelet-activating factor is advocated by few clinicians though not every effective.

Serum amylase value > 150 Somogyi unit/dl should raise the question of acute pancreatitis. Levels > 300 units make the diagnosis more likely, and values > 3 times normal virtually clinch the diagnosis. Serum amylase is usually elevated within 24 hours and the level gradually falls back towards normal over the next 3-5 days. Serum lipase levels remain elevated for a longer period of time than amylase.

CHOLERA WITH SEVERE DEHYDRATION

Cholera is a severe acute G.I. infection, caused by Vibrio cholerae (serotype 01) and is characterised by acute onset of diarrhoea (exotoxin-mediated), vomiting, fluid and electrolyte loss, dehydration and acidosis. Renal failure may complicate the situation. The patient remains mentally clear*till to the end. Death is usually as a result of acute circulatory failure.

Management :

1. Complete bed rest *in isolation.* The excreta of the patient should be properly disposed off. Notify the municipality/corporation.
2. Record vital signs, i.e., pulse, respiration, temperature (rectal), BP, intake-output chart carefully.
3. Nothing should be given by mouth except the oral rehydration salt.
4. A quick clinical assessment of state and degree of dehydration is made by assessing general appearance, pulse, BP, skin turgor (elasticity), eyes, tears, mucous membrane, thirst, urine output and anterior fontanelle (in infants).
5. I.V fluids should be immediately started with Ringer's lactate solution (fluid of choice in cholera) at the rate of 50-100 ml/min. A large bore needle (e.g., No. 18) is inserted for this purpose. Ringer's lactate will continue till Dacca solution is available.
6. *Dacca solution—*

Nacl — 5g
$NaHC0_3$ — 4g
Kcl — lg
Distilled water — 1 litre

To start with, 4/5 litres of solution is prepared. This is the recommended fluid for treatment of cholera. The fluid required is calculated every 8 hourly from urinary output, vomitus, stool and estimated insensible loss, which may be upto 5 litre/24 hours in hot and humid climate. The Dacca solution replaces running Ringer's lactate solution till the peripheral pulse are palpable. Then the drip rate is reduced at the rate of 30 ml/min. When the pulse, BP become near normal (i.e., severe dehydration has been corrected), oral rehydration therapy replaces I.V fluid treatment.

7. Oral rehydration therapy by oral rehydration salt (ORS)—As suggested by WHO, the 'universal formula' is :

Nacl	3.5 g/1
$NaHCo_3$	2.5 g/1
Kcl	1.5 g/1
Glucose	20 g/1

The content of the packet is dissolved in one litre of sterile drinking water. It should be taken frequently as directed by the physician (depends on degree of dehydration). It should be used for next 48 hours or till diarrhoea persists.

8. Cap tetracycline (250 mg/cap)— 1 cap 6 hourly for 3 to 5 days. Other antimicrobials like ampicillin, fluoroquinoles, trimethoprim-sulphamethoxazole or azithromycin may be used.
9. If vomiting is incessant—- Inj. metoclopramide (5 mg/ml), 10 mg, I.M or inj. promethazine hydrochloride 25-50 mg, I.M as and when required. Inj. ondansetron 2 ml (4 mg), I.V may be given instead.
10. Acidosis is corrected by 50-100 ml of inj. sodium bicarbonate (7.5%) given I.V in shot push, according to the necessity.
11. If acute renal failure develops, send the patient for peritoneal or haemodialysis.

* In severe dehydration, total fluid deficit is usually 100-110 ml /kg.

** If Ringer's lactate is not available : 2 litres of isotonic saline is alternated with 1 litre of isotonic sodium lactate/bicarbonate, and potassium is added to it. Accurate fluid loss may be recorded by the use of 'cholera cot' (hole is made in the cot under patient's buttocks, and a graded bucket is placed there).

*** Convulsions (febrile convulsions) in children is treated by inj. diazepam (0.2 mg/kg/I.V dose).

**** inj chlorpromazine—50 mg, 6 hourly may be helpful in reducing intestinal secretion and fluid loss.

******* Calculation of rate of fluid to be infused :**

1 ml = 15 drops.

Infusing 540 ml (1 bottle) in 8 hours, give fluid at the rate of 1 drop/4 sec. i.e., 15 drops/min (approx).

Infusing 540 ml (1 bottle) in 6 hours, give fluid at the rate of 1 drop/3 sec. i.e., 20 drops/min (approx).

Infusing 540 ml (1 bottle) in 4 hours, give fluid at the rate of 1 drop/2 sec. i.e., 30 drops/min (approx).

HAEMOPTYSIS

Usually haemoptysis is scant and stops spontaneously. If haemoptysis is prolonged, massive (> 100-600 ml/24 hours) or alarming, the following treatment should be instituted immediately.

1. Reassurance. Complete bed rest in semi-reclined position with leaning on the affected side (if chest pain or chest X-ray indicates the side of lesion); this posture is maintained to prevent asphyxiation due to aspiration of blood into normal lung. Only liquid diet is allowed.
2. Advise for chest X-ray (PA and lateral view), if feasible. Blood should be sent for TC, DC, ESR, sugar, BT, CT, grouping and cross-matching; CT scan of thorax, if feasible.
3. Inj. diazepam—5-10 mg, I.M stat given.
4. I.V drip of normal saline is started as a 'route of emergency' and let the fluid run at the rate of 15-20 drops/min.
5. Record vital signs repeatedly. Thorough and meticulous general survey, and examination of chest and CVS (with special reference to mitral stenosis) to come to an aetiological diagnosis, should always be tried.
6. If shock supervenes, treat by :
   a) I.V normal saline infusion.
   b) Head-low position with intermittent 0_2 therapy at the rate of 4-6 litres/minute.
   c) Blood transfusion, as early as possible.
   d) Frequent bronchial aspiration to prevent collapse of the lung.
7. Cough suppression —Small and repeated dose of linctus codeine may be given in harassing or troublesome cough as coughing may prevent normal clotting after haemorrhage.
8. Inj. ethamsylate (125 mg/ml)—2 ml, I.M/I.V stat in severe haemoptysis, as a coagulant. Tab tranexamic acid (500 mg/tab) may be added, 1 tab 3 times daily as fibrinolytic inhibitor.
9. Syrup amoxycillin (125 mg/5 ml)—2 tsf 8 hourly to prevent secondary infection.
10. Treatment of the cause, i.e., antituberculosis drugs for pulmonary tuberculosis, antibiotics with higher doses in pneumonia, specific drugs for complicated mitral stenosis should be started.
11. If respiratory distress starts, think of asphyxiation due to aspiration. Intubation and suctioning are done by sending the patient to 'Respiratory Care Unit' (RCU). Endotracheal intubation is also indicated in ongoing bleeding, poor gas exchange and haemodynamically unstable patients.

A Fogarlty balloon catheter passed through bronchoscope may stop bleeding with tamponade technique. Removal of the clot may be done under bronchoscopic supervision. Lastly, surgical help may be sought. Few pulmonologists prefer bronchial artery catheterisation and embolisation in uncontrolled haemoptysis.

*** Haemoptysis according to age and time :**

- Young — tuberculosis, bronchiectasis, mitral stenosis, bronchial adenoma, arteriovenous malformations
- Around 40 years — Bronchogenic carcinoma
- Recurrent — Chronic bronchitis, bronchial adenoma, bronchiectasis

SEVERE ANAEMIA

Anaemia is the qualitative or quantitative diminution of RBC and/or haemoglobin concentration in relation to standard age and sex, and clinically manifested by pallor. When the haemoglobin concentration goes below 40%, i.e., Hb < 6 g/dl, it is designated as severe anaemia.

The patient usually complains of severe weakness, fatigue, light-headedness, giddiness, pre-syncope or fainting, lassitude, anorexia, palpitation, breathlessness, anginal pain, tingling sensation in the extremities (paraesthesia), insomnia and irritability, or dysphagia (Plummer-Vinson syndrome).

Causes :

1. Acute haemorrhage : Haematemesis and/or melaena, haemoptysis, menorrhagia, epistaxis, haematuria, bleeding haemorrhoids or road-traffic accident.
2. Acute haemolysis : Sickle cell crisis, thalassaemia.
3. Deficiency of iron, folic acid, vitamin B_{12} : Iron dificiency anaemia, megaloblastic anaemia.
4. Failure or depression of bone marrow : Aplastic anaemia, chronic infection, long-continued rheumatoid arthritis, chronic renal failure, lymphoma, disseminated carcinomatosis.

Management :

In the presence of cardiac or cerebral symptoms, emergency treatment by blood transfusion is necessary.

1. packed cell transfusion : One unit of packed red cell transfusion (450 ml) usually raises the haemoglobin concentration by about 1 g/dl in an average adult. Transfuse cautiously at the rate of 10-15 drops/minute. If the patient is in cardiac failure, always give I.V frusemide 20-40 mg before transfusion. In a suspected patent of IHD, keep the rate of transfusion at 10 drops/ minute. More then one unit of blood should not be transfused in 24 hours. In non-availability of packed cell, transfuse whole blood and discard the plasma. It is better to transfuse packed cell when Hb concentration is < 7g/dl.
2. Treatment of the underlying cause : This should be started simultaneously. Treat anaemia by replacement of iron, vitamin B_{12}, folic acid; combat CRF by drugs and haemodialysis, leukaemia by specific chemotherapy, aplastic anaemia by oxymetholone or bone marrow transplant.

- Other indications of blood transfusion are : (1) Hypertransfusion therapy—to block production of defective cells e.g., thalassaemia (2) Exchange transfusion e.g., haemolytic disease of the newborn.

** In India, one pouch usually contains 350 ml of blood (300 ml blood and 50 ml anticoagulant).

Hazards of transfusion :

About 5% patients receiving blood transfusion will have some reaction. The complications arising out of transfusion are often classified into acute (< 72 hrs) and delayed (> 72 hrs), but this results in a degree of overlap; thus an alternative is to consider them dividing into two broad groups, immune and non-immune reactions. Antibody-mediated reactions are directed against RBC, WBC, platelet, and immunoglobulins (e.g., IgA). The non-immune reactions are circulatory overload, thrombophlebitis, air embolism, iron overload and transmission of infectious agents.

The major hazards of transfusion are :

1. Febrile or pyrogen reactions with rigors (non-haemolytic).
2. Allergic reactions (urticarial and anaphylactoid).
3. Haemolytic reactions.
4. Circulatory overload.
5. Thrombophlebitis.
6. Air embolism.
7. Transmission of infection.
8. Complications of massive transfusion.
9. Transfusion haemosiderosis.
10. Dilutional coagulation defects.
11. Immunological sensitisation by compatible blood (eg, Rh-isoimmunisation).
12. Transfusion-related acute lung injury.
13. Hypothermia, plasticizers (components of bag get eluted, into bag's content and enter recipient's body).

Individual complications are analysed below :

(A) Febrile reactions (pyrogens, antibodies against donor's plasma protein or leucocytes antigens are thought to be responsible) : fever, chills, urticaria, pruritus etc.

Rx : 1. Slow the drip rate.

2. Cover with blanket; hot drinks.
3. Tab paracetamol (500 mg)—1 tablet orally.
4. Inj. promethazine or inj. diphenhydramine or inj. chlorpheniramine—1 amp, I.M, stat.
5. In recurrent febrile episodes—transfuse WBC-free and plasma-free red blood cells.
6. If rigor occurs—inj. diazepam, 1 amp (10 mg), I.M may be given. Keep the patient under close vigilance. Ralely, glucocorticoids or adrenaline may be required.

(B) Anaphylactic reaction : Read 'Syringe (5 ml/50 ml)' in 'Instruments and procedures' section.

(C) Haemolytic reaction (as a result of transfusing incompatible blood group/haemolysed blood/ improper storage of donor's blood) : Features—

1. Fever
2. Chill
3. Aching loin pain
4. Chest pain
5. Nausea, vomiting
6. Tachycardia
7. Hypotension
8. Throbbing of head
9. Breathlessness
10. Pallor

This is the 'stage of shock'. In the post-shock stage, haemoglobinuria develops; jaundice may develop after 12 hours. Ultimately, acute renal failure (ARF as a result of acute tubular necrosis) sets in.

Rx : 1. Immediately stop the transfusion.

2. Collect the clotted and EDTA-treated samples of patient's blood along with the remainder of the suspected unit and send them to the blood bank to repeat the cross-matching.
3. Blood should be examined for serum bilirubin and test of DIC (disseminated intravascular coagulation); plasma and freshly voided urine should be tested for free haemoglobin.
4. Management is targetted for preservation of intravascular volume and protection of normal renal function :
   a) Urine output should be 100 ml/hour or greater—by diuretics (inj. frusemide 40 mg, I.V), I.V fluid (normal saline) or mannitol (300 ml of 20%) infusion.
   b) 7.5% inj. $NaHCo_3$ (1 amp = 10 ml) may be added to I.V fluid to alkalinize the urine which will help in excretion of free haemoglobin.
   c) Treat DIC and ARF, accordingly.
5. Inj. hydrocortisone hemisuccinate 100-200 mg, I.V stat may be of some help.

(D) Circulatory overload : Features—

1. Breathlessness
2. Tightness of chest
3. Cough (dry)
4. Basal crepitations
5. Raised jugular venous pressure
6. Facial puffiness (late feature)

Rx : 1. Slow the rate of transfusion (stop transfusion, if required).

2. Propped-up position with moist 0_2 inhalation.
3. Inj. morphine—slow I.V injection in a total dose of 5-10 mg, at a rate of 2 mg/min.
4. Inj. frusemide—20-40 mg, I.V stat and may be repeated after 30 minutes.
5. Digitalis—0.5 mg in 10 ml normal saline, I.V, given over 10 minutes.
6. The patient may be transferred to ICU for continuous monitoring of pulse, BP, respiration and cardio-respiratory status. In disperate situation, intubation and positive-pressure ventilation may be required.

(E) Thrombophlebitis :

1. Tab paracetamol (500 mg, thrice daily) or aspirin (325 mg, thrice daily) or aceclofenac (100 mg, once daily after meal).
2. Elevation of the limb; application of crepe bandage.
3. In severe infection, antibiotics may be required.
4. Tab serratiopeptidase (10 mg, thrice daily) or trypsin-chymotrypsin preparation (thrice daily).
5. Ointment containing heparin and benzyl nicotinate (e.g., thrombophob) to apply locally.

(F) Air embolism : The incidence is less with collapsible plastic bags.

Features : Breathlessness, tachycardia, hypotension, cyanosis and syncope.

Rx : 1. The patient is placed on left lateral position.

2. Head-end down with foot-end up position.
3. Help of cardio-thoracic surgeon is sought for.

If these positions are adopted, air may be disloged/displaced from the outflow tract of right ventricle.

(G) Transmission of infection :

1. Hepatitis B virus
2. Hepatitis C virus
3. HIV-I and HIV-2
4. HTLV-1
5. West Nile virus
6. Malaria
7. Syphilis
8. Cytomegalovirus
9. Brucellosis
10. Yersinia
11. Trypanosomiasis
12. Toxoplasmosis

(H) Complications of massive transfusion :

Administration of blood products in 24 hours of greater than the normal volume of blood of the patient (e.g., > 5 litre) may be associated with (massive transfusion)—

1. Hypothermia—Rapid infusion of chilled blood may produce cardiac dysrrhythmias. So, prevent the situation by warming the blood before transfusion.
2. Citrate intoxication—Patient may develop hypocalcaemia (paraesthesia, tetany, hypotension and low cardiac output) and is usually seen in patients with hepatic dysfunction. Calcium gluconate, I.V, 10 ml of a 10% solution may prevent the situation.
3. Hyperkalaemia and acidaemia may occur—usually not significant.
4. Bleeding complications—this may happen as a result of dilution of platelet and coagulation factors. Transfusion of fresh blood may tackle the situation.
5. Microembolism—may lead to acute lung injury.

(I) Iron overload—As each unit of RBC contains 200-250 mg of iron, iron overload features (i.e., endocrine, hepatic and cardiac dysfunction) occur after 100 units of RBC transfusion. So, judicious transfusion is preferable.

(J) Transfusion-related acute lung injury :

Antileucocyte antibodies present in donor's blood are responsible; usually develops within 4 hours of transfusion and often indistinguishable from ARDS (adult respiratory distress syndrome).

Features—Breathlessness, hypotension, fever, chills and hypoxaemia.

Rx : by ventilatory support. Usually diuretics are of no help.

MANAGEMENT OF CARDIAC ARREST (CPR)

Cardiac arrest is the sudden and complete loss of cardiac function where the pulse is not palpable, BP can not be recorded, respiration stops and the patient becomes unconscious. Unless promt treatment is started within 4-5 minutes, the patient dies. Ventricular fibrillation, pulseless ventricular tachycardia, cardiac asystole or electromechanical dissociation is responsible for cardiac arrest. **Cardiopulmonary resuscitation (CPR)** should be immediately instituted to rescue patients with acute circulatory or respiratory failure or both, followed by implementation of advanced life support measures.

(Causes of cardiac arrest :

1. Ventricular fibrillation (VF) or pulseless ventricular tachycardia—acute myocardial infarction (AMI), drugs (e.g., quinidine or digitalis toxicity), electrical shock, dyselectrolytaemia (1K^+ or TK^+, 4Ca^{++}, 4-Mg**).
2. Ventricular asystole—massive AMI, failure of conduction.
3. Electromechanical dissociation—rupture of the heart, massive pulmonary thromboembolism.]

Basic life support (BLS) starts immediately :

1. Check the patient's responsiveness-—Shake and shout.
2. Airway : The patient should be placed on a firm, flat surface in face up, i.e., in an extended supine position with elevated legs. Extend the neck (head tilt) and raise the chin (chin lift). Remove visible vomitus debris or dentures after opening the mouth. If any foreign body is suspected, the patient is rolled over to one side and 4-5 forceful blows are delivered rapidly between two shoulder blades by the heel of the palm; again the patient is placed in supine position. Oropharyngeal aspiration may be needed.
3. Breathing : Mouth to mouth breathing (direct or indirectly via a ventilation tube) should be started immediately at the rate of 12/minute. Extending patient's neck, pinching patient's nose by index finger and thumb, and placing a gauge piece on patient's mouth, start mouth to mouth respiration. First, take a deep inspiration and then exhale totally on the patient's mouth. Always look at the patient's chest for signs of expansion (i.e., for signs of adequate ventilation). If facilities are available, ventilate with Ambu bag, face mask. Start 100% 0_2. In foreign body obstruction within larynx or trachea, *Heimlich's manoeuvre* should be attempted to relieve the obstruction (standing behind the patient, encircle the waist with your arms. A clenched fist is placed against the epigastrium, above umbilicus but below the xiphistemum. After grasping the fist with the other hand, quick upward thrusts are applied into the patient's abdomen several times necessary to clear the airway).
4. Circulation : If carotid or brachial pulse is still not palpable, deliver a blow over the chest and start closed cardiac massage immediately. With the heel of both hands (one placed above the other), the lower part of the body of sternum is compressed vertically (depresing sternum by 3-5 cm) at the rate of 60-100/ minute after placing the patient on a hard surface. For one rescuer, ventilate twice after 15 chest compressions; and for two rescuers ventilate once after 5 chest compression. Cardiac massage should be gentle, rhythmic and smooth.

[5. Automated external defibrillator (AED); Since VF is the major cause of cardiac arrest, application of early defibrillation by paramedical staffs or doctors is of paramount importance.]

6. Try to record an ECG of the patient to come to an aetiological diagnosis. The BLS should be stopped for 5 seconds at the end of first minute (and thereafter every 2-3 minutes) to assess whether spontaneous breathing or circulation has resumed or not. The BLS should be continued till ALS is made available for revival. Now start **advanced life support (ALS)** as follows ;

(A) Cardiac asystole —

Precordial thump or blow; if vital signs do not return

i

Inj. adrenaline—5-10 ml of 1 ; 1000 aqueous solution by I.V route

I

Inj. atropine 3 mg, I.V, once only

I

Inj. calcium chloride (10%)—5-10 ml of the solution is given, I.V slowly

i

If electrical activity is yet to be evident, support life by transvenous or transthoracic pacemaker

(B) Ventricular fibrillation—

' Precordial thump or blow

i

Defibrillate by DC shock with 200 Joules initially

I

Repeat DC shock with 360 Joules

i

Inj. adrenaline—5-10 ml of 1 : 1000 aqueous solution by I.V route

I

Mouth to mouth breathing with simultaneous closed cardiac massage

1

If this fails, start lignocaine 75 mg bolus in I.V shot push; then continue 50 mg, I.V every 5 minutes upto a maximum dose of 225 mg

I

Inj. bretylium 5 mg/kg bolus in I.V shot push

I

Defibrillation by DC shock with 360 Joules

* Intubate the patient and resuscitate by assisted ventilation; always try to correct acidosis.

** VF is the most common and easily treatable cause of cardiac arrest.

(C) Electromechanical dissociation—

Inj. adrenaline— 5-10 ml of 1 : 1000 aqueous solution by I.V route

4

Try to correct acidosis, hypoxia, hypovolaemia, hypothermia, electrolyte imbalance, pulmonary embolism (if present)

I

Mouth to mouth breathing with simultaneous closed cardiac massage

7. Acidosis—Inj. sodium bicarbonate (7.5%) 50 ml, I.V stat and 30-50 ml to be repeated every 10 minutes till circulation is restored.
8. Hypotension—Start dopamine infusion (2-20 (ig/kg/min) by mixing 200 mg of inj. dopamine in 540 ml of normal saline and to run at the rate of 10-12 drops/min. Try to adjust the systolic BP near about 100 mm of Hg.
9. Cerebral oedema—Inj. hydrocortisone hemisuccinate 500 mg, I.V stat.
10. Termination of CPR—If pulse is absent, BP is non-recordable, spontaneous respiration is lacking and the patient remains unconscious for 30 minutes with fixed and dilated pupils—terminate CPR. A flat ECG diagnoses cerebral death.

* ALS targets to restore normal cardiac rhythm and give support to circulation by defibrillation, I.V drugs, positive pressure ventilation etc.

PAROXYSMAL ATRIAL TACHYCARDIA (PAT)

In PAT, the pulse rate is usually 160-220/min and the rhythm is regular. It is thought to be due to a run of rapidly repeated atrial premature beats.

1. Non-pharmacological (mechanical) measures to increase the vagal tone :
   a) Valsalva manoeuvre in supine position (most effective way),
   b) Carotid sinus massage (after excluding occlusive carotid disease),
   c) Self-induced gagging,
   d) Pressure over the eyeballs, coughing, breath holding, stretching the arms and body, lowering the head between two knees.

* These physical measures delay the AV conduction, blocks the re-entry phenomenon and may terminate the attack.

2. Drugs (if mechanical measures fail) :
   a) Adenosine—It is a very short-acting naturally occuring purine nucleoside and a first-choice drug for PAT. The dose is 6 mg given as a rapid I.V bolus followed by a 10 to 30 ml saline flush; if necessary, may repeat with 12 mg, I.V bolus. Contraindications for its use are 2° or 3° AV block, atrial fibrillation, sick sinus syndrome and ventricular tachycardia. It may produce bronchospasm in asthmatics; other side effects are flushing, cheat pain, heaviness in the limbs, transient hypotension or atrial standstill. Usually the attack of PAT is terminated within a few seconds.
   b) Verapramil—If adenosine is not effective, inj. verapramil 5-10 mg, I.V is given over 5 minutes which may terminate the attack; if no effect, the drug may be repeated after 30 minutes.
   c) Other drugs—
      Metoprolol (5 mg, I.V bolus upto 15 mg),
      Esmolol (500 **Mg/kg** I.V bolus, **then** 50 **|ig/kg/min),**
      Digitalis (0.75-1 mg, I.V loading),
      Amiodarone (200 mg) or disopyramide (200 mg) orally may be effective.
3. DC shock :
   If drugs fail or the patient shows signs of cardiogenic shock (haemodynamically unstable), heart failure or angina—synchronized DC shock (150 Joules) may prove effective.
4. Follow-up—Avoid tea, coffee, smoking, alcohol, exclude underlying valvular heart disease or thyrotoxicosis. Advice tab. verapramil (80 mg) 1 tab thrice daily to continue.

* Ideally, the carotid massage, antiarrhythmic treatment and DC shock should be done in an ICU under ECG monitoring.

ACUTE RHEUMATIC FEVER

1. Complete bed rest till fever, arthritis, carditis, WBC count, ESR and tachycardia subside. Prolonged bed rest is necessary for 2-6 weeks in **rheumatic carditis.**
2. High calorie, salt restricted diet.
3. Chorea—is being treated by reassurance, clonazepam, chlorpromazine or haloperidol.
4. Symptomatic treatment :
   a) Arthritis, arthralgia, fever—aspirin (0.3 g/tab; acetyl salicylic acid) is started in a dose of 80-120 mg/kg/day in children and 4-8 g/day in adults in 4-6 divided doses, and continued for 2 weeks. If symptoms subside, a lower dose of 60-70 mg/kg/day (in children) is continued for a further 2-4 weeks. Gastric intolerance may be combated by giving antacid 15-30 min after each dose of aspirin, or proton-pump inhibitor. Typically, aspirin should be continued until ESR becomes normal, and then tapered off gradually.
   b) Patient without carditis—aspirin is preferred.
   c) Patient with carditis but without heart failure—aspirin + glucocorticoid (role of corticosteroids are doubtful in carditis but majority of cardiologists opine that they help in rapid resolution of heart failure). Prednisolone (5 or 10 mg/tab) 1-2 mg/kg/day (maximum of 80 mg) is given orally for a period of 2 weeks and then tapered off over next 2 weeks.
   d) Patient with carditis and heart failure—majority opine that corticosteroid is mandatory over and above aspirin. Treatment of CCF is done accordingly (see before).
   e) Antibiotics—Single injection of 1.2 million units of benzathine penicillin, I.M is given to eradicate Group A streptococcus, if present (after proper skin test). Oral penicillin V (phenoxymethyl penicillin) 500 mg twice daily, orally for 10 days or erythromycin 40 mg/kg/day, orally may be used for 10 days (in patients allergic to penicillin).
5. Secondary prevention of acute rhumatic fever : The mainstay of controlling rheumatic heart disease is secondary prevention. The dose of inj. benzathine penicillin is 1.2 million units, I.M given at 3 weekly interval (in endemic areas and high-risk cases, the interval is 2-3 weeks).
   Dose of penicillin in children is 0.6 million units. Instead oral penicillin V may be used 250 mg

twice daily or oral erythromycin 250 mg twice daily (in penicillin allergy). Controversies exist regarding duration of therapy and the guideline is—

a) Rheumatic fever without proven carditis—5 years after the last attack or until the age of 18 years, whichever is longer.

b) Rheumatic fever with carditis but having minimal residual valve damage—10 years after the last attack or 25 years of age, whichever is longer.

c) Rheumatic fever with carditis along with residual heart disease—10 years after the last episode or until the age of 40, whichever is longer. Few clinicians prefer to give penicillin life long in this situation.

d) If valvular surgery is done—penicillin prophylaxis is continued life long.

6. Follow up :

Echocardiographic evaluation in assessing subsequent valve lesions, specially in patients with carditis.

* Prophylaxis against infective endocarditis is needed in valve damage.

** 'Post-steroid rebound' may be prevented by an 'overlap' course of aspirin when the corticosteroid is being tapered over a 2 week period. Aspirin in then continued for 2-3 weeks more.

TETANUS

The diagnosis of tetanus is made on clinical grounds. The disease is characterised by muscular rigidity, spasm of muscles, trismus, risus sardonicus (facial grimace), neck rigidity, opisthotonus (forward bending of the body like an arc), autonomic disturbances but the consciousness and mental clarity remain intact till to the end.

Management :

1. Isolation; preferably transfered to 'Infectious diseases' ward or hospital.
2. Complete bed rest in a railed cot in a noise-free (quiet), dark room. There should not be any undue light, sound or cutaneous stimulation for the patient.
3. If oral feeding is possible, give liquid feed orally. If not possible, insert Ryle's tube. In its failure, maintain nutrition by I.V fluid therapy.
4. Skilled nursing is necessary. Check vital signs repeatedly. Maintain intake-output chart. Cleanse the wound (if any) with soap-water/povidone-iodine/normal saline-20% hydrogen peroxide solution; debridement, if necessary.
5. Maintain airway.
6. Inj. Human Tetanus Immunoglobulin (HTIG)—I.M injection of 500 units of antitoxin; single dose. It should be given after proper skin test though hypersensitivity reaction is rare. HTIG is administered before manipulating the wound. Pooled IVIG may be an alternative to HTIG.
7. Inj. crystalline penicillin—2 million units, I.V, every 4-6 hourly after proper skin test, for 10 days. Metronidazole (500 mg/100 ml)—500 mg, I.V, 6 hourly; erythromycin or clindamycin may be given in penicillin allergy.
8. Inj. diazepam (5 mg/ml)—10 mg is given I.V stat and may be repeated, if necessary in muscle spasm/convulsions. Larger doses of diazepam may be required (> 250 mg/day); lorazepam and midazolam are other options. Chlorpromazine, baclofen or tizanidine may also be used in muscle spasm. Neuromuscular blockade may be necessary.
9. Labetalol, esmolol, clonidine or verapramil may be considred in autonomic dysfunction.
10. Tracheostomy and assisted ventilation are necessary in asphyxia due to laryngeal spasm or hypoventilation from oversedation.
11. I.V fluid therapy is done by 5% dextrose (1 bottle), dextrose-normal saline (2 bottles) and amino acid (1 bottle) infusion. Total 4 bottles/day are required.
12. Inj. tetanus toxoid—ft should be given I.M (0.5 ml) at a different site of HTIG, and should be repeated (0.5 ml, I.M) after 1 month and 6 month.

ORGANOPHOSPHORUS COMPOUND POISONING

These insecticides are potent inhibitors of cholinesterase. They are absorbed quickly after ingestion, inhalation or through the intact skin. Inactivation of acetylcholinesterase allows accumulation of excessive acetylcholine at different neurosynaptic sites like CNS, autonomic ganglia, parasympathetic and motor nerve endings. The **organophosphorus compounds** are malathion, parathion, guthion, chlorothion and diazinon; common **carbamate insectisides** are carbaryl, propoxur and aldicarb.

Management :

1. Gastric lavage with normal saline in a hospital. The first sample should be kept fpr toxicology. Change the soiled clothings and preferably, wash the contaminated skin with soap and water. Wash the contaminated eyes with normal saline.
2. 100 g of activated charcoal is mixed in $/_2$ bottle of normal saline and introduced into the stomach through Ryle's tube. This is done after a satisfactory stomach wash.
3. Inj. atropine sulphate (0-6 mg/amp)—4-5 amp. I.V stat and 1-2 amp. to be given by slow I.V route at every 5-10 min interval till full atropinization is achieved, i.e., the mouth is dry, pulse becomes >100/min and pupil becomes fully dilated. Afterwards, 1 amp. to be given I.V, 8 hourly for next 2-3 days. Atropine counteracts the *muscarinic effects* of organophosphorus poisoning.
4. Inj. pralidoxime (PAM)—1 g in aqueous solution to be given I.V stat over 5-10 minutes, and to be repeated 3 to 4 times daily (maximum total dose is 4 g) for 2-5 days. Alternatively, an infusion of PAM may be given at the rate of 8-10 mg/kg/hour. PAM counteracts the *nicotinic effects* as well as the muscarinic effects of organophosphorus poisoning. PAM is a cholinesterase reactivator and should be started as early as possible.
5. Moist 0_2 inhalation at the rate of 4-6 litres/min; if required (respiratory failure), ask for assisted ventilation. Place the patient in a railed cot.
6. Suction of the mouth, oropharynx and nose repeatedly.
7. Inj. diazepam—5 mg, I.V slowly, if convulsions appear.
8. Inj. frusemide (20 mg/amp)—20 mg, I.V stat and may be repeated in non-cardiogenic pulmonary oedema. Few clinicians advocate inj. hydrocortisone hemisuccinate 100-200 mg, I.V stat in this situation.
9. Maintain an I.V drip with dextrose (5%)-normal saline solution at the rate of 15 drops/min.

* Upto 100 amp. (60 mg) or even more of atropine may be given in quick succession in moribund patient of poisoning by organophosphorus compound.

** PAM is of little value if started after 24 hours of incidence of poisoning.

*** Signs of **atropinisation**—Tachycardia, dry mouth (can not spit), fixed and dilated pupil, rise of surface temperature. Signs of over-atropinisation—Restlessness, disorientation, delirium, hyperpyrexia, subsultus tendinum (involuntary movements of fingers) and irrelevant talks. In over-atropinisation, give inj. haloperidol 1 ml (5 mg), I.M stat.

**** patients of **organophosphorus poisoning** show following features : Nausea, vomiting, diarrhoea, blurring of vision as a result of miosis, sweating, lacrimation, salivation, bradycardia, hypotension, involuntary urination and defecation (muscarinic *effects).* They may also have muscular twitching, fasciculations, tachycardia, hypertension, extreme weakness and flaccid paralysis *(nicotinic effects).* The *CNS effects* are anxiety, restlessness, tremor, convulsions, confusion and coma.

SNAKE BITE

Venomous snakes are basically of three families :

a) Viperidae—Crotalinae (pit vipers, rattle snakes) and Viperinae (Russell's viper). This group is vasculotoxic and presents with haemorrhages from different sites like haematuria and haemoptysis, vomiting, shock, intense local reaction and acute renal failure.

b) Elapidae (cobras, kraits, mambas, coral snakes)—This group is neurotoxic and produces ptosis, facial palsy, bulbar palsy, muscle weakness, paralysis of respiratory muscles, blurred vision and slurred speech.

c) Hydrophiidae (sea snakes)—This group is myotoxic and produces myoglobinuria, acute renal failure. In majority of sea snakes, no venom is released (dry bites).

* There are two other venomous snake family called Colubridae which includes mongoose snakes, and Atractaspididae (Natal black snake) which gives rise to coronary vasoconstriction or AV conduction defects.

Management :

1. First aid measures— Reassurance; if necessary, mild sedation (alprazolam 1 tablet, i.e., 0-25 mg) is given to allay apprehension. Firm and wide pressure bandaging is applied 5 cm above the bite area, preferably with 'immobilisation' by a splint. The tourniquet (even a handkerchief will do) should be so tight (lympho-occlusive dressings) that it would allow the tip of one finger only to pass through, and will obstruct the lymph flow and not the arterial or venous circulation. The tourniquet should be released at 20 minutes interval for 1-2 minutes and reapplied just proximal to the progressing oedematous area.

   Now-a-days, application of tourniquet seems to be controversial. It may be used if the transit period is > 60 minutes from the time of bite to application of antivenin. In fact, it worsen local tissue necrosis. According to recent trend, tourniquets should not be used as it leads to higher rates of amputation of limb.
2. Try to identify the snake and refer the victim to nearby hospital.
3. Inj. polyvalent antivenin serum (AVS)—First do the intradermal test by 01 ml of the solution (after mixing 1 unit in 10 ml of distilled water). Inj. adrenaline (1 : 1000 solution) must be kept ready in hand to combat anaphylaxis. If there is absence of any skin reaction, mix 10 vials (each vial containing 1 unit of antivenin are made into 10 ml solution) in 400 ml normal saline and let it run at the rate of 50-100 drops/min, I.V according to severity. Again, 10 vials may be repeated, if necessary. AVS gives maximum benefit, if given within 24 hours.
4. Inj. benzathine penicillin—1.2 million units I.M stat after proper skin test to check secondary infection of the devitalised bitten area.
5. Inj. diclofenac (25 mg/ml)—2 ml, deep I.M stat in severe local pain.
6. Inj. Human Tetanus Immunoglobulin (HTIG)—If the patient did not receive full course of inj. tetanus toxoid earlier, give 250 units stat by I.M route (after proper skin test).
7. Inj. tetanus toxoid—0-5 ml, I.M stat and to be repeated after 1 month (0-5 ml, I.M) and 6 month (0-5 ml, I.M).
8. Blood transfusion, if the patient is in shock or there is profuse internal haemorrhage.
9. *Shock and hypotension*—Albumin (5%) infusion is better than dextrose or normal saline. Dopamine infusion (2-20 mg/kg/min) or even inj. hydrocortisone hemisuccinate 200 mg, I.V slowly or fresh frozen plasma (FFP), may be started. Moist O_a inhalation is given at the rate of 4-6 litres/min.
10. *Acute renaljailure*—Try to correct the electrolyte imbalance and give sufficient fluid parenterally. Inj. mannitol (20%) 300 ml is infused over 3 hours or large dose of frusemide (100-200 mg) I.V is given. If not corrected by above measures, the patient may require *peritoneal or haemodialysis.*
11. In Elapidae (cobra) group of snake bite—Inj. neostigmine 0-5 mg (1 ml) is given, I.V every half an hour for 4-6 injections until the ptosis or neurodeficit is corrected (here, the toxin blocks neuromuscular junction). Then injection neostigmine is given every one hourly and ultimately to be given at 2-3 hours interval till all signs of paralysis have disappeared.

    Every injection of I.V neostigmine should be preceded by 0-6 mg (1 amp) of inj. atropine given by I.V route.
12. *Respiratoryfailure*—In respiratory muscle paralysis (by Elapidae group), ventilation by a respirator and proper control of blood gases should be employed.
13. Lately surgical debridement, fasciotomy or skin grafting may be needed.

* As the outcome of snake bite is unpredictable in the initial stage, all cases should be carefully monitored for at least first 12 hours. Dose of antivenin serum (AVS) in children is either equal or a bit more than the adult dose. Antibiotics covering gram-negative organisms and anaerobes are advocated in local infection.

** Spreading blisters suggest a massive dosage of venom. Vomiting, hypotension, bleeding from different sites are signs of systemic envenomation. Wound debridement and skin grafting afterwards may be required, specially in cobra and viper bites. If no pulse is felt in a bitten limb, 'compartment syndrome' should be suspected and surgical help should be immediately sought for.

*** *Conventional dosage schedule of* AVS :

a) Only local swelling, no systemic symptoms—2-5 units.
b) Systemic symptoms/haemorrhagic abnormalities—5-9 units.
c) Severe systemic manifestations/shock—10-15 units.

**** **Do not do** : cruciate incision and suction over the fang marks, applying ice packs, tight ligatures and local antivenin infiltration, giving the victim alcoholic beverage or applying electric shock.

***** In positive antivenin (AVS) skin test, pretreat with H_1 and H_2 blockers and dilute the antivenin. Treat anaphylaxis with inj. adrenaline and inj. hydrocortisone. In spite of reactions, in a desperate situation, start the 'diluted' antivenin in a 'slow' infusion.

N.B. : Do it 'RIGHT' in snake bite : reassurance, immobilization of the extremity, go to the hospital and tell the doctor telltale symptoms and signs.

DOG BITE

1. Immediately cleanse and scrub the wound vigorously with soap water; then flush with normal saline solution. Chemical treatment with any virucidal agent e.g., alcohol, tincture iodine or povidone-iodine may now be done. Chemical cleansing with 1-4% benzalkonium chloride or 1% centrimonium bromide may be effective in inactivating the virus. If necessary, debride surgically. Do not put any suture to close the wound (i.e., left open).
2. Confine the dog and observe for at least 10 days, if possible.
3. Inj. Human Rabies Immunoglobulin (HRIG) 10 IU/kg is infiltrated around the bite and another 10 IU/kg is given by I.M route in the gluteal region. If hyperimmune animal serum is available, double the dose. Always do intradermal test for any hypersensitivity reaction.
4. Inj. Human Diploid Cell Vaccine (HDCV)—It is the safest and recommended vaccine, and 1 ml is given I.M in the deltoid, on days 0, 3, 7, 14, 28 and 90. The dose on the day 90 is the booster dose. Local reactions, e.g., swelling, erythema and induration at the injection site are not uncommon. This vaccine is costly.
5. Inj. Human Tetanus Immunoglobulin (HTIG)—250 units by I.M route stat (after skin test).
6. Inj. tetanus toxoid— 0-5 ml, I.M stat and to be repeated after 1 month (0-5 ml, I.M) and 6 month (0-5 ml, I.M).
7. Inj. crystalline penicillin—10 lac units, I.M twice daily for 7 days after proper skin test. Co-amoxyclav (amoxycillin 500 mg + clauvulinic acid 125 mg) 625 mg, tds for 5 days is an alternative to penicillin. Moxifloxacin 400 mg, once daily, orally may be given in suspected mixed aerobic and anaerobic infection.
8. Observe the patient for development of any neurological abnormality. Allow normal diet.
9. If the dog dies or is killed, the brain should be examined for Negri bodies by immunofluorescence test in a specialised centre. In this situation, report to the concerned physician.

* HRIG is not given in every case. If the dog may ue suspected to be rabid, immediately start HRIG.

** If the dog is found to be healthy even after 10 days, probably it does not have rabies.

*** Pre-exposure prophylaxis by HDCV in I.M route may be given (persons at risk) on days 0,7, and 21 or 28.

**** jf 7 days have elapsed after dog bite, it is not necessary to give HRIG because endogenous antibodies have already being produced.

SCORPION BITE

Scorpion stings pose a big problem in many regions of the world, often reported from rural areas, specially in developing countries like India. Common poisonous scorpions in India are black scorpion (Palamneus) and red scorpion (Mesobuthus).

1. Apply ice packs to wound. Apply tourniquet proximal to the site of bite. Reassurance.
2. Inj. pheniramine maleate 15 mg, I.M stat or inj. promethazine hydrochloride 50 mg. I.M stat is given.
3. Inj. tetanus toxoid—0-5 ml, I.M stat and to be repeated after 1 month (0.5 ml, I.M) and 6 month (0-5 ml, I.M).
4. Local infiltration (ring block) by inj. lignocaine hydrochloride (2%) usually ameliorates the severe local pain. The usual dose is 2-5 ml which may repeated after 1/ hour. Local emetine or dehydroemetine also relieves pain but may produce tissue necrosis. NSAID may be used to relieve pain.
5. Inj. antivenin (serotherapy)—May be given I.V in cranial nerve dysfunction and increased involuntary activity in sketetal muscles. Practically, this is not required in most of the patients. Specific antivenin, if available, should be administered at the earliest.
6. Inj. diazepam—5-10 mg, I.M stat if the patient becomes restless.
7. Prazosin (1 mg/tab), 1 tab stat and 0.25-0.5 mg every 4-6 hourly may be administered to control hypertension. It is the sheet-anchor and most promising drug in the prevention of cardio-pulmonary complications (e.g., pulmonary oedema). Prazosin is usually indicated in extremes of ages and severe poisoning.
8. Corticosteroid may be given in severe cases. Management of DIC (disseminated intravascular coagulation) should be done, if present. Infusion of glucose-insulin solution may be beneficial in systemic envenomation.
9. Others—dopamine infusion for hypotension, intubation for respiratory failure, and frusemide for acute pulmonary oedema. Always monitor the patient for arrhythmia, conduction abnormalities and arterial O_2 saturation.

CHAPTER VI : DRUGS

DRUGS ON AUTONOMIC NERVOUS SYSTEM :

Drugs Oral	***Dosage*** ***Parenteral***	***Indications***	***Contraindications***	***Adverse effects***
ADRENALINE	0.2-0.5 ml, S.C/I.M (1 in 1000 in 1ml)	1. Anaphylaxis 2. Cardiac resuscitation 3. Bronchial asthma 4. Arrest of haemorrhage in epistaxis or after tooth extraction	1. IHD 2. Systemic hypertension 3. Tachycardia 4. Cardiac dysrrhythmia	1. Pain chest(angina) 2. Pallor, palpitation, tremor, headache 3. Sudden elevation of BP 4. Ventricular dysrrhythmia in patients with infarction
DOPAMINE —	2.5-5 (ig/kg/ min (diuresis) 5-10 |xg/kg/ min (stimulates cardiac contraction)	1. Cardiogenic shock 2. Hypotension 3. Cardiac arrest 4. Refractory heart failure	Hypertrophic cardiomyopathy	1. Nausea, vomiting 2. Chest pain 3. Palpitation 4. Arrhythmias
DOBUTAMINE	2.5-10 ng/kg/min	Same as dopamine	Same as dopamine	Same as dopamine
BETA-BLOCKERS a) (eardioselective : atenolol, metoprolol, acebutol, bisoprolol, betaxolol, celiprolol) b) (Beta-blockers used in heart failure : carvedilol, metoprolol. bisoprolol, bucindolol)	Widely varies accor-■ — ding to aetiology and beta-blocker with different mode of action e.g., propranolol 10-320 mg, labetalol 200-800 mg	1. Migraine (prophylaxis) 2. Anxiety neurosis 3. Thyrotoxicosis 4. Glaucoma (open angle) 5. Portal hypertension (variceal bleeding) 6. Angina, systemic hypertension, SVT, anoxic spells of Fallot's tetralogy, IHSS, AMI 7. Pheochromocytoma 8. Essential tremor 9. Reduction of infarction (myocardial) size	1. Bronchial asthma 2. CCF 3. Heart block 4. Cardiogenic shock 5. Bradycardia 6 Patients on oral hypoglycaemic agents 7. Peripheral vascular disease	1 Bradycardia, heart block 2. Bronchospasm 3. CCF 4. Hypoglycaemic unresponsiveness in diabetes mellitus 5. Fatigability, depression 6. Constipation 7. Cold extremities 8. Nightmare, skin rash 9. Impotence

Drugs	Dosage: Oral	Dosage: Parenteral	Indications	Contraindications	Adverse effects
ATROPINE	—	0.6-12 mg (0.6 mg/ml)	1. Organophosphorus poisoning 2. dysmenorrhoea and intestinal colic 3. Complete heart block 4. Pre-anaesthesia 5. For mydriasis and cycloplegia 6. For ophthalmoscopy 7. As an antidote to neostigmine	1. Glaucoma 2. Enlarged prostate 3. Psychosis 4. Pyloric stenosis 5. Paralytic ileus	1. Palpitation 2. Retention of urine 3. Blurring of vision 4. Psychosis 5. Precipitation of glaucoma 6. Paralytic ileus 7. Dry mouth
NEOSTIGMINE	15-30 mg	0.5-2 mg, S.C or I.M	1. Myasthenia gravis 2. Snake bite (Elapidae gr.) 3. Supraventricular tachycardia 4. Retention of urine, paralytic ileus 5. Curare poisoning	1. Hypersensitivity 2. Peritonitis	1. Salivation, sweating 2. Pain abdomen or diarrhoea 3. Pain chest 4. Tremor 5. Fasciculations
OXIMES (pralidoxime)	—	lg, 8 hourly. I.V slowly	Organophosphorus poisoning (malathion, parathion)	1. Hypersensitivity 2. Carbamate poisoning	1. Thrombophlebitis 2. Drowsiness 3. Diplopia 4. Palpitation 5. Giddiness
EPHEDRINE	30 mg	30 mg, S.C or I.M	1. Bronchial asthma 2. As a nasal decongestant 3. As a mydriatic 4. Nocturnal enuresis	Same as adrenaline	Same as adrenaline
EDROPHONIUM	—	10 mg, I.M	To diagnose myasthenia	Same as neostigmine	Same as neostigmine

Drugs	Dosage Oral Parenteral	Indications	Contraindications	Adverse effects
DRUGS USED IN BRONCHIAL ASTHMA / AIRWAYS OBSTRUCTION :				
SALBUTAMOL	4 mg, 8 hourly 100-200/mg by inhalation	1. Bronchial asthma 2. Hyperkalaemic periodic paralysis	1. Cardiac tachyarrhythmia 2. Narrow angle glaucoma	1. Tremor 2. Palpitation 3. Nervousness 4. Hypokalaemia
TERBUTALINE	5 mg, 8 hourly 0.5 mg S.C	Bronchial asthma	Same as salbutamol	Same as salbutamol
ISOPRENALINE	5-20 mg, sublingually 0.5 ml of 1 : 200 solution by inhalation. 1-10 mg/min by I.V route	1. Bronchial asthma 2. Stokes-Adams syndrome 3. Heart block 4. Severe bradycardia 5. Shock	1. IHD 2. Tachycardia	1. Tremor 2. Arrhythmia 3. Chest pain 4. Anxiety 5. Headache
AMINOPHYLLINE	— Loading dose : 6 mg/kg Followed by : 0.5-1 mg/kg/hr (mixed with N. saline or 5% dextrose)	1. Bronchial asthma 2. Cardiac asthma 3. As a diuretic 4. Sometimes in heart failure 5. Sometimes in COPD	1. Convulsion 2. Arrhythmia 3. Vomiting 4. Palpitation	1. Vomiting 2. Collapse 3. Convulsion 4. Headache
EPHEDRINE		See drugs on autonomic nervous system		
THEOPHYLLINE	100-600 mg 3-5 mg/kg, I.M or I.V	Bronchial asthma	Same as aminophylline	Same as aminophylline
DISODIUM CROMOGLYCATE OR NEDOCROMIL SODIUM	— 20 mg, 6 hourly by inhalation	1. Prophylaxis for acute episode of br. asthma 2. Allergic rhinitis	1. Acute asthmatic attacks 2. Status asthmaticus	1. Local irritation 2. Wheezing, breathlessness
IPRATROPIUM BROMIDE	— 20 mg/puff by inhalation, 8 hourly	1. COPD 2. Acute bronchial asthma, specially where the patient suffers from coexistent cardiac disorders 3. Acute attack of chronic bronchitis	1. Very old age 2. Where rapid action with highest potency is required	Mild anticholinergic side effect may occur

Drugs	Dosage Oral Parenteral	Indications	Contraindications	Adverse effects
KETOTIFEN	1-2 mg. — 12 hourly /day	I. Prophylaxis of bronchial asthma 2. Allergic rhinitis or conjunctivitis	1. Hypersensitivity 2. Glaucoma	1. Drowsiness 2. Increased appetite 3. Weight gain 4. Thrombocytopenia (rare)
DRUGS USED IN SYSTEMIC HYPERTENSION :				
ALPHA METHYLDOPA	250-750 mg, 8 hourly —	1. Syst. hypertension 2. Malignant hypertension 3. Hypertension with pregnancy	CVA (the drug produces drowsiness)	1 Sedation 2. Haemolytic anaemia 3. Diarrhoea 4. Gynaecomastia 5. Chronic active hepatitis 6. Lupus-like syndrome
CLONIDINE	0.1-0.6 mg, — 2 to 4 times/day	1. Syst. hypertension 2. Prophylaxis of migraine 3. Autonomic neuropathy in diabetes mellitus (nocturnal diarrhoea)	1. Hepatic coma 2. Sick sinus syndrome 3. Pheochromocytoma with hypertension	1. Postural hypotension 2. Drowsiness 3. Impotence 4. Dry mouth 5. Rebound hypertension after abrupt withdrawal
NIFEDIPINE	5-20 mg, — 8 hourly	1. Syst. hypertension 2. Hypertensive emergencies (rarely used) 3. IHD (chronic stable angina, Prinzmetal's angina) 4. Raynaud's phenomenon	1. Hypotension 2. Cardiogenic shock 3. Acute myocardial infarction 4. 2nd or 3rd degree heart block	1. Tachycardia 2. Ankle oedema 3. Flushing 4. Hyperplasia of gum 5. Hyperkalaemia 6. Headache 7. Constipation

Drugs	Dosage *Oral Parenteral*	*Indications*	*Contraindications*	*Adverse effects*
AMLODIPINE	2.5-10 mg, 12-24 hourly —	Same as nifedipine	Same as nifedipine	Same as nifedipine
CAPTOPRIL	12.5-75 mg, 12 hourly —	1. Systemic hypertension 2. CCF 3. Crisis of scleroderma 4. Diabetic nephropathy 5. Postmyocardial infarction	1. Pregnancy 2. Renal failre 3. Bilateral renal artery stenosis 4. Aortic stenosis	1 Cough (dry) 2. Hyperk^laemia 3. Pancytopenia 4. Disturbance of taste 5. Fever, pruritus, rash
* Other ACE inhibitors are ramipril (1.25, 2.5, 5, 10 mg), perindopril (2, 4, 8 mg), lisinopril (5, 10, 20, 40 mg), benazepril (5, 10, 20, 40 mg), fosinopril (10, 20 mg), quinapril (5, 10, 20, 40 mg)				
ENALAPRIL	2.5-40 mg daily —	Same as captopril		
BETA-BLOCKERS		See autonomic nervous system (atenolol and metoprolol mainly)		
INDAPAM1DE	2.5 mg/day —	Essential hypertension	1. Severe renal or hepatic failure 2. Hypokalaemia	1. Hyperuricaemia 2. Na+, K+ & H20 depletion 3. Dizziness
PRAZOSIN (alpha-blocker)	1-10 mg. 12 hourly —	1. Syst. hypertension 2. CCF 3. Pheochromocytoma 4. Benign hypertrophy of prostate	1. CCF due to mechanical obstruction 2. Hypotension	1. Postural hypotension 2. Dry mouth 3. Sudden syncope 4. Palpitation 5. Dizziness
RESERPINE (not used now)	0.05-0.25 mg 0.5-2.5 mg. daily I.V or I.M	1. Syst. hypertension 2. Hypertensive emergencies	1. Peptic ulcer • 2. Depression 3. Suicidal tendency 4. Epilepsy	1. Nasal congestion 2. Depression 3. Diarrhoea 4. Dyspepsia 5. Parkinsonism 6. Postural hypotension 7. Impotence

Drugs	Dosage Oral	Parenteral	Indications	Contraindications	Adverse effects
HYDRALAZINE	10-75 mg, 6 hourly	10-50 mg, I.V or I.M	1. Syst. hypertension 2. Renal diseases with hypertension 3. Malignant hypertension	1. Severe IHD 2. SLE	1. Angina pectoris 2. Lupus-like syndrome (SLE) 3. Headache 4. Dizziness 5. Palpitation
SODIUM — NITROPRUSSIDE		0.5-8 jag/ kg/min, I.V	1. Malignant hypertension 2. LVF, not responding to other drugs	Hypersensitivity	1. Sweating 2. Cyanide toxicity 3. Apprehension
DIAZOXIDE —		1-5 mg/kg upto 150 mg rapidly repeated after 5 min.	1. Malignant hypertension ; 2. Hypertensive emergencies	1. Severe IHD 2. SLE 3 CVA	1. Angina pectoris 2. Hirsutism 3. Hyperuricaemia 4. Hyperglycaemia 5. Fluid retention
LOSARTAN POTASSIUM (specific angiotensin-II receptor antagonist)	25-50 mg, once daily	—	Systemic hypertension	1. Pregnancy 2. Hypersensitivity 3. Renal failure	1. Dizziness 2. Orthostatic hypotension 3. Palpitation 4. Dry mouth 5. Cough (rare) 6. Skin rash
* Other drugs in this group are candesartan (4, 8, 16, 32 mg), irbesartan (75, 150, 300 mg), valsartan (80, 160 mg), telmisartan (40, 80 mg), eprosartan (400, 600 mg)					
LABETALOL	200-400 mg/day	—	1. Hypertensive emergencies 2. Syst. hypertension 3. Hypertension with pregnancy 4. Clonidine withdrawal	1. 2nd and 3rd degree heart block 2. Bronchospasm 3. Cardiogenic shock	1. Headache 2. Postural hypotension 3. Nightmares

Drugs	Dosage Oral	Parenteral	Indications	Contraindications	Adverse effects
DIURETICS :					
FRUSEMIDE	20-80 mg, 8 or 12 hourly/day (40 mg/tab)	Same as oral dosage (20 mg/2 ml)	1. Mild syst. hypertension 2. Oedematous states 3. CCF 4. Acute pulm. oedema (LVF) 5. Cerebral oedema 6. Forced diuresis 7. Hypertensive emergencies	1. Hypotension 2. Hypokalaemia 3. Hepatic precoma	1. Hyponatraemi a 2. Hypokalaemia 3. Hyperglycaemia 4. Pancreatitis 5. Noise in ears (high dose) 6. Hyperuricaemia 7. Weakness
BUMETANIDE	1 mg/day	—	Same as above but it is more potent (1 mg bumetanide = 40 mg frusemide)		
HYDROCHLOR-THIAZIDE	12.5-25 mg. 8 or 12 hourly/day	—	Same as above. Acts best in cardiac oedema		
SPIRONOLACTONE	100-400 mg/day	—	1. Cirrhosis of liver 2. Renal oedema 3. Congestive cardiac failure 4. Primary hyperaldo-steronism 5. To counteract K+ loss due to loop diuretic and thiazides	1. Hperkalaemia 2. Addison's disease	1. Gynaecomastia 2. Hyperkalaemia 3. Diarrhoea 4. Menstrual irregularities 5. Confusion
TRIAMTERENE	100-200 mg/day	—	Same as spironolactone	Same as spironolactone	1. Leg cramps 2. Nephrolithiasis 3. Hyperkalaemia 4. Diarrhoea 5. Dry mouth
AMILORIDE	5-10 mg/day	—	Same as spironolactone	Same as spironolactone	1. Dry mouth 2. Hyperkalaemia 3. Muscle cramps
ACETAZOLAMIDE	250-500 mg/day in divided dosage	—	1. As diuretic 2. Glaucoma 3. Resistant epilepsy 4. Periodic paralysis	1. Hepatic disorders 2. Hyperchloraemic acidosis	1. Hypokalaemia 2. Acidosis (metabolic) 3. Bone marrow depression 4. Drowsiness 5. Paraesthesia

Drugs	Dosage: Oral	Dosage: Parenteral	Indications	Contraindications	Adverse effects
MANNITOL (20%)		1.5-2 mg/kg, I.V very rapidly	1. Cerebral oedema 2. Poisoning (e.g., barbi-turate) 3. Acute renal failure (pre-renal shutdown) 4. Hepatic pre-coma 5. To reduce intraocular tension (when others fail) 6. Forced diuresis in haemolytic reaction after blood transfusion	1. Cerebral haemorrhage 2. Electrolyte disturbance	1. Electrolyte disturbance (hyponatraemia, hypokalaemia) 2. Rebound increase in intracranial tension 3. Pulmonary oedema
ANTI-ANGINAL DRUGS :					
NITRATES :					
a) Glycerol trinitrate	0.2-0.6 mg, sublingual 2.5-6.5 mg, oral	2% skin ointment	1. Angina pectoris 2. LVF 3. Pulmonary hypertension 4. Unstable angina 5. Cyanide poisoning	1. Glaucoma 2. Hypertrophic cardiomyopathy 3. Hypotension	1. Headache 2. Flushing 3. Dizziness 4. Syncopal attack
b) Isosorbide dinitrate	2.5-5 mg, sublingual 10-40 mg, oral	—	1. As above 2. Portal hypertension	As above	As above
c) Isosorbide mononitrate	10-20 mg, orally at 8 A.M and 3 P.M — eccentric dosage schedule	—	1. As isosorbide dinitrate 2. Pulmonary hypertension 3. Postmyocardial infarction	As above	1. As above 2. Sweating 3. Palpitation 4. Throbbing headache
d) Pentaerythritol tetranitrate	40-80 mg/day, orally	—	Same as above (principally used in IHD)	As above	As above
OXYFEDRINE	24-48 mg/day	—	1. Angina pectoris 2. Acute myoc. infarction	1. Obstructive cardiomyopathy 2. Aortic incompetence	1. Giddiness 2. Nausea 3. Constipation 4. Headache
NIFEDIPINE			Vide antihypertensive drugs		
AMLODIPINE			Vide antihypertensive drugs		

Drugs	Dosage Oral Parenteral	Indications	Contraindications	Adverse effects
ATENOLOL	50-100 mg/day, — single daily use	Vide drugs on autonomic nervous system		
PROPRANOLOL	80-240 mg/day in divided dosage	Vide drugs on autonomic nervous system		
TRIMETAZIDINE	40-60 mg /day in divided dosage	1. Angina pectoris (stable) 2. Unstable angina 3. Postmyocardial infarction	Hypersensitivity	1. Headache 2. Nausea & vomiting 3. G. I. disturbance
VERAPRAMIL	40-80 mg, 8 hourly 10 mg, I.V in PSVT	1. Angina pectoris 2. PSVT, atrial fibrillation or flutter 3. Extrasystoles 4. Hypertensive emergencies 5. Portal hypertension 6. Angina due to obst. cardiomyopathy	1. 2nd and 3rd degree heart block 2. CCF 3. Sick sinus syndrome 4. Hypotension 5. AMI	1. Headache 2. Palpitation 3. Hypotension 4. Constipation
DILTIAZEM	30-240 mg/day 20 mg, I.V in divided doses bolus in PSVT 60-120 mg, 12 hourly in sustained release form	As above	1. As above 2. WPW syndrome	1. Dry mouth 2. Headache 3. CCF 4. Bradycardia 5. Flushing
NICORANDIL (K^+ channel activator)	10-30 mg in twice — daily dose	Angina pectoris	1. Hypotension 2. LVF 3. Cardiogenic shock	1. Headache 2. Flushing 3. Tachycardia 4. Vomiting
RANOLAZINE (inhibitor of late inward Na* current)	500-1000 mg in twice daily dose	Chronic angina pectoris who continue to be symptomatic despite a standard medical treatment	1. Hepatic failure 2. Renal failure 3. Drugs producing QT-prolongation (quinidine) and with ketoconazole	QT-prolongation in ECG

* Ivabradine is another novel anti-anginal drug

**** The WHO classification of calcium-channel blockers :**

- Class I — Verapramil
- Class II — Nifedipine, nicardipine, amlodipine
- Class III — Diltiazem

Drugs	Dosage Oral Parenteral	Indications	• Contraindications	Adverse effects
ANTIARRHYTHMIC DRUGS :				
QUINIDINE	200-400 mg, I.V, 800 mg diluted 4 to 6 in 50 ml of 5% dextrose hourly and given at 1 ml/min	1. Atrial fibrillation and flutter 2. PSVT 3. Ventricular premature beats 4. VT, ventricular fibrillation 5. Hiccough (intractable) 6. Malaria	1. Heart block 2. Hypotension 3. Myasthenia gravis	1. Bradycardia 2. Hypotension 3. Vomiting, diarrhoea 4. Cinchonism 5. Convulsion 6. Thrombocyto-penia, anaemia
PROCAINAMIDE	250-500 mg, I.V : 500 mg loading dose. 4 to 6 followed by hourly 2 mg/kg/hour I.M : 100-500 mg	Same as quinidine	Same as quinidine	1. Pancytopenia (especially agranulocytosis) 2. Lupus-like syndrome (SLE) 3. Psychosis 4. QT-prolongation in ECG
DISOPYRAMIDE	100-300 mg 6-8 hourly —	Same as quinidine	Same as quinidine	1. Blurred vision 2. Constipation 3. Retention of urine 4. Feeling faint 5. Myoc. depression 6. Dry mouth
LIGNOCAINE (LIDOCAINE)	— 1 mg /kg as bolus dose followed by 0.5 mg/kg bolus at 8-10 min interval to 3 mg/kg, I.V in 5% dextrose	1. Ventricular premature beats. 2. VT, ventricular fibrillation (specially in the setting of AMI) 3. Nerve block, anaes-	1. Heart block 2. Cardiac decompensation	1. Confusion 2. Convulsion 3. Respiratory arrest 4. Drowsiness 5. Hypotension

Drugs	Dosage Oral	Parenteral	Indications	Contraindications	Adverse effects
MEXILETINE	400 mg initially ; then 200-250 mg, 6-8 hourly	250 mg, I.V slowly	Same as 1 and 2 of lignocaine	1. Heart block 2. Cardiogenic shock	1. Nausea, vomiting, bad taste 2. Drowsiness, confusion, blurred vision 3. Hypotension, bradycardia
PHENYTOIN SODIUM	100-200 mg, 6 hourly	100 mg, slow I.V, in every 5 minutes	1. SVT and VT 2. Ventricular extrasystoles 3. Digitalis-induced arrhythmias	1. Sinus bradycardia 2. SA block 3. Stokes-Adams syndrome	1. Gum hypertrophy 2. Megaloblastic anaemia 3. Cerebellar ataxia 4. Hirsutism 5. Hypotension 6. Confusion
PROPRANOLOL	10-200 mg, 6 hourly	I.V : 0.5 - lmg/ min to 0.15-0.2 mg/kg	Vide autonomic-nervous system		
VERAPRAMIL	40-80 mg,- 8 hourly	—	Vide anti-anginal drugs		
AMIODARONE	200-600 mg, 6 hourly	I.V given for VT -15 mg/min as infusion for 10 min followed by 1 mg/min for 6 hrs for next few days	1. Vent, arrhythmias refractory to other treatment 2. VT 3. Tachyarrhythmia due to WPW syndrome 4. Atrial fibrillation and	1. Heart block 2. Cardiogenic shock	1. Hepatitis 2. Pulmonary fibrosis 3. Microdeposits in cornea 4. Bluish skin 5. Bradycardia

Drugs Oral	Dosage Parenteral	Indications	Contraindications	Adverse effects
DIGOXIN 0.25-1.5 mg over 24 hrs	0.5-1 mg	1. CCF 2. Atrial fibrillation and flutter 3. PSVT 4. Sometimes in LVF 5. As an inotropic drug	1. AMI 2. Partial heart block 3. Myocarditis 4. Ventricular tachycardia , 5. High output failure	1. All types of cardiac arrhythmia except Mobitz type II block and parasystole 2. Especially, ventricular bigeminy 3. Anorexia, nausea, vomiting 4. Yellow vision 5. Gynaecomastia
ADENOSINE — .	I.V : 6 mg bolus; if no response, give 12 mg bolus	Supraventricular tachyarrhythmias	1. Hypotension 2. Br. asthma 3. 2°/3°AV block 4. Atrial fibrillation	1. Transient atrial standstill 2. Hypotension 3. Flushing 4. Chest pain
ANALGESICS, ANTIPYRETICS AND ANTI-INFLAMMATORY DRUGS :				
ACETYL SALICYLIC ACID (aspirin) 300-500 mg, 8 hourly ; upto 4-8 g/day	—	1. Analgesic 2. Antipyretic 3. Anti-inflammatory 4. IHD (75-300 mg/day) 5. TIA (75-300 mg/day) 6. Rheumatic fever	1. G. I. bleeding 2. Gout 3. Bronchial asthma 4. Bleeding tendency	1. Nausea, vomiting, G. I. bleeding 2. Salicylism (vertigo, tinnitus) 3. Wheeze and breathlessness 4. Reye's syndrome 5. Bleeding tendency
PARACETAMOL 500-lg/day ; upto 4g/day	—	Analgesic and antipyretic actions	Hepatic pre-coma	1. Skin rash 2. Nausea and vomiting 3. Large doses (1 Og) produce hepatic failure 4. Leucopenia (rare)

Drugs	Dosage Oral	Parenteral	Indications	Contraindications	Adverse effects
NIMESULIDE (not recommended in children)	100 mg, 12 hourly	–	1. 1, 2 and 3 of aspirin 2. Any painful condition in the body	1. Active peptic ulcer 2. Severe hepatic impairment	1. Heartburn and epigastric distress 2. Nausea and vomiting 3. Dizziness 4. Pruritus
INDOMETHACIN	50-200 mg/day in divided doses	—	1. Acute gout 2. Rheumatoid arthritis 3. Osteoarthritis 4. Ankylosing spondylitis 5. Dysmenorrhoea 6. Bartter's syndrome 7. PDA in neonates	1. Active peptic ulcer 2. Bronchial asthma	1. Pain abdomen 2. Haematemesis, melaena 3. Breathlessness 4. Giddiness, blurred vision 5. Skin rash
PENTAZOCINE	25-100 mg	60-120 mg, I.M or I.V	Chronic/recurrent pain associated with : 1. Surgery, colic, burn. trauma 2. Pre-anaesthesia 3. Intense headache 4. Often used in the place of morphine in acut LVF or AMI	1. Respiratory depression 2. Head injury 3. Raised intracranial tension *	1. Respiratory depression 2. Hallucination ad nightmares 3. Dizziness, confusion and drowsiness 4. Nausea & vomiting
MORPHINE	10-15 mg	10-15 mg, I.M or S.C	1. Analgesic, hypnotic and sedative 2. Antitussive 3. Acute LVF 4. Pre-anaesthesia 5. Relief of prolonged and intractable pain	1. Acute hepatic disorder 2. Respiratory depression 3. Paralytic ileus 4. COPD or bronchial asthma	1. Respiratory depression 2. Bronchocon-striction 3. Constipation 4. Drug dependence and tolerance 5. Retention of urine

Drugs	Dosage Oral	Parenteral	Indications	Contraindications	Adverse effects
PETHIDINE	—	50-100 mg I.M or I.V	Same as morphine	Same as morphine	Same as morphine
ANTIHISTAMINICS AND ANTI-5HT DRUGS :					
(A) Antihistaminics :					
1. Chlorpheniramine maleate	5-20 mg	5-20 mg, I.M	1. Allergic disorders : Pruritus,.urticaria, rhinorrhoea. hay fever, angio-oedema, drug rash, common cold 2. Motion sickness (diphenhydramine) 3. As hypnotic 4. Pre-anaesthesia	1. Hypersensitivity 2. Skillful work like drivers, machine operators, pilot	1. Sedation, fatigue 2. Dry mouth, blurred vision 3. Excitation (children) 4. Urinary difficulty
2. Promethazine	10-25 mg	25-50 mg, I.M			
3. Diphenhydramine	25-75 mg	10 mg, I.M			
4. Pheniramine maleate	25-75 mg	—			
		—			
5. Dimethindene maleate	1-2 mg, 8 hourly	—			
6. Hydroxyzine	10-25 mg, 8 hourly	—			
7. Azatadine	1 mg, 12 hourly	—			
8. Clemastine	1 mg, 8 or 12 hourly	—			
9. Mizolastine	10 mg	—			
10. Ketotifen	1-2 mg, 12 hourly	—			
(B) ANTIHISTAMINICS (non-sedative effect)					
1. Astemizole	10 mg	—			
2. Terfenadine	60 mg, 12 hourly	—	Same as above	—	As above (less or no sedation)
3. Loratidine	10 mg	—			
4. Cetrizine	5-10 mg	—			
5. Fexofenadine	120 mg	—			
6. Desloratadine	5 mg	—			
7. Levocetrizine	5 mg	—			
(C) ANTI-5HT :					
1. Cyproheptadine	4-20 mg	—	1. As above 2. For stimulation of appetite 3. Prophylaxis of migraine 4. Diarrhoea in carcinoid syndrome	As above	As above
2. Methysergide	6-8 mg	—	As cyproheptadine	As cyproheptadine	As cyproheptadine

Drugs Oral (Dosage)	Parenteral	Indications	Contraindications	Adverse effects
SEDATIVES AND ANTIPSYCHOTIC DRUGS :				
PHENOTHIAZINES 100-800 mg	25 mg/ml, I.M	1. Schizophrenia 2. Anxiety, mania 3. Hyperexcitability 4. Aggressive disorder 5. Hiccough 6. Peri-operative 7. Nausea 8. Hyperpyrexia 9. Tetanus	1. Coma 2. Along with other CNS depressants 3. Bone marrow depression	1. Drowsiness 2. Obstructive jaundice 3. Leucopenia and thrombocytopenia 4. Tardive dyskinesia 5. Skin pigmentation 6. Hypotension
HALOPERIDOL 0.25-20 mg, 8 hourly	2-10 mg, I.M or I.V	1. Schizophrenia 2. Manic disorders 3. Organic psychosis 4. Highly agitated patients	Same as above but with less sedative effect	
DIAZEPAM 5-10 mg, 8 hourly	10-20 mg, I.V	1. Tranquilliser 2. Pre-anaesthesia 3. Muscle relaxant 4. Sleep disorder, anxiety. delirium tremens 5. Convulsive disorders 6. Tetanus 7. Ecclampsia 8. Status epilepticus	1. Respiratory depression 2. Acute narrow angle glaucoma 3. Myasthenia gravis	1. Drowsiness 2. Respiratory depression 3. Ataxia 4. Blurred vision 5. Slurred speech 6. Confusion 7. Change in libido 8. Addiction
ZOPICLONE 3.75-7.5 mg at bed time	—	1. Transient, situational or chronic insomnia 2. Physical and mental	1. Myasthenia gravis 2. Severe sleep apnoea syndrome	1. Metallic after-taste 2. Impaired judgement

Drugs	Dosage Oral	Dosage Parenteral	Indications	Contraindications	Adverse effects
IMIPRAMINE	50-150 mg	—	1. Depression 2. Nocturnal enuresis 3. Narcolepsy 4. Diabetic neuropathy 5. Migraine 6. Bulimia 7. Irritable bowel syndrome	1. Manic phase of MDP 2. Acute myocardial infarction 3. Benign hypertrophy of prostate	1. Drowsiness 2. Dry mouth and other anti-cholinergic effects 3. Palpitation 4. Weight gain 5. Constipation
AMITRIPTYLINE	75-150 mg		same as imipramine	same as imipramine	same as imipramine
FLUOXETINE (SSRI)	20 mg		1. Drepression (where sedation is not wanted) 2. Obsessive compulsive disorders	1. Mania 2. Severe renal impairment	1. Insomnia 2. Fatigue 3. Sexual dysfunction
SERTRALINE	25-100 mg		1. Drepression with anxiety 2. Panic disorders 3. Obsessive compulsive disorder	1. Hepatic insufficiency 2. Concurrent administra-tion of MAOI	1. Dry mouth 2. Tremor 3. Dizziness 4. Rash 5. Insomnia
LITHIUM	900-1500 mg (therapeutic blood level : 0.6-1.2 meq/I)		1. Acute hypomania, mania 2. Recurrent depression 3. SIADH 4. Cluster headache 5. Prophylaxis of MDP 6. Idiopathic thrombocy-topenic purpura	1. Electrolyte disturbance 2. Dehydration 3. Severe renal impairment	1. Confusion and incoordination 2. Blurred vision 3. Nausea and diarrhoea 4. Ataxia, slurred speech b. Goitre 6. Diabetes insipidus
OLANZAPINE	5-20 mg		1. Schizophrenia and related psychosis 2. Acute mania in bipolar disorder	1. Narrow-angle glaucoma 2. Lactation	1. Somnolence 2. Weight gain 3. Akathisia 4. Tardive dyskinesia
ESCITALOPRAM (SSRI)	10-20 mg once daily		1. Depression 2. Panic disorder with or without agoraphobia 3. Obsessive compulsive disorder	1. Pregnancy & lactation 2. <18 yrs of age 3. Serotonin syndrome 4. Within 14 days of use of MAOI	1. Suicidal tendency 2. Worsening of depression 3. Acute psychosis 4. Sexual dysfunction

Drugs	Dosage: Oral	Dosage: Parenteral	Indications	Contraindications	Adverse effects
THIORIDAZINE	150-600 mg		1. Schizophrenia 2. Mania 3. Behavioural disturbances	1. Extrapyramidal reactions 2. Severe hepatic or renal dysfunction	1. Drowsiness, dry mouth 2. Retinal damage 3. Unsteadiness 4. Sexual dysfunction
ALPRAZOLAM	0.25-0.5 mg, 8 or 12 hourly	—	1. Anxiety disorders 2. Panic and phobic disorders	1. Acute narrow angle glaucoma 2. Myasthenia gravis	1. Drowsiness 2. Lack of coordination 3. Impairment of memory
BARBITURATES			See antiepileptic drugs		
ANTIEPILEPTIC DRUGS :					
PHENOBARBITONE	60-180 mg in divided doses	60-400 mg, I.V	1. Epilepsy (tonic-clonic and focal) 2. Ecclampsia 3. Mania 4. As sedative and hypnotic 5. In jaundice to increase conjugation of bilirubin 6. Pre-anaesthesia	1. Sinus bradycardia 2. AV block 3. Acute porphyria	1. Drowsiness 2. Confusion 3. Fixed drug eruption 4. Addiction 5. Megaloblastic anaemia
PHENYTOIN SODIUM	300-400 mg, usually in divided doses	13-18 mg/kg, I.V (in N. saline)	1. Epilepsy (tonic-clonic. focal, complex partial) 2. Trigeminal neuralgia 3. Cardiac arrhythmia 4. Diabetic neuropathy 5. Chorea	1. SA block, Stokes-Adams syndrome 2. Acute porphyria	1. Gum hyperplasia 2. Lymphadenopathy 3. Megaloblastic anaemia 4. Hirsutism 5. Osteomalacia 6. CNS depression 7. Ataxia, incoordi-nation,. confusion

Drugs	Dosage Oral Parenteral	Indications	Contraindications	Adverse effects
CARBAMAZEPINE	100-200 mg, — 8 hourly	1. Epilepsy (tonic-clonic, focal, complex partial) 2. Trigeminal neuralgia 3. Diabetic neuropathy 4. Post-herpetic neuralgia 5. Lightening pain of tabes 6. Movement disorders 7. Diabetes insipidus	1. Bone marrow depression 2. Jaundice	1. Bone marrow Depression 2. Stevens-Johnson syndrome 3. Vertigo 4. Ataxia, diplopia, dizziness 5. Hepatotoxicity
SODIUM VALPROATE	750-1250 mg/day —	1. Epilepsy (absence. atypical absence attack, psychomotor and myoclonic epilepsy) 2. To prevent febrile convulsion in children	1. Hepatic disorder 2. Thrombocytopenia	1. Sedation 2. Fulminant hepatitis 3. Alopecia 4. Bone marrow depression
GABAPENTIN	300 mg on 1st day, — 600 mg on 2nd day 900 mg on 3rd day and continued as 900 mg/day	1. Adjunctive therapy of partial seizures. not controlled by other drugs 2. Neuropathic pain	Hypersensitivity	1. Somnolence 2. Ataxia 3. Tremor 4. Nystagmus 5. Headache
CLONAZEPAM	1-12 mg/day —	Epilepsy e.g., infantile spasm, myoclonic, atonic, absence seizures; panic attacks	1. Respiratory depression 2. Hypersensitivity	1. Drowsiness 2. Unsteadiness 3. Forgetfulness 4. Confusion 5. Lethargy
DIAZEPAM	5-40 mg 10 mg, I.V bolus	Vide sedatives and antipsychotic drugs		
PREGABALIN	75-600 mg daily — (usually 75-150 mg) in divided doses	1. Adjunctive therapy in partial seizures 2. Neuropathic pain (e.g., carpal tunnel syndrome, root pain) 3. Fibromyalgia	1. Lactation 2. Skillful works, e.g., pilot	1. Somnolence, euphoria, confusion, decreased libido, fatigue

Drugs	Dosage Oral Parenteral	Indications	Contraindications	Adverse effects
ANTI PARKINSONIAN DRUGS :				
LEVODOPA	2-8 g/day —	Parkinsonism	1. Closed angle glaucoma 2. Melanoma 3. Hypertension 4. Severe psychosis	1. Nausea and vomiting 2. Dyskinesia 3. Postural hypotension 4. 'On-off phenomenon' 5. Hallucinations 6. Palpitation
SELEGILINE	10 mg/day in — divided doses	Parkinsonism	1. Epilepsy 2. Tardive dyskinesia	1. Confusion 2. Involuntary movements 3. Palpitation 4. Psychosis 5. Sexual dysfunction
AMANTADINE	100 mg daily — or 12 hourly	1. Parkinsonism (except drug-induced) 2. Post-encephalitic sequelae 3. Prophylaxis of influenza A	1. Epilepsy 2. Renal disorder	1. Mental confusion 2. Ankle oedema 3. Oculogyric episode 4. Suicidal tendency 5. Livedo reticularis
BENZHEXOL	2 mg, 8 or 12 hourly —	Parkinsonism (even in the presence of IHD or hypertension)	1. Glaucoma 2. Enlarged prostate 3. Paralytic ileus	See the adverse reaction of atropine
BROMOCRIPTINE	2.5 mg, 8 hourly — (upto 50-100 mg/day)	1. Parkinsonism 2. Galactorrhoea 3. Inhibition of lactation 4. Acromegaly 5. Premenstrual syndrome 6. Prolactinoma	1. Uncontrolled hypertension 2. Ecclampsia	1. Headache 2. Constipation 3. Abnormal movements 4. Nausea and vomiting 5. Digital vasospasm 6. Alcohol intolerance 7. Postural hypotension

Drugs	*Dosage* *Oral Parenteral*	*Indications*	*Contraindications*	*Adverse effects*
ANTITUBERCULOUS DRUGS :				
INH	Adult : 300 mg (5 mg/kg) — Children : 10 mg/kg	Tuberculosis	1. Hypersensitivity 2. Severe jaundice 3. Convulsion	1. Drug fever 2. Peripheral neuropathy 3. Hepatitis 4. Convulsion 5. Psychosis
RIFAMPICIN	Adult (< 50 kg) : 450 mg — Adult (> 50 kg) : 600 mg Children : 10-20 mg /kg	1. Tuberculosis 2. Leprosy 3. Prophylaxis of meningitis against H. influenzae, Legionellla, N. meningitidis 4. Meningococcal carrier	1. Severe hepatic disorder 2. Severe vomiting	1. Flu-like syndrome 2. Hepatitis 3. Vasculitis 4. Nausea,, vomiting 5 Purpura (rare) 6. Orange-red coloured urine
ETHAMBUTOL	25 mg/kg for 2 months, — 15 mg/kg thereafter	Tuberculosis	1. Hypersensitivity 2. Optic neuritis	1. Optic neuritis 2. Nausea and vomiting 3. Hypersensitivity reaction
PYRAZINAMIDE	Adult : 35 mg/kg — (max - 2.5 g) Children : 40 mg/kg (max - 2 g)	Tuberculosis	1. Hepatitis 2. Gout	1. Hepatitis 2. Hyperuricaemia 3. Fever 4. Skin rash 5. Arthralgia
STREPTOMYCIN	— Adult : 0.75-lg, I.M Children : 20 mg /kg, I.M	1. Tuberculosis 2. Plague, brucellosis, tularaemia 3. UTI, RTI 4. Chancroid and granuloma inguinale 5. SBE, meningitis	1. Diseases in the ear e.g., CSOM 2. Hypersensitivity	1. Giddiness 2. Deafness 3. Loss of renal function 4. Exfoliative dermatitis

* INH, rifampicin, ethambutol, pyrazinamide and streptomycin are first line drugs. Rest are included in the second line

Drugs	Dosage: Oral	Dosage: Parenteral	Indications	Contraindications	Adverse effects
CYCLOSERINE	Adult ; 1 g/day Children : 10 mg/kg/day	—	Tuberculosis	1. Epilepsy 2. Psychosis 3. Depression	1. Depression 2. Convulsion 3. Psychosis 4. Megaloblastic anaemia 5. Tremor
PARA-AMINO SALICYLIC ACID (PAS)	10-15 g/day Children-300 mg/kg	—	Tuberculosis (specially multi-drug resistant)	1. Hypersensitivity 2. Goitre	1. Nausea, vomiting diarrhoea 2. Hypothyroidism, goitre 3. Leucopenia, eosinophilia 4. Acute renal failure
CIPROFLOXACIN	250-750 mg, 12 hourly	100-200 mg, I.V, 12 hourly	1. UTI, prostatitis. ear infection 2. Enteric fever, septicae-mia, gonorrhoea 3. 2nd line of anti-tuber-culosis drug 4. Skin and soft tissue infection, pyogenic liver abscess, intra-abdominal infection 5. Diarrhoea	1. Convulsion 2. Patient receiving theophylline (relative contra-indication)	1. Arthralgia 2. Convulsion 3. Stevens- Johnson syndrome 4. Tremor 5. Insomnia
ETHIONAMIDE/ PROTHIONAMIDE	0.75 - 1 g/day	—	2nd line of drug against tuberculosis	1. Hypersensitivity 2. Gout	1. Nausea 2. Jaundice 3. Metallic taste in mouth 4. Neuropathy 5. Gout

Drugs	Dosage Oral Parenteral	Indications	Contraindications	Adverse effects
ANTILEPROSY DRUGS :				
DAPSONE	2 mg/kg (not — exceeding 100 mg/day)	1. Leprosy 2. Dermatitis herpeteformis 3. Vasculitis	Hypersensitivity to sulpha drugs	1. Rash, drug fever 2. Exfoliative dermatitis 3. Agranulocytosis, haemolytic anaemia 4. Psychosis 5. Hepatitis 6. Hypoproteinaemia
RIFAMPICIN	600 mg, once or — twice monthly	See antituberculous drugs		
CLOFAZIMINE	50 mg/day —	1. Leprosy 2. Chronic skin ulcer (Buruli ulcer) 3. Erythema nodosum leprosum	Hypersensitivity	1. Brown disco-louration of skin 2. Abdominal pain 3. Pruritus 4. Anorexia, nausea, vomiting 5. Phototoxicity
THIACETAZONE	150 mg/day —	1. Tuberculosis 2. Leprosy	1. Hypersensitivity 2. Immunodeficiency (e.g., AIDS)	1. Skin rash, Stevens-Johnson syndrome 2. Nausea, vomiting 3. Bone marrow depression
PROTHIONAMIDE		See antituberculous drugs		
OFLOXACIN	200-400 mg/day —	1. Similar to ciprofloxacin (Ref: antituberculous drugs) 2. Leprosy	1. Hypersensitivity 2. Convulsion	1. Similar to ciprofloxacin 2. Pseudomembranous colitis

Drugs	Dosage: Oral	Dosage: Parenteral	Indications	Contraindications	Adverse effects
DRUGS FOR KALA AZAR :					
SODIUM ANTIMONY GLUCONATE	—	20 mg/kg, I.V or deep I.M daily for 28 days ; 1 ml of inj. contains 100 mg of drug	Kala-azar	1. G_6PD deficiency 2. Hepatic and renal impairment	1. Nausea, vomiting diarrhoea 2. Anaphylaxis 3. Hepatitis 4. 'Nitritoid crisis' 5. Renal failure 6. Arthralgia
MEGLUMINE ANTIMONIATE	—	50 mg/kg/day, for 15 days		Same as above	
PENTAMIDINE ISETHIONATE	—	2-4 mg/kg, thrice weekly for 10-12 days	1. Kala-azar 2. Blastomycosis	1. Hypersensitivity 2. Hypoglycaemia	1. Hypoglycaemia 2. Hypotension 3. Peripheral neuropathy 4. Fever, rigor
AMPHOTERICIN-B	—	0.5-1 mg/kg, I.V on alternate days (total 1-3 g)	1. Systemic mycoses 2. Fatal fungal infection and intestinal moniliasis 3. Resistant kala-azar	Hypersensitivity	1. Pain at inj. site 2. Renal impairment 3. Cardiovascular toxicity (arrhythmia) 4. Convulsion, deafness, diplopia
MILITEFOSINE	2.5 mg/kg/day in dividied doses for 28 days	—	Resistant kala-azar	1. Pregnancy 2. Lactation	1. Mild and transient G.I. disturbances 2. Motion sickness 3. Reversible elevations of creatinine, AST and ALT
ALLOPURINOL	20-30 mg/kg/day	—	1. Chronic gout, urate nephropathy, recurrent urate stone formation 2. In anti-cancer therapy 3. In resistant kala-azar with sodium antimony gluconate 4. American trypanosomiasis	1. Hypersensitivity 2. Recent acute attack of gout	1. Fever, chill 2. Headache 3. Vasculitis 4. Rash

*

Drugs	Dosage Oral Parenteral	Indications	Contraindications	Adverse effects
ANTIMALARIAL DRUGS :				
QUININE	Q. sulphate Q. dihydrochloride 300-600 mg. 8 hourly (300 mg/ml) for 7 days 10 mg/kg, I.V, 8 hourly	1. Chloroquine resistant malaria (p.v. or p.f.) 2. Cerebral malaria 3. Nocturnal muscle cramp 4. Quinidine-like effect on heart	1. Hypoglycaemia 2. G_6PD deficiency 3. Pregnancy (relative contraindication)	1. Cinchonism, tinnitus, vertigo, deafness 2. Nausea, vomiting 3. Haemoglobinuria and ARF 4. Idiosyncrasy (pruritus) 5. Photosensitivity 6. Hypoglycaemia 7. Arrhythmias 8. Psychosis
CHLOROQUINE	10 mg base/kg 5 mg/kg followed by 5 mg base/kg at 6, 24 and 48 hours (in malaria)	1. Treatment and prophylaxis of malaria 2. DLE	1. Psoriasis 2. Porphyria 3. G_6 PD deficiency 3. Hepatic amoebiasis 4. Rheumatoid arthritis 5. Photoallergic reaction	1. Nausea, vomiting 2. Blurred vision 3. Retinopathy 4. Ototoxicity 5. Psychosis and convulsion
PRIMAQUINE	15 mg daily for 14 days —	1. Radical cure of p.v. or p.o. 2. Gametocidal for p.f.	1. SLE 2. G_6PD deficiency 3. Pregnancy	1. Abdominal discomfort 2. Methaemoglobinaemia 3. Anaemia and leucopenia
PROGUANIL	200 mg/day, continued — for 6 weeks	1. Prophylaxis of p.f. malaria 2. Suppression of transmission of malaria	1. G_bPD deficiency 2. SLE	1. Gastric intolerance 2. Mouth ulcer 3. Reversible alopecia 4. Renal impairment 5. Skin reaction

Drugs	Dosage: Oral	Dosage: Parenteral	Indications	Contraindications	Adverse effects
MEFLOQUINE	15/kg, in 1-2 doses, 6-8 hourly	—	1. Chloroquine sensitive/ resistant malaria due to p.v. or p.f. 2. Prophylaxis against p.v or p.f.— 250 mg (1 tab) weekly	1. Convulsion 2. Psychosis 3. Hypersensitivity to quinine 4. Pregnancy	1. Neuropsychiatric dysfunction 2. Vomiting, diarrhoea 3. Rash, itching 4. Convulsion
AMODIAQUINE	10 mg/kg on 1st day, 5 mg/kg/day for next two days	—*	Treatment and prophylaxis of malaria	1. G6PD deficiency 2. Hypersensitivity	1. Nausea and vomiting 2. Agranulocytosis 3. Skin rash 4. Headache
ARTEMETHER	—	Loading dose of 3.2 mg/kg, I.M, then 1.6 mg/kg, I.M daily to a total of 640 mg	1. Multidrug resistant p.v. / p.f. malaria 2. Malaria with end-organ damage	1. Hypersensitivity 2. Prolonged QT on the ECG	1. Bradycardia, 1° AV block 2. Leucopenia 3. Nausea, vomiting, abdominal cramps 4. Neurotoxicity
ARTEETHER	—	150 mg, I.M once a days for 3 days	Same as artemether	Same as artemether	Same as artemether
ARTESUNATE	Day 1: 100 mg BD Day 2-5 : 50 mg BD Total : 600 mg	2.4 mg/kg, I.V stat followed by 2.4 mg/kg at 12 and 24 h, and then daily if necessary	Same as artemether	Hypersensitivity	1. Bradycardia, 1° AV block 2. Transient elevation of transaminases
HALOFANTRINE	500 mg at 6 hours interval for 3 doses in a day; with fatty meal	—	Same as artemether	1. Cardiac arrhythmias 2. Hypersensitivity 3. Pregnancy	1. Diarrhoea 2. Abdominal pain 3. QT prolongation in ECG 4. Arrhythmias

* Artemether-lumefan trine combination (1.5 mg/9 mg/kg BD for 3 days with food) is effective in multidrug-resistant falciparum malaria.

Drugs	Dosage Oral	Parenteral	Indications	Contraindications	Adverse effects
PYRIMETHAMINE	25 mg per dose (for malaria)	—	I. Treatment and prophylaxis of malaria (along with sulphadoxine 500 mg) 2. Toxoplasmosis 3. Actinomycetomas 4. Prophylaxis of p. carinii pneumonia	1. Megaloblastic anaemia 2. Hypersensitivity	1. Agranulocytosis 2. Megaloblastic anaemia 3. Sore throat 4. Loss of appetite
LIPID LOWERING AGENTS :					
LOVASTATIN	10-80 mg/day at bed time	—	1. Primary hypercholes-terolaemia 2. Combined hypercholes-terolaemia and hyper-triglyceridaemia	1. Active liver disease 2. Hypersensitivity ■	1. Nausea 2. Myopathy 3. Headache 4. Sleep disorder 5. Fatigue 6. Memory loss 7. Progression to cataract
SIMVASTATIN	10-40 mg/day at bed time	—	Hypercholesterolaemia	Same as lovastatin	Same as lovastatin
ATORVASTATIN	10-80 mg/day at bed time	—	1. Hypercholesterolaemia 2 Mixed hyperlipidaemia	Same as lovastatin	Same as lovastatin
ROSUVASTATIN (super-statin)	10-20 mg/day at bed time	—	1. Hypercholesterolaemia 2 Mixed dyslipidaemia	1. Severe renal disease 2. Same as lovastatin	Same as lovastatin
FENOFIBRATE	200 mg once daily with food	—	1. Hyperlipidaemia (e.g., hypertriglyceridaemia) 2 Dislipidaemia in diabetes	1. Renal or hepatic disease 2. Gall bladder disease 3. Pancreatitis	1. Elevated liver enzymes 2. Muscle toxicity 3. Gall stones 4. Photosensitivity

Drugs	*Dosage* *Oral Parenteral*	*Indications*	*Contraindications*	*Adverse effects*
EZETIMIBE	10 mg/day —	1. Adjunct to diet in hypercholesterolaemia 2 With a statin or as monotherapy	Hepatic impairment	1. Myalgia 2. t in serum transaminases 3. Nausea 4. Angio-oedema
GEMFIBROZIL	600 mg BD, 30 — min before meal	1. Hypertriglyceridaemia 2. T VLDL	Sever hepatic or renal dysfunction	1. G.I. upset 2. Myopathy 3. Gall stone formation 4. Blurred vision 5. Headache
NICOTINIC ACID	500 mg at betime, — gradually increasing to 1-2 g at bedtime	1. Hypercholesterolaemia (T LDL) 2. T VLDL 3. i HDL	Hyperuricaemia	1. Gout 2 Flushing 3. G.I. upset 4. LFT abnormalities
CHOLESTYRAMINE	4-24 g/d in — divided doses	T LDL	1. Hypertriglyceridaemia 2. Autonomic neuropathy 3. Constipation	1. G.I. upset 2. t VLDL

* Hypersensitivity may develop in any drug; thus, hypersensitivity is the common contraindication of all

—— O ——

CHAPTER VII : CHARTS (DATA ANALYSIS)

CHARTS ON HAEMATOLOGY

PREFACE:

RBC :

(A) Total count (TC)—

a) Male : 4.5-6.3 millions/mm^3

b) Female : 4.2-5.4 millions/mm^3

(B) Haemoglobin (Hb)—

a) Male : 14.6-15.5 g/dl

b) Female : 13.3-14.6 g/dl

(C) Reticulocyte count— 0.2-2% of RBC. Increased reticulocyte count indicates bone marrow stimulation with new red cells production, e.g., haemolytic anaemia or acute blood loss.

$$\text{Reticulocyte index} = \text{Reticulocyte \%} \times \frac{\text{Patient's PCV}}{\text{Normal PCV}}$$

(D) Haematocrit or packed cell volume (PCV)—

a) Male : 42-52%

b) Female : 37-47%

(E) Haemoglobin content of RBC is assessed by—

Mean corpuscular haemoglobin (MCH) - 29.5 ± 2.5 pg

Mean corpuscular haemoglobin concentration (MCHC) - 35 ± 3 g/dl

The term 'colour index' is obsolete now-a-days rather the 'chromicity' of RBC is assessed by MCH and MCHC.

(F) Size of RBC—

Anisocytosis — Change in size

Mean diameter — 7.2 micron, and the normal shape is biconcave

Mean corpuscular volume (MCV) — 87 ± 7 cubic micron

Macrocyte >100 cubic micron

Microcyte < 70 cubic micron

* Anaemia with normal MCV suggests acute blood loss or anaemia of chronic disease (e.g., any chronic disease like tuberculosis, chronic inflammation or malignancy).

Anaemia with low MCV suggests iron deficiency anaemia or thalassaemia.

Anaemia with high MCV suggests vitamin B_{12} or folate deficiency.

(G) Shape of RBC —

Variations in shape is known as *poikilocytosis.* Target cell, spur cell, helmet cells are examples of change in shape of RBC. Distortion of size and shape indicates dyshaemopoiesis.

(H) Life span - 120 days.

(I) Anaemia - It is qualitative or quantitative diminution of RBC and/or haemoglobin concentration in relation to standard age and sex, and clinically manifested by pallor. Anaemia is divided into mild (9-12 g/dl), moderate (6-9 g/dl), and severe (< 6 g/dl) types clinically.

WBC :

(A) Total count (TC) - 4.3-10.8 x 10^9/L or 4300-10800/mm^3

Leucopenia < 4000/mm^3

Leucocytosis > 11000 / mm^3

(B) Differential count (DC) -

Neutrophils	45-74%
Lymphocytes	16-45%
Monocytes	4-10%
Eosinophils	0-7%
Basophils	0-1%

(C) Half life-

Neutrophils	8 hours
T lymphocytes	100 days
B lymphocytes	10 days

Platelets :

(A) Total count - 1.5-4 lacs/mm^3

Critical Count < 10000/mm^3 (recent view)

Thrombocytopenia < 1 lac/mm^3

Thrombocytosis > 4 lacs/mm^3

(B) Half Life - 3 days (life span 10 days)

Coagulation profile :

Bleeding time (BT) : 2.5-10 minutes (Ivy)

Clotting time (CT) : 9-15 minutes (glass tubes)

Prothrombin time (PT) : 12-16 seconds

Activated partial thromboplastin time (aPTT) : 32-46 seconds

* Anticoagulants used while collecting blood sample for different examinations are :

a) Oxalate (mixture of ammonium oxalate and potassium oxalate in a ratio of 3:2)
b) Citrate (trisodium citrate solution)—Useful for ESR estimation and coagulation study
c) EDTA (ethylenediamine tetra-acetic acid)—For cellular morphology and platelet count
d) Heparin (used for osmotic fragility test and electrolyte estimation)
e) ACD (acid citrate dextrose) solution (used in blood banking)

** Haemoglobin is estimated by,

a) Sahli or acid-haematin method
b) Cyanmethaemoglobin method
c) Alkali-haematin method, or
d) Oxyhaemoglobin method

ESR is estimated by,

a) Wintrobe's, or
b) Westergren's method

RBC and platelet are counted by,

a) Visual method, or
b) Electronic cell counters

WBC count is done in Neubauer's chamber

*** Extrinsic coagulation pathway is assessed by PT and intrinsic coagulation pathway by aPTT. Heparin therapy is monitored by aPTT and that of warfarin by PT.

**** For haematological investigations, venous blood is collected usually from the antecubital vein. Blood smear is then prepared on a clean slide with the help of another slide. To prevent haemolysis of RBC, the air-dried blood smear may be 'fixed' by covering the film with acetone-free methyl alcohol for 1 minute. The slide is now stained with Romanowsky dyes (e.g., Leishman's, Giemsa's stain) and lastly examined under the microscope. Thick smear is required for detection of malaria parasites and microfilaria.

IRON DEFICIENCY ANAEMIA

Hb	5.4 g/dl
RBC	4.4 millions/mm^3
WBC	8700/mm^3
Polymorphs	62%
Lymphocytes	35%
Monocytes	**2%**
Eosinophils	1%
Basophils	0%
Reticulocytes	1%
Anisocytosis	++
Poikilocytosis	++
Platelets	3 lacs/mm^3
MCH	22 pg
MCHC	24 g/dl
MCV	68 cubic micron

Interpretation :

1. Anaemia - Severe (Hb 5.4 g/dl, i.e., approximately 35%); RBC count is reduced to 90% approximately (slight reduction). So the cells are likely to be hypochromic.
2. MCH is low, MCHC is diminished; MCV is less too.
3. Anisocytosis and poikilocytosis indicate marrow stimulation e.g., haemolytic anaemia, deficiency disorder or infiltration of marrow by malignant cells.
4. WBC series, platelet and retie count show no abnormality.

Inference :

It is a case of microcytic hypochromic anaemia probably iron deficiency anaemia (IDA).

POSSIBLE CAUSES WITH RATIONAL APPROACH :

1. Iron deficiency anaemia (all features present).
2. Thalassaemia (reticulocyte count will be high).
3. Sideroblastic anaemia (dimorphic picture with sideroblasts seen).
4. Lead poisoning (basophilic stippling noted).
5. Anaemia due to chronic infection (WBC series show changes in TC and DC).

* Common causes of IDA are nutritional deficiency, chronic blood loss and increased demand due to pregnancy, lactation. Acute blood loss usually produces normocytic normochromic anaemia or macrocytic anaemia.

** Causes No. 1-4 produce microcytic hypochromic anaemia.

WHAT IS MENTZER INDEX ?

Mentzer index (MCV/RBC) is :

a) > 13 = Iron dificiency anaemia.
b) < 13 = p-thalassaemia trait.

CAUSES OF CHRONIC BLOOD LOSS :

1. Pediatric age group - Hookworm infestation, polyp.
2. Adult :
   a) Males - Haemorrhoids, peptic ulcer, oesophageal varices.
   b) Females - Menorrhagia, uterine fibroid.
3. Elderly patient :
   a) Males - Carcinoma of G. I. tract.
   b) Females - Dysfunctional uterine haemorrhage.

FERROKINETICS :

Serum iron : 70 - 140 pg%

Total iron binding capacity (T1BC) : 270 - 335 jig%

Serum ferritin : 30 - 300 ng/ml

Total body iron content:

Males - 50 mg/kg of body wt

Females - 35 mg/kg of body wt

Daily intake : 10-20 mg (1-2 mg/day is absorbed)

* It is assumed that 250 mg of iron is required to increase the Hb level by 1 g/dl. One unit of blood (450 ml) supplies 250 mg iron.

N.B. : MCH, MCHC and MCV may not be supplied in all haematological data analysis.

CLASSICAL PICTURE OF IRON DEFICIENCY ANAEMIA :

Haemoglobin is reduced. It is a microcytic hypochromic anaemia with low MCV, MCH and MCHC. Anisocytosis, poikilocytosis or target cells are seen in severe cases. Usually retie count is normal but if increased, one should think of blood loss where the patient has enough iron stores in body. Serum iron is low and TIBC is raised; plasma transferrin level is elevated but serum ferritin level is reduced. Bone marrow study reveals moderate erythroid hyperplasia and marrow iron stores (stained by Prussian blue technique) are found to be reduced or absent.

N.B. : In 'acute' blood loss, Hb and haematocrit remain normal in early stages but haemodilution usually prevails after 24-36 hours resulting in anaemia.

MEGALOBLASTIC ANAEMIA

Hb	5.9 g/dl
RBC	1.5 millions/mm^3
WBC	7500/mm^3
Polymorphs	55%; hypersegmentation +
Lymphocytes	38%
Monocytes	3%
Eosinophils	4%
Basophils	0%
Reticulocytes	1%
Anisocytosis	++
Poikilocytosis	++
Platelets	2 lacs/mm^3
MCH	33 pg
MCHC	39 g/dl
MCV	102 cubic micron

Interpretation :

1. Anaemia - Severe (i.e., Hb is 40%); RBC count is reduced to 30% and thus the cells are likely to be hyperchromic.
2. MCH, MCHC and MCV are increased (i.e., the cells are larger than normal and a bit hyperchromic)..
3. Anisocytosis and poikilocytosis point towards dyshaemopoiesis.
4. WBC series, platelet count and retie count are within normal limit.

Inference :

It is a case of macrocytic anaemia probably megaloblastic anaemia (hyperchromic RBC and hypersegmentation of polymorphs with six or more lobes in the nucleus also point towards this diagnosis).

CAUSES OF MACROCYTIC ANAEMIA :

Macrocytic anaemia is of two types, megaloblastic and non-megaloblastic, depending on the bone marrow *findings.*

1. Megaloblastic anaemia (mainly vitamin B_{12} and folic acid deficiency).
2. Liver diseases (needs liver function tests).
3. Aplastic anaemia (WBC count and platelets will be reduced).
4. Haemolysis or acute blood loss (leucocytosis, thrombocytosis and increased reticulocyte will be present).

So, the present chart probably deals with megaloblastic anaemia.

* Cause No. 2, 3, and 4 produce macrocytic anaemia which is normoblastic. Other causes are alcoholism, hypothyroidism, pregnancy, myelodysplastic states and drug-induced (e.g., zidovudine).

ADDISONIAN PERNICIOUS ANAEMIA :

It is a special variety of megaloblastic anaemia which results from a failure of secretion of intrinsic factor by the stomach, other than from total gastrectomy done in the past.

SOURCES AND DAILY REQUIREMENTS OF VITAMIN B,$_2$ AND FOLIC ACID :

a) Vitamin B_{12} - Meat, egg, liver and dairy products.
Daily requirement is 1-2 jag.

b) Folic acid - Fruits, green leafy vegetables and animal protein.
Daily requirement is 100 (xg.

COMMON CONDITIONS ASSOCIATED WITH VITAMIN B_{12} AND FOLIC ACID DEFICIENCY :

(A) Vitamin B_{12} deficiency - True vegetarians, tropical sprue, blind loop syndrome, fish tapeworm infestation, pernicious anaemia, Crohn's disease, gastrectomy.

(B) Folate deficiency - Poor intake of vegetables, pregnancy, chronic haemolytic anaemia, coeliac disease, phenytoin or methotrexate-induced, myeloproliferative disorders.

N.B. : Neurological manifestations of vitamin B_{12} deficiency are peripheral neuropathy, subacute combined degeneration (SCD) and dementia. It is known that folate appears as methyl tetrahydrofolate in plasma, which is converted into tetrahydrofolate with the help of vitamin B_{12}. So, clinically, folic acid should not be used simultaneously to treat vitamin B_{12} deficiency anaemia because it may precipitate severe neurological damage like SCD (by utilising residual vitamin B_{12} for conversion of folate, and resulting in its absolute deficiency).

TREATMENT OF VITAMIN B,$_2$ AND FOLIC ACID DEFICIENCY :

(A) Vitamin B_{12} deficiency—Hydroxycobalamin 1000 jxg, I.M, in 5 doses at 2-3 days apart (i.e., a total of 5 mg), followed by maintenance therapy of 1000 |xg every 3 months for rest of the life. Alternatively, oral B_{12} 2 mg/day can be given as per recent recommendation.

(B) Folate deficiency—Oral folic acid 5 mg daily for 3 weeks cures acute deficiency, while 5' mg once weekly is sufficient for maintenance therapy.

ENUMERATE THE INVESTIGATIONS PERFORMED TO DIAGNOSE MACROCYTIC ANAEMIA :

1. Peripheral blood film (hypersegmented polymorphs are early changes).
2. ESR (increases in malignancy).
3. Thyroid function tests (for hypothyroidism).
4. Serum B_{12} level (normally 200-600 pg/ml).
5. Red cell folate level (normal value is 150-450 ng/ml).
6. Bone marrow study :
   a) Megaloblastic—Vitamin B_{12} or folate deficiency.
   b) Normoblastic—Liver diseases, hypothyroidism.
   c) Abnormal erythropoiesis—Aplastic anaemia, leukaemia.
   d) Increased erythropoiesis—Haemolysis, acute blood loss.
7. Schilling test (helps to identify the cause of vitamin B_{12} deficiency.

* ESR is increased in anaemia due to any aetiology except sickle cell anaemia.

ACUTE LEUKAEMIA

Hb	7.5 g/dl
RBC	2.5 millions/mm^3
WBC	48000 /mm^3
Polymorphs	43%
Lymphocytes -	26%
Monocytes -	0%
Eosinophils -	1%
Basophils	0%
Blast cells	30%
Reticulocytes -	1%
Anisocytosis	+
Poikilocytosis -	+
Platelets -	68000/mm^3

Interpretation :

1. Anaemia is moderate and seems to be normochromic. RBC count is proportionately reduced. Anisocytosis and poikilocytosis suggest dyserythropoiesis. Retie count is normal.
2. WBC count reflects marked leucocytosis. The DC is distributed amongst polymorphs, lymphocytes and blast cells. Huge number of blast cells (30%) in peripheral blood indicate either acute leukaemia (AML/ALL) or blast crisis of chronic leukaemia (CML mainly/rarely CLL).
3. Platelet count is markedly reduced.

Inference :

Probably it deals with a chart of acute leukaemia.

OTHER PROBABILITIES WITH RATIONAL APPROACH :

This chart may well fit in patients; with (a) Leukaemoid reaction, and (b) Blast crisis of CML.

Leukaemoid reaction - TC of WBC matches with leukaemoid reaction but presence of anaemia, absence of polymorphonuclear leucocytosis, presence of a large number of blast cells and low platelet count, and absence of metamyelocytes or myelocytes point against the diagnosis.

Blast crisis of CML - 30% blast cells match the diagnosis but absence of myelocytes, metamyelocytes, basophilia do not corroborate with the diagnosis. In blast crisis of CML, a higher total count of WBC is usually present.

* Leucocyte alkaline phosphatase (LAP) score is high in leukaemoid reaction but low in blast crisis of CML.

** The blast cells of AML contain Auer rods which are not seen in blast crisis of CML or leukaemoid reaction.

CLASSIFICATION OF ACUTE LEUKAEMIAS :

(A) Acute myeloid leukaemia (AML) : The French-American-British (FAB) classification :

MO :, Minimally differentiated leukaemia

M1 : Without maturation

M2 : With fnaturation

M3 : Hypergranular promyelocytic

M4 : Myelomonocytic

M5 : Monocytic

M_6 : Erythroleukaemia (Di Guglielmo's disease)

M7 : Megakaryocytic

(B) Acute lymphoblastic leukaemia (ALL) : The French-American-British (FAB) classification :

LI : Small cells which are usually homogeneous with scanty cytoplasm

L2 : Large cells which are heterogeneous with more cytoplasm

L3 : Large cells which are homogeneous with prominent cytoplasmic vacuolization (also known as 'Burkitt cell leukaemia')

Now-a-days, ALL is classified as :

Common type (Pre-B; 75%) — FAB subtype L_{1f} L_2

T Cell (20%) — FAB subtype L,, L_2

B Cell (5%) — FAB subtype L_3

Undifferentiated (rare)

* WHO classification of acute leukaemia is a bit different. Read from any standard text book of medicine.

Table 16 : Differentiation between myeloblast and lymphoblast

	Features	Myeloblast	Lymphoblast
1.	Nuclear-cytoplasm ratio	Low	High
2.	Number of nucleoli	3 or more	1 or 2
3.	Auer rods in cytoplasm	Present (10-20%)	Absent
4.	Cytochemical staining :		
	a) Myeloperoxidase	+ ve	- ve
	b) Sudan Black B	+ ve	- ve
	c) Chloracetate esterase	+ ve	- ve
	d) Periodic Acid Schiff (PAS)	+ ve in < 25% cells	+ ve in > 50% cells

CHRONIC MYELOID LEUKAEMIA

Hb	10 g/dl
RBC	2.7 millions/mm^3
WBC	- 2.2 lacs/mm^3
Myelocytes	26%
Metamyelocytes	- 20%
Promyelocyte	2%
Polymorphs	40%
Lymphocytes	4%
Monocytes	1%
Eosinophils	- 3%
Basophils	- 2%
Myeloblasts	2%
Anisocytosis	+
Poikilocytosis	+
Platelets	- 4.8 lacs /mm^3

Interpretation :

1. There is mild anaemia which seems to be normochromic. Anisocytosis and poikilocytosis indicate some amount of dyserythropoiesis.
2. The total amount of WBC is much increased with large number of myelocytes and metamyelocytes. There is presence of 2% myeloblast too. Basophilia is present.
3. The platelet count is increased.

Inference :

The marked leucocytosis with presence of myelocytes and metamyelocytes, associated with basophilia in the peripheral blood smear virtually clinch the diagnosis of chronic myeloid leukaemia (CML). Platelet count may be high initially but ultimately the count falls gradually.

* In CML, the peripheral blood film may contain upto 10% myeloblasts.

WHAT IS LEUKAEMOID REACTION ?

It is the extreme degree of elevation of WBC count (usually 30000-50000/mm^3 with many immature cells; rarely > 50000/mm^3) which is composed of mature and/or immature neutrophils, is known as leukaemoid reaction. It reflects the response of normal healthy bone marrow to various stresses.

The common causes are :

1. Disseminated tuberculosis (specially in children) or any severe infection.
2. Malignant infiltration of bone marrow (breast, lung, kidney).
3. Severe haemolysis.
4. Application of cytokines (G-CSF or GM-CSF).

There may be presence of myelocyte or few myeloblasts in the peripheral blood. RBC, eosinophil, monocyte, basophil and platelet counts usually remain normal in leukaemoid reaction. The leucocyte alkaline phosphatase (LAP) score is high; there is absence of splenomegaly. Bone marrow is hyperplastic.

ENUMERATE DIFFERENT HAEMATOPOIETIC GROWTH FACTORS :

(A) Factors work early in stem cell differentiaton ; interleukin (IL)-l, IL-3, IL-6, IL-7 and IL-11.

(B) Factors work later in cellular differentiation cascade : erythropoietin (EPO), granulocyte colony-stimulating factor (G-CSF), granulocyte macrophage colony-stimulating factor (GM-CSF) and thrombopoietin (TPO). These are used therapeutically in different diseases.

WHAR ARE MYELOPROLIFERATIVE DISEASES ?

These are chronic interrelated conditions associated with proliferation of erythroid precursors, myeloid cells or megakaryocytes in the marrow. There may be progression from one disease to another disease process. The conditions are :

1. Chronic myeloid leukaemia.
2. Polycythemia vera.
3. Essential thrombocythemia.
4. Myeloid metaplasia (myelofibrosis).

These conditions may give rise to acute leukaemia.

CLASSIFY CHRONIC LEUKAEMIAS :

(A) Chronic myeloid leukaemia : The FAB classification :

- Ph^a + ve
- Ph^a - ve, BCR^b + ve
- Ph^a - ve, BCR^b - ve
- Eosinophilic leukaemia

a = Philadelphia chromosome

b = Breakpoint clusture region

(B) Chronic lymphocytic leukaemia : The FAB classification :

- Common B cell
- Rare T cell
- Hairy cell
- Prolymphocytic

CAUSES OF BASOPHILIA :

Basophilia = abolute basophil count > 100/mm^3. This is commonly found in,

1. Myeloproliferative disorders (specially, CML).
2. Allergic disorders.
3. Chronic inflammatory disorders.
4. Malignancy, myxoedema, post-splenectomy.

LEUKAEMOID REACTION INDUCED BY VARIOUS BACTERIAL INFECTIONS :

1. The smear shows large number of immature neutrophils (non-segmented neutrophils), i.e., there is a 'shift to the left'.

2. Toxic granulations appear within the cytoplasm of the neutrophils.
3. Often small, oval bodies appear within the neutrophils, and is known as Dohle bodies.

PANCYTOPENIA

Hb	7.8 g/dl
RBC	2.6 millions /mm^3
WBC	2500/mm^3
Polymorphs	28%
Lymphocytes	70%
Monocytes	2%
Eosinophils	- 0%
Basophils	0%
Reticulocytes	1%
Platelets	40000/mm^3

Interpretation :

1. Moderate anaemia, probably normochromic in type. Retie count is normal (i.e., haemolysis or marrow infiltration is absent).
2. Marked leucopenia is noted. There is presence of neutropenia, eosinopenia, monocytopenia and lack of basophil associated with relative lymphocytosis.
3. The platelet count is very low.

Inference :

Presence of anaemia, leucopenia and thrombocytopenia constitutes the diagnosis of pancytopenia.

CAUSES OF PANCYTOPENIA :

(A) Aplastic anaemia - Idiopathic, chemical and physical agents (benzene, ionising radiation, alkylating agents, chloramphenicol), immunologically-mediated, infections like hepatitis, chronic kala-azar or overwhelming sepsis.

(B) Pancytopenia associated with increased or normal bone marrow cellularity — Hypersplenism, myelodysplastic syndromes, vitamin B_{12} and folic acid deficiency.

(C) Paroxysmal nocturnal haemoglobinuria (PNH).

(D) Bone marrow infiltration like carcinomatosis, lymphoma, disseminated tuberculosis, myelofibrosis.

(E) Systemic lupus erythematosus (SLE).

* Combination of pancytopenia with fatty and empty bone marrow clinch the diagnosis of aplastic anaemia.

DRUGS RESPONSIBLE FOR APLASTIC ANAEMIA :

1. Chloramphenicol.
2. Phenylbutazone.
3. Sulphonamides.
4. Phenytoin sodium.
5. Alkylating agents (cyclophosphamide).
6. Chlorpropamide.
7. Carbamazepine.
8. Zidovudine.
9. D-penicillamine.
10. Ticlopidine.

OUTLINE OF MANAGEMENT OF APLASTIC OR HYPOPLASTIC ANAEMIA :

The treatment depends on providing 'supportive care' while awaiting for bone marrow recovery and 'specific therapy' to accelerate recovery of marrow.

1. General measures : withdrawal of aetiologic agent, strict aseptic precautions, prophylactic use of oral antibiotics; cautious use of razors; avoidance of intramuscular injections and drugs like aspirin. Barrier nursing is strictly employed (shifting the patient to intensive Therapeutic Unit, if necessary).

2. Packed red cells transfusion (to keep haematocrit above 25%), granulocyte transfusion (in < 200/mm³ granulocyte count), and platelet transfusion (in < 20000/mm³ platelet count).
3. Broad-speetrum antibiotic therapy is started in the presence of fever or any sign of infection anywhere in the body.
4. Androgen therapy (e.g., oxymetholone in a dose 3-5 mg/kg/day for 3-6 months) in a target to increase the erythropoietin production may be initiated.
5. Haematopoietic growth factors (GM-CSF, G-CSF or erythropoietin) may be tried.
6. Immunosuppression by :
   a) Antilymphocyte/antithymocyte globulin (ALG/ATG) - Horse ATG (40 mg/kg/day for 4 days) or rabbit ALG (3.5 mg/kg/day for 5 days), given in I.V route may help in haematological recovery in 50% cases.
   b) Cyclosporine orally in a dose of 12 mg/kg/day with subsequent adjustment (if the patient can not afford ALG or ATG).
   c) Combination of ALG or ATG, with cyclosporine (standard medical treatment).
   d) ALG/ATG + androgens + corticosteroids (specially in females with severe disease).
7. Allogenic bone marrow transplantation : the only curative treatment for patients under 40 years of age. Patients over 40 years of age have a high risk of graft-versus-host disease as a complication.
8. Miscellaneous : Corticosteroids (controversial; to treat serum sickness due to ALG; in children with pure red cell aplasia); splenectomy may be tried in cases with pancytopenia.

AGRANULOCYTOSIS

Hb	14.5 g/dl
RBC	5.2 millions/mm³
WBC	1600/mm³
Polymorphs	12%
Lymphocytes	- 88%
Monocytes	- 0%
Eosinophils	- 0%
Basophils	- 0%
Platelets	3 lacs/mm³

Interpretation :

1. There is no anaemia. Hb content and RBC count are within normal limit.
2. The WBC count shows gross reduction, i.e., leucopenia is present (< 4000/mm³)
3. Differential count reflects reduction of granulocyte series. Marked neutropenia is present. The absolute count of neutrophil in this chart is 192/mm³ which is much below the expected lower limit (2000/mm³) of neutrophil count. Though the lymphocyte count shows lymphocytopenia (1408/mm³), in this chart it reflects relative lymphocytosis.
4. The platelet count is within normal limit.

Inference :

There is leucopenia as well as neutropenia. Anaemia and thrombocytopenia are absent. This is a chart of agranulocytosis.

CAUSES OF AGRANULOCYTOSIS :

1. Drugs like chloramphenicol, sulphonamides, chlorpropamide, chlorpromazine, propylthiouracil, cytotoxic drugs or antimetabolites, oxyphenbutazone, phenytoin, carbimazole, gold salt (used in rheumatoid arthritis).
2. Ionising irradiation.

3. As an integral part of pancytopenia.
4. Idiopathic agranulocytosis (rare), and cyclic neutropenia.

* In acute leukaemia, neutropenia is associated with low haemoglobin and low platelet count.

SALIENT FEATURES IN AGRANULOCYTOSIS :

1. H/O exposure to one of the drugs or agents.
2. The onset may be acute (sudden) or chronic (gradual). Acute patients present with sore throat (agranulocytic angina), fever with chill and rigor, severe prostration associated with malaise and weakness. The throat and mouth reveal multiple necrotic ulceration with little evidence of pus formation; there is halitosis. The fulminating cases die of septicaemia and toxaemia.
   The chronic patients present with recurrent malaise, fatiguability, low grade fever and sore throat.

HOW WILL YOU MANAGE A CASE OF AGRANULOCYTOSIS ?

1. Immediate stoppage of the offending drug or agent.
2. Transfer the patient in Intensive Therapeutic Unit (ITU) and start barrier nursing.
3. Blood culture should be done but usually it comes out to be sterile. Prophylactic antibiotic therapy may be started. If the absolute neutrophil count is less then 200/mm^3, parenteral antibiotic therapy using an aminoglycoside together with mezlocillin, and judicious administration of corticosteroid may be employed. If anaerobic infection is suspected, metronidazole may be given.
4. White blood cell transfusion from a compatible adult relative donor often relieves fever dramatically.
   Candidiasis in the mouth, if present, may be dealt with gention violet, nystatin; for systemic candidiasis, parenteral therapy with amphotericin B, fluconazole, voriconazole or caspofungin is employed. Oral hygiene should be properly maintained.
   N.B. : Actually, patients taking the drugs mentioned above (chloramphenicol, carbimazole etc) should be repeatedly warned to report the physician if any fever or sore throat appears.

WHAT TO DO IN CARBIMAZOLE-IND UCED AGRANULOCYTOSIS ?

Carbimazole is used in thyrotoxicosis. Though mild transient leucopenia (10%) may occur with carbimazole, agranulocytosis (0.2%) is rarely seen. Usually these effects are observed within 7-28 days of starting treatment. As agranulocytosis can not be predicted by routine blood count, *patients should always be warned for the development of sore throat, fever and mouth ulcers.* If the absolute neutrophil count goes below 1500/mm^3, antithyroid medication should be stopped.

ABSOLUTE COUNT OF DIFFERENT CELLS OF WBC SERIES :

Polymorphs	-	2000-7500/mm^3
Lymphocytes	-	1500-4000/mm^3
Monocytes	-	80-200/mm^3
Eosinophils	-	40-500/mm^3
Basophils	-	10-100/mm^3

CAUSES OF LYMPHOCYTOSIS AND MONOCYTOSIS :

(A) Lymphocytosis :

1. Infections e.g., tuberculosis, whooping cough, brucellosis, viral infections, infectious mononucleosis.
2. ALL and CLL; NHL.
3. Thyrotoxicosis.
4. Adrenal insufficiency.
5. Serum sickness.

(B) Monocytosis :

1. Chronic infections like tuberculosis, syphilis, kala-azar, brucellosis.
2. Collagen vascular diseases.
3. Acute monocytic and myelomonocytic leukaemia, Hodgkin's lymphoma.
4. Sarcoidosis.
5. Inflammatory bowel disease.

TROPICAL EOSINOPHILIA

Hb	–	14 g/dl
RBC	–	5 millions/mm^3
WBC	–	19000/mm^3
Polymorphs	–	42%
Lymphocytes	–	25%
Monocytes	–	1%
Eosinophils	–	32%
Basophils	–	0%
Platelets	–	2.6 lacs/mm^3

Interpretation :

1. There is no anaemia. Hb content and RBC count are within normal limit.
2. The WBC count sho<vs leucocytosis. The absolute eosinophil count is 6080/mm^3 which is much above the expected maximum value (500/mm^3).
3. The platelet count is within normal limit.

Inference :

This is a chart of eosinophilia, probably tropical eosinophilia.

WHAT IS TROPICAL EOSINOPHILIA ?

When the absolute eosinophil count goes above 500/mm^3, it is known as eosinophilia. The diagnosis of tropical eosinophilia is confirmed by :

1. Patient is a prolonged habitat of an endemic area (e.g., Asian subcontinent).
2. Absolute eosinophil count in blood is above 3000/mm^3.
3. Absence of microfilariae in peripheral blood, examined by concentration technique both in day and night.
4. Presence of filarial antibodies in high titre. The filarial complement fixation test is positive in almost every patient.
5. Plasma level of IgE is high (at least 1000 U/ml).
6. Response to diethylcarbamazine citrate (DEC) therapy within 7 to 10 days when the drug is continued in a dose of 100 mg tds for 14 days.

* Tropical eosinophilia is an atypical host response to different filariae including Wuchereria bancrofti, Brugia malayi, Loa loa, Brugia pahangi, Dirofilaria immitus.

FEATURES OF TROPICAL EOSINOPHILIA :

1. Paroxysmal dry cough with wheezing which is often nocturnal (commonest presentation).
2. Low grade pyrexia, loss of weight, lassitude, myalgia.
3. Splenomegaly and lymphadenopathy, rarely (Meyers-Kouwenaar syndrome).
4. Male : female ratio is 4 : 1; cough with nocturnal bronchospasm and wheeze, where the chest X-ray shows miliary mottlings (Weingarten syndrome) — mid and lower zones are mostly affected with prominent bronchovascular markings.
5. Treatment is done by DEC with 4-6 mg/kg of body weight/day for at least 14 days.

COMMON CAUSES OF EOSINOPHILIA :

1. Allergic disorders like bronchial asthma, hay fever, urticaria, angioneurotic oedema, eczema, pemphigus, allergic vasculitis, serum sickness.
2. Parasitic infestations like hookworm, schistosomiasis, toxocariasis, ascariasis, strongyloidiasis, filariasis, trichinosis, cysticercosis and tropical eosinophilia.
3. Drug like aspirin, iodides, penicillin, nitrofurantoin, sulphonamides.
4. Hypereosinophilic syndromes like Loeffler's syndrome, eosinophilic leukaemia.

5. Malignancy like Hodgkin's disease, mycosis fungoides, CML.
6. Collagen vascular diseases like polyarteritis nodosa, Churg-Strauss syndrome (vasculitis).

WHAT IS HYPEREOSINOPHILIC SYNDROME ?

It is a heterogeneous group of disorder with the common features of prolonged eosinophilia (absolute eosinophil count may go upto 50000-100000/mm^3) of unknown cause and usually associated with dysfunction of organs like heart, kidney, lungs, gastrointestinal tract, CNS, skin and even bone marrow. Patients commonly complain of pyrexia, weight loss, non-productive cough and respiratory distress. They usually die of congestive cardiac failure. Treatment by glucocorticoids may be of value in some cases.

THALASSAEMIA

Hb	7.2 g/dl
RBC	3 millions/mm^3
WBC	12700 /mm^3
Polymorphs -	63%
Lymphocytes -	32%
Monocytes -	2%
Eosinophils -	3%
Basophils	0%
Reticulocytes -	11%
Anisocytosis	++
Poikilocytosis	++
Target cells	+
Tear-drop cells	+
Normoblasts	+
Platelets	2.2 l'acs/mm^3
MCH	21 Pg .
MCHC	22 g/dl
MCV	66 cubic micron

Interpretation :

1. There is moderate anaemia (Hb 7.2 g/dl, i.e., approximately 50%). RBC count is reduced to 60% approximately). So the cells are likely to be hypochromic.
2. Moreover MCH, MCHC and MCV are low, reflecting microcytic hypochromic anaemia.
3. The WBC count shows leucocytosis. The differential count is within normal limit.
4. Reticulocyte count is high (normal value 0.2-2%). Reticulocytosis and presence of normoblasts probably indicate either erythroid hyperplasia or bone marrow infiltration.
5. Anisocytosis and poikilocytosis indicate dyserythropoiesis.
6. Target cells and tear-drop cells are abnormal findings, and indicate either erythroid hyperplasia or infiltration of bone marrow. The platelet count is within normal limit.

Inference :

Common causes of microcytic hypochromic anaemia are :

1. Iron deficiency anaemia.
2. Chronic haemolytic anaemia (e.g., thalassaemia).
3. Sideroblastic anaemia.
4. Sometimes seen in lead poisoning.

In sideroblastic anaemia, very often normocytes predominate; reticulocyte count is normal and sideroblasts are seen in peripheral blood. Absence of these facts negate the diagnosis of sideroblastic anaemia.

Again, erythroid hyperplasia (as there is presence of reticulocytosis and normoblasts) and dyshaemopoiesis (as there is presence of anisocytosis and poikilocytosis) point towards chronic haemolytic anaemia or iron deficiency anaemia with recent iron therapy.

The patients of lead poisoning will have specific occupational history like inhalation of fumes as from burning storage batteries, solder or paint spraying, or H/O ingestion of lead-containing material like paint. These patients reveal mild anaemia and basophilic stippling in the peripheral blood.

In iron deficiency anaemia (with iron therapy), usually reticulocyte count is not too high and leucocytosis is seldom present. Rather leucocytosis (often indicates pulmonary infection) may be present in chronic haemolytic anaemia.

So, this chart is probably dealing with chronic haemolytic anaemia. Presence of hypochromia as well as the grade of anaemia indicate the aetiology of anaemia towards thalassaemia major.

WHAT IS A RETICULOCYTE ?

These are premature or young red cells, which are disc-shaped and contains ribosomal material (RNA). Condensation of the ribosomes to form reticular material (for identification) is best observed by,

a) Supravital stain (cresyl blue, new methylene blue), or

b) Romanowsky stain.

Normal reticulocyte count is 0.2-2% of RBC. An absolute increase in reticulocyte count (reticulocytosis) usually reflects 'increased erythropoiesis' or haemolytic anaemia. Rarely, when under stress, reticulocyte count may increase (released from marrow) without having increased erythropoiesis. Low retie count is seen in aplastic anaemia and megaloblastic anaemia.

* The normoblasts in a blood film usually indicate excessive or abnormal blood formation, or irritation of bone marrow by infiltration.

** *In clinical practice, reticulocytosis commonly indicates haemolytic anaemia. Retie count is also increased following therapy in iron/Jolic acid/vitamin B_{12} deficiency anaemias, and in acute blood loss.*

*** **Sideroblasts** : the mitochondria, surrounding the nucleus of a normoblast, becomes iron-laden and appears as rings (known as ring sideroblast) with Prussian blue staining. Ring sideroblasts are seen in bone marrow.

**** **Corrected reticulocyte count in anaemia**—suppose, the retie count in an adult patient with 10 g Hb is 2% -> it does not reflect a true marrow response—

Corrected retie count will be :

$$\frac{\text{Patients' Hb x estimated retie count}}{\text{Normal Hb for that age and sex}}$$

$$= \frac{10 \times 2}{15} = 1.3\%$$

CAUSES OF TARGET CELLS IN PERIPHERAL BLOOD FILM :

1. Thalassaemia.
2. Iron deficiency anaemia.
3. Cholestatic jaundice.
4. Post-splenectomy.

HOW THE TARGET CELLS LOOK LIKE ?

These are flat red blood corpuscles with a central mass of haemoglobin (dense zone) surrounded by a ring of pallor (pale zone) and an extreme outer ring of haemoglobin (dense zone).

CLINICAL TRIAD OF CHRONIC HAEMOLYTIC ANAEMIA :

They are :

1. Anaemia,
2. Jaundice, and
3. Splenomegaly.

WHAT IS MEANT BY PUNCTATE BASOPHILIA OR BASOPHILIC STIPPLING ?

With Romanowsky staining, scattered deep-blue dots may be seen in the cytoplasm of abnormally damaged red cells. This type of basophilic stippling is commonly seen in chronic lead poisoning, beta-thalassaemia major and in any patient with severe anaemia (e.g., megaloblastic anaemia).

* Read Thalassaemia' from 'Bedside Clinics in Medicine, Part I' for further details.

THROMBOCYTOPENIA

Hb	- 8.8 g/dl
RBC	3.1 millions/mm^3
WBC	8200/mm^3
Polymorphs	- 55%
Lymphocytes	- 35%
Monocytes	- 6%
Eosinophils	- 4%
Basophils	- 0%
Reticulocytes	1%
Anisocytosis	- Nil
Poikilocytosis	- Nil
Platelets	- 68000/mm^3
Bleeding time	- 13 min
Clotting time	- 5 min.

Interpretation :

1. There is moderate anaemia which seems to be normochromic. Anisocytosis and poikilocytosis are absent (i.e., no dyshaemopoiesis).
2. Total and differential count of WBC, and reticulocyte count are within normal limit.
3. There is thrombocytopenia. Bleeding time (BT) is increased in the presence of normal clotting time (CT).

Inference :

Presence of anaemia (probably due to bleeding), normal leucocyte count, thrombocytopenia, increased BT and normal CT clinch the diagnosis of thrombocytopenia, probably immune or idiopathic thrombocytopenic purpura (ITP).

CRITICAL PLATELET COUNT:

It is 20,000/mm^3 (old view); the recent view is 10000/mm^3 and platelet count below this level may endanger the life of the patient by spontaneous haemorrhage in vital organs.

HOW A PATIENT OF ITP PRESENTS ?

Women usually between 20-40 years of age (the acute form affects children between 2-6 years of age) present with gradually developing petechiae-purpura over skin, bleeding from gum, menorrhagia, epistaxis or haematuria (easy bruisability and spontaneous subcutaneous haemorrhage are most common). Pyrexia and malaise are not uncommon.

On examination, bleeding spots over the skin is noted, There is neither any lymphadenopathy nor any sternal tenderness present. The spleen is not palpable in 90% patients. Hess' capillary test (tourniquet test) may be positive.

[Bone marrow shows normal or increased numbers of megakaryocytes, which are otherwise normal],

POSSIBLE CAUSES OF THROMBOCYTOSIS :

1. Post-splenectomy.
2. Malignancy, Hodgkin's disease, chronic inflammatory disorders.
3. After severe haemorrhage, tissue damage.
4. Myeloproliferative disorders (CML, polycythemia vera etc).

SIGNIFICANCE OF BT, CT, PT, PTT AND TT :

(I) Bleeding time (BT) Increased in thrombocytopenia and platelet functional defect (thrombasthenia); von Willebrand (vW) disease.

(II) Clotting time (CT) : Increased in coagulation disorders (e.g., haemophilia) and afibrinogenaemia.

(III) Prothrombin time (PT) Increased in factor VII deficiency (extrinsic pathway); factors II, V and X deficiency (common pathway); commonly seen in obstructive jaundice, haemorrhagic disease of the newborn, liver diseases, coumarin therapy, vitamin K deficiency.

(IV) Activated partial thromboplastin time (aPTT) : Increased in factors XII, XI, IX and VIII deficiency (intrinsic pathway); factors II, V and X deficiency (common pathway), Commonly seen in haemophilia, Christmas disease, heparin or kaolin cephalin therapy, DIC, vW disease.
clotting time (KCCT)

(V) Thrombin time (TT) : Increased in afibrinogenaemia or dysfibrinogenaemia.

NON THROMBOCYTOPENIC PURPURA :

(A) Vessel wall abnormalities, i.e., vasculitis, Henoch-Schonlein purpura, senile purpura, scurvy, uraemia, meningococcaemia, paraproteinaemia and drugs (e.g., sulphonamides); BT is usually normal, rarely increased. Platelet count is normal.

(B) Platelet functional defect (thrombasthenia) — BT is increased though platelet count remains normal.

* **Platelet functional defects** are of two types :

(A) Inherited—Glanzmann's thrombasthenia, Bernard-Soulier syndrome and storage pool disease.

(B) Acquired—Myeloproliferative disease, renal and liver disease, paraproteinaemias, drugs (e.g., NSAIDS).

MODALITIES OF TREATMENT ADOPTED IN ITP :

The patients usually require no treatment as long as the platelet count is > 30000/mm^3 unless they undergo a surgical procedure.

1. Platelet or fresh blood transfusion. Children usually do not require treatment. Supportive care.
2. Prednisolone (1 mg/kg of body weight/day).
3. I.V immunoglobulin (1 g/kg of body weight for 2 days) —Used temporarily to raise the platelet count (e.g., before surgery).
4. Rho (D) immune globulin therapy in a dose of 25 ng, I.V for 3 days are helpful.
5. Splenectomy (with pneumococcal, H. influenzae and meningococcal vaccination).
6. Vincristine, cyclophosphamide, cyclosporine, azathioprine or mycophenolate mofetil; danazol, dapsone are also tried.
7. Specific monoclonal antibodies e.g., rituximab [anti CD-20 (B cell) antibody], and recombinant thrombopoietin are promicing.
8. Eltrombopag (thrombopoietin receptor agonist) and romiplostin (a novel thrombopoiesis protein) have shown encouraging results.

* Read the chapter on 'Haemorrhagic spots' from 'Bedside Clinics in Medicine, Part I'.

CHARTS ON GLUCOSE TOLERANCE TEST (GTT)

PREFACE:

Diabetes mellitus is a clinical syndrome characterised by high blood sugar level (hyperglycaemia) and glycosuria due to relative or absolute deficiency of insulin secretion and/or action, or insulin resistance that leads to disturbances in carbohydrate, protein and fat metabolism, as well as disturbance of water and electrolyte homeostasis.

Oral GTT is an estimation of the capacity of a person to dispose off orally administered glucose (i.e., the glycaemic response). Now-a-days, it is not regarded as a very sensitive test to diagnose diabetes mellitus as several large studies suggest that most of the patients (approximately 75%) with impaired GTT do not develop diabetes mellitus. GTT has a tendency to overdiagnose diabetes mellitus though it may still have a place in research works. However, GTT may be indicated in 1) diagnosis of gestational diabetes mellitus (GDM), 2) diagnosis of pre-diabetes i.e., IFG (impaired fasting glucose) and IGT (impaired glucose tolerance), and 3) evaluation of unexplained nephropathy, neuropathy or retinopathy when random glucose concentration is < 140 mg/dl.

Procedure of the test :

1. The patient is starved overnight (at least 8 hours) after 3 days of unrestricted carbohydrate diet (at least 150 g/day).
2. The patient should take 1/2 an hour rest in the laboratory and abstain from smoking but is allowed to drink water; 2 ml of fasting venous blood is drawn, and urine is collected before the test ('zero hour').
3. Now 75 g of glucose dissolved in 300 ml of water is taken by mouth in 5 minutes in a case where the patint is non-diabetic or not on any therapy. For treated diabetic patients, postprandial blood should be drawn 2 hours after his recommended diabetic meal at scheduled time with usual drugs or insulin.
4. Thereafter blood and urine samples are collected every half-hourly for at least 2 hours. Quantitative estimation of sugar in blood and qualitative estimation of sugar in urine are performed.
5. A curve is now plotted on a white paper by time in hours against blood level of sugar in mg/dl or mmol/l.

- So, 5 samples of blood and urine each are required for the test.

** While performing GTT, a diabetic patient on drugs or insulin need not take 75 g of glucose, instead he can consume his usual diet in which he is accustomed in his day to day life. The patient must receive his drugs as per schedule on the day of the test.

Diagnostic criteria for diabetes mellitus :

- Symptoms of diabetes plus 'random' blood glucose concentration > 200 mg/dl, or
- 'Fasting' plasma glucose >126 mg/dl, or
- '2-h postload' plasma glucose > 200 mg/dl during an oral GTT.

The **new diagnostic criteria for pre-diabetes and diabetes are** :

In the new criteria, the categories of FPG are :

FPG < 100 mg/dl = Normal fasting glucose

FPG > 100 mg/dl and < 126 mg/dl = Impaired fasting glucose (IFG)

FPG >126 mg/dl = Provisional diagnosis of diabetes (on more than one occasion)

The corresponding categories when the oral GTT is used, are as follows :

2 hPG <140 mg/dl = Normal glucose tolerance

2 hPG > 140 mg/dl and < 200 mg/dl = Impaired glucose tolerance (IGT)

2 hPG > 200 mg/dl = Provisional diagnosis of diabetes (must be confirmed on a subsequent day)

* FPG = Fasting plasma glucose; 2 hPG = 2-h postload glucose

** The prognostic significance and outcome (i.e., accuracy) are same whether it is FPG > 126 mg/dl or 2 hPG > 200 mg/dl (i.e., in diabetics). This is why, in clinical practice, the FPG test is now-a-days mostly preferred because of ease of administration, convenience, acceptibility to patients and its lower cost.

*** Venous blood glucose < capillary blood glucose; and whole blood glucose < plasma glucose.

**** Blood glucose concentration in mg/dl should be divided by 18 to get the value in mmol/1, e.g., 110 mg/dl = 6.1 mmol/1, 126 mg/dl = 7 mmol/1, 140 mg/dl = 7.8 mmol/1, and 200 mg/dl =11.1 mmol/1.

***** 'Fasting' is defined as no calorie intake (i.e., overnight) for at least 8 hours. 'Random' is defined as any time of the day without regard to time since the last meal.

****** In most laboratories, plasma or serum is used for glucose estimation whereas most methods for self-monitoring of blood glucose (SMBG), the whole blood is used (by glucometer).

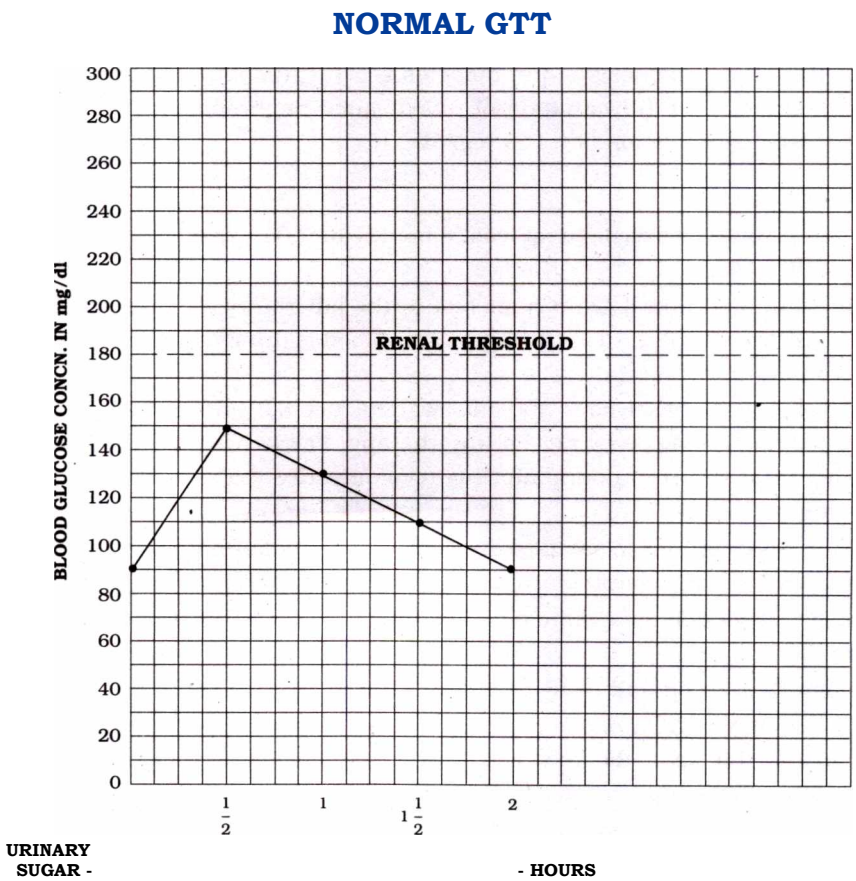

Fig. 7.1 : Normal curve

Interpretation :

1. The fasting plama glucose level is below 100 mg/dl (i.e., normal).
2. The highest level is reached near 150 mg/dl. All the 1/2, 1, 1 1/2 and 2-hour levels are below 180 mg/dl (normal renal threshold is 180 mg/dl).
3. The baseline is reached within 2 hours.
4. All the urine samples are sugar-free.

* **'Renal threshold'** is the capacity of the renal tubules to reabsorb glucose from the glomerular filtrate; if the plasma glucose concentration exceeds renal threshold, glycosuria occurs. Normal renal threshold is approximately 180 mg/dl but wide individual variation may exist.

Inference :

This is a normal curve following a glucose tolerance test.

IMPAIRED GTT/IFG

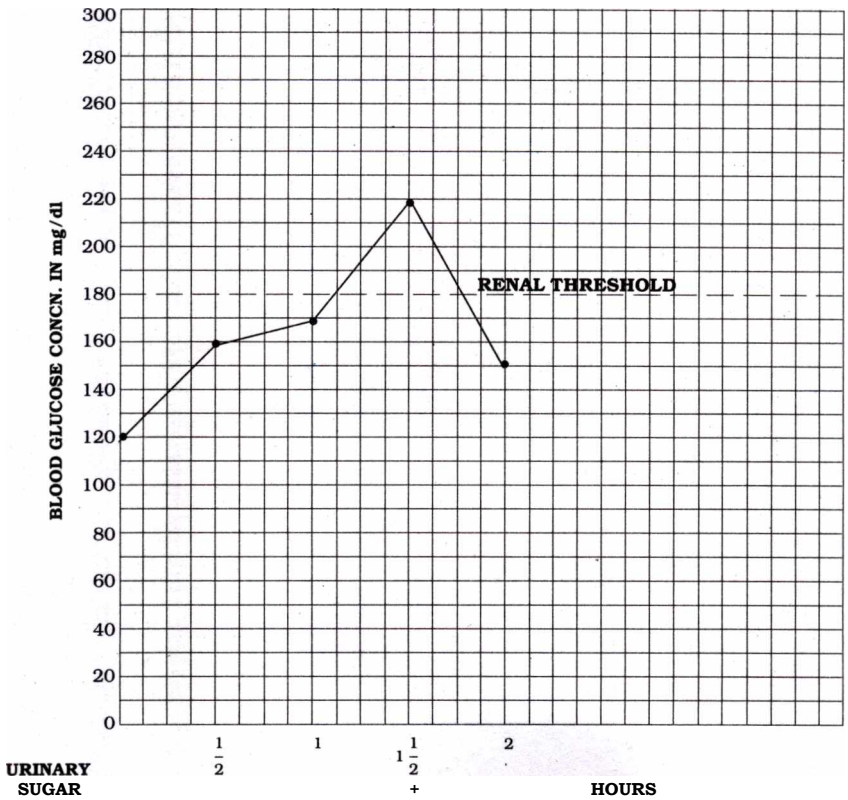

Fig. 7.2 : Impaired glucose tolerance with impaired fasting glucose

Interpretation :

1. The fasting plasma glucose level is above 100 mg/dl but below 126 mg/dl (i.e., IFG present)
2. The 1/2 and 1-hour levels are below the renal threshold but the $1^1/_2$-hour level has crossed 180 mg/dl and is near about 220 mg/dl.
3. Renal threshold is normal, i.e., 180 mg/dl.
4. The 2-hour level is 150 mg/dl (i.e., in between 140-200 mg/dl).
5. The l*/$_2$-hour urine sample contains sugar. Other samples are sugar-free.

Inference :

As the 2-hour test value is 150 mg/dl (i.e., in between 140-200 mg/dl) and FPG is 120 mg/dl (i.e., > 100 mg/dl but < 126 mg/dl), the chart is dealing with both IGT and IFG.

IMPORTANCE OF IMPAIRED GTT :

Patients with impaired glucose tolerance (IGT) and/or impaired fasting glucose (IFG) are now referred to as having '**pre-diabetes*** which indicates the relatively high risk for development of diabetes in these patients. Though they are not diabetic at the present moment, pre-diabetes indicates the need for further evaluation (future surveillance). Proper history taking is important and the patient may be kept under observation; the test may be repeated on a later date.

RENAL GLYCOSURIA

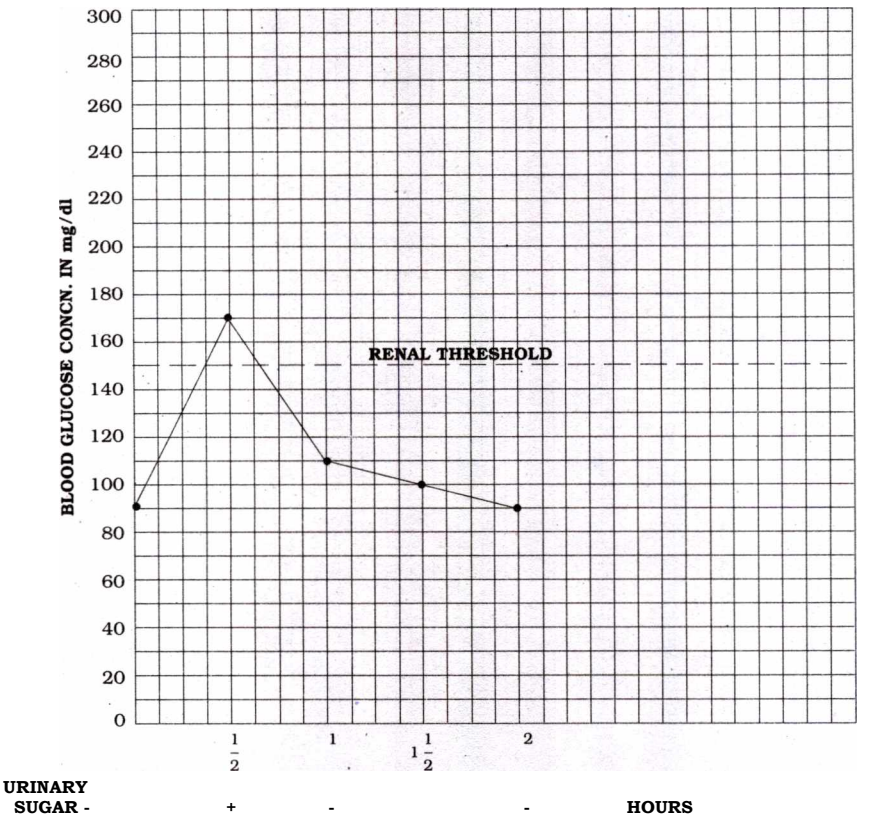

Fig. 7.3 : Renal glycosuria

Interpretation :

1. The fasting plasma glucose level is 90 mg/dl. The 1/2, 1, $1^1/_2$ and 2-hour level is below 180 mg/dl i.e., the normal level of renal threshold.
2. Renal threshold is 150 mg/dl (i.e., lower than normal).
3. Though the 1/2-hour level is 170 mg/dl, the urine sample shows presence of sugar, probably due to presence of low renal threshold for glucose.
4. The 2-hour level has touched the baseline.

Inference :

It is a curve of renal glycosuria.

WHAT IS RENAL GLYCOSURIA ?

It is a cause of glycosuria due to lowered renal threshold. There is absence of both hyperglycaemia and the classical symptoms of diabetes mellitus (polyuria, polyphagia and polydipsia). This is a benign condition and is often temporarily *seen in pregnancy.* Renal glycosuria is diagnosed by **Marble's criteria** (glycosuria in the absence of hyperglycaemia, normal oral GTT, identification of urinary reducing substance as glucose and constant glycosuria with little fluctuation related to diet). Probably it is a genetic disorder (autosomal recessive). Rarely, glycosuria may be severe enough to produce polyuria and polydipsia.

ALIMENTARY GLYCOSURIA

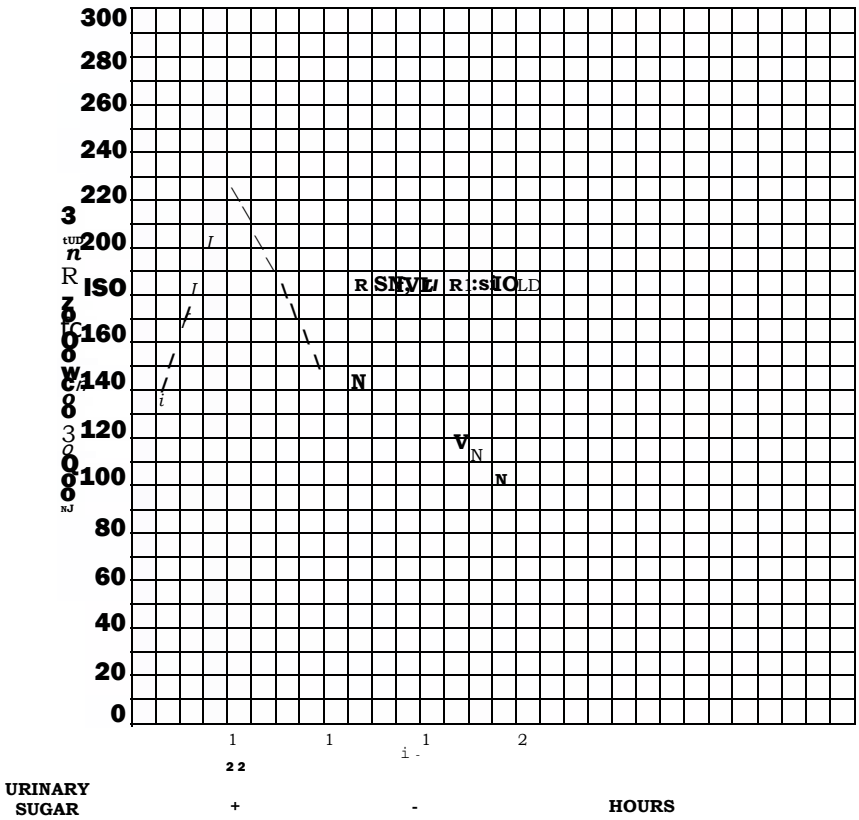

Fig. *7.4 : Alimentary glycosuria*

Interpretation :

1. The fasting plasma glucose level is 102 mg/dl (i.e., IFG present).
2. The 2-hourly level is 100 mg/dl and thereby excludes the diagnosis of diabetes mellitus.
3. The renal threshold is normal (180 mg/dl) and thus the urine sugar is absent in 0, 1, 1½ and 2-hour samples.
4. As the 1 /2-hour blood glucose level is 230 mg/dl (urine sample contains sugar), the possibilities of impaired GTT and alimentary glycosuria come in mind. As the 2-hourly blood level of glucose touches the baseline, question of impaired GTT does not arise. So, probably this is a curve of alimentary glycosuria.

Inference :

The GTT deals with alimentary glycosuria or 'lag storage curve'.

WHAT *IS ALIMENTARY GLYCOSURIA OR LAG STORAGE CURVE ?*

It is seen that in some persons there is rapid but temporary rise in blood glucose level following a meal and the level usually exceeds the normal renal threshold, and thus the urine sample contains sugar too; the fasting and 2-hour values remain normal. This benign condition is not related to diabetes mellitus. Lag storage is due to defective glycogen synthesis in the liver or some defect lying in the G.I. tract, and is commonly found in hepatic disorders. Alimentary glycosuria is a better term than 'lag storage'.

* This patient has incidental impaired fasting glucose (IFG).

CONDITIONS ASSOCIATED WITH ALIMENTARY GLYCOSURIA :

1. Normal Individual.
2. After gastric surgery (e.g., partial gastrectomy leads to rapid gastric emptying and *thereby* facilitate increased glucose absorption).
3. Hyperperistalsis due to any cause (e.g., peptic ulcer).
4. Hepatic disorders (e.g., hepato-cellular failure).
5. Hyperthyroidism.

* Remember, *damping syndrome* may produce sudden hyperglycaemia as is seen in alimentary glycosuria (partial gastrectomy -> rapid emptying of sugar containing meals into proximal small intestine -> abrupt increase in blood glucose concentration -> release of excess insulin stimulated by high blood sugar level -» subsequent hypoglycaemia with vasomotor symptoms) but in that situation, the 1 $^1/_2$ to 3-hour samples will show low blood glucose level (hypoglycaemia). However, the GTT may have to be continued for 3 hours instead of 2 hours to diagnose late dumping syndrome.

WHAT *IS GLYCOSURIA OF PREGNANCY* ?

Glycosuria is a common finding in pregnancy because of drop in renal threshold for glucose as a result of increase in GFR. Sometimes, lactose is found in urine in late pregnancy. As high blood sugar level in pregnancy is associated with increased perinatal morbidity and mortality, all patients with glycosuria of pregnancy should be properly screened to exclude **gestational diabetes mellitus (GDM).**

GDM is **defined as** diabetes with first onset or recognition during pregnancy. This includes pre-existing type 1 or type 2 DM (may be clinically undiagnosed); and the majority of women can expect to go back to normal glucose tolerance immediately after pregnancy. GDM is associated with an increased risk of later development of T_2DM. Approximately, *4%* of pregnant mothers may develop GDM. A high maternal blood glucose promotes fetal insulin production which stimulates fetal growth. Macrosomia of the fetus may complicate labour and delivery. GDM is treated with insulin as oral hypoglycaemic drugs cross the placenta and may be a potential risk for the fetus.

The European criteria for diagnosis of GDM in venous plasma glucose after a 75 g oral GTT is ;

Fasting > 99 mg/dl, or

2 hPG > 162 mg/dl

REDUCING AGENTS IN URINE (POSITIVE BENEDICT'S TEST) :

(A) Glucose (commonest) —Diabetes mellitus, impaired GTT, renal glycosuria, alimentary glycosuria, Fanconi's syndrome.

(B) Non-diabetic melituria —Lactose (pregnancy and during lactation), fructose (fructosuria), galactose (galactosuria), pentose (pentosuria after consumption of grapes, cherries, plums), homogentisic acid (found in alcaptonuria, a rare inborn error of metabolism).

(C) Spurious —Patient treated with ascorbic acid, nalidixic acid, cephalosporins or aspirin.

* Sucrose is not a reducing agent. Galactosuria and fructosuria may result from inborn error of metabolism.

POSITIVE ROTHERA'S TEST (NITROPRUSSIDE TEST) IN URINE :

1. Ketone bodies.
2. Cystinuria.
3. Homocystinuria.
4. False positive (spurious)—Drug treatment with salicylates, levodopa, captopril, penicillamine.

DIABETIC CURVE

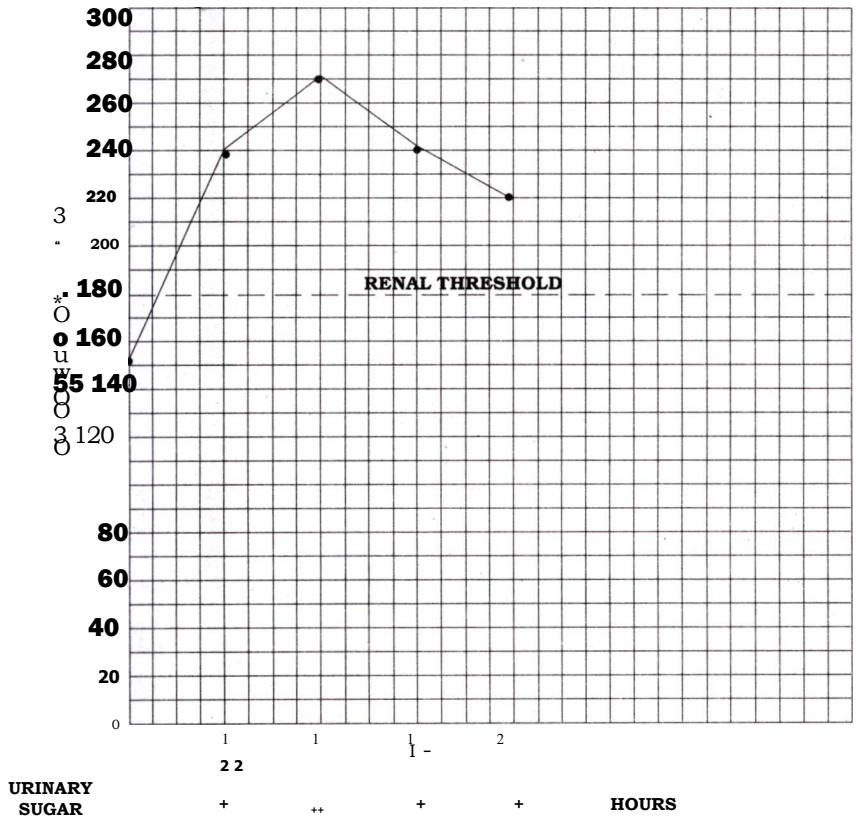

Fig. 7.5 : Diabetic curve

Interpretation :

1. The fasting plasma glucose level is 150 mg/dl and that of 2-hour postprandial (PP) level recorded is 220 mg/dl (i.e., > 200 mg/dl). The 1/2,1 and $1^1/_2$-hour levels are well above the renal threshold level (i.e. > 180 mg/dl), and virtually above 200 mg/dl.
2. The 1/2, 1, $1^1/_2$ and 2-hourly urine samples show presence of sugar (all the corresponding blood glucose level is above the renal threshold).

Inference :

This is the curve of a patient who is sufferring from diabetes mellitus of moderate severity.

AETIOLOGICAL CLASSIFICATION OF DIABETES MELLITUS (1997) :

I. Type 1 diabetes ((3-cell destruction leading to absolute insulin deficiency)
   a) Immune-mediated
   b) Idiopathic

II. Type 2 diabetes (insulin resistance ranging from deficiency to secretory defect)

III. Other specific types :
   (A) Genetic defects of P-cell function — Chromosome 12, *HNF- la (formerly MODY 3); chromosome 7, glucokinase (formerly MODY 2); chromosome 20, HNF-4a (formerly MODY 1); mitochondrial DNA, mutant insulins, hyperproinsulinaemia
   (B) Genetic defects in insulin action — Lipoatrophic diabetes, leprechaunism
   (C) Endocrine disorders — Acromegaly, Cushing's syndrome, pheochromocytoma, hyperthyroidism, glucagonoma, somatostatinoma, aldosteronoma
   (D) Disease of exocrine pancreas — Pancreatitis, trauma, pancreatectomy, cystic fibrosis, haemochromatosis, fibrocalcific pancreatic disease (FCPD), neoplasia

(E) Drug- or chemical-induced — Vacor (rat poison), thiazides, glucocorticoids, phenytoin, nicotinic acid, pentamidine, a-interferon, diazoxide

(F) Infections — Congenital rubella, cytomegalovirus

(G) Uncommon immune-mediated disorders — Anti-insulin receptor antibodies, 'stiff-man' syndrome

(H) Genetic syndromes associated with diabetes—Down's syndrome, myotonic dystrophy, Klinefelter's syndrome, Turner's syndrome, Friedreich's ataxia, Prader-Willi syndrome.

IV. Gestational diabetes mellitus (GDM)

* HNF = Hepatocyte nuclear factor; MODY — Maturity-onset diabetes of the young

** In this classification, the terms like IDDM and NIDDM are eliminated because many patients with NIDDM eventually would require insulin.

CHARTS ON STOOL / FAECES

PREFACE:

(A) ***Naked-eye examination or macroscopic examination :***

1. Amount — Copious or scanty.
2. Colour — Yellowish-brown due to the presence of stercobilinogen/stercobilin (normal), black (melaena, ingestion of bismuth, iron or licorice), red (ingestion of beets/mixed with blood/ haematochezia), pale (absence of bile, rapid passage through the intestine in diarrhoea, high fat content due to malabsorption), green (in the presence of diarrhoea, unaltered bile m^y be there due to rapid passage).
3. Consistency—Well-formed stool (normal), harder than normal (constipation), liquid or watery (diarrhoea), tarry or sticky (melaena), slimy or jelly like (due to the presence of excess mucus), soft and frothy (steatorFhoea).
4. Odour—Normal faecal odour (due to aromatic substances indole and skatole etc, and H_2S), odourless (cholera, acute bacillary dysentery), offensive (acute amoebic dysentery, malabsorption syndrome, melaena, jaundice, giardiasis, partial gut obstruction). In nursing in-
   ■ fants, stool gives a sour odour due to presence of fatty acids.
5. Parasites—Worms or segments of worms may be present e.g., roundworm, threadworm, tapeworm.

(B) Chemical examination :

1. Reaction—Usually it is neutral or slightly acidic (normal); alkaline stool may be found in acute bacillary dysentery, salmonella enteritis etc. Highly acidic stool may be present in lactase deficiency, after lactulose ingestion in hepatic pre-coma, or in sprue.
2. Orthotoluidine test—Detects presence of blood (occult or overt). Before performing this test, patient should have been on a meat-free diet for 3 days and should not have been taking vitamin C and aspirin (NSAID).

(C) Microscopic examination :

1. RBC (presence of blood, overt or occult).
2. WBC (acute bacillary dysenteiy; Campylobacter, enteroinvasive or enterohaemorrhagic E.coli, Clostridium difficile, salmonella infection).
3. Macrophages—Acute bacillary dysentery, acute infectious colitis, pseudomembranous colitis.
4. Eosinophils—Acute amoebic dysentery, eosinophilic enteritis.
5. Parasites, cyst—Intestinal amoebiasis, giardiasis or helminthiasis.
6. Bacteria—Acute bacillary dysentery (shigellosis), acute infectious colitis.
7. Flakes of mucus—Acute amoebic dysentery, acute bacillary dysentery, ulcerative colitis, irritable bowel syndrome, infection by Campylobacter jejuni, cholera, malabsorption syndrome.
8. Epithelia—Found in tropical sprue, acute bacillary dysentery.
9. Pus Cells—In dysentery of any aetiology.
10. Charcot-Leyden crystals—Acute amoebic dysentery.
11. Undigested food material—Malabsorption syndrome.

* Rice-watery stool—Cholera; pea-soup diarrhoea—Enteric fever; china-clay stool—Obstructive jaundice.

** Small bowel diarrhoea—High volume diarrhoea with uniform watery consistency; colonic diarrhoea—Low volume diarrhoea, the stool usually contains numerous small pieces of faeces.

*** During microscopic examination, a small portion of faeces is taken on the glass slide with the help of a broom-stick and emulsified with a drop of isotonic saline, and lastly coverslip is applied over it *(saline preparation).*

*** *Hanging-drop preparation :* A bit of diluted faecal matter is taken on a coverslip and the coverslip is then inverted on a slide, and examined under a microscope. By this way, darting motility of Vibrio cholerae can be nicely seen.

**** j_n health, osmolality of stool is 290 mosmol/kg of water.

ACUTE AMOEBIC DYSENTERY

Naked-eye examination :

Amount — Relatively copious
Colour — Dark red; faecal matter seen
Consistency — Liquid yellow stool; faecal matter streaked with blood and mucus. Faecal matter is not adherent to the bottom of the container
Odour — Offensive

Chemical examination :

Reaction — Acidic
Orthotoluidine test — ++

Microscopic examination :

RBC	- +, in clumps
WBC	- Very few
Macrophages	- Nil
Eosinophils	- Present
Parasite/cyst	- Trophozoites of E. histolytica, often with ingested RBC
Bacteria	- Few
Pus cells	- Scanty
Epithelia	- Absent
Charcot-Leyden crystals	- Present

Interpretation :

1. Liquid stool mixed with blood and mucus points towards acute dysentery. Infection by some organism is suggested by the presence of offensive odour. Formation of mild inflammatory exudate (pus cells and WBC are scanty) is indicated by the presence of very low fibrin content and thus the stool is not adherent to the container.
2. With the above features, presence of Charcot-Leyden crystals suggest acute amoebic dysentery. Positive orthotoluidine test confirms presence of blood in the stool.
3. Trophozoites (vegetative form) of E. histolytica confirms the diagnosis of acute amoebic dysentery.

Inference :

This is a chart of acute of amoebic dysentery.

DESCRIBE AN AMOEBIC ULCER IN INTESTINE :

Usually superficial (does not extend beyond muscularis mucosae), round or oval, from a pin's head to one inch or more, with ragged and undermined margin having overhanging mucous membrane (appearance of flask-shaped ulcer in vertical section), and the base of the ulcer is filled-up by necrotic material and yellowish slough.

ORGANS INVOLVED IN AMOEBIASIS :

(A) Intestine—Mainly the ileo-caecal region, rarely the sigmoido-rectal region.
(B) Extraintestinal sites—Liver, lung, brain (acanthamoeba and Naegleria fowleri), spleen, skin and cornea (keratitis caused by acanthamoeba).

LABORATORY DIAGNOSIS OF AMEOBIASIS :

(A) Stool examination :

1. Naked-eye examination.
2. Microscopic examination (4-6 specimens should be examined). Microscopic examination of fresh stool or colonic exudate revealed by sigmoidoscopy is the simplest way to diagnose colonic affection by amoebiasis. Motile trophozoites containing RBCs confirm the diagnosis.

(B) Blood examination—May show moderate leucocytosis (in symptomatic patients).

(C) Serological tests :

1. Indirect haemagglutination test.
2. Fluorescent antibody test (for amoeba).
3. Complement fixation test.
4. Elisa (Dot ELISA is often preferred).
5. Counterimmunodiffusion.
6. Agar gel diffusion.

* Remember, the 'trophozoite or vegetative' form of E. histolytica is the infective form, while the 'cystic' form is present in the carriers.

PATHOLOGICAL SITUATIONS WITH 'ULCERS IN INTESTINE' :

Amoebiasis, typhoid fever, tuberculosis, ulcerative colitis, Crohn's disease, malignancy, Zollinger-Ellison syndrome, bacillary dysentery, drug-induced (e.g., entetic-coated potassium tablet), ischaemic colitis and mesenteric artery occlusion (abdominal angina).

PRESENCE OF MUCUS IN THE STOOL :

1. Acute amoebic dysentery, acute bacillary dysentery.
2. Ulcerative colitis.
3. Irritable bowel syndrome.
4. Malabsorption syndrome.
5. Small amount may be present in normal person.

ACUTE BACILLARY DYSENTERY

Naked-eye examination :

Amount — Scanty
Colour — Bright red
Consistency — Liquid, mainly blood, mucus and pus. Scanty faecal matter which is adherent to the bottom of the container
Odour — Non-offensive (odourless)

Chemical examination :

Reaction — Alkaline
Orthotoluidine test — ++

Microscopic examination :

RBC	+++; discrete
WBC	+++
Macrophages	Numerous and many of them have RBC within
Eosinophils	Virtually absent
Parasite/cyst	Absent
Bacteria	Plenty of motile bacteria
Pus cells	Plenty
Epithelia	Present
Charcot-Leyden crystals	Absent

Interpretation :

1. Liquid stool mixed with blood and mucus points towards acute dysentery. Presence of RBC, WBC, pus cells, macrophages indicate massive inflammatory exudate and thus the faecal matter is adherent to the container as a result of high fibrin content.

2. Scanty faecal matter, presence of blood, mucus and pus, and alkaline reaction (as a result of presence of frank blood) are highly suggestive of acute bacillary dysentery. Positive orthotoluidine test confirms presence of blood in stool.
3. Presence of plenty of motile bacteria are probably due to shigella (producing acute bacillary dysentery) or E.coli (may be present normally). Absence of parasite/cyst as well as vegetative form of E. histolytica denies acute amoebic dysentery.
4. Other features are also corroborative of acute bacillary dysentery.

Inference :

This chart deals with acute bacillary dysentery (shigellosis).

COMMON CAUSES OF DYSENTERY (ACUTE DIARRHOEA WITH BLOOD AND MUCUS IN STOOL) :

1. Acute bacillary dysentery (there are four main pathologic strains of Shigella like S. dysenteriae, S. flexneri, S. boydii and S. sonnei).
2. Acute amoebic dysentery (E. histolytica).
3. Infection of large gut by Campylobacter jejuni, Salmonella enteritidis or Yersinia enterocolitica.
4. Enteroinvasive and enterohaemorrhagic E.coli.
5. Dysentery caused by Schistosoma mansoni.
6. Ulcerative colitis, Crohn's disease.
7. Pseudomembranous colitis caused by Clostridium difficile.
8. Mesenteric vascular disease.
9. Intestinal tuberculosis.
10. Diverticulitis.
11. Carcinoma of the large intestine (lower).

INVESTIGATIONS PERFORMED IN CHRONIC LOSS OF BLOOD AND MUCUS IN STOOL :

1. Stool examination (naked-eye and microscopic) with culture and sensitivity.
2. Proctoscopy, sigmoidoscopy/colonoscopy, and barium enema examination.
3. Biopsy of the intestine.

COMPLICATIONS OF ACUTE SHIGELLOSIS :

1. Haemorrhage, perforation, toxic dilatation of colon.
2. Bacteraemia.
3. Endotoxic shock.
4. Haemolytic-uraemic syndrome.
5. Pneumonia, meningitis, seizures (rarely seen).
6. Reactive arthritis and even the full spectrum of Reiter's syndrome.

* Diagnosis of bacillary dysentery depends on isolation of the organism from stool cultures.

** Read the treatment of 'Shigellosis' from the section of 'Emergency medicine'.

Table 17 : Differentiation between amoebic and bacillary dysentery

	Features	Amoebic dysentery	Bacillary dysentery
1.	Number of motions/day	6-8	> 10
2.	Amount	Copious	Small
3.	Colour	Dark red	Bright red
4.	Odour	Offensive	Odourless
5.	Faecal matter	Present	Minimal
6.	Reaction	Acidic	Alkaline
7.	Consistency	Non-adherent to the container	Adherent to the container
8.	RBC	Clumps	Discrete
9.	Pus cells	Scanty	Plenty
10.	Macrophage	Very few	Numerous
11.	Eosinophils	Present	Absent
12.	Charcot-Leyden crystals	Present	Absent
13.	Parasites	E. histolytica	Absent
14.	Bacteria	Nil	Motile bacteria

GIARDIASIS

Naked-eye examination:

Amount	Sufficient for examination
Colour	A bit whitish
Consistency	Greasy
Odour	Offensive

Chemical examination :

Reaction	—	Acidic
Orthotoluidine test	—	-ve

Microscopic examination

RBC	–	Nil
WBC	–	+
Macrophages	–	+
Eosinophils	–	Present
Parasite/cyst	–	Giardia lamblia present
Bacteria	–	Few
Pus cells	–	Absent
Epithdia	–	Absent

Interpretation with inference :

Presence of Giardia lamblia in a specimen of stool which is greasy, a bit whitish and offensive clinches the diagnosis of 'giardiasis'.

DESCRIBE THE CLINICAL FEATURES OF GIARDIASIS :

Commonly it affects the children in endemic areas (tropics), tourists, persons with poor hygiene, immunosuppressed individuals (e.g., IgA deficiency), male homosexuals and persons with achlorhydria. Mode of spread is through faecal-oral route (ingestion of cysts) and the incubation period is 1-3 weeks. The sites of involvement are duodenum and jejunum. The clinical manifestations range from asymptomatic carriage to fulminant diarrhoea and malabsorption. The patient may complain of abdominal pain, anorexia, nausea, vomiting, weakness and loose offensive stools; there may be abdominal tenderness with distension. There is acquired lactose intolerance. These features may continue for weeks or months, and the patient loses weight, becomes lethergic and complains of flatulent dyspepsia.

HOW TO INVESTIGATE THIS PATIENT ?

1. Examination of stool (at 2-3 days "interval on 3 seperate occasions) for cysts.
2. Doudenal or jejunal fluid is aspirated through Ryle's tube or endoscope, and examined for parasites/cyst.
3. Jejunal biopsy (the mucus should be examined fresh)—shows G. lamblia over the surface of the epithelium.
4. Tests to detect G. lamblia antigen in the stool—may be done.
5. Other investigations to exclude different causes of malabsorption (e.g., tropical sprue, coeliac disease).

TREATMENT:

1. Single dose of tinidazole 40 mg/kg in the range of 0.5-2 g, may be repeated after 1 week, or
2. Metronidazole 2 g daily for consecutive 3 days, or
3. Quinacrine hydrochloride 0.1 g, thrice daily for 5 days.

OCCULT BLOOD IN STOOL

Naked-eye examination :

Amount	Sufficient for examination
Colour	Yellowish
Consistency	Semisolid
Odour	Faecal odour

Chemical examination :

Reaction —

Haemoccult test —

Microscopic examination :

RBC, WBC, macrophages - Absent

Ova, parasite, cyst - Absent

Interpretation :

All the features indicate normal stool except the presence of positive haemoccult test. As the colour and consistency of the stool is not black, tarry, and the odour is not very offensive, it is not the stool of melaena. So there is presence of occult blood in stool specimen.

Inference :

This is a chart of stool containing occult blood.

COMMON CAUSES OF OCCULT BLOOD IN STOOL :

1. Chronic duodenal or gastric ulcer.
2. Erosive gastritis (commonly from NSAID, corticosteroids).
3. Variceal bleeding.
4. Carcinoma of the stomach.
5. Hookworm infestation.
6. Colo-rectal malignancy.
7. Mesenteric ischaemia.
8. Angiodysplasia of the colon.

* Intake of NSAID, hookworm infestation and colo-rectal cancer are common causes of occult blood in stool.

DESCRIBE STOOL OF MELAENA (ALTERTED BLOOD IN STOOL) :

1. Black tarry stool (due to production of acid haematin); sticky too.
2. Offensive (acid haematin is alteread by bacteria).
3. Semisolid in consistency.
4. Red-coloured fluid comes out from the stool after addition of water in it.
5. Usually associated with vertigo, dizziness or syncopal attack during defecation.

* Approximately 60 ml of blood is required to produce a single black stool and blood should remain for at least 8 hours within the gut lumen to produce melaena.

IN WHICH FORMS BLOOD MAY BE PRESENT IN THE STOOL ?

1. Frank blood or haematochezia.
2. Altered blood or melaena.
3. Invisible or occult blood (detected chemically).

PREREQUISITES FOR OCCULT BLOOD TEST IN STOOL (GUAIAC TEST; :

As bleeding from G.I. tract may be intermittent, the test should be performed for several (usually three) consecutive days.

1. To avoid false-positive results, 3 days high-fibre and meat-free diet is advocated.
2. To avoid false-negative result, patient should not have been taking vitamin C.
3. NSAID should not be taken (may produce erosive gastritis). Tooth-brush may be avoided for 3 days. *Medicinal iron should be stopped.*

* In modem haemoccult test, medicinal iron does not interfere with the test. Upto 2.5 ml of 'normal' faecal blood loss may be measured by radioactive chromium.

HOW DO YOU PROCEED TO DIAGNOSE A CASE WITH POSITIVE OCCULT BLOOD IN STOOL ?

1. Details history taking (intake of NSAID, anorexia for gastric malignancy etc.) and meticulous clinical examination (degree of iron deficiency anaemia suggests the duration of illness, lymphadenopathy to exclude carcinoma, abdominal mass indicating G.I. malignancy, splenomegaly for portal hypertension).
2. Stool examination for hookworm ova/parasite.
3. To diagnose the site of blood loss sigmoidoscopy, colonoscopy or barium enema should be followed by upper G.I. endoscopy.

4. Barium follow-through examination of the G.I. tract.
5. If diarrhoea or steatorrhoea is present, investigations for malabsorption is performed.
6. USG or CT scan of whole abdomen.
7. Angiography; radiolabeled erythrocyte scanning.

* Digital examination, proctoscopy and sigmoidoscopy are important manoeuvres/investigations in the aetiological diagnosis of haematochezia.

CHARTS ON URINE

PREFACE:

(A) *Routine examination (R/E)* of urine consists of :

I. Naked-eye examination, macroscopic examination or physical examination :

a) Volume or quantity per day
b) Colour and transparency
c) Odour
d) Specific gravity

Chemical examination :

a) Reaction or p^H
b) Proteins
c) Sugars
d) Ketone bodies
e) Blood and haemoglobin
0 Bile pigments and bile salts

Microscopic examination :

a) RBC
b) WBC and pus cells
c) Epithelial cells
d) Casts
e) Crystals
f) Microorganism, spermatozoa

* For microscopical examination, urine is centrifused at a speed of 1000-1500 rpm. for at least 3 minutes, and the deposit is examined under microscope.

(B) *Special examination* of urine consists of :

Culture and sensitivity tests (bacteriological examination) : > 100 000 bacteria/ml of mid-stream urine indicates urinary tract infection. Antibiotic sensitivity is known as 'antibiogram'.

Each component is discussed below in a nutshell :

1. Volume of urine in 24 hours ; The normal daily urinary output is 400 ml-3 litres, depending on the fluid intake. Average output in a healthy adult is 1.5 litre per day. Urine volume < 400 ml per day is **oliguria** and no urine formation for 12 hours is **anuria,** while **polyuria** is urinary output > 3 litres per day.
2. Colour and transparency : Normally fresh urine is clear to straw-yellow coloured. The colour varies from person to person and from day to day. Colour changes may occur in diseases or after ingestion of drugs, like—
   a) Red—Blood, haemoglobin, myoglobin, ingestion of beet roots, phenolpthalein in alkaline medium, drug like penazopyridine, and porphobilinogen (porphyria).
   b) Pink or dark orange—Rifampicin, senna.
   c) Milky white—Chyluria.
   d) Black—Alkaptonuria (darkens on standing due to presence of homogentisic acid), intake of methyl dopa, iron therapy (I.M), melanoma (melanogen), tyrosinosis.
   e) Yellowish-brown—Furazolidone, nitrofurantoin, tetracyclines, riboflavin, sulfasalazine.
   f) Greenish—Pseudomonas infection in urine, durgs (amitriptyline, methylene blue, propofol).
   g) Cloudy—Presence of pus, blood, cellular debris or crystals (phosphates or urates).

* *The colour of the normal urine is given by urochrome and uroerythrin. Normally urine darkens* on *standing because of oxidation of colourless urobilinogen to coloured urobilin.*

3. Odour : Normally urine has ammoniacal smell due to bacterial decomposition. E.coli infection gives rise to fishy smell, and smell of acetone may come out from the urine of a pateint having diabetic ketoacidosis; diabetics have 'fruity' odour in their urine.
4. Specific gravity : Minimally 50 ml of urine is required to measure the specific gravity. The specific gravity varies from 1002-1035 in a healthy person, depending on the state of hydration. Usually it is within 1015-1025, signifying *normal tubular ability* for concentrating urine. Normal osmolality of urine is 400-750 mosmol/kg of water.

   Very high specific gravity—Diabetes mellitus, severe dehydration, massive proteinuria.

   Very low specific gravity—Diabetes insipidus, psychogenic polydipsia.

   Fixed specific gravity at 1010 — End-stage renal disease.
5. Reaction or p^H : Normal urine is nearly always acidic in reaction (p^H 5-7.2). If the urine reaction repeatedly becomes neutral or alkaline, think of consumption of alkali, alkalosis, loss of tubular function to eliminate acid, patient on high vegetarian diet or UTI by organism other than E.coli (specially Proteus).
6. Protein : Presence of protein in urine signifies defect in the *glomerular Junction.* Normal adult may excrete upto 150 mg of protein in 24 hours. Proteinuria can be divided into mild (150-500 mg/day), moderate (500 mg-2 g/day) and massive types (> 2 g/day). Proteinuria is in the 'nephrotic range' when crosses 3.5 g/day.

   Proteinuria is divided into selective (steroid-responsive) and non-selective types.

   Selectivity is estimated by comparing the clearance of IgG with that of transferrin. If the clearance of IgG is > 20% of transferrin, it represents 'non-selective' proteinuria. If the value is < 10%, it indicates 'highly selective' proteinuria. The range between 10-20% is of little discriminatory value. 'Highly selective' proteinuria is found in minimal lesion nephropathy. The degree of selectivity gives an indication of the amount of glomerular damage.
7. Sugars ; Several reducing sugars may be found in urine sample (glucose, lactose, fructose, pentose, galactose) of which glucose is the most improtant. Presence of glucose in urine is known as glycosuria (e.g., alimentary glycosuria, renal glycosuria, diabetes mellitus). Sucrose is a non-reducing sugar.
8. Ketone bodies ; Ketone bodies are acetone, acetoacetic acid and p-hydroxybutyric acid. Ketone bodies may be found in urine in conditions like starvation, diabetic ketoacidosis, severe vomiting, diet enriched in fat and very low in carbohydrate, acute hepatic necrosis, and in alcoholic ketoacidosis.
9. Blood and haemoglobin : Haematuria.
10. Bile pigments and bile salts : In jaundice.
11. RBC ; Normal urine contains < 1 red cell per high power field (HPF) of centrifuged urine and not more than 3 red cells/mm^3 of uncentrifuged urine. Urine collection in menstruating female petients should be done cautiously to avoid contamination. Patients on anticoagulant therapy may have RBC in urine.
12. WBC : Normally uncentrifuged urine in men may contain < 3 leucocytes/HPF and females may have <10 leucocytes/HPF. If number of WBC is increased above the aforesaid level, think of urinary tract infection (UTI), renal calculi, renal tuberculosis, and send the urine for culture and sensitivity tests.

    A positive leucocyte esterase test results from the presence of WBC either as whole cells or as lysed cells. A negative test means that UTI is unlikely.

    Even a single eosinophil in urine reflects interstitial nephritis.
13. Epithelial cells : Size and shape of the cells often indicate the site of origin but otherwise they are not of much significance. Normal uncentrifuged urine contains not more than 3 cells/HPF.
14. Casts : Casts are coagulated protein (inside the tubules) and their presence indicate that the proteinuria has its origin in the kidney. Hyaline casts (the basic cast) are found in normal persons or in heavy proteinuria, RBC cast in acute glomerulonephritis, fatty cast in nephrotic syndrome, and granular cast may signify acute or chronic inflammation of the kidney (usually CRF).
15. Crystals : Calcium oxalate crystals are often found in normal acidic urine and tripple phosphate (ammonium magnesium phosphate) may be present in alkaline urine. Uric acid and

urates, cysteine, leucine and tyrosine crystals may be found in acidic urine. Usually crystals are of no pathological significance.

* Read proteinuria, haematuria, anuria, oliguria, polyuria from 'Bedside Clinics in Medicine, Part I'.

CHEMICAL EXAMINATION OF URINE :

1. Test for protein (Heat coagulation test) :

Three-fourth of a test tube is filled-up with the urine. Now holding the bottom, incline the test tube slightly and boil the top 2 cm over a flame. A white cloudy precipitate indicates the presence either of protein or of phosphates. On addition of 10% acetic acid drop by drop, the precipitate due to phosphates disappear; if it persists on adding 10% acetic acid, it is precipitated protein.

2. Test for sugar (Benedict's test) :

(This is not a specific test for glucose and any reducing substance like lactose, pentose, fructose or galactose present in the urine sample gives positive reaction).

5 ml of Benedict's reagent is taken in a test tube. It is heated to boiling point and then allowed to cool. To It, 8 drops of urine Is added. The test tube is now boiled for 2 minutes and then allowed to cool in running tap water. If the urine sample does not contain sugar, the colour of the solution remains unchanged (blue) but a precipitate appears in the presence of reducing substance (sugar), varying from light green turbidity—green precipitate—yellow precipitate—to brick red precipitate (these colour changes of precipitates indicate the approximate concentration of sugar as 0.1 tc 0.5 g/dl—0.5 to 1.0 g/dl—1.0 to 2.0 g/dl—to 2.0 g/dl or more, respectively).

3. Test for ketone bodies (Rothera's test) :

10 ml of urine is taken in a test tube and saturated with ammonium sulphate by adding excess of Its crystals. Then 3 drops of freshly prepared solution of sodium nitroprusside Is added to It. Now 2 ml of strong ammonia solution is poured very gently by the side of the inclined'test tube. A deep purple ring appears at the junction of the two fluids if the urine sample contains ketone bodies. If ketone bodies are absent, Rothera's test becomes negative.

* (Ketone bodies are acetone, acetoacetic acid and (3-hydroxy butyric acid. Positive Rothera's test Is given by the first two Ingredients and not by p-hydroxybutyric acid).

4. Test for bile salts (Hay's surface tension test) :

10 ml of urine Is taken in a clean test tube and finely powdered sulphur particles are sprinkled over it. If the urine sample contains bile salts, sulphur powder sinks at the bottom of the test tube but the sulphur powder remains on the surface of the urine if the sample does not contain bile salts.

* (Bile salts lower surface tension and hence cause sulphur powder to sink).

5. Test for blood :

a) Benzidine test — 2-3 ml of urine sample is mixed with an equal amount of saturated solution of benzidine In glacial acetic acid. Now, hydrogen peroxide Is added to the mixture when a blue colour denotes the presence of blood.

b) Orthotoluidine test — Similar to benzidine test; here, instead of benzidine in glacial acetic acid, 0.5 ml of 1% orthotoluidine solution In glacial acetic acid is used.

ACUTE GLOMERULONEPHRITIS

Naked-eye examination :

Quantity	—	350 ml/24 hrs.
Colour	—	Smoky
Specific gravity	—	1028

Chemical examination :

pH	**6.6**
Albumin	++
Blood	++
Sugar	Nil
Ketone bodies	Nil
Bile	Nil

Microscopic examination :

RBC	- Plenty in number
WBC/pus cells	- 2/HPF
Casts :	
Hyaline cast	- +
RBC cast	- ++
Epithelial cast	- + '
Bacteria	- Nil
Crystals	- Nil

Interpretation :

1. Quantity indicates oliguria (< 400 ml/24 hrs). Smoky urine points towards microscopic haematuria. High specific gravity reflects normal functioning renal tubules.
2. Moderate proteinuria (glomerular dysfunction), RBC and RBC casts (inflammatory basis of the disease process), presence of blood (injury to glomerulus) suggest acute glomerulonephritis. Presence of pus cells may reflect an inflammatory procedure.

Inference :

Presence of,

1. Oliguria,
2. Smoky urine,
3. RBC and RBC cast, and
4. Moderate albuminuria, all together confirm the diagnosis of acute glomerulonephritis (AGN).

HOW WILL YOU ASSESS THE 'RENAL FUNCTION' IN A PATIENT ?

(A) The **'glomerular function'** is assessed by :

a) Glomerular filtration rate (GFR)—The usual GFR in average adult is near about 120 ml/minute. Glomerular function is best assessed by renal clearance, where clearance C = UV + P; now, U and P are respectively the urinary and the plasma concentration of a specific substance, and V is the urine volume formed per minute. Classically the substance used are inulin or ^{51}Cr-EDTA but practically the clearance of creatinine is used in clinical practice.

Calculation of *creatinine clearance (CCr)* may be done by (ml/min) * :

$$\text{CCr (male)} = \frac{(140 - \text{age}) \times \text{body weight (in kg)}}{\text{Serum creatinine (mg/dl)} \times 72}$$

CCr (female) = 0.85 x CCr (male)

* This is 'Cockcroft-Gault equation' of CCr

b) Serum concentration of urea and creatinine (normal level of urea and creatinine are respectively 20-40 mg/dl and 0.6-1.2 mg/dl).

c) Glomerular damage is often indicated by significant proteinuria.

(B) The **'tubular function'** is assessed by :

a) Change in the urinary specific gravity by water deprivation test or administration of vasopressin.

b) Renal acidifying ability is judged by ammonium chloride test.

c) Conservation of electrolytes after administration of fludrocortisone.

COMMON COMPLICATIONS OF ACUTE GLOMERULONEPHRITIS :

1. Acute renal failure (ARF).
2. Hypertensive encephalopathy.
3. Acute left ventricular failure (LVF).
4. Infections — Urinary tract, respiratory tract etc.

TYPES OF ARF :

ARF is of two types : oliguric and non-oliguric.

(A) 'Oliguric'—has three phases like,

a) Oliguric phase (1-2 weeks),

b) Diuretic phase (1 week), and

c) Recovery, phase (2-3 weeks).

(B) 'Non-oliguric'—having features like,

a) No oliguria. Usually the urine output is > 1 litre/day.
b) Low urinary osmolality e.g., 350 mosmol/kg of water.
c) 25-50% patients of ARF suffer from non-oliguric type.
d) Diuretic phase is usually short (average. <1 week).
e) Dyselectrolytaemia is less common.
f) Progressive rise in urea and creatinine level.

* **Acute renal failure** (ARF) is a syndrome mainfested by abrupt deterioration of renal function with rapid decline of GFR (within hours to days) with retention of nitrogenous waste products and disturbance of extracellular fluid balance, electrolyte, and acid-base homeostasis, which is usually reversible within days or weeks.

METABOLIC ALTERATIONS IN ARF :

(A) Increased serum concentration of urea, creatinine, potassium, magnesium, phosphate, uric acid, H^+ concentration and fluid volume. Though there is sodium retention, increased fluid volume leads to dilutional hyponatraemia.

(B) Low serum level of calcium.

* Read AGN in details from 'Bedside Clinics in Medicine, Part I'.

NEPHROTIC SYNDROME

Naked-eye examination :

Quantity	—	1500 ml/24 hrs.
Colour	—	Clear
Specific gravity	—	1016

Chemical examination :

p^H	-	6.4
Albumin	-	+++
Blood	-	Nil
Sugar	-	Nil
Ketone bodies	-	Nil
Bile	-	Nil

Microscopic examination :

RBC	-	Nil
WBC/pus cells	-	1 / HPF
Casts :		
Hyaline cast	-	+
RBC cast	-	Absent
Fatty cast	-	++
Bacteria	-	Nil
Crystals	-	Nil

Interpretation :

1. Quantity, colour and specific gravity of urine shows no abnormality.
2. Massive proteinuria points the disease process towards nephrotic syndrome.
3. Hyaline cast may be a normal finding but presence of fatty cast (glomerular dysfunction) is highly suggestive of nephrotic syndrome.

Inference :

Presence of,

1. Macroscopically normal urine,
2. Massive albuminuria, and
3. Fatty cast, all together suggest the diagnosis of nephrotic syndrome.

DEFINE NEPHROTIC SYNDROME :

It is a clinical syndrome characterised by,

a) Massive proteinuria (albuminuria),

b) Hypoalbuminaemia (hypoproteinaemia),
c) Generalised oedema or anasarca, and
d) Hyperlipidaemia (hypercholesterolaemia).

* Proteinuria > 3.5 g/1.73 m^2 per day is considered to be in the nephrotic range. Normal body surface for a reference man is 1.73 m^2. According to few clinicians, lipiduria and hypercoagulability are new additions in the clinical complex of nephrotic syndrome.

** *Proteinuria is the hallmark of nephrotic syndrome.*

CLASSIFY PROTEINURIA :

Mild — 150-500 mg/day (+)
Moderate — 500 mg-2 g/day (++)
Massive — >2 g/day (+++); if the amount crosses 3.5 g/day, it is designated as 'nephrotic range'.

* Normally, upto 150 mg of protein may be excreted in 24 hours. Proteinuria often makes the urine frothy.

LIPIDS ALTERATION IN NEPHROTIC SYNDROME :

All types of lipid fraction are altered in nephrotic syndrome. Total cholesterol (both free and ester form), triglyceride, phospholipid and even chylomicron levels are elevated. Free fatty acid levels are usually reduced. LDL, VLDL are increased but HDL level may be normal, elevated or diminished (low HDL level is associated with severe nephrotic syndrome). Lipiduria is common and it is why fatty casts in urine are a characteristic feature.

WHY THE PATIENT SUFFERS FROM ANASARCA ?

Fluid comes out from the vascular compartment (due to low oncotic pressure as a result of hypoproteinaemia) into the tissue spaces and makes the patient oedematous.

* Read 'Nephrotic syndrome' from 'Bedside Clinics in Medicine, Part I'.

CHRONIC GLOMERULONEPHRITIS OR CHRONIC KIDNEY DISEASE

Naked-eye examination :	
Quantity	4 litre/24 hrs.
Colour	Clear
Specific gravity	1010
Chemical examination :	
pH	**6.2**
Albumin	+
Blood	Nil
Sugar	Nil
Ketone bodies	Nil
Bile	Nil
Microscopic examination :	
RBC	Nil
WBC/pus cells	2/HPF
Casts :	
Hyaline cast	+
RBC cast	Absent
Granular cast	**++**
Bacteria	Nil
Crystals	Nil

Interpretation :

1. Quantity indicates polyuria (> 3 litre/24 hrs). Specific gravity is lower than normal (1015-1025) indicating tubular dysfunction.
2. Presence of proteinuria may suggest glomerular dysfunction.

3. p^H is normal. Other biochemical findings are within normal limit.
4. Presence of granular cast suggests chronic glomerulonephritis i.e., renal parenchymal involvement.

Inference :

Presence of,

1. Low specific gravity at 1010.
2.. Albuminuria, and
3. Granular cast, all together suggest chronic glomerulonephritis [or chronic kidney disease (CKD)].

As the chart shows,

4. polyuria, it may be concluded that chronic glomerulonephritis has progressed to chronic renal failure (CRF).

* 'Broad casts' (casts of unusual width presumed to arise from dilated tubules) are often found in CRF.

WHY THE SPECIFIC GRAVITY IN CRF IS FIXED AT 1010 ?

Normally, the concentration of the urine (reflected by specific gravity) changes from time to time. As the patient progresses to CRF, the kidneys lose their ability to concentrate and dilute the urine; thus the specific gravity becomes lower, and approximates more and more to 1010, i.e., equivalent to the specific gravity of the glomerular filtrate. Thus, ultimately the urine becomes isotonic with plasma water (isosthenuria).

DIFFERENT CASTS IN URINE :

1. Hyaline cast - Normal persons, pyrexia, strenuous exercise, heavy proteinuria, concentrated urine, dehydration.
2. RBC cast - Acute glomerulonephritis.
3. Fatty cast - Nephrotic syndrome.
4. Granular cast - Chronic glomerulonephritis, may be non-specific.
5. WBC cast - Pyelonephritis, interstitial nephritis, transplant rejection.
6. Broad cast - Chronic renal failure.
7. Crystals In cast - Hypercalcaemia, hyperuricosuria.

CAUSES OF CRF :

1. **Chronic glomerulonephritis.**
2. **Malignant hypertension.**
3. **Diabetes mellitus.**
4. **Chronic pyelonephritis.**
5. **Nephrotic syndrome.**
6. **Polycystic kidney disease.**
7. **Collagen vascular diseases (e.g., SLE, scleroderma).**
8. **Obstructive uropathy.**
9. **Interstitial nephritis.**
10. **Analgesic nephropathy.**
11. **Gout, multiple myeloma, amyloidosis.**

* **Chronic renal failure (CRF) refers to long-standing, progressive and irreversible deterioration in renal function.**

CRF WITH ENLARGED KIDNEYS :

1. **Polycystic kidney.**
2. **Hydronephrosis (bilateral).**
3. **Diabetes mellitus with CRF.**
4. **Amyloidosis.**
5. **Multiple myeloma.**

* **CRF patients usually have bilateral small and contracted kidneys.**

Table 18 : Stages of chronic kidney disease (CKD)

Stage	Description	GFR (ml/min/1.73 m^2)
1	Kidney damage with normal or T GFR	> 90
2	Kidney damage with slightly *I* GFR	60-89
3	Moderalely 4- GFR	30-59
4	Severe i GFR	15-29
5	Kidney failure	< 15 (or dialysis)

* **Stage 5 Is *known* as end-stage renal disease (ESRD)**

MENTION THE COMMON COMPLICATIONS/ABNORMALITIES SEEN IN CRF ;

1. Haematologic and immunologic :
   a) Refractory anaemia.
   b) Lymphocytopenia; abnormality in WBC formation and function.
   c) Bleeding tendency.
   d) Increased susceptibility to infection.
2. G. I. tract :
   a) Uraemic fetor.
   b) Uraemic gastritis (nausea, vomiting).
   c) Peptic ulcer and G. I. tract haemorrhage.
   d) Ascites.
3. Cardio-pulmonary :
   a) Systemic hypertension.
   b) Acute left ventricular failure.
   c) Accelerated atherosclerosis.
   d) Pericarditis.
   e) Uraemic lung (pulmonary oedema).
4. Neuromuscular :
   a) Peripheral neuropathy.
   b) Convulsions.
   c) Coma.
   d) Flapping tremor.
   e) Encephalopathy.
   n Myopathy.
   g) 'Restless leg syndrome'.
   h) Dialysis dementia and dialysis disequilibrium syndrome (dialysis-induced).
5. Endocrine and metabolic :
   a) Secondary hyperparathyroidism.
   b) Renal osteodystrophy.
   c) Hyperuricaemia.
   d) Amenorrhoea, loss of libido, infertility.
6. Fluid and electrolytes :
   a) Metabolic acidosis.
   b) Hypocalcaemia.
   c) Volume contraction from polyuria. Na^+ level may be high, normal or low.
   d) K* level is usually high.
   e) Oedema.
7. Dermatological :
   a) Pallor.
   b) Hyperpigmentation.
   c) Ecchymosis.
   d) Generalised pruritus.
   e) Uraemic frost.

ANAEMIA IN CRF:

Anaemia in CRF is due to :

1. Decreased erythropoiesis due to relative deficiency of erythropoietin.
2. Reduced dietary intake due to loss of appetite.
3. Decreased red cell survival.
4. Diminished erythropoiesis due to uraemic toxins.
5. Reduced intestinal iron absorption.
6. Increased blood loss due to abnormal platelet function and increased capillary fragility.
7. Hypoproteinaemia leading to decreased transferrin level.
8. Vitamin B_{12} and folic acid deficiency.

OUTLINE OF TREATMENT IN RENAL FAILURE :

Renal replacement therapy is done by haemodialysis/haemofiltration, peritoneal dialysis and renal transplantation.

(A) Acute :
   a) Conservative treatment.
   b) Continuous arterio-venous or veno-venous haemofiltration.
   c) Haemodialysis.
   d) Peritoneal dialysis.

(B) Chronic :
   a) Conservative treatment.
   b) Haemodialysis.
   c) Continuous ambulatory periotoneal dialysis (CAPD).
   d) Renal transplantation.

D/D BETWEEN ARF AND CRF AT THE BEDSIDE :

A provisional diagnosis may be done by,

1. History (short in ARF and prolonged in CRF; ARF is often precipitated by diarrhoea, snake bite, septic abortion, pre-eclampsia or drugs (e.g., aminoglycosides)].
2. Patient is bloated (oliguric phase of ARF); patient of CRF is usually volume depleted from polyuria.
3. Severe anaemia clinches the diagnosis of CRF.
4. Though systemic hypertension may be present in both the types, target organ damage due to hypertension is evident in CRF only, e.g.,
   a) Cardiomegaly,
   b) Retinopathy,
5. Presence of bone pain (renal osteodystrophy) and peripheral neuropathy suggest CRF.
6. Ultrasonography shows bilateral contracted kidneys with loss of cortico-medullary differentiation in CRF; kidneys are usually of normal size in ARF.
7. A very rapid rate of rise in serum urea and creatinine suggests ARF. A report of previous urinalysis (normal in ARF) is also helpful for diagnosis.

* Acute on chronic renal failure' is precipitated by infection, obstruction (stone, blood clot), dehydration and nephrotoxic drugs (e.g., aminoglycosides).

INDICATIONS OF DIALYSIS IN ARF OR CRF :

1. Progressive metabolic encephalopathy.
2. Uncontrolled hyperkalaemia.
3. Intractable overload of fluid.
4. Uraemic pericarditis (most important clinical indicator).
5. Very high urea (usually above 300 mg/dl) and creatinine (usually above 7 g/dl) levels.
6. Creatinine clearance <15 ml/minute.
7. Refractory metabolic acidosis (p^H < 7.2), pulmonary oedema not responding to medical treatment, high catabolic state with rapidly progressive renal failure, significant bleeding diathesis, hypertension poorly-responsive to non-dialytic therapy.

N.B. : Most useful marker of renal function is serum creatinine as it is primarily eliminated by glomerular filtration. Blood urea is modified independent of renal function e.g., t **urea or BUN** is seen in high protein diet, catabolic states, G. I. bleeding, and i **urea or BUN** is observed in liver disease, malnutrition etc.

URINARY TRACT INFECTION

Naked-eye examination

Quantity	—	1600 ml/24 hrs.
Colour	—	Cloudy
Odour	—	Fishy
Specific gravity	—	1016

Chemical examination :

pH		6.1
Albumin		Trace
Blood		Nil
Sugar	-	Nil
Ketone bodies	-	Nil
Bile		Nil

Microscopic examination :

RBC	–	2/HPF
WBC/pus cells	–	40/HPF
Casts	–	Nil
Bacteria	–	Few motile organism
Crystals	–	+

Interpretation :

1. Parameters in macroscopic examination reveals fishy odour which probably reflects the presence of sulphides in urine as a result of urinary tract infection (UTI), and cloudy appearance as a result of plenty of pus cells.
2. Trace protenuria may be a normal finding or due to UTI. p^H reflects the acidic reaction of urine.
3. The presence of plenty of pus cells, few RBC and moreover few motile bacteria indicate an inflammatory basis of the disease process.
4. Presence of motile bacteria (commonly due to E.coli) along with plenty of pus cells suggest urinary tract infection.

Inference :

Urinary tract infection (UTI) probably due to E. coli.

REACTION IN URINE :

(A) Acidic :
   a) Commonly a normal finding.
   b) Urinary tract infection with E. coli.
   c) Acidification of urine done by vitamin C or NH_4C1.
   d) Acidosis (e.g., diabetic ketoacidosis, uraemia).

(B) Alkaline :
   a) Consumption of alkali.-
   b) Alkalosis.
   c) Urinary tract infection with Proteus.
   d) Loss of tubular function to eliminate acid (e.g., renal tubular acidosis).
   e) Patient is on high vegetarian diet.

ORGANISMS RESPONSIBLE FOR UTI:

1. E. coli (commonest; found in 75% cases; usually derived from faecal reservoir).
2. Streptococci.
3. Staphylococcus epidermidis.
4. Klebsiella.
5. Proteus.
6. Pseudomonas.
7. Chlamydia trachomatis.
8. Enterobacter.
9. Serratia
10. Candida (rare).

* Outside hospital — E.coli is commonest; nosocomial infection - Klebsiella, streptococci, E. coli.

PREDISPOSING FACTORS IN UTI :

1. Obstructive uropathy, renal stone, self-retaining catheter, neurological disorders (e.g., spinal cord injury), cystic kidney, vesico-ureteric reflux, impaired renal function.
2. Impaired body resistance due to diabetes mellitus, immunodeficiency, immunosuppressive therapy.
3. Females are more susceptible to males because of short length of urethra (4 cm), close proximity of urethra with anus, pregnancy (chance of retention), absence of bactericidal prostatic secretions, and urethral trauma during sexual intercourse.

TYPES OF UTI:

(A) Lower tract infection : Urethritis, cystitis and prostatitis.
(B) Upper tract infection : Acute pyelonephritis.

INVESTIGATIONS TO BE PERFORMED IN SUSPECTED UTI:

1. Routine examination (R/E) of urine.
2. Urine for culture and sensitivity test (C/S) along with colony count.
3. Blood for TC, DC, ESR.
4. Blood for sugar (fasting and postprandial), urea and creatinine.

5. Ultrasonography (USG) to exclude calculi, cyst, obstruction, congenital anomaly, anatomical abnormality. Now-a-day USG is preferred to IVP.
6. IVP, micturating cysto-urethrography and cystoscopy in selected cases.

WHAT SHOULD BE THE 'COLONY COUNT' IN A SYMPTOMATIC UTI ?

Golony count = Number of bacteria present per millilitre of urine sample examined.

Demonstration of > 100000 organism/ml grown from a properly collected mid-stream 'clean catch' urine sample strongly suggests infection (100000 organism = 10^5 organism).

Usually, colony count < 10000/ml does not signify any infection but there is no absolute rule of thumb regarding the colony count as in a symptomatic patient, a smaller number of bacteria (1000 to 10000/ml of mid-stream urine) may indicate infection.

CLINICAL FEATURES OF UTI:

(A) Urethritis : Burning pain during micturition (due to acid reaction of urine), increased frequency of micturition, dysuria.

(B) Cystitis : Dysuria, increased frequency, urgency, strangury (due to spasm of the internal sphincter), haematuria, incontinence or retention of urine, suprapubic pain and tenderness. Renal angles may be tender in ascending infection to kidneys.

(C) Systemic : Fever with chill and rigor, nausea, vomiting.

* In febrile UTI in male : think of acute epididymitis, acute prostatitis, or acute pyelonephritis.

WHAT IS ACUTE URETHRAL SYNDROME' ?

When dysuria, urgency and increased frequency of micturition are not accompanied by significant bacteriuria, it is known as acute urethral syndrome. It is commonly seen in women. Antibiotics are usually not indicated.

HOW TO COLLECT URINE FOR CULTURE AND SENSITIVITY TEST ?

Mid-stream urine is taken for examination in both the sexes. First, clean the external genitalia with distilled water and then collect the urine aseptically in a sterile container after discarding the first part of urine. Do not touch the container in the genitalia, particualrly in case of female patients. In a special situation, catheterised specimen or urine collected by suprapubic puncture may be taken for examination.

WHAT ARE THE DIFFERENT TYPES OF 'URINARY PAIN' ?

1. Renal pain—It is dull aching or boring in character, and present in the flanks or renal angle and extends along the rib margin towards the umbilicus. It is usually due to distension or irritation of renal capsule (e.g., AGN or big oxalate stone in the kidney).
2. Ureteric pain—If is acute, severe, colicky in nature and often associated with nausea, vomiting, chill and rigor, excessive perspiration and rigidity of abdominal muscles. Ureteric pain is due to smooth muscle spasm or distension.
   a) High ureteric pain—characteristically radiates to groin, testicles (or vulva) and inner aspect of thigh (i.e., along distribution of genitofemoral nerve, L_2).
   b) Mid uretric pain—usually felt in the lower quadrant of the abdomen on the affected side; may radiate upto groin.
   c) Low ureteric pain—Felt deep into the pelvis.
3. Vesical pain—It is usually due to overdistension of a normal bladder, A dull aching pain is felt in the hypogastrium which is relieved by micturition. A stone impacted in the intramural part may have referred pain to the tip of the penis.

COMPLICATIONS OF ACUTE AND CHRONIC PYELONEPHRITIS :

(A) Acute pyelonephritis :
1. Acute papillary necrosis.
2. Septicaemia.
3. Chronic pyelonephritis.
4. Chronic renal failure.

(B) Chronic pyelonephritis :
1. Hypertension.
2. CRF.
3. Pyonephrosis.
4. Renal calculi.

CAUSES OF INCREASED FREQUENCY OF MICTURITION :

1. Cystitis, urethritis, small contracted bladder, vesical calculus, benign hypertrophy of prostate.
2. Balanitis, pinhole meatus, phimosis.
3. Polyuric conditions, pregnancy, psychogenic, pressure in the bladder from adjacent structures.

* Diabetics also suffer from increased frequency of micturition to clean-up the polyuria or as a complication of UTI.

CAUSES OF STERILE PYURIA (PYURIA ASSOCIATED WITH STERILE CULTURE) :

1. Incompletely treated UTI.
2. Infections e.g., M. tuberculosis.
3. Calculi.
4. Interstitial nephritis.
5. Chemical cystitis.
6. Prostatitis.
7. Papillary necrosis.
8. Analgesic nephropathy.
9. Pregnancy.
10. Glucocorticoid therapy.

DIABETIC KETOACIDOSIS

Naked-eye examination:

Quantity — 3800 ml/24 hrs.
Colour — Clear
Odour — Smell of acetone
Specific gravity — 1038

Chemical examination :

p^H - 4.9
Albumin - +
Blood - Nil
Sugar - +++
Ketone bodies - +++
Bile - Nil

Microscopic examination :

RBC - Nil
WBC/pus cells - 2/HPF
Casts - Hyaline cast present
Bacteria - Nil
Crystals - Nil

Interpretation :

1. The chart reflects polyuria and high specific gravity as well as smell of acetone in the macroscopical examination of urine.
2. Reaction of urine is acidic. Ketonuria associated with glycosuria virtually diagnostic of diabetic ketoacidosis. Mild proteinuria indicates development of early diabetic nephropathy.
3. Microscopical examination is within normal limit, except the presence of hyaline cast (indicate glomerulopathy).

Inference :

It is a chart of diabetic ketoacidosis in a patient of early diabetic nephropathy.

DEFINITION OF DIABETIC NEPHROPATHY :

It is the presence of persistent proteinuria (> 500 mg protein/24 hrs; > 300 mg albumin/24 hrs) in a patient sufferring from diabetes mellitus in the absence of other renal disease, UTI or heart failure. Diabetic nephropathy (microvascular complication) includes all the lesions occuring in the kidneys of patients suffering from DM (e.g., glomerulosclerosis, interstitial nephritis etc.)

WHAT IS MICROALBUMINURIA ?

By convention, it is defined as urinary albumin excretion ratio (UAER) between 20-200 pg/min (i.e., 30-300 mg/day) in an overnight or 24-hour urinary collection demonstrated in at least 2-3 occasions within a period of 6 months. Microalbuminuria in diabetes mellitus usually develops around the 5th-10th year. *In type 1 DM, it is an early predictor of nephropathy and in type 2 DM, it usually predicts future development of malignant angiopathy and cardiovascular complications.* It is measured by radioimmunoassay. Microalbuminuria responses well with drugs like ACE-inhibitors.

Instead of 24-hours urine collection, a random sample is used in clinical practice where albumin concentration is related to urinary creatinine concentration. An **albumin** : **creatinine ratio** of 2.5 to 20 corresponds to albuminuria of 30 to 300 mg daily respectively.

The causes of microalbuminuria are :

1. DM with early renal involvement (indicates endothelial dysfunction).
2. Systemic hypertension.
3. Congestive cardiac failure.
4. Urinary tract infection.
5. Moderate to strenuous physical exercise.
6. As an acute phase response.

CONDITIONS ASSOCIATED WITH REDUCING SUBSTANCES AND KETONE BODIES IN URINE :

Read the 'Preface' of 'Charts on urine', and page 250.

* Read 'Management of diabetic ketoacidosis' from the 'Emergency medicine' section.

CHARTS ON CSF

PREFACE:

Initially, read the 'CSF DYNAMICS AND OTHER DETAILS' of CSF from 'Lumbar puncture needle' under 'Instruments and procedures' section.

(A) Naked-eye (macroscopic) examination :

1. Pressure — 60-150 mm of CSF (lying position), and
   150-250 mm of CSF (sitting position)

   Pressure may be,

   a) High—Cerebrovascular accidents (CVA), intracranial tumour, meningitis, meningism, encephalitis, cerebral abscess, benign intracranial hypertension, circulatory block like aqueduct stenosis or hypertensive hydrocephalus, head injury, hypoxic encephalopathy.

   b) Low—Spinal subarachnoid block, severe dehydration, thick CSF (e.g., in pyogenic meningitis), partially blocked needle, after repeated lumbar puncture, bad needle placement.

2. Colour or appearance — Crystal clear or colourless.

   The common variations in appearance are,

   a) Clear—Normal, tuberculous and viral meningitis, meningism.

   b) Turbid—Turbidity usually indicates high leucocyte count and is seen in pyogenic meningitis, rarely in carcinomatous meningitis and subarachnoid haemorrhage.

   c) Straw-coloured—Tuberculous meningitis.

   d) Haemorrhagic or red—Subarachnoid haemorrhage, trauma, extensive cerebral haemorrhage; rarely due to haemorrhagic encephalitis, bleeding diathesis.

   e) Xanthochromia—See the chart on 'Xanthochromia'.

3. Coagulum formation on standing —

   Normally, the CSF does not clot on standing and if it happens so, one should think of presence of high protein and fibrinogen in the CSF. Traumatic puncture clots on standing.

   a) Cobweb coagulum (forms after few hours; indicates mild to moderate rise of protein along with fibrinogen in CSF)—Tuberculous meningitis (most important cause, and the coagulum is a rich source of tubercle bacilli), acute anterior poliomyelitis and neurosyphilis.

   b) Big coagulum (forms immediately or shortly after withdrawal; indicates very high protein in CSF) — Spinal subarachnoid block, G. B. syndrome.

(B) Chemical (biochemical) examination :

1. Total protein : 20-40 mg%

   Normally the ratio of albumin and globulin in CSF is 8 : 1; the total protein may be 'very high' in conditions like G. B. syndrome, total spinal block, meningitis (specially tuberculous) and acoustic neurofibroma.

   Normally CSF IgG is < 15% of the total protein concentration. IgG is increased in multiple sclerosis, neurosarcoidosis, neurosyphilis and in some connective tissue diseases. CSF globulin can be detected by different tests like Pandy's test, Nonne-Apelt reaction, Noguchi's test, Lange's colloidal gold curve reaction and immunoelectrophoresis.

2. Sugar : 40-80 mg% (usuallyl/2 to 2/3rd of the random blood sugar concentration).
3. Chloride : 720-750 mg% (120-170 mmol/1). Normal plasma chloride value is 98-106 mmol/1. CSF chloride becomes markedly reduced in tuberculous meningitis (probably due to fall in the plasma level as a result of prolonged vomiting) and slightly reduced in pyogenic meningitis. CSF chloride is increased in uraemia.
4. p^H : 7.31 to 7.34

(C) Microscopic examination :

Normally the cells are mononuclear cells (70% lymphocytes and 30% monocytes).in the range of 0-5 cells/mm^3. There are no polymorphs.

If the increased cell count shows polymorphs and is above 75% of the total, it is known as *polymorphonuclear pleocytosis-,* and if more than 90% lymphocytes are found, it is designated as *lymphocytic pleocytosis.*

(D) Bacteriological (includes staining and culture): Normally CSF is sterile. Pathogens can be isolated by different staining techniques (Gram stain, Ziehl-Neelsen stain, India ink preparation) or cultures.

(E) Serological : VDRL, Kahn test, Wassermann reaction help in the diagnosis of neurosyphilis. Now-a-days, different serological tests are available for bacterial, mycobacterial and fungal infections.

(F) Special: Lange's colloidal gold curve reaction—a positive reaction (indicating high globulin in CSF) is found in tabes dorsalis (tabetic curve), GPI (paretic curve), and meningitis (meningitic curve). Polymerase chain reaction (PCR) to identify bacteria are available.

* To diagnose and interpret CSF study, a close liaison between physician and microbiologist is essential. Adenosine deaminase (ADA) activity in CSF in tuberculous meningitis is > 10 U/L.

ACUTE PYOGENIC MENINGITIS

Naked-eye examination :

Pressure - ++
Appearance - Turbid/cloudy
On standing - No coagulum formation

Chemical examination :

Protein - 180 mg%
Sugar - 12 mg%
Chloride - 695 mg%

Microscopic examination :

Total cells - 4000/'mm^3
Polymorphs - 90%
Lymphocytes - 10%

Bacteriological examination :

Gram +ve cocci seen in pairs or short chains

Interpretation :

1. CSF pressure is high indicating abnormality in CSF. Turbidity is probably due to large number of polymorphs.
2. Total protein is 'moderately' increased, sugar content is much reduced and the chloride concentration is a bit lower than normal.
3. High total count of cells with polymorphonuclear pleocytosis suggests pyogenic infection of the central nervous system (CNS).
4. Presence of gram +ve cocci in pairs or short chains indicates infection produced by pneumococcus.

Inference :

The CSF chart deals with acute pyogenic meningitis probably caused by pneumococcus (S. pneumoniae).

ORGANISMS INVOLVED IN ACUTE PYOGENIC MENINGITIS :

Worldwide, the three major pathogens are H. influenzae, N. meningitidis and S. pneumoniae which account for approximately 70-80% cases of pyogenic meningitis.

(A) Neonates (< 1 month) — gram -ve bacilli (E. coli), streptococci.
(B) Children (1 month to 15 years) — H. influenzae, N. meningitidis, S. pneumoniae, M. tuberculosis.
(C) Adults — N. meningitidis, S. pneumoniae, staphylococcus, M. tuberculosis, gram -ve bacilli.

CAUSES OF ALTERATION IN SUGAR CONTENT OF CSF :

(A) High : Diabetes mellitus and other hyperglycaemic states, rarely in cerebral haemorrhage.
(B) Low (hypoglycorrhachia) :
  a) Marked reduction - Pyogenic meningitis.
  b) Moderate reduction - Tuberculous, fungal and carcinomatous meningitis, neurosarcoidosis, lymphomatous infiltration, hypoglycaemia.
(C) Normal : In health, viral meningitis, encephalitis.

CLASSICAL FEATURES OF ACUTE PYOGENIC MENINGITIS :

1. Intense headache (generalised/nuchal), high fever, meningismus, nausea, vomiting, profuse sweating, rigors, myalgia and photophobia may be present.
2. The meningismus is accompanied by **positive neck rigidity (stiffness), Kernig's sign, and Brudzinski's sign (specially in children).** Fever, nuchal headache and neck rigidity are the classical triad of meningitis.
3. Features of cerebral dysfunction (mental obtundation) like altered sensorium, confusion, delirium or coma are not uncommon.
4. Convulsions, bilateral VIth nerve palsy as a false localising sign due to raised intracranial tension; focal neurodeficit evidenced by dysphasia, visual field defects, hemiparesis, extensor plantar response may be present.
5. Meningococcal meningitis may be suggested by the presence of skin rash (erythematous -> macular -> petechial -» purpuric) mainly present over the extremities (may be present over the conjunctiva). Herpes labialis may be found. Acute adrenal failure (Waterhouse-Friderichsen syndrome) may be noted as a complication.
6. Special features in neonates and young infants :
  a) Neck rigidity (stiffness) and Kernig's sign may be absent.
  b) Listlessness, high-pitched cry, refuse to suck, irritability.
  c) Fever may be absent.
  d) Poor muscle tone, persistent vomiting, a vacant state, circulatory collapse.
  e) Anterior fontanelle may or may not be bulging.

COMPLICATIONS OF ACUTE PYOGENIC MENINGITIS :

(A) Systemic—Waterhouse-Friderichsen syndrome, SIADH, septicaemia, acute renal failure, circulatory collapse, disseminated intravascular coagulation.
(B) Neurological—Focal fits, mental retardation, neurodeficit (aphasia, blindness, deafness), brain abscess, auditory impairment, internal hydrocephalus, subdural effusion, cranial nerve palsy.

CLINICAL ASSOCIATIONS IN DIFFERENT TYPES OF PYOQENIC MENINGITIS :

1. Pneumococcal : Pneumonia, mastoiditis, sinusitis, otitis media, endocarditis, splenectomised patients, multiple myeloma, head injury with basilar fracture of the skull, hypogammaglobulinaemia.
2. Meningococcal : Usually occurs in epidemics; fulminant; children living in overcrowded houses are predisposed.
3. Staphylococcal : Neonates (umbilical infection, pyoderma, septicaemia); older children (otitis media, mastoiditis, fracture of the skull, septic lesion in scalp).
4. H. influenzae : Convulsions are commonly seen. Auditory impairment is a residual complication.

POSSIBLE CAUSES OF ASEPTIC AND RECURRENT MENINGITIS :

(A) **Aseptic meningitis** : Meningitis induced by Echovirus, Coxsackievirus , HSV-2, HIV and Arbovirus; Weil's disease, carcinomatosis, drugs or contrast medium, subarachnoid haemorrhage, neurosarcoidosis.
(B) **Recurrent meningitis** : Herpes simplex virus (commonest), chemical meningitis due to leakage into CSF of contents from an epidermoid tumour, craniopharyngioma; due to primary inflammatory conditions like SLE, Behcet's syndrome, drug hypersensitivity, Mollaret's meningitis or Vogt-Koyanagi-Harada syndrome.

* Vide the management part from 'Emergency medicine' section of this book.

NON RESPONSE IN CNS INFECTIONS—PROBABILITIES :

(A) Recrudescence—during treatment by the same organism -> probably due to wrong treatment.

(B) Relapse—after stopping treatment by the same organism -> due to parameningeal focus of infection.

(C) Recurrence -»late or delayed by the same or other organism -> due to congenital or acquired defects the dura matter.

TUBERCULOUS MENINGITIS

Naked-eye examination :

Pressure - ++

Appearance - Clear

On standing - Formation of cobwe'b coagulum (fine clot)

Chemical examination :

Protein - 600 mg%

Sugar - 30 mg%

Chloride - 580 mg%

Microscopic examination :

Total cells - 450/mm^3

Polymorphs - 8%

Lymphocytes - 92%

Bacteriological examination :

Ordinary culture shows no growth (sterile)

Interpretation :

1. The CSF pressure is raised indicating abnormality in CSF. The clear appearance may be due to tuberculous or viral meningitis, or meningism. Cobweb coagulum strongly suggests meningitis due to tuberculous aetiology.
2. Total protein is 'much' raised, sugar content is slightly reduced and the chloride content is very much reduced.
3. High total cell count with lymphocytic pleocytosis seen.
4. Ordinary culture is sterile (probably needs special and appropriate culture media).

Inference :

High CSF pressure, clear appearance, very low chloride content, cobweb coagulum with lymphocytic pleocytosis strongly indicate tuberculous meningitis (TBM). Though lymphocytic pleocytosis is often observed in viral meningitis, it is not associated with low sugar content in CSF. Moreover, sterile ordinary culture points towards tuberculous aetiology too.

* Very high level of protein often indicates block to CSF flow due to tuberculous meningitis.

PLEOCYTOSIS :

(A) Polymorphonuclear pleocytosis—Acute pyogenic meningitis.

(B) Lymphocytic pleocytosis—Meningitis of tuberculous or viral aetiology, syphilitic or fungal meningitis, multiple sclerosis, viral encephalitis, neurosarcoidosis, rarely in partially treated pyogenic meningitis.

(C) Mixed pleocytosis—Early phase of viral meningitis (often the first 36 hours), sometimes in tuberculous meningitis.

COMMON CLINICAL FEATURES OF TBM :

This condition commonly occurs shortly after a primary infection in childhood or as a part of miliary tuberculosis.

(A) Children—Lassitude, anorexia, constipation, headache, lack of interest in toys or talking.

(B) Adults—Low grade pyrexia, malaise, intense headache, vomiting, convulsions, coma.

HOW WILL YOU INVESTIGATE A CASE OF TBM ?

1. Lumbar puncture : CSF for macroscopic, chemical and microscopic examination (sometimes repeated CSF examinations are necessary). Detection of AFB (tubercle bacilli) from the centrifused deposit of CSF or from the testing of cobweb smear—examination by Ziehl-Neelsen stain is done. CSF may be cultured in Lowenstein-Jensen (L-J) media. Guineapig inoculation test takes much time to give result. As culture in L-J media may take more than 6 weeks time, BACTEC system of culture technique may be adopted which gives the result within 7 days.

   Newer modes of diagnostic avenues may be of some help in quicker diagnosis from CSF:

   a) Adenosine deaminase assay (> 10 U/L).
   b) Polymerase chain reaction (PCR).
   c) Detection of tuberculostearic acid.
   d) ELISA (not very sensitive).
   e) Bromide partition test.

2. Blood for R/E (Hb. TC. DC, ESR), chest X-ray (PA view), Mantoux test (may be negative) are done. Lymphocytosis and high ESR may indicate towards tuberculous aetiology. Chest X-ray shows evidences either of primary complex or miliary tuberculosis. Sputum examination for AFB in concomitant pulmonary tuberculosis should be performed.

   Primarily, a high index of suspicion by the attending physician is necessary for a quick diagnosis.

ADENOSINE DEAMINASE ACTIVITY TO DIAGNOSE TUBERCULOUS MENINGITIS :

Adenosine diaminase (ADA), an enzyme associated with disorders that induce cell-mediated responses, in CSF is useful for the diagnosis of tuberculous meningitis. High ADA activity in CSF may found in :

1. Tuberculous meningitis.
2. Lymphoma with meningeal involvement.
3. Neurobrucellosis.
4. Sarcoidosis.
5. Subarachnoid haemorrhage.

* In pleural, pericardial or ascitic fluid ADA activity : 40-60 U/L is borderline activity, whereas > 60 U/L is high activity. In CSF, ADA > 10 U/L favours tuberculous aetiology.

WHAT ARE THE PREDISPOSING FACTORS FOR ACQUIRING TUBERCULOSIS ?

1. HIV infection (risk increases more than 100-times than normal).
2. I.V drug abusers (e.g., heroin addict).
3. Recent infection (probably within the past 2 years) with M. tuberculosis.
4. Diabetes mellitus (risk increases 3-times than normal).
5. Prolonged corticosteroid treatment or Cushing's syndrome, other immunosuppressive therapy.
6. Silicosis.
7. Leukaemias, lymphomas.
8. Gastrectomy or intestinal by-pass surgery.
9. End-stage renal disease.
10. Malignancy of head and neck region.

CLASSIFICATION OF NEUROLOGICAL TUBERCULOSIS ?

1. Tuberculous meningitis.
2. Tuberculous arachnoiditis.
3. Tuberculoma.
4. Tuberculous abscess.
5. Tuberculous encephalopathy.

COMPLICATIONS OF TBM :

Untreated or lately treated cases may prove to be fatal. Mortality ratio is moderately high and the survivors may be left with serious disabling sequelae like mental retardation, epilepsy, blindness, deafness and hydrocephalus.

* Read the 'Management of tuberculous meningitis' from 'Emergency medicine' section.

ACUTE VIRAL MENINGITIS

Naked-eye examination :

Pressure - ++
Appearance - Clear
On standing - No coagulum formation

Chemical examination :

Protein - 150 mg%
Sugar - 65 mg%
Chloride - 730 mg%

Microscopic examination :

Total cells - 140/mm^3
Polymorphs - 10%
Lymphocytes - 90%

Bacteriological examination :

Ordinary culture shows no growth (sterile)

Serological examination :

VDRL and Kahn test of the CSF are negative

Interpretation :

1. High pressure in the CSF indicates some abnormality in CSF. The colour is clear and there is no coagulum formation on standing.
2. Though the total protein content is moderately increased, the sugar and chloride concentration remain unchanged.
3. High total cell count with lymphocytic pleocytosis.
4. Negative serology virtually excludes neurosyphilis.
5. Sterile ordinary culture raises the possibilities of tuberculous, viral or fungal meningitis, or aseptic meningitis.

Inference :

High CSF pressure, clear appearance, absence of cobweb coagulum, moderately high protein with normal sugar and chloride content as well as lymphocytic pleocytosis strongly suggest acute viral meningitis.

Normal sugar and chloride content excludes tuberculous meningitis, and negative serology rules out the diagnosis of neurosyphilis.

Aseptic meningitis is usually due to a viral infection of the meninges, and may often confused with partially treated bacterial meningitis; however, question of bacterial meningitis does not come here (as there is lymphocytic pleocytosis). Fungal meningitis needs special culture medium. Possibility of acute viral meningoencephalitis may be there and can be ruled out after meticulous clinical examination (with added features of encephalitis).

VIRUSES PRODUCING MENINGITIS :

Acute viral infection of meninges is probably the commonest cause of meningitis. Though less serious than acute pyogenic meningitis, it may prove fatal if associated with encephalitis. Usually it is a benign and self-limiting disease.

Viruses responsible :

1. Enteroviruses (Echovirus, Coxsackievirus, Poliovirus)—Commonest.
2. Mumps virus.
3. Arboviruses (Togavirus and Bunyavirus).
4. Herpes simplex virus (HSV).
5. Lymphocytic choriomeningitis (arenavirus).
6. Influenza viruses.
7. HIV.
8. Rabies virus.
9. Epstein-Barr virus.
10. Varicella zoster virus.

Aseptic meningitis commonly occurs due to enteroviruses, arboviruses, HIV and HSV-2 (see the chart of 'Acute pyogenic meningitis' described earlier).

INVESTIGATIONS PERFORMED IN ACUTE VIRAL MENINGITIS :

1. Blood for routine examination (R/E) reveals leucopenia along with relative lymphocytosis.
2. Examination of CSF.
3. Detection of antiviral antibodies in both serum and CSF. Often the ratio of CSF/serum antibody increases the sensitivity of the diagnosis.
4. Amplification of viral-specific DNA or RNA from CSF.
5. Agarose electrophoresis of CSF gamma globulin may reveal oligoclonal bands in HTLV-1, mumps, HIV or rubella meningitis.

CLASSIFY NEUROSYPHILIS :

Nurosyphilis is very rare now-a-days and only considered as a theoretical possibility.

(A) Meningovascular—
- I. Cerebral :
  - a) Asymptomatic neurosyphilis.
  - b) Acute syphilitic meningitis.
  - c) Cerebral pachymeningitis.
  - d) Cerebral leptomeningitis.
  - e) Cerebral endarteritis obliterans (may produce hemiplegia).
  - f) Cerebral gumma (behaves like a SOL).
- II. Spinal :
  - a) Pachymeningitis hypertrophic cervicalis.
  - b) Chronic meningomyelitis.
  - c) Erb's spastic paraplegia.
  - d) Spinal endarteritis obliterans.
  - e) Syphilitic amyotrophy.
  - f) Syphilitic radiculitis.

(B) Parenchymatous—
- a) General paresis of insane (GPI)—Cerebral.
- b) Tabes dorsalis—Spinal.
- c) Taboparesis (tabes dorsalis plus GPI).

CLUE TO DIAGNOSIS OF FUNGAL MENINGITIS

Lymphocytic pleocytosis with low sugar level may suggest fungal meningitis (indicates tuberculous aetiology too). The CSF may show the fungus e.g., it is seen as budding yeast cells and surrounded by a gelatinous capsule in 'India ink preparation' in case of cryptococcus meningitis.

* Remember, in viral meningitis focal neurological signs are rare though high pyrexia is associated with. In comparison to pyogenic meningitis, headache is a prominent feature here.

MENINGISM

Naked-eye examination:

Pressure	-	++
Appearance		Clear
On standing	-	No coagulum formation

Chemical examination :

Protein		35 mg%
Sugar	-	70 mg%
Chloride	-	730 mg%

Microscopic examination :

Total cells	–	4 /mm^3
Polymorphs	–	Nil
Lymphocytes	–	100%

Bacteriological examination:

Ordinary culture shows no growth (sterile)

Interpretation :

All the parameters in macroscopic, chemical, microscopic and bacteriological examination are within normal limits except the raised CSF pressure.

For all probabilities, no specific diagnosis can be given. In the presence of raised CSF pressure, the most likely diagnosis is meningism which requires clinical correlation.

Inference :

The chart deals with meningism.

WHAT IS MENINGISM ?

It is synonymous with meningeal irritation as a result of some local or systemic infection without any direct infection/inflammation of CNS. The symptoms of meningism often mimic meningitis.

Clinical associations :

1. Enteric fever.
2. Pneumonia (commonly atypical variety).
3. Empyema thoracis.
4. Diphtheria.
5. Acute pyogenic tonsillitis.
6. Viral encephalitis.
7. Weil's disease.
8. Non-infectious conditions like leukaemia, lymphoma, subarachnoid haemorrhage, sarcoidosis, malignancy, SLE.

One may find positive neck rigidity in meningism which is usually painless. Meningitis produces painful neck rigidity. Kemig's sign is less pronounced in meningism.

Though passive resistance to head flexion is present in cerebral malaria, signs of meningism are always absent.

SUBARACHNOID HAEMORRHAGE

Naked-eye examination :

Pressure	- ++
Appearance	Blood -stained and uniformly red on standing
On prolonged standing	Supernanent fluid is yellow

Chemical examination :

Protein	500 mg%
Sugar	70 mg%
Chloride	725 mg%

Microscopic examination :

Total cells	Plenty
Polymorphs	few
Lymphocytes	few
RBC	10000/mm^3, few are crenated

Bacteriological examination:

Ordinary culture shows no growth (sterile)

Interpretation :

1. CSF pressure is high. The fluid is blood-stained and on prolonged standing, supernatent fluid becomes yellow. These findings are highly suggestive of subarachnoid haemorrhage.
2. Total protein is raised probably due to added protein from blood. Sugar and chloride content are within normal limits.

3. Total cell count is raised. Plenty of RBC are seen of which few are crenated. They indicate the diagnosis of subarachnoid haemorrhage.

Inference :

The chart deals with subarachnoid haemorrhage (SAH).

* D/D of this chart is traumatic haemorrhage in the CSF. In traumatic haemorrhage, CSF pressure is not altered and the CSF protein content is not so high.

CAUSES OF HAEMORRHAGIC CSF :

The common possibilities are,

1. Subarachnoid haemorrhage.
2. Trauma.
3. Extensive cerebral haemorrhage (dissecting).
4. Haemorrhagic encephalitis.
5. Bleeding diathesis.

For *diffemtiation between subarachnoid haemorrhage and trauma,* read the 'Lumbar puncture needle' from the 'Instruments and procedures' section. Extensive cerebral haemorrhage may develop into secondary subarachnoid haemorrhage. CSF shows lymphocytic pleocytosis in haemorrhagic encephalitis. Bleeding diathesis is diagnosed clinically and by coagulation profile.

AETIOLOGY OF SUBARACHNOID HAEMORRHAGE :

(A) Primary : Rupture of,

a) Saccular or berry aneurysm—Congential defect; commonest.
b) Arteriovenous malformations or dural arteriovenous fistula.
c) Mycotic aneurysm (may arise from endocarditis).
d) Traumatic/dissecting aneurysm.
e) Atherosclerotic aneurysm.
f) Neoplastic aneurysm.
g) Angioma.
h) Bleeding diathesis or use of anticoagulants.

(B) Secondary :

a) Dissecting intracerebral bleed—Specially in a hypertensive subject.
b) Haemorrhage into cerebral infarct.
c) Haemorrhage into cerebral tumour.

* The berry aneurysms are commonly located at :

1. Posterior communicating-internal carotid arterty junction.
2. Anterior communicating-anterior cerebral artery junction.
3. Middle Cerebral artery bifurcation region.

CONGENITAL MALFORMATIONS ASSOCIATED WITH BERRY ANEURYSM :

1. Polycystic kidneys.
2. Coarctation of aorta.
3. Arteriovenous malformations.
4. Elhers-Danlos syndrome, Marfan's syndrome.
5. Moya-moya disease.

COMMON CLINICAL FEATURES IN SAH :

1. Sudden onset of excruciating occipital headache.
2. Vomiting.
3. Convulsions, collapse and coma may be present.
4. *Neck rigidity and positive Kemig's sign.*
5. Features of increased intracranial tension.
6. Focal signs e.g., visual field defect, Illrd nerve palsy, hemiplegia etc (not common).
7. Fundoscopy reveals subhyaloid haemorrhage.
8. A bruit may be audible over the eyes or head in arteriovenous malformation.

COMMON COMPLICATIONS OF SAH :

There are four major causes of delayed neurodeficit in SAH.

1. Rebleed — Risk of rebleeding is usual in first 2 weeks (greatest between 5th and 9th day).
2. Vasospasm — May occur between 4-14 days (most frequent at 7 day) of initial event and may predispose to focal ischaemic deficit.
3. Hydrocephalus — Blockage of normal CSF may lead to acute, subacute or chronic hydrocephalus necessitating ventricular drainage.
4. Hyponatraemia — Usually occurs within first 2 weeks as a result of SIADH.

INVESTIGATIONS PERFORMED TO DIAGNOSE SAH :

1. Lumbar puncture and CSF analysis (the hallmark of diagnosis is blood in the CSF).
2. CT scan (high-quality non-contrast).
3. MRI scan.
4. Magnetic resonance angiography (MRA)—usually in patients who are fit for surgery (awake and < 65 years).
5. Digital subtraction angiography (DSA), or cerebral angiography (i.e., four-vessel conventional X-ray angiography involvong both carotids and both vertebral arteries).

* Now-a-days, CT imaging is the first investigation of choice and subsequently lumbar puncture is done if CT remains inconclusive.

WHY THE SUPERNATENT FLUID (CSF) IN SAH IS YELLOW ON PROLONGED STANDING ?

The uniformly sanguinous CSF develops yellow supernatent fluid on prolonged standing or centrifugation. This is known as xanthochromia. In the early stages, it is due to oxyhaemoglobin formation but lately bilirubin is responsible for.

PREVENTION OF VASOSPASM AND REBLEEDING ?

(A) Vasospasm (due to vasoconstrictor substances released from activated platelet, RBC or cerebral tissue)—It is prevented by slow calcium channel inhibitors e.g., nimodipine (30 mg/tab) is given as 2 tab 4 hourly to be started within 3-4 days of SAH and is usually continued for 3 weeks. It reduces mortality.

(B) Rebleeding (due to fibrinolysis)—Use of antifibrinolytic agent e.g., epsilon amino-caproic acid (EACA) is often considered. EACA is infused 24-48 g/day in 5% dextrose-saline over 24 hours with the help of a micro-drip apparatus. It is not routinely used as it increases the risk of delayed cerebral infarction.

XANTHOCHROMIA

Naked-eye examination:

Pressure	-	Nil
Appearance		Yellowish
On standing	-	Formation of big coagulum

Chemical examination :

Protein	-	1200 mg%
Sugar		65 mg%
Chloride		730 mg%

Microscopic examination :

Total cells	4 /mm^3
Polymorphs	Nil
Lymphocytes	100%
RBC	Nil

Bacteriological examination:

Ordinary culture shows no growth (sterile)

Queckenstedt's test :

Positive

Interpretation :

1. Absent pressure in the CSF with yellowish appearance (probably indicates xanthochromia) suggests spinal subarachnoid block.
2. Total cell count is within normal limit though the protein content is high, indicating 'albumlno-cytological dissociation'.
3. Positive Queckenstedt's test, i.e., no rise in CSF pressure on compression of internal jugular vein along with the above features confirm the diagnosis of complete spinal subarachnoid block.

Inference :

This is a chart of complete spinal subarachnoid block.

WHAT IS XANTHOCHROMIA ?

Xanthochromia is yellowish discolouration of the CSF. It is always an abnormal feature in the CSF and is commonly due to,

1. Old subarachnoid haemorrhage (due to oxyhaemoglobin and bilirubin).
2. Guillain-Barre syndrome (due to high protein).
3. Acoustic neurofibroma (due to high protein).
4. Froin's loculation syndrome (spinal block and is chiefly due to high protein).
5. Deep Jaundice (due to high bilirubin).
6. Massive old intracerebral bleed or haemorrhagic infarction (same as subarachnoid haemorrhage).
7. Subdural haematoma (rare).

CAUSES OF SPINAL SUBARACHNOID BLOCK :

1. Spinal tumours e.g., meningioma, neurofibroma.
2. Patchy arachnoiditis.
3. Spinal epidural abscess.

WHAT IS FROIN'S LOCULATION SYNDROME ?

This syndrome develops as a result of spinal cord compression (spinal block). CSF examination shows,

1. Low CSF pressure.
2. Xanthochromia.
3. Clot formation on standing.
4. High protein content.
5. Positive Queckenstedt's test.

WHAT *IS QUECKENSTEDT'S TEST* ?

Vide the chapter on 'Lumbar puncture needle' from 'Instruments and procedures' section.

WHAT DO YOU MEAN BY ALBUMINO CYTOLOGICAL DISSOCIATION ?

It means, there is raised protein content in the CSF without any rise in the total cell count. The probable causes are,

1. Guillain-Barre syndrome.
2. Froin's loculation syndrome.
3. Acoustic neurofibroma.

HOW *THE PATIENT WITH SPINAL BLOCK PRESENTS* ?

The patient usually presents with features of spastic paraparesis or paraplegia (compressive myel-opathy).

CHARTS ON TEMPERATURE

PREFACE:

At first, read the chapter on Abnormal temperature' from 'Bedside Clinics in Medicine, Part I' where the temperature patterns are disscused in details. However, a gist is given below :

Normal body temperature and its variations are :

1. Normal—98°F-99°F (with a diurnal variation of 1.5°F; the temperature is lowest in the morning and is highest in the evening)
2. Subnormal - Below 98°F
3. Pyrexia or febrile - Above 99°F
4. Hypothermia - Below 95°F
5. Hyperpyrexia - Above 106.7°F

Rectal or vaginal temperature > oral temperature > axillary temperature

* Tympanic membrane (TM) thermometers measure radiant heat from the tympanic membrane, and is lower than rectal temperature.

** Recently fever has been defined like this : AM temperature (oral) of > 98.9°F and PM temperature (oral) of > 99.9°F.

Types of fever :

I. Intermittent—Fever is present only for several hours and always touches the baseline sometime during the day. It has three subdivisions :
   a) Quotidian—When the paroxysm of fever occurs daily (i.e., daily rise and daily fall).
   b) Tertian—When the paroxysm occurs on alternate days (i.e., a gap of 48 hours).
   c) Quartan—When two days intervene between consecutive paroxysmal attacks (i.e., a gap of 72 hours).

II. Continued—Fever does not fluctuate more than 1°C (1.5°F) during the 24-hours period and it never touches the baseline.

III. Remittent—Daily fluctuation of fever is more than 2°C (3°F) during the 24-hours period and it never touches the baseline.

Appearance of rash in a febrile patient :

Mnemonics : 'very sick person must take double tea' stands for :

1st day — Varicella (chickenpox)
2nd day— Scarlet fever
3rd day — Pox (small pox; eradicated globally)
4th day — Measles
5th day — Typhus
6th day — Dengue
7th day — Typhoid or enteric fever

Onset of pyrexia may be :

a) Sudden—e.g., Malaria, lobar pneumonia,
b) Gradual—e.g., Enteric fever.

Epidemiological clues to fever/rash :

1. Male homosexuals : HIV, hepatitis B, amoebiasis
2. Travel abroad ; Malaria, typhoid, giardiasis, hepatic amoebiasis
3. Cats : Toxoplasmosis, tularaemia
4. Dogs : Leptospirosis
5. Sewerage workers/water sports : Leptospirosis
6. Hunting : Tularaemia, lyme disease
7. Hiking : Giardiasis, rocky mountain spotted fever
8. Raw meat : Brucellosis
9. Raw milk : Bovine tuberculosis, toxoplasmosis, brucellosis
10. Raw egg : Typhoid
11. I.V drug abuser : HIV, hepatitis B, infective endocarditis

* The term 'fastigium' is the period of highest rise in a temperature curve.

** In the clinical thermometer, an arrow is marked at 98-6°F or 37°C indicating normal body temperature (axillary temperature).

QUOTIDIAN TEMPERATURE

DAYS	1	2	3	4	5	6	7	8	9	10
105										
104										
103										
102										
101										
100										
99										
98.6										
98										
97										
96										

NAME : AGE : DISEASE : DATE OF ADMISSION :

Fig. 7.6 : Quotidian temperature

Inference :

The chart shows daily rise of temperature with daily fall. So. this is the quotidian variety of intermittent temperature.

CAUSES OF QUOTIDIAN TEMPERATURE :

1. Double infection of P. vivax.
2. Pent-up pus anywhere in the body.
3. Tuberculosis.
4. Urinary tract infection.
5. Amoebic liver abscess.
6. Septicaemia.
7. Filariasis.

IS IT THE COMMON TYPE OF TEMPERATURE IN P. VIVAX INFECTION ?

No. Tertian variety of intermittent temperature is commonly seen in P.vivax malaria.

TEMPERATURE PATTERN IN 'PENT-UP PUS' ANYWHERE IN THE BODY ?

It is known as **'hectic' temperature.** There is wide swings in the temperature and the temperature rises with chill and rigor, then persists for few hours, and suddenly falls with profuse perspiration.

Common examples are lung abscess, pyogenic liver abscess, empyema thoracis, empyema of gall bladder, subdiaphragmatic abscess, acute osteomyelitis. Hectic temperature may also be seen in septicaemia or pyaemia.

WHAT IS MEANT BY 'DOUBLE INFECTION' OF P. VIVAX ?

It is the infection by two different P.vivax types having different life cycles.

Often different species of malaria parasites develop in the same mosquito and may transmit the

infection to man giving rise to 'mixed infection', the commonest being P.vivax and P. falciparum species. This type of mixed infection may also give rise to quotidian temperature.

IMPORTANCE OF 'THICK' AND 'THIN' FILM BLOOD SMEAR IN MALARIA :

(A) Thick film :
- a) For screening
- b) Helpful in low parasitaemia

(B) Thin film :
- a) For confirmation of diagnosis
- b) Identification of the species
- c) Quantity load in P. falciparum

WHAT ARE PYROGENS ?

Pyrogens are substances that produce fever. It may be of two types : exogenous and endogenous. The exogenous pyrogens are microorganisms, their products, or toxin; chemically they are lipopolysaccharides. The endogenous pyrogens are chemically polypeptides produced primarily by macrophages/ monocytes. Common examples are interleukin-1, interleukin-6, tumour necrosis factor (TNF) a, interferon a (in *a* general sense, collectively known as *cytokines).*

TERTIAN TEMPERATURE

DAYS	1	2	3	4	5	6	7	8	9	10
105										
104										
103										
102										
101										
100										
99										
98.6										
98										
97										
96										

NAME : AGE : DISEASE : DATE OF ADMISSION :

Fig. 7.7 : Tertian temperature

Inference :

As the temperature comes on alternate days and touches the baseline, this is the tertian variety of intermittent temperature (i.e., the temperature shoots on 1st, 3rd, 5th, 7th, 9th days and so on).

CAUSES OF TERTIAN TEMPERATURE :

1. Benign tertian malaria (commonly by P. vivax and rarely by P. ovale or malariae).
2. Malignant tertian malaria (P. falciparum).

ASEXUAL CYCLE IN DIFFERENT TYPES OF PLASMODIUM :

I. P. vivax and P. ovale — 48 hours.
II. P. falciparum — Less than 48 hours.
III. P. malariae — 72 hours.

This determines the temperature pattern in different types of Plasmodium infection.

DIFFERENT STAGES IN MALARIAL PAROXYSM' :

There are 3 stages :

1. Cold stage (chill, shivering, rigor, teeth chattering, goose flesh),
2. Hot stage (feels hot, hot flush, throbbing headache, prostration, vomiting), and
3. Stage of sweating (drenching sweat, defervescence of fever, exhaustion).

The patient usually remains afebrile in between paroxyams.

* Infected female anopheline mosquito -> sporozoites inoculated in man -> goes into liver -» merozoites leave the liver -> invades RBC -> produce schizonts -> rupture of schizonts releases many merozoites into the blood and produces fever.

PATHOGENESIS OF CHILL, RIGOR AND SWEATING :

Normal temperature is maintained in health by regulating a balance between heat gain and heat loss, governed by the hypothalamus.

It should be looked upon in the setting of 'thermostat'. When the temperature is rising to a higher level, heat is being conserved, the cutaneous vessels are constricted (so the patient feels cold/chill) and the patient may even shiver violently. The shivering is known as 'rigor', and often associated with pilo-erection and teeth chattering.

When the higher temperature is reached, heat loss starts and the cutaneous vessels starts dilating for dissipation of heat. The patient feels hot and sweating starts.

CAUSES OF gUARTAN TEMPERATURE :

It is found in quartan malaria (P. malariae) which is rare in India.

CAUSES OF HYPERPYREXIA :

1. Malaria.
2. Septicaemia.
3. Encephalitis.
4. Pontine haemorrhage.
5. Lobar pneumonia.
6. Heat stroke.
7. Dhatura poisoning.
8. Malignant hyperthermia (halothane-induced).
9. Thyroid storm.
10. Neuroleptic malignant syndrome (haloperidol-induced).
11. Rabies.
12. Drug-induced (e.g., amphetamines).
13. Serotonin syndrome (SSRI/MAOI-induced).

* Fever is due to elevated set-point of the thermostat whereas hyperpyrexia results from inadequate heat dissipation.

ENUMERATE THE CAUSES OF HYPOTHERMIA :

1. Myxoedema coma.
2. Prolonged exposure to cold (in street beggars, accidental or in mountaineering).
3. Peripheral circulatory failure due to any cause.
4. Enteric fever if associated with haemorrhage or perforation (commonly in the 3rd week).
5. Hypoglycaemia.
6. Panhypopituitarism.
7. Adrenal insufficiency.
8. Artificial hypothermia induced in open heart surgery.
9. Extreme wasting as in starvation, terminal stage of malignancy.
10. Near-drowing.

CAUSES OF FEVER WITH CHILL AND RIGOR :

1. Malaria.
2. Urinary tract infection.
3. Pent-up pus anywhere in the body e.g., subdiaphragmatic abscess.
4. Septicaemia or pyaemia.

5. Cholangitis.
6. Subacute bacterial endocarditis.
7. Thrombophlebitis.
8. Acute pyelitis or acute pyelonephritis.
9. Acute lobar pneumonia.
10. Pyrogen reaction after fluid infusion or blood transfusion.
11. Filariasis.
12. Agranulocytosis.

ESSENTIAL INQUIRIES IN A CASE OF 'PYREXIA'

1. Localising symptoms.
2. Loss of weight.
3. Joint pain.
4. Immunosuppression.
5. Substance abuse.
6. Medications.
7. Travel.
8. H/O contact.

CONTINUED TEMPERATURE

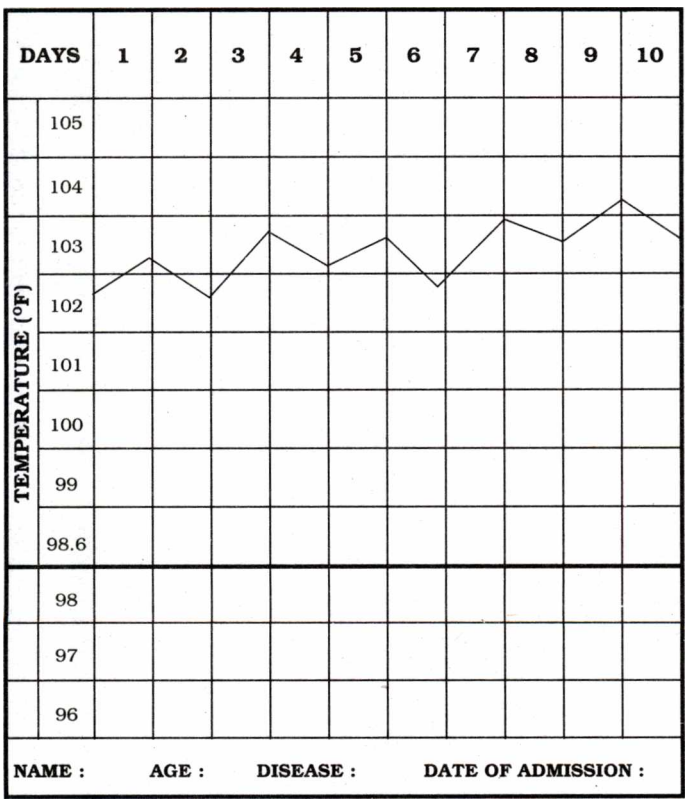

Fig. 7.8 : Continued temperature

Inference :

The fluctuation of temperature is limited within 1.5°F and it does not touch the baseline. This is a chart showing continued type of pyrexia.

CAUSES OF CONTINUED TEMPERATURE :

1. Lobar pneumonia.
2. Second week of enteric fever.
3. Miliary tuberculosis.
4. Meningococcal meningitis.
5. Acute rheumatic fever.
6. Subacute bacterial endocarditis (SBE).
7. Untreated urinary tract infection.
8. Collagen vascular diseases (e.g., SLE).
9. Lymphoma or leukaemias.

FEATURES OF ENTERIC FEVER IN THE SECOND WEEK :

(A) Symptoms :

1. Disappearance of headache.
2. Continued type of high pyrexia.
3. Constipation is usually replaced by 'pea-soup diarrhoea' (loose, greenish stool).
4. Lethargy and apathy appear.
5. Abdominal distention (meteorism).
6. Cough may be present (due to bronchitis).

(B) Signs :

1. Pulse—Tachycardia appears, dicrotic pulse usually disappears. Pulse is of low volume.
2. Tongue remains dry and coated.
3. Soft and mildly tender splenomegaly. Abdomen is distended and may be tender.
4. Rose spots may appear on 7th to 10th day.
5. Lungs may shows features of bronchitis/bronchopneumonia.

WHAT IS TYPHOID FACIES' ?

Classically the description goes like this : the face is thin and flushed; bright eyes and a dull, heavy, staring, apathetic expression. This type of facial appearance is characteristic of a patient of enteric fever who is progressing into the third week.

AETIOLOGY OF ENTERIC FEVER :

1. Transmitted by faecal-oral route through the contamination of milk, food or water.
2. The bacilli may persist in the gall bladder of chronic carriers for months or years.
3. Incubation period is 10-14 days.
4. a) Typhoid fever is caused by Salmonella typhi.
   b) Paratyphoid fever is due to S. paratyphi A and B.

DIAGNOSIS OF ENTERIC FEVER :

(A) First week :

a) Though in most patients the WBC count is normal, 25% patients may have leucopenia and neutropenia.
b) Blood culture (90%)—Often clot culture is done.
c) Culture of bone marrow aspirates will yield the organism (85-95%) even earlier than blood culture—Not used routinely is clinical practice.

(B) Second week :

a) Widal test (95%).
b) Blood culture (60%).

(C) Third week :

a) Stool culture (75%).
b) Widal test (95% in high titre).
c) Blood culture (50%).
d) Urine culture (70%).

(D) Fourth week ;

a) Urine culture (70%).
b) Stool culture (50%).
c) Widal test.
d) Blood culture (25%).

Mnemonics : Basu, i.e., the most efficacious test in first week—Blood culture, second week—Agglutination test (Widal test), third week—Stool culture, and in fourth week—Urine culture. Figure within the bracket indicates positivity in percentage of cases.

* The hallmark of enteric fever is prolonged and persistent pyrexia, if remains untreated. Leucopenia and relative bradycardia are typical.

LEUCOCYTOSIS IN ENTERIC FEVER :

If enteric fever is complicated by perforation or bronchopneumonia, leucocytosis may be observed.

WHAT ARE ROSE *SPOTS :*

These are sparse, small rose-red, blanching, slightly raised macules mainly present over upper abdomen and chest during the end of the first week of illness. It is usually visible only on fair-skinned persons. The lesions last only 2-3 days and result from bacterial embolism. Salmonella can be cultured from the biopsy of rose spots.

WHAT IS WIDAL TEST ?

1. It is an agglutination reaction where agglutinating antibodies develop against O, H and Vi-antigens.
2. It is usually positive from 7-10 days and onwards.
3. *The O-agglutinins are more valuable in active disease* than H-agglutinins which may develop as a result of previous inoculation or there may be an anamnestic rise. Vi-agglutinin develops after 3-4 weeks of illness and thus not used routinely for early diagnosis (important in diagnois of carriers).
4. A four-fold 'rising titre' is very suggestive of enteric fever. The titre has no correlation with the severity of illness.
5. A titre (against O-antigen) above 1:160 is suggestive and a titre above 1 : 640 is often very significant of enteric fever in a non-immunised person.
6. It is not a very reliable test and should be interpreted with caution, specially in typhoid vaccinated patients. Due to high rates of false positivity and false negativity, misinterpretation is very common. Now-a-days, Widal test is not preferred by the clinicians.

WHAT IS TYPHOID STATE ?

The untreated enteric fever patient may enter into severe toxaemic state along with high rise of temperature usually at the end of second week or onset of the third week of illness, and is manifested by some neurological (encephalitis-like) features like,

1. Semiconsciousness or unconsciousness.
2. Low muttering delirium.
3. Coma vigil—Patient lies with half-open eyes but ignorant of his surroundings (staring stupor).
4. Subsultus tendinum—Involuntary movements of fingers and wrists due to muscular twitching.
5. Carphology—Agitated plucking of the bed sheets, and
6. Convulsions rarely.

This is a moribund situation and should be tackled immediately with intravenous dexamethasone or hydrocortisone hemisuccinate along with parenteral antimicrobials (chloramphenicol, ceftriaxone).

* Steroids should not be used in the third or fourth week in classical enteric fever as there is chance of precipitation of intestinal haemorrhage or perforation.

** Features like meningism may be present in typhoid state.

LIFE-THREATENING COMPLICATIONS IN ENTERIC FEVER :

1. Typhoid state.
2. Intestinal haemorrhage or perforation (usually in the 3rd or 4th week).
3. Acute pancreatitis (rare).
4. Acute peripheral circulatory failure: endotoxic shock.
5. Myocarditis.
6. DIC (Disseminated Intravascular Coagulation).
7. Septicaemia, pyaemia.
8. Meningitis.

* Two other important complications (late) are carrier state and chronic cholecystitis.

IMMUNISATION AGAINST ENTERIC FEVER :

(A) Oral : Contain life-attenuated S. typhi. 4 doses : One capsule to be taken 1 hour prior to meal with cold or lukewarm water on every alternate days (on days 1,3,5 and 7). Totally 4 capsules are required (Typhoral). Booster dose to be repeated after every 5 years. The *minimal age for* vaccination is 6 years.

(B) Parenteral : Purified Vi-polysaccharlde inactivated vaccine prepared from bacterial capsule (Vi CPS). Single dose : One injection of 0.5 ml (Typhim VI) given I.M or deep S.C. Booster dose to be repeated every 2 years. The minimum age for vaccination is 2 years.

REMITTENT TEMPERATURE

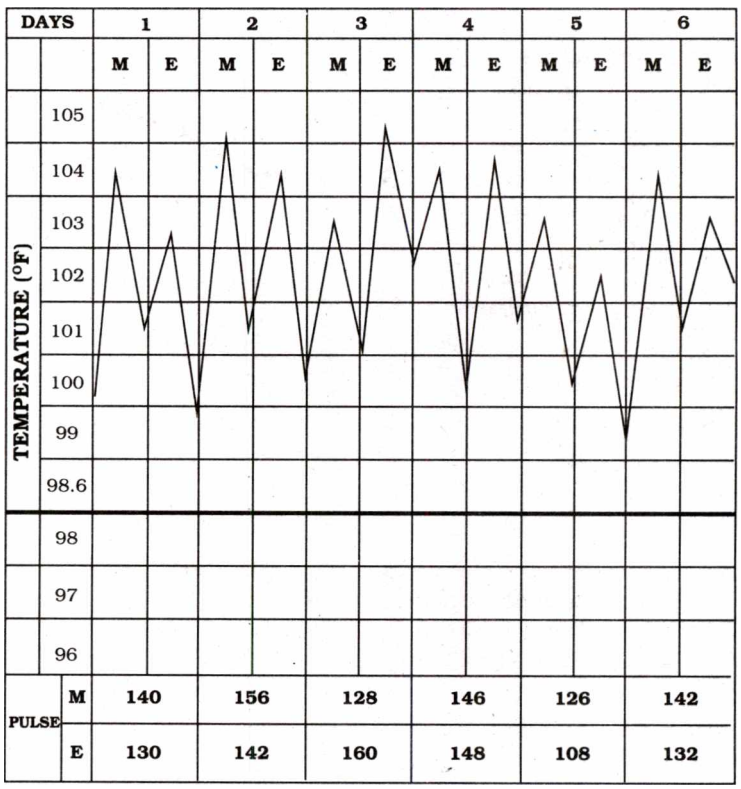

Fig. 7.9 : Remittent temperature

Inference :

The fluctuation of temperature is more than 3°F and it does not touch the baseline. There is a special feature in this chart, i.e., double rise of temperature on the same day and is known as double quotidian temperature. Basically, the chart deals with remittent type of pyrexia.

CAUSES *OF REMITTENT TEMPERATURE :*

1. Amoebic liver abscess.
2. Urinary tract infection.
3. Third week of enteric fever.
4. Acute bronchopneumonia.
4. Acute tonsillitis.
6. Bacteraemia, septicaemia, pyaemia.

PROBABLE CAUSES OF DOUBLE QUOTIDIAN (CAMEL HUMP FEVER) PYREXIA :

It is the double fever spike in a single day and is seen in :

1. Kala-azar (commonest cause).
2. Gonococcal perihepatitis or endocarditis.
3. Sometimes in acute bacterial endocarditis.

* This type of fever is often known as 'rabbit-ear patten' pyrexia.

WHAT IS PUO ?

It is also known as fever of unknown origin (FUO). Criteria to diagnose PUO are (Petersdorf and Beeson, 1961) :

1. Fever higher than 101°F on several occasions.
2. A duration of fever for more than 3 weeks.
3. Failure to reach a provisional diagnosis after one week of inpatient investigations.

Now-a-days PUO is classified as (Durack and Street, 1991) :

1. Classical PUO (as previous definition except the time frame which is 3 outpatient visits or 3 days in hospital without determining the cause, or one week of intelligent and invasive ambulatory investigations). Classical PUO may be due to infections, collagen vascular diseases, inflammatory diseases, malignancy, drug fever, factitious fever, habitual hyperthermia.
2. Nosocomial PUO (hospital-acquired)—Commonly due to septic thrombophlebitis, Cl. difficile colitis, drug fever etc.
3. Neutropenic PUO—The neutrophil count falls below 500/mm^3 and is commonly due to perianal infection, Candida or Aspergillus infection.
4. HIV-associated PUO—As a result of tuberculosis, mycobacterium avium intracellulare (MAI), toxoplasmosis, pneumocystis carinii, cryptococcosis, non-Hodgkin's lymphoma, drug fever.

COMMON CAUSES OF PUO IN INDIA :

1. Tuberculosis, amoebic liver abscess, SBE, chronic kala-azar, malaria, cryptococcosis, cysticercosis, AIDS.
2. Acute rheumatic fever, SLE, vasculitis.
3. Lymphomas, leukaemias, multiple myeloma, hypernephroma.
4. Drug fever, faulty thermometer, factitious fever.

* The success in diagnosing PUO rests on meticulous history taking (with special reference to family, occupational and recent travel history), repeated interview with the patient, thinking about the patient and careful physical examination.

PROBABLE CAUSES OF 'ASEPTIC FEVER' :

1. Heatstroke.
2. Lymphoma, leukaemias or disseminated malignancy.
3. Collagen vascular disease e.g., SLE.
4. Pontine haemorrhage.
5. Thyroid storm.
6. Drug fever, e.g.. rifampicin or sulphonamide-induced.
7. Acute myocardial infarction.
8. Gout.
9. Crush injury.
10. Over-atropinisation.
11. Radiation sickness.

ABSENT FEVER IN SUBACUTE BACTERIAL ENDOCARDITIS (SBE) :

1. Elderly patients.
2. Severe sepsis.
3. Congestive cardiac failure or renal failure.
4. Prior antimicrobial therapy.
5. Fungal endocarditis.

STEP-LADDER PATTERN PYREXIA

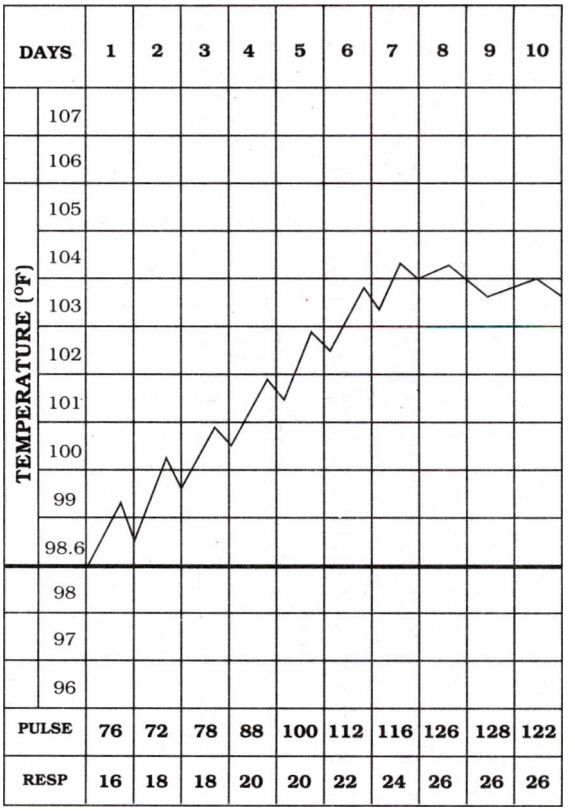

Fig. 7.10 : Step-ladder pattern pyrexia

Inference :

The above chart shows gradually increasing pattern of pyrexia for first 7 days of illness and may be called 'step-ladder pattern' pyrexia. The rise in the pulse rate shown in the chart is not corresponding to the elevated temperature and relative bradycardia is noted. The temperature pattern from 8th to 10th day is of continued in type.

The temperature pattern deals with pyrexia due to enteric fever/typhoid fever.

FEATURES OF ENTERIC FEVER IN ITS FIRST WEEK :

1. Step-ladder pattern of pyrexia.
2. Frontal headache.
3. Constipation (diarrhoea, vomiting and pain abdomen may be seen in children).
4. Anorexia, nausea, cough and epistaxis.
5. Flushed face with toxic look.
6. Angry looking tongue—Central coating with red tip and margins.
7. Caecal gurgling (due to presence of fluid faeces and air).
8. Relative bradycardia and rarely dicrotic pulse.
9. Rose spots appearing on the 7th day (usually appears on 7th-10 day).
10. There may be just palpable, soft and tender spleen at the end of first week.

WHAT IS 'STEP-LADDER PATTERN' PYREXIA ?

1. The temperature of today always exceeds that of previous day.
2. Usually the temperature rises (2°F) in the evening and falls (1°F) in the next morning.
3. It is basically continued or remittent type of pyrexia (i.e., not touching the baseline).

PATTERN OF PYREXIA IN DIFFERENT WEEKS OF ENTERIC FEVER :

1. 1st week — Step-ladder pattern.
2. 2nd week — Continued.
3. 3rd week — Continued or remittent type with fluctuation of 3°-4°F. There may be 'fall by crisis' of temperature as a result of haemorrhage of perforation.
4. 4th week — Reverse step-ladder pattern, i.e., temperature 'falls by lysis'.

WHAT IS RELATIVE BRADYCARDIA ?

It is known that with per degree (°F) rise of temperature in an adult, the pulse rate increases by 10 beats /minute. If the increase in pulse rate is less than 10 beats/minute with per degree (°F) rise of temperature, the condition is known as relative bradycardia. It is commonly found in,

1. Any viral illness (e.g., in yellow fever—known as Faget's sign; dengue).
2. First week of enteric fever.
3. Sometimes in pyogenic meningitis.
4. Brucellosis, psittacosis, Weil's disease.
5. Drug fever, factitious fever.

WHAT IS MEANT BY 'FALL BY CRISIS' AND 'FALL BY LYSIS' ?

Fall of temperature is also known as defervescence. They are :

(A) Fall by crisis—When the pyrexia falls to nornal or subnormal level very quickly within 6-12 hours and is associated with severe sweating, it is known as fall by crisis. It is usually found in,

1. Acute lobar pneumonia.
2. Enteric fever complicated by intestinal haemorrhage or perforation.
3. Adrenal crisis (seen in meningococcal meningitis).
4. Septicaemic shock.
5. Dengue.

(B) Fall by lysis—When the temperature falls gradually in steps over several days, it is known as fall by lysis. It is usually found in,

1. Uncomplicated enteric fever.
2. Rheumatic fever.
3. Acute bronchopneumonia.

* Most of the raised temperature falls by lysis. Use of antipyretics (paracetamol) may precipitate fall by crisis.

NEWER DIAGNOSTIC TESTS IN ENTERIC FEVER :

Slide agglutination test, indirect haemagglutination test, ELISA (IgG and IgM), counterimmunoelectrophoresis, enzyme immunoassay, PCR, IgM capture, monoclonal antibodies, DNA probes etc. Though highly sensitive, the tests are very costly.

TEMPERATURE CHART ON MEASLES

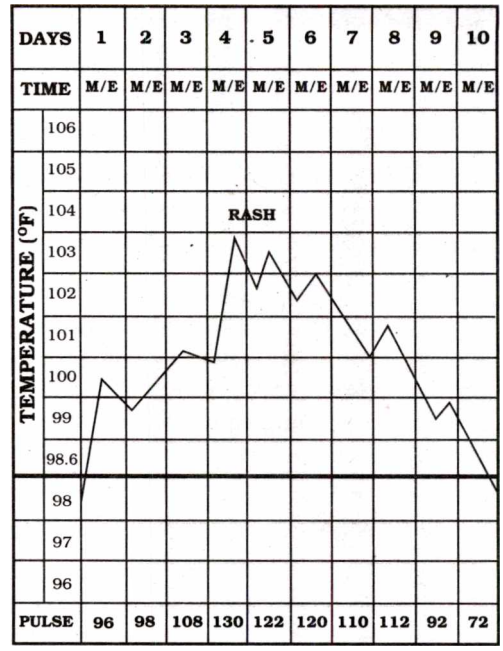

Fig. 7.11 : Temperature chart on measles

Inference :

The temperature shoots upto 100.5°F on the first day and then persists for next 2 days as continued in type. The chart shows that on the 4th day, the temperature again elevates upto 104°F with the appearance of rash in the body. Thereafter, pyrexia gradually **falls by lysis** on next 5 days, making the patient afebrile on the 10th day.

The pattern of pyrexia as well as the *appearance of rash on the fourth day* strongly indicate the diagnosis of measles.

AETIOLOGY:

Synonym — Rubeola.

Infective agent—Paramyxovirus (RNA virus).

Age—Young children are mostly affected.

Spread—By droplet infection.

Route of infection—Nasopharynx.

Incubation period—7-14 days (mean 10 days).

STAGES OF ILLNESS IN MEASLES :

1. Catarrhal stage.
2. Exanthematous stage.
3. Recovery stage.

DESCRIBE THE CHARACTERISTIC RASH IN MEASLES (EXANTHEM) :

1. Usually appears on the fourth day, maculo-papular in type. Rash first appears at the back of the ears, and at the junction of skin and hair on the forehead; ultimately face, neck, trunk, limbs upto palms and soles may be affected. The density of rash is found to be greatest on the forehead.

2. Rashes are discrete, pink, and blanch on pressure. Later they become confluent giving rise to characteristic blotchy appearance. Measle's rash is also known as *morbilliform rash.*
3. Rash disappears in the reverse order of appearance giving rise to a faint brown staining of the skin followed by a fine desquamation.

WHAT IS KOPLIK'S SPOT (ENANTHEM) ?

1. Koplik's spots are virtually pathognomonic of measles. Usually appears on the second day of illness and disappear before the appearance of exanthem (true rash).
2. These are tiny white or bluish-white spots surrounded by a. narrow zone of inflammation around the opening of the parotid duct, i.e., in the buccal mucous membrane (inner aspect of cheek) opposite the crown of upper second molar teeth. This stage is highly infectious.

ATYPICAL MEASLES :

It is seen in persons who has taken formalin-inactivated measles vaccine (not used after 1970) and were subsequently exposed to measles virus. It is believed to be due to hypersensitivity to measles virus induced by inactivated vaccine. The disease is severe with haemorrhagic rashes, oedema, high pyrexia and interstitial pulmonary infiltrates.

ADULT MEASLES :

Like many other viral infections, adult measles is severe in adults than in children. Rash is more severe and confluent, often with bacterial superinfection (e.g.. otitis media, sinusitis, pneumonia). Hepatitis and bronchospasm are more common.

PERIOD OF INFECTIVITY IN MEASLES :

The catarrhal stage and upto 5 days after appearance of morbilliform rash is highly infectious. The total duration of illness in a classical case is 10 days or less.

CHANGES OCCUR WITH MEASLES :

1. Transient loss of PPD (Mantoux test becomes negative).
2. Improvement of eczema and bronchial asthma.
3. Remission of leukaemia, lipoid nephrosis and Hodgkin's disease.

MAJOR COMPLICATIONS OF MEASLES :

(A) Three 'tubes' are mainly affected like,
   1. Otitis media,
   2. Bronchopneumonia, and
   3. Gastroenteritis.

(B) Bronchitis and bronchiolitis, giant cell pneumonia, conjunctivitis, myocarditis, generalised purpura, reactivation of tuberculosis, viral encephalitis, acute encephalomyelitis, subacute sclerosing panencephalitis (SSPE; develops after several years), keratitis.

PROPHYLAXIS AGAINST MEASLES :

(A) Active—Single dose (0.5 ml) of life-attenuated viral vaccine (by Enders and colleagues) given by S.C route at 9 months of age (may be given in combination with mumps and rubella vaccine, as 'MMR' vaccine) with booster dose at $1^1/_2$ years of age. MMR vaccine is likely to be replaced by MMRV (V for varicella) vaccine. Developing countries recommend measles vaccine at 12-15 months of age.

(B) Passive (post-exposure prophylaxis)—Human normal immunoglobulin is given within 6 days of exposure, by I.M route for attenuation of measles in contacts with the dose of,
   (i) 0.25 ml/kg—for healthy persons, and
   (ii) 0.5 ml/kg—for immunocompromised individuals.

TEMPERATURE CHART ON VARICELLA INFECTION

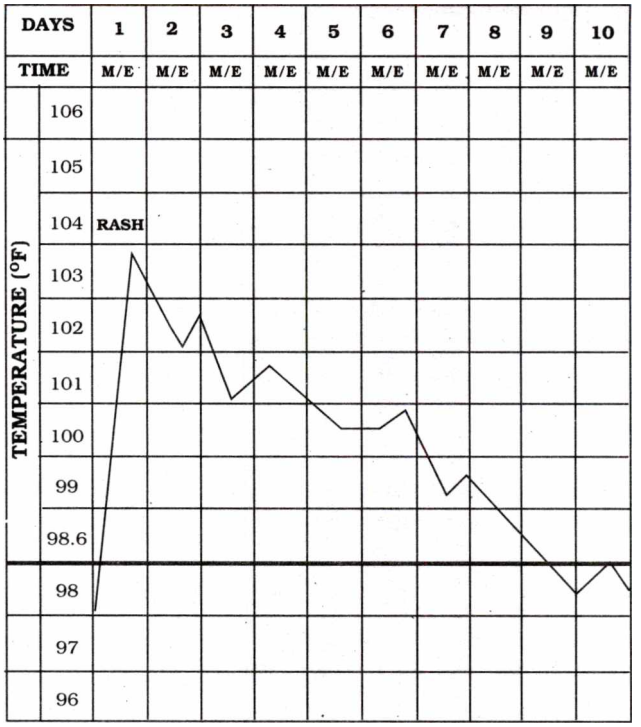

Fig. 7.12 : Temperature chart on varicella

Inference :

There is acute pyrexia on the 1st day reaching 103.8°F with the appearance of rash. Thereafter, pyrexia gradually **falls by lysis** for next 8 days and the patient becomes afebrile on the 9th day.

The pattern of pyrexia as well as the appearance of rash on the first day strongly indicate the diagnosis of varicella infection.

AETIOLOGY:

Infective agent — Varicella-zoster virus (DNA virus).

Spread — By droplet infection.

Route of infection—Nasopharynx.

Incubation period—12-21 days (mean 17 days).

Period of infectivity—Usually about a week, starting probably a day before the appearance of rash and continues upto next 6 days. *The crusts are not infective.* The patients are most infective during the prodromal period.

DESCRIBE THE CHARACTERISTIC RASH IN CHICKENPOX :

1. True rash appears on the first day of the illness. They are more dense on the trunk than on the face and limbs (centripetal). At first, it is macular in type and then rapidly passes over to papule, vesicle or even pustule.
2. Rash is mostly present on flexor surfaces. Axilla may be involved. Palms and soles are seldom affected. They are oval, superficial and likely to be ruptured very easily by simple pressure. *Rash is pleomorphic,* i.e., at a given time, different stages of rash are seen.
3. Vesicular rash are unilocular and not *umbilicated*; often surrounded by erythema. There is complete collapse on pricking. Rise of temperature occurs with appearance of each fresh crop of rash. Scabs begin to form usually 4-7 days after the appearance of rash and totally fall off within 14 days. Scar remains after separation of the crusts, which is usually not permanent.

* Total duration of illness in a classical case is 10 days.

COMPLICATIONS AFTER VARICELLA INFECTION :

1. Secondary bacterial infection of the skin lesion which may lead to septicaemia.
2. Interstitial pneumonia.
3. Encephalitis, transverse myelitis, optic neuritis, cerebellar syndrome, meningitis
4. Orchitis.
5. Myocarditis.
6. Acute glomerulonephritis.

DIFFERENTIAL DIAGNOSIS OF CHICKENPOX RASH :

1. Herpes zoster.
2. Impetigo contagiosa.
3. Dermatitis herpetiformis.
4. Bullous impetigo.
5. Infected scabies.
6. Rickettsialpox.
7. Disseminated vesiculo-papular lesions associated with echovirus, coxsackievirus and atypical measles.
8. Smallpox (eradicated world-wide).

* Though eradicated, concern about **smallpox** has increased recently because of the threat of bioterrorism. The lesions of smallpox are larger than chickenpox and are monomorphic (all are at same stage of evolution at a point of time).

PROPHYLAXIS AGAINST CHICKENPOX :

(A) Active—0.5 ml of vaccine (varilrix) is given in subcutaneous route. Single dose is required upto 12 years of age. Above 13 years, 2nd dose of vaccine is given at an interval of 6-10 weeks.

(B) Passive—Varicella-zoster Immunoglobulin (VZIG) is given within 72 hours of exposure. A dose of 1.25 ml to 5 ml is administered in I.M route.

VESICLES/BULLAE IN SKIN :

Cutaneous blisters are known as vesicle (< 0.5 cm) or bulla (> 0.5 cm). Blistering (vesicle/bulla) diseases of skin are :

1. Pemphigus vulgaris.
2. Bullous pemphigoid.
3. Dermatitis herpeteformis.
4. Stevens-Johnson syndrome.
5. Toxic epidermal necrolysis.
6. Bullous impetigo.
7. Staphylococcal scalded-skin syndrome.
8. Varicella or herpes zoster infection.
9. Epidermolysis bullosa.
10. Bullosis diabeticorum.
11. Behcet's syndrome.
12. Bullous SLE.

* **Pemphigus**—An autoimmune blistering disease with intraepidermal thin-walled, flaccid, easily ruptured bullae; affects apparently normal skin and mucous membrane with less tendency to heal. Mostly seen in scalp, face and flexures though may be generalised.

Pemphigoid—Subepidermal tense bullae with less chance of rupture, and a positive tendency to heal. Mucosa of mouth and conjunctiva are rarely involved. Mostly seen in trunk, limbs and flexures. Pemphigoid may be associated with (occult) lymphoma.

TEMPERATURE CHART ON LOBAR PNEUMONIA

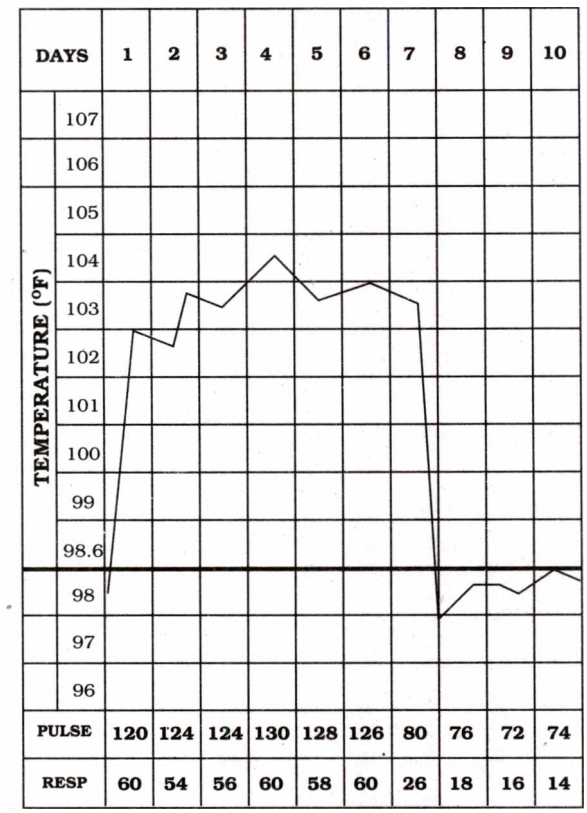

Fig. 7.13 : Temperature chart on lobar pneumonia

Inference :

Acute pyrexia on the 1st day where temperature shoots upto 103°F and remains continued in type for next 6 days. On the 7th day, temperature suddenly **falls by crisis.**

The *pulse : respiration ratio is diminished* as a result of high respiratory rate. The pulse : temperature ratio is not altered (i.e., absence of relative bradycardia or tachycardia).

The pattern of pyrexia is typically seen in acute lobar pneumonia.

WHAT IS PULSE : RESPIRATION RATIO ?

It is seen that with per degree (°F) rise of temperature, there is an increase in respiratory rate by 2 to 3/minute.

a) Normal pulse : respiration = 4:1 (72 : 18).

b) Increased pulse : respiration e.g., 12 : 1 (72 : 6) is seen in narcotic poisoning.

c) Decreased pulse : respiration e.g., 2 : 1 (112 : 56) is seen in acute lobar pneumonia.

* In a treated case of acute lobar pneumonia, temperature may fall by lysis or crisis on the 3rd or 4th day of illness.

CAUSES OF TACHYPNOEA :

1. Nervousness, exertion, anxiety.
2. Fever due to any cause.
3. Acute lobar pneumonia.
4. Left ventricular failure.
5. Acute pulmonary thromboembolism.
6. COPD.
7. Shock.
8. Acidosis.
9. ARDS or acute lung injury.
10. Hysterical hyperventilation.

Tachypnoea is increased rate of respiration (normal respiratory rate is 14-18/min).

TEMPERATURE CHART ON DENGUE

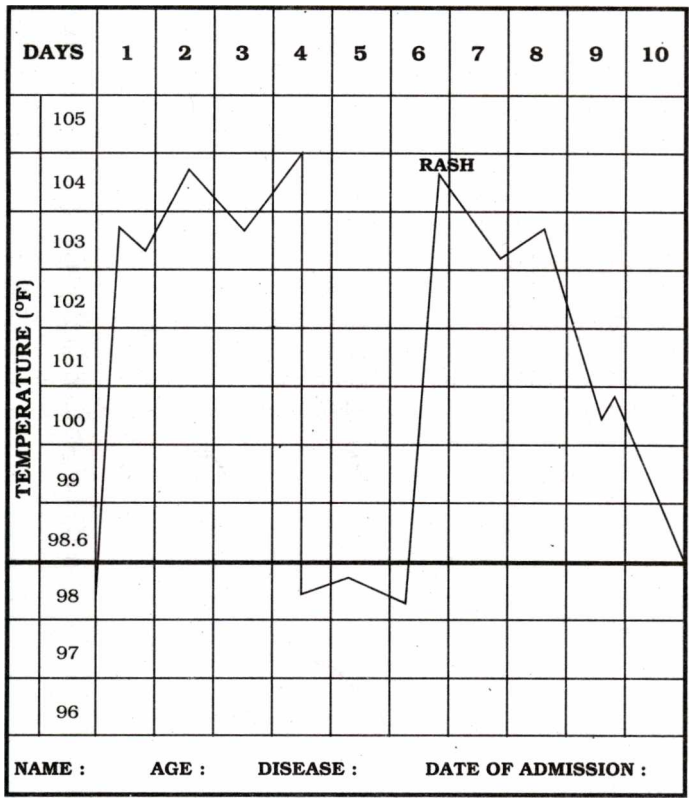

Fig. 7.14 : Temperature chart on dengue

Inference :

There is acute pyrexia on the 1st day which gradually increases on the next 3 days. Then the temperature **falls by crisis** and remains near normal for 2 more days only to reappear on the 6th day along with the development of rash. From 8th day onwards, temperature falls gradually and the patient Is afebrile on the 10th day.

This pattern of biphasic or **'saddle-back' pyrexia** is *classical of dengue.*

TYPE OF PYREXIA IN DENGUE :

It is continued or saddle-back in type, with a break usually on the 4th or 5th day. Fever persists for 7-9 days.

AETIOLOGY:

Causative agent—Arbovirus (flavivirus).

Principal vector—Aedes aegypti (mosquito).

Incubation period—2-7 days

Usual course of the disease—7-9 days (usually does not cross 10 days).

DESCRIBE THE CHARACTERISTIC RASH IN DENGUE :

(A) Primary or initial rash—Appears on the lst-2nd day. Rash is erythematous (diffuse flushing) and present over face, neck and shoulder.

(B) Secondary or true rash—Measly or morbilliform rash which appears on the 6th day of illness and is usually present over the dorsum of hands and feet. Ultimately the rash becomes generalised (mostly over the trunk) including the face. The rash may persist from 2 hours to several days and terminates by desquamation.

OTHER FEATURES IN DENGUE FEVER :

1. Pyrexia, generalised lymphadenopathy, intense headache, severe backache *('break-bonefever'),* retro-orbital pain, scleral injection, cough, epistaxis, scattered petechiae (may be with positive tourniquet test), relative bradycardia, extreme prostration.
2. Delirium, agitation, transient loss of accommodation, G.I. haemorrhage and splenomegaly may be found.

* Severe fatigue and depression are common after remission of fever.

** Chikungunya rash is of similar type but arthralgia or arthritis may be associated with.

TYPES OF DENGUE :

(A) **Classic dengue fever** : described above.

(B) **Dengue haemorrhagic fever (DHF)** : DHF is a severe form of dengue and is believed to be due to two or more sequential infections with different dengue serotypes. DHF is diagnosed on the basis of following triad—haemorrhagic manifestations (into skin, epistaxis, haematemesis, melaena), a platelet count < 100000/mm^3 and objective evidence of plasma leakage (shown either by fluctuation of packed cell volume > 20%, or evidence of pleural effusion, ascites or hypoproteinaemia). This develops into **'dengue shock syndrome'** which is characterised by a rapid and weak pulse with narrow pulse pressure (< 20 mm of Hg), or profound hypotension. Immediate volume-replacement therapy is mandatory, otherwise the mortality rate is 40%.

IMPORTANT POINTS TO BE REMEMBERED IN THE TREATMENT OF DENGUE :

1. Don't use NSAIDs or aspirin. Paracetamol should be used for bodyache.
2. Volume replacement and blood transfusion in dengue shock syndrome (capillary leak syndrome).
3. Platelet transfusion in thrombocytopenia.

CAUSES OF HAEMORRHAGIC FEVER :

1. Dengue haemorrhagic fever (flavivirus).
2. Yellow fever (flavivirus).
3. Meningococcaemia.
4. Gram-negative septicaemia.
5. Relapsing fever (by Spirochaetes).
6. Rocky Mountain spotted fever (by Rickettsiae).
7. Plague.
8. African trypanosomiasis (protozoa).
9. Viral haemorrhagic fever (Lassa fever, Marburg/Ebola virus)
10. Disseminated gonococcal infection.

WHAT IS PERIODIC FEVER' ?

It is the periodic attacks of pyrexia alternating with a period of apyrexia, and is commonly seen in :

1. Hodgkin's disease (Pel-Ebstein temperature).
2. Brucellosis.
3. Relapsing fever.
4. Malaria.
5. Rat bite fever.
6. Dengue.

CHARTS ON LIVER FUNCTION TESTS (LFT)

PREFACE:

These tests (LFT) do not point to a specific disease but indicate the underlying pathological process. The blood tests for liver function are :

1. Serum bilirubin—The normal serum bilirubin level is 0.3-1.0 mg/dl; the conjugated fraction is
   * 0.1-0.3 mg/dl and the unconjugated fraction remains 0.2-0.7 mg/dl.

   When chemical analysis reveals more than 50% conjugated bilirubin, it is considered to have predominantly conjugated hyperbilirubinaemia; and when the unconjugated bilirubin is more than 80% of the total bilirubin, the patient is considered to have primarily unconjugated hyperbilirubinaemia. Majority of hepatobiliary disorders lead to conjugated hyperbilirubinaemia. Conjugated hyperbilirubinaemia indicates impairment of secretion into the bile while unconjugated hyperbilirubinaemia points towards impaired conjugation.

   In hepato-cellular diseases e.g.. viral hepatitis or cirrhosis of liver, usually there is interference in all the three steps of bilurubin metabolism, i.e., uptake, conjugation and excretion. As excretion is the rate-limiting step and usually hampered to the greatest extent, it is the conjugated hyperbilirubinaemia which predominates in hepato-cellular disorders.

   Conventionally, serum bilirubin level upto 6 mg/dl, in between 6-15 mg/dl, and greater than 15 mg/dl are respectively known as mild, moderate and severe jaundice.

2. Aminotransferases (transaminases)—There are two enzymes which indicate hepato-cellular damage or injury to liver. Normal blood level of each enzyme is 10 -40 IU/L.

   SGPT : Serum glutamic pyruvic transaminase is now-a-days known as ALT (alanine aminotransferase).

   SGOT : Serum gluamic oxaloacetic transaminase is now-a-days known as AST (aspartate aminotransferase).

   Although raised SGPT (ALT) and SGOT (AST) levels may be observed in other non-hepatic diseases like acute myocardial infarction or skeletal muscle disorders, *SGPT (ALT) is more specific in hepato-cellular disorders than SGOT (AST).*

   SGPT (ALT) is exclusively found in the cytosol, while SGOT (AST) exists in both mitochondria and cytosol. Elevated levels are found in hepatic necrosis due to any aetiology (viral hepatitis, toxin or drug-induced hepatic injury). Low level may be seen in fulminant hepatitis (due to exhaustion) or uraemia (spurious). AST : ALT > 2 may be found in alcoholic hepatitis.

3. Alkaline phosphatase—Normal serum value is 35-130 IU/L or 3-13 KA unit (King-Armstrong). The enzyme is found in liver, bone, intestine and placenta.

   Mild to moderate elevation : In parenchymal hepatic disorders like hepatitis and cirrhosis of liver.

   Striking increase (3-10 times) occurs in biliary obstruction (extrahepatic or intrahepatic cholestasis).

   Common causes of raised serum alkaline phosphatase are pregnancy, adolescence, rickets, osteomalacia, bony metastasis, fracture of bone, sarcoidosis, hyperparathyroidism, tumours of G.I. tract, Paget's disease of bone and obstructive jaundice. The concomitant elevation of GGT (see below) and 5'-nucleotidase confirm the source of alkaline phosphatase as liver.

4. Serum proteins—They reflect the hepatic transport and synthetic function (serum bilirubin also reflects the same).

   Normal value of serum albumin is 3.5-5.5 g/dl and that of serum globulin is 2-3.5 g/dl. Albumin is synthesized by the liver. Serum globulins include alpha, beta and gamma globulin fractions (seperated on electrophoresis). In cirrhosis of liver, globulin level increases (polyclonal) due to stimulation of recticulo-endothelial system as the Kupffer cells can not clear all the antigens presented to the liver. Though albumin and globulin ratio has no physiologic significance, the ratio is often altered i.e., from 2 : 1, it tends to become 1 : 2 in cirrhosis of liver.

   A falling serum albumin in hepatic disorder is a bad prognostic sign.

5. Prothrombin time—The liver synthesizes six coagulation factors i.e., factor I, II, V, VII, IX and X. Determination of prothrombin time efficiently reflects the abnormality of these factors. As factor VII is the rate-limiting pathway in the coagulation cascade, it has the greatest influence on prothrombin time. *Prothrombin time is a very important 'prognostic marker' of hepato-cellular*

damage (i.e., a sensitive indicator of acute or chronic hepatic disorder). The normal prothrombin time is 12-16 seconds. In hepato-cellular injury, prothrombin time is increased and does not return to normal level with vitamin K therapy. Acutally, prothrombin time assesses the severity of hepatic damage.

6. Serum ammonia—Normal serum ammonia level is 10-80 pg/dl. A very high level reflects severe hepato-cellular damage. Highest level is found in hepatic encephalopathy.
7. Serum lipids—These are sensitive but non-specific indicators of hepato-cellular diseases. In cirrhosis of liver, serum cholesterol level is low. Acute parenchymal liver disorders may have high triglycerides and low cholesterol esters level. Cholestasis (intra- or extrahepatic) is-associated with raised unesterified cholesterol and serum phospholipids.
8. Bromsulphalein (BSP) excretion test—Not used now-a-days and its only value remains in the diagnosis of Dubin-Johnson syndrome (double rise).
9. Other enzymes :
   a) 5'-nucleotidase—Increased in hepatic necrosis. Elevated level of 5'-nucleotidase indicates that raised alkaline phosphatase is of hepatic in origin (elevated alkaline phosphatase level in pregnancy, bone metastasis or of intestinal origin do not have associated raised 5'-nucleotidase level).
   b) y-glutamyl transpeptidase (GGT)—It is the *most sensitive* indicator of hepatobiliary disorders. Though elevated in hepato-cellular damage, it is rather non-specific because elevated GGT level may be found in pancreatic, renal, cardiac or pulmonary disorders. GGT *is a potential marker of alcohol abuse.* GGT level is raised in hepato-cellular damage and cholestasis. The normal serum level is 9-58 U/L.
   c) LDH and OCT (ornithine carbamyl transferase) levels may be elevated in viral hepatitis, cirrhosis of liver and hepatic metastasis. These are not routinely performed.

* Hepato-cellular disease and cholestasis are associated with conjugated hyperbilirubinaemia while haemolysis results in raised level of unconjugated bilirubin. An isolated rise in serum bilirubin without SGPT or SGOT elevation may be due to haemolysis or familial. Increase in SGOT and SGPT level with hepato-cellular injury and a striking elevation of > 1000 IU/L are obtained in extensive hepatic damage by acute viral hepatitis, drug or toxin-induced liver injury, or ischaemic liver injury (e.g., prolonged hypotension or acute heart failure). The alkaline phosphatase rises much in cholestasis and to a lesser extent in hepato-cellular injury.

** **Severity assessment of hepatic injury** is reflected mainly by prothrombin time, and partly by serum albumin and Factor V levels.

*** Prothrombin time (PT) measures the extrinsic pathway while activated partial thromboplastin time (aPTT) reflects the intrinsic pathway of coagulation cascade.

ACUTE VIRAL HEPATITIS

Bilirubin	-	8.6 mg/dl
Conjugated	-	6.2 mg/dl
Unconjugated	-	2.4 mg/dl
SGPT (ALT)	-	296 IU/L
Alkaline phosphatase	-	145 IU/L
Total protein	-	7.4 g/dl
Albumin	-	4.5 g/dl
Globulin	-	2.9 g/dl
Prothrombin time	-	17 seconds
Australia antigen (HB_sAg)	-	Positive

Interpretation :

1. Serum bilirubin level is elevated (moderate jaundice) and the conjugated fraction is raised more. SGPT is raised by more than 7 times of upper limit of normal. Alkaline phosphatase level is slightly raised.

2. Total protein with albumin and globulin fractions are within normal limit (i.e., indicating the absence of chronic hepato-cellular dysfunction). Prothrombin time is a bit high.
3. Australia antigen (HB_sAg) is present.

Inference :

Predominant conjugated hyperbilirubinaemia with raised SGPT level reflects hepato-cellular damage or acute parenchymal liver disease. Presence of Australia antigen suggests acute viral hepatitis due to type B virus infection. The patient is now in the icteric stage.

* Often 'history' is very important to interpret the data.

CAUSES OF CONJUGATED HYPERBILIRUBINAEMIA :

1. Viral or drug-induced hepatitis.
2. Cholestasis (drug-induced or pregnancy-induced).
3. Cirrhosis of liver.
4. Extrahepatic biliary obstruction (gall stones, carcinoma of the head of pancreas).
5. Dubin-Johnson syndrome.
6. Rotor syndrome.
7. Secondary carcinoma of liver.

SEROLOGY IN DIFFERENT TYPES OF ACUTE VIRAL HEPATITIS :

Type A — IgM anti-HAV
Type B — HB_gAg and IgM anti-HBc
Type C — Anti-HCV
Type D —■ Co-infection : Anti-HDV plus IgM anti-HBc
Superinfection : Anti-HDV plus IgG anti-HBc
Type E — IgM anti-HEV

DRUGS PRODUCING HEPATO-CELLULAR JAUNDICE :

1. Rifampicin.
2. INH.
3. Halothane (anaesthetic).
4. Alcohol.
5. Paracetamol overdose (>10 g/day).
6. Phenytoin.
7. Ketoconazole.
8. Zidovudine.
9. Carbamazepine.

UNCONJUGATED HYPERBILIRUBINAEMIA

Bilirubin	5.8 mg/dl
Conjugated	1.1 mg/dl
Unconjugated	4.7 mg/dl
SGPT (ALT)	36 IU/L
Alkaline phosphatase	100IU/L
Total protein	7 g/dl
Albumin	4 g/dl
Globulin	3 g/dl
Prothrombin time	13 seconds
Australia antigen	Negative

Interpretation :

1. Serum bilirubin is elevated (mild jaundice). Unconjugated bilirubin is raised by more than 80% of total bilirubin. SGPT (ALT), alkaline phophatase are within normal limit.
2. Total protein, prothrombin time are normal. Australia antigen is absent.

Inference :

The chart reflects mild, predominantly unconjugated hyperbilirubinaemia without any hepato-cellular damage. The possibilities are **(predominant unconjugated hyperbilirubinaemia)** :

1. Haemolysis (thalassaemia, spherocytosis, immune haemolysis, G_6PD deficiency).
2. Ineffective erythropoiesis.
3. Prolonged fasting (< 300 cal/day).
4. Sepsis.
5. Gilbert's syndrome and rarely, Crigler-Najjar syndrome.
6. Neonatal jaundice.

HOW TO COME TO A DEFINITIVE DIAGNOSIS FROM HERE ?

1. Details history.
2. Meticulous clinical examination : Haemolytic jaundice will have splenomegaly. Gilbert's syndrome shows no physical abnormality except mild jaundice. In the presence of sepsis, patient will present with pyrexia.
3. Blood for routine examination as well as the peripheral blood film will point towards haemolytic jaundice (e.g., thalassaemia). Reticulocytosis suggests haemolysis; Hb concentration will reflect the degree of anaemia in haemolysis.
4. 'Fasting test'—When a patient of Gilbert's syndrome is placed on 300 calorie per day for 2 days, the patient will show increase in bilirubin level by 1.5 mg/dl after 2 days of fasting.

PROGNOSIS IN GILBERT'S SYNDROME :

The disease is benign in nature and the prognosis is good. The life-span is normal.

CONGENITAL NON HAEMOLYTIC HYPERBILIRUBINAEMIA — SPECTRUM OF DISEASES :

1. Gilbert's syndrome (unconjugated).
2. Crigler-Najjar syndrome (type I and type II; unconjugated).
3. Dubin-Johnson syndrome (conjugated).
4. Rotor syndrome (conjugated).

COMMON EXAMPLES OF HAEMOLYTIC JAUNDICE IN CITY HOSPITALS :

1. Thalassaemia.
2. Mismatched blood transfusion.
3. Snake bite (Viperidae group).
4. Malaria (specially falciparum malaria).
5. Rh incompatibility.
6. Drug-induced (primaquine or sulphonamide-induced in G_6PD deficiency).

* In haemolytic jaundice, bilirubin is usually less than 6 mg/dl.

CIRRHOSIS OF LIVER

Bilirubin	4.9 mg/dl
Conjugated	3.1 mg/dl
Unconjugated	1.8 mg/dl
SGPT (ALT)	62 IU/L
Alkaline phosphatase	170 IU/L
Total protein	7.2 g/dl
Albumin	2.9 g/dl
Globulin	4.3 g/dl
Prothrombin time	18 seconds
Australia antigen	Negative

Interpretation :

1. Total bilirubin is high (mild jaundice) and there is conjugated hyperbilirubinaemia. SGPT (ALT) is just elevated and alkaline phosphatase is slightly raised.

2. Total protein is normal with hypoalbuminaemia and hyperglobulinaemia. Albumin and globulin ratio is 1 : 1.5; prothrombin time is raised by 2 second over the highest limit of normal. Australia antigen is negative.

Inference :

High bilirubin level, just raised SGPT (ALT) and alkaline phosphatase (excludes acute hepatic parenchymal injury and cholestasis respectively), low albumin as well as high globulin level clinch the diagnosis of chronic liver disease (e.g., cirrhosis of liver). Increased prothrombin time reflects hepato-cellular damage (e.g., failure) and certainly indicates a bad prognostic sign.

CAUSES *OF HYPERGLOBULINAEMIA (POLYCLONAL GAMMOPATHY) :*

1. Chronic liver disease e.g., cirrhosis of liver.
2. Chronic infection e.g., chronic kala-azar.
3. SLE and other collagen vascular diseases.
4. AIDS.

CAUSES OF HYPOGLOBULINAEMIA :

1. Hereditary forms (X-linked hypogammaglobulinaemia, severe combined immunodeficiency).
2. Multiple myeloma.
3. Chronic lymphatic leukaemia.

CART *IT BE A CHART OF CARCINOMA OF LIVER ?*

No. Primary hepato-cellular carcinoma (hepatoma) 'usually' does not raise the bilirubin level. Secondary metastasis in liver may produce jaundice but globulin level remains normal. Moreover, in carcinoma of liver the alkaline phosphatase level would have been more high.

HOW TO CONFIRM YOUR DIAGNOSIS ?

Liver biopsy confirms the diagnosis of cirrhosis of liver.

HOW A PATIENT OF CIRRHOSIS OF LIVER USUALLY PRESENTS ?

Apart from the features peculiar to the aetiology, cirrhosis of liver results in two major events : hepato-cellular failure and portal hypertension, the tempo of which determines the clinical presentation. The patient may be in the 'compensated' or 'decompensated' form.

Usually the patient presents with undue fatiguability, flatulent dyspepsia, anorexia, swelling of legs or abdomen, jaundice, haematemesis or melaena, poor health, or in the stage of hepatic pre-coma.

CHOLESTASIS

Bilirubin	18 mg/dl
Conjugated	14.6 mg/dl
Unconjugated	3.4 mg/dl
SGPT (ALT)	58 IU/L
Alkaline phosphatase	1300IU/L
Total protein	7 g/dl
Albumin	4.2 g/dl
Globulin	2.8 g/dl
Prothrombin time	19 seconds
Australia antigen	Negative

Interpretation :

1. There is very high bilirubin level (severe jaundice) with predominant conjugated hyperbilirubinaemia. SGPT (ALT) level is slightly raised. Alkaline phosphatase is 10 times more than the upper limit of normal.
2. Total protein with albumin and globulin fractions show no abnormality (suggesting absence of chronic hepato-cellular damage as well as reflecting normal protein metabolism). Prothrombin time is raised by 3 seconds above normal. Australia antigen is absent (i.e.. playing no role).

Inference:

Conjugated hyperbilirubinaemia with very high alkaline phosphatase signifies cholestasis. As SGPT (ALT) level is not much altered, probably it is a case of extrahepatic cholestasis.

CAUSES OF OBSTRUCTIVE JAUNDICE :

(A) Intrahepatic (medical) :

1. Viral hepatitis (cholestatic variety).
2. Chronic hepatitis.
3. Cirrhosis of liver (specially primary biliary cirrhosis).
4. Lymphoma.
5. Recurrent cholestasis of pregnancy.
6. Drugs like chlopromazine, chlorpropamide, erythromycin oestolate, oral contraceptive pills, methimazole, anabolic steroids, methyl testosterone.
7. Secondary carcinoma of liver.

Extrahepatic (surgical) :

1. Gall stone impaction in CBD.
2. Carcinoma of the head of pancreas, periampullary carcinoma.
3. Carcinoma of the gall bladder.
4. Enlarged glands at porta hepatis.
5. Stricture of CBD.
6. Sclerosing cholangitis from ulcerative colitis.
7. Cholangiocarcinoma.

HOW THE PROTROMBIN TIME IS CORRECTED IN CHOLESTASIS ?

It is known that vitamin K-dependent coagulation factors are II, VII, IX and X. Vitamin K is a fat-soluble vitamin and its deficiency is seen most commonly as a result of cholestasis, either intra- or extrahepatic. Thus, coagulopathy may occur from cholestasis.

In extrahepatic 'cholestasis', parenteral replacement of vitamin K usually corrects the prothrombin time rapidly to normal (within 24-48 hours). But if the coagulopathy is due to 'hepatic disorders', the prothrombin time may not improve or may improve but not to normal. In the liver, vitamin K is required for a complex conversion to produce the different coagulation factors (II, VII, IX, X), and protein C and protein S. Thus in hepatic disorders (e.g., intrahepatic cholestasis), coagulopathy is usually not corrected after administration of vitamin K (the complex conversion in the liver is hampered). The usual dose of vitamin K is 10 mg, I.M daily for consecutive 3 days.

MODALITIES ADOPTED IN TREATING PRURITUS IN CHOLESTASIS :

1. Cholestyramine (a bile salt sequestering agent)—12 g/day orally in divided doses, before as well as after meals.
2. Ursodeoxycholic acid (UDCA)—13-15 mg/kg/day orally.
3. Antihistaminics (e.g., tab cetrizine 10 mg daily).
4. Phenobarbitone—May be tried in resistant cases.
5. Ondansetron—this 5 HT type 3 receptor antagonist may be of some value; 4-8 mg, BID/TID.
6. Naloxone (opiate antagonist), naltrexone or propofol (hypnotic)—May be tried.
7. Methyl testosterone—25 mg daily sublingually. Anabolic steroid, i.e., stanazolol may be of some help.
8. Rifampicin 300-450 mg/day orally may relieve pruritus within one week. It is a hepatotoxic drug (recently introduced in the therapeutic armamentarium of pruritus in cholestasis).
9. Biliary drainage (internal or external).
10. Phototherapy—UV radiation for 9-12 minutes/day improves pruritus.
11. Plasmapheresis—rarely utilised in severe intractable itching.
12. Hepatic transplantation—Probably the only answer in chronic intractable pruritus.

CHRONIC HEPATITIS

Bilirubin	- 7.1 mg/dl
Conjugated	- 5.2 mg/dl
Unconjugated	- 1.9 mg/dl
SGPT (ALT)	- 360 IU/L
SGOT (AST)	- 324 IU/L
Alkaline phosphatase	- 142 IU/L
Total protein	- 5.9 g/dl
Albumin	- 2.9 g/dl
Globulin	- 3 g/dl
Prothrombin time	- 17 seconds
Australia antigen	- Positive
IgG anti-HBc	- Positive
HB_eAg	- Positive
Anti-HCV	- Negative
Antinuclear factor (ANF)	- Negative

Interpretation :

1. Serum bilirubin is moderately increased with predominant conjugated hyperbilirubinaemia. Both SGPT (ALT) and SGOT (AST) are raised but ALT level is > AST level. Serum alkaline phosphatase is also elevated.
2. Total protein is a bit subnormal as a result of hypoalbuminaemia. Serum globulin is within normal limit. Albumin : globulin ratio is approximately 1 : 1 ; prothrombin time is just elevated by 1 second over the highest limit of normal.
3. Australia antigen is found with evidence of (IgG anti-HBc) chronic infection by type B hepatitis virus. HB Ag is also positive. Marker of type C virus is not found. ANF is absent.

Inference :

There is conjugated hyperbilirubinaemia. Serum transaminases are 8-9 times more than normal. Serum alkaline phosphatase is slightly elevated. Hypoalbuminaemia with just raised prothrombin time indicates hepatocyte damage.

Positive HB_gAg and IgG anti-HBc indicate chronic HBV infection; Presence of HB_eAg indicates replication of HBV (i.e., highly infective). Markers of HCV and autoimmunity (ANF) are not found.

Thus, it seems that the patient is suffering from chronic hepatitis as a result of type B virus infection of high infectivity.

* If cirrhosis develops from chronic hepatitis, SGOT (AST) tends to exceed SGPT (ALT). Classically, in type B induced chronic hepatitis, SGPT (ALT) tends to be elevated more than SGOT (AST).

AETIOLOGY OF CHRONIC HEPATITIS :

1. Hepatitis B, C, and D.
2. Autoimmune hepatitis (lupoid hepatitis).
3. Wilson's disease.
4. Alcoholic liver disease, non-alcoholic steatohepatitis (NASH), cXj-antitrypsin deficiency, ulcerative colitis.
5. Drug e.g., methyl dopa, oxyphenisatin, INH, nitrofurantoin, ketoconazole.
6. Cryptogenic.

COMMON TYPES OF CHRONIC HEPATITIS :

Chronic hepatitis is the chronic inflammatory reaction in the liver continuing without improvement *Jor more than 6 months.* 'Liver biopsy' confirms the diagnosis. The types are :

1. Chronic lobular hepatitis—Histology resembles unresolved acute viral hepatitis.
2. Chronic persistent hepatitis—The limiting plate between hepatocytes and portal zones remain intact, and piecemeal necrosis is not seen. There is expansion of the portal zone by infiltration with mononuclear cells.

3. Chronic active hepatitis (severe form)—Prognostically grave. There is erosion of limiting plate, presence of piecemeal necrosis, formation of 'rosette" and bridging necrosis.

This classification is not helpful for prognostication. The new classification of chronic hepatitis is based on 1. Aetiology, 2. Clinical grade, 3. Histological grade, and 4. The stage (extent of fibrosis).

SIGNIFICANCE OF SEROLOGICAL MARKERS IN TYPE B INFECTION :

HB Ag -> Acute hepatitis B; persistence indicates infectivity and ongoing viral replication

IgG anti-HBc -» Past exposure to hepatitis B or chronic HBV infection

IgM anti-Hbc -> Acute HBV infection

DNA polymerase and HBV DNA -> Indicates ongoing viral replication

Anti-HBe -> late acute or chronic hepatitis B of low infectivity

Anti-HBs -> Immunity to HBV (i.e., vaccinated or previouus exposure)

AUTOIMMUNE HEPATITIS :

The aetiology is unknown but prominent immunological changes are noted in liver and blood. The patient is usually a female in the age group of 15-25 years or at menopause.

Serum transaminases are 10 times high with gamma globulin level 2 times more than normal. Serum ANF is positive; anti-smooth muscle and anti-LKM, antibody may be positive. The patient shows dramatic response to corticosteroid.

LINE OF TREATMENT IN HVB/HCV INDUCED CHRONIC HEPATITIS :

1. Treatment of hepato-cellular failure.
2. Pegylated a-interferon is used to prevent ongoing viral replication .
3. Other antiviral drugs like lamivudine, famciclovir, adefovir dipivoxil, entecavir, fialuridine, adenine arabinoside (a purine nucleoside) may be tried.
4. A patient of chronic hepatitis or cirrhosis of liver should be screened at 6-monthly interval for the development of hepato-cellular carcinoma by serial measurement of serum a,-fetoprotein.

FEW VALUABLE INFORMATIONS

Table 19 : Serum 'tumour markers'

	Carcinoma			Tumour markers
a)	Testicular (germ cell)	—»	a)	Alpha-1 -fetoprotein (AFP), P-human chorionic gonado-trophin (P-HCG)
b)	Ovary	—>	b)	CA-125
c)	Prostate		c)	Prostate spicific antigen (PSA)
d)	Choriocarcinoma	-H.	d)	p-HCG
e)	Hepato-cellular	->	e)	AFP
f)	Colorectal		f)	Carcinoembryonic antigen (CEA)
g)	Breast	—>	g)	CA-15-3
h)	G.I. tract carcinoma, especially pancreas ->		h)	CA-19-9
i)	Many cancers including mesothelioma		i)	Osteopontin

* These are intracellular proteins or cell surface glycoproteins released into the circulation from internal malignancy, and detected by immunoassays.

Lipid profile :

Normal range :
Total cholesterol : < 200 mg/dl (desirable)
Low density lipoprotein (LDL) : < 100 mg/dl (optional)
High density lipoprotein (HDL) : 40-60 mg/dl
Very low density lipoprotein (VLDL) : 35-100 mg/dl
Triglycerides (TG) : < 165 mg/dl

Lactate dehydrogenase (LDH) isoenzymes :

LDH_1 : 14-26% (cardiac, RBCs)
LDH_2 : 29-39% (cardiac, RBCs)
LDH_3 : 20-26% (pulmonary)
LDH_4 : 8-16% (striated muscle, liver)
LDH_S : 6-16% (striated muscle, liver)

Protein electrophoresis :

Albumin	normal range 3.5-5.5 g/dl
Globulin	normal range 2-3.5 g/dl
ft,	normal range 0.2-0.4 g/dl
	normal range 0.5-0.9 g/dl
P	normal range 0.6-1.1 g/dl
y	normal range 0.7-1.7 g/dl

Immunoglobulins :

Normal range of,
IgG : 700-1700 mg/dl
IgA : 70-350 mg/dl
IgM : 50-300 mg/dl
IgD : 0-14 mg/dl
IgE : 10-179 mg/dl

Arterial blood gases :

Po_2 : 95 ± 5 mm of Hg
Pco_2 : 40 ± 2 mm of Hg
Arterial 0_2 saturation 97 + 2%
HCo_3 : 22-26 meq/1
p^H : 7.38-7.44

Haemoglobin electrophoresis :

HbA_1 : 95-98% (97%)
HbA_2 : 1.5-3.5% (2.5%)
HbF : < 2%
HbC and HbS : absent

Creatine kinase (CK, CPKj isoenzymes :

a) CK-MB : Increased in AMI, myocarditis, pericarditis, cardiac defibrillation, cardiac surgery, cardiomyopathy, severe rhabdomyolysis, strenuous exercise (e.g., marathon runners).

CK-MB has two subforms : MB! and MB_2 (MB_2 is released from cardiac cells and converted in the blood to MB_1). CK-MB_2 > 1.0 U/L, with a ratio of CK-MB_2/CK-MB, > 1.5 diagnoses AMI within 6 hours of onset of symptoms.

b) CK-MM : Increased in crush injury, convulsions, rhabdomyolysis, polymyositis and dermatomyositis, I.M injections, muscular dystrophy (myopathy), drugs (e.g., statins, colchicine).

c) CK-BB : Increased in CVA, meningitis; severe shock; neoplasm of breast, prostate and lung.

C-reactive protein (CRP):

Normal range : < 5 mg/L

It is a trace plasma protein which increases in response to infection, trauma, tissue necrosis and inflammation. The CRP level correlates better than the ESR with the changing disease activity in different rheumatic diseases.

It is elevated in :

Rheumatoid arthritis, rheumatic fever, bacterial infections, inflammatory bowel disease, third trimester of pregnancy, different inflammatory and neoplastic diseases, AMI. In SLE, the CRP is not elevated and thus the concentration of CRP is often used to distinguish infection in SLE (high) from disease activity (not high).

High sensitivity C-Reactive protein (hs-CRP or cardio-CRP) is a new test to diagnose pateint with silent atherosclerosis. The risk of cardiovascular event increases if it is > 1.1 mg/L.

Rheumatoid factor:

Normally : negative

Titres > 1:40 are considered significant and are found in (i.e., rheumatoid factor is elevated in) rheumatoid arthritis, SLE, vasculitis e.g., polyarteritis nodosa, old age, infections (e.g., SBE, syphilis, leprosy), chronic liver disease, sarcoidosis, Sjogren's syndrome, pulmonary fibrosis.

Antinuclear antibody (ANA):

Normal range : < 1:20 titre

ANA is positive in SLE (more significant if titre is > 1:160), drug-induced lupus, mixed connective tissue disease, scleroderma, rheumatoid arthritis, chronic autoimmune hepatitis, Sjogren's syndrome, necrotizing vasculitis, old age (> 80 yrs), HIV infection, bacterial endocarditis, interstitial pulmonary fibrosis.

International normalised ratio (INR) :

The INR is a comparative rating of prothrombin time (PT) ratios. The INR represents the observed PT ratio (i.e., patient's prothrombin time divided by normal pooled plasma prothrombin time) adjusted by the International Reference Thromboplastin. This method was adopted by WHO in 1982 and is used to standardize the reporting of PT. That means the INR is the PT ratio that would be obtained if the WHO reference thromboplastin, which by definition has an ISI (International Sensitivity Index) of 1.0 were used to assess PT.

Disorder	**Recommended INR range**
TLA	2-3
Atrial fibrillation	2-3
Pulmonary embolism	2-3
Deep vein thrombosis	2-3
Mechanical prosthetic valves	3-4.5
Recurrent venous thromboembolism	3-4.5

Leucocyte alkaline phosphotase (LAP) score :

Increased in : leukaemoid reaction, neutrophilic leucocytosis from infections, after steroid administration, Hodgkin's disease, polycythemia vera, myelosclerosis, hairy cell leukaemia.

Decreased in : Chronic myeloid leukaemia, paroxysmal nocturnal haemoglobinuria, thrombocytopenic purpura, hypophosphataemia.

Antineutrophil cytoplasmic antibodies (ANCAs):

p-ANCA or antimyeloperoxidase ('p' stands for perinuclear pattern): found in microscopic polyarteritis, crescentic glomerulonephritis, Churg-Strauss syndrome, inflammatory bowel disease, primary sclerosing cholangitis, primary biliary cirrhosis, autoimmune chronic active hepatitis.

c-ANCA or antiproteinase-3 ('c' stands for cytoplasmic pattern): found in Wegener's granulomatosis.

a,-fetoprotein :

Normal range : 0-15 ng/ml

Increased in : hepato-cellular carcinoma (usually with values > 1000 ng/ml), germinal neoplasia (ovary, testis, retroperitoneum), hepatic disorders (alcoholic cirrhosis, chronic active hepatitis), anencephaly of fetus, spina bifida, pancreatic carcinoma, retinoblastoma, atresia of oesophagus.

INCUBATION PERIOD OF SOME IMPORTANT INFECTIONS

AIDS	uncertain (few month to 6 years or more)
Amoebiasis	3-4 weeks
Bacillary dysentery (shigellosis)	1-7 days
Brucellosis	1-3 weeks
Chickenpox	12-21days
Cholera	few hours to 5 days
Dengue	2-7 days
Diphtheria	2-5 days
Encephalitis (Japanese)	9-12 days
Enteric fever	10-14 days
Gonorrhoea	2-10 days
Hepatitis A	2 to 6 weeks
Hepatitis B	6 weeks to 6 months
Influenza	2-3 days
Kala-azar	usually 3-6 months
Leprosy	3-5 years
Leptospirosis	4-20 days
Malaria	usually 8-14 days (rarely upto months)
Measles	7-14 days
Meningitis (meningococcal)	2-10 days
Mumps	2-3 weeks
Plague	1-7 days
Poliomyelitis	3-21 days
Rabies	usually 1-3 months
Rubella	2-3 weeks
Syphilis	9-90 days
Tetanus	3 days to 3 weeks
Tuberculosis	months to years
Whooping cough	7-14 days

THERAPEUTIC AND TOXIC BLOOD LEVELS OF COMMONLY USED DRUGS

	Therapeutic level	Toxic level
Amitriptyline	150-250 ng/ml	> 500 ng/ml
Carbamazepine	4-12 ng/ml	> 15 ng/ml
Chlordiazepoxide	700-1000 ng/ml	> 5000 ng/ml
Diazepam	100-1000 ng/ml	> 5000 ng/ml
Digoxin	0.8-2 ng/ml	> 2.5 ng/ml
Ethanol	—	> 300 mg/dl
Lithium	0.6-1.2 meq/1	> 2 meq/1
Phenobarbital	15-35 ng/ml	> 60 ng/ml
Phenytoin	10-20 ng/ml	> 20 ng/ml
Quinidine	2-5 fig/ml	> 6 ng/ml
Salicylate	150-300 |ig/ml	> 300 ng/ml
Theophylline	5-20 ng/ml	> 20 ng/ml
Valproic acid	50-150 ng/ml	> 150 ng/ml

IMPORTANT HAEMATOLOGICAL DATA

RBC count :	
Males	4.5-6.3 millions/mm^3
Females	4.2-5-4 millions/mm^3
Reticulocyte	0-2-2% of RBC
Red blood cell volume :	
Males	30 ml/kg of body weight
Females	25 ml/kg of body weight
Osmotic fragility of RBC :	
Slight haemolysis	0-45-0-39%
Complete haemolysis	0-33-0-30%
Haemoglobin :	
Males	14-6-15-5 g/dl
Females	13-3-14-6 g/dl
Haematocrit :	
Males	42-52%
Females	37-47%
MCH	29-5 ± 2.5 pg
MCHC	35 ± 3 g/dl
MCV	87 ± 7 cubic micron
WBC count (total)	4-3-10.8 x 10^9/L
Differential WBC count:	
Neutrophils	45-74% of total WBC
Lymphocytes	16-45% of total WBC
Monocytes	4-10% of total WBC
Eosinophils	0-7% of total WBC
Basophils	0-1% of total WBC
Platelet count	1-5-4 lacs/mm^3
Bleeding time (Ivy)	2-5-10 minutes
Coagulation time (glass tubes)	9-15 minutes
Prothrombin time	12-16 seconds
Partial thromboplastin time (activated)	32-46 seconds
Clot retraction time	onset-1 hour, completion-6 hours
ESR (Westergren):	
Males	0-15 mm/hour
Females	0-20 mm/hour
p^H (arterial blood)	7-38-7-44
Red cell life span	120 days
Red cell life span $T_{1/2}$ $t^{51}Cr$)	25-35 days

APPROXIMATE CONVERSION CHART

1 ounce (oz)	28 ml
1 gallon (gal)	4.5 litres
1 inch (in)	2.54 cm
1 foot (ft)	0.3 m
1 pound (lb)	0.45 kg
1 calorie (cal)	4.2 J

IMPORTANT SERUM BIOCHEMICAL VALUES

Albumin	3-5-5-5 g/dl
Aminotransferases :	
AST (SGOT)	0-40 U/L
ALT (SGPT)	0-40 U/L
Ammonia	10-80 mg/dl
Amylase	20-96 U/L (method-dependent)
Bicarbonate	22-26 meq/L
Bilirubin :	0-3-1-0 mg/dl
Conjugated	0-1-0-3 mg/dl
Unconjugated	0-2-0-7 mg/dl
Calcium (total)	9-11 mg/dl
Calcium (ionised)	4-5-5-6 mg/dl
Chloride	98-106 meq/L
Cholesterol (total)	upto 200 mg/dl
Copper	70-140 |ag/dl
Cortisol :	
8 A.M.	5-25 ng/dl
4 P.M.	2-15 ng/dl
Creatinine	0-6-1.2 mg/dl
Creatinine kinase (CK, CPK)	55-170 U/L
CK-MB	< 6% of total CK
Ferritin	30-300 ng/ml
Folate	5.4-18 ng/ml
Globulin	2-3-5 g/dl
Glucose (fasting)	75-100 mg/dl
Glucose (2 hour postprandial)	<140 mg/dl
Hb A_{1C} (glycated Hb)	4-6% of total Hb
Insulin	2-20 (xU/ml
Iron	70-140 ng/dl
Lipase	3-43 U/L (method-dependent)
Lactate dehydrogenase	100-190 U/L
Osmolality	280-300 mosmol/kg
Oxygen content:	
Arterial blood	17-21 volume %
Venous blood	10-16 volume%
Phosphatase:	
Acid	1-5 U/L
Alkaline	35-130 U/L
Phosphate	3-4-5 mg/dl
Potassium	3-5-5 meq/L
Prolactin	2-15 ng/ml
Protein (plasma)	5-5-8-0 g/dl
Sodium	136-145 meq/L
Triglyceride	< 165 mg/dl
TSH	0.3-5 nU/ml
T_3 (triiodothyronine)	80-150 ng/dl
T_4 (thyroxine)	4-12 |ig/dl
Urea	20-40 mg/dl
Uric acid	2-7 mg/dl
Vitamin B_{12}	200-600 pg/ml

YOUR ORAL TABLE

1. You should look smart and confident.
2. Always be well-dressed with a clean shave.
3. Have a clean apron with I.D card bearing university roll number.
4. Avoid all sorts of casual attitude. Maintain etiquettes of the examination hall.
5. Do not chew any type of masala or chewing gum. Switch off your mobile phone.
6. Listen the question carefully and then answer 'to the point'. Speak out clearly, slowly and precisely but always try to keep the flow.
7. Try to answer in the order of frequency i.e., from more common to less common causes, and avoid rare ones. Do not hurry, rather show patience.
8. It is better to say, 'I can not recollect' or 'I am no sure' instead of going on thinking indefinitely.
9. Never argue with your examiner.
10. Answering simple questions usually gives guarantee for 'passing'. So do not cheat, do not guess, do not be biased.

MODEL DISTRIBUTION OF MARKS FOLLOWING RECOMMENDATION OF MCI

General Medicine : Full marks 300

Theory : Paper I + Paper II = 60 + 60

Internal assessment : 60 (theory 30 + practical 30)

Oral (including X-ray and CT, ECG, instruments and specimens, charts, medical emergency) : 20

Clinical (bedside) : 100 (one long case 60 + one short case 30 + two spot cases 10)

* Marks distributed in the long case (60) as follows : History 15 + demonstration of signs 25 + discussion and crossing 20

** Internal assessment : Distribution of marks (60) will be as follows : Medicine 40 + dermatology (including STD) 10 + psychiatry 5 + chest and TB 5

*** Criteria to pass in the examination :

Aggregate 50% i.e., 150 marks

Theory and oral (including internal assessment) 50% i.e., 100 marks

Practical (bedside clinics) 50% i.e., 50 marks

N.B. : One should get 50% in internal assessment to pass in the examination

Theory part :

Paper I— CVS, respiratory system, haematology, neurology, endocrinology and rheumatology

Paper II— Tropical diseases, gastro-intestinal, and diseases of liver and biliary system, renal diseases, metabolic and nutritional diseases, poisoning and environmental diseases, psychiatry, dermatology including STD

****Each theory paper usually contains 4 short questions (4 x 10) and short notes (5 short notes x 4).. Short questions are short-structured essay type and problem-oriented type. There may be overlap in Paper I & II.

***** Acute cases (e.g., LVF, acute severe asthma) are usually not given in the examination.

Long case comprises of history writing + demonstration of signs + relevant discussion.

Short case means general survey and examination of one particular system (nothing to be written).

Spot case means spotting the diagnosis (with examiner observing) and mentioning its justification.

INDEX

A

ACE-inhibltors. 162, 165, 206
Achalasia cardia 104
Acidosis 26
Adenosine 133, 196, 213
Adenosine deaminase 274
Agranulocytosis 238
Air bronchogram 80
Airway tube 53
Alkalosis 26
a-fetoprotein 306-308
Alprazolam 218
Amantadine 220
Ambu bag 57
AMI 128-130, 164
Aminophylline 29, 159, 204
Amitriptyline 181, 217, 309
Amiloride 208
Amiodarone 196, 212
Amlodipine 206, 209
Amoebiasis 74, 185, 186, 253
Anaemia 191, 229, 231, 232, 237, 241, 265
Anaphylaxis 29, 157, 161, 192
ANCA 308
Angina pectoris
    stable 128, 164, 209
    unstable 167, 168
    prinzmetal 168
Anion gap 26
Antibiogram 258
Anticoagulants 230
Anti-5HT drugs 215
Antihistaminics 215
Antinuclear antibody (ANA) 308
Anuria 8, 258
Aplastic anaemia 237
Arteether 226
Artemether 226
Artesunate 226
Ascitic tapping 60
Aspirin 164, 166, 167, 179, 213
Asthma
    bronchial 157, 159, 204
    cardiac 94, 157, 158
Atherosclerosis 71
Atrial fibrillation 133, 165, 211-213
Atrial flutter 134, 165, 211-213
Atropinisation 198
Auscultation 40
Auscultatory gap 43
Axis deviation 116, 117

B

Basal ganglia calcification 114
Basophilia 236
Basophilic stippling 243
Bazett's formula 124
Bence Jones protein 107
Benedict's test 250, 260
Benzidine test 260
Beta-blockers 133, 162, 202, 206
Bifascicular block 137, 139
Biochemical values, serum 311
Blast crisis 234
Blood pressure 40-45, 168-170, 205
Blood transfusion 27, 191-193
Blood transfusion set 22
Bradycardia 131, 165, 170, 291
Bradycardia-tachycardia syndrome 144
Brain abscess 70, 150, 178
Brainstem functions 153
Bromocriptine 154, 220
Bronchiectasis 66, 84
Bronchogenic carcinoma 67, 92, 93, 95, 96
Blullae 67, 88, 295
Bullus lesion, skin 295

C

Calcification
    abdomen 101
    cheSt 92
Captopril 166, 206
Capture beats 136
Carbamazepine 167, 219, 309
Cardiac arrest 194
Cardiac asystole 194
Cardiac failure, congestive (CCF) 161, 213
Cardiac neurosis 163, 167
Cardiac silhouette 77, 78
Cardiogenic shock 165
Cardiomegaly 99, 126
Cardiomyopathy 99
Cardiopulmonary resuscitation (CPR) 194
Cardiospasm 104
Cardiothoracic ratio 77
Casts 259, 264
Catheter, simple rubber 6
Cavity, pulmonary 66, 85-87
Cerebellar cone syndrome 16, 17
Cerebral embolsim 179
Cerebral haemorrhage 179
Cerebral malaria 174
Cerebral oedema 178
Cerebral thrombosis 179
Cerebrovascular accidents 149, 150, 179
Charts 229-306
Chickenpox 294, 295
Chloroquine 173, 186, 225
Cholera 189
Cholestasis 303, 304
Chvostek's sign 48
Ciprofloxacin 178, 186, 187, 222
Cirrhosis of liver 73, 302
CLO test 102
Clofazimine 223

Clopidogrel 167, 179
Coagulum
big 20, 270
cobweb 20, 270, 273
Cockcroft-Gault equation 261
Coin lesion 93
Collapse of the lung 88
Colloid 22
Colony count, urine 268
Coma
diabetic 150, 154
hepatic 150, 153
hypoglycaemic 155
management 151
myxoedema 171
psychogenic 153
Compensatory pause 132, 135
Complete heart block 142, 170, 171
Condom 52
Conducting system, heart 137
Consolidation of the lung 64, 80
Convulsions, febrile 180
Cor pulmonale 127, 128, 160
Cotton 49
CPR 194
C-reactive protein 308
Creatinine clearance 261
Creatine kinase 165, 307
Crystalloid 22
CSF 16-21, 270-280
CT scan 112
Cut-down 112
Cut-down 23, 30
CVA 149, 179
Cytokines 283

D

Dacca solution 189
Dapsone 223
Darrow's solution 23, 24
Deafness 47
Decannulation 6.
Dehydration 24, 36, 186, 189
Delta wave 143
Dengne 297, 298
Dextrocardia 76, 147
Diabetes mellitus 154, 155, 245, 251, 269
Diaphragm 76, 79, 93
Diarrhoea 36-38, 185, 189, 253, 255
Diazepam 180, 181, 216, 219
Digoxin 145, 162, 213, 309
Diltiazem 210, 212
Diphtheria 50
Disopyramide 211
Diuretics 161, 208
Dobutamine 202
Dock's sign 95
Dog bite 200
Doll's-eye movement 153
Dopamine 160, 165, 202
Drip tube 22
Drugs 202-228
Dry tap
humbar puncture 18
sternal puncture 11
Duodenal cap 102
Duodenal ulcer 102
Dumping syndrome 250
Dysentery
amoebic 37, 73, 185, 253, 255
bacillary 37, 73, 185, 254, 255

E

ECG 115-149
Einthoven triangle 116
Electrical alternans 145
Electrophoresis
haemoglobin 307
protein 107, 307
Emphysema 67, 83, 120
Endocarditis 71
Endotracheal tube 57
Enteric fever 73, 178, 187, 286-288, 290, 291
Eosinophilia 240
Epilepsy 180, 218
Escitalopram 217
Ethambutol 221
Extrasystoles 132, 134
Ezetimibe 228

F

Fab classification 234
Fasting test 302
Femoral tap 29
Fenofibrate 227
Ferrokinetics 232
Fibrosis of the lung 88
Fluoxetine 217
FNAC 15
Folic acid 233, 311
Froin's syndrome 280
Fusion beats 136

G

Gabapentin 219
Gastric outlet obstruction 105
Gastric ulcer 102
GFR 261
Giardiasis 256
Gilbert's syndrome 302
Glomerular functions 261
Glomerulonephritis
acute 67, 182, 260
chronic 68, 263
Glucose tolerance test
impaired 245, 247
normal 245, 246
Glycosuria
alimentary 249
pregnancy 250
renal 248, 250
Guaiac test 257
Gumma 72

H

Haematemesis 184
Haematocrit 229, 310
Haematological data 229, 230, 310
Haemoptysis 91, 190
Haemorrhagic fever 298
Halofantrine 226
Hammer 48
Hanging-drop preparation 253
Hay's surface tension test 260
Heart block
  atrioventricular 140, 143
  bifascicular 139
  complete 142
  first degree 140
  LBBB 138
  RBBB 138
  SA block 143
  second degree 141
  trifascicular 137, 140
Heart failure
  acute LVF 94, 158
  congestive cardiac failure 99, 161
  refractory 162
  RVF 161
Heart rate, ECG 118, 123
Heat coagulation test 260
Heatstroke 175
Heimlich's manoeuvre 194
Helicobacter pylori 100-102
Hepatisation 64
Hepatitis
  acute 187, 300
  autoimmune 305, 306
  chronic 305
Herpes zoster 167
Hiccough 183
Hilar enlargement 93
Hoi ter monitoring 116, 143, 144
Honeycomb lung 85
Hydralazine 169, 207
Hydropneumothorax 83
Hyperbilirubinaemia
  conjugated 301
  unconjugated 301
Hyperchlorhydria 3
Hyperdefecation 37
Hypereosinophilic syndrome 241
Hyperglobulinaemia 303
Hyperkalaemia 27, 32, 146
Hypernatraemia 27
Hypernephroma 69
Hyperpyrexia 152, 172, 175, 281, 284
Hypertension 40-45, 168, 205
Hypertensive emergency 168
Hypertensive encephalopathy 168, 169, 180
Hypertrophy
  atrial 78, 119, 126
  ventricular 78, 126, 127
Hyperventilation, hysterical 153, 157, 161
Hyperviscosity syndrome 107
Hypochlorhydria 3
Hypoglobulinaemia 303
Hypoglycaemia 150, 155
Hypoglycorrhachia 272
Hypokalaemia 27, 147
Hyponatraemia 24, 27
Hypothermia 144, 152, 172, 281, 284
Hypoventilation 153

I

Idioventricular rhythm 137, 142
Imipramine 217
Immunoglobulins 107, 307
Increased intracranial tension 178, 179
Incubation period 309
Infusion set 22
INH 177, 221
Inhalers 54, 55
INR 308
Instruments 1-63
Insulin 32-35, 311
Intracath 53
Intrinsicoid deflection 124
Isosthenuria 264
I.V fluid bottles 22

J

J-point 121
Jaundice 150, 153, 299, 300-306
Jerks 48
J wave 144

K

Kala-azar 10, 224, 289
Kartagener's syndrome 84
Katz-wachtel phenomenon 127
Kerley's lines 96
Ketoacidosis, diabetic 155, 269
Kidney
  flea bitten 69
  granular contracted 68
  large white 68
  polycystic 69
Koplik's spot 293
Korotkoff sounds 42

L

Labetalol 169, 207
Lactic acidosis 157
Lactulose 154
Lag storage, curve 249
LAP score 308
Laryngeal obstruction 5
Leprosy 223
Leukaemia
  acute 10, 234
  chronic 235
Leukaemoid reaction 234, 236, 308
Levodopa 154, 220
Lie, heart 118
Life support
  advanced 194
  basic 194

Lignocaine 195, 201, 211
Lipid profile 179, 307
Lithium 217, 309
Liver abscess
    amoebic 28, 30, 74, 186
    pyogenic 74
Liver biopsy 12-15
Liver function tests 299
Lock-jaw 50, 51
Loperamide 186
Losartan 207
L-thyroxine 171, 311
Lumbar puncture 15-21
Lung abscess, pyogenic 65, 85
LVF 94, 158
Lymphangitis carcinomatosa 92, 97
Lymphoblast 235
Lymphocytosis 239

M

Malaria
    benign tertian 173, 282, 283
    cerebral 174, 177
    malignant 173, 283
Mannitol 154, 176, 178, 209
Mantoux test 32, 90, 91
Marble's criteria 248
M-band 107
Measles 292
Measuring tape 49
Mediastinal widening 92
Mediastinum 76, 78, 92
Medical emergencies 150-201
Mefloquine 173, 226
Melaena 184, 257
Melituria 250
Meninqism 20, 21, 178, 276
Meningitis
    aseptic 272, 276
    bacterial 20, 70, 176, 271
    fungal 276
    recurrent 272
    tuberculous 20, 70, 177, 273
    viral 21, 177, 275
Meningoencephalitis 177
Mentzer index 231
Meteorism 286
Metered dose inhaler 54
Metronidazole 154, 185, 186
Microalbuminuria 269
Micro-drip set 22
Migraine 181
Miliary mottlings 91
Miltefosine 224
Minnesota tube 185
Mitral stenosis 96, 119, 120
Mitralisation 96, 97
Mobitz block 140, 141
Monocytosis 239
Morphine 164, 166, 214
MRI scan 113
Mucus, stool 254, 255
Multiple myeloma 106
Murphy's chamber 22
Muscarinic effects 198
Myeloblast 235
Myeloproliferative diseases 236
Myocardial infarction, acute 128-130, 164
Myxoedema coma 171

N

Nebuliser 55
Neck, rigidity 20, 175
Needle 30
Ncomycin 154
Nephrotic syndrome 262
Neurosyphilis 276
Nicorandial 210
Nicotinic acid 228 •
Nicotinic effects 198
Nifedipine 164, 167, 169, 205, 209
Nimesulide 214
Nitroglycerine 164, 166, 169, 209
Nitroprusside, sodium 169, 207
Nodal rhythm 137
Norfloxacin 182

O

Occult blood, stool 256
Oculocephalic reflex 153
Oculovestibular reflex 153
Oesophageal carcinoma 103
Oesophageal varices 103, 184, 185
Olanzapine 217
Oligaemia, pulmonary 98
Oliguria 258
Oral rehydration salt 36
Organophosphorus poisoning 150, 198
Orthotoluidine test 252, 253, 254, 256, 260
Osborne wave 144
Osmolality 37, 259
Osteosclerosis 107
Oximes 198, 203

P

Pacemaker 137, 149
Pancarditis 71, 196
Pancreatitis, acute 188
Pancytopenia 237-239
Paracentesis abdominis 60
Paracetamol 173, 213
Paraneoplastic syndrome 95
Paraprotein 107
Parenteral nutrition 27
    Paroxysmal atrial tachycardia (PAT) 132, 133, 146, 195
Patch tonsil 50
pemphigoid 295
Pemphigus 295
Pentazocine 214
Peptic ulcer disease 100-103, 184, 185
Pericardial effusion 62, 98, 99, 148

Pericardiocentesis 62
Pericarditis 71, 148, 167
Periodic fever 298
Peritoneal biopsy 61
pethidine 158, 215
petit heart 83
Phenobarbitone 180, 218, 309
Phenothiazines 216
Phenytoin sodium 181, 212, 218, 309
Philadelphia chromosome 236
Phosphate, alkaline 107, 111, 299
Pin 48
Plasmodium
falciparum 173, 174
ovale 173
vivax 173
Pleocytosis, CSF 271, 273
Plethora, pulmonary 98
Pleural biopsy 62
Pelural effusion 61, 80
Pleurisy 167
P-mitrale 119, 126
Pneumonia 64, 80, 296
Pneumothorax 82
Polyuria 258
Postural drop 44
P-pulmonale 119, 127, 128
PR interval 115, 123
Pre-diabetes 245, 247
Pre-excitation 143
Pregabalin 219
Premature beats
atrial 132
ventucular 134
Primaquine 173, 225
Procainamide 211
proctoscope 56
proteinuria 259, 260, 263
Prothrombin time 244, 299, 304, 308, 310
Pruritus 304
Pseudocavity 87
Pseudomonas aeruginosa 176, 177
Pulmonary hypertension 97, 120
Pulmonary nodule 93
Pulmonary oedema 94, 157, 158
Pulmonary thromboembolism 128, 157, 160
Pulmonary tuberculosis 65, 89-92, 190
Punctate basophilia 243
PVO 289
Pupils 150, 153
Purpura 243, 244
Pyelonephritis, acute 182, 267, 268
Pyloric stenosis 105
Pyrazinamide 177, 221
Pyrexia
intermittent 281-285
continued 285
remittent 288
unknown origin 289
Pyrogens 283
Pyuria 269

9

QRS interval 124
QT interval 115, 124
Queckenstedt's test 18, 21, 280
Quinidine 146, 211, 309
Quinine 173, 174, 225

R

Rabies 200
Radiology 75-114
Ranolazine 210
Record syringe 10, 29
Rectal biopsy 57
Renal biopsy 58
Renal failure
acute 261, 262, 265
chronic 107, 263-266
Renal functions, assessment 261
Renal pain 268
Renal threshold 246, 248
Retie index 229
Reticulocyte 229, 242, 310
Retinopathy, hypertensive 45
Rheumatic fever 196
Rhumatic heart disease 70, 196
Rheumatoid factor 308
Rhythm disturbances 125, 130-137
Rib erotion 95
Rib notching 95
Rickets 110
Rifampicin 177, 221
Ring lesion, CT brain 114
Ringer's lactate 23, 24
Rinne's test 47
Rose spots 287, 290
Rosuvastatin 227
Rotahaler 55
Rotation, heart 118
Rotch's sign 78, 98
Rothera's test 250, 260
RR interval 123
Ryle's tube 1-3

S

Saline, normal 23
Salt restriction 161, 163
Scalp vein set 31
Scorpion bite 200
Scurvy 109
Seizures 180
Selegiline 220
Sengs taken tube 185
Sertraline 217
Shigellosis 73, 185, 254, 255
SLADH 178, 272
Sick sinus syndrome 144, 171
Sideroblast 242
Silhouette sign 80
Sinus arrhythmia 131
Sinus bradycardia 131
Sinus rhythm 130, 137
Sinus tachycardia 131

Smallpox 295
Snake bite 198
Sodium antimony gluconate 224
Sodium bicarbonate 156, 157
Sodium valproate 219, 309
Spacehaler 55
Spatula 50.
Spatula test 51
Sphygmomanometer 40-45
Standardisation, ECG 125
Statins 166, 227
Status epilepticus 180
Sternal puncture 9-12
Stethoscope 39
Stokes-Adams syndrome 142, 149, 150, 152, 170
Strain pattern, ECG 122, 126, 127
Streptokinase 165, 166
Streptomycin 177, 221
Stress ulcer 103
Stroke 149, 179
Subarachnoid haemorrhage 21, 149, 180, 277
Supraventricular tachycardia 132
Syringe 28-31
$_{8,93}X_3$ pattern 128, 139
S,S_2S_3 syndrome 127

T

Tachyarrhythmias 132-137
Tachypnoea 296
Tape (measuring) 49
Target cell 242
Temperature 45, 46, 172, 175, 281-298
Terbutaline 159, 204
Test tube 51
Tetanus 51, 197
Thalassaemia 108, 241
Theophylline 30, 159, 204
Thermometer, clinical 45, 281
Thickened pleura 81
Thoracentesis 61
Three-way cannula 35
Throat swab 49, 52
Thrombasthenia 244
Thrombocytopenia 243
Thrombocytosis 243
Thrombophlebitis 193
Tinidazole 185, 186
Tongue depressor 50
Tonsillitis 50
Torch 51
Torsades de pointes 136
Total parenteral nutrition 27
Tourniquet test 243, 298
T-P segment, ECG 121
Tracheostomy 4-6
Transaminases 299
Treadmill test (TMT) 125
Trifascicular block 137, 140
Triidothyronine 171, 311
Trismus 50, 51, 197
Tropical eosinophilia 91, 240
Tubercle $_{66}$, 72
Tuberculin syringe 32
Tuberculosis, diagnosis 91
Tuberculous infiltrations 89
Tubular functions 261
Tumour markers 307
Tuning fork 46
Typhoid meningism 175, 178
Typhoid state 178, 287

U

U-wave 115, 121
Ulcer disease
    duodenal $_{102}$
    gastric $_{102}$
Urease test 102
Urinary pain 268
Urinary tract infection 182, 266
Urine tests (chemical) 260
Urokinase 165

V

Vaccination
    chickenpox 295
    measles 293
    typhoid 288
Vasopressin 184
VAT 124
Venesection 23, 30
Ventricular asystole 137, 194
Ventricular fibrillation 136, 194, 195
Ventricular flutter 136
Ventricular premature beats 134
Ventricular tachycardia 135
Verapramil 133, 196, 210
Vesicles, skin 295
Vibration sense 47
Vital signs 152
Vitamins
    B_{12} 233, 311
    C 109,110
    D 110, 111
Voltage, ECG 118, 120
Volumatic 55

W

Weber's test 47
Wenckebach block 140, 141
White cell count 229, 230, 310
Widal test 286, 287
W-P-W syndrome 143

X

Xanthochromia 21, 279
X-rays 75-114
Xylocaine 183, 195, 201, 211

Z

Zidovudine 177
Zolpidem 216
Zopiclone 216

Key Features of the Book

- A lucid, substantially revised and updated quick reference in medicine
- Common medical instrumental 'procedures'
- Key details of X-rays and CT scans
- Classic manual of electrocardiogram
- Major disease-oriented 'pathology specimens'
- Extensive discussion on emergency medical management
- Easy-to-use outline format of drugs
- Logical approach on data interpretations

About the Author

Professor Arup Kumar Kundu has been working as an internist for nearly 25 years and is renowned for his sharp clinical acumen, analytical approach and clarity of expression towards solving different problems in internal medicine. He is vibrant and innovative in his field, and has multifaceted personality. Dr. Kundu, an astute clinician and a dedicated teacher, has been teaching medicine to students, both undergraduates and postgraduates, and has been an examiner in different Indian Universities. He is well-known all over the country for his proficiency as an illustrious teacher in medicine. Dr. Kundu, a brilliant academician and an avid medical writer, has authored three other indispensable books entitled 'Bedside Clinics in Medicine, Part I', 'MCQs in Internal Medicine' and 'Pearls in Medicine for Students'. He is a gifted orator and has been invited as speaker / faculty in different State and National conferences. He has taken part in International symposia / seminars, and is credited with more than 80 publications in peer-reviewed journals. Dr. Kundu has contributed constructive articles in National daily / weekly, interviews in AIR / Doordarshan for common people. He has written sections on online appendix of Kumar and Clark's textbook 'Clinical Medicine', both in the 6th and the 7th edition, and is an Indian member, International Advisory Panel of the 7th edition of the book. He has also contributed chapter in API textbook of Medicine, the 8th edition. Dr. Kundu, known all over as 'clinical scientist', has been conferred the fellowship of the Indian College of Physicians (FICP) and the membership of prestigious New York Academy of Sciences (USA)

ISBN : 978-93-80599-22-9